

---

## MILITARY DERMATOLOGY

---



The Coat of Arms  
1818  
Medical Department of the Army

A 1976 etching by Vassil Ekimov of an original color print that appeared in *The Military Surgeon*, Vol XLI, No 2, 1917

---

The first line of medical defense in wartime is the combat medic. Although in ancient times medics carried the caduceus into battle to signify the neutral, humanitarian nature of their tasks, they have never been immune to the perils of war. They have made the highest sacrifices to save the lives of others, and their dedication to the wounded soldier is the foundation of military medical care.

---

# Textbook of Military Medicine

Published by the

*Office of The Surgeon General  
Department of the Army, United States of America*

Editor in Chief  
Brigadier General Russ Zajtchuk, MC, U.S. Army  
*Director, Borden Institute  
Commanding General  
U.S. Army Medical Research Development, Acquisition, and Logistics Command  
Professor of Surgery  
F. Edward Hébert School of Medicine  
Uniformed Services University of the Health Sciences*

Officer in Charge and Managing Editor  
Colonel Ronald F. Bellamy, MC, U.S. Army  
*Borden Institute  
Associate Professor of Military Medicine,  
Associate Professor of Surgery,  
F. Edward Hébert School of Medicine  
Uniformed Services University of the Health Sciences*

Scientific Advisor  
Donald P. Jenkins, Ph.D.  
*Deputy Director for Healthcare  
Advanced Research Projects Agency  
Department of Defense  
Adjunct Associate Professor of Surgery  
Georgetown University  
Visiting Associate Professor of Anatomy,  
F. Edward Hébert School of Medicine  
Uniformed Services University of the Health Sciences*

*The TMM Series*

**Part I.** *Warfare, Weaponry, and the Casualty*

Medical Consequences of Nuclear Warfare  
(1989)

Conventional Warfare: Ballistic, Blast, and Burn  
Injuries (1991)

Military Psychiatry: Preparing in Peace for War  
(1994)

War Psychiatry

Medical Aspects of Chemical and Biological  
Warfare

Military Medical Ethics

**Part II.** *Principles of Medical Command and Support*

Medicine and War

Medicine in Low-Intensity Conflict

**Part III.** *Disease and the Environment*

Occupational Health: The Soldier and the  
Industrial Base (1993)

Military Dermatology (1994)

Mobilization and Deployment

Environmental Hazards and Military Operations

**Part IV.** *Surgical Combat Casualty Care*

Anesthesia and Perioperative Care of the  
Combat Casualty

Combat Injuries to the Head, Face, and Neck

Combat Injuries to the Trunk

Combat Injuries to the Extremities and Spine

Rehabilitation of the Injured Soldier



This World War II scene painted by Franklin Botts, titled *Jungle—Ally of the Enemy*, exemplifies Major General Sir W. G. Macpherson's insight regarding the profound toll that dermatologic problems can take during wartime:

*Diseases of the skin ... are generally regarded as lesser maladies, that is to say, conditions which as a rule neither threaten life nor seriously impair health. For the individual this is true, but in the case of an army the collective results of such minor affections may become of high importance because, for military purposes, a man incapacitated for duty is a loss to the fighting force whatever the extent or cause of his personal disability.*<sup>1</sup>

—Major-General Sir W. G. Macpherson, K.C.M.G., C.B., L.L.D.

<sup>1</sup>In: Macpherson WG, Horrocks WH, Beveridge WW, eds. Medical Services. Hygiene of the War. In: *History of the Great War*: Vol. 1. London, England: His Majesty's Stationery Office; 1923: 68.

Painting: Courtesy of the U.S. Army Center of Military History, Washington, D.C.

# MILITARY DERMATOLOGY

---

*Specialty Editor*

COLONEL WILLIAM D. JAMES, MC, U.S. ARMY  
*Chief*  
*Dermatology Service*  
*Walter Reed Army Medical Center*

---

*Office of The Surgeon General*  
*U.S. Department of the Army*  
*Falls Church, Virginia*

*Walter Reed Army Medical Center*  
*Washington, D.C.*

*Uniformed Services University of the Health Sciences*  
*Bethesda, Maryland*

*Armed Forces Institute of Pathology*  
*Washington, D.C.*

1994

**Editorial Staff:** Lorraine B. Davis  
Senior Editor  
Colleen Mathews Quick  
Associate Editor/Writer  
Scott E. Siegel, M.D.  
Volume Editor

---

This volume was prepared for military medical educational use. The focus of the information is to foster discussion that may form the basis of doctrine and policy. The volume does not constitute official policy of the United States Department of Defense.

**Dosage Selection:**

The authors and publisher have made every effort to ensure the accuracy of dosages cited herein. However, it is the responsibility of every practitioner to consult appropriate information sources to ascertain correct dosages for each clinical situation, especially for new or unfamiliar drugs and procedures. The authors, editors, publisher, and the Department of Defense cannot be held responsible for any errors found in this book.

**Use of Trade or Brand Names:**

Use of trade or brand names in this publication is for illustrative purposes only and does not imply endorsement by the Department of Defense.

**Neutral Language:**

Unless this publication states otherwise, masculine nouns and pronouns do not refer exclusively to men.

---

CERTAIN PARTS OF THIS PUBLICATION PERTAIN TO COPYRIGHT RESTRICTIONS.  
ALL RIGHTS RESERVED.

NO COPYRIGHTED PARTS OF THIS PUBLICATION MAY BE REPRODUCED OR TRANSMITTED IN ANY FORM OR BY ANY MEANS, ELECTRONIC OR MECHANICAL (INCLUDING PHOTOCOPY, RECORDING, OR ANY INFORMATION STORAGE AND RETRIEVAL SYSTEM) WITHOUT PERMISSION IN WRITING FROM THE PUBLISHER OR COPYRIGHT OWNER

Published by the Office of The Surgeon General at TMM Publications  
Borden Institute  
Walter Reed Army Medical Center  
Washington, DC 20307-5001

**Library of Congress Cataloging-in-Publication Data**

Military dermatology / specialty editor, William D. James.  
p. cm. -- (Textbook of military medicine. Part III, Disease and the environment)  
Includes bibliographical references and index.  
1. Dermatology. 2. Medicine, Military. I. James, William D. (William Daniel), 1950- . II. Series.  
[DNLM: 1. Skin Diseases. 2. Military Medicine. 3. Military Personnel. UH 390 T355 Pt. 3 1994]  
RL72.M54 1994  
616.5'008'80355--dc20  
DNLM/DLC  
for Library of Congress

94-24682  
CIP

PRINTED IN THE UNITED STATES OF AMERICA

03, 02, 01, 00, 99, 98, 97, 96, 95,

5 4 3 2 1



# Contents

Foreword by The Surgeon General	xi
Preface	xiii
Patient Flow in a Theater of Operations	xv
1. Historical Overview and Principles of Diagnosis	1
2. Cold-Induced Injury	21
3. Skin Diseases Associated with Excessive Heat, Humidity, and Sunlight	39
4. Immersion Foot Syndromes	55
5. Cutaneous Reactions to Nuclear, Biological, and Chemical Warfare	69
6. Allergic and Irritant Contact Dermatitis	111
7. Cutaneous Trauma and its Treatment	143
8. Arthropod and Other Animal Bites	157
9. Arthropod Infestations and Vectors of Disease	183
10. Viral Hemorrhagic Fevers	197
11. Rickettsial Diseases	213
12. Tropical Parasitic Infections	255
13. Bacterial Skin Diseases	291
14. Leprosy	319
15. Cutaneous Tuberculosis	355
16. Atypical Mycobacterial Diseases	391
17. Superficial Fungal Skin Diseases	423
18. Deep Fungal Skin Diseases	453
19. Sexually Transmitted Diseases	493
20. Common Skin Diseases	549
Acronyms and Abbreviations	597
Index	599

# Foreword

Skin diseases such as infections, infestations, and immersion foot may devastate the fighting strength of a unit by incapacitating its soldiers. In addition, whereas environmental insults such as severe cold will affect an entire force, the sheer numbers of troops who fall victim to frostbite or nonfreezing injuries can easily *cripple* an entire force. It is important to keep in mind that incapacity due to skin disease is usually preventable. When preventive measures fail, the soldier may be back on the front line relatively quickly with proper treatment, as opposed to the more dramatic missile wounds, where evacuation and replacement are often necessary. The role that military dermatologists play in educating, implementing preventive measures, and treating these common disorders is indispensable.

Owing to the historical perspective of the *Textbook of Military Medicine* series, this volume contains several lessons to be learned. First, dermatologists who can function as consultants, educators, preventive medicine officers, and healers need to be available for deployments of a division or greater. Organization that will provide them mobility so they can provide on-the-spot advice to unit commanders in the field regarding preventive strategies will help avoid many days of soldiers' incapacitation. Second, training of nonsurgical medical officers in the diagnosis and treatment of skin disorders should be firmly established as a portion of the core curriculum. This volume will provide a useful tool from which such training can be modeled. And third, research efforts directed at protective and preventive strategies needs to continue to be supported.

This volume will be useful to active-duty and reservist dermatologists, family practitioners, general medical officers, internists, nurses, physician assistants, and medics. It provides an up-to-date, in-depth, highly visual resource both for teaching and for providing medical care to our soldiers in the field.

Lieutenant General Alcide M. LaNoue  
The Surgeon General  
U.S. Army

August 1994  
Washington, D.C.

# Preface

*Historically, diseases of the skin have not been accorded the concern they deserve. This fact may result from the low mortality generally associated with skin disorders. The high morbidity rates and the noneffectiveness rates, however, demand critical attention to the skin.... The noneffectiveness rates must be calculated at the dispensary and sick-call level, where nonduty days caused by dermatologic disorders are a considerable source of manpower loss.<sup>1</sup>*

—Andre J. Ognibene  
Brigadier General (ret)  
Medical Corps, U.S. Army

The skin is an effective barrier against ordinary environmental intrusions. In time of war, however, when the soldier is deployed to environments quite foreign to ordinary peacetime conditions, minor skin insults and irritations can progress to debilitating illnesses. During wartime, the knowledge and application of the principles of simple skin care and routine hygiene are essential. Exposure to extremes of temperature and humidity and excessive sunlight and wetness are only a few of the environmental insults to which the skin is exposed. When further compromised by blisters and cuts and attacked by insects and microorganisms, the skin's protective barrier is breached and soldiers are rendered unavailable for duty.

This volume places military dermatology in its historical context and emphasizes the conditions that specialists and general medical officers in the field are likely to see (eg, friction blisters, macerated feet, superficial fungal infections). Owing to the military's new peacekeeping role, this volume also discusses diseases that are uncommon in the United States but prevalent worldwide in specific geographical locations (eg, cutaneous tuberculosis, mycobacterial infections). Chapter 5, Cutaneous Reactions to Nuclear, Biological, and Chemical Warfare, is unique to a textbook of this type.

As then-Colonel Ognibene understood when he wrote the preface (quoted above) to Lieutenant Colonel Allen's masterly treatise on the skin diseases seen during the Vietnam conflict, combat mortality from dermatologic disorders is low but morbidity from mundane skin conditions can render soldiers noneffective. Prevention and treatment of the ordinary dermatologic disorders and recognition of tropical diseases and infections should therefore be central to the practice of military medicine. Commanders must continually be educated that protecting the individual soldier's skin is integral to conserving the fighting strength.

Brigadier General Russ Zajtchuk  
Medical Corps, U.S. Army

August 1994  
Washington, D.C.

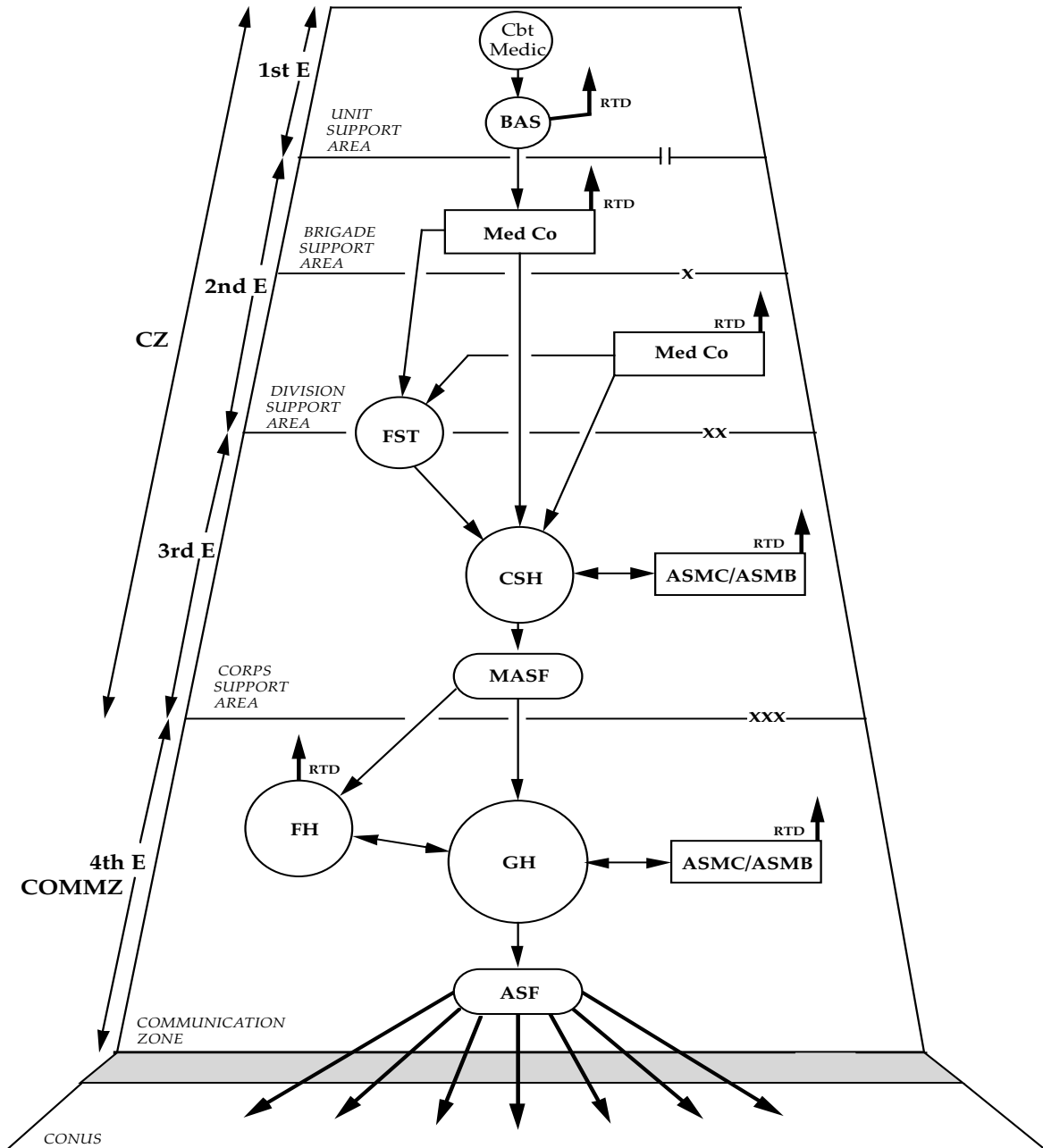
<sup>1</sup>In: Allen, AM. *Skin Diseases in Vietnam, 1965–72*. In: Ognibene AJ, ed. *Internal Medicine in Vietnam*. Vol 1. Washington, DC: Medical Department, US Army, Office of The Surgeon General, and Center of Military History; 1977: xi.

---

The current medical system to support the U.S. Army at war is a continuum from the forward line of troops through the continental United States; it serves as a primary source of trained replacements during the early stages of a major conflict. The system is designed to optimize the return to duty of the maximum number of trained combat soldiers at the lowest possible level. Far-forward stabilization helps to maintain the physiology of injured soldiers who are unlikely to return to duty and allows for their rapid evacuation from the battlefield without needless sacrifice of life or function.

---

## Medical Force 2000 (MF2K) PATIENT FLOW IN A THEATER OF OPERATIONS



ASF: Aeromedical Staging Facility, USAF  
 ASMB: Area Support Medical Battalion  
 ASMC: Area Support Medical Company  
 BAS: Battalion Aid Station  
 Cbt Medic: Combat Medic  
 CSH: Combat Support Hospital  
 COMMZ: Communication Zone  
 CZ: Combat Zone

E: Echelon  
 FH: Field Hospital  
 FST: Forward Surgical Team  
 GH: General Hospital  
 MASF: Mobile Aeromedical Staging Facility, USAF  
 Med Co: Medical Company  
 RTD: Return to Duty

# Chapter 1

## HISTORICAL OVERVIEW AND PRINCIPLES OF DIAGNOSIS

LARRY E. BECKER, M.D.\* AND WILLIAM D. JAMES, M.D.†

---

### HISTORICAL OVERVIEW

World War I  
World War II  
Vietnam Conflict  
Lessons Not Learned  
Recommendations

### PRINCIPLES OF DIAGNOSIS

Anatomy  
Physical Examination  
Patient History  
Differential Diagnostic Considerations

### SUMMARY

\*Colonel, Medical Corps, U.S. Army; Chief, Dermatology Service, Brooke Army Medical Center, Fort Sam Houston, Texas 78234-6200, and Consultant in Dermatology to The U.S. Army Surgeon General

†Colonel, Medical Corps, U.S. Army; Chief, Dermatology Service, Walter Reed Army Medical Center, Washington, D.C. 20307-5001

## HISTORICAL OVERVIEW

Skin diseases are of major importance in military operations. Although they cause few fatalities, they are a significant cause of combat ineffectiveness, troop morbidity, and poor morale. Widespread scabetic infestation, as detailed in Chapter 8, Arthropod and Other Animal Bites, is an excellent example of a skin disease with these repercussions; successful completion of unit missions has been compromised repeatedly. Louse-borne rickettsial infections have incapacitated entire armies since the 16th century, as discussed in depth in Chapter 11, Rickettsial Diseases. The loss of soldiers to the line commander, whether due to missile injury, accident, systemic infection, or skin disease, has the same effect: fewer soldiers available to accomplish the mission.

Certain skin diseases such as immersion foot (discussed in Chapter 4, Immersion Foot Syndromes) or tropical acne (Chapter 3, Skin Diseases Associated with Excessive Heat, Humidity, and Sunlight) often require extended recovery periods or evacuation, thus compounding the problem. While diarrheal illness accounted for the highest number of admissions during the Vietnam conflict (skin diseases ranked third), the average hospital stay for diarrhea was only 3 days, compared to an 8-day average for dermatologic conditions.<sup>1</sup> Because of poor institutional memory, the history of dermatology in military operations tends to repeat itself. The commentary in Chapter 2, Cold-Induced Injury, exemplifies this fact. We must relearn after every conflict that early diagnosis and treatment of skin diseases, combined with close supervision, constant education, preventive measures, and adequate equipment, clearly are vital to preserving the fighting strength.

### World War I

A. N. Tasker wrote, in 1928:

Diseases of the skin, exclusive of dermatological manifestations of venereal diseases, though ordinarily considered to be of minor importance in so far as danger to life is concerned, are of great importance to an army operating in the field, by reason of the noneffectiveness they cause.<sup>2(p551)</sup>

This assertion is strongly supported by statistics from World War I. Although outpatient data are

not available, from 1 April 1917 to 31 December 1919, 126,365 U.S. Army soldiers were hospitalized for skin disease.<sup>2</sup> Recorded diagnostic categories and case frequencies for these admissions included scabies, 34,134; other (unclassified), 20,270; furuncle, 19,958; abscess, 16,329; cellulitis, 12,824; eczema, 4,035; ectoparasitism, 3,269; herpes, 3,141; trichophytosis, 2,813; impetigo, 2,735; carbuncle, 2,330; psoriasis, 1,506; erythema, 1,495; dermatitis, 858; pityriasis, 579; and lichen, 89.<sup>2</sup> Over 2 million days of service are estimated to have been lost by reason of skin disease alone.<sup>3</sup>

In World War I, skin diseases became notorious because of the sickness and lost man-hours they caused. In the British army in 1915, in the United Kingdom, 40.88/1,000 men were admitted for diseases of the skin and areolar tissue. In France and Flanders, the rate was 126.13/1,000.<sup>4</sup> For one British army in France during the later stages of the war, the more common diseases were scabies, infections of the skin, and pyrexia of unknown origin, and these conditions accounted for 90% of all sickness.<sup>5</sup> Because insect bites and infestations are commonly secondarily infected, pyoderma and pyrexia often arose as related problems. Troops with lice infestations were not admitted to sick call because disinfection was practiced as a routine among field forces; nevertheless, the majority of troops had pediculosis.<sup>2</sup>

In the U.S. Army in the United States and in the American Expeditionary Forces in France, dermatology was combined with urology. In The Surgeon General's Office, a section of the Division of Infectious Diseases and Laboratories was devoted to these combined areas.<sup>2</sup> Specialists were assigned to each camp and large hospital in the United States. The American Expeditionary Forces' Division of Urology and Diseases of the Skin had a senior consultant in urology and two consultants in dermatology.<sup>2</sup>

In general, both in the United States and in France, hospitalized patients with skin diseases were treated on the general wards or on the venereal disease wards.<sup>2</sup> In a few hospitals in the United States, wards were set aside solely for treating skin diseases. During the spring and summer of 1918, some field hospitals attached to combat divisions of the American Expeditionary Forces operated as skin hospitals.<sup>2</sup>

## World War II

During World War II, because many nondermatologic physicians failed to appreciate the importance of correct early diagnosis and early adequate care of skin diseases, dermatoses frequently developed to a stage at which weeks or sometimes months of duty time were lost before the soldier could return to duty.<sup>6</sup> The correct decision as to the disposition of a soldier with a cutaneous disease (evacuation, limited duty, or return to combat duty) was often difficult to make. In these circumstances, a well-qualified dermatologist would have been of immense value.<sup>6</sup>

However, prior to mobilization in 1940, not a single qualified dermatologist served in the U.S. Army Medical Corps, and army hospitals did not include a department of dermatology<sup>6</sup> or even have a single medical officer with a cursory knowledge of dermatology assigned.<sup>7</sup> Tables of Organization of army hospitals had no provision for a dermatologist.<sup>7</sup> A Consultant in Dermatology to the Office of The Surgeon General was not appointed until April 1945, shortly before the end of the war, although many theaters had excellent consultants who played very important roles in organizing dermatologic services and outpatient care.<sup>7</sup> As the U.S. Army Medical Corps grew to a total of 48,319 physicians, it included 107 board-certified dermatologists, 30 fully trained but not board-certified dermatologists, and 151 officers with some dermatologic training.<sup>6</sup>

During the early phases of U.S. involvement in World War II, Major General James C. Magee stated:

Skin diseases are of greater importance in military service than in civil life. Although there are few fatalities from these diseases they result in a considerable loss of effective manpower and partial incapacity of a material number of the personnel of many commands.<sup>8(pvi)</sup>

Conservative estimates hold that between 15% and 25% of visits to an outpatient department were for skin disease in a temperate climate. This proportion increased to 60% to 75% in a tropical climate.<sup>6</sup>

In May 1945, in the southwest Pacific, numerous dispensaries show as many as three fourths of those reporting to sick call were suffering from diseases of the skin.<sup>6</sup> From 1 November 1944 to 1 November 1945, approximately 14% to 16% of all patient evacuations to the United States from the southwest Pacific were due to diseases of the skin.<sup>6</sup> During all

months, skin disease was a more frequent cause of evacuation than battle casualties.<sup>6</sup> In many general hospitals located in tropical overseas areas, 15% to 20% of admissions were for skin diseases.<sup>6</sup> In one evacuation hospital in the Pacific, 54.8% of the evacuations for general medical causes were for skin diseases.<sup>9</sup>

Among the Royal Air Force, Royal Australian Air Force, Royal New Zealand Air Force, and Royal Canadian Air Force training in Canada during the war, diseases of the skin and cellular tissue were among the top six causes of both morbidity and wastage (time loss).<sup>10</sup> In the two New Zealand Expeditionary Forces in the Middle East, skin disease accounted for 10% of total hospitalizations.<sup>11</sup> For the Royal New Zealand Air Force in the Pacific Theater, more men were unfit and more time was lost from skin diseases than from any other type of disease. Twenty-eight percent of the medical admissions in the area were on account of skin disease.<sup>11</sup> To put this in perspective, during the first 8 months of 1945, 1,000 cases of skin disease were reported in a force of 7,800. Nearly 100 of these soldiers were hospitalized for more than 3 weeks, and 79 had to be repatriated to New Zealand.<sup>11</sup>

Few prevalence figures from World War II are available. An excellent prospective study of British soldiers in Malaya and Hong Kong shortly after the war revealed that of 1,694 soldiers examined, 79.5% had dermatoses of the feet; 33.5% had tinea corporis, tinea cruris, or both; 28% had prickly heat; 13.9% had acne; and 1.9% had nonbullous impetigo.<sup>12</sup>

## Vietnam Conflict

Statistics for hospital admissions and outpatient visits are more complete for the Vietnam conflict than for any other in which the United States has been involved,<sup>1</sup> although many experts believe substantial underreporting of outpatient information took place because of political pressures on commanders during the war.

Skin diseases were the single greatest cause of outpatient visits to U.S. Army medical facilities during the entire Vietnam conflict.<sup>1,13</sup> There were 1,412,500 recorded visits for skin diseases, twice as many as for any other category of disease.<sup>1</sup> Skin disease was probably significantly underreported because most troops suffering from pyoderma and fungal infections were placed on light duty and never appeared in reported statistics. One of the greatest medical causes of combat ineffectiveness in Vietnam was cutaneous disease.<sup>1,13,14</sup> In some line



units in the Mekong Delta, man-days lost from combat duty secondary to cutaneous disease exceeded losses from all other causes combined.<sup>14</sup> Skin disease had far greater impact on front-line military units, with relative sparing of troops in garrison. Hot, humid conditions and poor hygiene magnified this disparity. The U.S. Ninth Infantry Division operated in the Delta region in southern South Vietnam and suffered the greatest impact. Forty-seven percent of the total man-days lost to the division in a 1-year period (1968–1969) were due to skin disease.<sup>1</sup> This figure includes battle wounds, nonbattle injuries, and disease.<sup>1</sup> More significantly, in actual infantry battalions, 80% of the man-days lost in this division were due to skin disease.<sup>1</sup>

Of all soldiers seeking medical treatment for skin diseases during the Vietnam conflict, fewer than 1% were hospitalized. Cases were selected for hospitalization based on the disease severity, refractoriness to outpatient treatment, and interest to the physician. This procedure was in direct contrast to such diseases as malaria and hepatitis, for which hospitalization was routinely practiced. In this context, the following hospital statistics are even more impressive. By category of disease, skin disease was the third leading cause for admission, ranking behind diarrheal disease and respiratory infections.<sup>1</sup> Malaria was the fourth leading cause.<sup>1</sup> From 1965 through 1972, 45,815 soldiers were admitted by all medical officers for skin disease. Pyoderma, eczema, cystic acne, and tinea led the list of diagnoses for admission.<sup>1</sup> Of soldiers hospitalized by dermatologists, 20% to 25% were evacuated from Vietnam: a total of 4,166 soldiers.<sup>1</sup> This figure represents 9.7% of all evacuations from Vietnam for disease.<sup>1</sup>

### **Lessons Not Learned**

Lessons not learned relating to skin disease have arisen from inadequate organization and training. The following section contains quotations from the official histories of warfare in this century that convey many common themes. We clearly have not learned or have not acted on lessons relating to the dermatologic problems from one conflict to the next.

### **Organization**

The Table of Organization and Equipment (TOE) of today's army hospitals in almost all instances does not contain a position for a dermatologist, a

situation identical to that at the onset of World War II. Furthermore, no positions exist for dermatologists in division, corps, or army medical staffs. Outpatient dermatologic care is almost totally neglected at division level and below. Corps assets are severely lacking.

In 1947, Pillsbury and Livingood warned, concerning the U.S. Army in World War II, that in any military organization of greater than 100,000 troop strength, the surgeon in charge should have an advisor in dermatology. They envisioned that the dermatologist would be assigned to a hospital but should be called on for advice regarding the overall policies relating to cutaneous diseases in the command, and should visit units at intervals to determine the incidence of dermatologic disease and be of assistance to the unit medical officers.<sup>6</sup>

Cautionary advice was not directed solely at the United States. In 1953, W. R. Feasby, in commenting on Canadian forces in World War II, wrote that each command should have the service of a dermatologist, as should each large concentration of personnel of all three services. He further stated that each corps or army should have a senior dermatologist, with one or two junior specialists available per division.<sup>15</sup> Duncan and Stout,<sup>11</sup> in an official history of New Zealand in World War II, remarked that each hospital unit in an overseas force should have a skin specialist on its staff.

The British army was better organized for dermatologic care than other Allied forces in World War II. The British followed their consultant's recommendations in organizational structure. He advised that on the staff of the Director of Medical Services of each army there should be an advisor or consultant in dermatology. A fundamental part of the policy adopted in organizing a dermatologic service was that fully equipped centers, each under the aegis of a trained dermatologist, were available, and that evacuation of cases to these centers was rapidly achieved. Further, in each corps a dermatologist was available whose activity was not entirely confined to work in a skin clinic. He had authority to travel about the corps area and to instruct unit medical officers on the prevention, diagnosis, and treatment of cutaneous disease.<sup>4</sup>

### **Training**

With today's emphasis on specialization, the ever-decreasing number of flexible or rotating internships, and the lack of required rotations in derma-

tology in the medical education of a large majority of physicians and medical students, we remain poorly trained to care for dermatologic diseases. Regarding diagnostic skills in the U.S. Army in World War II, it was noted that many physicians had so little opportunity for dermatologic training in medical school and internship that they were unable to arrive at a diagnosis of even the simplest conditions of the skin.<sup>6</sup>

Up-to-date, specialized publications on dermatologic diagnosis and care in a field environment are important to supplementing the knowledge base of all military physicians and physician assistants. In Washington, D.C., in 1942, at the instigation of the U.S. Army and the Committee of Medicine of the National Research Council, the preparation of a simple manual dealing with the diagnosis and treatment of cutaneous diseases commonly encountered was completed.<sup>6,8</sup> This small textbook manual was distributed to nearly all medical corps officers in the U.S. Army, Army Air Corps, and Navy. Many wartime hospital reports carry the statement that dermatologic disabilities could have been cut in half if treatment methods had been improved and patients had been brought into early contact with a dermatologist.<sup>7</sup>

R. M. B. MacKenna, writing about the British army in World War II, remarked that a poorly trained healthcare provider could do more harm than good:

It is important to realize that usually the greatest hazard to which a patient who is suffering from a cutaneous disease is exposed during the first stages of his malady is that he is treated by a unit (regimental) medical officer who, as he has had no specialized training in dermatology, may be uncertain of the diagnosis, and therefore may conduct treatment by a method of trial and error. This method is successful only in a few cases. In the majority it leads to an aggravation of the disability or dermatitis medicamentosa and eventually to an unnecessarily prolonged period of hospitalization.<sup>4(p159)</sup>

Commenting on skin diseases in the U.S. Army in Vietnam, A. M. Allen observed that the lack of emphasis on education and training in dermatology was undoubtedly responsible for a large portion of the morbidity caused by skin diseases. This lack of emphasis was not apparent in other medical fields of importance in tropical warfare, such as malaria and enteric diseases, but seemed to be attributable to a general lack of appreciation for the enormous losses of manpower that can result from

cutaneous diseases. He concluded that, with the exception of dermatologists, the medical personnel who were called upon to diagnose, treat and prevent skin disease in Vietnam had little if any training in dermatology.<sup>1</sup> In Vietnam, until the appearance of a field manual on skin disease in 1969, very little relevant information was available, and some of what was available was misleading. The manual published in 1942 was long outdated.

## **Recommendations**

To provide first-rate military medical care and to preserve the fighting strength of our soldiers by preventing as well as treating skin diseases, we must address three areas of weakness that have been important historically: organization, training, and research. We must reorganize our TOEs, upgrade our training efforts to train healthcare providers adequately about the importance of skin care in the field, and reestablish significant research efforts to solve lingering and recurrent dermatologic problems.

## **Organization**

Working closely with the Combat Developments Division of the U.S. Army Medical Department Center and School, we must reexamine TOEs for medical forces. A dermatologist should be on the staff of all larger TOE hospitals. Corps-level assets should have a dermatology team with adequate vehicle support to travel about the corps and division areas to evaluate, teach, and treat. One senior consultant dermatologist should be assigned to corps staff and should direct teams that provide outpatient care to divisional level troops, ensuring that two dermatologists are available in each corps team for each division supported. A theater consultant in dermatology and a dermatology team should be assigned for all troop deployments greater than division level, unless deployment is to a tropical area, in which case a consultant and team should be assigned for brigade-size and larger deployments. Early prevention and outpatient treatment can prevent many of the medical casualties experienced in prior conflicts. A change in the Professional Filler System (PROFIS) approach to designating dermatology specialists is necessary, in which dermatologists would be assigned to dermatology teams or consultant positions. While this change is being instituted, consideration should be given to assigning dermatologists to Division Preventive

Medicine Officer positions in the PROFIS system. Sets, kits, and outfits (SKOs) must be updated to ensure appropriate dermatologic therapeutics and supplies for all levels, from the company aidman's bag through dermatology team sets.

### Training

Mandatory rotations in dermatology should be established for all military nonsurgical interns and residents to provide a significant base of knowledge for the diagnosis and treatment of common skin diseases. Military medical training centers must ensure that a core curriculum for dermatology residents and medical students covers the common skin diseases and does not emphasize only the rare and unusual diseases. There should be continued work with the American Academy of Dermatology in establishing a core curriculum in dermatology for nondermatologists. A manual of dermatology for physicians patterned after the National Research Council's World War II manual<sup>8</sup> covering common dermatologic problems and their treatment should be published, widely distributed, and periodically updated. Universal distribution to military physicians of such a manual should be ensured as is done for the *The Emergency War Surgery* NATO Handbook.<sup>16</sup>

The dermatology consultant's input into basic medical training for corpsmen should be ensured.

### Research

Since the demise of the Department of Dermatology Research at the Letterman Army Institute of Research, The Presidio, San Francisco, California, in 1980, almost no research relating to field problems and skin disease has been conducted by the services. Research efforts should be reestablished through the U.S. Army Medical Research and Development Command to address better field diagnosis and treatment of common disabling dermatologic conditions such as pyoderma, fungal infections, and miliaria. An in-depth review of bathing availability and requirements and their relationship to skin disease should take place. A method of funding should be developed to allow military training programs in dermatology to send small research teams to locations such as the Jungle Warfare School in Panama, where field studies can address real-time problems. The military should resurrect, further develop, and field better protective and preventive items of issue such as shower thongs for wear by troops in base camps to decrease susceptibility to foot problems.<sup>1,9</sup>

## PRINCIPLES OF DIAGNOSIS

The advantage a medical officer has in caring for the soldier with skin disease is that the abnormalities about which the complaint revolves are usually visible, and may also be palpable. In the performance of the direct examination, key clues must be carefully noted by a discerning, educated detective. Additional observations that can aid in solving the diagnostic mystery are easily gained by examining the skin and mucous membrane sites not directly called into question by the soldier, and through directed questioning. Laboratory tests taken as standard of care in a hospital, such as potassium hydroxide preparations, Tzanck preparations, cultures, and skin biopsies, may not be readily available in the field. Thus, maximum use of information gained by close, educated inspection is necessary.

### Anatomy

Knowledge of the normal anatomy is essential before the healthcare provider can understand der-

matologic terminology and principles of diagnosis. The skin is composed of three basic layers: the epidermis, the dermis, and the subcutaneous tissue. The epidermis is the most superficial and thinnest of the three; however, it is the principal site available for inspection. A key finding in proceeding through differential diagnostic possibilities will be based on the pivotal answer to this question: Is there epidermal involvement? Normal epidermis is smooth-surfaced and has skin lines running through it at regular intervals. With the notable exception of the palms and soles, most areas have small, regularly placed openings through which hairs grow. It should be appreciated that most cells that compose the epidermis are keratinocytes, whose primary role is to provide a physical barrier to external forces. A smaller subset of cells is concerned with pigment production. These cells—melanocytes—give the skin its normal color but can be damaged after inflammation or may proliferate, leading to the potentially deadly growth, melanoma. Although a third group of cells exist, the Langerhans cells,

which provide immunological surveillance, these cells are rarely important in observational diagnosis of the conditions discussed in this text.

The dermis is the site of residence of most components of the skin. Within this 1- to 4-mm area lie blood vessels, nerves, glands, hair follicles, and structural matrix. This tough but flexible layer of tissue provides for temperature regulation, sensation, and natural lubrication, and gives to the skin many of the cosmetically important characteristics valued by all of us. Abnormalities of the dermis that will provide clues to the diagnostic dilemmas posed most commonly in the field environment involve vascular dilation and inflammation. A blanchable redness of the skin implies that one or both of these changes have occurred. A nonblanching redness usually results from extravasation of erythrocytes into the dermis secondary to vascular damage.

A noninflammatory thickening or growth confined to the dermis (with normal overlying epidermis) usually occurs from a benign or malignant tumor of existing normal structures or from an infiltrative disease. In most cases, a biopsy is required to make a definitive diagnosis. The importance of these sporadic conditions to military medicine is minor. The key diagnostic intervention, the skin biopsy, is often deferred unless the lesion is growing rapidly or numerous sites are involved. Dermal tumors and infiltrative diseases will generally not be discussed in this textbook.

The third layer of the skin, the subcutaneous tissue, is composed primarily of fat cells and provides insulation, cushioning, and a reserve energy source. In general, disorders of the fat are of lesser importance in the field due to their sporadic nature. Skin biopsy is usually required for definitive diagnosis.

### Physical Examination

Of the numerous diagnostic clues available to the physician, the morphologic characteristics of the lesions are often the most helpful. They provide a useful means of categorizing disease states and allow generation of a meaningful differential diagnosis. Once the primary lesion is recognized, other characteristics obtained by observing secondary changes, configuration, regional distribution, and associated nondermatologic signs as well as historical information will quickly narrow the possibilities. To use this approach, physicians should employ the basic vocabulary that defines primary and secondary skin changes as well as

special lesions and configurations, as presented in Figures 1-1 through 1-19. It is in these words the healthcare provider needs to tell the story of skin disease because, if the end of the diagnostic trail cannot be successfully reached, consultation couched in these terms will be most rapidly and reliably regarded.

Such obvious information as age, sex, race, and regional distribution (covered vs sun-exposed, flexural vs extensor, truncal vs extremity) needs to be consciously noted and included for consideration. Finally, inspection of the skin is not complete unless details of any alteration in color, consistency, or growth pattern of hair and nails are noted. The mucous membranes are to be viewed as important sites of ancillary clues to the diagnosis and should be examined closely in all soldiers who present with skin disorders.

### Patient History

Although the physical characteristics of skin lesions provide the most critical information leading to diagnosis, a historical account of the evolution of the disease is important not only to understand the disease process better but, often more vital, to allow soldiers to express their unique, individual concerns to the physician. All soldiers desire a correct diagnosis and effective medication for their condition, but equally crucial in most cases is the individualized education given to them by a sincere, concerned, thoughtful physician. Only by allowing soldiers to tell their stories can this be accomplished.

In nearly every encounter, the duration and evolution of the disorder, as well as any previous therapy that may have altered the natural course, need to be elicited. Skin-related symptoms, particularly with regard to itching or pain, as well as associated, concurrent, systemic symptoms; past medical history (especially as related to oral medication and allergies); family history; and social history may be important in individual cases. The medical officer needs to understand (a) how the disease affects the soldier (does it impair function, alter sleep, or cause cosmetic concern?); (b) the reason the soldier sought care; (c) suggested causes, diagnoses, or therapies; and (d) the main concern of the soldier (eg, "Is it cancer?" "Am I going to give this to my friends?" "What did I do to cause this?" "Can I avoid [anything] to make myself better?"). All of these are of paramount importance in history-taking.

## Differential Diagnostic Considerations

The algorithms included in this chapter (Figures 1-20 through 1-25) are presented for the nondermatologist in the field who is tasked with the care of soldiers without laboratory or skin biopsy capability. The algorithms address only some of the most commonly seen skin diseases. These diagnostic road maps make use of classic characteristics of the disease categories depicted. Many variations from

the standard presenting physical findings exist; therefore, these algorithms are not foolproof. They depend on the medical officer's recognition of the primary or predominant physical findings. Once a diagnosis is reached, the appropriate section of this book can be referred to for further information. Useful tests or additional information that will help to confirm the diagnosis have been added next to the algorithm endpoints; the tests can be obtained when support is, or becomes, available.

Fig 1-1 is not shown because the copyright permission granted to the Borden Institute, TMM, does not allow the Borden Institute to grant permission to other users and/or does not include usage in electronic media. The current user must apply to the publisher named in the figure legend for permission to use this illustration in any type of publication media.

**Fig. 1-1.** Primary versus secondary lesions. Primary lesions are the earliest alterations present. With the passage of time, changes may occur leading to less diagnostic secondary lesions. Reprinted from the AAD Library of Teaching Slides with permission from the American Academy of Dermatology.

Fig 1-2 is not shown because the copyright permission granted to the Borden Institute, TMM, does not allow the Borden Institute to grant permission to other users and/or does not include usage in electronic media. The current user must apply to the publisher named in the figure legend for permission to use this illustration in any type of publication media.

**Fig. 1-2.** Macule. A flat change in color of the skin. Reprinted from the AAD Library of Teaching Slides with permission from the American Academy of Dermatology.

Fig 1-3 is not shown because the copyright permission granted to the Borden Institute, TMM, does not allow the Borden Institute to grant permission to other users and/or does not include usage in electronic media. The current user must apply to the publisher named in the figure legend for permission to use this illustration in any type of publication media.

**Fig. 1-3.** Vesicle and bulla. Blisters containing clear fluid. Vesicles are the smaller of the two, with bullae being 0.5 cm or larger. Reprinted from the AAD Library of Teaching Slides with permission from the American Academy of Dermatology.

Fig 1-4 is not shown because the copyright permission granted to the Borden Institute, TMM, does not allow the Borden Institute to grant permission to other users and/or does not include usage in electronic media. The current user must apply to the publisher named in the figure legend for permission to use this illustration in any type of publication media.

**Fig. 1-4.** Pustule. Yellowish cloudy fluid is present. Reprinted from the AAD Library of Teaching Slides with permission from the American Academy of Dermatology.

Fig 1-5 is not shown because the copyright permission granted to the Borden Institute, TMM, does not allow the Borden Institute to grant permission to other users and/or does not include usage in electronic media. The current user must apply to the publisher named in the figure legend for permission to use this illustration in any type of publication media.

**Fig. 1-5.** Papules, nodules, and tumors are palpable skin lesions of varying size. Papules are less than 0.5 cm in diameter, nodules larger. Tumors are very large growths. Reprinted from the AAD Library of Teaching Slides with permission from the American Academy of Dermatology.

Fig 1-7 is not shown because the copyright permission granted to the Borden Institute, TMM, does not allow the Borden Institute to grant permission to other users and/or does not include usage in electronic media. The current user must apply to the publisher named in the figure legend for permission to use this illustration in any type of publication media.

**Fig. 1-7.** Wheal. Edema causes a transient papule or plaque to occur. Reprinted from the AAD Library of Teaching Slides with permission from the American Academy of Dermatology.

Fig 1-6 is not shown because the copyright permission granted to the Borden Institute, TMM, does not allow the Borden Institute to grant permission to other users and/or does not include usage in electronic media. The current user must apply to the publisher named in the figure legend for permission to use this illustration in any type of publication media.

**Fig. 1-6.** Plaque. An elevated, flat-topped lesion whose width exceeds its height. Reprinted from the AAD Library of Teaching Slides with permission from the American Academy of Dermatology.

Fig 1-8 is not shown because the copyright permission granted to the Borden Institute, TMM, does not allow the Borden Institute to grant permission to other users and/or does not include usage in electronic media. The current user must apply to the publisher named in the figure legend for permission to use this illustration in any type of publication media.

**Fig. 1-8.** Scale. Dry, usually whitish flakes on the surface of the epidermis. Reprinted from the AAD Library of Teaching Slides with permission from the American Academy of Dermatology.

Fig 1-9 is not shown because the copyright permission granted to the Borden Institute, TMM, does not allow the Borden Institute to grant permission to other users and/or does not include usage in electronic media. The current user must apply to the publisher named in the figure legend for permission to use this illustration in any type of publication media.

**Fig. 1-9.** Oozing and crusts. Oozing consists of tissue fluid, often with cellular debris, exuding from acutely inflamed skin. Crusts are usually moist, yellowish debris and appear when the fluid from vesicles, bullae, pustules, or oozing dries. Reprinted from the AAD Library of Teaching Slides with permission from the American Academy of Dermatology.

Fig 1-10 is not shown because the copyright permission granted to the Borden Institute, TMM, does not allow the Borden Institute to grant permission to other users and/or does not include usage in electronic media. The current user must apply to the publisher named in the figure legend for permission to use this illustration in any type of publication media.

**Fig. 1-10.** Fissure, erosion, ulcer. Fissures are thin linear tears in the epidermis. An erosion is a wider-based loss of a portion of the epidermis, while an ulcer is larger and deeper. Reprinted from the AAD Library of Teaching Slides with permission from the American Academy of Dermatology.

Fig 1-11 is not shown because the copyright permission granted to the Borden Institute, TMM, does not allow the Borden Institute to grant permission to other users and/or does not include usage in electronic media. The current user must apply to the publisher named in the figure legend for permission to use this illustration in any type of publication media.

**Fig. 1-11.** Lichenification. A thickening of the epidermis leading to accentuated skin markings.

Fig 1-12 is not shown because the copyright permission granted to the Borden Institute, TMM, does not allow the Borden Institute to grant permission to other users and/or does not include usage in electronic media. The current user must apply to the publisher named in the figure legend for permission to use this illustration in any type of publication media.

**Fig. 1-12.** Atrophy. A thin, wrinkled, often depressed area resulting from loss of skin tissue.

Fig 1-13 is not shown because the copyright permission granted to the Borden Institute, TMM, does not allow the Borden Institute to grant permission to other users and/or does not include usage in electronic media. The current user must apply to the publisher named in the figure legend for permission to use this illustration in any type of publication media.

**Fig. 1-13.** Comedo. Commonly called blackheads or whiteheads, these keratin-filled hair follicles are the earliest lesions of acne. Reprinted from the AAD Library of Teaching Slides with permission from the American Academy of Dermatology.

Fig 1-14 is not shown because the copyright permission granted to the Borden Institute, TMM, does not allow the Borden Institute to grant permission to other users and/or does not include usage in electronic media. The current user must apply to the publisher named in the figure legend for permission to use this illustration in any type of publication media.

**Fig. 1-14.** Telangiectasia. Enlarged superficial blood vessels. Reprinted from the AAD Library of Teaching Slides with permission from the American Academy of Dermatology.

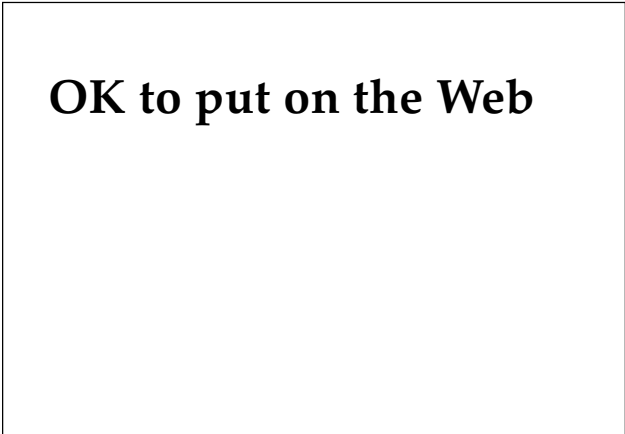
Fig 1-15 is not shown because the copyright permission granted to the Borden Institute, TMM, does not allow the Borden Institute to grant permission to other users and/or does not include usage in electronic media. The current user must apply to the publisher named in the figure legend for permission to use this illustration in any type of publication media.

**Fig. 1-15.** Burrow. The scabies mite will leave a linear track as she moves through the epidermis. Reprinted from the AAD Library of Teaching Slides with permission from the American Academy of Dermatology.

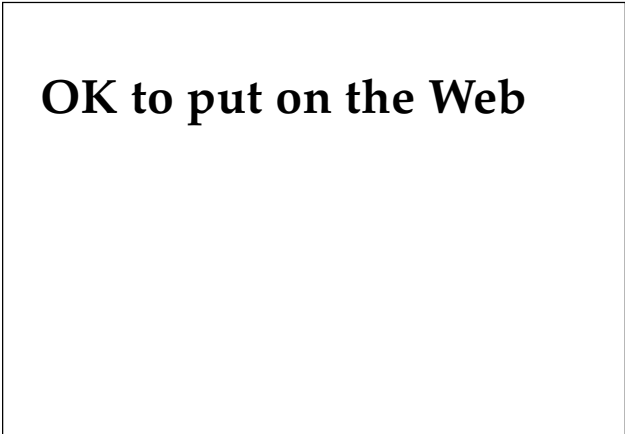
Fig 1-16 is not shown because the copyright permission granted to the Borden Institute, TMM, does not allow the Borden Institute to grant permission to other users and/or does not include usage in electronic media. The current user must apply to the publisher named in the figure legend for permission to use this illustration in any type of publication media.

**Fig. 1-16.** Scar. New formation of connective tissue as a reparative process due to damage to the dermis or deeper tissues. Reprinted from the AAD Library of Teaching Slides with permission from the American Academy of Dermatology.

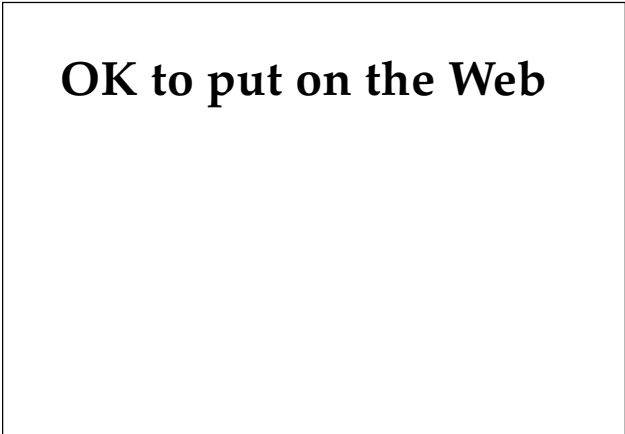




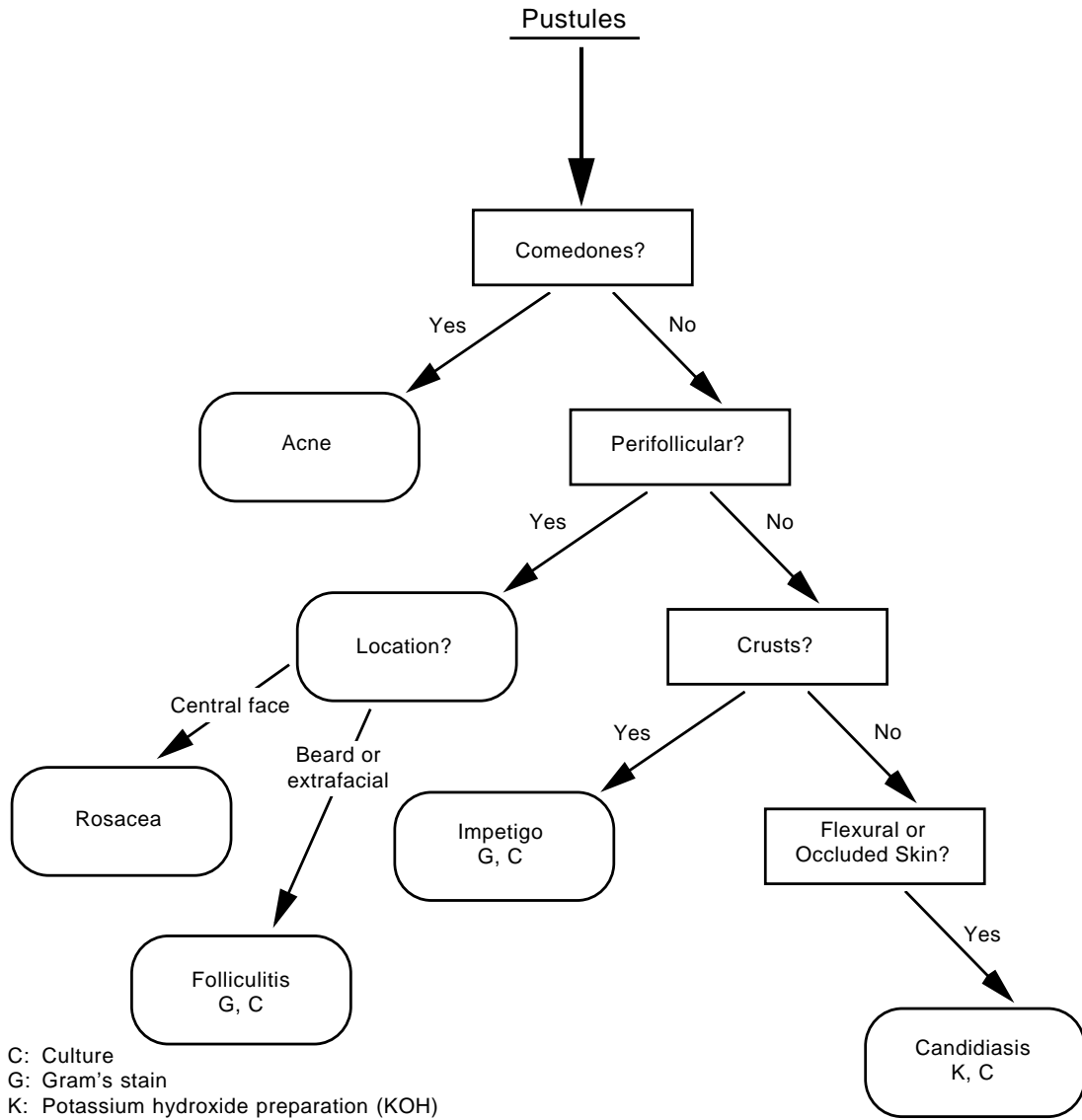
**Fig. 1-17.** Poison ivy will often cause linear lesions due to brushing of the plant against the skin or spreading of the allergen by scratching.



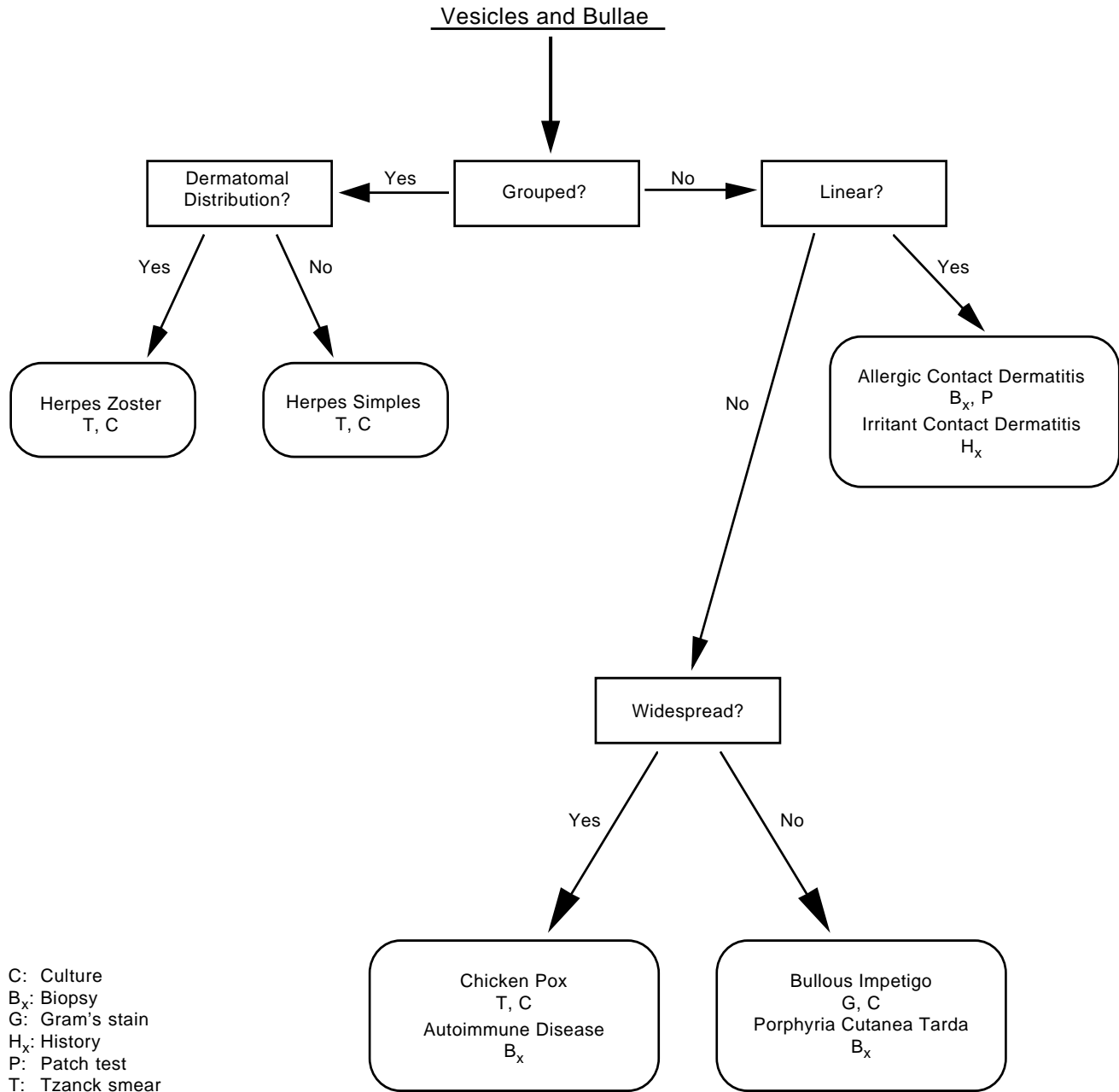
**Fig. 1-18.** Grouped vesicles on an erythematous base characterize herpes simplex as well as herpes zoster.



**Fig. 1-19.** An annular arrangement describes a ringlike lesion that surrounds a central area of more normal-appearing skin.



**Fig. 1-20.** Pustular lesions are often a sign of bacterial or fungal infection. Gram's stain, culture, and potassium hydroxide analysis will aid in the diagnosis of these conditions.



**Fig. 1-21.** Blisters may be a sign of infection; however, in a field environment they are likely to be secondary to irritant or allergic contact dermatitis.

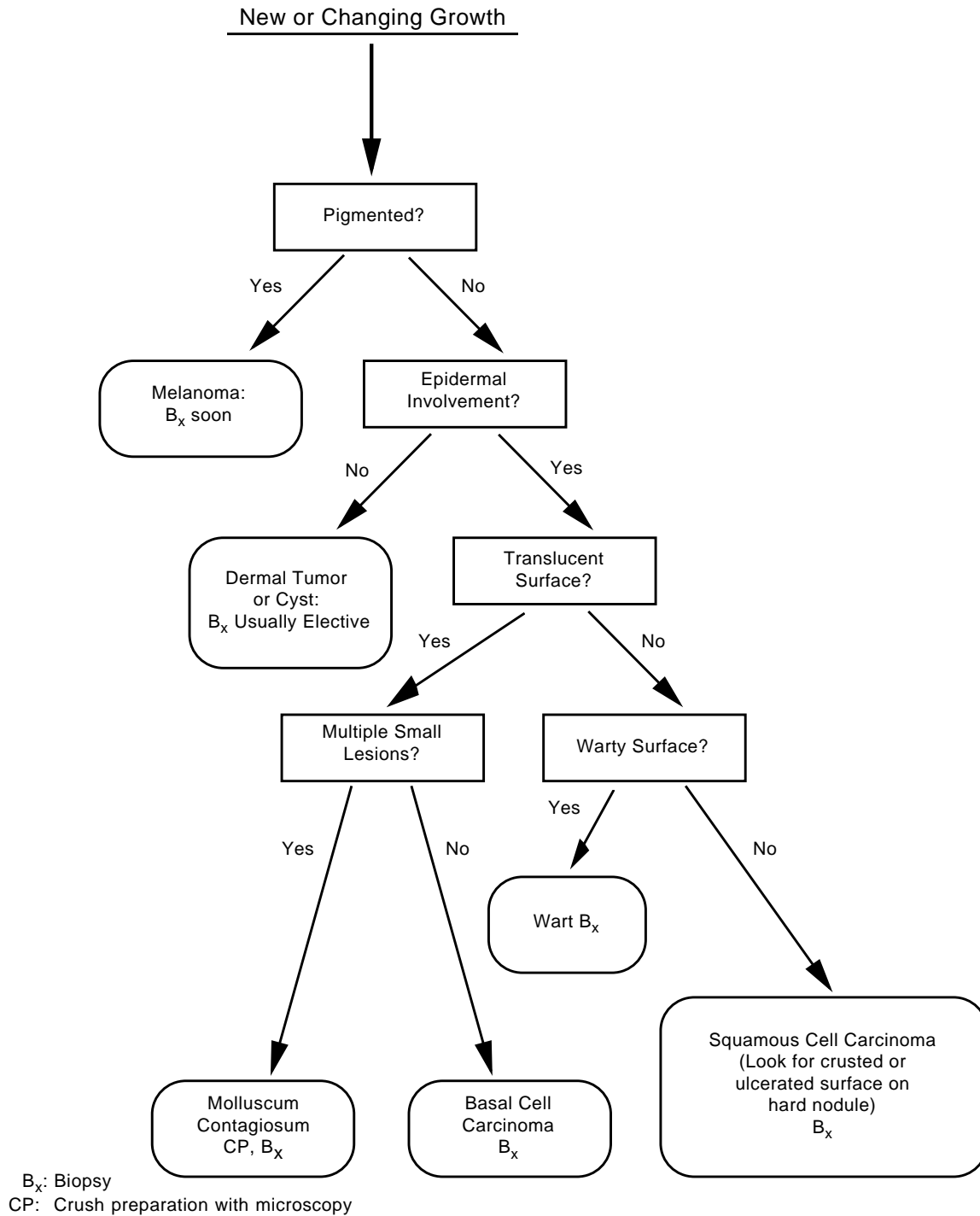
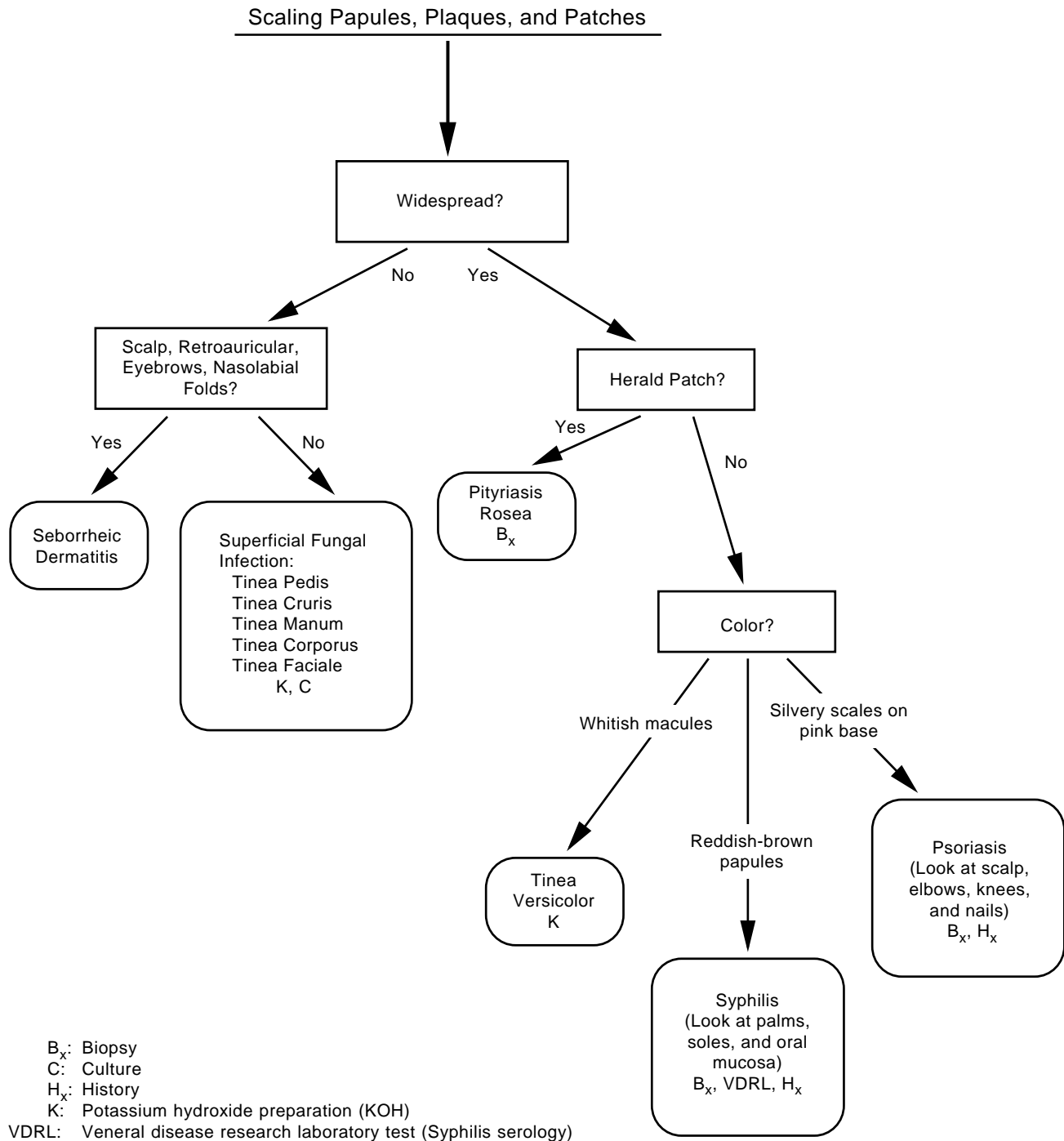
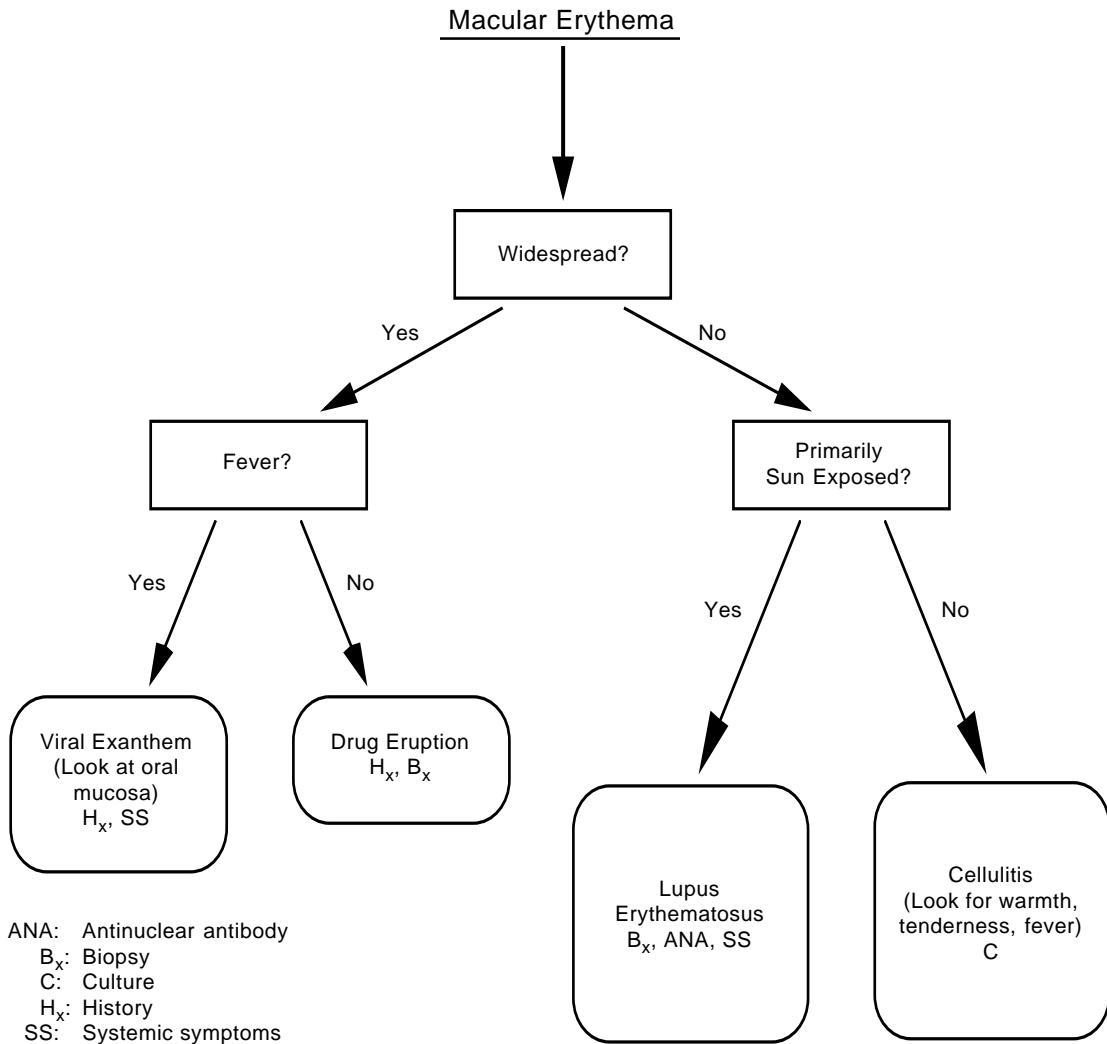


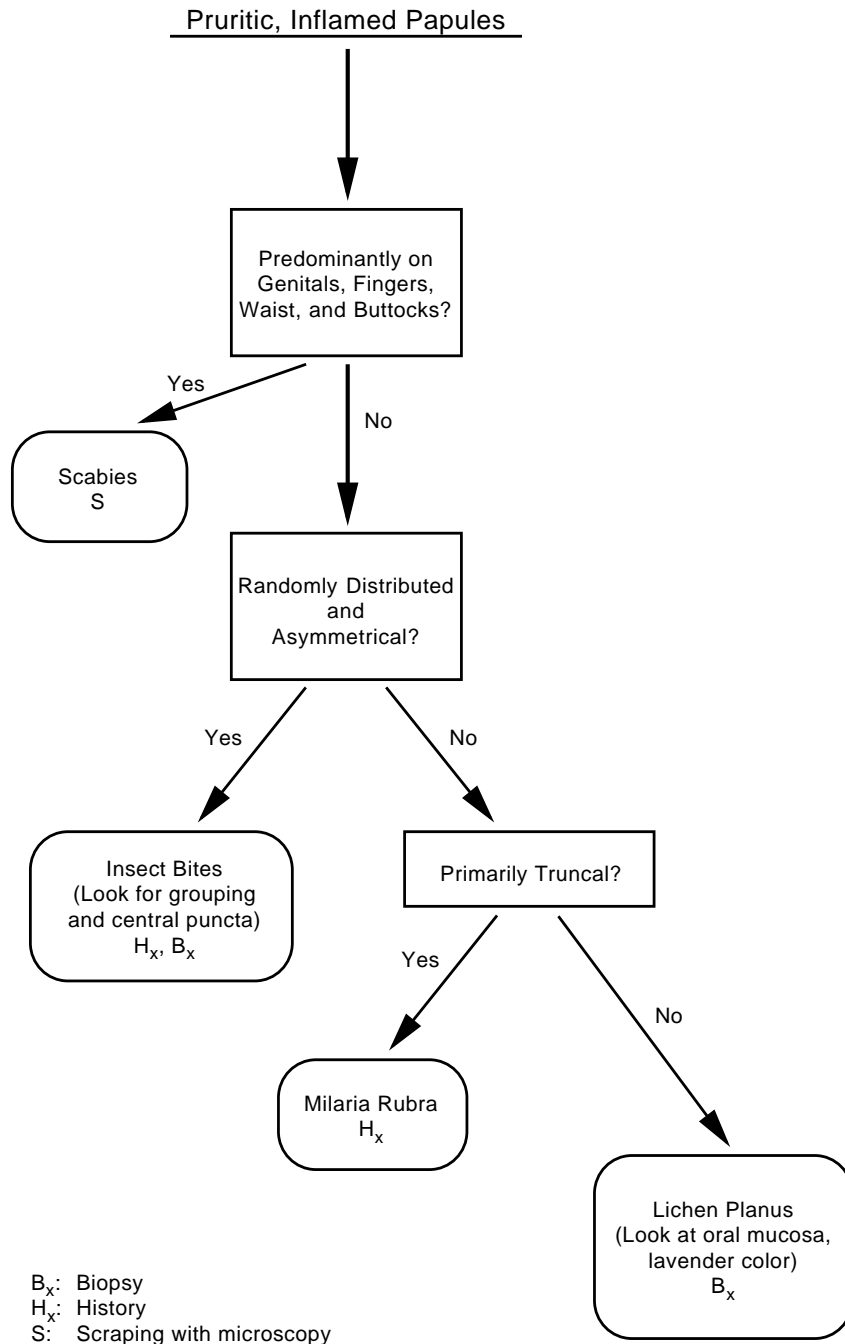
Fig. 1-22. New or changing growths do not often require immediate attention in the field, as they are usually slow in their development.



**Fig. 1-23.** A number of disorders exhibit scaling papules, plaques, and patches. Superficial fungal infections are extremely common in tropical environments. Syphilis is important to recognize because treatment will prevent long-term sequelae and spread of disease.



**Fig. 1-24.** Macular erythema is a usually acute event that may worsen and even cause death if not recognized. A papular component may sometimes be present.



**Fig. 1-25.** Pruritic, inflamed papules are among the most common types of skin lesions. Itching is intense, and the lesions commonly show secondary changes such as excoriations and crusts.

## SUMMARY

Skin diseases are a significant cause of combat ineffectiveness, morbidity to soldiers, and poor morale. Their importance to military operations is most pronounced in tropical and subtropical climates, where over half the man-days lost to front-line troops are directly related to skin disease. Although these facts have been repeatedly observed and recorded in official histories from World War I, World War II, and the Vietnam conflict, the U.S. Army today remains largely unprepared to prevent

skin disease or provide expert dermatologic medical care in tropical operations.

Reevaluation of Tables of Organization and Equipment and Professional Filler System policies is highly recommended. Increased research on the prevention and early treatment of skin diseases is sorely needed. Finally, training of non-dermatologists in the basics of skin care, preventive policies, and dermatologic diagnosis needs to be accomplished.

## REFERENCES

1. Allen, AM. *Skin Diseases in Vietnam, 1965–72*. In: Ognibene AJ, ed. *Internal Medicine in Vietnam*. Vol 1. Washington, DC: Medical Department, US Army, Office of The Surgeon General and Center of Military History; 1977: 2, 29–30, 34–35, 42.
2. Tasker AN. Diseases of the skin. In: Siler JF, ed. *Communicable and Other Diseases*. In: *The Medical Department of the United States Army in the World War*. Vol 9. Washington, DC: Medical Department, US Army, Office of The Surgeon General; 1928:551–557.
3. Lane CG. Medical progress, military dermatology. *N Engl J Med*. 1942;227:293–299.
4. MacKenna RMB. Special contributions on military dermatology. *British Med Bull*. 1945;3:158–161.
5. MacPherson WG, Horrocks WH, Beveridge WWO, eds. *History of the Great War, Medical Services, Hygiene of the War*. London, England: His Majesty's Stationery Office; 1923: 68–111.
6. Pillsbury DM, Livingood CS. Experiences in military dermatology: Their interpretation in plans for improved general medical care. *Arch Dermatol and Syph*. 1947;55:441–462.
7. Pillsbury DM, Livingood CS. Dermatology. In: Havens WP, ed. *Infectious Diseases and General Medicine*. In: Havens WP, Anderson RS, eds. *Internal Medicine in World War II*. Vol 3. Washington, DC: Medical Department, US Army, Office of The Surgeon General; 1968: 543–588.
8. Pillsbury DM, Sulzberger MB, Livingood CS. *Manual of Dermatology*. Philadelphia, Pa: WB Saunders Company; 1942: vi.
9. Grauer FH, Helms ST, Ingalls TH. Skin infections. In: Hoff EC, ed. *Communicable Diseases Transmitted Through Contact or by Unknown Means*. In: Coates JB Jr, ed. *Preventive Medicine in World War II*. Vol 5. Washington, DC: Medical Department, US Army, Office of The Surgeon General; 1960: 83–137.
10. Feasby WR, ed. Organization and campaigns. In: *Official History of the Canadian Medical Services, 1939–1945*. Vol 1. Ottawa, Canada: Queen's Printer and Controller of Stationery; 1956: 391–427.
11. Duncan T, Stout M. *War Surgery and Medicine, Official History of New Zealand in the Second World War, 1939–45*. Wellington, New Zealand: War History Branch; 1954: 688–703.
12. Sanderson PH, Sloper SC. Skin disease in the British army in S.E. Asia. Part 1. Influence of the environment on skin disease. *Brit J Dermatol*. 1953;65:252–264.
13. Blank H, Taplin D, Zaias N. Cutaneous *Trichophyton mentagrophytes* infections in Vietnam. *Arch Dermatol*. 1969;99:135–142.



14. Allen AM, Taplin D, Lowy JA, Twigg L. Skin infections in Vietnam. *Milit Med.* 1972;137:295–301.
15. Feasby WR. Clinical subjects. In: *Official History of the Canadian Medical Services, 1939–1945.* Vol 2. Ottawa, Canada: Queen's Printer and Controller of Stationery. 1953; 123–132.
16. US Department of Defense. Bowen TE, Bellamy RF, eds. *The Emergency War Surgery NATO Handbook.* 2nd rev. Washington, DC: GPO; 1988.

# Chapter 2

## COLD-INDUCED INJURY

DAVE CORBETT, D.O.\* AND PAUL BENSON, M.D.†

---

### INTRODUCTION

### MECHANISMS OF HEAT LOSS

- Conduction
- Convection
- Radiation
- Evaporation
- Respiration

### FACTORS INFLUENCING HEAT LOSS

- Weather and Duration of Exposure
- Type of Combat Action
- Clothing
- Other Factors

### PATHOGENESIS OF COLD INJURY

### DIRECT COLD INJURY

- Asteatotic Eczema
- Frostbite

### INDIRECT COLD INJURY

- Pernio
- Livedo Reticularis
- Acrocyanosis
- Erythrocyanosis
- Trench Foot
- Cold Panniculitis
- Raynaud's Disease and Phenomenon

### SUMMARY

\*Captain, Medical Corps, U.S. Navy; Dermatology Branch, National Naval Medical Center, Bethesda, Maryland 20814

†Lieutenant Colonel, Medical Corps, U.S. Army; Dermatology Service, Walter Reed Army Medical Center, Washington, D.C. 20307-5001

## INTRODUCTION

Cold injuries have played an important role in the loss of combat effectiveness for armies since early recorded history. References to frostbite have been found in the writings of Hippocrates, Aristotle, and Galen. Other historical entries have documented significant problems with cold injuries among the Greek armies of the late fourth and early third centuries BC.<sup>1</sup>

During the American Revolution, James Thatcher described serious losses from cold injury in 1777; an army of 10,000 men lost 2,900 to combat operations. Even in 1777, there was some understanding of the pathogenesis of cold injury. A physician general to the military hospitals, Benjamin Rush, wrote in a small pamphlet with directions for preserving the health of soldiers:

The commanding officer should take the utmost care never to suffer a soldier to sleep, or even to sit down in his tent with wet clothes, nor to lie down in a wet blanket or upon damp straw. The utmost vigilance will be necessary to guard against this fruitful source of diseases among soldiers.<sup>1(pp29-30)</sup>

Baron Larrey, surgeon to the French armies in the Napoleonic Wars, described frostbite and "congelation" as important reasons for the defeat of the army in Poland in 1812. He also noted that "general remedies should always precede surgery"<sup>1</sup> and described the detrimental effects of sudden rapid warming of frozen body parts by the camp fire.

The Crimean War (1854–1856) revealed the impact of proper training and equipment on the number of casualties caused by cold. During the first winter (1854–1855), British troops fought trench warfare, with static defensive positions. Soldiers were inexperienced and unfamiliar with the potential hazards of cold weather. They were also hampered by a lack of adequate food and clothing, and the debilitating effects of diarrhea and dysentery. In a force of slightly less than 50,000 soldiers, 1,924 cases of cold injury were reported, with 457 fatalities—23.8% of the total cold injuries. During the winter of 1855 to 1856, there were only 474 cases of cold injury and 6 fatalities (1.3%). Weather conditions and precipitation were essentially the same in both years. But during the second year the troops had far better living conditions along with improved winter clothing and ample food. The average soldier was hardened and knew better how to care for himself and prevent cold injury.<sup>1</sup>

In the Franco-Prussian War of 1870, 1,450 cases of severe frostbite occurred among 92,067 Prussian troops. During the Russo-Turkish War (1877–1878), 4,500 frostbite casualties were reported, representing 1.5% of the 300,000-man force in Bulgaria and 5.1% of the 87,989 casualties evacuated.<sup>1</sup>

British medical observers with the Japanese Army made detailed reports from 25–29 January 1905 during the Russo-Japanese War. Of 7,742 total casualties, 505 soldiers were hospitalized for frostbite, approximately a 1:15 ratio of frostbite to battle wounds. The toes were affected in 67% of the cold injury cases and the fingers in 28%. Injuries were mild and amputation was seldom required. In a subsequent engagement, the British observers noted that the Japanese troops were given extra socks and rations. Halts were called during marches to remove boots and replace them with Chinese felt or straw shoes. The number of frostbite casualties dropped dramatically to only 70 soldiers hospitalized for cold injury.<sup>1</sup>

The most detailed history of cold injuries among combat soldiers can be gleaned from World War I. The British experience is the most extensive, and U.S. casualties were lower as a result of lessons learned before our involvement. Additionally, most of the trench warfare for U.S. forces occurred during times of the year when exposure to cold and wet was not great. The British, however, did not seem to profit from their experience in the Crimean War and, as a result, their expeditionary force suffered a high rate of cold injury during the first winter of World War I.<sup>1</sup> Injuries were reported as frostbite, water bite, footbite, cold bite, puttee bite, trench bite, chilled feet, or only as "feet cases."<sup>1</sup> Not until after the first winter did the term "trench foot" come into general usage. Medical and nonmedical officers promptly realized the significance of this affliction, which is caused by prolonged exposure to cold and dampness at temperatures above freezing. Forces suffered not only loss of manpower but the additional financial consideration of casualties that were entitled to disability pensions.<sup>1</sup>

Cold injury began insidiously among British troops with one case of frostbite in August 1914, one in September, 11 in October, 1,555 in November, and 4,823 in December, when the term "trench foot" first appeared in medical records. The highest incidence of cold injury was in the infantry, with officers affected slightly less severely than enlisted

soldiers. The total number of cold injuries in all theaters of operations and bases including the United Kingdom was 115,361 cases. During 1915, the cases of frostbite and trench foot were separated (they were not thereafter), with 30,691 admissions for frostbite and 29,172 for trench foot. Total cold injuries for 1914 to 1915 numbered 97,414 cases. Only 443 cases were noted in the hospital records of 1916 to 1918.<sup>1</sup>

The American records for World War I reveal a total of 2,061 admissions for trench foot, which included 27 officers. The total number of man-days lost was 92,249, an average of 45 days per case. Preventive measures included regular inspections of the feet by officers, as well as changing socks once daily, foot exercises, dry clothing, and a nutritious diet.<sup>1</sup>

The lessons from World War I were forgotten and the United States sustained many casualties in World War II before the problem was again taken seriously. Cold injuries ranged from high-altitude frostbite injuries to trench foot and immersion foot injuries suffered by ground troops from the Mediterranean and European theaters to the Aleutian Islands. Lessons learned in one theater or service were not used to full advantage in other theaters.<sup>1</sup>

The Eighth Air Force could attribute varying proportions of the total number of casualties in airborne personnel to high altitude frostbite from the beginning of their operations in 1942 to the end of conflict in May 1945. During fiscal year 1943 to 1944, more crew members sustained wounds from cold than from enemy fire. These losses were even more significant in that one third required hospitalization, with an average loss of 4 to 14 days of duty even for mild injuries. Of these, many required months of recuperation and many were unable ever to return to duty.<sup>1</sup> For one 14-month period ending in December 1943, 1,634 men were removed from flying status as a result of cold injuries. During this same period, 1,207 men were removed from flying status because of injuries sustained from enemy action. In 1944 the number of casualties increased because of increased combat operations, but the percentage of losses from cold injuries decreased presumably because of lessons learned as well as improved equipment and training.<sup>1</sup>

In the Mediterranean theater, during the winter of 1943 to 1944, combat ground losses from cold injuries, mainly trench foot, were significant. For the 6-month period ending 30 April 1944, there were 5,700 cold casualties of 27,602 wounded in action, or an approximate 1:5 ratio of cold-to-combat loss, for the Fifth U.S. Army alone.<sup>1</sup> These losses

become even more significant when we realize that almost all these injuries occurred among combat troops, the most difficult to replace. Many of these troops were never able to return to full duty. Of those who did return to duty, about 60% were casualties the following winter, as recurrent trench foot was a significant problem. Improved clothing and education and changes in the daily routine (such as changing socks at least daily and providing laundry and exchange of dirty socks for clean socks) were instrumental in reducing these numbers the following winter. The British had much lower cold casualty rates yet they fought in the same weather conditions and intensity of combat as the American forces. The British had troop rotation, much stricter enforcement of foot care, and better clothing than the Americans. Their cold-to-combat loss ratio was 1:45, compared to a 1:4 ratio for the Americans during the same period.<sup>1</sup>

The bitter lessons learned by the Fifth U.S. Army in Italy during 1943 to 1944 unfortunately did not reduce cold injuries in the European theater. Records show 46,000 cold injuries in the European theater from autumn 1944 to spring 1945, or about 5% of all hospital admissions for medical treatment. In the Mediterranean theater, the rate had dropped to 1.3% of admissions from 4% the previous winter. Cases peaked the week ending 17 November 1944 with 5,386 cases, with another smaller peak of 3,213 cases appearing during the week ending 29 December 1944, the Battle of the Bulge. The incidence of frostbite was much higher during December, with more cases of trench foot in November. After the spring thaw began 1 February 1945, the character of the epidemic returned to increasing numbers of trench foot cases. During November and December 1944, there were an astonishing 23,000 cases of cold injury on the Western Front. In terms of combat riflemen (4,000 to a division), the loss amounted to about 5.5 *divisions*.<sup>1</sup>

Changes in clothing types and design had occurred because of U.S. experiences in Italy during the winter of 1943 to 1944, but requisitions were made too late and clothing did not arrive in theater until after the worst of winter was over. Poorly fitting and poorly insulated shoes, a lack of adequate socks, and poorly fitting outer garments all played a role in producing the large number of cold casualties sustained in the European theater. The mistaken belief that the war would end before winter arrived in 1944 was a factor in not requisitioning the necessary cold weather clothing.<sup>1</sup>

During the Korean conflict, experiences of previous wars were once again forgotten, and 9,000 cold

injuries were reported, mostly frostbite.<sup>2</sup> Of these injuries, 8,000 occurred in the winter of 1950 to 1951.<sup>2</sup> Inactivity such as often occurs in heavy combat seemed to be a prime factor in developing cold injuries. In one study of over 1,000 cases, 67% of cold-injured individuals had been pinned down by enemy fire, sleeping in a foxhole, or riding in a truck.<sup>3</sup> Comparing injuries from the winters of 1950 to 1951 and 1951 to 1952 shows a decrease not only in numbers, but in severity as well. Nearly 50% of frostbite injuries were third and fourth degree during 1950 to 1951 compared to only 25% during 1951 to 1952.<sup>3</sup> This lessened severity seems best related to the change in U.S. military position during the second winter from more active combat to a more static defensive position.<sup>3</sup> One third of the cold injuries during the winter of 1951 to 1952 occurred during the period 22 to 26 November during an enemy attack. American troops were changing positions previously held by Republic of Korea personnel and were pinned down.<sup>3</sup> To show the importance of combat tempo on the cold casualty rate, Orr<sup>4</sup> noted the following statistics from the winter of 1950 to 1951, based on 320 soldiers from one unit admitted to Osaka Army Hospital over a 90-day period: days with no enemy contact had an average of 0.7 admissions per day; light contact, 1.2 admissions per day; moderate contact, 6.4 admissions per day; and heavy action, 9.3 admissions per day.

History has repeatedly demonstrated the devastating effects of underestimating the impact of cold weather and of failing to plan for cold weather

#### EXHIBIT 2-1

#### PREVENTION OF COLD INJURIES

---

- Leadership
- Buddy system
- Instruction and training
- Appropriate clothing
- Protection of skin from contact with metals or liquids
- Advance meteorologic data
- Frequent troop rotation
- Adequate diet and hydration
- Adequate rest

---

Data source: Corbett D. Cold injuries. *Journal of the Association of Military Dermatologists*. Fall 1982;8(2):34-40.

injuries. The British may have had fewer casualties because of the way they approached the prevention of cold injuries. Their view was that cold injuries were a result of poor leadership rather than a need for better medical care. Cold injuries, like heat injuries, are avoidable in all but the most intense combat situations. Close supervision, constant education, and adequate equipment are essential to avoiding cold injuries (Exhibit 2-1). As medical professionals, our duties and obligations are to provide the best educational support to the line unit commanders as well as to provide the best treatment for injuries.

### MECHANISMS OF HEAT LOSS

Cold injury is the damage to tissue produced by heat loss, resulting from exposure to cold. This loss can occur by several mechanisms: conduction, convection, radiation, evaporation, and respiration.

#### Conduction

Conduction loss is heat loss by direct contact with a cold object. This loss is infrequent but can be a severe source of injury. Contact with cold metal is a common injury. Liquids such as gasoline and other solvents cause rapid evaporative cooling because of their low freezing points, which can result in instant frostbite on contact in subfreezing temperatures. Heat loss by conduction may occur up to 32-fold faster in water than in air.<sup>5</sup> The source of the moisture can be perspiration, water, or other liquids.

#### Convection

Convection loss occurs when air currents dissipate the thin warm air layer that surrounds us. Body hair and clothing help to maintain this warm air layer. Wind chill is important in that the faster the wind blows, to a maximum of 40 mph, the faster the protective layer of warm air is removed (Figure 2-1).

#### Radiation

Radiation of heat occurs from exposed body surfaces. The hands, face, head, and neck are the most commonly exposed sites. At 4°C approximately 50% of body heat can be lost from an uncovered head and at -15°C this loss may increase to 75%.<sup>5</sup> Proper headgear can help elevate body tempera-

Wind Speed (mph)	Actual Temperature (°F)												
	50	40	30	20	10	0	-10	-20	-30	-40	-50	-60	
	Equivalent Chill Temperature (°F)												
Calm	50	40	30	20	10	0	-10	-20	-30	-40	-50	-60	
5	48	37	27	16	6	-5	-15	-26	-36	-47	-57	-68	
10	40	28	16	3	-9	-21	-33	-46	-58	-70	-83	-95	
15	36	22	9	-5	-18	-32	-45	-58	-72	-85	-99	-112	
20	32	18	4	-10	-25	-39	-53	-67	-82	-96	-110	-124	
25	30	15	0	-15	-29	-44	-59	-74	-89	-104	-118	-133	
30	28	13	-2	-18	-33	-48	-63	-79	-94	-109	-125	-140	
35	27	11	-4	-20	-35	-51	-67	-82	-98	-113	-129	-145	
40	26	10	-6	-22	-37	-53	-69	-85	-101	-117	-132	-148	
Wind speeds > 40 mph have little additional effect	<b>Little Danger</b> (in < 5 h with dry skin; greatest hazard is from false sense of security)				<b>Increasing Danger</b> (exposed flesh may freeze within 1 min)				<b>Great Danger</b> (exposed flesh may freeze within 30 sec)				

**Fig. 2-1.** Potential heat loss, skin cooling, and lower internal temperature can be increased by air movement. The wind-chill index integrates windspeed and air temperature to estimate associated risk of cold injury. The wind-chill temperature index is the equivalent still-air (no wind) temperature that would produce the same heat loss on bare skin. A full description of the medical aspects of military operations in the cold is the subject of US Army Research Institute of Environmental Medicine (USARIEM) Technical Note 92-2, *Sustaining Health and Performance in the Cold*. Source of chart: US Army Research Institute of Environmental Medicine Technical Note 92-2. *Sustaining Health and Performance in the Cold: Environmental Medicine Guidance for Cold-Weather Operations*. Natick, Mass: USARIEM; July 1992: 37.

ture by reducing heat loss; by removing headgear during heavy exercise, soldiers can increase heat loss.

### Evaporation

Evaporation that occurs when water vapor is released from the skin is an important form of heat loss. Clothing that allows water vapor to escape helps to conserve heat because wet skin requires increased heat loss to dry the skin. This loss of heat

keeps us alive in hot climates, but is detrimental in a cold environment.

### Respiration

Respiration is an additional source of heat loss and results from breathing out humidified, warm air. Heavy exercise results in rapid breathing and significant loss of heat and water. Covering the mouth with a mask (eg, wool) can retain some of the exhaled heat and prewarm the incoming air.<sup>3</sup>

## FACTORS INFLUENCING HEAT LOSS

Multiple factors can contribute to heat loss and the risk of cold injury. These factors include the degree of cold encountered, intensity of combat, protective cloth-

ing available, and others. Combat conditions often involve several of these factors and leave military and involved civilians at high risk for cold injuries.

## Weather and Duration of Exposure

Short exposure (ie, only a few minutes) to intense cold, especially with high winds, moisture, or skin contact with metal or volatile solvents, can lead to frostbite, whereas prolonged exposure to higher temperatures contributes to trench foot, immersion foot, and pernio. The average duration of exposure resulting in frostbite is 10 hours. During the Korean conflict, 80% of the cases in 1950 to 1951 reported a duration of exposure of 12 hours or less, with a range of 2 to 72 hours.<sup>4</sup> Trench foot and immersion foot occurred in as little as a few hours or as long as 14 days, with an average of 3 days.<sup>2</sup>

## Type of Combat Action

Units on active defense, under attack, or on the attack are at the greatest risk of cold injury. Static situations do not allow for movement and lead to prolonged exposure. Active combat and defense increase fatigue, and often do not allow for re-warming, clothing changes, or proper nutrition.

## Clothing

Modern cold weather clothing is based on the “layering” principle and employs a wind- and water-resistant outer layer. Multiple layers of loosely fitting clothing make use of the insulating properties of dead air spaces. This looseness extends to the boots as well. Footgear must be loose enough to allow for thick socks and not constrict the circulation and yet must be water-resistant. As exercise increases, clothing layers must be removable to allow for heat loss equal to the increased output. Wearing or not wearing a hat, as previously noted, can make a significant difference. Newer water-vapor-permeable outer garments permit the escape of moisture, which helps preserve the garment’s insulating capability. Finally, mittens are more protective than gloves; the individual finger slots in gloves increase surface-area heat loss.

## Other Factors

Several other factors can significantly increase the risk of suffering cold injuries:

- Young children and the elderly have greater susceptibility to cold injuries.

### EXHIBIT 2-2

#### COLD INJURY RISK FACTORS

---

Inadequate clothing  
Harsh weather (low temperatures, high winds, moisture)  
Active combat or defense  
Lack of troop rotation  
Decreased blood flow from combat injuries  
Age (children and elderly)  
Low military rank  
Previous cold injury  
Fatigue  
Discipline and training  
Psychosocial factors (eg, homeless or mentally ill out in the cold)  
Race  
Geographic origin  
Poor nutrition  
Erratic physical activity  
Vasoconstricting medications  
Use of alcohol

---

Data source: Corbett D. Cold injuries. *Journal of the Association of Military Dermatologists*. Fall 1982;8:34–40.

- Junior enlisted ranks are more susceptible to cold injury than senior enlisted ranks and officers because of their inexperience and increased exposure to cold. They may also be less receptive to preventive training.
- Previous cold injury predisposes to reinjury.
- Fatigue leads to apathy, improper wearing of clothing, and neglect of hygiene (eg, keeping feet dry).
- Lack of adequate troop rotation can increase the risk of cold injury.
- Combat injuries can be complicated by shock and decreased blood flow, further increasing the risk of cold injury.
- Race is an important risk factor, with blacks being 2- to 6-fold more vulnerable to frostbite than whites.<sup>6,7</sup>
- Overactivity leads to excessive perspiration and wetting of clothing, resulting in its loss of insulating capacity. However, underactivity is equally detrimental, causing stasis and lack of heat generation (Exhibit 2-2).

## PATHOGENESIS OF COLD INJURY

Several mechanisms are responsible for cold injury with its subsequent tissue damage and loss. Cellular damage can occur from intracellular ice crystal formation as tissue freezes. Other mechanisms of injury are believed to be secondary to vascular damage with resulting microcirculatory failure and tissue hypoxia. This leads to clumping of erythrocytes and capillary stasis. Irreversible occlusion of small vessels by aggregates of cells with thrombus formation has been demonstrated in

rewarmed tissue after freezing. In addition, as a result of tissue hypoxia and possibly the direct effect of cold, there is an increase in capillary permeability with loss of plasma into the extravascular space. These events lead to further hemoconcentration, increased viscosity, and stasis.<sup>8</sup>

Cold causes direct metabolic impairment, affecting sensitive cellular enzyme systems adversely and impairing cellular function. Injuries resulting from cold exposure can be classified as direct and indirect.

## DIRECT COLD INJURY

Direct cold injuries are caused by exposure to low temperatures and are not associated with exacerbation of an underlying disease. Examples of direct cold injury include asteatotic eczema and frostbite.

### Asteatotic Eczema

Asteatotic eczema is a pattern of skin that is dry, scaly, rough, and less flexible than normal, often with a cracked appearance. The dermatosis is more frequently seen in the elderly, though quite common in young adults, and is aggravated by cold. Dry pruritic skin leads to scratching, excoriations, and often secondary infection. The most common site is the anterior lower legs (Figure 2-2).

### *Etiology*

The dry skin of asteatotic eczema is due to decreased hydration of the stratum corneum. Decreasing sebaceous secretion, which occurs with aging, results in insufficient lipid to maintain water within the stratum corneum. Atmospheric conditions, cold, and low humidity play definite roles in developing dry skin. Poor nutrition is also a factor.<sup>9</sup>

### *Clinical Manifestations*

Scaling and pruritus is prominent in asteatotic eczema, particularly on the lower legs, but any body area can be involved. With increasing severity, fissuring in a lacework pattern and follicular hyperkeratosis eventually occur. Rubbing and scratching can lead to lichenification of affected areas.

### *Treatment*

Lubrication is the mainstay of therapy for the dry skin associated with asteatotic eczema. Any moisturizer is acceptable, and common petrolatum is excellent and usually readily available. Applying after a shower will help seal water in the skin.



**OK to put on the Web**

**Fig. 2-2.** An example of typical asteatotic eczema on a lower extremity. Note the almost fish-scale appearance and mild lichenification secondary to scratching.



## Frostbite

Frostbite is destruction of local tissue induced by temperatures below freezing. All the predisposing factors mentioned in Exhibit 2-2 may interact and lead to injury.

### Etiology

Frostbite is caused by both the actual freezing of tissue and the subsequent vascular changes that occur. The human body's initial response to cold exposure is vasoconstriction of skin vessels to reduce heat loss and conserve core temperature. The vasoconstriction persists with continued cold exposure. Blood vessel walls and endothelial cells<sup>10</sup> are altered with increased permeability and sludging of blood. Arteriovenous shunting eventually occurs and areas of tissue are bypassed and devitalized. Rapid freezing leads to the formation of intracellular ice crystals and consequent cell damage. Proteins are denatured and enzyme systems impaired. Cells dehydrate when they are damaged by cold, and water moves into the extracellular spaces.<sup>8</sup>

### Clinical Manifestations

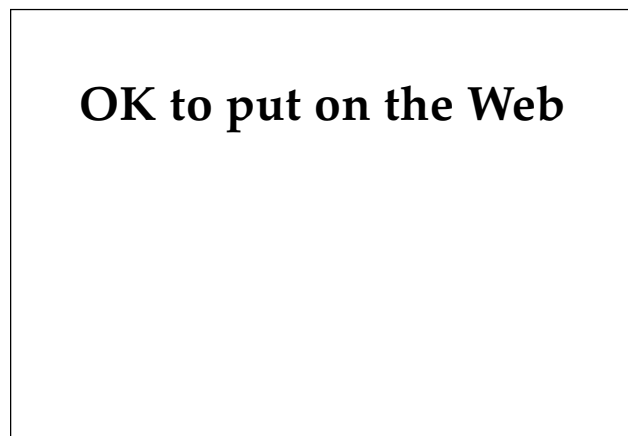
Frostbite is separated into four categories, which will be discussed in increasing order of severity: first-degree frostbite, or frostnip; second-degree or superficial frostbite; and third- and fourth-degree or deep frostbite.

**First-Degree Frostbite (Frostnip).** Frostnip is the superficial freezing of skin, often facial skin or fin-

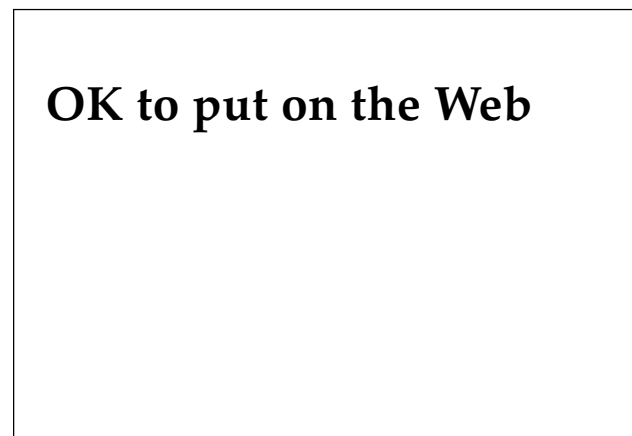
gertips, which becomes blanched and numb. If no further cold exposure occurs and the area is rewarmed, no permanent damage or tissue changes ensue. There can be redness, itching, and mild edema beginning within 3 hours after thawing and lasting up to 10 days.<sup>2,8,11</sup>

**Second-Degree Frostbite (Superficial Frostbite).** Superficial frostbite freezes the skin and subcutaneous tissues but spares the deeper structures, which are still soft to deep palpation. Blanching and numbness are present. As the tissue thaws, the patient develops pain, erythema, and swelling of the affected sites. The skin can take on a mottled cyanotic appearance (Figure 2-3). Blisters may form (Figure 2-4), usually within 24 to 48 hours but sometimes as soon as 6 hours after thawing. These blisters are clear and often extend to the tips of digits, which is considered a good prognostic sign (Exhibit 2-3). Only ruptured blisters should be debrided. Over the next several weeks, the tissue may mummify, turn black, and slough, revealing red, atrophic new skin (Figures 2-5 and 2-6). Hyperhidrosis often occurs by the second to third week, and long-term cold sensitivity can also arise.

**Third- and Fourth-Degree Frostbite (Deep Frostbite).** Both third- and fourth-degree frostbite involve loss of deep tissue. Third degree frostbite involves freezing of skin and subcutaneous tissue with tissue loss and ulceration. With thawing, vesicles may form, but they are often smaller and hemorrhagic and do not extend to the tips of digits. After early anesthesia, severe pain can begin within a few days. Hard black eschars form and separate over several weeks, leaving a granulation base (Figure 2-7). Healing time averages 68 days, and



**Fig. 2-3.** Early appearance of either superficial or deep frostbite. Note the mild edema and cyanotic appearance of the toes.



**Fig. 2-4.** Superficial frostbite with large blebs extending to the fingertips.

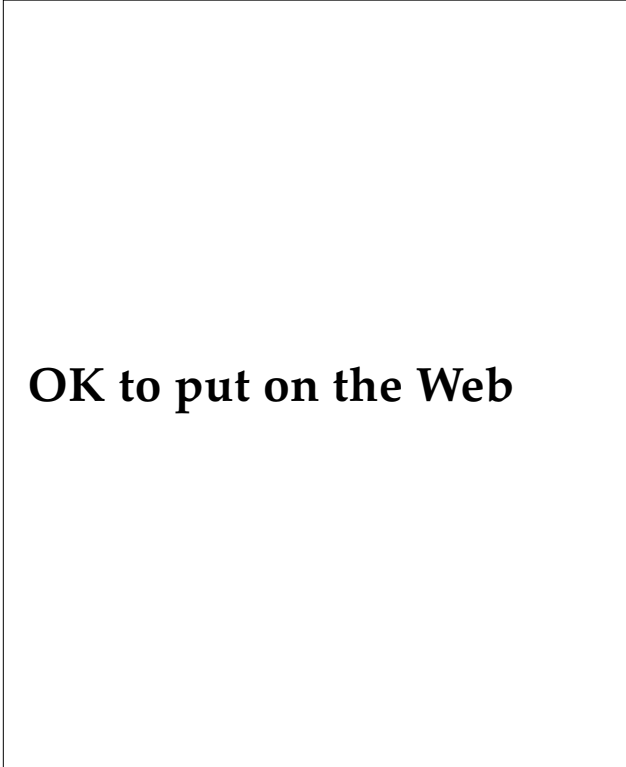
**EXHIBIT 2-3****PROGNOSTIC SIGNS OF FROSTBITE****Favorable Indicators**

- Large, clear blebs extending to the tips of the digits
- Rapid return of sensation
- Rapid return of normal (warm) temperature to the injured area
- Rapid capillary filling time after pressure blanching
- Pink skin after rewarming

**Unfavorable Indicators**

- Hard, white, cold, insensitive skin
- Cold and cyanotic skin without blebs after rewarming
- Dark, hemorrhagic blebs
- Early evidence of mummification
- Constitutional signs of tissue necrosis, such as fever and tachycardia
- Cyanotic or dark red skin persisting after pressure
- Freeze-thaw-refreeze injury

Data source: US Department of the Navy. *Cold Injury*. Washington, DC: DOD; NAVMED P-5052-29. March 1970: 1-14.



**OK to put on the Web**

**Fig. 2-5.** Same patient seen in Figure 2-3, approximately 6 weeks later, showing demarcation.

hyperhidrosis, which can appear at 4 to 10 weeks, may persist for months.<sup>2</sup>

Fourth-degree frostbite involves complete necrosis and loss of deep tissue including bone (Figure 2-8). The deeper tissues are solid to deep palpation. With rewarming, the skin can become purple to red and anesthetic. Edema is usually found proximal to the area of fourth-degree injury, reaching a peak by 6 to 12 hours.<sup>2</sup> The area may then rapidly progress to a dry type of gangrene with lines of demarcation noted as early as 72 hours post-thaw.<sup>11</sup> A slower progression also can occur, with eschar and gangrene formation not evident until 2 to 3 weeks after thawing. Severe pain and intense burning will occur with thawing, and large amounts of analgesics may be needed.<sup>9</sup> Paresthesias appear 3 to 13 days after rewarming, lasting for at least 6 months in more than 50% of frostbite victims.<sup>12</sup> The line of demarcation becomes apparent in an average of 36 days and extends to bone 60 to 80 days after injury.<sup>2</sup> Long-term frostbite sequelae consist of cold sensitivity, paresthesia, numbness, pain, and hyperesthesia.<sup>12</sup> Other problems include frostbite arthritis, which occurs weeks to years later and resembles osteoarthritis,<sup>13</sup> and hyperhidrosis.<sup>9</sup>



**OK to put on the Web**

**Fig. 2-6.** Early presentation of superficial frostbite. No loss of digits took place. Note shallow ulcerations on plantar aspect of feet.

## OK to put on the Web

**Fig. 2-7.** Hands with deep frostbite and well-demarcated areas of eventual tissue loss. These will autoamputate if left alone, allowing for the preservation of maximal tissue.

### *Treatment*

Prevention of frostbite is the best form of therapy. Frostnip can be treated immediately in the field. Rewarming can be accomplished by placing fingers in the axilla, blowing warm air over the frozen surfaces, or placing a warm hand on the area. Recovery is usually prompt and no long-term therapy is necessary.

Frozen parts should not be thawed until definitive care is available (ie, no possibility of refreezing). Once thawed, the part is painful, and if the feet are involved, the individual will be unable to walk. Freeze-thaw-refreeze cycles are also very damaging and must be avoided. When treating military personnel, one must consider the availability of definitive care. If transportation is not available, the soldier with frostbite may have to continue to fight or walk out of the combat area. Neither action would be possible if frostbitten feet were permitted to thaw.

The more serious types of frostbite are treated by rapid rewarming of the affected areas in a warm-water bath at 40°C to 42°C until the most distal part is flushed.<sup>4</sup> Rewarming is painful and analgesia is required. Bed rest, elevation of the affected extremity, and protection of the injured area with twice daily antiseptic whirlpool baths for gentle debridement are essential. Tetanus toxoid should be given to all victims. Secondary infection is common, but not all sources recommend prophylactic antibiotics. Smoking is not permitted. Early

## OK to put on the Web

**Fig. 2-8.** This hobo suffers from deep frostbite. He was locked in a freezer car for approximately 18–24 hours, with these unfortunate results.

heparinization, begun within 36 hours<sup>2</sup> and stopped in 2 to 3 days,<sup>11</sup> has been shown to be of help, but anticoagulation of individuals in a field setting may be impossible and there may be other trauma to consider.<sup>2</sup> Low molecular weight dextran, 1.5 gm/kg intravenously on the first day, then 0.75 mg/kg intravenously daily for 5 days, has been shown to decrease blood viscosity and increase tissue perfusion in limited trials.<sup>14</sup> Intraarterial reserpine, 0.25 to 0.5 mg, can be used if vascular spasm is noted on angiogram at about the 10-day point, with repeat angiogram in 2 days.<sup>11</sup> Surgical sympathectomy has been used late in the healing process for severe cases<sup>8</sup> but its use is not universally recommended.<sup>6</sup> Both extensive surgical debridement and amputation are to be avoided until devitalized tissue is clearly demarcated and spontaneous sloughing has occurred, which may take months.<sup>9</sup> Moist gangrene with infection is, of course, an exception to this rule.

## INDIRECT COLD INJURY

Indirect cold injury is associated with exposure to low temperatures as well as other factors, and is often linked to disease processes that are exacerbated by cold. Finding skin lesions after cold exposure can lead to the discovery of underlying disease.

### Pernio

Pernio, or chilblain, refers to the development of bluish red patches on arms and legs that are chronically exposed to cold, damp climates. A mild form of cold injury, pernio was described as early as 1680.<sup>8</sup> This condition is prevalent in England and is less commonly seen in very cold climates where heating is usually more adequate and protective clothing is worn on a regular basis.<sup>9</sup>

### Etiology

Vasospasm is the primary mechanism causing pernio in predisposed individuals who appear to have an inherently high peripheral vascular tone. The nonfreezing cold is amplified by high humidity. The vasospasm produces local tissue hypoxia, which leads to the initial cyanotic and erythematous skin lesions.<sup>8</sup>

Histological evaluation of pernio reveals edema of the papillary dermis and a superficial or both superficial and deep perivascular lymphocytic infiltrate. Necrotic keratinocytes and lymphocytic vasculitis have also been reported.<sup>9</sup>

### Clinical Manifestations

Pernio is divided into *acute* and *chronic* disease. The acute form is seen primarily in children and young adults. The chronic form is seen most commonly in adults. Acute pernio presents with bluish red, slightly edematous patches, most commonly on the lower extremities. Prolonged exposure to damp cold with inadequate protection precedes the development of lesions. The skin findings persist for 7 to 10 days or less, and resolve spontaneously with a residual brownish red hyperpigmentation in many cases.<sup>8</sup>

Chronic pernio—edematous, cyanotic lesions with secondary ulceration and hemorrhage—is seen after repeated episodes of acute pernio. Patients can present with subcutaneous nodules accompa-

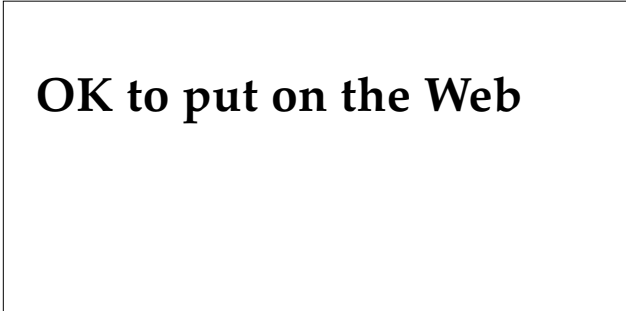
nied by a burning sensation, pruritus, or both. Acute pernio is more common in winter, but with repeated episodes lesions may become persistent, with the atrophy and ulcerations lasting throughout the year. The differential diagnosis includes nodular vasculitis, erythema induratum, erythema nodosum, and livedo vasculitis with ulcerations.<sup>8</sup>

### Treatment

Protective clothing and warmth are the mainstay of therapy for pernio. Emollient creams can be of benefit. Antibiotics and topical care may be needed if ulcerations or secondary infection is present. Vasodilating drugs can be useful in some patients. Nifedipine has been effective at a dose of 20 mg three times daily.<sup>9</sup> Sympathectomy has been utilized in extreme cases only, but does not prevent recurrences.<sup>8</sup>

### Livedo Reticularis

Livedo reticularis is a persistent reticulated pattern of red to bluish coloration of the skin (Figure 2-9). The skin mottling can be transient as seen with infants exposed to cold and is known as *cutis marmorata*. If the pattern persists after rewarming then the term *livedo reticularis* is used. Congenital livedo reticularis (*cutis marmorata telangiectatica congenita*)<sup>15</sup> results from several inherited syndromes, such as Down's syndrome, Cornelia de Lange syndrome, homocystinuria, and neonatal



**OK to put on the Web**

**Fig. 2-9.** Livedo reticularis. The netlike vascular pattern is typical of the disease.

lupus erythematosus. These disorders display persistent forms of livedo that are not related to cold exposure. The causes of acquired livedo reticularis are numerous (Exhibit 2-4). It can be benign, as with cold, or may be a sign of serious underlying disease such as vasculitis, connective tissue disease, or malignancy. Livedo derives from the Latin *liveo*, meaning “blue, black, or livid.” The term was first used by Hebra in 1868.<sup>8</sup>

### ***Etiology***

Similar physiological explanations for the livedo pattern were given by Renault (1883), Unna (1896), and Spalteholz (1927).<sup>16</sup> It was postulated by all three authors that the cutaneous circulation is arranged in “cones,” 1 to 3 cm in diameter, with the apex deep in the dermis and a central ascending arteriole. They proposed that the density of the

#### **EXHIBIT 2-4**

#### **CAUSES OF ACQUIRED LIVEDO RETICULARIS**

---

Ex 2-4 is not shown because the copyright permission granted to the Borden Institute, TMM, does not allow the Borden Institute to grant permission to other users and/or does not include usage in electronic media. The current user must apply to the publisher named in the figure legend for permission to use this illustration in any type of publication media.

---

Adapted with permission from Fleischer A, Resnick S. Livedo reticularis. *Dermatol Clin.* 1990;8(2):347–354.

arterial bed is decreased at the margins, but that the superficial venous plexus is more prominent at the periphery.<sup>16</sup> If this theory were valid, any process that impedes blood flow would result in a larger proportion of deoxygenated hemoglobin. There would then be a more livid color at the margins of the cones, and the reticulated pattern would be prominent.<sup>8</sup> This hypothesis does help to explain the clinical findings. However, anatomical studies using serial thick sections have failed to demonstrate the proposed pattern.<sup>16</sup>

### *Clinical Manifestations*

The congenital form of livedo reticularis can be regional or widespread, and is associated with superficial ulcerations. Other anomalies are found in up to 50% of these cases.<sup>16</sup> The acquired form can be seen in many conditions (see Exhibit 2-4). These conditions are exacerbated by exposure to cold, but rewarming does not cause resolution of the livedo pattern. The red-blue net pattern is usually asymptomatic unless ulceration has occurred, and is seen most commonly on the lower legs. The pattern can be seen on other body areas as well, including upper legs, buttocks, lower trunk, and arms.<sup>8</sup> Finding the underlying cause for livedo is important, and cold exposure may make the disease more evident and lead to a definitive diagnosis and treatment.

### *Treatment*

No specific therapy for livedo reticularis exists. Underlying treatable causes must be addressed.

### **Acrocyanosis**

Acrocyanosis is characterized by symmetrical bluish discoloration and coolness of the extremities and is often associated with hyperhidrosis of the palms and soles. The disorder is usually seen in colder climates.

### *Etiology*

The exact cause of acrocyanosis is unknown but there are several theories. Nailfold biomicroscopy reveals decreased blood velocity and dilated capillaries and venules in patients with acrocyanosis. Various investigators have localized initiating events to arterioles, capillaries, and the venous system. It has also been proposed that the initial

change is an alteration in blood viscosity that is enhanced by cooling and leads to damage of the capillaries in the papillary dermis.<sup>8</sup>

There have been various reports of acrocyanosis associated with conditions such as mental deficiency,<sup>17</sup> but these have not been independently confirmed.<sup>8</sup> A familial predisposition has been noted.<sup>17</sup>

### *Clinical Manifestations*

Persistent symmetrical cyanosis and coolness of the hands and feet are the most common findings of acrocyanosis, with occasional involvement of the chin, lips, and nose. Hyperhidrosis and edema of the palms and soles are also commonly noted. Cyanosis increases as the temperature decreases and changes to erythema with elevation of the dependent part. Peripheral pulses are usually intact, and the symptoms may persist for years after typically beginning in the second or third decade. Vascular disease and ulceration are absent, which distinguishes acrocyanosis from other diseases such as Raynaud's (Figure 2-10).<sup>8</sup>

### *Treatment*

The mainstay of therapy for acrocyanosis is protection from the cold. Other forms of treatment have included  $\alpha$ -adrenergic blocking agents, which may provide temporary relief.<sup>8</sup>



**OK to put on the Web**

Fig. 2-10. Acrocyanosis. Note that the cyanotic appearance stops at the palmar crease, which is common in this disorder.

## Erythrocyanosis

Erythrocyanosis consists of cyanotic discoloration occurring over areas of thick, subcutaneous fat such as the thighs, and is seen most commonly in winter. The lesions may be nodular and similar to pernio. Discussions of this disorder are usually found in older British literature. Erythrocyanosis is rarely encountered now.<sup>9,17</sup>

### *Etiology*

Erythrocyanosis may be a form of cold panniculitis; however, the exact etiology is unknown.<sup>9,17</sup>

### *Clinical Manifestations*

Erythrocyanosis is usually seen in women on the legs and thighs and is often found in horseback riders. The skin is at times tender.

### *Treatment*

Warm clothing and reduction of the insulating fat layer are the only effective treatments for erythrocyanosis.

## Trench Foot

Trench foot, or immersion foot, is seen after prolonged exposure to cold and dampness at temperatures above freezing (0°C–10°C).<sup>8</sup> This subject is discussed in detail in Chapter 4, Immersion Foot Syndromes.

## Cold Panniculitis

Cold panniculitis consists of tender subcutaneous nodules occurring with cold exposure on uncovered areas. Cheeks and legs are the most common sites, and children are more often affected than adults.

### *Etiology*

Because the nodules of cold panniculitis are usually seen in children, it has been postulated that the more highly saturated fat seen in newborns solidifies at a higher temperature than the adult's less saturated fat.<sup>17</sup> Excessive fibrinolytic activity and cryofibrinogens have been detected in the serum of

affected individuals.<sup>8</sup> It has also been thought to be a hypersensitivity reaction.<sup>8,17</sup>

### *Clinical Manifestations*

Tender nodules develop several hours after cold exposure of unprotected areas. The legs and cheeks are common sites, as previously mentioned. The nodules may enlarge and become plaques, which then spontaneously resolve over 2 to 3 weeks.

### *Treatment*

No specific therapy exists for cold panniculitis. Proper clothing and avoidance of cold will prevent most cases.

## Raynaud's Disease and Phenomenon

Raynaud's disease is a paroxysmal constriction of small arteries and arterioles of the extremities, usually precipitated by cold. However, it can be induced by other stimuli including emotions. The etiology of Raynaud's disease is unknown. By definition, Raynaud's phenomenon (syndrome) occurs secondary to an underlying systemic disease or occupational trauma (Exhibit 2-5).<sup>8,17,18</sup>

Raynaud's disease was first described by Raynaud in 1862. Hutchinson noted in 1901 that the clinical manifestations of Raynaud could be seen in association with several different conditions. He

### EXHIBIT 2-5

#### CAUSES OF RAYNAUD'S PHENOMENON

- Cold injury sequelae (frostbite and trench foot)
- Arterial occlusive disease (arteriosclerosis)
- Collagen vascular diseases (systemic lupus, dermatomyositis)
- Occupational trauma (jackhammer, typist, mechanic, etc.)
- Cold agglutinins (atypical pneumonia, lymphoma, etc.)
- Cryoglobulins (neoplastic, collagen vascular, chronic disease)
- Neurologic disorders (central and peripheral)

suggested that when an underlying disease process could be identified, the condition should be called Raynaud's phenomenon. When the condition is idiopathic, it is referred to as Raynaud's disease.<sup>8</sup>

Raynaud's is seen in females 5-fold more often than in males, with an average age of onset of 31 years and a range of 4 to 68 years of age. In males, 73% of patients were less than 40 years of age. After long-term follow-up in two studies, 60% to 70% of the patients with Raynaud's could be described as having primary Raynaud's disease.<sup>8</sup>

### *Etiology*

The pathophysiology of the vasospastic attacks in primary Raynaud's disease is unknown. In secondary Raynaud's phenomenon, the vasospasm can be caused by sympathetic stimuli, external physical pressure (seen in farmers, typists, pianists, and individuals who use vibrating tools, eg, hard-rock miners), and decreased blood flow secondary to increased blood viscosity or arterial disease. A study on Raynaud's disease and phenomenon showed that vasospasm could be induced in fingers even with a lidocaine digital nerve block in place, arguing against the widely believed etiologic role of sympathetic hyperactivity.<sup>19</sup>

Histological evaluation of vessels in Raynaud's patients has revealed intimal thickening, thrombus formation, and recanalization in the digital arteries of patients with severe disease, especially those with secondary disease.

### *Clinical Manifestations*

With Raynaud's disease and phenomenon, the skin classically undergoes a triple response with initial blanching or pallor proceeding to cyanosis indicative of vasospasm. The third (recovery) stage is erythema, probably secondary to an end-stage hyperemia.<sup>8</sup> Typically the problem is noted distally in a bilateral digital distribution, and eventually the entire digit becomes involved. Involvement of the hands, feet, and thumbs is less common. Unilateral involvement has been reported. The lips, tip of the nose, ears, and, less commonly, even the tongue can be involved.<sup>8,17</sup> Numbness is common, and pain may be mild or absent; paresthesia can occur during the recovery phase. Nails may show longitudinal ridging, increased brittleness, onycholysis, koi-

lonychia, and thinning of the plate.<sup>8,17</sup> Ulcerations and stellate scars occur on the tips of fingers and toes. In severe cases gangrene develops, and amputation of the gangrenous tips of digits has been necessary on rare occasions (0.4% of cases).<sup>8</sup>

### *Treatment*

The goal of treatment for Raynaud's is vasodilation of the involved vessels with minimal side effects. Prevention of episodes is of primary importance. Protective warm clothing, especially for the hands and feet, is important to avoid localized and generalized cooling. Sudden cooling of the skin, such as occurs when reaching into refrigerators and freezers, entering air-conditioned buildings, and handling cold objects, is to be avoided. Patients with underlying disease that causes the vessels to have limited capacity to dilate are the most difficult to manage.

Vasodilating agents typically have too many side effects to be of extensive use in treating Raynaud's. These sympatholytic agents, which include methyl dopa, phenoxybenzamine, tolazoline, guanethidine, and oral or intraarterial reserpine, have generally been abandoned. However, prazosin hydrochloride has been shown to be effective and has acceptable side-effect levels. In one 8-week study,<sup>20</sup> the drug was effective when given in doses of 1 to 2 mg orally three times daily. Doses up to a maximum of 20 mg per day are used to treat hypertension.<sup>20</sup> Postural hypotension can occur suddenly, and the initial doses should be given cautiously and while the soldier is supine.<sup>8</sup>

Biofeedback has been shown to increase digital blood flow but time and expense can be prohibitive. Surgical sympathectomy, once popular, has been shown to be less useful, and now conservative therapy is usually advocated. Sympathetic stellate ganglion block can be useful in acute cases of severe digital infarction and can be given daily by an experienced anesthesiologist.<sup>8</sup>

Direct vasodilating agents, such as the calcium channel-blocking agent nifedipine, have been useful in treating Raynaud's. In a 7-week study,<sup>21</sup> effective doses were begun at 10 mg three times daily and, if well tolerated, were increased to 20 mg three times daily. Again, Raynaud's patients with fixed vascular disease benefit the least.<sup>8</sup> Topical nitrates appear to improve digital blood flow and temperature and can be useful in conjunction with



other therapies. Two percent glyceryl trinitrate in lanolin applied for 3 minutes and allowed to remain on for 20 minutes before removal may provide

temporary improvement in digital blood flow and skin temperature.<sup>22</sup>

Patients must *not* smoke under any circumstance.

### SUMMARY

History has demonstrated that cold injuries may cause a loss of combat troops that can exceed battle casualties. Proper training of our combat forces, combined with proper supplies and planning, can minimize losses to cold injury. Good planning requires that a number of questions be posed: What weather conditions and intensity of combat will be encountered? Are sufficient supplies such as food and clothing available? Have the officers and enlisted soldiers been trained in prevention? Do commanders have sufficient troops for frequent rotations to the line?

Cold injuries most often involve front-line infantry,

a commander's most valuable commodity. These injuries often require months of rehabilitation or cause permanent disability. Because large numbers of cold injuries usually occur only during times of war, exact treatment protocols have not been developed, and further research needs to be done. Early recognition of signs and symptoms and immediate institution of therapy are critical. Training of medical officers in recognition and treatment of diseases caused or exacerbated by cold must be a priority. Line officers also need our help as their medical advisors in establishing adequate preventive measures and enabling the swift return of troops to duty.

### REFERENCES

1. Whayne TF, DeBakey ME. *Cold Injury, Ground Type, in World War II*. Washington, DC: Medical Department, US Army, Office of The Surgeon General; 1958.
2. US Departments of the Army, Navy, and Air Force. *Cold Injury*. Washington, DC: DOD; TB MED 81, NAVMED P-5052-29, AFP 161-11. 30 September 1976: 1–15.
3. Hanson H, Goldman R. Cold injury in man: A review of its etiology and discussion of its prediction. *Milit Med*. October 1969;134(11):1307–1316.
4. Orr K, Fainer D. Cold injuries in Korea during winter of 1950–1951. *Medicine*. 1952;39:177–220.
5. Reuler J. Hypothermia: Pathophysiology, clinical settings, and management. *Ann Intern Med*. 1978;89:519–527.
6. Vaughn B. Local cold injury—menace to military operations: A review. *Milit Med*. 1980;145(5):305–310.
7. Sumner D, Criblez T, Doolittle W. Host factors in human frostbite. *Milit Med*. 1974;139:454–461.
8. Demis DJ. *Clinical Dermatology*. 17th ed. Philadelphia: JB Lippincott, 1990.
9. Page E, Shear N. Temperature-dependent skin disorders. *J Am Acad Dermatol*. 1988;18(5):1003–1019.
10. Marzella L, Jesudass R, Manson P, Myers R, Bulkley G. Morphologic characterization of acute injury to vascular endothelium of skin after frostbite. *Plast Reconstr Surg*. 1989;83(1):67–75.
11. Leecost T. Frostbite, diagnosis and treatment. *Journal of the American Podiatry Association*. November 1981;71(11):599–603.
12. Taylor M, Kulungowski M. Frostbite injuries during winter maneuvers: A long-term disability. *Milit Med*. 1989;154(8):411–412.
13. Glick R, Parnami N. Frostbite arthritis. *J Rheumatol*. 1979;6(4):456–460.

14. Bangs C, Boswick J, Hamlet M, Sumner D, Weatherley-White RCA. Winter problems: When your patient suffers frostbite. *Patient Care*. 1 Feb 1977:132–157.
15. Cohen P. Cutis marmorata telangiectatica congenita: Clinicopathologic characteristics and differential diagnosis. *Cutis*. 1988;42:518–522.
16. Fleischer A, Resnick S. Livedo reticularis. *Dermatol Clin*. 1990;8(2):347–354.
17. Corbett D. Cold injuries. *J Assoc Military Dermatologists*. Fall 1982;8:34–40.
18. Coffman J. The enigma of primary Raynaud's disease. *Circulation*. 1989;80(4):1089–1090.
19. Freedman R, Mayes M, Sabharwal S. Induction of vasospastic attacks despite digital nerve block in Raynaud's disease and phenomenon. *Circulation*. 1989; 80(4): 859–862.
20. Surwit R, Gilgor R, Allen L, Duvic M. Double-blind study of prazosin in the treatment of Raynaud's phenomenon in scleroderma. *Arch Dermatol*. March 1984;120:329–331.
21. Rodeheffer R, Rommer J, Wigley F, Smith C. Controlled double-blind trial of nifedipine in the treatment of Raynaud's phenomenon. *N Engl J Med*. 1983;308(15):880–883.
22. Kleckner M, Allen E, Wakim K. The effect of local application of glyceryl trinitrate (nitroglycerine) on Raynaud's disease and Raynaud's phenomenon, studies on blood flow and clinical manifestations. *Circulation*. May 1951;3:681–689.

# Chapter 3

## SKIN DISEASES ASSOCIATED WITH EXCESSIVE HEAT, HUMIDITY, AND SUNLIGHT

LEONARD SPERLING, M.D.\*

---

### INTRODUCTION

#### CLASSIC FORMS OF HEAT INJURY

- Heat Cramps
- Heat Exhaustion
- Heatstroke

#### DERMATOSES CAUSED BY EXCESSIVE ENVIRONMENTAL HEAT

- Miliaria
- Hypohidrosis Syndrome
- Tropical Acne
- Cholinergic Urticaria

#### DERMATOSES EXACERBATED BY HEAT AND HUMIDITY

- Dyshidrotic Eczema
- Bacterial Infections of the Skin
- Fungal Infections of the Skin
- Friction Blisters
- Erythermalgia

#### DERMATOSES CAUSED BY EXCESSIVE SUN EXPOSURE OR ALLERGY TO SUNLIGHT

- Sunburn
- Phototoxicity and Photoallergy
- Polymorphous Light Eruption
- Solar Urticaria

#### DERMATOSES EXACERBATED BY SUNLIGHT

- Porphyria Cutanea Tarda
- Erythropoietic Protoporphyrria
- Others

### SUMMARY

\*Lieutenant Colonel, Medical Corps, U.S. Army; Dermatology Service, Walter Reed Army Medical Center, Washington, D.C. 20307-5001

## INTRODUCTION

Whenever the armed forces of the United States have first entered extremely hot climates, a large number of heat-related casualties have been encountered.<sup>1</sup> In all 20th-century wars, however, soldiers have quickly adjusted and were able to function successfully. Operations Desert Shield and Desert Storm (1990–1991) were no exceptions. In the Saudi Arabian desert, troops relearned the lessons of North Africa and the Pacific islands of World War II, where the casualties included numerous heat-related deaths. The same lessons were relearned during the summer months in Korea and in the jungles of Vietnam.

*Heat injury* is generally defined as a fairly acute physiological stress manifested by such conditions as heat cramps, heat exhaustion, and heatstroke.<sup>2</sup> Heat also has many deleterious effects on the skin, and several disorders are caused by, or are severely exacerbated by, high ambient temperatures. This is particularly important because the skin is largely responsible for thermoregulation in humans. Skin acts as a radiator and, in concert with fluids and electrolytes, can allow soldiers to withstand remarkably hot climates for indefinite periods. Certain skin diseases impair this critical thermoregulatory function, predisposing the affected soldier to the various types of acute heat injury.

The various skin diseases related to heat have another important impact: their disabling effects on

troops. Skin diseases accounted for over 12% of total outpatient visits during the Vietnam conflict.<sup>3</sup> The three most common ailments in this group were miliaria, pyoderma (bacterial infections of the skin), and tinea (fungal infections of the skin), all of which are intimately related to heat and humidity. Over one half the patients who were evacuated from Vietnam for dermatological ailments suffered from tropical acne, eczematous dermatitis, dyshidrosis, and fungal infections.<sup>3</sup> The tropical environment of Southeast Asia clearly played an important role in the pathogenesis of all of these conditions.

Warm climates present another danger to troops: sun exposure. A variety of dermatoses are caused or severely exacerbated by solar radiation. Tropical climates are notorious for their long hours of intense sunshine. Most desert climates share this abundance of radiation, with an additional ingredient—lack of shelter from the sun.

Although problems due to heat will be discussed separately from those due to sunlight (visible and ultraviolet [UV]), in many cases these factors are related. Perspiring soldiers are apt to remove as much clothing as possible, thus predisposing themselves to burns from UV light. The injury of sunburn can impair the sweating mechanism, and by so doing impair the thermoregulatory mechanisms that allow soldiers to function in the heat.

## CLASSIC FORMS OF HEAT INJURY

A discussion of heat-related dermatoses would not be complete without a review of heat injury in general. The subject is covered in detail in Technical Bulletin MED 507, *Prevention, Treatment and Control of Heat Injury*.<sup>2</sup> The resting human eliminates about one fourth of the basal metabolic heat production via the lungs and skin.<sup>2</sup> If body temperature starts to increase above its normal set point, the first physiological responses are vasodilation of the skin and an increase in the heart rate. These allow the skin to function more efficiently as a radiator of excess heat. When the body no longer can lose sufficient heat by simple radiation, and the skin temperature reaches or exceeds a critical level, the activity of the sweat glands increases. *The heat loss that can be achieved by sweating becomes the most important, and sometimes the only, means of maintain-*

*ing a normal core body temperature.*<sup>2</sup> As environmental humidity increases, the ability of the air to evaporate the sweat decreases, thus reducing cooling. Inadequate cooling results in continued sweating, which results in a loss of body water and salt. Initially, the lost water is drawn from the circulating blood volume. If this fluid is not replaced, the resulting dehydration adds strain to the circulatory system, which has already resorted to an increased heart rate in its efforts to radiate heat from the skin. Hyperventilation (panting) will increase heat loss from the lungs, but creates a respiratory alkalosis that contributes to the signs and symptoms of heat-exhaustion syndromes.

Air motion (convection), in the forms of natural breezes and artificial wind produced by fans, is an important factor in cooling. It replaces the layer of

air next to the skin with cooler and dryer air, improving heat loss by conduction and accelerating the evaporation of sweat. The efficacy of air motion diminishes progressively as humidity and air temperature increase. If air temperature becomes higher than skin temperature, heat transfer by conduction will proceed from the air into the skin.

Other factors in the production of heat injury include the physical work being performed and the physical condition of the individual. Intense work obviously increases body heat and the burden on homeostatic mechanisms such as sweating and heart rate. Lack of acclimatization, obesity, dehydration, excessive intake of alcohol, lack of sleep, increasing age, poor general health, and fatigue of the homeostatic mechanisms over time all decrease a person's ability to withstand high temperatures. The following discussions of heat cramps, heat exhaustion, and heatstroke summarize the various forms of heat injury.<sup>2</sup>

### **Heat Cramps**

Heat cramps result primarily from the excessive loss of salt relative to water from the body. The muscles of the extremities and the abdominal wall are subject to these painful cramps. Body temperature remains normal unless heat exhaustion has set in. Treatment is simply the intravenous administration of normal (0.9%) saline solution in adequate quantities.

### **Heat Exhaustion**

Heat exhaustion results from peripheral vascular collapse due to excessive salt depletion and dehydration. It is characterized by profuse sweating, headache, tingling in the extremities, pallor,

shortness of breath, palpitations, and gastrointestinal symptoms. Neuromuscular disturbance (incoordination) and cerebral dysfunction (clouded sensorium) may be present in varying degrees. Rectal temperature is often elevated. The signs and symptoms are basically those of shock; normal saline must be administered, and the soldier should rest. Any physical factor that promotes the return of blood to the heart is indicated, as is true for other forms of shock.

### **Heatstroke**

Heatstroke is a medical emergency with a high mortality rate. It results when the normal thermoregulatory mechanisms become nonfunctional, and the main source of heat loss (sweating) is blocked. Heat exhaustion can act as a prodrome, but the onset of heat shock is abrupt, with loss of consciousness, seizures, or delirium. Core body temperature rises rapidly to 106°F to 108°F or higher. Signs and symptoms of obvious shock are evident, and if elevated body temperatures persist, organ failure (eg, kidney, brain, or heart) occurs. The first goals of treatment are to lower the body temperature and simultaneously to replace fluids and electrolytes.

These forms of heat injury become less likely with proper acclimatization. If troops are exposed to a hot climate and gradual incremental physical activity over a 2-week period, substantial tolerance to the ill effects of heat can be acquired. This process includes improvement in cardiovascular performance, sweating, and probably other factors as well. Even though acclimatization to a hot, dry, desert climate is an effective way to prepare for hot, humid, tropical climates, adjustment to tropical conditions still requires several weeks of increasing exercise at the actual site to be fully effective.

## **DERMATOSES CAUSED BY EXCESSIVE ENVIRONMENTAL HEAT**

Overexposure to environmental heat can cause a number of skin disorders including miliaria, hypohidrosis syndrome, tropical acne, and cholinergic urticaria. The pathogenesis and treatment of these disorders are not militarily unique but are among the most prevalent among soldiers newly introduced to hot climates.

### **Miliaria**

Miliaria is probably the simplest and purest example of a skin disease attributable almost entirely

to the effects of heat and humidity.<sup>4</sup> Miliaria crystallina (sudamina), miliaria rubra, miliaria profunda, and miliaria pustulosa are clinical subtypes.<sup>5</sup> This disorder of sweating was one of the most common diseases affecting soldiers stationed in tropical climates during World War II.<sup>6</sup> Not only was miliaria a very common problem in areas such as the Southwest Pacific and the China-Burma-India theater, it was also common within warmer regions of the United States. Sixty-six percent of the naval personnel studied on Guam in 1945 exhibited miliaria rubra at some time during their first 7

months of duty.<sup>7</sup> In Vietnam, miliaria was very common but was almost never a direct cause of disability in troops. However, some physicians thought that it predisposed soldiers to fatigue and heat exhaustion. Miliaria was a major cause of outpatient visits and referrals to dermatologists.<sup>3</sup>

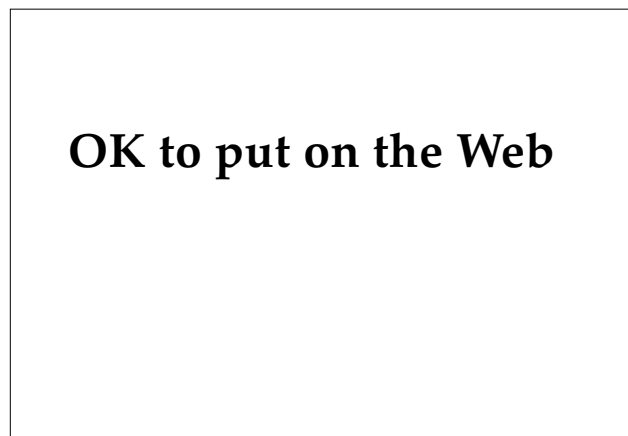In Vietnam, where the ambient temperature had marked seasonal changes, the incidence of clinically significant miliaria in soldiers rose sharply after the temperature exceeded 38°C. Cooks were especially vulnerable to the disorder because they worked in small, poorly ventilated rooms where both temperature and humidity were especially high. Some soldiers in Vietnam were clearly more susceptible to the condition than others, an observation that was never explained; the condition occurred among those who were heat-acclimatized as well as among those who were not.<sup>3</sup>

### *Miliaria Crystallina*

*Miliaria crystallina* is characterized by clear, superficial vesicles without any evidence of inflammation (Figure 3-1). It is typically asymptomatic and short-lived. No treatment is necessary, and the condition usually resolves spontaneously in a few hours to a few days.

### *Miliaria Rubra*

The most common form of miliaria is *miliaria rubra*, more commonly known as prickly heat.



**Fig. 3-1.** *Miliaria crystallina* exhibits clear, superficial vesicles with no signs of inflammation. It is usually asymptomatic and short-lived, and no treatment is needed.

*Miliaria rubra* usually begins in the flexural folds and intertriginous parts of the body. It appears as a deeply erythematous, follicular, papulovesicular eruption. Typically it flares during the day and subsides to some extent at night. Untreated, the rash often becomes increasingly widespread and severe, and eventually persists even during the night. Its character also changes with time, becoming more inflammatory and fixed. If perspiration is excessive, the erythematous papules become capped by small, firm vesicles.<sup>6</sup> *Miliaria rubra* causes considerable discomfort but is seldom disabling. The condition does not seem to be influenced by race, obesity, complexion, place of former habitat, gender, or tanning.<sup>7</sup>

### *Miliaria Profunda*

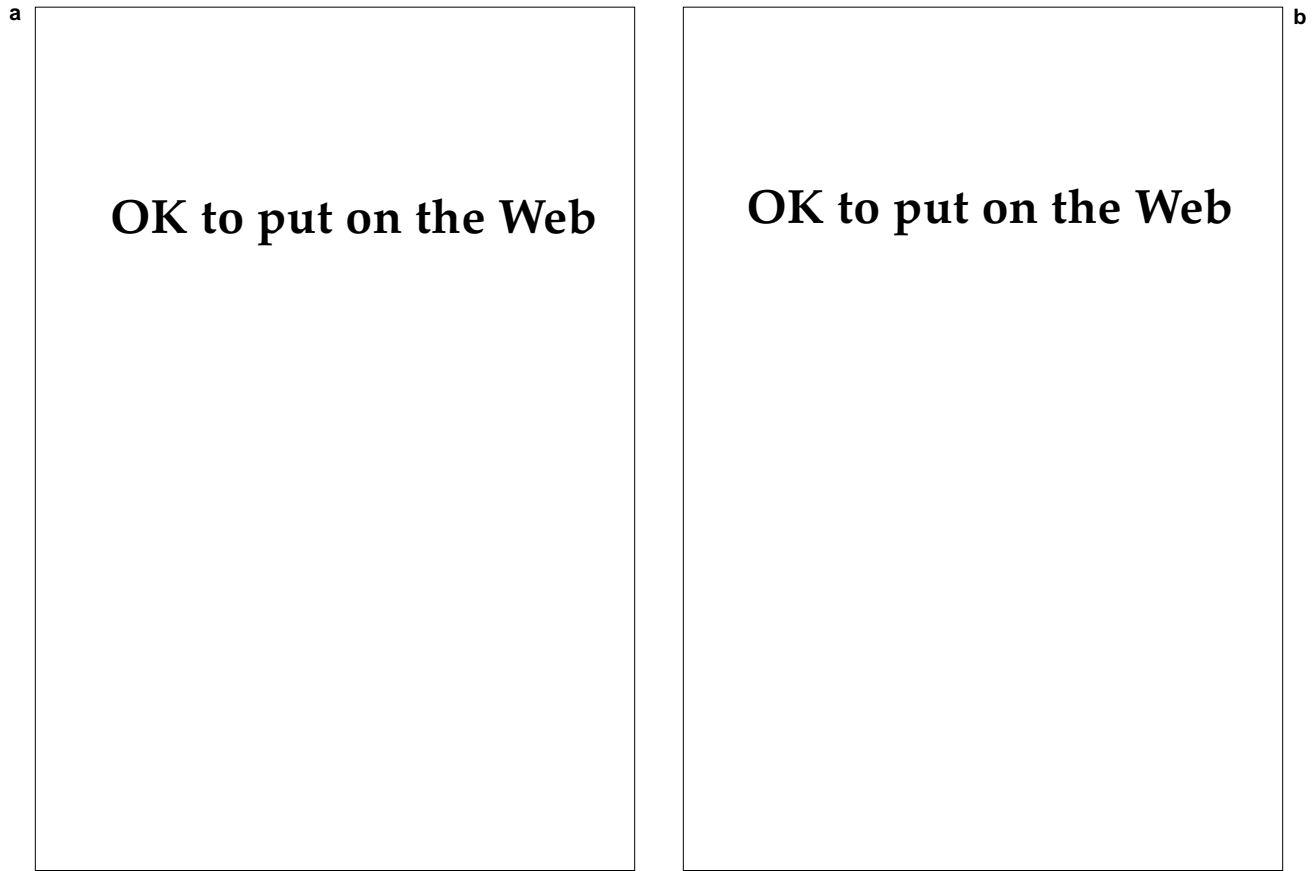
A more serious form of miliaria—*miliaria profunda*—was seen much less frequently than *miliaria rubra* during the Vietnam conflict. It typically develops from severe and prolonged *miliaria rubra*. Patients with *miliaria profunda* present with noninflamed nodules on the trunk and extremities; in most cases, these nodules are nonpruritic and not readily apparent on examination. The disease can be truly debilitating and is the cause of hypohidrosis syndrome (discussed below), also called tropical anhidrotic asthenia, a potentially fatal disorder.

### *Miliaria Pustulosa*

*Miliaria pustulosa* is always preceded by some other dermatitis that has produced injury, destruction, or blocking of the sweat ducts.<sup>5</sup> Examples of predisposing dermatoses include contact and atopic dermatitis and lichen simplex chronicus. The pustules are discrete, superficial, sterile, and are not associated with the hair follicle; lesions can thus be distinguished from a bacterial folliculitis (Figure 3-2). These pruritic lesions occur most frequently on the intertriginous areas, on the flexure surfaces of the extremities, and on the scrotum.

### *Pathogenesis and Treatment*

The pathogenesis and treatment of miliaria, and the anhidrosis that is its sequela, have been subjects of considerable investigation and debate.<sup>4,8-10</sup> One researcher found that miliaria could be reliably reproduced by applying occlusive plastic film to the skin.<sup>9</sup> After 48 to 72 hours of such occlusion, clinically and histologically typical miliaria was produced. When more than 30% of the total skin



**Fig. 3-2.** (a) These discrete, superficial pustules are typical of miliaria pustulosa. Unlike bacterial folliculitis, the lesions are sterile and are not associated with a hair follicle. (b) Miliaria pustulosa—magnified view of sterile, pustular lesions.

surface was wrapped and occluded, the ensuing widespread hypohidrosis produced an increased susceptibility to heat-retention disease.<sup>4</sup> This susceptibility persisted even when the skin appeared normal on casual inspection. Substantial hypohidrosis or even anhidrosis was a typical sequela of experimentally induced miliaria, just as it is in the naturally occurring disease. Experimental hypohidrosis lasted as long as 3 weeks in some volunteers, usually those most severely affected.<sup>10</sup> These volunteers, whose work performance was tested 1 and 2 weeks after suffering from miliaria, were found to have markedly impaired tolerance for working in the heat. After approximately 60% of the body was wrapped, the postmiliarial hypohidrosis caused incapacitating and potentially dangerous heat exhaustion, even in heat-acclimated volunteers who worked in a hot environment.<sup>10</sup>

The pathogenesis of both miliaria and its consequent hypohidrosis are associated with alterations in the orifices or ducts of the sweat glands. These

changes are related to the suppression of normal delivery of sweat to the skin's surface.<sup>4</sup> However, it remains unclear whether any of the observable anatomical alterations cause hypohidrosis or merely result from sweat retention. Inflammation is almost certainly a secondary event because it does not occur until 24 hours after sweat blockade has ensued. One group of researchers<sup>8</sup> found that they could relieve experimental anhidrosis with stratum corneum stripping, which implies a sweat blockage in or just below the horny layer.

Other researchers<sup>5</sup> studied the role of resident bacteria in the etiology of miliaria. They found that the degree of miliaria and hypohidrosis after experimentally induced disease was directly proportional to the increase in the density of resident aerobic bacteria, notably cocci. No anhidrosis resulted when antibacterial substances were used to prevent the proliferation of the microflora. The investigators postulated that cocci secrete a toxin that injures sweat-duct luminal cells and precipitates a cast within the lumen. Infiltration by inflam-

matory cells might create an impaction that completely obstructs the passage of sweat for several weeks. This hypothesis has never been established with certainty; the antecedent to the histological changes of sweat-duct leakage or rupture and the clinical picture of miliaria remain elusive.<sup>4</sup>

Miliaria crystallina requires no treatment. The other, deeper forms of miliaria are best treated by removing the soldier from the hot, humid environment.

### Hypohidrosis Syndrome

Hypohidrosis syndrome (also known as tropical anhidrotic asthenia) is a curious and unusual disorder that was first described in American and British troops during World War II.<sup>1</sup> Some of these soldiers were stationed in the desert in the southwestern United States at the time, and others were in southern Iraq. Cases that occurred in Louisiana and the Southwest Pacific were also described.

The syndrome, which can either appear suddenly or have a gradual onset, is characterized by

- absence of sweating over most or all of the cutaneous surface;
- ability to sweat in profuse amounts in a very limited area (usually the face);
- relatively mild symptoms of overheating, weakness, dizziness and headache;
- diuresis; and
- cutaneous changes ranging from prickly heat and transient papules to xerotic skin with a fine scale.<sup>1</sup>

Most patients had already been in a hot climate for some time and had had no previous difficulty sweating. Often the hottest season was drawing to a close when the symptoms emerged.<sup>1</sup>

Most patients suffering from hypohidrosis were not severely ill and did not suffer from hyperpyrexia. Many had been mildly uncomfortable for several days before seeking medical attention. Blood electrolyte studies and skin biopsies, when performed, were normal. Treatment consisted of rest in a relatively cool place, and subjective recovery was usually rapid. However, several weeks to as long as 4 months elapsed until sweating returned to normal. No satisfactory explanation for the cessation of sweating was ever found. Some speculated that a functional fatigue or exhaustion of the sweat mechanism was responsible.<sup>1</sup> Miliaria profunda may be the underlying mechanism in some cases of hypohidrosis.<sup>3</sup>

### Tropical Acne

Tropical acne is a severe, disabling condition that is peculiar to hot and humid environments. Although many of the victims have a history of mild acne during adolescence, the skin is often quiescent when the problem erupts. Most young people with a history of acne *do not* develop tropical acne, and there is no way to predict which individuals will develop the condition.<sup>11</sup> Tropical acne has an explosive onset that begins, on the average, 3 to 6 months after the patient is exposed to tropical climatic conditions. Patients are usually about 25 years old when affected, but susceptibility ranges from teenagers through 30-year-olds. Those who are deprived of proper bathing facilities and are subjected to extreme heat and poor hygienic conditions for great lengths of time are most susceptible. Garrison troops with access to adequate facilities are not affected nearly so severely.<sup>6</sup>

The lesions in tropical acne are typical of those found in conglobate acne: pustules, papules, nodules, and draining sinuses.<sup>11</sup> Each lesion tends to be highly inflamed and juicy, with a purulent or sanguinous discharge. In soldiers, the first manifestation is of cystic lesions on the back, making it impossible to carry a pack.<sup>6</sup> Confluence of lesions covering broad expanses of skin is often seen (Figure 3-3). The face tends to be spared, but elsewhere the lesions are more extensive even than those seen in conglobate acne. The neck, arms (even forearms), and entire torso are often involved. Characteristically, the buttocks and upper thighs are affected.



**OK to put on the Web**

**Fig. 3-3.** Tropical acne first manifests itself as cystic lesions on the back, making it impossible for a soldier to carry a pack. Therapy is futile unless the soldier is moved out of the hot, humid climate.



As is typical of other highly inflammatory diseases, the sedimentation rate is often elevated and a leukocytosis is present. The patient with tropical acne often feels ill and can no longer function successfully as a soldier. The bacterial organisms recovered from cultures usually show normal skin flora or occasional colonies of *Staphylococcus aureus* and Gram-negative rods. However, bacterial infection is not believed to play an important role, and antimicrobials are ineffective as a form of therapy.<sup>11</sup>

Tropical acne persists undiminished in intensity until the patient is moved to a cooler, dryer climate. The patient is usually treated for weeks or months before the medical officer makes the inevitable decision to evacuate the patient to a more favorable locale.<sup>6</sup> Once the patient is removed from the tropical environment, the condition promptly begins to clear. Before the advent of systemic retinoids, no treatment, including hospitalization, was effective. Few data are available concerning the efficacy of isotretinoin in treating tropical acne, but even this drug would not be practical. Under the best of conditions, the drug takes several months to reverse the changes of severe, inflammatory acne. Frequent monitoring of laboratory parameters would be required during this period, and success is by no means guaranteed. The simplest, most effective, and essential therapy for this devastating disease is removal of the patient from the tropics.

### Cholinergic Urticaria

Cholinergic urticaria is a fairly common disorder, and is seen most often in young adults.<sup>12</sup> The condition can be triggered by a variety of factors, including heat, exercise, and emotional stress. The patient first notes a sensation of warmth, which is then followed by an eruption of 1- to 3-mm wheals, which are surrounded by an erythematous flare (Figure 3-4). Usually the torso is affected, but in severe cases the rash is generalized. Wheezing and systemic symptoms (nausea, headache, and abdominal pain) are unusual but have been reported.<sup>13</sup> Angioedema has also been reported.<sup>14</sup>

Avoiding the predisposing factors is the most

## OK to put on the Web

**Fig. 3-4.** In cholinergic urticaria, multiple small (1- to 3-mm) wheals are surrounded by an erythematous flare. Lesions are induced by exercise and resolve completely in a few hours.

important aspect of treatment. This is understandably difficult in a hot environment, especially when coupled with the rigorous exercise and stressful training expected of a soldier. Regular exercise can induce tolerance, but could be dangerous in a patient who develops systemic symptoms.<sup>12</sup> H<sub>1</sub>-blocking antihistamines such as hydroxyzine (10–25 mg four times daily)<sup>15</sup> can be helpful. Aspirin should be avoided because it often will worsen the eruption.<sup>16</sup> These patients should never exercise alone when their disease is active.<sup>12</sup>

## DERMATOSES EXACERBATED BY HEAT AND HUMIDITY

Hot, humid conditions can worsen a variety of dermatoses, among which are dyshidrotic eczema, bacterial and fungal infections, friction blisters, and erythralgia. Frequently, wet clothing and boots are also contributing factors.

### Dyshidrotic Eczema

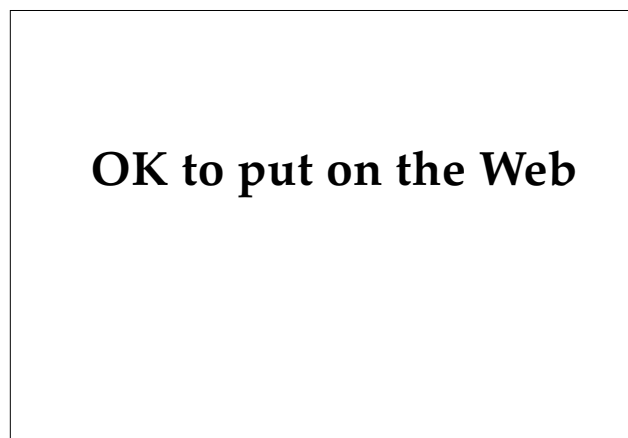Dyshidrotic eczema (also known as dyshidrosis or pompholyx) is a vesicular eruption of the palms and soles. Lesions are spongiotic intraepidermal

vesicles that often burn or itch. The characteristic vesicles are usually bilateral and roughly symmetrical in distribution. Sometimes the lesions are arranged in groups and can become confluent to form bullae (Figures 3-5 and 3-6). The vesicle fluid is at first clear and colorless but may eventually become straw colored or purulent. Hyperhidrosis is often present in affected individuals.

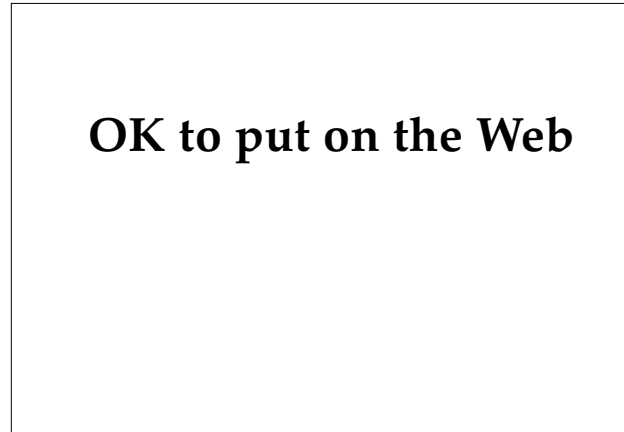
The exact etiology of dyshidrotic eczema is unknown. Some investigators believe that hyperhidrosis is not one of the causative factors but that emotional stress is a more important prerequisite.<sup>5</sup> However, combat troops in tropical environments are subjected to both considerable stress and profuse sweating; regardless of the exact etiology, they are prime candidates for the condition. The combination of extreme heat and nervous tension was believed to be largely responsible for the large number of cases seen in Vietnam.<sup>3</sup> Treatment is often difficult. Potent topical corticosteroids and cool soaks (eg, with Burow's solution or just cool tap water) may suffice for milder cases. Severe involvement can require oral or intramuscular corticosteroids. Extensive lesions on palms, soles, or both can be disabling and may require evacuation for the problem to remit.

### Bacterial Infections of the Skin

Heat and humidity predispose soldiers to a variety of bacterial infections. The combination of heat, humidity, wet clothing, poor hygiene, and minor



**Fig. 3-5.** Vesicles characteristic of dyshidrotic eczema are seen here on the palm. The lesions can be intensely pruritic.

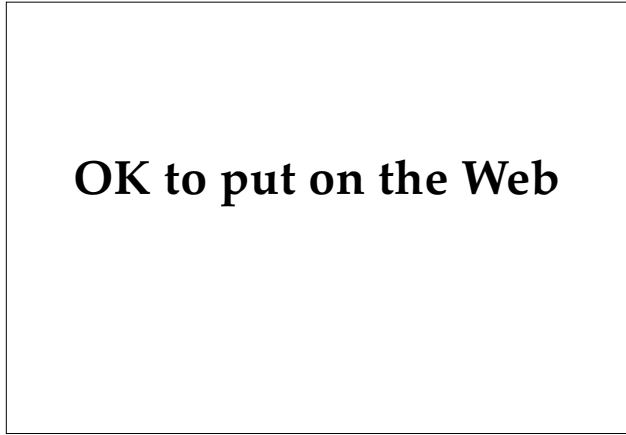

**Fig. 3-6.** Lesions on the sides of the fingers are common in dyshidrotic eczema. Other frequently affected sites include the palms and the soles.

skin trauma was believed to be the most important factor contributing to the high rates of cutaneous infections seen in Vietnam.<sup>3</sup> These infections were especially common in combat troops (as opposed to support personnel). Adverse climatic conditions, when coupled with the poor personal hygiene often found in combat troops, can lead to frequent and severe infections. Staphylococcal skin infections (superficial pustular impetigo, furunculosis, pyogenic paronychia, and staphylococcal impetigo), streptococcal infections (impetigo, ecthyma, erysipelas, and cellulitis), and a host of less common infections are found among soldiers in tropical climates. A detailed account of bacterial infections and their treatment may be found in Chapter 13, Bacterial Skin Diseases.

### Fungal Infections of the Skin

The various forms of tinea (ringworm) are more frequent and more severe among soldiers who are stationed in hot and humid environments. Superficial fungal infections were the most common and troublesome of all the dermatologic conditions that occurred among United States forces in Vietnam.<sup>3</sup> Just as in bacterial infections, the combination of heat, humidity, wet clothing and boots, and poor hygiene contributed significantly to the severity and frequency of fungal infections (Figure 3-7). A detailed discussion of these superficial fungal infections may be found in Chapter 17, Superficial Fungal Skin Diseases.



**Fig. 3-7.** Superinfected tinea pedis. Gram-negative organisms are often found in these mixed infections.

### Friction Blisters

Friction blisters are common in all climates but can be significantly more frequent and severe in hot, humid environments. For a detailed discussion of friction blisters, see Chapter 7, Cutaneous Trauma and Its Treatment.

### Erythralgia

Erythralgia is a condition in which the hands, legs, or feet develop intense erythema and pain resulting from environmental heat. A particularly warm climate is not necessary to precipitate attacks. Simply an increase in local skin temperature may be sufficient to precipitate a prolonged and painful attack. Symptoms usually involve the lower extremities and are almost always bilateral.<sup>17</sup> Men are more often affected than women. Patients try to relieve the discomfort by cooling their affected limbs using fans, cold water soaks, ice packs, and so forth.

Cases can either be primary (with no underlying disorder) or secondary, in which case an underlying condition such as polycythemia vera exists. Other associations seen with secondary erythralgia include venous insufficiency, diabetes mellitus, hypertension, systemic lupus erythematosus, and rheumatoid arthritis.<sup>12</sup> The pathogenesis is unknown and no treatment is universally effective. Aspirin (650 mg every 4 hours) is the most dependable therapy.<sup>12</sup> In cases of secondary erythralgia, treatment of the underlying or associated disorder may relieve this painful condition.

## DERMATOSES CAUSED BY EXCESSIVE SUN EXPOSURE OR ALLERGY TO SUNLIGHT

Several skin disorders can arise either directly from exposure to the sun's rays or from sunlight's interaction with drugs. With all of these conditions, preventive measures are critical.

### Sunburn

Sunburn is a cutaneous photosensitivity reaction that can occur in all humans, although its severity diminishes as melanin pigmentation increases.<sup>18</sup> It seldom occurs in black-skinned individuals. A single instance of severe sunburn can be disabling, and repeated episodes put the person at much greater risk for the development of nonmelanoma skin cancer (usually basal cell and squamous cell carcinomas). Additionally, there is evidence to suggest that several episodes of sunburn or even one severe sunburn substantially increases the risk of developing malignant melanoma.<sup>19</sup> For all these reasons, prevention of sunburn is important to improving not only fighting capability but also the long-term general health of the soldier.

UV-B radiation, with the shortest wavelengths of light (290–320 nm) to reach the earth's surface, is responsible for most if not all of the short-term effects of sunburn. The common name for UV-B radiation is therefore "sunburn rays." UV-A radiation (320–400 nm) and visible light (400–800 nm) have longer wavelengths, and are not associated with sunburn.

UV-B erythema (sunburn) becomes visible within 2 to 6 hours of sun exposure and peaks at 24 to 36 hours.<sup>18</sup> The erythema fades in 3 to 5 days, and in all but the fairest-skinned individuals, is followed by an increase in skin pigmentation (tanning). Severe sunburn is as injurious to the skin as a thermal burn, and severe cases can actually require hospitalization in a burn unit. Because UV-B radiation does not penetrate beneath the epidermis to any significant degree, the actual injury is primarily epidermal. This injury is manifested histologically by dyskeratotic "sunburn cells" and clinically by erythema, edema, and in more severe cases, blistering. Various mediators of inflammation are

activated by the sunburn phenomenon, and the dermis also becomes secondarily involved. These consequences are evident from the vasodilation, dermal edema, and leukocyte infiltration that occur in sunburned dermis. The exact mechanism by which UV radiation causes skin inflammation remains poorly understood.<sup>18</sup> For practical purposes, it is enough to remember that sunburn acts like a true burn, although third-degree injury (dermal necrosis) does not occur.

Once the erythema of a sunburn is well established, its treatment is similar to a thermal burn of equivalent severity. Severe sunburn with extensive blistering may require hospitalization and the kind of management that is utilized in a thermal burn unit. Oral or parenteral administration of high doses of corticosteroids can be of symptomatic benefit, but they must be tapered rapidly to reduce the chance of secondary infection.<sup>18</sup> Most sunburn cases are much milder and can be managed with cool-water soaks, topically applied corticosteroid creams, and

oral aspirin (650 mg every 4 hours, as needed) or indomethacin (25 mg three times a day, as needed). If an anticipated case of sunburn is treated early, before erythema has appeared or peaked, topical or oral indomethacin may delay the onset and diminish the intensity of UV-B erythema.<sup>20,21</sup> Although indomethacin might afford some symptomatic relief, there is no evidence to suggest that these drugs prevent the actual epidermal injury that accompanies sunburn. The delayed, post-24-hour erythema appears to be uninhibited by such treatment.<sup>21</sup>

Clearly the most helpful tactic is to avoid sunburn in the first place. The largest amounts of UV-B radiation penetrate the atmosphere at midday, when the sun casts no shadow. Avoiding outdoor work during the hours of 1000 to 1400 will reduce the chance of overexposure. Another rule of thumb is for soldiers to avoid outdoor work when their shadows are shorter than their height, which always corresponds to the time of day when UV-B radiation is most intense.

### EXHIBIT 3-1

#### PHOTOTOXIC AND PHOTOALLERGIC CHEMICALS

##### Phototoxic chemicals

Dyes  
Eosin  
Coal-tar derivatives  
Acridine  
Anthracene  
Furocoumarins  
Psoralen  
8-methoxypsoralen  
4,5,8-trimethylpsoralen  
Drugs  
Thiazides  
Chlorothiazides  
Doxycycline and other tetracycline-like derivatives  
Furosemide  
Nalidixic acid  
Naproxen  
Benoxaprofen  
Phenothiazines such as chlorpromazine  
Piroxicam  
Quinidine  
Amiodarone  
Sulfonamides

##### Photoallergic chemicals

Halogenated salicylanilides  
Tetrachlorosalicylanilide  
Antifungal drugs  
Multifungin  
Fentichlor  
Jadit  
Phenothiazines  
Chlorpromazine  
Promethazine  
Sulfanilamides  
Sunscreens  
PABA esters  
Digalloyltriolate  
Whiteners  
Stilbene  
Fragrances  
Musk ambrette  
6-methylcoumarin

##### Chemicals that are both phototoxic and photoallergic

Phenothiazines  
Sulfonamides

Source: Harber LC, Bickers DR, eds. *Photosensitivity Diseases: Principles of Diagnosis and Treatment*. Philadelphia, Pa: BC Decker, Inc; 1989.

Protective clothing should be worn whenever possible. A broad-brimmed hat is appropriate for any climate, and will reduce UV radiation exposure to the head and neck. Long-sleeved shirts and full-length trousers should be worn whenever possible. A significant amount of light can penetrate loosely woven or soaking-wet clothing, and a tightly woven, heavier fabric is always preferable. Gloves will protect the hands.

When protective clothing is impractical, such as in an extremely hot and humid climate, a chemical sunscreen should be applied. Numerous types are available, but for field conditions a sunscreen with a sun protection factor (SPF) of at least 15 should be used. It is especially important to treat the face, ears, neck, and hands, because it is often impossible to cover these areas with protective clothing (a hat is not protective from reflected light off sand, snow, water, and so forth). Most chemical sunscreens contain *p*-aminobenzoic acid (PABA) or its derivatives. Soldiers who are sensitive to PABA can use equally effective sunscreens based on salicylates, cinnamates, benzophenones, and dibenzoyl-methanes.

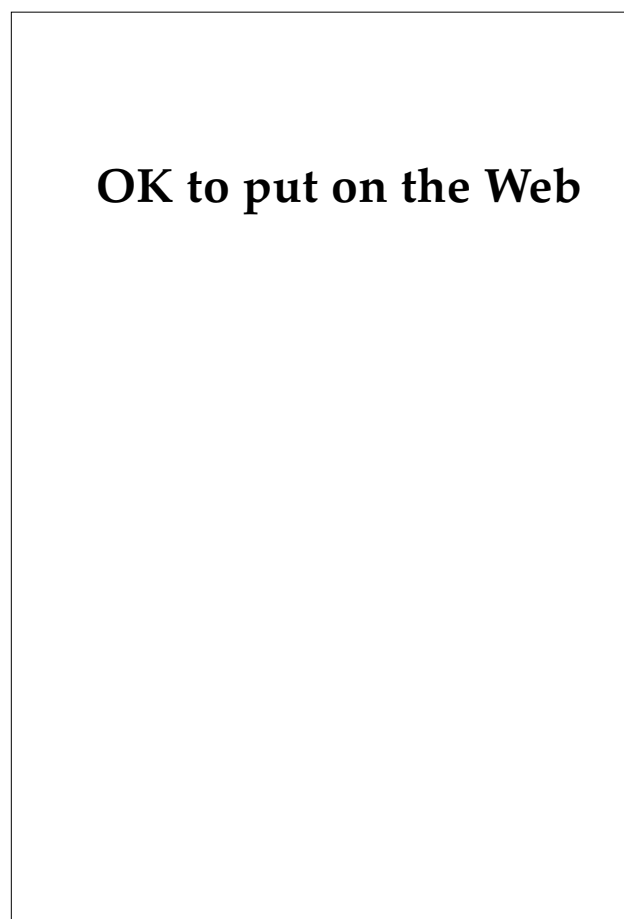
Individuals with deep tans or naturally dark skin have considerable protection from UV-B radiation but are still susceptible to UV radiation-induced photodamage.<sup>21</sup> However, tanning as a protective measure is both impractical and injurious. Some individuals can never achieve a truly protective tan; rapid deployment to sunny climates eliminates the possibility of achieving a tan without the morbidity of burning. Tanning itself is an indication that UV radiation-induced epidermal injury has occurred, which predisposes an individual to all the long-term adverse sequelae such as skin cancer and premature aging.

### Phototoxicity and Photoallergy

Both phototoxicity and photoallergy are due to the combined effects of drugs (or other chemicals) and sunlight. Neither drug nor light is alone sufficient to cause the reaction. In theory, phototoxic drugs are capable of causing an adverse reaction in *all* individuals if administered in high enough doses. Photoallergic drugs cause idiosyncratic responses (only certain predisposed patients will develop the allergy). Some photoallergic and phototoxic reactions occur when the responsible drug or chemical is taken internally and carried to the skin via the bloodstream. Other chemicals are capable of causing photocontact allergy (the reaction between

light and drug occurs when the offending chemical is applied to the surface of the skin and then irradiated) (Exhibit 3-1).

In general, phototoxic reactions are confined to areas of the skin exposed to light, such as the face, the pinnae of the ears, the "V" of the neck, the nuchal area, and the extensor and dorsal surfaces of the arms (Figure 3-8). Phototoxicity from many systemically administered drugs, such as the tetracycline derivatives, can appear as mild erythema resembling severe sunburn. However, the full spectrum of sunburnlike reactions may occur, including extensive blistering. Reactions to some agents such as the psoralens can cause eventual hyperpigmentation of the involved areas. Certain systemically administered phototoxic drugs such as demeclo-



**Fig. 3-8.** Phototoxic reactions such as this one caused by Tegretol (carbamazepine, manufactured by Basel Pharmaceuticals, Summit, N.J.) are generally confined to regions of the skin exposed to light. A photoallergic eruption might assume a similar appearance.

cycline can also cause photoonycholysis, in which separation of the nail from the nail bed occurs.

Photoallergy is much less common than phototoxicity.<sup>18</sup> It involves an immunological response of the skin to the combination of a specific chemical and light. The general mechanism of action is believed to be the conversion of the offending chemical by light into a photoproduct. The photoproduct then binds to a soluble or membrane-bound protein to form the antigen that precipitates a delayed-hypersensitivity immune response. Once the patient has been sensitized to the chemical, subsequent reexposures will elicit a cutaneous reaction.<sup>22</sup>

The most common groups of chemicals causing photoallergy are topically applied fragrances and antibiotics. Typically, the reactions caused by these agents resemble acute contact dermatitis such as that seen with poison ivy. The eruption is papulovesicular or vesicular and frankly eczematous. Light-exposed areas of the body are the sites of involvement, just as is the case with phototoxic reactions. Postinflammatory hyperpigmentation, however, is less often encountered in photoallergy.

Establishing the diagnosis of photoallergy or phototoxicity requires phototesting (and photopatch testing in cases of photoallergic contact dermatitis). The technique of phototesting, which may require specialized equipment, is beyond the scope of this chapter. Treatment involves avoiding the contributing factors—certain wavelengths of light and the responsible chemical. In theory, avoiding the chemical or drug alone should be sufficient. However, certain drugs such as hematoporphyrin bind avidly to dermal proteins and are only slowly eliminated from the skin, which can take months. Phototoxicity from this drug can therefore be prolonged.

### Polymorphous Light Eruption

Polymorphous light eruption (PMLE), a condition of unknown etiology, is one of the most common disorders of photosensitivity.<sup>18</sup> Several other names have been applied to the condition, some of which are either synonymous with or variants of PMLE. These names include solar eczema, summer prurigo, solar dermatitis, and perhaps hydroa aestivale. A photosensitivity disease called actinic prurigo is often included as a clinical subset of PMLE, although some authorities consider it to be a separate condition.<sup>23</sup> The entire group of conditions designated as PMLE may represent a clinical spectrum of severity for a single disease or, alternatively, may actually represent a diverse group of

photosensitivity disorders with different pathogeneses. For purposes of this chapter, the entire group will be referred to as PMLE.

PMLE occurs in all ethnic groups, but Native Americans appear to be genetically predisposed to the subset called actinic prurigo. All age groups can be affected, and there does not seem to be a clear-cut difference in incidence between males and females.

The lesions of PMLE can assume a variety of appearances (hence the name polymorphous) including erythema, eczema, vesicles, papules, nodules, plaques, and areas that are excoriated, lichenified, or both (Figures 3-9 and 3-10). The lesions are most common on the face, but relatively sun-protected areas such as the submental region are spared. The eruption is usually confined to sun-exposed areas, but because the lesions of PMLE are usually patchy and irregular, a sharp border is seldom as evident as that seen in phototoxic or photoallergic reactions.

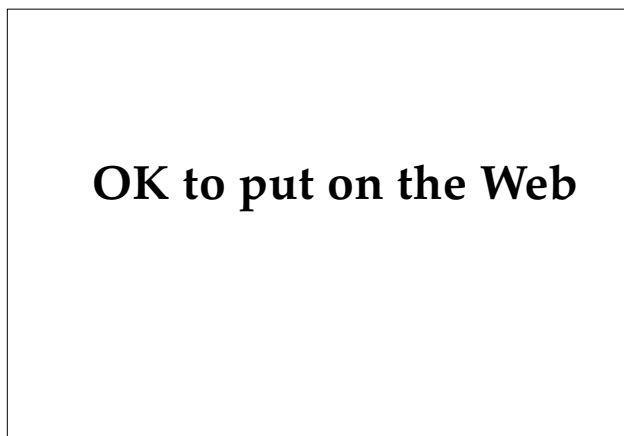
Typically, PMLE begins or recurs in the spring as the amount of UV light and opportunities for exposure increase. Lesions usually erupt several hours after sun exposure has occurred. They begin as papules or plaques in light-exposed areas, and are moderately to severely pruritic. The pruritus is often described as “stinging.”<sup>18</sup> Subsequent exposures to sunlight will cause new lesions, again after a lag of several hours. However, as spring and summer progress, many patients experience a lessening of disease severity, as if “hardening” is occurring. Lesions persist for several days. With repeated outbreaks at close intervals, large eczematous or lichenified plaques may form.

The histopathological findings are often helpful



**OK to put on the Web**

Fig. 3-9. Polymorphous light eruption: papular lesions.



**Fig. 3-10.** Polymorphous light eruption: diffuse erythema and swelling.

in making a diagnosis. Characteristically, dense aggregates of mononuclear cells are seen in a perivascular distribution in the mid- and upper dermis. Epidermal changes are nonspecific and include edema, spongiosis, parakeratosis, acanthosis, and mild vacuolar degeneration of the basal cell layer.<sup>18</sup>

PMLE can be caused by UV-B or UV-A radiation, visible light, or a combination of these. Different patients seem sensitive to different wavelengths of light. This phenomenon may be a true difference in reactivity between individuals, or may simply indicate that the term PMLE represents a variety of diseases with differing etiologies. Phototesting may pinpoint the offending wavelengths of light, but such an evaluation is relatively complex and is often unrewarding.

The best treatments for PMLE are avoiding sunlight and wearing protective clothing. However, avoidance is often impractical, especially in soldiers whose duties require outdoor work. Sunscreens are usually somewhat helpful, although they seldom achieve complete control. Because many cases of PMLE are caused by UV-B radiation, sunscreens containing PABA or other UV-B blockers can be useful. Sunscreens that are protective in the UV-A range (eg, Photoplex, consisting of avobenzone and padimate O, manufactured by Allergan Herbert, Irvine, Calif.) are less effective because they screen relatively little UV-A radiation (compared to the excellent blockade achieved by many UV-B sunscreens). Opaque sunscreens such as titanium dioxide are effective against all damaging wavelengths but are also messy and cosmetically unacceptable.

Antimalarial drugs taken systemically are the mainstay of therapy for incapacitating disease that is not adequately controlled by the above methods. Plaquenil (Hydroxychloroquine, manufactured by Sanofi Winthrop Pharmaceuticals, New York, N.Y.) is used most often, and can be effective in low doses (250–500 mg daily). It may only be required during the spring and early summer, when disease activity is at its peak. The major drawback to the antimalarial drugs is the retinal toxicity that they can cause. Patients need to be monitored every 3 months to assure that irreversible ocular changes are not in progress. These drugs also may produce some less serious side effects such as headaches, gastrointestinal upset, blurred vision, and pruritus. Clearly the antimalarial drugs are far from ideal as a treatment for a relatively benign, although potentially incapacitating, disease.

For severe flare-ups of PMLE, systemic corticosteroids are effective. Serious long-term side effects make this class of drugs undesirable for chronic therapy.

### Solar Urticaria

Solar urticaria manifests itself by the onset of erythema and pruritus a few minutes after sun exposure; these areas then become edematous or frankly urticarial. The eruption is limited to sun-exposed skin, and in the absence of reexposure, the lesions disappear after several hours. This stage is followed by a period of 12 to 24 hours in which the skin is refractory to new lesions, even if sun exposure occurs. Like typical urticaria, an extensive outbreak can be associated with an anaphylaxis-like reaction.<sup>18</sup>

Solar urticaria can occur at any age, but most reported cases have been in the 30- to 40-year-old age group. Women are more often affected than men. The condition may spontaneously remit within a few months (which occurs in about one fourth of patients), but usually persists for years.

All wavelengths of sunlight have been implicated in causing one or more of the various subsets of solar urticaria. Eruptions caused by visible light seem to have the best prognosis.<sup>18</sup> Phototesting may reveal the culprit wavelengths, which is of obvious practical value in preventing outbreaks. However, because such testing requires special equipment that is usually only available in medical centers, it has little use in field medicine.

No specific therapy exists for solar urticaria. Avoiding sun exposure is the most successful pre-

ventive measure, but this is usually impractical. Antihistamines are often not effective until sedating doses are used. Antimalarials have been found useful in a few cases. Desensitization has proven effective in several cases.<sup>18</sup> This method involves frequent exposure of a small area of the skin to the

offending wavelengths of light until no reaction occurs. Then the size of the treated area is gradually increased until the entire body can be exposed without a reaction. Daily or every-other-day exposures of 10 to 20 minutes often keep the patient lesion-free despite normal sunlight exposure.

## DERMATOSES EXACERBATED BY SUNLIGHT

Several skin diseases can be markedly worsened by exposure to sunlight, making it extremely difficult for the soldier to function effectively. Fortunately, most of these disorders are uncommon.

### **Porphyria Cutanea Tarda**

Porphyria cutanea tarda (PCT) actually is an example of phototoxicity, but in affected patients the phototoxic drugs are endogenous porphyrins. PCT patients present with blisters and erosions in sun-exposed areas. The disease is caused by a metabolic defect in the production or metabolism of porphyrins. Visible light in the 400 to 410 nm range is the part of the spectrum most responsible for the reaction. Therapy consists of phlebotomy (to reduce hepatic iron stores), antimalarial drugs, or both.

### **Erythropoietic Protoporphyrin**

Patients with erythropoietic protoporphyria, a much less common defect in porphyrin metabolism, present acutely with areas of sun-exposed

skin that become painful shortly after sun exposure. Erythema and edema then develops in those sites where stinging pain has occurred. Pain is usually more prominent than the visible skin lesions, but small, pitted scars can develop over time. Oral beta carotene has been found to be useful in reducing the severity of the disease. Erythropoietic protoporphyria is an autosomal dominant inherited condition that usually manifests itself in childhood, and is therefore very unlikely to be encountered in active-duty military personnel.

### **Others**

The skin lesions of both discoid lupus erythematosus and systemic lupus erythematosus can be induced or significantly worsened by sunlight. Recurrent herpes simplex viral outbreaks can be precipitated by sun exposure.

The rash of pellagra is clearly a photosensitive disorder. Except in maltreated prisoners of war and soldiers who are taking the drug isoniazid, this deficiency of tryptophan and niacin is very unlikely to occur.

## SUMMARY

Soldiers entering hot or sunny climates are at risk for heat-related skin injury or disease, which can often be debilitating. Even the classic forms of heat injury such as heatstroke are influenced by the skin because sweating is so important for temperature homeostasis.

Excessive environmental heat is directly responsible for miliaria, the best known form of which is prickly heat. Tropical acne, cholinergic urticaria, and the hypohidrosis syndrome can also be problems in hot climates.

Some skin conditions may be exacerbated by heat and humidity, turning a mild dermatosis into a disabling disease. Bacterial and fungal infections of the skin are always problems in hot and humid

settings, and friction blisters and dyshidrotic eczema are far more commonly seen in those conditions.

The intense UV light found in sunny climates is responsible for sunburn, which can be just as incapacitating as a thermal burn. A higher incidence of phototoxic and photoallergic reactions to drugs is expected with increased sun exposure. Allergy to certain wavelengths of sunlight (polymorphous light eruption) can be especially problematic.

Certain skin conditions such as the porphyrias and cutaneous lupus erythematosus can be significantly worsened by exposure to sunlight. It is unlikely that a soldier with either condition could function effectively in a sunny environment.



REFERENCES

1. Eichna LM. Heat casualty. In: *Infectious Diseases and General Medicine*. Vol 3. In: Havens WP, Anderson RS, eds. *Internal Medicine in World War II*. Washington, DC: Medical Department, US Army, Office of The Surgeon General; 1968: 195–330.
2. US Departments of the Army, Navy, and Air Force. *Prevention, Treatment and Control of Heat Injury*. Washington, DC: 1980. Technical Bulletin MED 507.
3. Allen AM. *Skin Diseases in Vietnam, 1965–72*. In: Ognibene AJ, ed. *Internal Medicine in Vietnam*. Vol 1. Washington, DC: Medical Department, US Army, Office of The Surgeon General, and Center of Military History; 1977: 29–52.
4. Sulzberger MB, Harris DR. Miliaria and anhidrosis. *Arch Dermatol*. 1972;105:845–850.
5. Arnold HL, Odom RB, James WD. *Andrews' Diseases of the Skin*. Philadelphia: WB Saunders Co; 1990: 4.
6. Pillsbury DM, Livingood CS. Dermatology. In: *Infectious Diseases and General Medicine*. Vol 3. In: Havens WP, Anderson RS, eds. *Internal Medicine in World War II*. Washington, DC: Medical Department, US Army, Office of The Surgeon General; 1968: 543–674.
7. Sulzberger MB, Emik LO. Miliaria: Clinical and statistical findings. *J Invest Dermatol*. 1946;7:53–59.
8. Papa CM, Kligman AM. Mechanisms of eccrine anhidrosis. Part 1: High level blockade. *J Invest Dermatol*. 1966;47:1–9.
9. Stoughton, RB. Suppression of miliaria rubra (prickly heat) by a topical anticholinergic agent. *J Invest Dermatol*. 1964;42:228.
10. Sulzberger MB, Griffin TB. Induced miliaria, post-miliarial hypohidrosis and some potential sequelae. *Arch Dermatol*. 1969;99:145–151.
11. Plewig G, Kligman AM. *Acne: Morphogenesis and Treatment*. New York: Springer-Verlag; 1975; 194–196.
12. Page EH, Shear NH. Temperature-dependent skin disorders. *J Amer Acad Dermatol*. 1988;18:1003–1019.
13. Kounis NG, MacMahon RG. Cholinergic urticaria with systemic manifestations. *Ann Allergy*. 1975;35:243–245.
14. Lawrence CM, Jorizzo JL, Kobza-Black A, Coutts A, Greaves MW. Cholinergic urticaria with associated angioedema. *Br J Dermatol*. 1981;105:543–550.
15. Lookingbill DP, Marks JG Jr. *Principles of Dermatology*. Philadelphia: WB Saunders Co; 1986: 198.
16. Douglas HMG. Reactions to aspirin and food additives in patients with chronic urticaria, including the physical urticaria. *Br J Dermatol*. 1975;93:135–144.
17. Babb RR, Alarcon-Segovia D, Fairbairn JF II. Erythralgia, review of 51 cases. *Circulation*. 1964;29:136–141.
18. Harber LC and Bickers DR, eds. *Photosensitivity Diseases: Principles of Diagnosis and Treatment*. Philadelphia: BC Decker, Inc; 1989.
19. Lew RA, Sober AJ, Cook N, Marvell R, Fitzpatrick TB. Sun exposure habits in patients with cutaneous melanoma. *J Dermatol Surg Oncol*. 1983;9:981.
20. Eaglstein WH, Marsico AR. Dichotomy in response to indomethacin in UV-C and UV-B induced ultraviolet light inflammation. *J Invest Dermatol*. 1975;65:238–240.

21. Consensus Development Panel. National Institutes of Health Summary of the Consensus Development Conference on sunlight, ultraviolet radiation, and the skin. *J Am Acad Dermatol.* 1991;24:608–612.
22. Epstein JH. Phototoxicity and photoallergy in man. *J Am Acad Dermatol.* 1983;8:141–147.
23. Lane PR, Sheridan DP, Hogan DJ, Moreland A. HLA typing in polymorphous light eruption. *J Amer Acad Dermatol.* 1991;24:570–573.

# Chapter 4

## IMMERSION FOOT SYNDROMES

JOHN ADNOT, M.D.\* AND CHARLES W. LEWIS, M.D.†

---

### INTRODUCTION

### OVERVIEW

### INJURIES IN COOL OR COLD CLIMATES

Trench Foot  
Immersion Foot  
Management

### INJURIES IN WARMER CLIMATES

Tropical Immersion Foot  
Warm Water Immersion Foot

### SUMMARY

\*Private Practice of Dermatology, Overton Park Building, 4200 S. Hulen Drive, Fort Worth, Texas 76109; formerly, Dermatology Service, Fitzsimons Army Medical Center, Aurora, Colorado 80045

†Private Practice of Dermatology, Dermatology Clinic, Regenstrief Health Center, 1050 Walnut Street, RG524, Indianapolis, Indiana 46202; formerly, Chief, Dermatology Service, Brooke Army Medical Center, Fort Sam Houston, Texas 78234

## INTRODUCTION

Since the founding of this country, American soldiers have been fighting wars wearing a wide variety of shoes and boots to protect their feet from the environment. Soldiers of the Continental Army, 1775 to 1781, wore simple low-cut leather shoes with the rough side out and cloth leggings laced over the lower leg.<sup>1</sup> Joseph Lovell, a surgeon general in the 1800s, noted the importance of enabling soldiers to keep their feet warm and dry with wool socks and laced shoes reaching at least to the ankle. He also observed that letting the feet remain wet and cold for any length of time led to constitutional illnesses.<sup>2</sup>

In 1861, Union and Confederate soldiers wore any type of personally owned boot or shoe, but most used a simple, laced, ankle-high brogan. During the Civil War, Union troops were issued the first mass-produced shoes that distinguished between the left and right foot. Up to this time, most shoes were made to be worn on either foot. Many Confederate troops were barefoot or used canvas and wood to fashion crude walking shoes. Officers and mounted troops typically wore leather boots.<sup>2</sup>

Ankle-high, heavy leather shoes continued to be manufactured and were issued to soldiers during World War I. Wool wraps called puttees were wound around the lower leg from the knee to the ankle to protect the leg. It was not until the spring of 1918, however, that the Pershing boot, a heavier shoe with more waterproof construction, was developed.<sup>3</sup> It was effectively designed for the demands of trench warfare. After the war, modifications on footwear reflected garrison life and the need for economy.<sup>3</sup>

Ankle-high shoes and canvas leggings were initially worn in World War II. Because of material shortages and lack of preparedness for the footwear needs of wartime, despite the experience available from World War I, it was not until the end of 1943 that the first combat boot appeared.<sup>3</sup> It was a brown laced boot with a leather flap on the upper. Because leather is a permeable material, all leather boots leak to some extent. It was not until 1944 that the M-1944 Shoepac, with a moccasin-type rubber boot, was approved for distribution. It was the best available modification for the cold, wet conditions of trench warfare in Europe.<sup>3</sup> The first jungle boots made of canvas and rubber were used in the

South Pacific.<sup>3</sup> A modified jungle boot, the tropical combat boot, was designed and tested during the latter part of World War II. It consisted of spun nylon, a leather midsole, and a full-length rubber outer sole. Production was not started until the summer of 1945.<sup>3</sup>

During the Korean conflict, a special brown leather jump boot that laced all the way up the front was issued to paratroopers and became popular throughout the army. Except for switching to a black color, these boots remained mostly unchanged through the Korean and Vietnam conflicts. In the mid-1960s a black leather and olive drab nylon-webbing jungle boot with a cleated sole became the favorite footwear of the American soldier.<sup>4</sup>

The type of footwear worn by the soldier in combat, along with environmental conditions and preventive hygiene measures, has played a crucial role in producing a variety of cutaneous disorders of the feet. These "disease, nonbattle injuries" range from minor inconveniences to very significant conditions that may result in hospitalization.

Based on methods of clinical diagnosis and laboratory confirmation of soldiers evacuated from war zones with inflammatory conditions of the feet, the following list was presented by Pillsbury and Livingood:

At Fitzsimons General Hospital, after classification and appropriate studies, patients referred with this diagnosis were divided into the following categories and proportions:

1. The hyperhidrosis (dyshidrosis) syndrome, 51 percent.
2. Pyoderma secondary to trauma, maceration, or hyperhidrosis (dyshidrosis) syndrome, 14 percent.
3. Dermatophytosis, 20 percent.
4. Dermatitis venenata produced by medication (which had usually been prescribed for the treatment of the presumed fungal infections), 11 percent.
5. Other dermatitis venenata, 2 percent.
6. Resistant pustular eruptions (the so-called bacterid of Andrews), 1 percent.
7. Pustular psoriasis, 0.5 percent.
8. Acrodermatitis continua of Hallopeau, 0.5 percent.<sup>5(p593)</sup>

Controlled studies demonstrating effective methods for preventing foot diseases in military popula-

tions are rare. However, two studies are well documented:

A convincing controlled study along these lines was conducted by Maj. (later Lt. Col.) Laurence Irving, Chief, Physiology Section, Headquarters, Eglin Field, Fla. Sandals were issued to approximately 1,000 men, who were permitted to wear them on the post as much as they wished; most of them practically gave up wearing shoes. A similar number of men wore shoes as usual. Within a month, the proportion of severe dermatophytoses in men wearing sandals fell from 30 to 3 percent, while in the control group, the disease remained as troublesome as usual.

A similar study was conducted in New Guinea, while the 43d Infantry Division was in a rest area. Some 300 men with unclassified skin diseases, many of whom undoubtedly had dermatophytosis of the feet, were kept on the beach for 4 hours daily, without clothing or shoes. They bathed, exercised, or just lay in the sun as they wished. Within a month, the majority of infections had cleared without any other treatment.<sup>5(pp602-603)</sup>

During the conflict in Vietnam, one of the au-

thors (CWL) convinced the Commander of the Second Brigade, First Infantry Division, to direct the purchase of 5,000 pairs of rubber shower thongs for use after combat operations in the rice paddies. By allowing soldiers to use these open rubber thongs upon return to base camp, and limiting the continuous wet exposure to not more than 72 hours, the rate of tropical immersion foot problems was generally kept to a level of 10% or less. Prior to institution of these policies, a combat unit could experience 70% to 75% loss of personnel due entirely to inflammatory skin diseases of feet that had been continuously wet more than 72 hours (Exhibits 4-1 through 4-3).

While it is often impossible to determine the exact role of diseases limited to the feet in overall effectiveness of a combat unit, rates of sick call and hospitalization always increased during periods of combat operations in the rainy seasons and decreased in dry seasons.<sup>4</sup> However, the fact that many combat units lost hundreds to thousands of man-days due to large numbers of individuals placed either on quarters or on light, noncombat status because of their skin diseases, was rarely included in statistical reports.

## OVERVIEW

Injuries to the feet from prolonged immersion in water or contact with dampness, in a range of environmental temperatures, may be collectively referred to as "immersion foot syndromes." These syndromes have been referred to as trench foot, swamp foot, tropical jungle foot, paddy-field foot, jungle rot, sea boot foot, bridge foot, and foxhole foot. Although most common during wartime, they also appear with occupational and recreational activities.

Injuries related to simultaneous exposure to cold

temperatures and a wet environment are subdivided into trench foot and immersion foot. Those involving warmer temperatures include tropical immersion foot and warm water immersion foot.

This review describes each condition to alleviate confusion over nomenclature and to aid in recognition and treatment (Table 4-1). To keep the focus narrow, the extremes of the temperature injury spectrum (ie, true frostbite and burns) are not specifically addressed, but referred to as necessary for clarification.

## INJURIES IN COOL OR COLD CLIMATES

All four of the immersion foot syndromes discussed in the next two sections are characterized by pain that is continuous over several days to weeks. They may incapacitate large numbers of troops in a unit simultaneously because of common exposure to the harsh environment. Commanders may prevent these injuries by being aware of the hazards and preventing long-term exposure to the predisposing conditions. In this section the two syndromes resulting from cold, wet conditions will be discussed.

### Trench Foot

"Trench foot" refers to injury resulting from prolonged exposure to wet conditions, *without* immersion, in cold weather. The term probably originated in World War I, when many men were confined to trenches in cold, damp weather for prolonged periods. The condition was recognized as a cause of considerable loss of manpower as far back as the Greek Campaigns<sup>6</sup> and the Napoleonic and Crimean

**EXHIBIT 4-1**

**ARMY REGULATION 40-29: PREVENTION OF SKIN DISEASE AMONG TROOPS OPERATING IN INUNDATED AREAS**

HEADQUARTERS  
UNITED STATES ARMY VIETNAM  
APO SAN FRANCISCO 96375

REGULATION NUMBER 40-29

10 January 1968

MEDICAL SERVICE  
Prevention of Skin Disease Among Troops  
Operating in Inundated Areas

1. **PURPOSE:** To outline policy and procedures for the prevention of disabling skin conditions, which may occur when troops are required to conduct field operations in flooded rice paddies and other inundated areas.
2. **SCOPE:** This regulation is applicable to all units assigned or attached to this command.
3. **GENERAL:** Fungus infection of the foot is probably the most common skin disease causing disability among troops in RVN. The common athlete's foot with involvement of the toe webs and soles of the feet does not occur frequently in Vietnam; or if it does, it is relatively mild. The most severely affected areas have been the top of the feet and legs under the boots, the groin, and the buttocks. The lesions often spread to produce bright red rings which may run together. Although not so common, immersion foot is also a potential hazard.
4. **RESPONSIBILITIES:** Commanders are responsible for implementing measures outlined below when, in their opinion and upon the advice of their surgeon, they are considered necessary and practical.
5. **PREVENTIVE MEASURES:**
  - a. Limiting the duration of operations in watery terrain. The tactical situation permitting, a 48 hour limit (2 days and 2 nights) should be placed on operations involving continuous exposure to water. If this is not possible, casualties from fungus infection may be disabled for 2 or more days after a five-day operation.
  - b. Proper care of the feet.
    - (1) One of the most important measures is to insist that troops wear boots and socks only when necessary while in base camps. Shower clogs or thongs are recommended as substitutes.
    - (2) During operations, commanders should have a few men at a time remove their footgear and allow their feet to dry as the tactical situation permits.
    - (3) Dry socks should be included in resupply missions in the field whenever possible. Mesh socks are preferred.
  - c. Exposure of the skin to the sun.
    - (1) Where possible, exposure of as much of the body as possible to the sun for 30 minutes every day is recommended. To avoid sunburn, new arrivals should be gradually exposed for short periods of time until a protective tan develops.
    - (2) In base camps, during daylight hours when mosquitoes are not a problem, troops should be allowed to wear abbreviated clothing such as shorts. This should be limited to those troops whose operations mission predisposes them to skin disease.
  - d. Cleansing of the skin.
    - (1) As soon as troops return from an operation, they should remove dirty clothing and shower immediately. It appears that showering in potable water will reduce the incidence of skin diseases. However, showers using nonpotable water are preferable to no showers.
    - (2) The use of antibacterial (germicidal) soaps should be encouraged. Any of the nationally advertised brands are acceptable.
  - e. Laundering field clothing. Field clothing should be washed in potable water. Quartermaster or modern contract laundries are preferred. Starching of field clothing reduces ventilation, and is not recommended for troops in active combat operations or other strenuous physical activities.
  - f. Underclothing. Troops should be discouraged, but not prohibited, from wearing underclothes while on operations in the field. Underclothes reduce ventilation of the skin.

(AVHSU-PM)

FOR THE COMMANDER:

ROBERT C. TABER  
Brigadier General, US Army  
Chief of Staff

WILLIAM H. JAMES  
Colonel, AGC  
Adjutant General

This Regulation supersedes USARV Reg 40-20, 25 Jan 66

**EXHIBIT 4-2**

**MEMORANDUM ON PREVENTION OF SKIN DISEASE IN NINTH INFANTRY DIVISION**

DEPARTMENT OF THE ARMY  
HEADQUARTERS 9th INFANTRY DIVISION  
APO SAN FRANCISCO 96370

AVDE-MD

28 October 1968

SUBJECT: Prevention of Skin Disease SEE DISTRIBUTION

1. The maintenance of the health of a unit is a command responsibility. Tropical skin diseases are the most common cause of non-effectiveness within the 9th Infantry Division Area. Commanders have adequate medical personnel, effective medications and proven techniques to reduce this very serious problem
2. Diseases of the foot and boot area developed rapidly after 48 hours of continuous exposure to the rice paddies and swamps, and may affect 35% to 50% of the combat strength of an infantry unit after 72 hours. With each succeeding exposure, skin infections are more severe and require over three weeks of intensive treatments.
3. Consequently, commanders will limit operations to 48 hours in the paddy followed by a minimum of 24 hours utilization in a dry area. This limitation will be exceeded only in situations which override the inevitable loss of combat strength from skin disease.
4. Additionally, to reduce the non-effectiveness rate caused by skin disease, commanders will conduct foot inspections and require their men to put on dry socks daily. Men should remove their boots and socks whenever possible (up to four hours daily), to let their feet dry out. After an operation all personnel will be examined by medical personnel.

JULIAN J. EWELL  
Major General, USA  
Commanding

DISTRIBUTION:

A

**EXHIBIT 4-3**

**MEMORANDUM ON PROPER FOOT CARE FOR SOLDIERS AT FORT GORDON, GEORGIA**

DEPARTMENT OF THE ARMY  
HEADQUARTERS U.S. ARMY SIGNAL CENTER AND FORT GORDON  
FORT GORDON, GEORGIA 30805-5000

AZTH-CG

20 November 1990

MEMORANDUM FOR Commander, U.S. Army Training and Doctrine Command  
ATTN: ATCD-SE (COL Charles Ball), Fort Monroe, Virginia 23651-5000  
SUBJECT: Proper Foot Care for Soldiers at Fort Gordon

1. Every summer an unnecessarily large number of soldiers at Fort Gordon require treatment in the Dermatology Clinic for severe eczema of the feet, usually with secondary infection which results from excessive heat and humidity. It is aggravated by the wearing of wool winter socks and combat boots during periods of high heat and humidity. Soldiers suffering from this problem lose many hours of training and are restricted from physical training until the skin of the feet can heal. After a severe episode of foot eczema, the skin is easily broken down for many weeks following recovery and relapses are common.
2. Standard treatments for this condition include topical and internal medications. An integral part of treatment, however, is evaporation of perspiration through the wearing of adequately ventilated foot wear and cotton or cotton blend socks.
3. Therefore, recommend that OD cotton socks be added as an additional issue item primarily to those soldiers participating in basic and advanced individual training in the summer months where excessive heat and humid climate exists. With the addition of cotton socks, daily rotation of boots and normal foot care during the summer months, many cases of foot eczema can be prevented and excessive lost training time and physical training restrictions can be minimized.
4. Point of contact at Fort Gordon is Ms. Ree Hill, Chief, Supply Brand, Installation Supply and Services Division, Directorate of Installation Support, AUTOVON 780-5186/4507.

PETER A. KIND  
Major General, USA  
Commanding

JAMES E. HASTINGS  
Brigadier General, MC  
Director, Health Services

**TABLE 4-1**  
**COMPARISON OF IMMERSION FOOT SYNDROMES**

Syndrome	Site	Symptoms	Signs	Systemic Involvement	Healing Time	Pathological Changes
Trench foot	Foot	Prehyperemic: Early: numbness, pain, paresthesia Late: anesthesia, "walking on blocks of wood" Hyperemic: tingling, progressing to throbbing, burning pain, and hyperesthesia; distal anesthesia may persist Posthyperemic: deep ache joint pain, prolonged anesthetic changes	Prehyperemic: pale, swollen, vesiculobullous lesions, distal cyanosis Hyperemic: increased edema, warm, dry, erythematous, bounding pulses, vesicles, bullae, ecchymosis Posthyperemic: Early: cool, moist, patchily or entirely cyanotic, normal to decreased pulses Late: skin and muscular atrophy, osteoporosis, deformity	None	Visible changes in 4 wk-6 mo; neurological and structural changes in months (may be permanent)	Prehyperemic: thrombosis, edema, vasoconstriction Hyperemic: thrombosis, capillary rupture, hemorrhage, vasodilation, edema, subepidermal vesiculation Posthyperemic: fibrin deposition in vessels and muscles, edema of nerve axons, variable lymphatic damage
Immersion foot	Usually foot, occasionally knee, thigh, or buttocks	Same as trench foot	Same as trench foot	None	Same as trench foot	Same as trench foot
Tropical immersion foot	Dorsum of foot, ankles	Early: burning pain (aggravated by pressure from footwear, walking, or both) and itching  Late: paresthesia, hyperesthesia, anesthesia	Early: erythema, edema, macu- lopapular rash, vesicles or bullae, and tenderness, delineated by top of boot  Recovery: decreased fever, adenopathy, tenderness, and pain by 72 h; erythema and edema subside in 5-7 d followed by fine branny desquamation of all affected areas	Fever (38°C-39°C), femoral adenopathy	3-7 d	Parakeratosis, acanthosis, lymphocytic perivascular infiltrate, edema, telangiectasia, extravasation of erythrocytes
Warm water immersion foot	Plantar surfaces of feet	Pain on weight-bearing, tingling, "walking on rope" sensation	Early: swelling, wrinkling, and pallor of plantar surfaces  Recovery: resolution of changes in 24 h; shedding of stratum corneum starts in 4-6 d, lasts 7-14 d; feet remain tender until new callus develops	None	1-3 d (symptoms); 7-14 d (fully functional)	Thickening of stratum corneum



Pathogenesis	Water Exposure	Water Temp.	Relation to Water Temp.	Treatment	Prophylaxis	Susceptibility Factors
Direct vascular injury by cold	2–14 d continuously wet (but not necessarily immersed)	15°C	Lower temperature hastens injury	Removal from wet environment, avoidance of weight-bearing, rewarming of body, elevation and cooling of feet, nutritious diet, asepsis, tetanus prophylaxis, prophylactic antibiotics, conservative surgical approach, avoidance of smoking	Individual education in first aid and recognition; frequent rotation out of wet, cold areas; maintenance of nutritional status; informed command elements	Dependency, immobility, trauma, anoxia, poor nutrition, improper warming
Same as trench foot	1 d or more of continuous immersion	15°C	Same as trench foot	Same as trench foot	Enclosed survival craft, individual protective suits	Same as trench foot
Passage of water through epidermis, with secondary subacute dermatitis	3–10 d of continuous immersion	22°C–32°C	None	Allowing feet to dry until asymptomatic	24 h of drying for each 48 h of exposure	Previous episodes may increase susceptibility to repeated episodes
Hyperhydration of stratum corneum	1–5 d of intermittent immersion	22°C–32°C	Increased temperature hastens injury	Allowing feet to dry until asymptomatic	Daily drying (overnight), silicone barrier greases	Thicker stratum corneum predisposes to injury

Wars.<sup>7,8</sup> Yet these lessons seem to have been lost on modern armies. In Europe during World War II, American forces sustained 11,000 cases of trench foot in November 1944 with more than 6,000 in the Third U.S. Army alone.<sup>9</sup>

Trench foot is nearly identical to gradual-onset frostbite, but the maximum temperature at which trench foot can occur has not been established. Ice crystals will not form in tissue above 0°C, but from 0°C to 10°C to 15°C clinical trench foot will develop if exposure lasts 48 hours or longer.<sup>8</sup> Other contributing factors include nutritional deficiency; trauma (rubbing or walking on affected feet); wind; improper clothing type and integrity; circulatory stagnation and tissue anoxia from dependency, inactivity, hemorrhage, or shock; and improper technique used to rewarm an injured limb.<sup>7</sup>

Clinically, trench foot is insidious in onset, the soldier first noting a cold sensation giving way to numbness. Paresthesia and pain may be noted with weight bearing.<sup>8,10</sup> With continued exposure, complete anesthesia to touch, pain, and temperature occurs: a feeling described as “walking on blocks of wood.”<sup>9</sup>

The feet appear pale and swollen and may exhibit vesiculobullous lesions.<sup>6-8</sup> The degree of edema during this ischemic or prehyperemic stage depends on whether the feet are intermittently rewarmed during the course of exposure (which results in less edema).<sup>9</sup> The feet may appear mottled or purple, suggesting impending gangrene, yet such permanent damage is usually minimal with proper care (Figure 4-1).<sup>9-10</sup>

The hyperemic<sup>6</sup> or inflammatory<sup>9</sup> stage occurs several hours after removal of footgear and re-warming of the extremity. Sensation returns proximally to distally, first as a tingling sensation that rapidly progresses to an extreme burning, throbbing pain.<sup>8-10</sup> Warmth cannot be tolerated and soldiers become more comfortable with cooling of the extremity.<sup>9</sup> Hypesthesia replaces anesthesia except for the most distal areas, which may remain anesthetic for weeks or months. The feet rapidly swell and become warm, dry, and erythematous, with bounding pulses.<sup>9,10</sup>

In milder cases, this stage peaks at 24 hours. Severe cases, however, may progress for 48 to 96 hours and produce areas of blistering and circulatory compromise that are more likely to become gangrenous. Hemorrhage and ecchymosis may be present.<sup>8,11</sup>

Milder cases of trench foot subside slowly over 1 to 4 weeks and are frequently accompanied by a variably scarring exfoliation<sup>6,9</sup> of the affected areas. More severe cases progress to the posthyperemic stage. Although trench foot patients are susceptible

## OK to put on the Web

**Fig. 4-1.** Mild edema and a mottled appearance of the plantar aspect of the feet are characteristic of the early hyperemic stage of trench foot. Prolonged exposure to cold, damp conditions leads to prolonged incapacity. Photograph: Courtesy of David Corbett, CDR, Dermatology Branch, National Naval Medical Center, Bethesda, Md.

to sepsis, the uncomplicated course of this injury has no systemic manifestations.

The posthyperemic or postinflammatory stage is prolonged. The previously hot, dry foot becomes cool, moist, mottled or entirely cyanotic, with pulses difficult to find. The extreme pain of the hyperemic stage subsides to a deep ache, noted especially distally and often associated with the smaller joints.<sup>8,9</sup> Hyperesthesia and paresthesia disappear rapidly, whereas anesthesia tends to remain for months or years.<sup>6,9</sup> Late changes in more severely affected soldiers may include atrophy of the skin,<sup>6</sup> osteoporosis,<sup>9</sup> and muscular atrophy and deformity (especially of the clawfoot type).<sup>9,11</sup>

Histologically, trench foot is a manifestation of injury to the microvasculature.<sup>8,10</sup> Peterson and Hugar<sup>12</sup> state that prolonged exposure to cold causes increased blood viscosity and sludging of red cells within the vessels. Combined with sympathetic vasoconstriction and loss of serum proteins through damaged endothelium, the result is thrombosis,

ischemia, and cell injury.

Thrombosed vessels of the dermis and subcutaneous tissue, reflex vascular dilation, capillary rupture, and increased vascular permeability all contribute to the edema, vesiculation, and ecchymoses of the hyperemic stage.<sup>8-10</sup> The work of Smith et al,<sup>8</sup> in which trench foot was duplicated in rabbits, also showed fibrin deposition in vascular walls and muscle bundles, edema and neutrophilic infiltration of dermal collagen and muscles, edema of nerve axons, and vacuolization of muscular fibers of vascular endothelium. Smith and coworkers observed variable damage to lymphatic tissue.

Biopsies of tissue in the posthyperemic stage have demonstrated atrophy and thinning of the dermis, fibrosis and collagen deposition around nerve endings and blood vessels, and replacement of muscle bundles and fibrils by scar tissue.<sup>6</sup>

### Immersion Foot

Immersion foot can be considered the sailor's counterpart of the soldier's trench foot. The term "immersion foot" was first used during World War II to describe a syndrome of clinical conditions occurring in extremities exposed to prolonged, continued immersion in water of temperature ranging from above freezing to 15°C. Seen most dramatically during World War II, immersion foot typically develops in shipwrecked persons who are adrift either in water or in lifeboats partially filled with water.<sup>6,7,9,10</sup> It also was reported in Vietnam, the result of prolonged immersion in rice paddies.<sup>11</sup>

Clinically, soldiers with immersion foot show the same prehyperemic, hyperemic, and posthyperemic stages as do those affected with classic trench foot.<sup>6,9-11</sup> In immersion foot, however, the injury may extend more proximally to include the knees, thighs, and buttocks, depending on the depth of immersion.<sup>6</sup> Also, because of the continuous exposure, immersion foot may begin the first day, whereas trench foot usually begins after several days of lesser and, perhaps, intermittent exposure. The histopathological findings seen in immersion foot are similar to those of trench foot.

### Management

Treatment of nonfreezing injuries such as trench foot and immersion foot is based on reversing the ischemia while not aggravating the edema, red cell extravasation, or inflammation of the hyperemic stage. With rewarming, damaged tissue cells have a greatly increased need for effective blood flow to

remove products of necrosis. As this reflex vasodilation occurs, previous thrombosis and direct injury to endothelial cells by cold and anoxia cause a massive transudation of plasma and red blood cells, which leads to variable degrees of edema, vesiculation, and hemorrhage.<sup>6</sup>

To reduce metabolic demand and reflex vasodilation, the healthcare provider must raise the core temperature of the body while keeping the affected extremities cool.<sup>6,9,10</sup> Elevating the patient's uncovered feet in a stream of cool air from a fan while keeping the remainder of the body warm and well nourished usually achieves this goal. Patients notice a decrease in pain, and edema, hyperemia, and vesiculation subside.<sup>6</sup> Cooling of the extremities continues until the hyperemic stage has subsided and circulation is reestablished. The practice of rubbing the affected extremity with snow or ice further injures already compromised tissue and has no place in modern therapy.<sup>6,8-10</sup>

Other general measures include avoidance of weight bearing and direct trauma, aseptic precautions, prophylactic antibiotics, avoidance of smoking, tetanus prophylaxis, analgesics, a nutritious high-protein diet, and possible plasma transfusion as indicated. Surgical treatment should be delayed as long as possible to allow natural demarcation of tissue loss, and amputation should be correspondingly conservative.<sup>6,9,10</sup>

Other forms of therapy suggested for frostbite have not been specifically investigated for nonfreezing injuries and are *not* recommended. These treatments include rapid rewarming, low molecular weight dextran, sympathetic blockade, ultrasound, continuous epidural anesthesia, anticoagulation, and regional sympathectomy.<sup>12-15</sup>

Treatment of the posthyperemic stage is mostly symptomatic, utilizing physiotherapy, exercise, and surgical correction of deformity.<sup>9</sup> Early sympathectomy in more severe cases may prevent late sequelae such as fibrosis, contractures, and scarring,<sup>6</sup> but such intervention awaits further study.

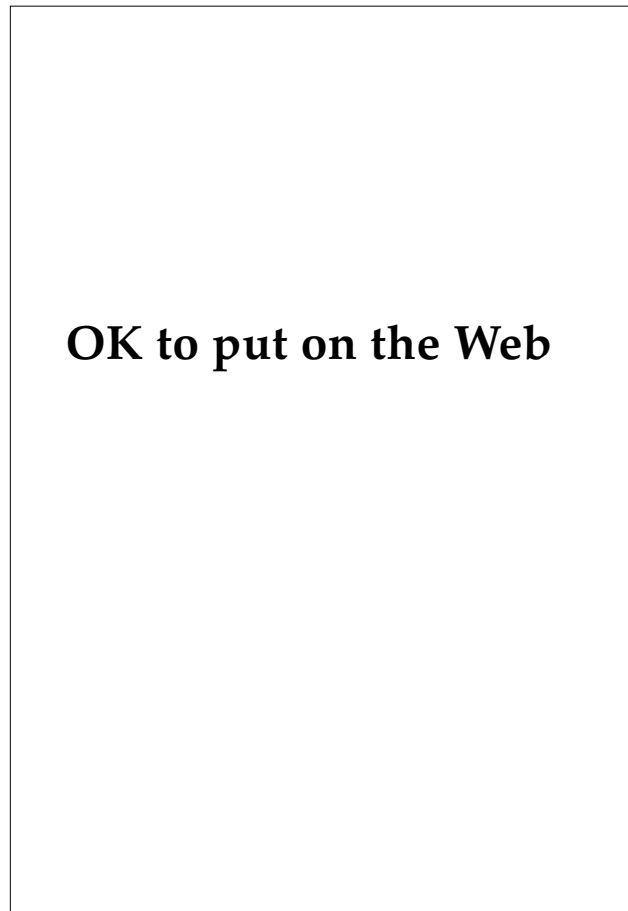
Prevention of trench foot and immersion injury is difficult, especially in wartime circumstances. Of primary importance is the proper choice, use, and care of protective footwear. Individual education in first aid and recognition of impending injury, attention to personal hygiene, frequent rotation out of wet and cold areas, maintenance of nutritional status and morale, and informed command personnel are all necessary to prevent trench foot. Immersion foot may be prevented by the use of enclosed survival craft and by the availability of cold water protective suits for individuals on ships at sea.

## INJURIES IN WARMER CLIMATES

As with trench foot and immersion foot, pain and disability characterize the following two preventable warm water syndromes. While the healing time is shorter for the warm water syndromes—several days to 2 weeks as compared with several weeks to months in cooler climates—the impact on fighting strength is obviously dramatic. Prevention by responsible policies and adherence to them by the commander are of paramount importance to the accomplishment of the unit's mission.

### Tropical Immersion Foot

Investigators first referred to what they felt was a variant of classic immersion foot occurring in a

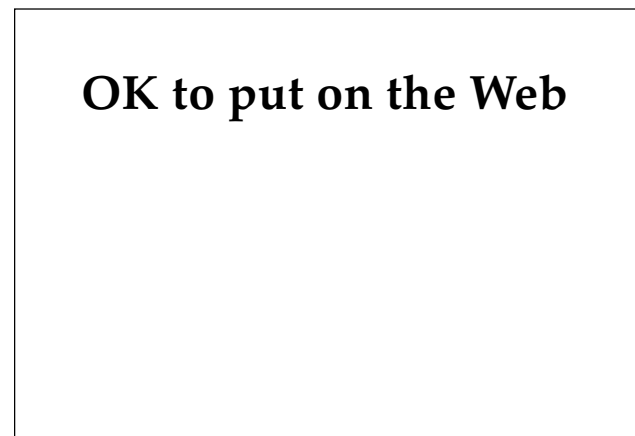


**Fig. 4-2.** Physical examination of this soldier whose feet had been continuously immersed in the warm water of a rice paddy for several days reveals tropical immersion foot with striking edema. Photograph: Courtesy of David Taplin, PhD, Dermatology Department, University of Miami School of Medicine, Miami, Fla.

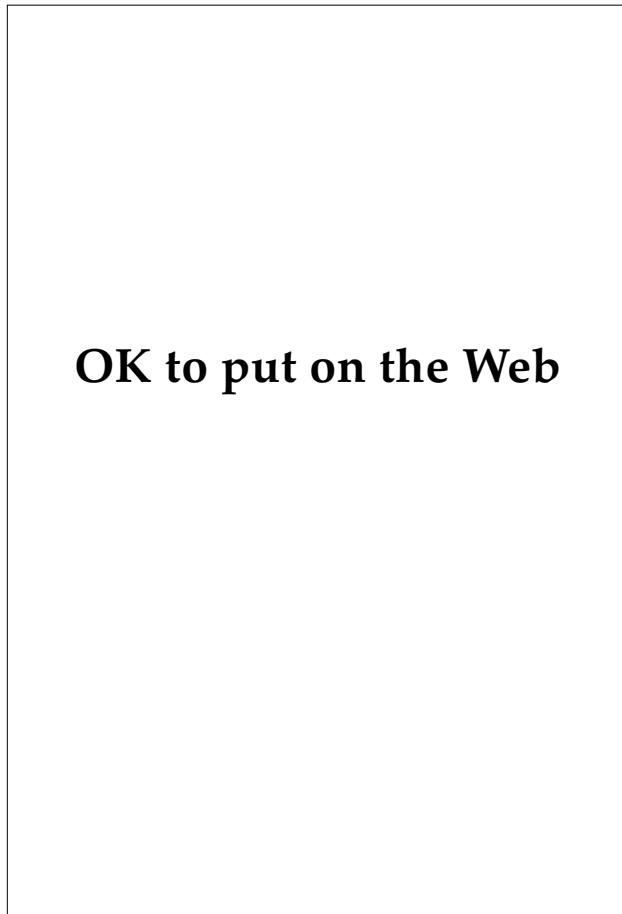
considerably warmer environment in troops fighting in the Philippines during World War II.<sup>9</sup> A similar hot, wet environment experienced by ground forces in Vietnam was recognized as the cause of many foot casualties. Such casualties frequently resulted in greater loss of combat unit strength than did all other medical causes combined and often were instrumental in limiting the duration of field operations.<sup>16</sup>

Tropical immersion foot, commonly known as “paddy foot,” occurs after continuous or near-continuous immersion of the foot in water or mud of temperatures above 22°C for periods ranging from 2 to 10 days.<sup>9,16-18</sup> The first symptoms include burning<sup>16</sup> and itching<sup>18</sup> sensations on the dorsum of the foot. With continued exposure, walking becomes progressively more difficult.<sup>9,18</sup>

When footgear is removed, the foot is edematous (Figures 4-2 and 4-3). Usually, the shoes cannot be replaced.<sup>9,16</sup> The feet may initially appear pale,<sup>9</sup> but they rapidly become intensely erythematous in a distribution sharply demarcated at shoe- or boot-top level (Figures 4-4 and 4-5). This erythema affects the dorsum of the foot but not the plantar surfaces—an important differentiating point from warm water immersion foot.<sup>9,16-19</sup> Papules, vesicles, or both may appear, sometimes with a hemorrhagic component.<sup>18-20</sup>



**Fig. 4-3.** The erythema of tropical immersion foot (shown here in an early stage) affects the dorsal surface of the foot. Warm water immersion foot, which results from intermittent rather than continuous exposure to warm, wet conditions, affects only the soles. Photograph: Courtesy of David Taplin, PhD, Dermatology Department, University of Miami School of Medicine, Miami, Fla.



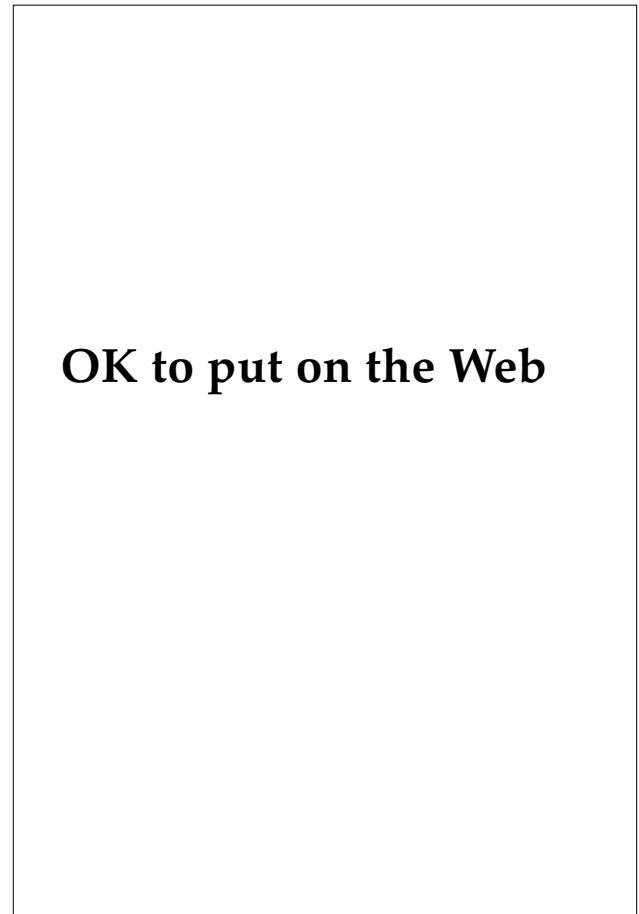
**OK to put on the Web**

**Fig. 4-4.** On close examination of a patient with early tropical immersion foot, erythema, peeling, and fissures are present. Skin changes such as these are often accompanied by adenopathy and fever. Photograph: Courtesy of David Taplin, PhD, Dermatology Department, University of Miami School of Medicine, Miami, Fla.

Although tenderness and pain (especially on weight bearing) are often prominent in tropical immersion foot, hyperesthesia, paresthesia, and anesthesia are more common. Most notable are the systemic reactions. Severely affected soldiers have tender unilateral or bilateral femoral adenopathy and a fever of 38°C to 39°C.<sup>9,16-18</sup>

No definite predisposing factors are known, but physicians and commanders estimate that severe tropical immersion foot develops within 4 days in 3% to 5% of exposed individuals. These individuals seem predisposed to repeat injury.<sup>16</sup> In about 80% of those exposed, some degree of the disorder develops after 10 to 12 days.<sup>18</sup>

Histologically, tropical immersion foot shows epidermal parakeratosis and acanthosis,<sup>20</sup> dermal edema and telangiectasia, and a lymphocytic perivascular infiltrate with associated extravasation



**OK to put on the Web**

**Fig. 4-5.** In tropical immersion foot, the erythema extends up the leg to a point of sharp demarcation at boot-top level. Photograph: Courtesy of David Taplin, PhD, Dermatology Department, University of Miami School of Medicine, Miami, Fla.

of red blood cells.<sup>16,18-20</sup> Willis,<sup>21</sup> in an experiment exposing the backs and arms of volunteers to controlled continuous water contact, achieved similar histological changes. He postulated that such changes are caused by loss of barrier function of the swollen stratum corneum, with secondary irritation or damage to the underlying tissues.

Management of tropical immersion foot consists of bed rest, elevating and drying the feet, analgesics if necessary, and antibiotics if indicated. Usually, fever and adenopathy resolve within 72 hours, and the erythema and edema subside in 5 to 7 days, followed by a fine branny desquamation resulting in normal-appearing feet.<sup>16,18</sup> Even the most severe cases usually resolve within 2 weeks without sequelae such as gangrene, persistent sensory changes, or orthopedic disability.

Prevention is easily accomplished if a 24-hour

drying-out period is alternated with each 48 hours of water exposure.<sup>16,18</sup> In a military setting, the commander's attention to this matter is critical. Although rapid-drying boots and socks may delay the onset of tropical immersion foot,<sup>16</sup> silicone greases used as a barrier ointment have not proved effective.<sup>20</sup> Since persons affected with the disorder seem predisposed to reinjury,<sup>16,19</sup> special attention to preventive measures is indicated for these individuals.

### Warm Water Immersion Foot

Although warm water immersion foot may seem the most innocuous of the immersion foot syndromes, it can incapacitate an individual for 3 to 14 days. This condition occurred in many service members in Vietnam when they were subjected to variable periods of intermittent exposure to wet, warm conditions. More recently, warm water immersion foot has been noted in persons wearing insulated boots, without water exposure, presumably from the buildup of perspiration—the so-called “moon-boot syndrome.”<sup>22,23</sup>

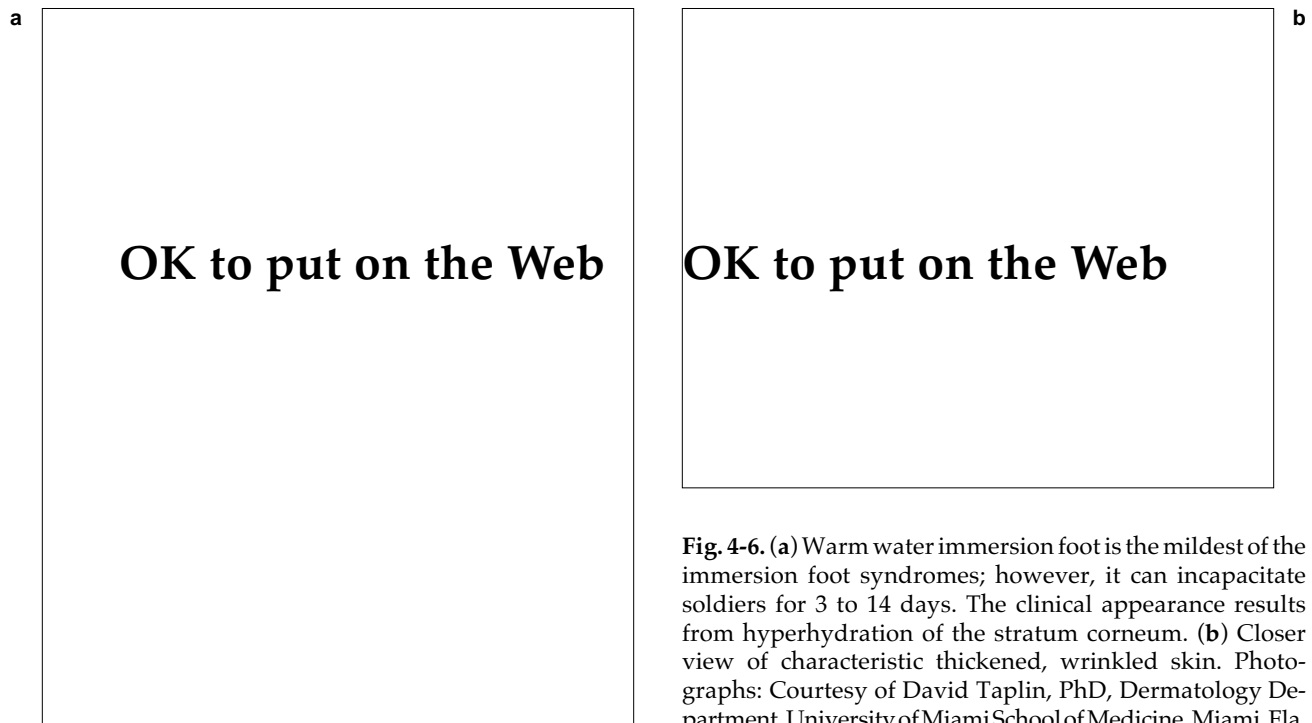
After 1 to 3 days of exposure, affected individuals begin to note pain on weight bearing, tingling, and a sensation described as “walking on rope.”<sup>16</sup> When footwear is removed, the soles of the feet are

thickened, severely wrinkled, and macerated (Figure 4-6).<sup>16,17,24,25</sup> Although these changes may extend to the sides of the foot, they do not affect the dorsum.

Warm water immersion foot appears to develop faster at higher water temperatures.<sup>13</sup> Persons with thicker, callused soles tend to experience more severe (although not earlier) symptoms.<sup>16,17,24,26</sup> Microscopically, hyperhydration of the stratum corneum is the only finding.<sup>27</sup>

Treatment consists of bed rest and drying the feet.<sup>16-18</sup> The wrinkles and maceration resolve within 24 hours, but tenderness may last 2 to 3 days. The patient is asymptomatic by the third day. Shortly thereafter, however, thick portions of the sole begin to fissure and peel, shedding completely within 1 to 2 weeks. During this peeling, the stratum corneum may be more susceptible to infection via the fissures,<sup>17</sup> and patients experience tenderness on walking as new calluses develop.<sup>18</sup>

Prophylaxis consists of drying the feet for 6 to 8 hours (overnight) of every 24 hours.<sup>16,17,28</sup> Silicone grease applied to the entire foot<sup>24,25,28</sup> or to the soles alone<sup>15</sup> retards the development of warm water immersion foot. Footgear with adequate drainage and composed of rapidly drying materials may also slow the development of this condition.



**Fig. 4-6.** (a) Warm water immersion foot is the mildest of the immersion foot syndromes; however, it can incapacitate soldiers for 3 to 14 days. The clinical appearance results from hyperhydration of the stratum corneum. (b) Closer view of characteristic thickened, wrinkled skin. Photographs: Courtesy of David Taplin, PhD, Dermatology Department, University of Miami School of Medicine, Miami, Fla.

## SUMMARY

As is the case for most cutaneous diseases seen in soldiers, the counterpart of immersion foot exists in the civilian community. Immersion foot problems in homeless individuals have recently been reported following continuous exposure to a damp environment over a period of days to weeks.<sup>29</sup> Ski instructors have also been reported to develop this syndrome.<sup>11</sup>

Military medical history continues to teach recurring critical lessons; the kinds and amounts of skin disease occurring in soldiers can be predicted on the basis of knowledge of such factors as climate, terrain, and environmental conditions. In order to significantly decrease the impact of skin disease on combat effectiveness, military dermatologists should be integrated at the division level, so that command policies and tactical considerations can

incorporate these medical matters and ensure logistical support for the successful outcome of military operations.

In wartime, a soldier who becomes a "foot casualty" is as useless to his commander as one who sustains a bullet wound. It is up to the soldier-physician to advise commanders appropriately on the prevention of these environmental injuries. A familiarity with the clinical and pathophysiological aspects of immersion foot syndromes also enables the physician to render appropriate care, which in turn may prevent or ameliorate long-term disability.

(The sections "Injuries in Cool or Cold Climates" and "Injuries in Warmer Climates" and Table 4-1 are reprinted from: Adnot J, Lewis CW. *Immersion Foot Syndromes*. J Assoc Mil Derm. 1985;11(1):87-92.)

## REFERENCES

1. Gillett MC. *The Army Medical Department, 1775-1818*. Washington, DC: Medical Department, US Army, Office of The Surgeon General, and Center of Military History; 1981: 192.
2. Brown HE. *The Department of the United States Army from 1775 to 1873*. Washington, DC: The Surgeon General's Office. 1873: 104.
3. Risch E. *The Quartermaster Corps: Organization, Supply, and Services*. Vol 1. Washington, DC: Office of the Chief of Military History, Department of the Army; 1953: 102-103, 108, 110.
4. Allen AM. *Skin Diseases in Vietnam, 1965-72*. In: Ognibene AJ, ed. *Internal Medicine in Vietnam*. Vol 1. Washington, DC: Medical Department, US Army, Office of The Surgeon General, and Center of Military History; 1977: 7, 81.
5. Pillsbury DM, Livingood CS. Dermatology. In: *Infectious Diseases and General Medicine*. Vol 3. In: Havens WP, Anderson RS, eds. *Internal Medicine in World War II*. Washington, DC: Medical Department, US Army, Office of The Surgeon General; 1968.
6. White JC, Scoville WB. Trench foot and immersion foot. *N Engl J Med*. 1945;232:415-422.
7. Green, R. Frostbite and kindred ills. *Lancet*. 1941;2:689-693.
8. Smith JL, Ritchie J, Dawson J. On the pathology of trench frostbite. *Lancet*. 1915;2:595-598.
9. Wayne TF, DeBakey ME. *Cold Injury, Ground Type, in World War II*. Washington, DC: Office of The Surgeon General, Department of the Army, 1958.
10. Webster DR, Woolhouse FM, Johnston JL. Immersion foot. *J Bone Joint Surg Br*. 1943;24:785-794.
11. Gold RH. A review of immersion foot. *J Am Podiatry Assoc*. 1966;56:414-415.
12. Peterson G, Hugar DW. Frostbite: Its diagnosis and treatment. *J Foot Surg*. 1979;18:32-35.

13. Bouwman DL, Morrison S, Lucas CE, et al. Early sympathetic blockade for frostbite—Is it of value? *J Trauma*. 1980;20:744–749.
14. Weatherly-White RCA, Sjostrom B, Paton BC. Experimental studies in cold injury. Part 2: The pathogenesis of frostbite. *J Surg Res*. 1964;4:17–22.
15. Weatherly-White RCA, Paton BC, Sjostrom B. Experimental studies in cold injury. Part 3: Observation on the treatment of frostbite. *Plast Reconstr Surg*. 1965;36:10–18.
16. Allen AM, Taplin D. Tropical immersion foot. *Lancet*. 1973;2:1185–1189.
17. Samitz, M.H. Immersion injuries. In: *Cutaneous Disorders of the Lower Extremities*. 2nd ed. Philadelphia: JB Lippincott; 1981: 179–183.
18. Akers WA. Paddy foot: A warm water immersion foot syndrome variant. *Milit Med*. 1974;139:605–618.
19. Allen AM, Taplin D, Lowy JA, et al. Skin infections in Vietnam. *Milit Med*. 1972;137:295–301.
20. Douglas JS, Eby CS. Silicone for immersion foot prophylaxis: Where and how much to use. *Milit Med*. 1973;137:386–387.
21. Willis I. The effects of prolonged water exposure on human skin. *J Invest Dermatol*. 1973;60:166–171.
22. Blogg H. Moon-boot foot syndrome. *Br Med J*. 1982;285:1774–1775.
23. Philipp R. Moon-boot foot syndrome. *Br Med J*. 1983;286:562.
24. Taplin D, Zaias N. Tropical immersion foot syndrome. *Milit Med*. 1966;131:814–818.
25. Rietschel RL, Allen AM. Immersion foot: A method for studying the effects of protracted water exposure on human skin. *Milit Med*. 1976;141:778–780.
26. Taplin D, Zaias N, Blank H. The role of temperature in tropical immersion foot syndrome. *JAMA*. 1967;202:546–549.
27. Gill KA. *Naval Medical Field Research Laboratory Report: Field study on silicone ointments MDX-4-4056 and MDX-4-4078*. Camp Lejeune, NC: Department of the Navy; 1967: 1–7.
28. Buckles LJ, Gill KA, Gustave TA. Prophylaxis of warm-water immersion foot. *JAMA*. 1967;200:681–683.
29. Wrenn K. Immersion foot: A problem of the homeless in the 1990s. *Arch Intern Med*. 1991;151:785–788.



# Chapter 5

## CUTANEOUS REACTIONS TO NUCLEAR, BIOLOGICAL, AND CHEMICAL WARFARE

SCOTT D. BENNION, M.D.\* AND KATHY DAVID-BAJAR, M.D.†

---

### INTRODUCTION

### HISTORY

- Nuclear Warfare
- Biological Warfare
- Chemical Warfare

### NUCLEAR WARFARE

- Thermal and Radiation Effects
- Therapy of Cutaneous Radiation Injury
- Late Sequelae of Radiation Exposure

### BIOLOGICAL WARFARE

- Anthrax
- Tularemia
- Plague
- Hemorrhagic Fevers
- Botulism
- Mycotoxins

### CHEMICAL WARFARE

- Chemical Warfare Doctrine and Weaponry
- Sulfur Mustard and Nitrogen Mustard
- Arsenical Vesicants
- Management of Vesicant Injury
- Halogenated Oximes
- Nerve Agents and Cyanides

### SUMMARY

\*Colonel, Medical Corps, U.S. Army; Dermatology Service, Fitzsimons Army Medical Center, Aurora, Colorado 80045

†Major, Medical Corps, U.S. Army; Dermatology Service, Fitzsimons Army Medical Center, Aurora, Colorado 80045

## INTRODUCTION

Throughout the history of warfare, adversaries have continually utilized new technology in an attempt to gain the advantage. In recent history, a great deal of effort has been centered on the development of nuclear, biological, and chemical weapons by many countries in pursuit of this goal. Although in the United States the military has been aware of the situation, the military medical community has been slow to react to these threats. Consequently, research and development of new and more effective drugs, therapeutic approaches, and prophylaxis for nuclear, biological, and chemical (NBC) casualties have not received adequate attention.

This problem persists in the field of dermatology. Although basic research has suggested many potential therapies for the treatment of NBC casualties, the application of these findings in the development and fielding of treatments for NBC casualties on the battlefield has been slow in developing. It is incumbent on all military physicians, including

dermatologists, to become aware of the NBC threat, to know how NBC weapons induce pathology, and to utilize current and potential therapies to treat NBC casualties.

Clearly, many new developments in medicine can be applied to improve the standard NBC treatment regimens now in place; but to reach this objective, physicians must have a clear understanding of the effects of NBC weapons at the clinical and physiological levels and how these weapons may be used in future wars.

To this end, a brief discussion of the tactics of NBC warfare is presented, the clinical data compiled over the last 80 years on the effects of NBC weapons are summarized, and the most recent cases of mustard gas use from the Iran-Iraq War are discussed. Standard NBC therapies that have been developed during the two world wars are recounted and new therapeutic regimens based on more recent research are detailed.

## HISTORY

Some weapons not only inflict casualties but manage to strike considerable fear in the enemy. It is this unique blend of real and perceived danger that makes nuclear, biological, and chemical weapons so appealing for nations and groups to acquire.

### Nuclear Warfare

The history of nuclear warfare encompasses a fairly short time, dating back to the bombing of Nagasaki and Hiroshima in 1945. Despite the brevity of the nuclear era, it has been an extraordinary time when the way nations have had to deal with each other both politically and militarily has changed dramatically. This situation is due to the magnitude of destructive power that nuclear weapons possess. The threat of the destruction of global civilization has given the leaders of the nuclear nations pause when contemplating future conflicts.

The destructive physical power of the atomic bomb in the form of thermal and blast energy was acutely apparent after the atom bombs were dropped on Japan, but the lingering effects of radiation were not fully realized until weeks and months after the bombing.

That radiation could cause tissue damage has been known since Roentgen discovered X rays in 1896. Shortly after the discovery, Thomas Edison noted that his assistant, Clarence Dally, who had been working with X rays, developed an acute inflammation of his hands followed by scaling, blistering, ulceration, and eventual malignancy. This type of effect became apparent in the aftermath of the bombing of Hiroshima. Dr. Michihiko Achiya published her diary elucidating those times.<sup>1</sup> Some of the excerpts from her diary clearly describe the evolution of radiation symptoms and the constellation of signs associated with radiation poisoning. The following excerpt describes the thermal effects of a nuclear explosion as related by Dr. Tabuchi:

"It was a horrible sight," said Dr. Tabuchi. "Hundreds of injured people who were trying to escape to the hills passed our house. The sight of them was almost unbearable. Their faces and hands were burnt and swollen; and great sheets of skin had peeled away from their tissues to hang down like rags on a scarecrow. They moved like a line of ants. All through the night, they went past our house, but this morning they had stopped. I found them lying on both sides of the road so thick that it was impossible to pass without stepping on them."

"The sight of the soldiers, though, was more dreadful than the dead people floating down the river...they had no faces! Their eyes, nose and mouths had been burned away, and it looked like their ears had melted off. It was hard to tell front from back. One soldier, whose features had been destroyed and was left with his white teeth sticking out, asked me for some water, but I didn't have any. I clasped my hands and prayed for him. He didn't say anything more. His plea for water must have been his last words. The way they were burned, I wonder if they didn't have their coats off when the bomb exploded."<sup>1(p15)</sup>

Dr. Achiya noted the following long-term effects of radiation poisoning in her notes:

Another observation was that the severity of gastrointestinal symptoms appeared to bear no relation to the extent of burns and other injuries. Many patients with severe wounds recovered rapidly whereas there were patients with the symptoms described who did not appear to be injured at all but who, nevertheless, died. Among those who died, many had a bloody diarrhea similar to that seen in dysentery, and others had bloody urine or sputum. Severe uterine hemorrhage, which at first we mistook for derangements of menstruation, was common among the women. Some, who lingered as long as a week, died with stomatitis or gangrenous tonsillitis. Now, with the death curve rising again, stomatitis appeared and with it petechiae. The occurrence of petechiae followed the same pattern we had observed in patients with gastrointestinal symptoms. They bore no relationship to the type or severity of injury, and those who appeared to be uninjured and had even felt well enough to help in the care of other patients were beginning to show these blood spots beneath the skin. We had several instances of presumably healthy people who developed petechiae and died before persons who were obviously critically ill. You can understand what an ominous portent the development of petechiae had for us.<sup>1(pp97-98)</sup>

The events of the nuclear holocaust in Japan have led the leaders of the nations with nuclear capability to avoid the use of nuclear weapons. However, as more nations develop the technological capability to construct nuclear devices, the threat of a repeat of the devastation of Hiroshima becomes more likely. Therefore, medical officers must be prepared to treat the casualties of nuclear warfare.

### Biological Warfare

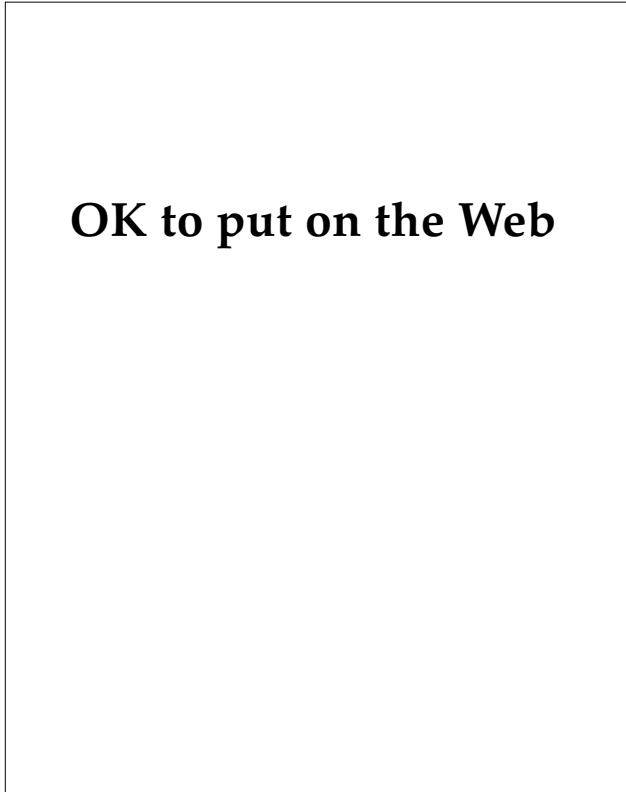
The use of biological weapons in warfare is not a recent development. In the 14th century, at the

siege of the fortress of Kaffa by the Tartars, corpses infected with plague were catapulted into the fort to infect its occupants.<sup>2</sup> There are several reports of American Indians receiving articles contaminated with smallpox given to them in an attempt to infect the Indians with smallpox. The British troops under the orders of Amherst supplied the Amerindians with smallpox-infested blankets.<sup>3</sup> During World War I, it is believed that attempts were made to produce an epidemic of plague in the city of Petrograd. Also, anthrax and glanders are believed to have been used in World War I, primarily directed at infecting horses. These latter efforts involved the use of scientific discoveries (ie, the discovery of pure cultures and infection chains) and the application of these recent scientific discoveries for warfare. During World War II, the Japanese are believed to have organized industrial production of disease pathogens and carriers. Our own involvement in the research and development of biological weapons began in 1941.<sup>4</sup>

In April 1979, Sverdlovsk, a small village in the Soviet Union, was decimated by an anthrax epidemic in which many of the people of the town died of a pneumonic form of anthrax.<sup>5,6</sup> Although the Soviet government vehemently denied the charge that this tragedy was caused by a biological warfare-agent accident, it is unlikely that an epidemic of pneumonic anthrax could have been caused by any other circumstance.

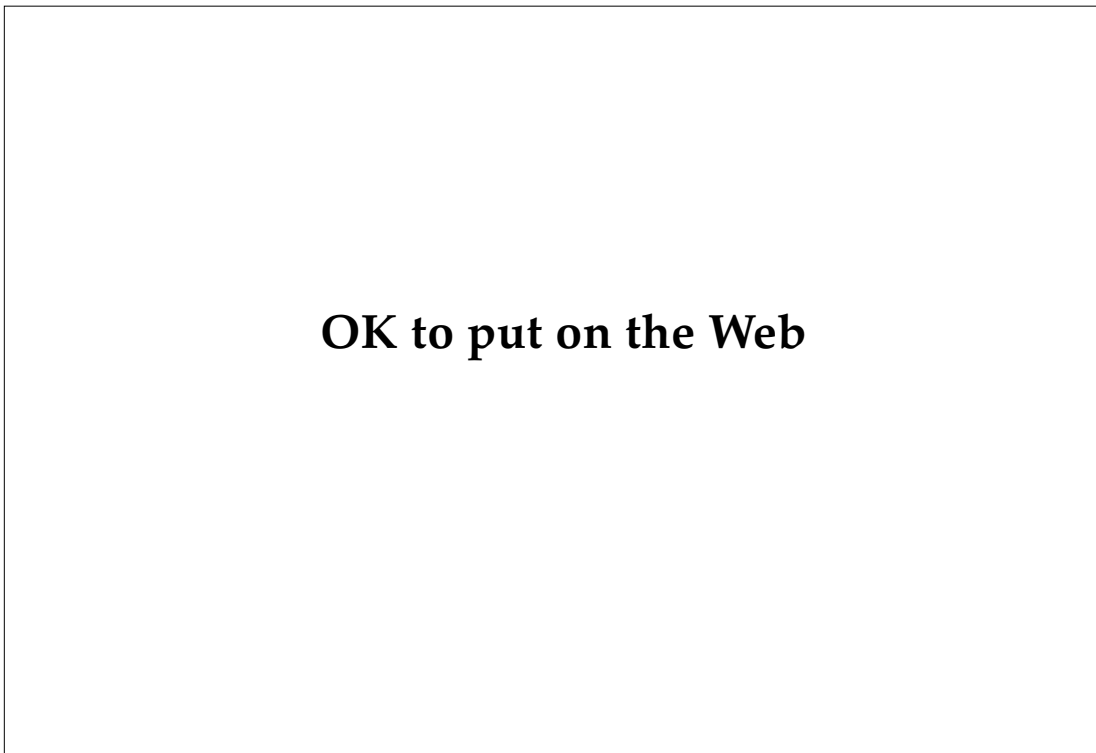Historical accounts also exist concerning the pathology caused by the by-products of microbes. The effects of fungal toxins have been known for centuries even though the cause was not. The earliest mention is on an Assyrian tablet dated from 600 BC, which refers to a noxious pustule in the ear of grains. The tablet probably refers to the infection of rye grains by the fungus *Claviceps purpurea* (Figure 5-1), which produces ergot alkaloids, the causative agents in ergotism.<sup>7,8</sup> During the Middle Ages, large epidemics of hallucinations, delirium, convulsions, and severe limb ischemia leading to dry gangrene and autoamputation were attributed to the ingestion of rye contaminated with ergot fungus (*Claviceps purpurea*).<sup>8</sup> One of the most vivid presentations of this malady is by Hieronymos Bosch in his painting *The Last Judgment*. In Figure 5-2, a detailed area of the painting, the signs and symptoms associated with ergot poisoning are shown.

During the latter part of World War II, the Soviets experienced an outbreak of human alimentary aleukia that caused numerous fatalities.<sup>9</sup> The outbreak was attributed to a fungal contamination of



**Fig. 5-1.** (left) Rye grain infected with *Claviceps purpurea*, a fungus that produces ergot alkaloids. The darkening of the grains is characteristic of the infection. Photograph: Courtesy of Dr. Werner Schreiber, Nuremberg, Germany.

**Fig. 5-2.** (below) Detail of Hieronymus Bosch's *The Last Judgment* depicting the signs and symptoms of ergot poisoning. The painful paresthesias are represented by the "frying" extremities in the pan, the man roasting on the spit, and the webbed feet of the figure in the lower left corner. The cutaneous manifestations of blackened ischemic extremities and ascites are depicted in the figure in the upper right. Photograph: Courtesy of Akademie der bildenden Künste, Vienna, Austria.



grains (corn, barley) by fungi that produce trichothecene mycotoxins. The lethality of these fungal toxins apparently impressed the Soviets because they incorporated trichothecenes into weapons. The subsequent use of trichothecene by the Russians in Afghanistan and Southeast Asia was supported by several reports that there have been chemical attacks on individuals in those areas, with resultant symptoms suggestive of trichothecene poisoning.<sup>10,11</sup> Although the validity of the findings has been questioned, the discovery of Soviet gas masks in Afghanistan, contaminated with fungal toxins, is strong supportive evidence that these agents have been used by the Soviets.<sup>12</sup>

### **Chemical Warfare**

Since the first employment of mustard and chlorine gases in World War I, the use of chemical weapons has been sporadic. This restraint has been based in part on a fear engendered in world leaders by the effectiveness with which chemical weapons were used in that war. Due to the infrequency of chemical warfare in the last 75 years, the belief prevails that chemical weapons are a recent invention; however, the use of chemical weapons to gain advantage in war dates back to the Peloponnesian War in 428 BC. In this incident, which was the first recorded use of chemical weapons, the Spartans started a fire with sulfur-saturated wood under the walls of a city defended by the Athenians. Chronicles of ancient history also record that the Greeks used pots filled with a mixture of sulfur, pitch, tow, and resins; the pots were ignited and hurled into towns, producing suffocating smoke and fire.<sup>13</sup>

Despite protests by the clergy and others, the production of more effective weapons based on the technology of the day continued. An example of this was the crossbow. In 1139, Pope Innocent III and the Ecumenical Council to the Lateran expressed horror at its lethality in battle and banned its use (except against non-Christians) under penalty of excommunication.<sup>13</sup> Although the Pope had far-reaching influence at that time, the use of the crossbow in war became standard and widespread. Its use ebbed only when the more effective bow and arrow was demonstrated to possess a more rapid rate of fire in battle.

Attempts to introduce new and more effective weapons to gain advantage in battle continued into the 19th century. For example, the use of chlorine gas in warfare was not a German invention but one of an American named John W. Doughty. And chlorine might have been used in the U.S. Civil War

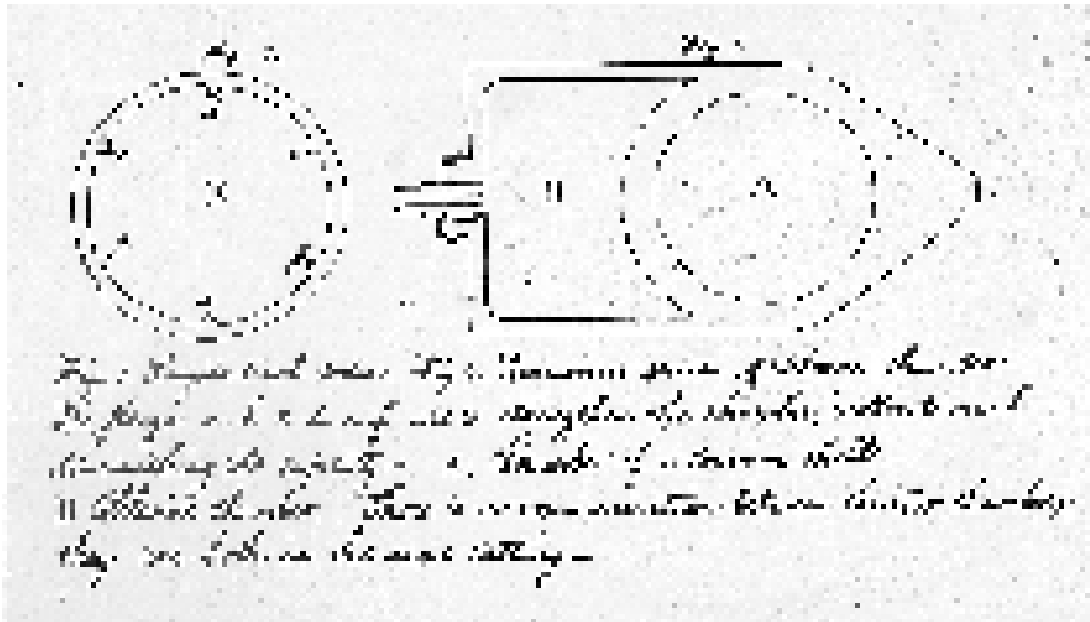
if the War Department of 1862 had followed up on a suggestion of Doughty's that was contained in a letter with an illustration (Figure 5-3). This document is now kept in the Old Records division of the Adjutant General's Office in the Archives Building, Washington, D.C. The letter clearly predicted the details of the use of chlorine gas by the Germans in World War I.<sup>14</sup> The War Department concluded that there was no merit in Mr. Doughty's invention.

Efforts to prevent the use of certain weapons continued in the 19th century when the Hague Conference of 1899 was convened. At that time, a resolution was being contemplated (later rejected) that would ban the use of poisonous gases in war. The United States' representative, Admiral Mahan, was opposed to such a ban and stated:

The reproach of cruelty and perfidy, addressed against those supposed (gas) shells, was equally uttered formerly against firearms and torpedoes, both of which are now employed without scruple ...It was illogical, and not demonstrably humane, to be tender about asphyxiating men with gas when all were prepared to admit that it was allowable to blow the bottom out of an ironclad at midnight, throwing four or five hundred men into the sea, to be choked by water with scarcely the remotest chance to escape.<sup>15(p686)</sup>

Since then, the United States has continued to have an ambiguous position on the use of chemical warfare. This position was demonstrated by the United States' refusal to ratify the Geneva Gas Protocol in 1926.<sup>16</sup> In 1972, the Biological and Toxin Weapons Convention was written to supplement the Geneva Protocol, and it was signed by 103 nations including the United States.<sup>10</sup> However, this treaty does not limit research in the defense of biological warfare.

During World War I, a stalemate existed on Germany's Western Front between the allied forces of Britain and France, and the Germans. To break this stalemate, the Germans actively searched for a new weapon that could enhance their ability to wage effective maneuvers on the battlefield and break through the entrenched allied positions. Alerted to the possibilities of gas warfare by their scientists, they enlisted the help of two eminent German chemists, Professor Walther Nernst<sup>14</sup> and L. F. Haber. With their guidance, the Germans delivered the first gas attack of modern times near a small village in Belgium called Ypres. On April 22, 1915, late in the afternoon, they released large amounts of chlorine gas, the same chemical as that



Hon. Edwin M. Stanton  
Secretary of War

Sir

The above is a representation of a projectile which I have devised to be used as a means for routing an *entrenched* enemy. Believing it to be new and valuable, I send the War Department a brief description: Chlorine is a gas so irritating in its effects upon the respiratory organs, that a small quantity diffused in the atmosphere, produces incessant & uncontrollably violent coughing. It is 2 ½ times heavier than the atmosphere, and when subjected to a pressure of 60 pounds to the inch, it is condensed into a liquid, its volume being reduced many hundred times. A shell holding two or three quarts, would therefore contain many cubic feet of the gas.

If the shell should explode over the heads of the enemy, the gas would, by its great specific gravity, rapidly fall to the ground: the men could not dodge it, and their first intimation of its presence would be by its inhalation, which would most effectually disqualify every man for service that was within the circle of its influence; rendering the disarming and capturing of them as certain as though both their legs were broken.

To silence an enemy's guns or drive him from his entrenchments, it would be only necessary to explode the shells over his head or on his windward side. If exploded in rapid succession over or within a fort, evacuation or surrender could not be delayed beyond fifteen minutes. Casemates and bomb-proofs would not protect the men.

This kind of shell would, I think, in the present advanced state of military engineering, be a very efficient means for warding off the attacks of iron-clad vessels and *steam rams*; for, as to the steam ram, a ten inch gun that would carry a shell containing a gallon or two of the liquid, would with ordinary accuracy, be able at the distance of ¾ of a mile, to envelop him in an atmosphere that would cause his inmates to be more anxious about their own safety than about the destruction of their enemy.

It may be asked if the gas which drove the enemy from his guns, would not prevent the attacking party who used the gas from taking possession of the abandoned position. I answer it would not: for, this shell does not, like the Chinese stink-pots, deposit a material emitting a deleterious gas *lighter* than the atmosphere, but suddenly projects into the air a *free* gas much *heavier* than the atmosphere, which does its work as it descends to the earth, where it is soon absorbed.

Experiment alone can determine whether this shell has any practical merit. Possibly, I overrate its value; but it must not be forgotten, that while it does the work of an ordinary shell, it also carries with it a force against whose effect the most skillful military engineering can not possibly make any adequate provision.

As to the moral question involved in its introduction, I have, after watching the progress of events during the last eight months with reference to it, arrived at the somewhat paradoxical conclusion, that its introduction would very much lessen the sanguinary character of the battlefield, and at the same time render conflicts more decisive in their results.

If I have erred, I have, *at least* meant well.

Yours,  
Respectfully,  
John W. Doughty

April 5th, 1862, 419 Eighth Avenue, New York

Fig. 5-3. Reproduction of original drawing by John W. Doughty, showing the chlorine gas weapon he proposed in 1862. Redrawn by Karen Wyatt, Medical Illustrator, Fitzsimons Army Medical Center, Aurora, Colorado. Letter reprinted from the Old Records division of the Adjutant General's Office in the Archives Building, Washington, D.C.

mentioned in John Doughty's letter almost half a century before. The yellow-green gas drifted toward the entrenched British soldiers and, being heavier than air, filled all the low-lying areas including the trenches where the British soldiers had taken refuge against a preceding bombardment. The cloud engulfed the 15,000 soldiers. After 15 minutes the attack was over; it had caused total chaos and perhaps 5,000 deaths (the exact number remains controversial).<sup>17</sup> The desired effect occurred and the British line was broken; however, the Germans did not take advantage of the situation and eventually were pushed back. The birth of modern chemical warfare had occurred and the use of the weapon that could "shoot around corners" had begun.

Although the German potential for waging chemical warfare was known to the U.S. forces in Europe, the full impact of these new weapons was not realized until Ypres. This battle, with its resultant casualties, arrested the American Expeditionary Forces' attention and forced the U.S. Army quickly to develop a chemical capability of its own. An excerpt from a 1918 army technical report titled *History of the First Gas Regiment*<sup>18</sup> is indicative of the prevailing doctrine of that era:

It is impossible to conclude otherwise than that gas warfare is an extremely effective agent...However [as] much [as] the elimination of gas in the future as an agent in warfare might be desired, to make its elimination a certainty is impossible, for it is reasonable to suppose that a nation that would violate its treaties would not be scrupulous about the use of weapons to obtain its ends.

Had Germany waited until she had sufficient chlorine and was ready to gas the whole British and French Armies upon every suitable front, she could have won the war in one gas attack. She erred vitally in trying gas on a small scale.<sup>18(p57)</sup>

After World War I, concerns persisted about the use of chemicals in future wars and, although no chemical warfare occurred in World War II, the history of that era is replete with isolated anecdotes in which one country used chemical weapons against another. Italy utilized a mustard agent against Ethiopia in 1935.<sup>16</sup> In 1941, the Japanese employed mustard gas against the Chinese at Ichang. A little-known incident in the northern Italian port city of Bari resulted in the only gas casualties in the European theater during World War II. The USS *John Harvey*, a supply ship carrying mustard gas munitions anchored in the harbor, was attacked by the Germans and destroyed. The contamination of the waters and surrounding area resulted in over 600

casualties.<sup>19</sup> Although many feared the use of chemicals in World War II and Germany had the ability to deploy both blistering and nerve agents, they were not used. This outcome may have been due to a combination of factors including the fact that the Allied Forces had the capability to retaliate in kind. Hitler's reluctance to use chemicals may have also been due to his own personal aversion to chemical weapons based on his experience of being gassed in World War I. In *Mein Kampf*, he relates his experience from 1918:

...the English gas attack on the southern front before Ypres burst loose; they used yellow-cross gas (mustard gas), whose effects were still unknown to us as far as personal experience was concerned. In this same night I myself was to become acquainted with it. On a hill south of Wervick, we came on the evening of October 13 into several hours of drumfire with gas shells which continued all night more or less violently. As early as midnight a number of us passed out, a few of our comrades forever. Toward morning I, too, was seized with pain which grew worse with every quarter hour, and at seven in the morning I stumbled and tottered back with burning eyes. A few hours later my eyes had turned into glowing coals; it had grown dark around me.<sup>20(pp201-202)</sup>

In 1967, reports surfaced that Egypt had used a form of mustard gas against Yemen.<sup>16</sup> During the 1980s, reports from Vietnam and Afghanistan have pointed toward the use of chemical weapons in conflicts in those areas. Most recently, the use of vesicants (blistering agents, eg, mustard gas) and nerve gas by Iraq against its own Kurdish population and against the Iranians in the Iran-Iraq War has focused our attention on the likelihood that U.S. forces will face adversaries who are able and willing to use chemical weapons on the battlefield.

In 1987, the Vesicant Workshop was held at The Johns Hopkins University Applied Physics Laboratory under the sponsorship of the U.S. Army Medical Research and Development Command. In his keynote address, General Richard T. Travis noted that the workshop was being held

because of the use of sulfur mustard by Iraq in the Gulf War and the subsequent recognition of the availability and effectiveness of vesicant agents on the battlefield....Mustard's threat is critical, partly because it incapacitates so many more combatants than it kills and partly because it is so easily prepared from commercially available chemicals. Recently, a Belgian company was alleged to have exported 500 tons of thiodiglycol to Iraq in 1983. This chemical, when combined with hydrochloric acid, produces mustard in excellent yield. Clearly,

the synthesis of sulfur mustard is within the capability of any third world country.<sup>10(p645)</sup>

Despite the naysayers who deny the possibility of chemical warfare in future wars, an increasing body of evidence, especially that gleaned from the Iran-Iraq War, cannot be ignored and strongly suggests that chemicals will be used.

In his book titled *The Reformation of War*, General J. F. C. Fuller describes the ideal weapon:

1. Its production should not detrimentally affect prosperity.
2. It should be simple to manufacture in peace or war.

3. Its nature should be unknown to the enemy.
4. It should be capable of incapacitating without killing, and the incapacity should not be permanent.
5. It should permit of a defense against it being well-known in advance and prepared for by the side using it.
6. It should inflict no permanent damage upon property.<sup>14(p10)</sup>

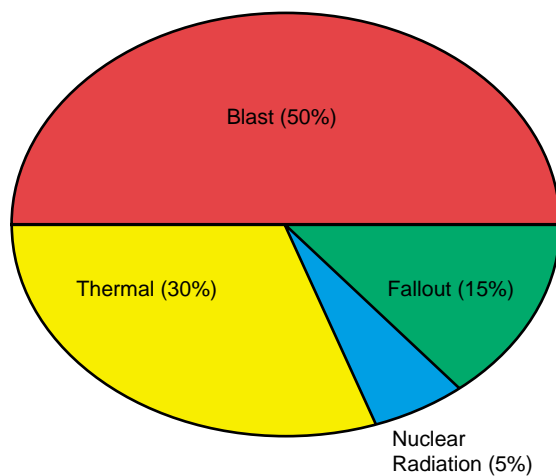
These characteristics fit chemical agents precisely, and mustard in particular. In today's world, one could conclude that the ideal weapon, especially for countries without a nuclear capability, is a chemical agent.

### NUCLEAR WARFARE

The types of casualties produced by a nuclear explosion depend on where the explosion occurs but are always due to one of three effects: blast injuries (direct and indirect), thermal burns, and radiation injuries. Thermal and blast energy account for 80% of the energy released by an atomic bomb (Figure 5-4). A discussion of blast injuries is beyond the scope of this chapter; therefore, we will limit the review to the dermatologic aspects of thermal burns and radiation injuries.

#### Thermal and Radiation Effects

Thermal burns can be caused directly by the initial flash of the thermonuclear explosion or by fires that are secondary to the explosion. The flash



**Fig. 5-4.** Partition of energy of a nuclear air blast. Note that the majority of energy from a nuclear device is blast and thermal energy, the same energy released from a conventional bomb. Fallout and nuclear energy account for only 20%.

burns, which are caused by radiant or infrared energy from the initial fireball, occur on unprotected skin or skin under a light garment. Figures 5-5 and 5-6 illustrate the effect of garment protection from the thermal effects of the initial blast.

The treatment of thermal burns and blast injuries is greatly complicated by the effects of ionizing radiation. This radiation occurs in the form of neutrons, X rays, beta particles (electrons), and gamma radiation produced within the first minutes of the nuclear fireball, and alpha, beta, and gamma radiation from the residual fallout. The charged alpha and beta particles can only penetrate the skin layers, causing an initial erythema that can progress to superficial and deep ulcers (Figure 5-7). Such an occurrence took place in 1946 during the Bikini BRAVO shot, in which many Marshall Islanders were exposed to fallout from the large amount of coral picked up in the blast. The fallout in the form of lime "snowflakes" fell on 239 islanders, causing an initial burning and itching during the first 2 days, followed by epilation and a "wet" superficial ulceration that occurred 2 to 3 weeks after the exposure.<sup>21</sup> Conversely, gamma rays, X rays, and neutrons, all of which have no charge, penetrate deeply into the body and can cause severe damage to vital tissues, especially those such as the hematopoietic tissue with a high rate of cell division. The loss of significant numbers of bone marrow cells can lead to an immunosuppressed state in which the casualty is highly susceptible to bacterial infections. In addition, the epidermal healing process can be delayed by the same mechanism, leading to a protracted recovery period.

The effects of radiation on the human body fall into several different categories dependent on ra-





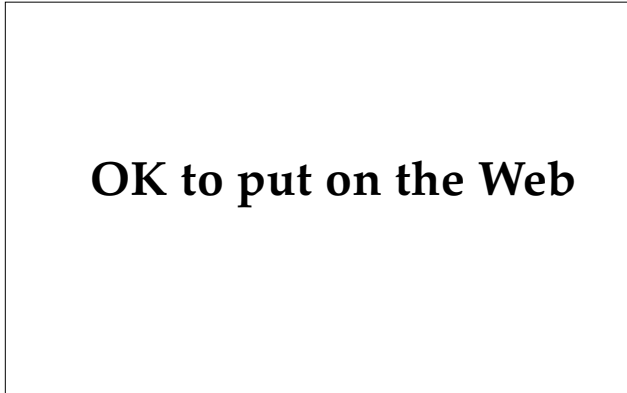
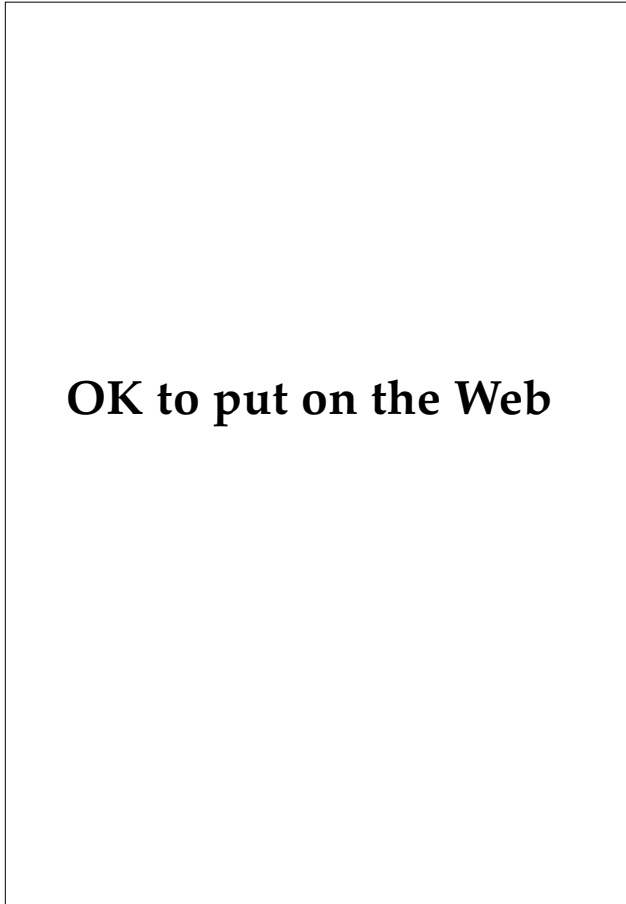
**Fig. 5-5.** A Japanese nuclear casualty with thermal burns caused by the initial fireball. Note the lack of burns on the upper scalp and forehead (a) secondary to the protective effect of the cap (b). Photograph: Courtesy of the Defense Nuclear Agency, Washington, D.C.

diation dose (Figure 5-8).<sup>22</sup> At doses greater than 100 to 150 rads, patients typically develop the radiation hematopoietic syndrome, which, after a latent period of 2 to 3 weeks, is manifested by bone marrow suppression, cutaneous and internal hemorrhage, and immunosuppression. Between 400 and 1,000 rads, the gastrointestinal syndrome occurs. This syndrome consists of edema, pseudomembrane formation in the gastrointestinal tract, and submucosal hemorrhage in the bowel and is accompanied by prolonged nausea, vomiting, watery diarrhea, shock, and death. Above 1,000 to 2,000 rads, casualties are likely to develop the cardiovascular/central nervous system (CNS) syndrome, which is invariably fatal. In this syndrome, CNS symptoms can occur within minutes, culminating in confusion, prostration, seizures, and coma. Patients with this syndrome typically die in shock or secondary to CNS complications.

With doses of less than 100 rads, the skin is

essentially unaffected. At doses of 100 to 200 rads, a transitory erythema can occur within minutes and last 2 to 3 days.<sup>23</sup> This erythema is thought to be caused by vascular dilation secondary to the release of histamine and other vasoactive peptides. Then a deeper erythema develops around day 7 and lasts through day 14. The subsequent scaling, suggestive of a sunburn and hyperpigmentation, appears 14 to 21 days after radiation exposure in many cases. Doses of 200 to 1,000 rads typically produce epilation at approximately 1 to 3 weeks that at the lower doses (100–300 rads) is transient, and at doses greater than 700 rads is permanent.<sup>24</sup> The onset of epilation can be an indicator of radiation dose because higher doses induce earlier epilation.<sup>25</sup> In the 700-rad range, the number of casualties will be significant.

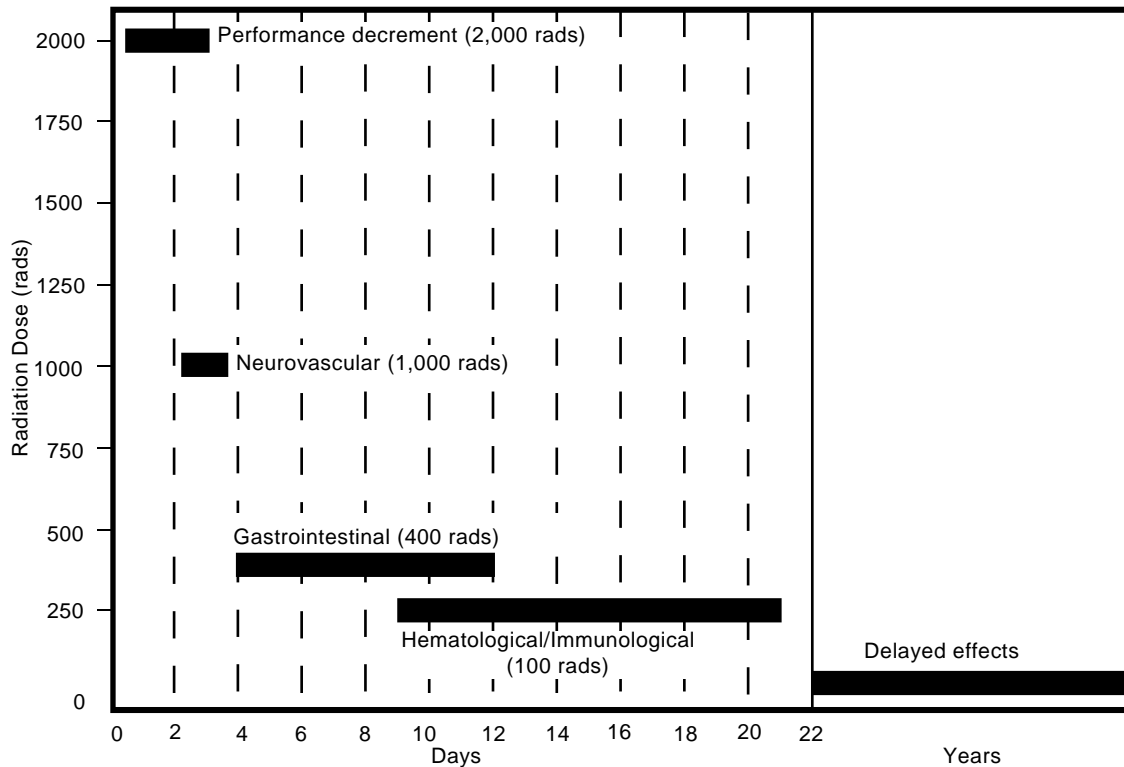
In case reports in which patients received high doses of radiation (4,000–8,000 rads), patients describe an acute burning sensation of their skin. In addition, if the patients survive over several days,



**Fig. 5-6.** ( left) A pattern burn in a Japanese nuclear casualty caused by headgear protection at the time of the atomic bomb fireball. Photograph: Courtesy of the Defense Nuclear Agency, Washington, D.C.

**Fig. 5-7.** (above) Superficial radiation burns caused by beta radiation from nuclear fallout. Photograph: Courtesy of the Defense Nuclear Agency, Washington, D.C.

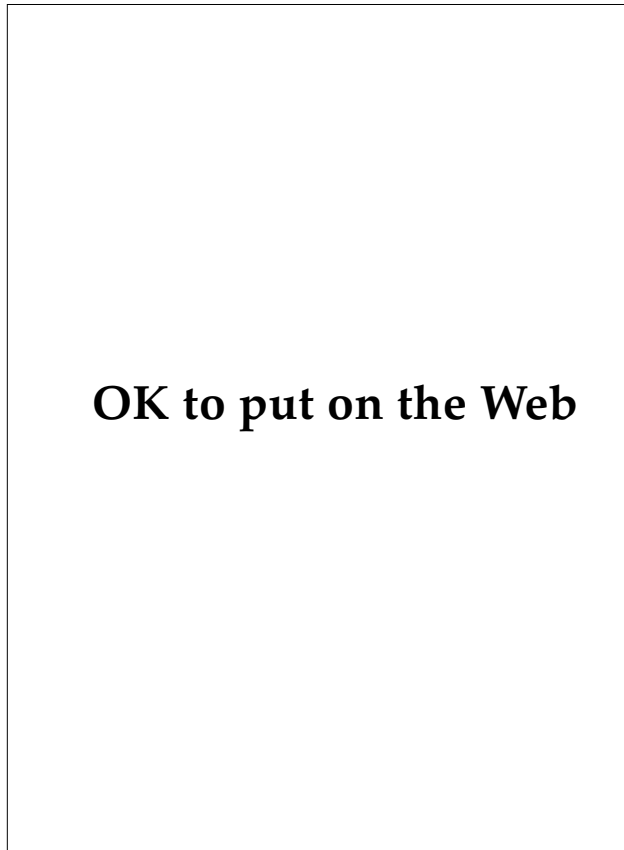
**Fig. 5-8.** (below) The effects of acute radiation exposure. Adapted from Walker RI, Cerveny TJ, Young RW. Acute radiation syndrome in humans. In: Walker RI, Cerveny TJ, eds. *Medical Consequences of Nuclear Warfare. Part I, Vol2.* In: *Textbook of Military Medicine.* Washington, DC: Office of The Surgeon General, US Department of the Army; 1989: 21.



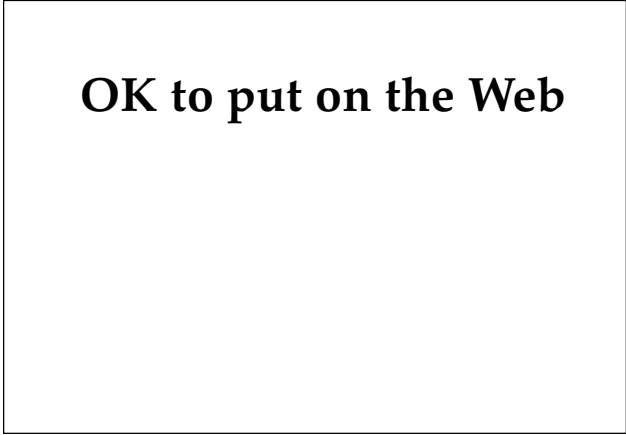vascular damage in the cutaneous tissues can result in diffuse bullae formation over the exposed skin surfaces (Figures 5-9 and 5-10).<sup>26</sup> The histological picture of skin exposed to high doses of radiation consists of keratinocyte damage with pyknotic nuclei, severe dermal edema, and subepidermal vesicle formation.<sup>23</sup> With higher doses, endothelial cell swelling, intravascular thrombi, and fibrosis can be seen.<sup>23</sup>

Skin manifestations that occur over weeks to months, in addition to those noted above, include<sup>25</sup>

- late erythema that occurs after 6 to 8 months and is associated with vasculitis, edema, and pain;
- moist desquamation that is usually manifest at the 3-week period with doses of 1,200 to 2,000 rads; and
- necrosis with onset at a few weeks to months, accompanied by fibrosis, atrophy, and vascular proliferation (Figures 5-11 and 5-12);



**Fig. 5-9.** Bullae on the hands of a Los Alamos nuclear accident victim 24 days after exposure. Photograph: Courtesy of the Defense Nuclear Agency, Washington, D.C.



**Fig. 5-10.** Bullae on the hands of an individual involved in a nuclear incident in which he received a 1,000-rad dose. The patient developed a cardiovascular/central nervous system radiation syndrome secondary to the exposure, and he subsequently died. Photograph: Courtesy of the Defense Nuclear Agency, Washington, D.C.

necrosis occurs at doses of greater than 2,500 rads.

The systemic effects of ionizing radiation can also manifest cutaneously. At doses of greater than 100 rads, depletion of the platelets and their precursors can cause cutaneous petechiae and hemorrhage. Bone marrow damage can also cause immunosuppression, which could lead to increased skin infections.

The patient who survives the acute phase of radiation exposure is at increased risk for chronic radiation dermatitis and cutaneous neoplasms (delayed effects).

#### Therapy of Cutaneous Radiation Injury

Participation of dermatologists in the treatment of thermal injuries after a strategic nuclear encounter will be, of necessity, significant. Overwhelming numbers of casualties will quickly saturate the capabilities of surgical personnel, leaving others to care for the burn victims who do not need intensive surgical or burn care. Dermatologists, with their broad experience in and knowledge of skin pathophysiology, will be uniquely qualified to care for this type of casualty.

Treatment for the cutaneous effects of ionizing radiation remains largely symptomatic. The initial step in caring for these patients is decontamination. Fallout particles can cause superficial burns to the

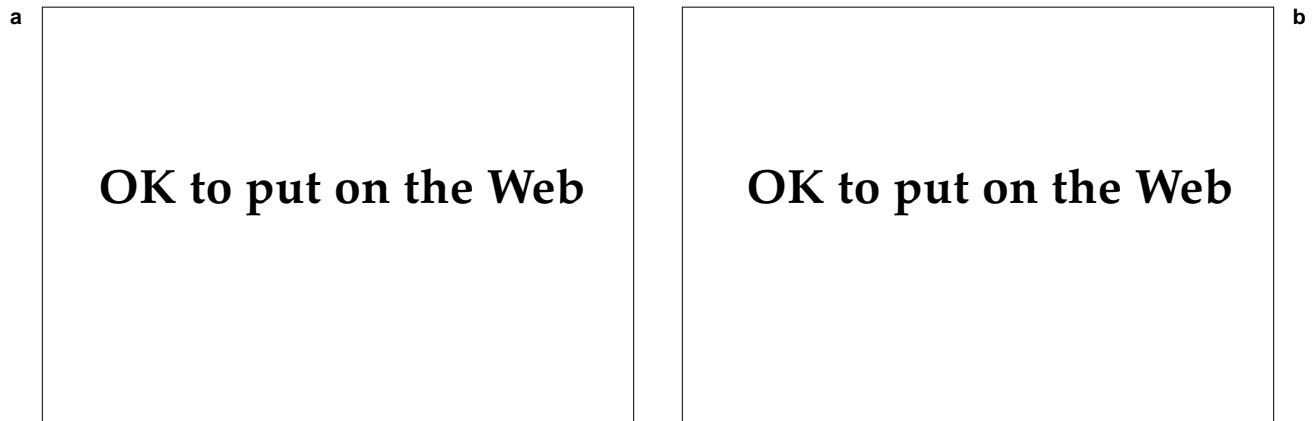


Fig. 5-11. Two cases of chronic radiation necrosis, ulceration, and scarring secondary to radiation therapy for breast cancer.

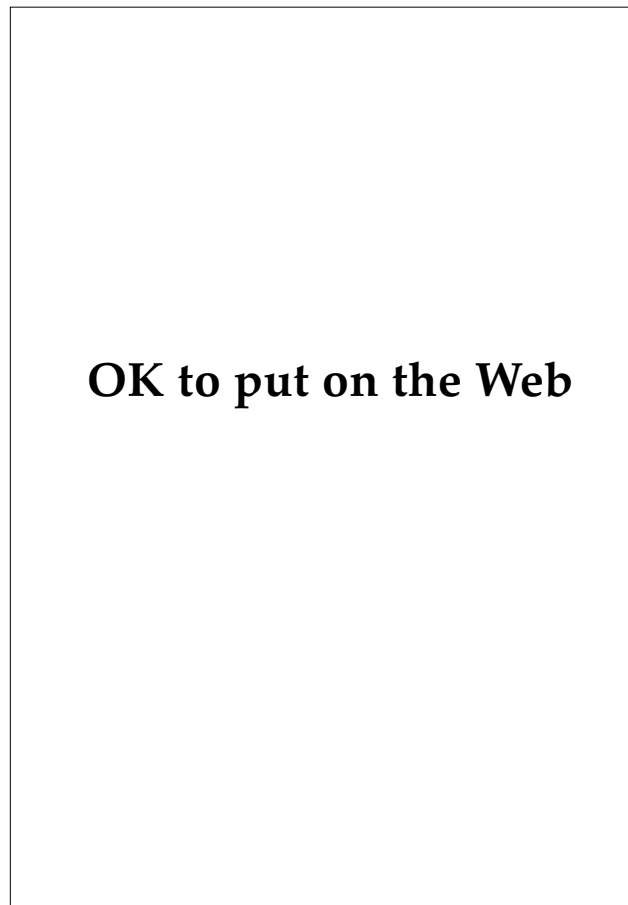


Fig. 5-12. Chronic telangiectasia, scarring, and pigmentary changes of the skin following radiation therapy.

skin but pose a relatively minimal risk for systemic problems. Of importance to medical personnel is the fact that patient contamination poses little risk to them and should not hinder appropriate lifesaving measures in an emergent situation.<sup>27</sup>

After decontamination, care of acute radiation injuries should consist of gentle cleansing and washing of denuded blisters and superficial and deep ulcerations. As with burns, frequent changes of sterile dressings and silver sulfadiazine and mafenide antibiotic creams are useful in the inhibition of local bacterial infections. Careful monitoring for signs of local and systemic infections is paramount because these patients are often immunosuppressed and are at increased risk for the development of infection.

Because of the damage to the mucosal barrier of the gastrointestinal tract secondary to the radiation, these patients are particularly susceptible to enteric pathogens. For this reason, it has been recommended that nonabsorbable antibiotics be given to decrease the intestinal flora.<sup>24</sup> In addition, fevers of unknown origin should be treated immediately with broad-spectrum antibiotics that cover *Enterobacteriaceae* and *Bacteroides fragilis*. In radiation patients who exhibit an increased potential for Gram-negative organisms as well as avascular ulcerations, ciprofloxacin offers coverage for cutaneous infections with many Gram-negative organisms including *Enterobacter* and *Pseudomonas* species, and moderate coverage for *Staphylococcus* species, especially those that are methicillin resistant.<sup>28</sup>

Hydrogel and hydrocolloid gel dressings such as Vigilon (manufactured by C.R. Bard, Inc., Murray Hill, N.J.) and DuoDERM (manufactured by ConvaTec, Princeton, N.J.) may decrease wound

discomfort and wound healing time in radiation ulcers and should be considered, if available.<sup>29</sup>

Surgical treatment of chronic, painful nonhealing ulcers is often necessary in patients exposed to radiation doses greater than 1,000 rads. Surgical debridement of necrotic tissue, early treatment of cutaneous infections, and grafting are essential to ensure optimal healing.<sup>30</sup> Because the ulcer base often has a compromised blood supply secondary to vascular damage, the use of pedicled flaps that have an intrinsic blood supply may offer an improved recovery (lower graft-failure rate).<sup>31</sup>

Over the past decade, there has been increased study of drugs with an apparent systemic radioprotective effect. Animal studies of sulfhydryl drugs such as cysteamine (MEA) have demonstrated that both systemic and topically applied sulfhydryl drugs exert a significant radioprotective effect (taken either prophylactically or shortly after exposure) for acute and late sequelae of radiation exposure.<sup>32</sup> Histological examination of the animals receiving MEA at the time of irradiation demonstrated that fewer vascular abnormalities existed than in nonprotected animals. This finding suggests that both acute and late skin changes may be, in part, due to vascular damage. A study of radiation therapy patients who received the hemorrhagic drug pentoxifylline demonstrated significantly shortened healing time of skin ulcerations and duration of pain.<sup>33</sup> This study also suggests that drugs that act to maintain blood flow to irradiated skin help the healing process.

Another drug found to exert a protective effect on animal tissue is cuprozinic-superoxide dismutase (CSD).<sup>34</sup> Treatment with CSD reduces the bone marrow cell toxicity from irradiation in mice by a factor of two. The exact mechanism by which CSD protects the cell is unclear, but studies have demonstrated that it inhibits the action of poly(ADP [adenosine diphosphate]-ribose) synthetase, which is activated by DNA strand breaks.<sup>35,36</sup> Poly(ADP-ribose) synthetase, when upregulated by breaks in the DNA, depletes the cellular NAD (nicotinamide adenine dinucleotide) and thereby deprives the cell of substrates to produce ATP (adenosine triphosphate), which is necessary for cell function.<sup>36</sup> Further studies of CSD will be needed to determine its efficacy in humans. Other researchers have used cytokines to stimulate bone marrow precursors in radiation syndrome patients. Interleukin- (IL) 1, alone and in combination with tumor necrosis factor, IL-6, and colony stimulating factors, has promoted recovery in irradiated mice.<sup>37</sup> In eight patients with bone marrow failure due to cesium 137

exposure, the use of granulocyte-macrophage stimulating factor resulted in a prompt increase in bone marrow granulocytes.<sup>38</sup> Other drugs that are available and may have some beneficial effect on the course of radiation-induced skin injuries include the antioxidants such as ascorbic acid,  $\alpha$ -tocopherol, and butylated hydroxyanisole (BHA).<sup>39</sup>

### Late Sequelae of Radiation Exposure

Radiodermatitis and an increased propensity for cutaneous neoplasms are the late sequelae of radiation exposure. The onset of radiodermatitis is dependent on several variables including type of radiation, total dose, duration of dose, and density of radiation. Most of the clinical experience with the cutaneous effects of radiation has been with patients who have received radiation therapy. Patients who have received fractionated radiation therapy in the 4,000 to 6,000 rad range experience an acute erythema, blistering, necrosis, and sloughing of tissue, leaving an ulcer that heals slowly or is nonhealing (see Figure 5-11).<sup>23</sup> Fractionation of the radiation dose allows for high doses of radiation to be given with minimal skin damage; therefore, one high-dose exposure can cause significantly more skin damage than a higher dose that is fractionated. Case studies of radiation accident victims, which report that blistering and ulcer formation can occur with as little as 1,000 rads, support this contention.<sup>24</sup> The ulcerations heal with mottled hyper- and hypopigmentation, atrophic scarring, dermal fibrosis, and telangiectasia (see Figure 5-12).<sup>23</sup> Histologically, chronic radiation damage resembles severely actinically damaged skin, with epidermal hyperkeratosis, keratinocyte atypia, and elastotic changes in the dermis. In addition, there are dermal vessel changes with thickened walls and thromboses. The appendages, especially sebaceous glands and hair follicles, which are fairly sensitive to ionizing radiation, are often absent.<sup>40</sup> Skin cancers arising in radiation dermatitis include both squamous cell and basal cell carcinomas. These tumors tend to be more aggressive than tumors arising from skin not affected by ionizing radiation.<sup>40</sup>

The therapy of chronic radiation sequelae of the skin is largely palliative. The treatment of chronic ulcerations due to ionizing radiation is excision and graft placement.<sup>30</sup> The vascular changes of vessel wall thickening and thrombosis secondary to ionizing radiation exposure often lead to ischemia, poor healing, and increased chance of infection. Cell culture studies of fibroblasts exposed to ionizing radiation have demonstrated that irradiated fibroblasts have a

significantly prolonged generation time when compared to normal fibroblasts.<sup>41</sup> Therefore, it is important to remove all ischemic, necrotic, and infected tissue, including the ulcer bed and the surrounding affected epidermis, to obtain viable margins in which to place a graft.<sup>30</sup> The best graft is that of a pedicled flap from a site distant from the affected area to ensure viability of tissue, or musculocutaneous or muscle flaps with their own blood supply to increase vascularity in the damaged area.<sup>31</sup>

Other problems attendant with skin radiation injuries, especially those with large areas of cutaneous involvement, are severe pain, hepatorenal failure, and encephalopathic coma. These problems were especially prevalent during the Chernobyl nuclear reactor disaster in 1986.<sup>42</sup> Therapy for these patients consists of plasmapheresis for the hepatorenal failure and analgesics including antiinflammatory drugs and narcotics for the pain.

## BIOLOGICAL WARFARE

Biological weapons, perhaps the most feared tools of war, are potentially much more destructive than any other nonnuclear munitions.<sup>43</sup> In a U.S. Army manual prepared for Operation Desert Shield, biological warfare was defined as "the use of microorganisms or toxins derived from living organisms to produce death or disease in humans, animals, or plants."<sup>44(p74)</sup> Some authorities have broadened the concept of biological warfare to include herbicides, defoliants, and other biologically active substances. Others define biological warfare more narrowly and exclude toxins because they are active outside their organism of origin. Two international agreements relate to the use of biological weapons in war: one that prohibits first use of chemical and bacteriological weapons in war (1925 Geneva Protocol) and another that prohibits the development, production, and stockpiling of biological and toxin weapons (Biological and Toxin Weapons Convention of 1972).<sup>45</sup> Despite these international agreements and widespread moral disapproval of the use of biological weapons, they have existed for many years, and there is continued evidence of development and production of biological weapons by the former Soviet Union and other countries.

A number of features make biological weapons attractive.

- Compared to other types of munitions, production costs are low.
- International monitoring of production is difficult.
- They are well suited for secret warfare operations.
- They are selective in their effects on the enemy: while biological weapons preserve industrial complexes, supply routes, and other military facilities, enemy personnel are either incapacitated or killed.

- Specific agents can be selected to achieve a high fatality rate, or to cause a high morbidity rate with a relatively low fatality rate, depending on the military objectives.
- Biological weapons may be used for both strategic and tactical objectives.

A number of criteria are used to select specific agents for use in biological warfare. One characteristic that makes an agent particularly attractive as a biological weapon is its ability to be aerosolized, especially if a particle size of 1.0 to 5.0  $\mu\text{m}$  can be achieved. At this size, the agent generally is invisible and can also reach the lower parts of the respiratory tract (small bronchi, bronchioli, and alveoli). Resistance to environmental conditions, such as sun, heat, or cold, as well as to usual disinfectant agents, is also a desired characteristic. Preferred agents are highly virulent and able to produce severe illness, and are resistant to the usual chemotherapeutic agents. For production purposes, the ability to propagate the agent easily and to preserve it, particularly by lyophilization, is desired. Lastly, agents that produce atypical biological actions, particularly in the form in which they are delivered militarily (eg, anthrax by aerosolization) lead to difficulty in differential diagnosis and thus are also desirable. Agents currently believed to be fully developed as biological weapons that produce some dermatologic signs or symptoms include anthrax, tularemia, plague, hemorrhagic fevers, botulism, and mycotoxins.

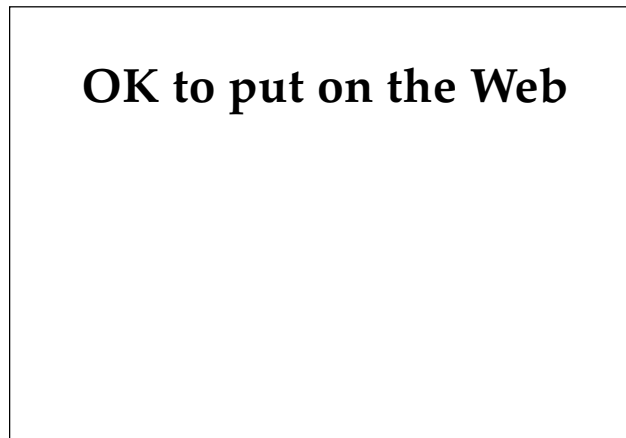
### Anthrax

Anthrax is caused by *Bacillus anthracis*, a large Gram-positive rod, either aerobic or anaerobic, that is nonhemolytic, encapsulated, and capable of forming spores. The toxin produced by *B anthracis* is

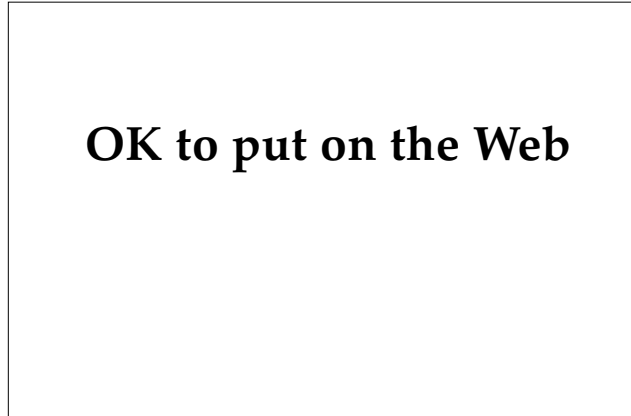
complex and includes three separate soluble proteins called protective antigen, edema factor, and lethal factor. All three have been purified, characterized, and their structural genes cloned and sequenced. A fragment of protective antigen binds to the membrane of target cells and serves as a specific receptor for edema factor or lethal factor, allowing entry of either factor by receptor-mediated endocytosis. Edema factor is a calmodulin-dependent adenylate cyclase, expressed only in target cells that provide the required calmodulin activator and ATP substrate, which is converted to cyclic AMP (adenosine monophosphate). The biological effects of edema factor, edema and inhibition of phagocytosis by polymorphonuclear leukocytes, are believed to be due to the actions of cyclic AMP in the intoxicated cells. The mechanism of action of lethal factor is unknown.<sup>46</sup> The usual source of human disease from *B anthracis* is contact with infected animals or contaminated animal products, usually manifested initially by cutaneous lesions. When used as a biological warfare weapon, the method of delivery would most likely be via aerosol, producing inhalation anthrax, a rare form of the naturally occurring disease, with a mortality rate approaching 100%. The skin and the gastrointestinal tract are other possible portals of entry when *B anthracis* is used as a biological weapon.

#### *Cutaneous Findings*

When the skin is the portal of entry, the characteristic finding in anthrax is a macule that progresses



**Fig. 5-13.** Large necrotic lesion of cutaneous anthrax. Photograph: Courtesy of Armed Forces Institute of Pathology, Washington, D.C.



**Fig. 5-14.** Cutaneous anthrax. Photograph: Courtesy of Armed Forces Institute of Pathology, Washington, D.C.

through papular, vesicular, or pustular stages leading to an ulcer with a blackened, necrotic eschar and surrounding, nonpitting, gelatinous, and painless edema (Figures 5-13 and 5-14). The lesion usually occurs on an exposed surface. Satellite vesicles may surround the lesion. Painful regional lymphadenitis is common. Pruritus may be an early symptom; however, advanced lesions are often asymptomatic.

#### *Other Clinical Findings*

The majority of patients with cutaneous anthrax do not have systemic symptoms; however, severe edema and septic shock may occur. Anthrax meningitis occurs rarely. If it is acquired via the gastrointestinal tract, symptoms include abdominal pain, enteritis, ascites, bloody diarrhea, fever, and nausea and vomiting. Usually, mesenteric adenitis is present. Oropharyngeal anthrax is associated with fever, sore throat, dysphagia, and, occasionally, respiratory distress. The most severe form of anthrax is acquired via inhalation, with fulminant pneumonitis and hemorrhagic mediastinitis the characteristic features.

#### *Diagnosis*

Gram's stains or cultures from cutaneous anthrax lesions usually yield *B anthracis*. Blood, pleural fluid, and cerebrospinal fluid may also be positive using routine culture techniques. Impression smears of mediastinal lymph nodes and spleen as well as smears from pleural and cerebrospinal fluid should be positive by Gram's or Giemsa stains. Direct fluorescent antibody staining of tissues is

available. Lastly, anthrax toxin may be detected in the blood by immunoassays.

### **Treatment**

Penicillin G, 2 million units every 6 hours until edema subsides, followed by a 7- to 10-day course of oral penicillin is the recommended therapy for cutaneous anthrax, with erythromycin, tetracycline, or even chloramphenicol used in adults unable to take penicillin. For gastrointestinal or inhalation anthrax, high-dose penicillin G, 2 million units every 2 hours, is recommended. Specific therapy recommended in a primer developed for medical personnel involved in Operation Desert Shield includes ciprofloxacin 1,000 mg initially, followed by 750 mg by mouth twice daily, or intravenous doxycycline, 200 mg initially, followed by 100 mg every 12 hours. The duration of these regimens should be dictated by symptoms. Supportive therapy for shock and respiratory compromise may also be needed.

### **Prophylaxis**

A vaccine consisting of purified protective antigen has been developed, with limited data from human studies suggesting that protection against both cutaneous and inhalation anthrax occurs with doses given at 0, 2, and 4 weeks, and then at 6, 12, and 18 months. Animal studies suggest that good protection lasting 2 years may be afforded after just two doses, 10 to 16 days apart.<sup>44</sup> Live, attenuated spore vaccines are used for both animals and humans in the former Soviet Union.

Prophylaxis with antibiotics, specifically ciprofloxacin (500 mg by mouth twice daily) or doxycycline (100 mg by mouth twice daily), has been suggested if information is received that a biological weapon attack is imminent.<sup>44</sup>

### **Military Significance**

Anthrax has many characteristics that make it a good choice as a biological weapon. It can be produced very quickly in almost unlimited quantities, and it produces a spore form that is highly resistant to heat, disinfectants, sunlight, and other environmental factors. It can be delivered in wet or dry form and produces an aerosol of optimum size. Although high numbers of spores are required to kill 50% of exposed individuals (the LD<sub>50</sub> [median lethal dose] is between 8,000 and 10,000), such

doses would not be difficult to deliver using currently available techniques.<sup>45</sup> An outbreak of anthrax in the Soviet Union city of Sverdlovsk in April 1979 is regarded by the United States as an accidental release of dry anthrax spores, presumably from an explosion within the Microbiology and Virology Institute, a military facility. Although the official Soviet explanation for this incident was that anthrax-contaminated meat was the cause of the outbreak, an analysis by the United States suggests this incident was the result of an accident within a biological warfare facility.<sup>45</sup>

### **Tularemia**

Tularemia is caused by *Francisella tularensis*, a small, Gram-negative, pleomorphic, bipolar rod. Under ordinary conditions, the disease is acquired by contact with infected animals or via an insect vector. Delivery by aerosol would be the likely method for tularemia used as a biological weapon, causing typhoidal tularemia. For a further discussion of tularemia, see Chapter 13, Bacterial Skin Diseases.

### **Plague**

Plague is caused by *Yersinia pestis*, a Gram-negative bacillus with pleomorphic or coccoid variants. The disease is usually acquired by skin inoculation via a flea bite or through direct animal contact. When used as a weapon of biological warfare, an aerosol would most likely be the method used. For a detailed discussion of plague, see Chapter 13, Bacterial Skin Diseases.

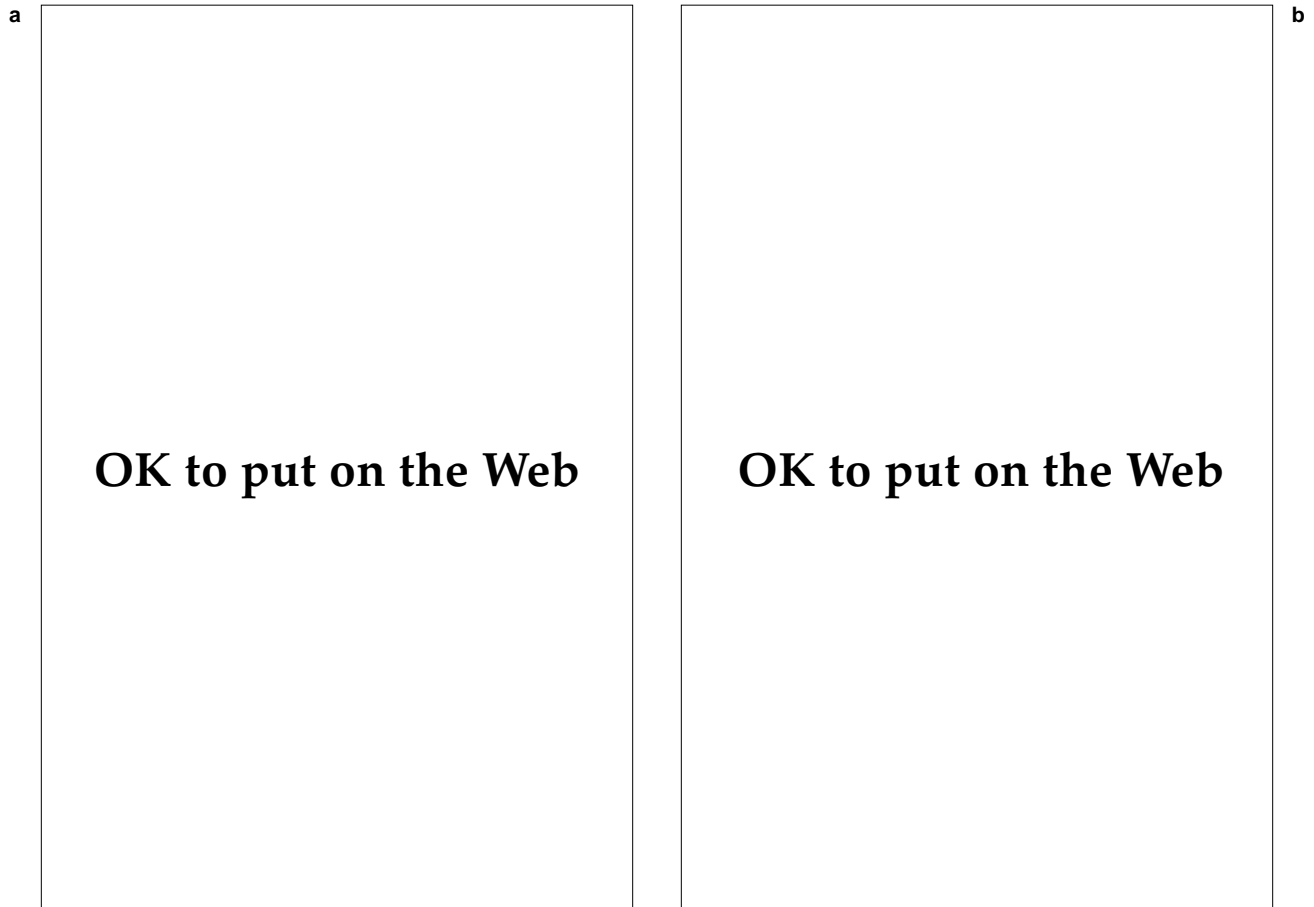
### **Hemorrhagic Fevers**

Hemorrhagic fevers include a number of viral infections, such as the Marburg virus and Lassa and Ebola fevers. All the viruses in this group are highly infectious. The clinical picture is similar for many of these diseases. A more complete discussion can be found in Chapter 10, Viral Hemorrhagic Fevers.

### **Cutaneous and Other Clinical Findings**

The cutaneous eruptions seen with the hemorrhagic fevers have been described as maculopapular in nature, becoming petechial with time. A generalized erythema may be present (Figure 5-15). Extensive purpura may develop (Figure 5-16).





**Fig. 5-15.** (a) The scarlatiniform eruption and (b) the characteristic blanching that occur in the scarlatiniform type of dengue fever. Photograph: Courtesy of U.S. Army Medical Research Institute of Infectious Diseases, Frederick, Md.

Mucous membranes may be involved, with blisters leading to ulcerations as well as petechiae and hemorrhages (Figures 5-17 and 5-18). Conjunctivitis may also be seen.

Hemorrhagic fevers usually begin with a flulike syndrome following a 3- to 10-day incubation period. Deterioration often occurs about the third day after symptoms begin, with high fever, weakness, nausea, vomiting, diarrhea, headache, chest pain, joint pains, and an eruption. Bleeding may be a significant problem, and death secondary to shock may occur in as many as 50% of patients.<sup>47</sup>

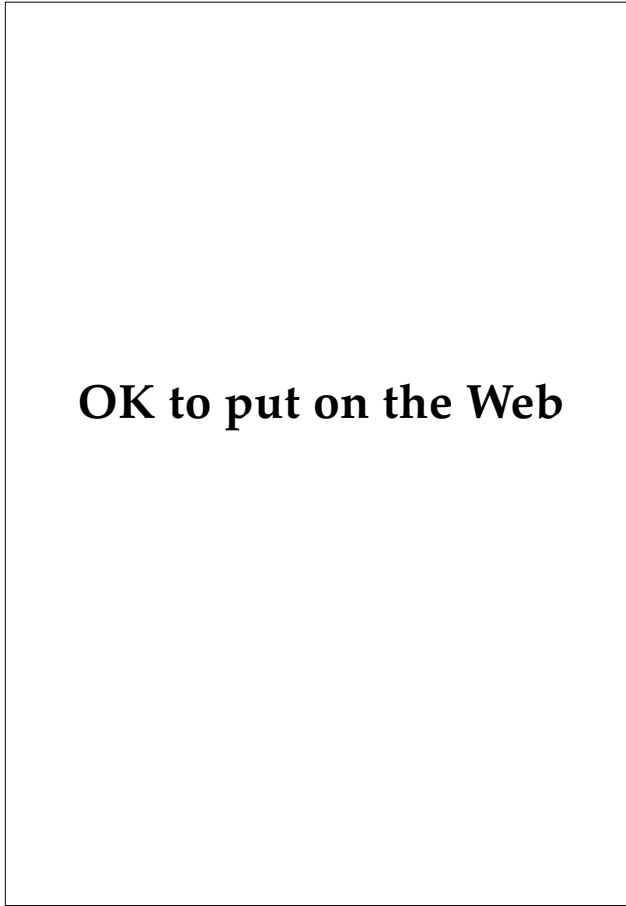
### **Diagnosis**

Definitive diagnosis of hemorrhagic fevers may be difficult; however, the virus may be identified using electron microscopy or fluorescent microscopy on peripheral blood or cell cultures. Serologic tests by enzyme-linked immunosorbent assay

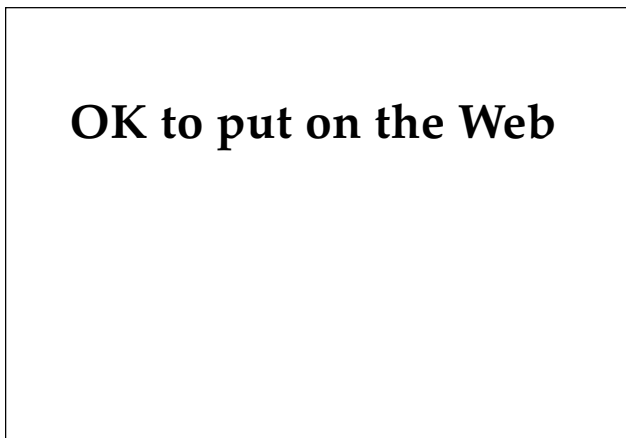
(ELISA) or hemagglutination are available in some cases. Clinical criteria for dengue hemorrhagic fever have been established by the World Health Organization.

### **Treatment**

Currently, treatment of hemorrhagic fevers consists of symptomatic support. Control of hemorrhagic diathesis and fluid and electrolyte management are particularly important. Use of convalescent serum has been helpful in isolated cases but would not be practical for mass casualties. Ribavirin might be useful in the treatment of viral hemorrhagic fevers, including Crimean-Congo hemorrhagic fever. The dose of ribavirin recommended is 400 mg by mouth every 4 hours for 24 hours, then 400 mg by mouth every 8 hours for 7 to 10 days or, if given intravenously, a 2-g loading dose, then 1 g every 8 hours for 4 days, then 500 mg every 8 hours for 6



**Fig. 5-16.** Large purpuric lesion in a hemorrhagic fever patient. Photograph: Courtesy of U.S. Army Medical Research Institute of Infectious Diseases, Frederick, Md.



**Fig. 5-17.** Gingival petechiae characteristically seen in cases of Argentine and Bolivian hemorrhagic fever. Photograph: Courtesy of U.S. Army Medical Research Institute of Infectious Diseases, Frederick, Md.

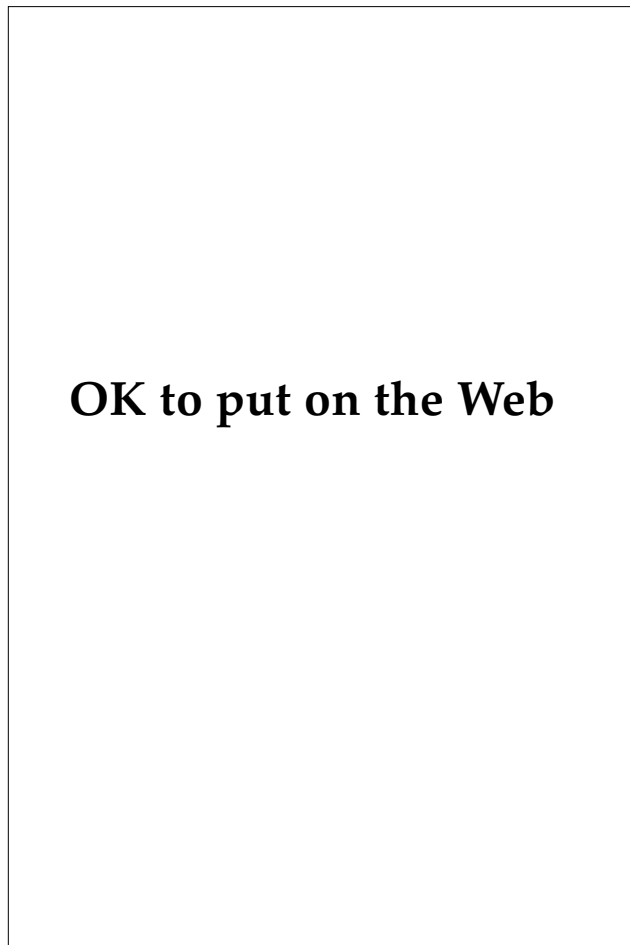
days. When given intravenously, ribavirin should be diluted in saline or 5% dextrose in water and should be administered over 15 to 20 minutes. Strict isolation of affected individuals is mandatory and should include contact, body fluids, blood, and respiratory isolation.<sup>44</sup>

### *Prophylaxis*

A number of vaccines for the hemorrhagic fevers have been studied, with none currently licensed for use in humans.

### *Military Significance*

The hemorrhagic fevers fulfill many of the criteria for effective biological agents including stability



**Fig. 5-18.** The characteristic petechial lesions of the soft palate, which are seen in several hemorrhagic fevers. Photograph: Courtesy of U.S. Army Medical Research Institute of Infectious Diseases, Frederick, Md.

in aerosol form, high virulence and the ability to produce severe illness, and the absence of specific prophylactic measures or specific treatments for the disease produced.

### Botulism

Botulism refers to the disease produced by the potent neurotoxins of the organism *Clostridium botulinum*. *C botulinum* is a Gram-positive, incompletely aerobic, spore-forming bacillus. Its neurotoxins are large proteins of molecular weight approximately 150,000 daltons, and are identified by their antigenic specificities as types A, B, C, D, E, F, and G. Their toxic effects are due to inhibition of acetylcholine release from cholinergic terminals at the motor end plate.<sup>48</sup> Human disease occurs after ingestion of preformed toxin (food poisoning), by enteric production and subsequent absorption of toxin (infant botulism, shaky foal disease, adult sudden death), or via absorption from infected wounds. It is speculated that the most likely method of delivering botulism via weapons would be by aerosolization of alpha toxin, a highly toxic phospholipase C.

### Cutaneous and Other Clinical Findings

Dry mucous membranes, with extreme dryness of the mouth, perhaps with crusting, are the only mucocutaneous findings in clostridial food poisoning; dilated pupils and a clear sensorium are seen; gastrointestinal symptoms are variable. Sensory functions are intact, but cranial nerve weakness and descending peripheral motor weakness progressing to paralysis occurs, which may result in respiratory failure. In infant botulism, feeding problems from cranial nerve weakness, altered cry, hypotonia, poor head control, and constipation are seen. Wound botulism results in disease similar to that seen in clostridial food poisoning. No information is available on the precise toxic effects of inhalation botulism; however, it is presumed to result in a serious pulmonary insult, with associated vascular leak, hemolysis, thrombocytopenia, and liver damage.<sup>44</sup>

### Diagnosis

The clostridial enterotoxin can be detected in fecal samples, vomitus, or gastric fluid from individuals with clostridial food poisoning. An animal bioassay is available for detection of toxin in serum but may be falsely negative.

### Treatment

In addition to supportive care for cranial nerve paralysis, respiratory failure, and autonomic dysfunction, an equine antitoxin is available, and a human pentavalent antitoxin is being tested in the treatment of botulism.<sup>44</sup> Attempts to remove remaining toxin from the gastrointestinal tract may be helpful, as well as antibiotics.

### Prophylaxis

A pentavalent toxoid of *C botulinum* types A, B, C, D, and E is currently being tested. This toxoid is not yet available for general prophylactic use.<sup>44</sup>

### Military Significance

Botulinum toxins are dangerous as biological warfare agents because they produce illness with a high mortality rate. The toxins are readily available and are relatively stable, resisting degradation by acid and proteolytic enzymes, and requiring heating to 100°C for 10 minutes for inactivation. They can be delivered in aerosol form. In addition to being highly lethal, those individuals who survive botulism intoxication often require several weeks of convalescence; thus, effects on troop strength are potentially very serious.

### Mycotoxins

Mycotoxins are toxins produced by many strains of fungi that grow on food products and produce toxic effects in animals and people exposed to them. Mass outbreaks of disease in animals caused by moldy foods have been documented in animals and humans. The only human outbreak with extensive documentation occurred in the USSR during the later years of World War II, producing a syndrome termed alimentary toxic aleukia, a panleukopenia.<sup>49</sup> Interest in mycotoxins has increased in recent years due to reports of their use as biological warfare agents in various regions of the world, including Southeast Asia and Afghanistan.<sup>50-54</sup> Trichothecene mycotoxins are a family of sesquiterpenes, all derived from a trichothecene ring system (Figure 5-19). They are insoluble in water, but can be solubilized in lipids, propylene glycol, and dimethyl sulfoxide (DMSO). They are produced by many species of molds in the genera *Fusarium*, *Myrothecium*, *Trichothecium*, *Trichoderma*, and *Cephalosporium*. They produce a wide range of toxic effects in ani-

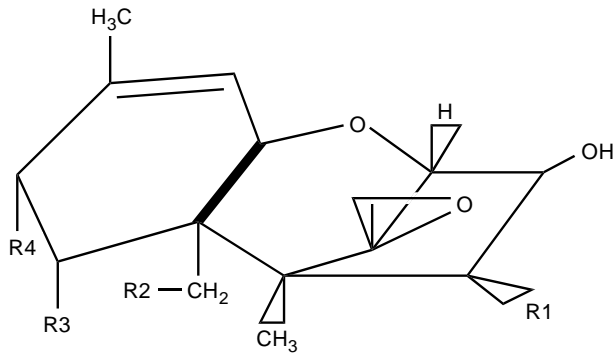


Fig. 5-19. Diagram of the basic trichothecene ring.

mals, depending on dose, specific metabolites present, and even the particular combinations of toxins present.<sup>55</sup> The biochemical changes leading to cell death induced by the toxins are not completely known; however, it has been shown that protein synthesis is impaired at the initiation, elongation, and termination phases, and marked polysomal disaggregation is evident.<sup>49,56</sup> It is believed that trichothecene mycotoxins are very potent inhibitors of protein synthesis in eukaryotic cells.<sup>56</sup> The most toxic trichothecene toxin identified is called T-2 toxin. Others include deoxynivalenol (DON, also called vomitoxin), diacetoxyscirpenol (DAS), and zearalenone. Most of the information that follows is derived from the study of the T-2 toxin.

### Cutaneous Findings

Exposure to trichothecene toxins often causes prominent cutaneous findings. Erythema, which may be generalized, occurs within minutes to hours of exposure. It may be accompanied by itching, burning, tingling, or even painful sensations. Eanescent "scattered red spots" have also been reported. Blisters, which may be large, and red papules have also been described. A Red Cross physician described erythematous 5- to 10-mm papules with fine vesicles that developed 6 to 24 hours after exposure as characteristic lesions. The lesions later become black and crusted. When blisters erode or form ulcers, prolonged healing, up to several months, may be noted. In severe cases, large sheets of skin were shed. Alopecia has also been reported, along with necrotic oral ulcers.<sup>57</sup>

### Other Clinical Findings

Severe systemic symptoms, sometimes resulting

in death, have been reported from presumed trichothecene toxin exposure. Extensive bleeding, acute leukopenia, septicemia, and bone marrow function failure may all be seen. Based on evaluation and questioning of presumed victims of trichothecene toxin exposures in Cambodia, Laos, and Afghanistan, the clinical signs and symptoms of trichothecene toxicosis are believed to occur in four stages<sup>56,57</sup>:

1. The initial findings consist of a burning sensation of the skin and mucous membranes, headache, dizziness, weakness, abdominal pain, vomiting and diarrhea, fever, sweating, tachycardia, and cyanosis. This stage may last up to 9 days.
2. Next, from 2 to 4 weeks following exposure, anemia, leukopenia, granulocytopenia, thrombocytopenia, and lymphocytosis are seen, along with symptoms of headache, fatigue, vertigo, and the clinical finding of petechiae.
3. The third stage is not well characterized as to duration and may result in death. Petechiae, focal necrotic lesions, ulcerative pharyngitis, gastrointestinal and mucosal hemorrhage, lymphadenopathy, and progression of hematological abnormalities occur.
4. Lastly, resolution of hemorrhage and necrotic lesions may occur, with slow improvement of hematological abnormalities, and a prolonged risk of infectious complications.

### Diagnosis

The diagnosis of mycotoxin-related disease will be a challenge for medical personnel. The specific signs and symptoms that result from exposure depend on a large number of variables including the specific mycotoxin or mycotoxins involved, the method of delivery, the dose received, the specific vehicle used, the portal of entry into the body, climatic conditions, the use of protective gear, and the nutritional status and general health of the casualty. Because of the large number of variables determining the clinical presentation, the spectrum of disease resulting from exposure to mycotoxins will likely be very broad. Differential diagnosis should include exposure to other toxins, such as the vomiting agents (adamsite, diphenylchloroarsine), mustards, Lewisite, phosgene oxime, and nerve agents.<sup>57</sup> The vomiting agents have a shorter duration of action, about 30 minutes, compared to 1 to 2

days for mycotoxins, and also generally cause less severe vomiting. Mustard agents produce symptoms that are not quite as delayed as with mycotoxins, and less often cause burning, dysesthesias, generalized erythema, or hemorrhagic lesions. Healing following mustard exposure is delayed even longer than that seen after mycotoxin injury. Lastly, mustard generally does not cause hemoptysis, hematemesis, or toxic pulmonary edema. Lewisite may cause many signs and symptoms similar to mycotoxins; however, they occur much sooner, usually within a few minutes of exposure. In addition, hematemesis and other hemorrhagic signs and symptoms are more often seen with mycotoxin exposure than with Lewisite. Phosgene oxime causes immediate effects on the skin and eye, and also causes less hemorrhage than the mycotoxins. With nerve agents, miosis, severe bronchoconstriction, wheezing, hypersecretion, and polyuria are prominent, and skin changes are not seen. Pulmonary edema, massive hemoptysis, and hematemesis are not sequelae of nerve agents.

Although optimal field detection of mycotoxins is not yet available, a number of detection methods have been developed or are under study including radioimmunoassay in biological fluids, gas chromatograph mass spectrometry, polarography, thin-layer chromatography, gas-liquid chromatography, high-performance liquid chromatography, infrared spectroscopy, and nuclear magnetic resonance spectroscopy. The most promising area of development of detection methods is in the use of immune-based systems such as monoclonal antibodies.<sup>57</sup>

### ***Treatment***

Immediate treatment of mycotoxin exposure should include lavage of eyes and skin with any nontoxic liquid. Absorption from the skin is slow; therefore, thorough cleansing with soap and water is very important in limiting the amount of systemic toxin exposure. Wounds should be irrigated with saline or other solutions, blotted with sterile dressings, then managed like other wounds. The U.S. Army's M258 kit, which is used in mustard decontamination, has been found to be unsatisfactory for decontaminating mycotoxins from the skin. Personnel performing the decontamination should wear eye and skin protection. Contaminated water should be considered toxic. Instruments that become contaminated must be handled carefully, because even autoclaving may not eliminate the mycotoxins. If heavy exposure is suspected, stripping of the stratum corneum from the hands and face with tape

may remove a reservoir of mycotoxin, as significant binding to the stratum corneum may occur.

In addition to skin, the bowel may serve as a reservoir for mycotoxins. Toxin is excreted in the bile and subsequently reabsorbed. Emesis is often associated with mycotoxin exposure and probably eliminates some toxin. Activated charcoal, bentonite powder, and cholestyramine given orally may be used to bind the toxin and remove it from the gastrointestinal tract. Once in the circulation, mycotoxins are excreted primarily in urine, so one might consider dialysis or hemoperfusion; however, such treatments have not been adequately studied and may even be contraindicated if coagulopathy or hypotension is present.

Systemic steroids and vitamins A, C, and E are mycotoxin treatments supported by animal studies. If significant skin exposure has occurred, consideration of therapy with microsomal enzyme inducers such as phenobarbital may be reasonable, as this treatment may speed clearance of toxin that is being slowly absorbed.<sup>57</sup>

### ***Prophylaxis***

Standard protective clothing and chemical warfare masks are believed to provide some protection from mycotoxins.<sup>57</sup> In addition, a variety of drugs have been proposed as possible pretreatments for mycotoxin exposure. A number of compounds have been studied in animal models; however, no single pretreatment is known to prevent disease from mycotoxins without causing side effects. Drugs that are proposed as possibly useful include microsomal enzyme-inducing compounds such as phenobarbital; free-radical protectants or antioxidants such as vitamins A, C, and E; membrane-stabilizing drugs such as the systemic steroids; detoxifying compounds such as the thiazolidines; and antimuscarinic drugs such as atropine. In addition, maintaining normal stores of intracellular glutathione may be an important protective measure and could be accomplished by adequate nutrition, avoidance of alcohol, tobacco, and drugs, and possibly by dietary supplementation with D-L methionine.<sup>57</sup> The decision to pretreat troops, and the specific agents employed, will need to be carefully considered in view of the possible adverse effects caused by pretreatment.

### ***Military Significance***

Characteristics of trichothecenes that make them good candidates for biological warfare agents

include their irritating and damaging effects on many organs vital to effective combat, such as the eyes, skin, upper and lower respiratory tracts, mouth, throat, and entire gastrointestinal tract. Effects are also seen in the peripheral and central nervous systems; skeletal and cardiac muscles; and the hematopoietic, clotting, and immune systems. In large doses, death may occur within minutes to hours, whereas smaller doses cause delayed death or incapacitation that may last for days to weeks. As adjuncts to more toxic agents, mycotoxins may irritate the skin enough to prevent wearing of protective gear.<sup>57</sup> Production of mycotoxins is relatively simple, and reports of mycotoxins found

in high concentrations, along with man-made materials such as DMSO, suggest that the incorporation of trichothecenes into weapons has already been successful. It is believed that delivery can be accomplished by aircraft via spraying, dusting, rockets, or dropped exploding containers, as well as artillery and mortar rounds.<sup>57</sup> Trichothecenes are moderately potent, with nanogram levels causing skin erythema. Field detection is not yet reliable. In addition, mycotoxins are persistent, difficult to decontaminate, and have no specific treatment or prophylaxis. Thus, their potential use as biological weapons must be considered a serious threat.

## CHEMICAL WARFARE

The technology for the development of chemical agents is readily available and the manufacture of these agents is relatively simple. Compounding the problem is the willingness of some countries with the technology to manufacture tactical weapons to supply other countries with the arms that are capable of delivering chemical weapons. Reports suggesting that Iraq has produced thousands of tons of sarin, tabun, and mustard gas demonstrate how real the problem has become.<sup>58</sup> Therefore, the likelihood is quite high that one will encounter the use of chemical weapons in future conflicts.

### Chemical Warfare Doctrine and Weaponry

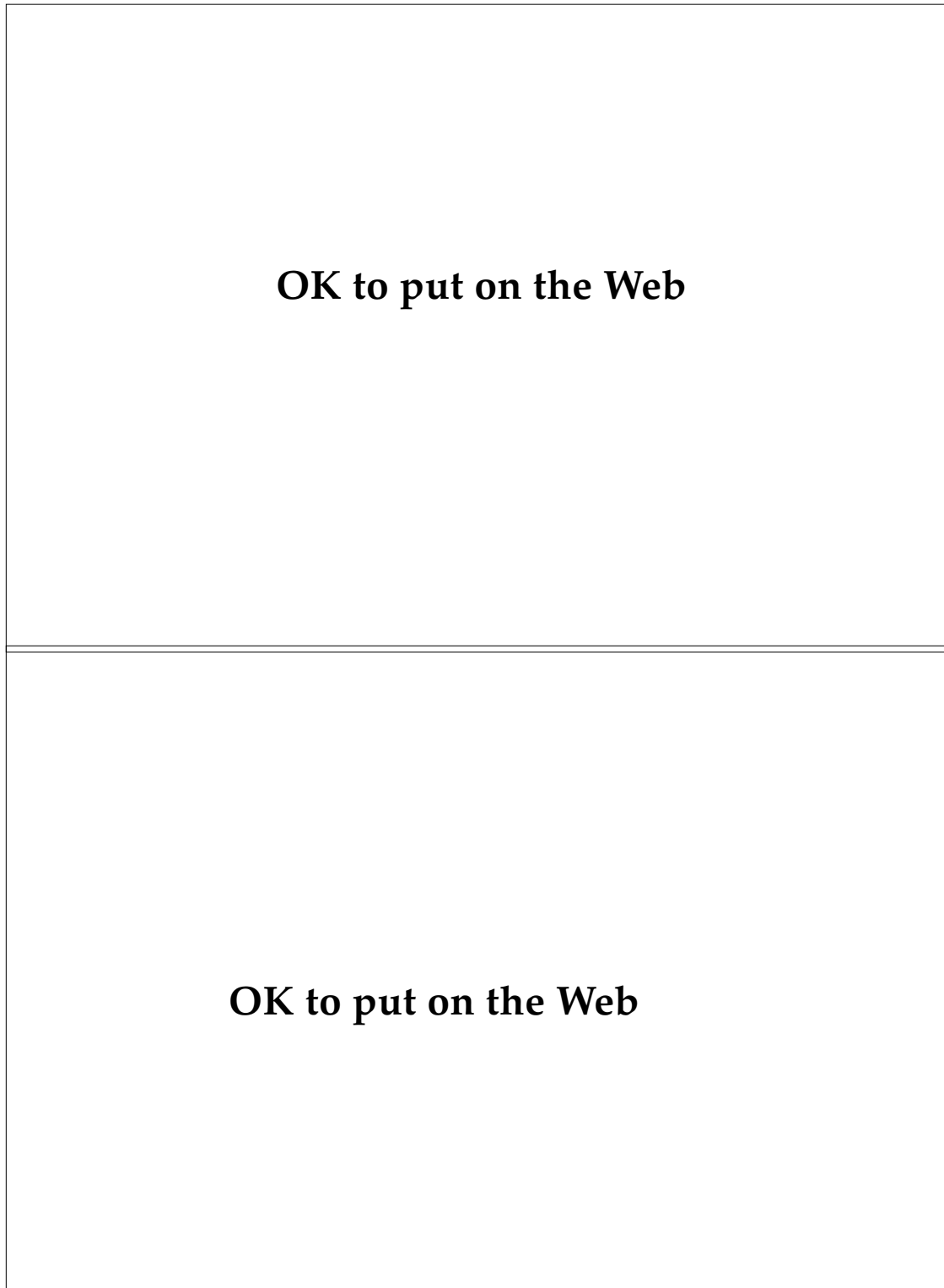
To understand the potential for chemical casualties in modern warfare, one needs to understand why chemicals might be used on the battlefield. Many think that the main purpose for using chemical warfare would be to inflict fatalities; however, close scrutiny of the chemical tactics and doctrine of the former Soviet Union suggests otherwise. Their goal in the use of chemical weapons was to degrade the enemy's combat effectiveness. This feat was accomplished through inflicting nonlethal casualties, denying key terrain, and necessitating the wearing of chemical protective clothing. To accomplish these goals, massive amounts of chemical agents have to be delivered, and it appears that the Soviets acquired both the necessary quantities of agent and the means with which to deliver it.

It is estimated that at one time Soviet chemical munitions consisted of 350,000 tons of various agents that composed up to 20% of the artillery munitions stockpile and 30% of the FROG and Scud rocket warheads.<sup>59</sup> Although this stockpile is now being

rapidly destroyed, substantial amounts will remain, and the possibility that these weapons could fall into the hands of third-world nations or terrorists is strong. Additional means of chemical delivery include the multiple rocket launcher, mortars, aerial sprays, and bombs. In combination, these weapons would be used to degrade our ability to wage war. Figure 5-20 shows the various areas of the battlefield that would be subject to attack. Areas likely to receive persistent chemical agents would include key terrain, necessitating that those positions would either have to be evacuated or the troops in those areas would have to don chemical protective gear and lose a significant portion of their combat effectiveness. The former Soviet doctrine also required the chemical attack of rear areas in which command centers, hospitals, and logistical supply areas are located. This strategy would be well within the capabilities of Soviet-made weapons including the artillery (20-km range), FROG missiles (60-km range, 300-kg payload), the Scud missiles (280-km range, 1,000-kg payload),<sup>15,16</sup> and the FROGGER aircraft. Nearer the forward edge of the battle area, smaller weapons such as mortars could be used. In addition, the multiple rocket launchers of the Soviet Army have been noted for their capacity to deliver large quantities of chemical agents over a company-sized defensive area (Figure 5-21).<sup>59,60</sup> Intelligence estimates suggest that the main chemical threats developed by the former Soviet Union include mustard gas, cyanide gas, and various nerve agents.

### Sulfur Mustard and Nitrogen Mustard

The mustard used in World War I, called sulfur mustard (H), Yperite, or LOST, has a chemical struc-



**Fig. 5-20.** A depiction of a chemical warfare attack based on Soviet tactics. Note the use of persistent agents such as mustard in rear areas where hospitals may be located. Reprinted from US Department of the Army. *Desert Storm*. Washington, DC: DA; 1992. DA PAM S-8.

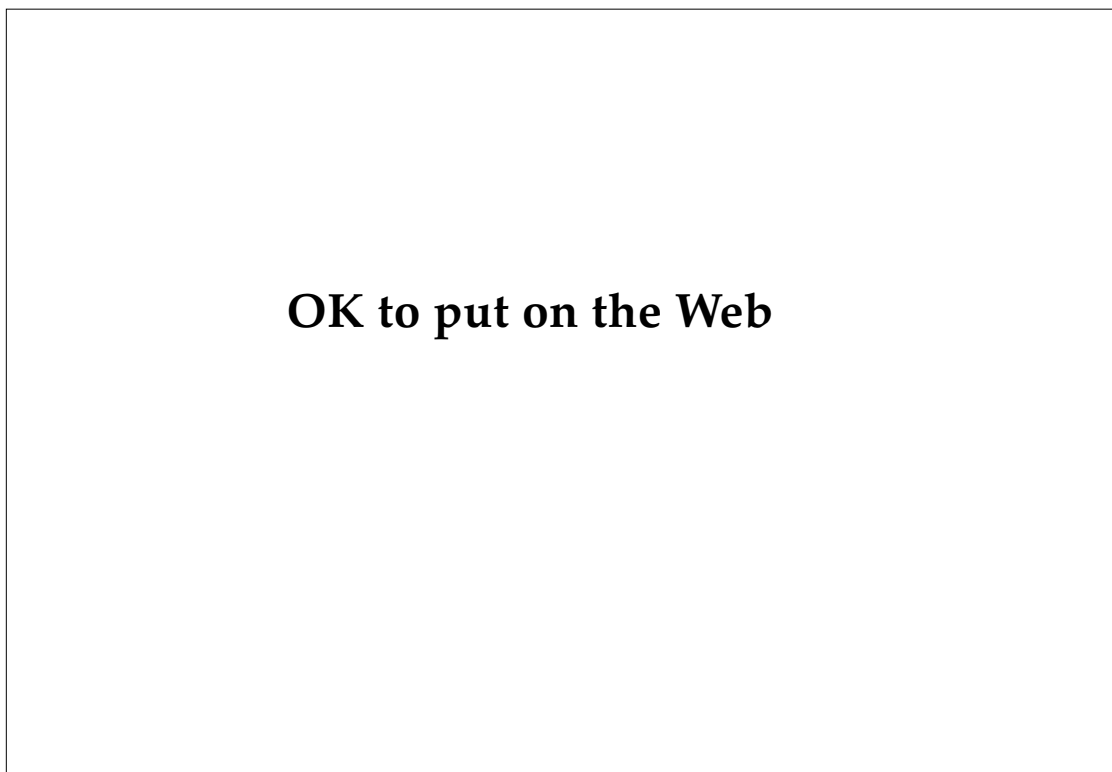
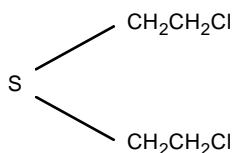
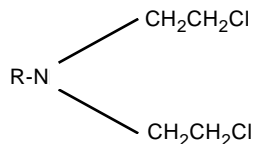


Fig. 5-21. Two Russian-made multiple rocket launchers that were captured from the Iraqi Army during Operation Desert Storm. On the left is the BM-21 122-mm multiple rocket launcher.

ture that contains two reactive chloroethyl bonds, which are reactive with a variety of organic compounds including DNA molecules.<sup>61</sup>



Mechlorethamine, mustargen, or nitrogen mustard (NH) is the alkylating agent used currently as a chemotherapeutic agent. It is a congener of Yperite with a nitrogen substituted for sulfur.



Although nitrogen mustard is considered more toxic and less persistent than sulfur mustard, they have

similar properties that make them useful as chemical weapons:

- Mustard is highly toxic in low concentrations to all organ systems.
- An initial period of latency is exhibited in mustard casualties, which can last from hours to days dependent on the dose of mustard received.
- Mustard has an ability to adhere to fomites such as clothing, weapons, and other personal articles, which can injure individuals such as medical personnel who come in contact with mustard casualties.
- Mustard is highly stable in storage and persistent on the battlefield.
- The density of mustard in vapor form is higher than that of air and therefore mustard will remain stationary and sink into trenches and other protective structures in the delivery area.
- Mustard can be delivered effectively with a variety of weapons.



- Production is simple and relatively inexpensive.
- Mustard casualties typically have a low mortality and a long recuperation, which can overwhelm the capacity of the medical treatment facilities all along the echelons of care.

The mustards are colorless to light yellow viscous liquids that, in high concentrations, smell like garlic or fish. Hydrolysis of mustard, which renders it relatively nontoxic, occurs in water, albeit slowly over hours. The process of hydrolysis can be greatly accelerated by the addition of a strong base or acid; however, the reaction between mustard and concentrated acids can produce high amounts of heat and possibly fire. Therefore, dilute acid solutions should be used in mustard decontamination. Decontamination agents include sodium thiosulfate, chloramine, potassium permanganate, sodium bicarbonate, hypochlorite, hydrogen peroxide, sodium chlorate, super tropical bleach, sodium hydroxide, soap and water, and ammonia solutions. Absorbants that bind mustards include fuller's earth, activated charcoal, and other available absorbent powders including earth and flour. Mustards are soluble in organic solvents such as petroleum distillates and alcohols, and these agents may be used to assist in removal of mustards; however, care must be used to avoid increased skin absorption of mustards with these solvents.

### *Pathophysiology of Mustard Poisoning*

Mustard is a local and pulmonary irritant and vesicant, and a systemic poison. Whether in gas or liquid form, mustard binds to tissue and reacts irreversibly within minutes or is taken into the circulation.<sup>62</sup> The action of mustard involves the release of alkylating chemical linkages that interfere with DNA synthesis by binding to the nucleotides within the DNA strands; this is the radiomimetic effect of mustard (ie, it mimics the effect of radiation in producing DNA molecule breaks).<sup>61</sup> This characteristic appears to result in the death of the cell. The exact mechanism is not understood but may involve the upregulation of cellular DNA repair enzymes, which decrease the intracellular stores of NAD that are normally used to produce ATP, the energy storage molecule of the cell.<sup>63</sup> The loss of ATP in the epidermal cells of the skin may also induce a hypoxemia-like state, which may result in oxygen radical formation and subsequent cell-structure damage from reaction with the free radicals.<sup>64</sup>

Another mechanism of cell death has been postulated that involves the effect of mustard on the Ca<sup>2+</sup> adenosinetriphosphatase (ATPase) in the cell membrane. The alkylation of the sulfhydryl groups in this enzyme leads to an increase in cytosolic calcium and cell death.<sup>65</sup> Direct DNA damage, inactivation of cellular enzymes such as pyruvate oxidase, increased cell-membrane permeability, and the resultant loss of the cell's ability to maintain the integrity of the cell membrane may all contribute to cell death. Despite the fact that the action of mustard at the molecular level is not completely understood, the knowledge already gained over the past 2 decades has led to new insights into potential therapeutic modalities for mustard casualties, which will be discussed later in this chapter.

At a cellular level, skin damage is related to the amount of exposure to mustard, either as a gas or a liquid. Although the fixation of mustard to the tissue occurs within several minutes, histological changes within the epidermis are not evident until 30 to 60 minutes after exposure and do not become fully manifest until 2 to 3 days after exposure. The earliest changes are in individual keratinocytes, which become pyknotic and dyskeratotic (Figure 5-22). In 24 hours, inspection reveals more keratinocytes that are dyskeratotic and swollen, invasion of inflammatory cells into the epidermis, and intra- and subepidermal vesicle formation as a result of widespread cellular edema and death. This process often occurs over 2 to 10 days and is slowly progressive. In the affected areas, at the height of the reaction, dermal vessels are contracted and necrotic. This feature probably contributes to the dermal edema and epidermal necrosis seen histologically during this period.<sup>66,67</sup> Typically, an absence of thrombi in vessels and a mild, mixed, perivascular infiltrate are found. Histological specimens taken from Iranian mustard casualties revealed that blister formation was intra-epidermal, with the periodic acid-Schiff- (PAS) positive basement membrane located on the floor of the vesicle (Figure 5-23).<sup>68</sup> A sparse, inflammatory infiltrate in the blister and upper dermis are present. The picture of a necrotic epidermis with minimal inflammation mimicked the histology of toxic epidermal necrolysis. When these blisters healed, the histological picture of the areas of dark pigmentation included increased amounts of melanin throughout the epidermis (especially along the basal layer) and in dermal macrophages and was consistent with postinflammatory hyperpigmentation (Figure 5-24).<sup>68</sup>

**OK to put on the Web**

**Fig. 5-22.** Micrograph of a human skin graft on a nude mouse 24 hours after mustard exposure. Note the epidermal cell necrosis, infiltration of inflammatory cells, and incipient blister formation along the dermal–epidermal junction. Photograph: Courtesy of Dr. Bruno Papirmeister, Science Applications International Corporation, Joppa, Md.

**OK to put on the Web**

**Fig. 5-23.** Histological picture of a newly formed blister in an Iranian casualty exposed to mustard gas. The stain is periodic acid-Schiff (PAS); note that the PAS-positive basement membrane is at the floor of the blister. Photograph: Courtesy of Dr. Luis Requena, Universidad Autónoma de Madrid, Madrid, Spain.

**OK to put on the Web**

**Fig. 5-24.** Biopsy of an area of residual hyperpigmentation in a mustard casualty reveals increased melanin deposition along the basal cell layer of the epidermis (Fontana-Masson’s stain). Photograph: Courtesy of Dr. Luis Requena, Universidad Autónoma de Madrid, Madrid, Spain.

Clinically, mustard blisters result in superficial ulcerations not unlike those that develop in chemical or thermal burns. Although the ulcers look like burns, reepithelialization and the propensity to infection are altered due to the radiomimetic effects of mustard. These effects include prolonged healing due to the suppression of cell division and systemic immunosuppression via immune cell damage and death.

### *Clinical Signs and Symptoms of Mustard Exposure*

The experience with mustard poisoning in World War I until recently has been the chief source of information on the effects of mustard on human subjects. A classic description of the effects of mustard on an unprotected individual was provided in 1925:

On exposure to the vapor or to a finely atomized spray of mustard, nothing is noticed at first except the faint though characteristic smell. After the lapse of several hours, usually four to six, the first symptoms appear. The systemic symptoms are intellectual dullness or stupidity, headache, oppression in the region of the stomach, nausea or vomiting, malaise and great languor and exhaustion. In many cases these symptoms may not be noticed, and the local symptoms first attract attention. The eyes begin to smart and water. There is a feeling of pressure or often of a foreign body, and photophobia, and when examined the conjunctiva is found to be reddened. The nose also runs with thin mucus as from a severe cold in the head, and sneezing is frequent. The throat feels dry and burning, the voice becomes hoarse, and a dry harsh cough develops. Inflammation of the skin now shows itself as a dusky red erythema of the face and neck which look as though they had been sunburned, but are almost painless. The inner surfaces of the thighs, the genitals, the buttocks, the armpits, and other covered portions of the body are similarly affected. Mustard affects more severely those parts of the body where the skin is tender and well supplied with sweat glands. Itching and burning of the skin may be spontaneous, or first noticed as the result of washing. Even these mild symptoms may be sufficiently irritating to cause sleeplessness. At the end of twenty-four hours a typical appearance is presented. The conjunctivitis has steadily increased in intensity, the vessels are deeply injected, and one of the main items of distress is caused by the pain in the eyes which may be very intense. The patient lies virtually blinded, with tears oozing from between bulging edematous eyelids, over his reddened and slightly blistered face, while there is a constant nasal discharge, and con-

tinuous harsh, hoarse coughing. Frontal headache is often associated with pain in the eyes and photophobia and blepharospasm is always marked. During the second day the burned areas of the skin generally develop into vesicles, and the scrotum and penis and other badly burned areas become swollen, edematous and painful to the touch. Bronchitis now sets in with abundant expectoration of mucus, in which there may later be found large actual sloughs from the inflamed tracheal lining. The temperature, pulse rate and respiration rate are all increased.

These symptoms now increase in intensity for several days if the case has been severely burned. On the other hand, cases that have been only slightly poisoned may never proceed to the blister stage.<sup>69(p327)</sup>

Recent United Nations observers sent to Iran to evaluate chemical casualties have given descriptions of sulfur mustard victims that essentially mirror this description.<sup>68</sup> In the aftermath of a chemical attack on the Iranian towns of Oshnaviyeh and Abadan, the victims were described with initial symptoms of severe coughing, discharge from the nose and eyes, conjunctivitis (Figure 5-25), and skin irritation, all of which occurred from 20 minutes to several hours after the chemical exposure. The first skin symptom was often itching, and with heavy gas exposure was accompanied by nausea and vomiting. The skin then developed an erythema not



**OK to put on the Web**

**Fig. 5-25.** Conjunctivitis in an Iranian soldier exposed to mustard. Although the skin is minimally affected, eye involvement is relatively severe. As demonstrated in this patient, the eyes are significantly more sensitive to the effects of mustard than the skin. Photograph: Courtesy of Dr. Luis Requena, Universidad Autónoma de Madrid, Madrid, Spain.

**OK to put on the Web**

**Fig. 5-26.** Mild erythema with some mucosal involvement in an Iranian mustard casualty. Note the yellow crusting below the mouth, which is suggestive of a secondary bacterial infection. Photograph: Courtesy of Dr. Luis Requena, Universidad Autónoma de Madrid, Madrid, Spain.

**Fig. 5-27.** Diffuse bullae in an Iranian mustard casualty. This type of blistering usually occurred in relatively heavy mustard exposures. The intensity of the blistering was usually greater in the intertriginous areas, where there was increased moisture. Photograph: Courtesy of Dr. Luis Requena, Universidad Autónoma de Madrid, Madrid, Spain.

**OK to put on the Web**

**Fig. 5-28.** Diffuse superficial ulcerations secondary to the rupture of bullae in an Iranian casualty of a mustard attack. Note the involvement of the inguinal area. Although this area was probably protected with at least two layers of clothing, the increased moisture in the area resulted in significant blistering. The characteristic hyperpigmentation seen in mustard casualties is apparent around this individual's waist and neck areas. Photograph: Courtesy of Dr. Luis Requena, Universidad Autónoma de Madrid, Madrid, Spain.

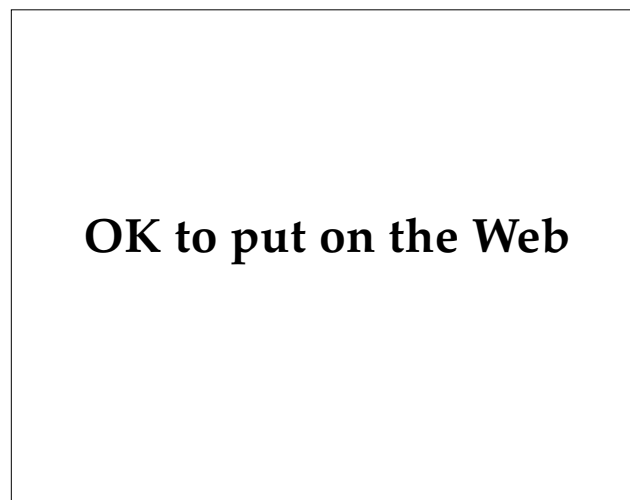**OK to put on the Web**

unlike that seen with a moderate sunburn (Figure 5-26). After 1 to 4 days, blisters appeared on exposed areas of the extremities (Figure 5-27). In some patients, the blisters coalesced to form large bullae that broke, leaving large superficial ulcers that covered in excess of 85% of the surface area (Figure 5-28).<sup>70,71</sup> In patients in the Abadan attack, intertriginous areas such as the axillae and inguinal areas became intensely involved (Figures 5-29 and 5-30). The affected skin developed black and blue discoloration and became infected in many areas.<sup>70</sup> Other signs and symptoms included hemoptysis, bronchitis, pulmonary edema, severe leukopenia, thrombocytopenia, and pancytopenia. Death was usually a result of respiratory compromise, infection, fluid imbalance, or any combination.

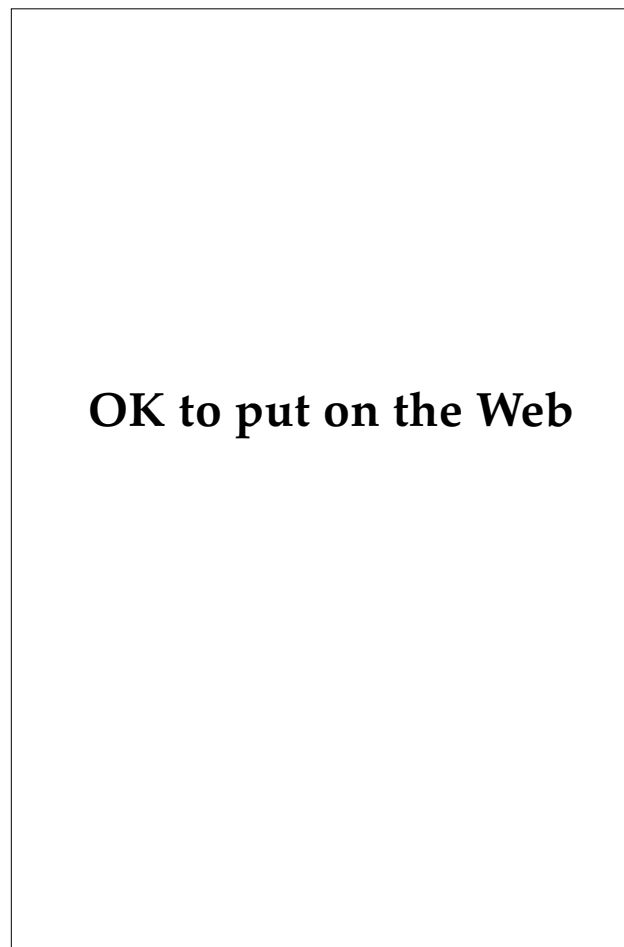
The course of the signs and symptoms of mustard exposure depends on dose, type of exposure (liquid versus vapor), individual susceptibility, and other variables such as protective equipment worn and decontamination measures. Therefore, symptoms ranging from mild, transient, respiratory symptoms to severe, widespread, systemic involvement can be seen in the casualties from a single gas attack.

The clinical course of skin signs and symptoms of mustard poisoning can be divided into five phases: the latent phase, erythema phase, blistering phase, necrosis phase, and healing phase. In cases of mild exposure to vaporized mustard (concentrations around 1  $\mu\text{L}/\text{L}$ ), often the course consists only of the

latent and erythema phases without the blistering and necrosis phases. In moderate-to-severe exposures to high concentrations of gas or to liquid mustard (concentrations above 10  $\mu\text{L}/\text{L}$ ), all phases occur and often at an accelerated pace. In mild exposures, the latent skin phase, in which no symptoms occur, may last up to 24 to 48 hours; but in heavy exposures, skin symptoms such as itching, burning, and erythema have been noted in as short a time as 5 minutes. Although there can be variability in the clinical course, Table 5-1 summarizes the chronology of the different phases of the acute signs and symptoms of mustard poisoning utilizing clinical data from several sources, including case histories of some Iranian mustard casualties reported by the World Health Organization.<sup>70-73</sup> Skin lesions



**Fig. 5-29.** Intertriginous (axillary) accentuation of blistering in an Iraqi mustard casualty. Photograph: Courtesy of Dr. Luis Requena, Universidad Autónoma de Madrid, Madrid, Spain.

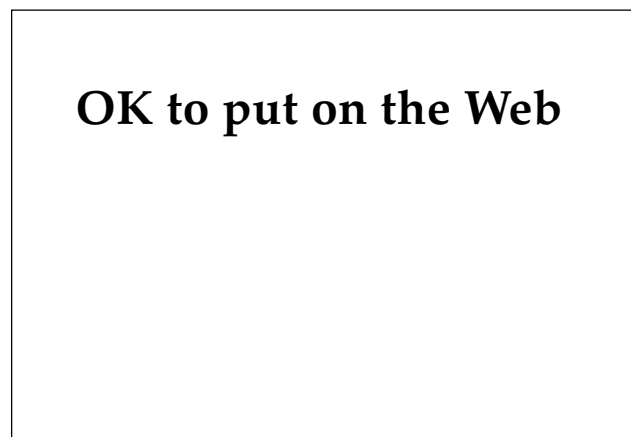

**Fig. 5-30.** Axillary accentuation of skin blistering and erosion in an Iraqi vesicant casualty. Photograph: Courtesy of Dr. U. Imobersteg, United Nations Observation Team, Gunten, Switzerland.

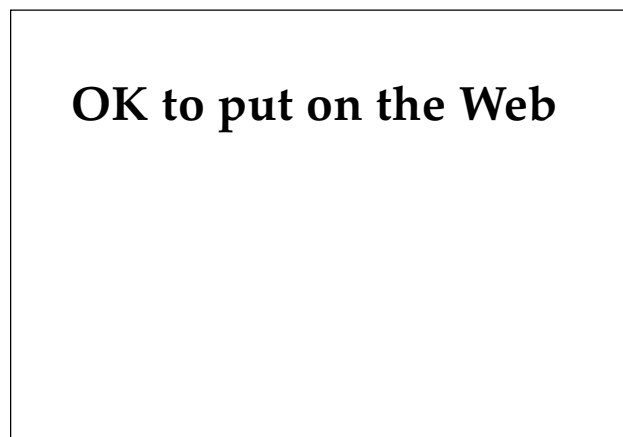**TABLE 5-1**  
**SKIN MANIFESTATIONS OF MUSTARD TOXICITY**

Phase	Time of Onset (range)	Skin Signs and Symptoms	Associated Systemic Symptoms
Latent	0–6 h (0–24 h)	Itching; exposed area can be dry and pale	Nausea and vomiting (early onset: 19–20 min)
Erythema	6–48 h (1 h–5 d)	Itching, burning, edema, cyanosis (no progression to blisters in mild cases)	Nausea and vomiting
Blistering (usually occurs only with relatively high doses of mustard)	6–48 h	Increased itching, pain; blisters usually at periphery of erythema; maximal expression at day 3–4; ulceration with trauma, infection development in area	
Necrosis	1–2 d	Upper dermis with necrosis of vessels; severe pain associated	Increased incidence of infection; leukopenia at day 7–10
Healing	2–8 wk	Superficial blisters with ulceration will heal in 2 wk without scarring; deep ulcers heal with scarring in 4–8 wk or remain as indolent ulcers. Post-inflammatory hyperpigmentation common in both	

Data source: US Department of the Army. *Treatment of Chemical Agent Casualties and Conventional Military Chemical Injuries*. Washington, DC: DA; 1974. Army TM 8-285: 2-7.



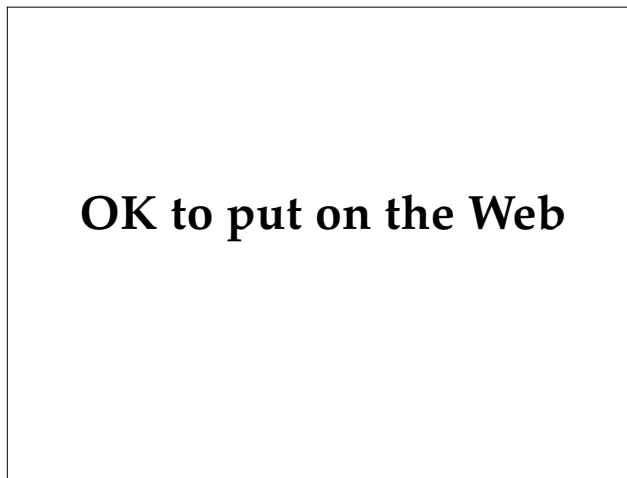
**Fig. 5-31.** Minimal residual hypopigmentation in an area exposed to a small amount of distilled mustard.



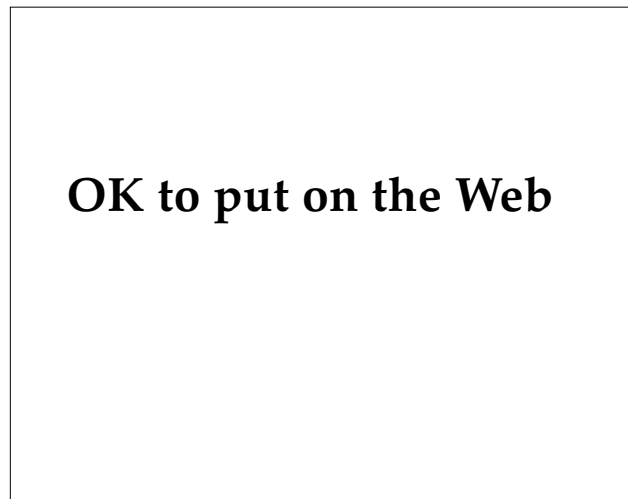**Fig. 5-32.** Iranian mustard fatality. Note the large area of involvement with the characteristic blistering and skin darkening. Photograph: Courtesy of Dr. Peter Dunn, Materials Research Laboratory, Victoria, Australia.

may vary in the severity of tissue damage and course of healing according to the amount of mustard absorbed at the site. A mild exposure to sulfur mustard at a testing facility resulted in a superficial blister that healed with mild hypopigmentation

within 2 weeks (Figure 5-31). At the opposite end of the spectrum are the mustard casualties who received a heavy mustard exposure and percutaneous absorption, which led to necrosis of the epidermis and dermis over large areas (Figure 5-32). The



**Fig. 5-33.** A localized mustard lesion. In this lesion, a gradation of skin damage is apparent in a targetlike pattern. In the central area, blistering and superficial ulceration occurred. Surrounding the area of most intense exposure is an area of intact necrotic skin and peripherally, an area of skin darkening. Photograph: Courtesy of Dr. Peter Dunn, Materials Research Laboratory, Victoria, Australia.

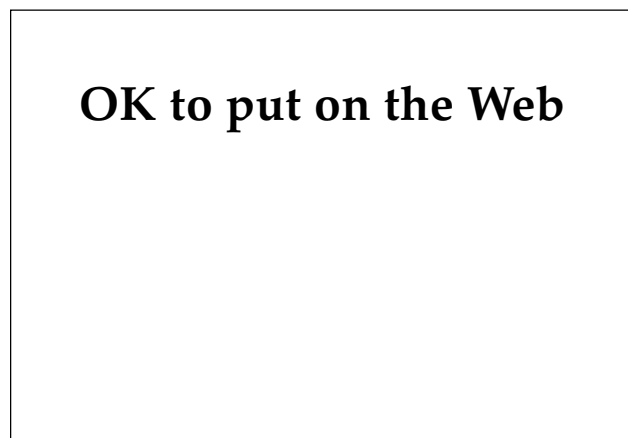


**Fig. 5-34.** Residual hyperpigmentation in the healing phase of a mustard lesion. Typically, the hyperpigmentation would be greatest in the areas of highest mustard exposure. Photograph: Courtesy of Dr. U. Imobersteg, United Nations Observation Team, Gunten, Switzerland.

**TABLE 5-2**  
**HEALING TIME OF MUSTARD BURNS OF THE SKIN**

Type of Burn	Days	Weeks
Erythema	3-7	—
Facial blisters	5-8	—
Pinpoint blisters	—	1-2
Large nonfacial blisters	—	2-4
Feet and genital blisters	—	4-6
Mustard burns with coagulation necrosis	—	6-8

Adapted from McNamara BP. *Medical Aspects of Chemical Warfare*. Alexandria, Va: Defense Technical Information Center; 1960. Report AD 240713: 18.



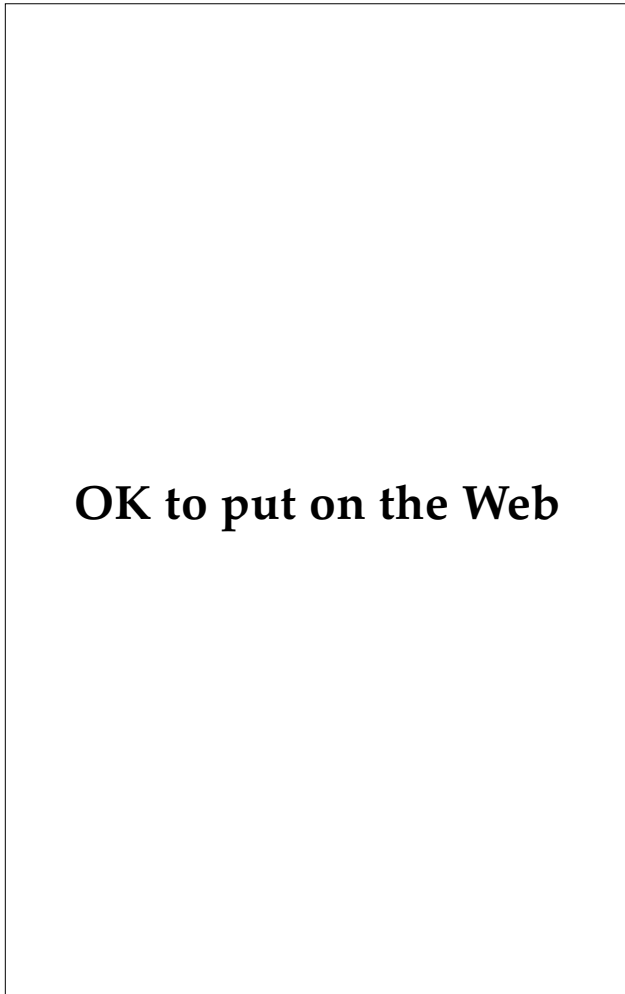**Fig. 5-35.** Another example of hyperpigmentation in a mustard lesion. The mechanism of the hyperpigmentation as shown here is probable postinflammatory deposition of melanin in the dermis and is directly related to the severity of the primary lesion. Photograph: Courtesy of Dr. Peter Dunn, Materials Research Laboratory, Victoria, Australia.

dose-response relationship of skin damage and mustard dose is clearly demonstrated in Figure 5-33. In this mustard patient, an isolated exposure to mustard produced a graded response, from severe necrosis of the skin in the central area of greatest

mustard concentration to a mild erythema in the areas of lesser mustard concentration at the periphery of the lesion. The dose of mustard also has a significant effect on the healing time (Table 5-2).<sup>74</sup> As the blistered areas heal, characteristically a dark

red-brown hyperpigmentation occurs at the periphery of the lesion (Figures 5-34 and 5-35).

Many organ systems are affected by mustard poisoning. Because the mucosal surfaces are exposed in the cornea and the lining of the upper airways, the eyes and respiratory tract are the most frequently involved organ systems. Eye injuries range from conjunctivitis in mild exposures to corneal damage, scarring, and iritis in severe exposures (Figure 5-36). Respiratory compromise occurs in vapor exposures. Mustard gas in concentrations less than that which can be detected by smell can cause significant upper airway signs and symptoms if inhaled over a several-day period. Respiratory injuries range from mild inflammation of the upper airway to bronchopneumonia, pulmo-



**Fig. 5-36.** Residual corneal opacity secondary to mustard exposure. Photograph: Courtesy of Dr. Luis Requena, Universidad Autónoma de Madrid, Madrid, Spain.

nary edema, and, in severe exposures, adult respiratory distress syndrome. The onset of mustard poisoning symptoms in the skin, respiratory system, and eye often occur concurrently, beginning within the first several hours after exposure and peaking within the first 72 hours. As with skin symptoms, an early onset of eye and pulmonary symptoms suggests a worse prognosis. Table 5-3 shows the relative frequency of the various signs and symptoms of Iranian mustard casualties.

Absorption of mustard through epithelial surfaces or ingestion of mustard via contaminated food or water can lead to hematopoietic, neurological, and gastrointestinal involvement. When ingested, mustard can cause acute nausea and vomiting. Later symptoms include oral and esophageal pain and desquamation, abdominal pain, hemorrhage, diarrhea, and prolonged anorexia. These symptoms can interfere with the maintenance of adequate hydration and electrolyte balance in patients who may already have difficulties secondary to compromise of the skin barrier.

Neurological involvement can produce nystagmus, decreased motor activity, disturbed consciousness, anxiety, hearing loss, motor paralysis, and coma.<sup>61,66</sup> Case reports of acute and delayed (3 mo after mustard administration) neurotoxicity from nitrogen mustard (mechlorethamine) describe mental confusion, ataxia, amnesia, headache, hyperreflexia, and localizing CNS signs as additional symptoms occurring after mustard therapy.<sup>75,76</sup> In both cases, an increased ventricular pressure was noted, and measures taken to decrease the intraventricular pressure resulted in clinical resolution of the symptoms. These symptoms may be misdiagnosed as nerve agent poisoning if the physician is unaware of the CNS effects of mustard poisoning.

Mustard toxicity to the hematopoietic system can result in myelosuppression within 7 to 15 days after exposure.<sup>61</sup> The resultant drop in leukocyte and platelet counts can lead to increased susceptibility to infection and bleeding during this period. The implications for therapy during bone marrow suppression are significant. An immunocompromised patient with large areas of denuded epidermis is at great risk for sepsis and must be followed closely and treated when evidence of infection is discovered.

The synergistic effect of combined injuries in a casualty must also be considered when triaging and treating a patient. These patients typically have injuries secondary to conventional weapons such as shrapnel wounds in combination with an NBC injury such as mustard poisoning. Past experience



**TABLE 5-3**  
**FREQUENCY OF SIGNS AND SYMPTOMS IN**  
**94 MUSTARD CASUALTIES DURING THE**  
**IRAN-IRAQ WAR**

Signs and Symptoms by Organ System	Frequency (%)
Ophthalmic	
Conjunctivitis	94
Blurred Vision	80
Photophobia	72
Temporary blindness	4
Skin	
Erythema	86
Pigmentation	82
Blistering	69
Severe burning	12
Skin (scrotal)	
Erythema	25
Edema	21
Pain	18
Ulceration	10
Respiratory	
Coughing	86
Dyspnea	45
Wheezing	40
Rales	22

Adapted with permission from Balali M. Clinical and laboratory findings in Iranian fighters with chemical gas poisoning. *Arch Belg.* 1984(suppl):256.

with these casualties has revealed that the lethality and morbidity of the combination of injuries is higher than that expected from the added effects of either injury alone.

### Arsenical Vesicants

Chlorovinyl-dichloroarsine, or Lewisite (L), is an arsenical vesicant. It is a colorless to brown liquid with a fruity to geranium-like odor, is more volatile than mustard, and is soluble in organic solvents. Lewisite is considered to be a lesser threat than mustard and will be described briefly.

Lewisite's mode of action in many ways appears to mimic that of mustard. It appears to bind to thiol (sulfhydryl) groups on enzymes, which results in decreased cell metabolism and death. Clinically, Lewisite skin injuries are similar to those caused by mustard gas (Exhibit 5-1). The main differences include an earlier onset of pain (occurring within

minutes of exposure), a decreased incidence of skin infection, and a shortened healing time (2–3 wk). Like mustard compounds, Lewisite has an effect on multiple systems including the eye, respiratory tract, gastrointestinal tract, musculoskeletal system, nervous system, and the hematopoietic system, among others. Since Lewisite is an arsenical compound and some of its toxicity involves the arsenical group, Lewisite therapy includes the use of the chelator British anti-Lewisite (BAL). Topical application of BAL ointment within 5 minutes after exposure and intramuscular injection of a 10% solution at a dose of 0.025 mL/kg every 4 hours for a total of 4 to 6 injections may decrease some of the epidermal and systemic toxicity of Lewisite.

### Management of Vesicant Injury

Management of blister agent casualties can be divided into several chronological phases: prophylaxis, decontamination, and treatment of lesions. Prophylaxis consists of the use of protective clothing, avoidance of contaminated areas, and destruction of the enemy's chemical capability. Because these prophylactic measures can, at best, only minimize chemical casualties in a war rather than eliminate them, we must be prepared to decontaminate and treat vesicant injuries with all effective means at our disposal.

### Decontamination

Protection for the medical personnel who are caring for blister agent casualties is perhaps the single most important aspect in mustard casualty treatment. Mustards are notorious for their persistence and ability to adhere to fomites. In 1956, an incident of mustard poisoning occurred in North Africa that illustrates the potential for symptomatic vesicant exposure of individuals including medical personnel, who are not exposed to the actual chemical attack but come in contact with contaminated casualties, their clothing, and other fomites. This incident involved three children who were playing with a mustard gas shell that exploded. During their transport to the hospital and the initial period of care, nine contacts including a physician, a nurse, and several medical assistants, experienced symptoms of mustard gas poisoning ranging from conjunctivitis to severe blistering, nausea, and vomiting.<sup>77</sup>

Once medical providers become blister agent casualties, they are unable to provide further care, producing a significant degradation of the medical

## EXHIBIT 5-1

### DIFFERENTIAL CHARACTERISTICS OF LEWISITE AND MUSTARD TOXICITY

---

1. Liquid Lewisite is absorbed into the skin more rapidly.
2. Erythema appears more rapidly with Lewisite and is intense red instead of pink.
3. The area between normal surrounding skin and affected skin is less well defined in Lewisite lesions. The demarcation becomes clear after 2 to 3 days. The areas of injured skin of mustard lesions are well defined from the beginning.
4. Edema is much more pronounced with Lewisite.
5. Instead of the single, large blister produced by Lewisite, mustards create tiny blisters at the periphery of the injury ("pearl necklace") that later join to form large blisters.
6. Maximum development of inflammatory reaction occurs earlier with Lewisite than with mustards.
7. A Lewisite ulcer is bright red with a multitude of hemorrhages at the base. The base of a mustard ulcer is gray and has a single hemorrhage that is usually superficial.
8. Secondary infections are rare with Lewisite and frequent with mustard.
9. Pigmentation is less frequent with Lewisite-induced lesions than with mustard-induced lesions.
10. Wounds contaminated with Lewisite change color sharply and more rapidly than those contaminated with mustards; the tissues may show gray-black spots with a silver sheen that later turn red-brown. Wounds contaminated with Lewisite will give off the characteristic odor of geranium for 8 hours or longer.
11. Wounds contaminated with Lewisite present additional problems and increased risk of systemic effects. The casualty notices sharp pain in the wound out of proportion to the trauma.
12. Coagulation is poor and bleeding can become life-threatening with Lewisite injuries. The edges of the wound may turn pale yellow and, after a period of erythema (18–24 h), inflammatory blisters develop in the adjacent skin.

---

Adapted from Augerson WS, Sivak A, Marley WS. Chemical casualty treatment protocol development—treatment approaches. In: *Lewisite*. Vol 3. Air Force Chemical Defense Report. AD-B112 916, September 1986: 1–55.

unit's ability to sustain its mission. Therefore, it is necessary to ensure that affected soldiers are decontaminated before medical treatment. In emergent cases, soldiers may be treated before decontamination by personnel wearing appropriate protective gear. However, chemical protective gear worn by the patient or the physician poses a significant obstacle in the evaluation and treatment of the patient.<sup>78</sup>

Decontamination of mustard casualties and fomites exposed to mustard can be accomplished by absorption and deactivation of the chemicals. The U.S. Army's M13 decontamination kit contains dusting pads of fuller's earth, which absorbs liquid mustard, and chloramide powder, which inactivates mustard. The army's newer M258 skin decontaminating kit contains solutions of chloramide and a mixture of ethanol, phenol, and sodium

hydroxide to inactivate mustard compounds. In the absence of standard decontaminating kits, other decontaminants can be used. For example, washing repeatedly with soap and warm water can inactivate large quantities of mustard on the skin. If water is not available, mechanical scraping and application of absorbents such as activated charcoal or grain flours can be used to decontaminate the skin. Strong basic solutions such as ammonia and lye, or chlorinated acids such as sodium hypochlorite (household bleach), may be used to decontaminate fomites.

#### *Conventional Therapy*

Conventional therapy for mustard wounds consists of symptomatic care (burn care) of the lesions

and their attendant symptoms. Patients with areas of involvement less than 20% of the total body surface are unlikely to develop significant complications secondary to fluid and electrolyte imbalances<sup>79</sup> and can be treated in a nonacute care setting. Dermatologists are uniquely qualified to care for this group of patients.

After thoroughly decontaminating and cleansing the involved areas, topical care is initiated. Application of anti-infectious creams such as Sulfamylon (mafenide acetate, manufactured by Sanofi Winthrop, New York, N.Y.) or Silvadene (silver sulfadiazine, manufactured by Marion Merrell Dow, Kansas City, Mo.) inhibits bacterial colonization and infection of the denuded skin and should be routinely used in mustard casualties with blisters and superficial ulcers. Use of antibacterial ointments and creams such as Neosporin (polymyxin B sulfate, bacitracin zinc, and neomycin, manufactured by Burroughs Wellcome, Research Triangle Park, N.C.) and bacitracin also are useful in protecting blister wounds and promoting reepithelialization.<sup>80</sup> The new biosynthetic dressings such as hydrogel and hydrocolloid gel accelerate reepithelialization, induce faster healing, reduce wound contamination, and decrease pain.<sup>81</sup> They also absorb fluid (sera) from the occluded area into their biosynthetic matrix, and this action may allow binding and inactivation of any free mustard compounds from the wound. Constant vigilance of the denuded areas to monitor for early signs of bacterial infection is of paramount importance. Daily debridement and cleansing of the wounds is necessary to avoid undue risk of developing infection.

Symptoms related to skin injury by sulfur mustard include pain and itching. Symptomatic therapy for the itching includes potent antihistamines such as Atarax (hydroxyzine hydrochloride, manufactured by Roerig, New York, N.Y.) and Sinequan (doxepin hydrochloride, manufactured by Roerig, New York, N.Y.). Topical steroids may help in areas of severe itching resistant to antihistamines, but caution should be used since steroids may slow healing. In addition to standard analgesics such as codeine, nonsteroidal antiinflammatory drugs (NSAIDs) such as Clinoral (sulindac, manufactured by Merck and Co., West Point, Pa.) and Naprosyn (naproxen, manufactured by Syntex, Humacao, P.R.) help relieve pain and may reduce inflammation. Because NSAIDs can adversely affect renal function, careful consideration should be given before utilizing them in blister patients, who are susceptible to fluid and electrolyte imbalances.

### *Potential New Therapies*

Research into new treatments for mustard gas injury has focused on two areas: deactivating the compounds before they can cause significant damage and reducing the mustard's deleterious effects. Both approaches require rapid application for best results.

***Inactivation of Mustard Compounds.*** Because mustard reacts with tissue within minutes of exposure, specific therapy designed to inactivate the chemical or to slow its rate of absorption must be initiated within minutes to be maximally effective. Most casualties, however, appear to continue to absorb free, nonfixed mustard compounds from their skin surface or from mustard-contaminated fomites, so therapy specifically used to inactivate mustard externally or internally may be useful long after the initial mustard exposure.

Studies have shown that thiols or compounds containing sulfhydryl groups decrease the toxic effects of mustard.<sup>82,83</sup> Their action, in part, appears to be mediated through the direct inactivation of mustard compounds. The list of the thiols that have been used is long but only a few thiol compounds are readily available currently. A thiol compound that has been used orally in the past to treat acetaminophen toxicity is Mucomyst (acetylcysteine, manufactured by Apothecon, Princeton, N.J.). That regimen includes an oral loading dose of 140 mg/kg followed by doses of 40 mg/kg every 4 hours for a total of 17 doses. The drug is relatively innocuous, with side effects including nausea, vomiting, and, rarely, urticaria. Another thiol that is available for parenteral use is sodium thiosulfate. Currently, it is used to treat cyanide poisoning. Dosage is 50 mL of a 25% solution (12.5 g) given intravenously over 10 minutes. At this dose, the only significant side effect is that of hypovolemia secondary to an osmotic diuresis caused by the drug.

Theoretically, thiols could also be used topically in wounds and areas where routine decontamination may be contraindicated. The only drawback to these drugs is that they do not react with mustard already bound to tissue; therefore, their ideal use would be as a pretreatment. Studies have shown that thiols have a systemic protective effect even when given up to 15 minutes after exposure.<sup>83</sup> Research in Germany in 1950 utilized iontophoresis of a cysteine hydrochloride solution on human subjects exposed to varying amounts of sulfur mustard.<sup>84</sup> The results demonstrated that the therapy, which was begun after erythema developed, re-

sulted in significant amelioration in the clinical course of blister formation and healing.

Other substances that could inactivate mustard compounds when applied topically include albumin, collagen, powdered milk, gel or collagen dressings, and activated charcoal slurry, all of which have an affinity for mustard agents and will bind and inactivate them.<sup>66</sup>

#### **Reduction of Untoward Reactions to Mustard.**

Two therapies greatly reduce the effects of mustard compounds on the skin<sup>62</sup>: cooling the skin and using trichloroacetic acid crystals to prevent desiccation. Cooling the skin with ice bags appears to inhibit vesication of mustard-exposed skin. The physiology of the inhibition of mustard toxicity with cooling is unknown but may be related to decreased transport through the skin and into the bloodstream, or a decrease in the rate of mustard reaction with substrates within the tissue at lower temperatures. The application of trichloroacetic acid crystals after the erythema of mustard exposure develops prevents vesication. Dermatologists routinely use 20% to 50% solutions for cosmetic peels without complication; however, trichloroacetic acid at 50% concentrations and above can cause significant dermal scarring<sup>85</sup> and the medical officer should use great caution in considering this therapy in a soldier who already has significant compromise to the integrity of the epidermis.

Other readily available drugs that have been reported to ameliorate the toxic effects of mustards on the skin by interfering with primary mustard reactions at the molecular level include vitamin E (antioxidants), Mandelamine (methenamine mandelate, manufactured by Parke-Davis, Morris Plains, N.J.), and niacin.<sup>66</sup>

#### **Treatment of Complications**

Complications from exposure to mustard compounds arise from (a) systemic toxicity of the absorbed mustard and (b) direct insult to the epidermal barrier. Damage to the epidermal barrier results in increased fluid loss from the body and electrolyte imbalance. With areas of involvement greater than 20%, the casualty must be evacuated to a hospital capable of treating burn patients, if possible. If the area of epidermal barrier loss is less than 20%, the patient can be managed in a nonacute care setting.<sup>79</sup> However, the patient must be carefully monitored to avoid the complications of hypovolemia and electrolyte imbalance. Another complication associated with epidermal barrier loss in mustard casu-

alties is the increased incidence of cutaneous and systemic infection. Therefore, mustard casualties must be monitored closely for signs and symptoms of infection. If an infection is suspected, blood and the appropriate tissue cultures must be obtained and the patient placed on antibiotics. Typically, two of the most common pathogens in burn patients are *Staphylococcus aureus* and *Pseudomonas aeruginosa*; therefore, broad-spectrum antibiotics should be used. The patients should not be placed on prophylactic systemic antibiotics because this only results in the colonization of the wounds with drug-resistant organisms.

The suppressive effect of mustard on the immune system can increase the likelihood of cutaneous and systemic sepsis. Leukopenia secondary to mustard exposure typically is the greatest approximately 7 to 10 days after mustard exposure. At this time, the patients are most likely to become septic, and close monitoring during this period is paramount.

As noted earlier, mustard patients usually develop symptoms concurrently in several organ systems after exposure. When the skin is involved in mustard toxicity, the eyes, respiratory system, gastrointestinal system, hematopoietic system, heart, and central nervous system can also be affected. Although treatment of the effects of mustard on these systems is beyond the scope of this chapter, the same basic principles of skin therapy can be applied to the treatment of mustard toxicity in these systems. A good review of the treatment of mustard casualties is available elsewhere.<sup>66</sup>

When triaging and treating chemical casualties, the synergistic effect on the morbidity and mortality of casualties with injuries that involve a combination of conventional and NBC injuries must be kept in mind.

#### **Halogenated Oximes**

Phosgene oxime (CX) is a colorless liquid or solid (melting point 40°C) that has an intense, disagreeable odor. It belongs to a class of chemical agents called urticants or nettle gases. It should not be confused with phosgene (CG), which is primarily a choking agent and exerts its effects mainly in the upper airways and lung. Phosgene oxime's primary sites of action are the skin, eyes, and upper respiratory system. In these areas, it is extremely irritating to the epidermal and mucosal tissues.<sup>86</sup> Its mechanism of action is not completely understood, but studies suggest that it is an alkylating agent and

its toxicity is mediated via binding to sulfhydryl and  $\text{NH}_2$  groups. The action on the skin, like Lewisite, is immediate, with development of irritation and burning suggestive of the reaction to stinging nettle. With the characteristic pain that is felt almost immediately with exposure, a white area surrounded by erythema develops. An urticaria-like edema ensues within the first hour, followed by blistering after 24 hours. The skin can become necrotic, and healing may take up to 3 months.<sup>86,87</sup> Specific treatment consists of immediate decontamination with copious amounts of water and any mild base (buffer) such as sodium bicarbonate solution. After initial therapy, symptomatic burn therapy is indicated.

### Nerve Agents and Cyanides

Although nerve agents (tabun [GA], sarin [GB], soman [GD], and VX) and the cyanides (hydrogen cyanide [AC] and cyanogen chloride [CK]) are considered threat agents by the allied forces, their cutaneous effects are minimal and will be described briefly.

The cutaneous effects of nerve agents are mostly limited to the areas of exposure. In these areas, nerve agent casualties may develop increased sweating secondary to the muscarinic-like effect of the agents on eccrine sweat gland innervation.<sup>86</sup> The

muscarinic effects of nerve agents on the erector pili muscles may cause contraction and the development of "goose-bumps" on exposed areas. Fasciculations of the striated muscle underlying the exposed area can occur as a result of the nicotinic-like effects of the absorbed nerve agents. Tabun and sarin have caused a cyanotic redness and edema of the skin, respectively.<sup>66</sup>

Treatment of nerve agents consists of the administration of atropine to inhibit the muscarinic effects of the agent, and pralidoxime chloride (2-PAM) to reactivate acetylcholinesterase.

The cyanides (blood agents) act by inactivating cytochrome oxidase, which prevents the cells from utilizing oxygen. They are acutely lethal, causing apnea, convulsions, and death within minutes. Because the cells cannot utilize oxygen, the blood remains oxygenated and the mucosal membranes and skin of a blood agent casualty appear dark red. Although this sign is nonspecific, it is very suggestive of cyanide poisoning in the context of convulsions and acute loss of consciousness. Acutely, the only effective therapy is amyl nitrite inhalation, which generates methemoglobin, which, in turn, binds cyanide. After an intravenous line is established, sodium thiosulfate can be given. Sodium thiosulfate reacts with cyanide to form thiocyanate, which can be excreted by the kidneys.

## SUMMARY

The threat of chemical warfare today is real and medical officers must be prepared to treat chemical casualties if the need arises. In the past, this area has been neglected; however, the possibility that U.S. military forces could sustain a substantial number of nuclear, biological, and chemical (NBC) casualties in future conflicts is very high. Therefore, it is incumbent on us, as physicians, to ensure that we are capable of rendering the best care possible.

In preparation for cutaneous lesions found in NBC casualties, medical personnel should understand some fundamental principles that have been noted in this chapter:

- Basic supportive measures for NBC casualties are based on the same medical principles, such as wound and burn care, that are already contained in the present literature and known to most physicians.
- There is an overriding need to protect medical personnel in an NBC environment to

ensure they do not become casualties and thus severely hinder the medical team's capabilities.

- Although supportive care of NBC casualties requires no NBC training, specific therapy with NBC antidotes and decontamination of patients requires specialized knowledge gained only through extensive review of medical literature or through attendance of military medical NBC courses. Therefore, military physicians should actively prepare for the possibility that they may treat NBC casualties by reading the NBC literature and attending NBC training courses.
- If placed in a situation with an NBC threat such as that of the Persian Gulf War, the medical officer should immediately evaluate the preparedness of his medical unit to treat casualties. This evaluation should include the availability of specific NBC antidotes such as sodium thiosulfate for cyanide

poisoning, NBC protective gear for the medical personnel, and decontamination supplies and equipment for area and patient decontamination.

- Triage procedures will be complicated by NBC casualties. Medical officers should be capable of triage and treatment of combined injuries, in which patients have conventional wounds such as blast injury in addition to exposure to chemical or biological agents. Often these patients would be treatable if they had only one type of injury but would be expectant (ie, seriously injured or with poor chance of survival) with the combination of injuries.

- NBC doctrine often targets rear areas, where hospitals and other medical facilities are located. Therefore, medical officers should be aware of the enemy's NBC doctrine and should be prepared for movement and decontamination of medical facilities if the threat is high.

Future wars involving NBC undoubtedly will be very different from those since World War I. However, if physicians, nurses, and other medical personnel are prepared and cognizant of the threat, the impact of an enemy NBC offensive on the combat effectiveness of U.S. forces will be minimized.

## REFERENCES

1. Achiya M; Wells W, trans. *The Journal of a Japanese Physician, August 6–September 30, 1945, Hiroshima Diary*. Chapel Hill, NC: University of North Carolina Press; 1955: 14–15.
2. Werner G. *Military Internal Medicine* [trans from German]. AFMIC-HT-045-87. Fort Detrick, Frederick, Md: Armed Forces Medical Intelligence Center; 1985.
3. Hopkins DR. *Princes and Peasants: Smallpox in History*. Chicago, Ill: University of Chicago Press; 1983.
4. Bernstein BJ. The birth of the US biological-warfare program. *Sci Am*. 1987;256(6):116–121.
5. Smith RJ. Soviet anthrax explanation is debunked. *Science*. 1980;209:375.
6. Wade N. Death at Sverdlovsk: A critical diagnosis. *Science*. 1980;209:1501–1502.
7. Schreiber W. Medicinal plants: Ergot (*Claviceps purpurea*). *Medical Corps International*. 1988;5:66–70.
8. Schreiber W. Ergot poisoning. *Medical Bulletin (Seventh Corps)*. 1980;37:18–23.
9. Burfening PJ. Ergotism. *J Am Vet Med Assoc*. 1973;163:1288–1290.
10. Orient JM. Chemical and biological warfare. *JAMA*. 1989;262:644–648.
11. Rosen RT, Rosen JD. Presence of four Rusariun mycotoxins and synthetic material in "Yellow Rain." *Biochem Mass Spectrum*. 1982;9:443–450.
12. Marshall E. A cloudburst of yellow rain reports. *Science*. 1982;218:1202–1203.
13. Schreiber W. Surgery through the ages from Galen to Billroth. *Medical Bulletin*. 1981;38(4/5):11–12.
14. Waitt AH. *Gas Warfare*. New York, NY: Duell, Sloan and Pearce; 1942: 9–11.
15. Prentiss AM. *Chemicals in War. A Treatise on Chemical Warfare*. New York, NY: McGraw-Hill Book Co, Inc; 1937: 686.
16. Brown F. *Chemical Warfare, A Study In Restraints*. Princeton, NJ: Princeton University Press; 1968:106–107.
17. Haber LF. *The Poisonous Cloud: Chemical Warfare in the First World War*. Oxford, England: Clarendon Press; 1986: 245–246.

18. Defense Technical Information Center. *History of the Chemical Warfare Service, American Expeditionary Forces, First Gas Regiment*. Part 14. Alexandria, Va: DTIC; 1918. Report AD 494982.
19. Alexander SF. Medical report of the Bari harbor mustard casualties. *Military Surgeon*. 1947;101:1-17.
20. Hitler A; Manheim R, trans. *Mein Kampf*. Boston, Mass: Houghton Mifflin Co; 1971: 201-202.
21. Glasston S, Dolan PJ. *The Effects of Nuclear Weapons*. Washington, DC: Department of Defense and Department of Energy; 1977: 1-13.
22. Conklin JJ, Walker RI. *Military Radiobiology*. New York, NY: Academic Press, Inc; 1987: 1-8.
23. Goldschmidt H. Radiodermatitis and other sequelae of ionizing radiation. In: Demis DJ, ed. *Clinical Dermatology*. Philadelphia, Pa: Harper and Row; 1985: Unit 19-8, 1-13.
24. Wolpaw JR. *The Acute Radiation Syndrome: Diagnosis and Treatments*. Armed Forces Radiobiology Research Institute Report. Washington, DC: US Army; January 1983: J-1-J-15.
25. Nenot JC. Medical and surgical management for localized radiation injuries. *J Radiat Biol*. 1990;57:783-795.
26. Fanger H, Lushbaugh CC. Radiation death from cardiovascular shock following a criticality accident. *Arch Path*. 1967;83:446-460.
27. Bester WT, Call CA. Medical management of nuclear and chemical casualties. *Emerg Care Quart*. 1987;2:67-74.
28. Fitzpatrick JE. Management of resistant bacterial infections. *Corium*. 1989;2:4-12.
29. Orsted H. Radiation skin reaction. *The Canadian Nurse*. October 1989;85:30-31.
30. Krizek TJ. Difficult wounds: Radiation wounds. *Clin Plast Surg*. 1979;6:541-543.
31. Shack RB. Management of radiation ulcers. *South Med J*. 1982;75:1462-1466.
32. Lowy RO, Baker DG. Protection against local irradiation injury to the skin by locally and systemically applied drugs. *Radiology*. 1962;105:425-428.
33. Dion MW, Hussey DH, Dorrnbos JF, Vigliotti AP, Wen BC, Anderson B. Preliminary results of a pilot study of pentoxifyllin in the treatment of late radiation soft tissue necrosis. *Int J Radiat Oncol Biol Phys*. 1990;19:401-407.
34. Petkau A. Protection of bone marrow progenitor cells by superoxide dismutase. *Mol Cell Biochem*. 1988;84:133-140.
35. Uchigata Y, Yamamoto H, Kawamura A, Okamoto H. Protection by superoxide dismutase, catalase, and poly(ADP-ribose) synthetase inhibitors against alloxan- and streptozotocin-induced islet DNA strand breaks and against the inhibition of proinsulin synthesis. *J Biol Chem*. 1982;257:6084-6088.
36. Yamamoto H, Uchigata Y, Okamoto H. Streptozotocin and alloxan induce DNA strand breaks and poly(ADP-ribose) synthetase in pancreatic islets. *Nature*. 1981;294:284.
37. Neta R. Radioprotection therapy of radiation injury with cytokines. *Prog Clin Biol Res*. 1990;352:471-478.
38. Butturini A, De Souza PC, Bale RP, et al. Use of recombinant granulocyte-macrophage colony stimulating factor in the Brazil radiation accident. *Lancet*. 1988;2:471-475.
39. Decosse JJ. Antioxidants. *Prog Clin Biol Res*. 1988;279:131-134.
40. Lever WF, Schumburg-Lever G. *Histopathology of the Skin*. 7th ed. Philadelphia, Pa: JB Lippincott Co; 1990: 235-237.

41. Rudolph R, Van de Berg J, Schneider JA, Fisher JC, Poolman WL. Slowed growth of cultured fibroblasts from human radiation wounds. *Plast Recon Surg*. 1988;82:669–677.
42. Nenot JC. Medical and surgical management for localized radiation injuries. *Int J Radiat Biol*. 1990;57:783–795.
43. Kadivar H, Adams SC. Treatment of chemical and biological warfare injuries: Insights derived from the 1984 Iraqi attack on Majnoon Island. *Milit Med*. 1991;156(4):171–177.
44. McKee K. Biological agents. In: *Diagnosis and Treatment of Diseases of Tactical Importance to US CENTCOM Forces*. 2nd ed. Washington, DC: US Army; 1991.
45. Soviet Biological Warfare Threat. DST-161OF-057-86. Washington, DC: Defense Intelligence Agency; 1986.
46. Holmes RK. Anthrax. In: Braunwald E, ed. *Harrison's Principles of Internal Medicine*. 12th ed. New York, NY: McGraw-Hill Book Co, Inc; 1991: 575–577.
47. Sanford JP. Arbovirus infections. In: Braunwald E, ed. *Harrison's Principles of Internal Medicine*. 12th ed. New York, NY: McGraw-Hill Book Co, Inc; 1991: 725–739.
48. Abrutyn E. Botulism. In: Braunwald E, ed. *Harrison's Principles of Internal Medicine*. 12th ed. New York, NY: McGraw-Hill Book Co, Inc; 1991: 579–580.
49. Wogan GN. Mycotoxins. *Ann Rev Pharm*. 1975;15:437–451.
50. Fox JE. Opinions diverge: Toxins dropped, or bee feces “clouds” the cause? *US Medicine*. 1 May 1984;1, 30.
51. Grunwald H, ed. Deadly dose: New charges about yellow rain. *Time*. 13 December 1982: 51.
52. Nowicke JW, Messelson M. Yellow rain—a palynological analysis. *Nature*. 1984;309:205–206.
53. Stahl CJ, Green CC, Farnum JB. The incident at Tuoi Chrey: Pathologic and toxicologic examinations of a casualty after chemical attack. *J Forensic Sci*. 1985;30(2):317–337.
54. Ezz EA, Ambeva EE, Castillo NC, Guerra H. *Chemical and Bacteriological (Biological) Weapons: Report of the Group of Experts to Investigate Reports on the Alleged Use of Chemical Weapons*. United Nations 36th session, Agenda item 42. New York, NY: United Nations; 1981.
55. Bhavanishankar TN, Ramesh HP, Shantha T. Dermal toxicity of Fusarium toxins in combinations. *Arch Toxicol*. 1988;61:241–244.
56. Ellenhorn MJ, Barceloux DG. *Medical Toxicology: Diagnosis and Treatment of Human Poisoning*. New York, NY: Elsevier; 1988: 84.
57. Augerson WS, Sivak A, Marley WS. Chemical casualty treatment protocol development—treatment approaches. In: *Trichothecene Mycotoxins*. Vol 5. Cambridge, Mass: Arthur D Little, Inc; 1986: 1–207.
58. Norman C. CIA details chemical weapons spread. *Science*. 1989;243:888.
59. Elfried G, Russian CW. Our Achilles' heel, Europe. *Army*. 1979;Dec:24–28.
60. Howarth RA. The chemical warfare threat. Aberdeen Proving Ground, Md: Operations and Liaison Office, US Army Medical Research Institute of Chemical Defense; 1 January 1982: 10-1–10-18
61. Haskell CM. Drugs used in cancer chemotherapy. In: *Cancer Treatment*. Philadelphia, Pa: WB Saunders Co; 1990: 44–46.
62. Papirmeister B, Feister AJ, Robinson SI, Ford RD. *Medical Defense Against Mustard Gas, Toxic Mechanisms and Pharmacological Implications*. Boston, Mass: CRC Press; 1991: 80–82.



63. Papirmeister B, Gross CL, Meier HL, Petrale JP, Johnson JB. Molecular basis for mustard-induced vesication. *Fundam Appl Toxicol*. 1985;5:S134–S149.
64. Somani SM, Babu SR. Toxicodynamics of sulfur mustard. *Int J Clin Pharmacol Ther Toxicol*. 1989;27:419–435.
65. Orrenius, S. Biochemical mechanisms of cytotoxicity. *Trends Pharmacol Sci FEST*. 1985(suppl):15.
66. Augerson WS, Sivak A, Marley WS. 1986. *Chemical Casualty Treatment Protocol Development, Treatment Approaches—Mustards*. Vol 2. San Antonio, Texas: US Air Force Systems Command, Brooks AFB; 1986: 1-15–1-22. US Air Force Report HSD-TR-87-007.
67. Ireland MW. *Medical Aspects of Gas Warfare*. Vol 14. Washington, DC: Government Printing Offices; 1926: 93–98.
68. Requena L, Requena C, Sanchez M, et al. Chemical warfare. *J Am Acad Dermatol*. 1988;19:529–536.
69. Vedder EB. *The Medical Aspects of Chemical Warfare*. Baltimore, Md: Williams & Wilkins; 1925: 327.
70. United Nations. *Report of the Mission Dispatched by the Secretary-General to Investigate Allegations of the Use of Chemical Weapons in the Conflict Between the Islamic Republic of Iran and Iraq*. New York, NY: United Nations; 12 March 1986: 1–16. Report S/17911.
71. United Nations. *Report of the Mission Dispatched by the Secretary-General to Investigate Allegations of the Use of Chemical Weapons in the Conflict Between the Islamic Republic of Iran and Iraq*. New York, NY: United Nations; 19 August 1988: 1–15. Report S/20134.
72. United Nations. *Report of the Specialties Appointed by the Secretary-General to Investigate Allegations by the Islamic Republic of Iran Concerning the Use of Chemical Weapons*. New York, NY: United Nations; 12 March 1984: 25–47. Report S/16433.
73. United Nations. *Report of the Mission Dispatched by the Secretary-General to Investigate Allegations of the Use of Chemical Weapons in the Conflict Between the Islamic Republic of Iran and Iraq*. New York, NY: United Nations; 10 May 1988: 1–23. Report S/19823.
74. McNamara BP. *Medical Aspects of Chemical Warfare*. Alexandria, Va: Defense Technical Information Center; 1960: 7–28. Report AD 240713.
75. Bethlenfalvay NC, Bergin JJ. Severe cerebral toxicity after intravenous nitrogen mustard therapy. *Cancer*. 1972;29:366–369.
76. Zaniboni A, Simoncini E, Marpicati P, Montini E, Marini G. Severe delayed neurotoxicity after accidental high-dose nitrogen mustard. *Am J Hematol*. 1988;27:304.
77. Heully F, Gruninger M. Collective intoxication caused by the explosion of a mustard gas shell. *Annales Medecine Legale*. 1956;36:195–204.
78. Bennion S. Designing of NBC protective gear to allow for adequate first aid. *Milit Med*. 1982;147:960–962.
79. Chan P, ed. *Proceedings of the Vesicant Workshop*. Frederick, Md: US Army Medical Research and Development Command; 1987. Report USAMICD-SP-87-03.
80. Winton GB, Salache SJ. Wound dressings for dermatologic surgery. *J Am Acad Dermatol*. 1985;13:1026–1044.
81. Eaglstein WH. Experiences with biosynthetic dressings. *J Am Acad Dermatol*. 1985;12:434–440.
82. Walker IG, Smith JF. Protection of L-cells by thiols against the toxicity of sulfur mustard. *Can J Physio Pharm*. 1969;47:143–151.

83. McKinley MD, McKinley FR, McGown EI. *Thiosulfate as an Antidote to Mustard Poisoning: A Review of the Literature*. Washington, DC: US Army Medical Research Institute; 1982: 73–94. Report AD-A121-877.
84. Meyer-Doring HH. Die behandlung von beta-beta'-dichloridiathylsulfidverletzungen durch elektroforese mit cysteinhydrochlorid. *Arch Exper Path u Pharmakol*. 1950;209:443–455.
85. Resnik SS. Chemical peel with trichloroacetic acid. In: Roenigk RK, ed. *Dermatologic Surgery Principles and Practice*. New York, NY: HH Marcel Dekker, Inc.; 1989: 979–986.
86. US Department of the Army. *Treatment of Chemical Agent Casualties and Conventional Military Chemical Injuries*. Washington, DC: DA; 1974. Technical Manual 8-285.
87. US Department of the Army. *NATO Handbook on the Medical Aspects of NBC Defensive Operations*. Part 3, Chemical. Washington, DC: DA; 1973. Field Manual 8-9.

# Chapter 6

## ALLERGIC AND IRRITANT CONTACT DERMATITIS

MARK A. CROWE, M.D.\* AND WILLIAM D. JAMES, M.D.†

---

### INTRODUCTION

#### ALLERGIC CONTACT DERMATITIS

Allergic Contact Dermatitis due to Plants: Offending Agents  
Allergic Contact Dermatitis due to Plants: Geographical Distribution  
Other Allergic Contact Dermatitides

#### IRRITANT CONTACT DERMATITIS

Alkalis and Acids  
Hydrocarbons  
Diethyltoluamide Dermatitis  
Chloracne  
Irritant Contact Dermatitis due to Plants

#### OTHER CONTACT DERMATITIDES

Mechanical Injury  
Pharmacological Reactions  
Contact Urticaria

#### CONTACT DERMATITIS BY ANATOMICAL SITE

Eyelids  
Face  
Neck  
Trunk  
Abdomen  
Groin  
Hands and Feet

#### PATCH AND USE TESTING

#### TREATMENT

Removal of the Irritant  
Nonsteroidal Therapy  
Steroids

#### SUMMARY

\*Lieutenant Colonel, Medical Corps, U.S. Army; Dermatology Service, Madigan Army Medical Center, Tacoma, Washington 98431-5000; formerly, Walter Reed Army Medical Center, Washington, D.C. 20307-5001

†Colonel, Medical Corps, U.S. Army; Chief, Dermatology Service, Walter Reed Army Medical Center, Washington, D.C. 20307-5001

## INTRODUCTION

One of the most frequent dermatologic disorders requiring both outpatient and inpatient therapy that arises during military conflicts is dermatitis caused by contact with exogenous materials. In some regions of the world, contact dermatitis produces a significant proportion of those battlefield casualties that are dermatologic in nature.<sup>1</sup> During World War II, the Office of The Surgeon General reported 75,371 hospital admissions for treatment of contact dermatitis, with over 99% of those soldiers being returned to duty.<sup>1</sup> Under wartime conditions, inadequate facilities may limit proper personal hygiene, and the exposure to common chemical irritants and allergens can be prolonged.

During World War II, toxicodendrons (poison ivy and related plants) were the most frequent cause of plant dermatitis,<sup>2</sup> and reactions to topical therapies were also exceedingly common.<sup>3-5</sup> In 1944, Woolhandler<sup>6</sup> reported that over 10% of his military dermatologic practice was related to contact dermatitis, with fungus infections being the only dermatologic disorder that was more frequent. After the war, a report<sup>7</sup> of cutaneous diseases in U.S. Army Air Force personnel revealed that contact dermatitis to greases, solvents, and zinc chromate was the most common skin disease encountered. In this population, contact dermatitis was more frequent than pyodermas, fungus infections, or verrucae.

More recently, Allen reported that contact dermatitis was infrequent among troops in Vietnam but at times was an important source of discomfort and disability.<sup>8</sup> Although contact dermatitis resulted in only a small percentage of the total number of clinic visits to the 95th Evacuation Hospital in Da Nang, Vietnam, it was listed as one of the top ten dermatologic conditions treated.<sup>8</sup> Contact dermatitis also caused many minor casualties who were treated at battalion aid stations and returned to duty. Much of the decrease (from World War II rates) in the rate of contact dermatitis casualties referred to the evacuation hospital in Vietnam was believed to be related to the development of antibiotics, steroid preparations, and nonsensitizing creams after World War II. Thus, there is extensive information suggesting that contact dermatitis re-

sults in a constant drain on troop strength and readiness.<sup>8</sup> In addition, a delay in diagnosis may result in the prolonged loss of a soldier to a disorder that can be treated easily and effectively.

With the exception of phytodermatitis (plant-related dermatitis), contact dermatitis related to individual contactants rarely causes a significant impact on troop strength. The most likely situation in which contact dermatitis might produce significant numbers of casualties is if large numbers of soldiers were exposed to the same chemical agents (eg, mass exposure of soldiers in Vietnam to insect repellents and defoliants). Additional casualties can be avoided if the causative agent is identified and further exposure prevented.

In general, because dermatologic diagnoses tend to rely heavily on visual clues, the clinical history is less important to dermatologists than it is to most subspecialists. However, in the field of contact dermatitis, a detailed history is extremely important. When contact dermatitis is suspected and the contactant is not obvious, the medical officer must specifically query the soldier regarding environmental exposures. An occupational exposure history should include a detailed description of daily activities with emphasis on exposures to materials such as paints, dyes, cleaning solutions, soaps, and other materials used in the work environment. Often a site visit is productive. The soldier should be asked whether symptoms improve or worsen over weekends or vacations. It is important to inquire into exposures in the home and during recreational activities, exposures related to hobbies, and exposures from the use of any topical or oral therapy.

This chapter will emphasize potential sources of contact-related dermatitis in a battlefield environment. The modern U.S. Army includes support personnel who perform essentially every occupation encountered in the civilian sector, from combat laundry to the maintenance of sophisticated hardware. Materials other than plants that have resulted in contact dermatitis will be discussed if they have particular significance or are unusual and enlightening causes of contact dermatitis. Several excellent texts cover the topic of contact dermatitis in great detail.<sup>9-11</sup>

## ALLERGIC CONTACT DERMATITIS

Contact dermatitis is generally subdivided into allergic contact dermatitis (ACD) and irritant contact dermatitis. ACD is an acquired, type IV hypersensitivity response generated after exposure to an allergen. Not everyone will react to the allergen, and the allergic response does not occur during the primary exposure unless the soldier has been exposed to a closely related compound in the past.

Type IV hypersensitivity reactions consist of two distinct phases: the induction phase and the elicitation phase. During the induction phase, an allergen, or hapten, penetrates the epidermis where it is picked up and processed by an antigen presenting cell. Antigen presenting cells include Langerhans cells, dermal dendrocytes, and macrophages. The processed antigen is then presented to T lymphocytes, which undergo blastogenesis in the regional lymph nodes. One subset of these T cells differentiates into memory cells, while others become effector T lymphocytes that are released into the bloodstream.

The elicitation phase occurs when the sensitized individual is reexposed to the antigen. The antigen penetrates the epidermis and is again picked up and processed by an antigen presenting cell. The processed antigen is then presented to the circulating effector T lymphocytes, which, in turn, produce lymphokines. These lymphokines mediate the production of the inflammatory response that is characteristic of an ACD.

As a type IV hypersensitivity reaction, ACD has symptoms that usually develop hours to days after exposure. The dermatitis associated with allergic reactions is frequently very pruritic and may extend beyond the borders of the region exposed to the allergen. ACD is generally much more edematous and vesiculation is much more common than that seen in an irritant contact dermatitis. Relative to irritant contactants, very small quantities of allergens are required to stimulate allergic dermatitis. The most common causes of ACD are toxicodendrons (poison ivy, oak, or sumac), *p*-phenylenediamine, nickel, rubber compounds, ethylenediamine, potassium dichromate, and thimerosal.<sup>9</sup>

Patch testing can often confirm the etiology of an ACD. By placing standard concentrations of common allergens or specific ingredients in an impli-

cated product on the skin and leaving them covered for 2 days, one can identify the cause of the dermatitis. If the soldier has been previously sensitized to one of the agents under occlusion, the reexposure will produce the elicitation phase of a type IV hypersensitivity reaction resulting in pruritus, erythema, and vesiculation.

Irritant dermatitis, which is also called primary irritant dermatitis, is due to a nonallergic reaction resulting from exposure of the skin to an irritating substance and is much more common than ACD. Examples of irritant contact dermatitis include the reactions that result from contact with acids; alkalis; and metal salts such as cyanides of calcium, copper, mercury, nickel, silver, and zinc. Contact with the halogens and many hydrocarbons also produces irritant dermatitides. With a high-enough concentration, an irritant will cause dermatitis in any individual and the reaction may follow the first exposure. Significantly higher concentrations are required to induce irritant contact dermatitis than are required to stimulate an allergic reaction.

Soldiers with an irritant contact dermatitis may develop symptoms within minutes of the exposure. The dermatitis is often localized to the site of exposure and a burning sensation is more common than the intense pruritus often associated with ACD. The severity of the dermatitis depends on the concentration and dwell time of the irritant as well as the site and condition of the skin. Areas of the body with thick, dry skin are the most resistant to the effects of irritants.

### Allergic Contact Dermatitis due to Plants: Offending Agents

The family Anacardiaceae probably accounts for more cases of ACD than all other plant families combined. It is composed of about 70 genera and 600 species of trees, shrubs, and vines that are found mostly in the tropics but with some species in temperate regions. Genera of the family Anacardiaceae include *Anacardium*, *Gluta*, *Mangifera*, *Semecarpus*, and *Toxicodendron*. Poison ivy, poison oak, and poison sumac were classified in the genus *Rhus* until recently, when they were reclassified to the genus *Toxicodendron*. For example, poison ivy is

now termed *Toxicodendron radicans* rather than *Rhus radicans*. True members of the genus *Rhus* rarely cause contact dermatitis. The term rhus dermatitis is still commonly encountered and refers generically to ACD produced by exposure to poison ivy, poison oak, or poison sumac.

The antigen in these plants is an oleoresin known as urushiol, from the Japanese word *kiurushi*, meaning sap.<sup>12</sup> In poison ivy and poison oak, the active agent in urushiol is pentadecylcatechol. Slight molecular variations in catechols may result in large variations in the degree of antigenicity. Poison ivy and poison oak sap contain a near maximal percentage of these allergenic catechols.<sup>13</sup>

Prevention of ACD begins by educating the soldier in the recognition of common plants that may produce eruptions. The soldier should keep exposed skin to a minimum when in areas of high risk for exposure to toxicodendrons. If exposure to contactants is suspected, the exposed skin should be washed thoroughly with soap and water as soon as feasible. Soldiers returning from an area endemic for toxicodendrons should shower with soap to remove residual allergens. Soldiers should also be aware that plant resins on clothing, field jackets, and equipment can produce ACD many months after it was deposited.

### Poison Ivy and Poison Oak

Plants in the genus *Toxicodendron* produce a large percentage of the cases of phytodermatitis. The genus *Toxicodendron* includes two species of poison ivy, *Toxicodendron rydbergii*, a nonclimbing shrub, and *T radicans*, which can be either a shrub or a climbing vine. In addition, there are many subspecies of *T radicans* (Figures 6-1 and 6-2). The genus *Toxicodendron* also includes western poison oak (*T diversilobum*—Figure 6-3), eastern poison oak (*T toxicarium*—Figure 6-4), and poison sumac (*T vernix*). These plants do not contain resin canals and consequently uninjured plants do not induce a dermatitis: the plant must be injured or bruised before oleoresin containing the urushiol can contact the skin. Smoke from burning plants can cause a severe dermatitis. All parts of the plant are antigenic and, under controlled conditions, over 70% of the population in the United States will react to the urushiol in poison ivy and oak.<sup>14</sup> Vernacular names for poison ivy include (English) climbing or three-leaved ivy, climath, trailing or climbing sumac, mercury, black mercury vine, markry, mark-weed, picry; (French) *sumac radicaant*, *lierre toxique*; and (German) *Kletter-Gift Sumach*, *Rankender Sumach*, and *Gift Efeu*.

Vernacular names for poison oak include (English) western or Pacific poison oak, eastern poison oak; (French) *sumac irrégulièrement lobé*; and (German) *Verschiedenlappiger Sumach*.<sup>10</sup>

Oleoresin adheres to skin, clothes, equipment, and pets. Contaminated clothes can cause the eruption to recur even after prolonged storage. Oleoresin on the hands can be unintentionally spread to the face and genitals resulting in very severe eruptions (Figures 6-5 and 6-6). Blister fluid, on the other hand, does not contain urushiol and will not result in further contamination of the affected soldier or care providers.

The oleoresin that exudes from damaged areas of poison ivy, poison oak, and poison sumac will frequently form into a black deposit on the leaves, stems, or trunk. The patient seen in Figure 6-7 developed a characteristic dermatitis after exposure to oleoresin from poison ivy. In addition, the oleoresin on the skin darkened into a black, enamellike deposit. This characteristic of the oleoresin to darken on exposure to the air is found in many other members of the Anacardiaceae family. Beaman<sup>15</sup> reported sleeping on a foundation of poles in an area of rocky terrain in Malaysia. The next morning he discovered the poles, which were most likely from a species of *Gluta* that had been cut by his guide, had developed obvious black deposits. Dermatitis developed within 15 to 20 hours. It is this same attribute of the oleoresin that makes it useful as a marking agent when obtained from *Semecarpus anacardium* (the India marking nut tree) and that produces the color associated with the lacquer of the Japanese lacquer tree (*T verniciflua*). Leaves from plants suspected of being related to poison ivy can be crushed between sheets of white paper. The leaves are discarded and the oleoresin on the paper allowed to dry for a few minutes. Oleoresin from *Toxicodendron* should darken markedly.<sup>16</sup> Although no one characteristic is reliable for identifying *Toxicodendron*, the finding of dark black deposits on damaged plants and trees should alert the physician to the distinct possibility that the sap or resin can produce ACD.

**Signs and Symptoms.** Clinically, the typical urushiol eruption is manifested by erythema, edema, papules, vesicles, and bullae (Figure 6-8). Linear streaks are characteristic, but not always noted. Daily contact with the plant may result in an eruption 9 to 14 days after initial contact even in someone not previously sensitized.<sup>14</sup> In previously sensitized individuals the eruption can occur within hours to several days of exposure. Different parts of the body are more sensitive to urushiol or may be

**OK to put on the Web**

**Fig. 6-1.** *Toxicodendron radicans* subsp *radicans*. Poison ivy species found commonly in the eastern United States. The mature plant has leaflets that are usually unlobed and ovate (widest below the center). It climbs by aerial rootlets. Reprinted courtesy of J. D. Guin, Department of Dermatology, University of Arkansas, Fayetteville, Ark.

**OK to put on the Web**

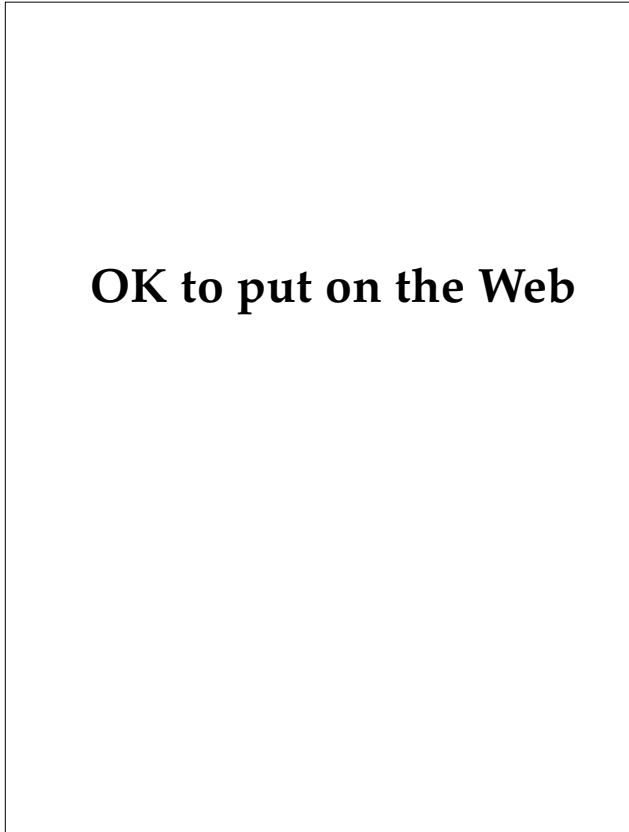
**Fig. 6-2.** *Toxicodendron radicans* subsp *radicans*. Poison ivy species found commonly in the eastern United States. Reprinted courtesy of J. D. Guin, Department of Dermatology, University of Arkansas, Fayetteville, Ark.

**OK to put on the Web**

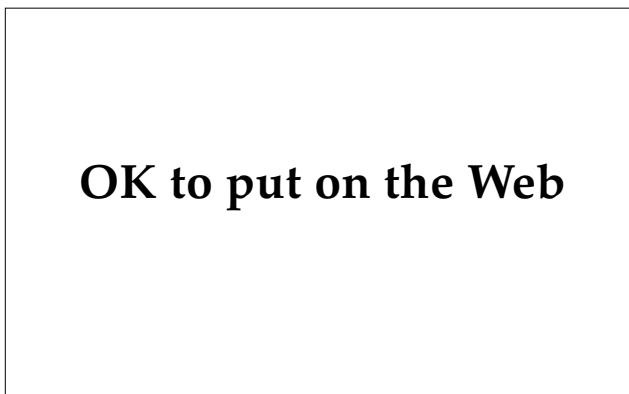**Fig. 6-3.** Western poison oak (*Toxicodendron diversilobum*). This plant grows in a variety of soil types in California, Oregon, and Washington. It may develop aerial roots and climb, although it is often seen as a shrub. The fruit is the largest of any of the toxicodendrons and often dangles like ripe cherries. The leaflets have rounded lobes resembling the leaves of a live oak. Reprinted courtesy of J. D. Guin, Department of Dermatology, University of Arkansas, Fayetteville, Ark.

**OK to put on the Web**

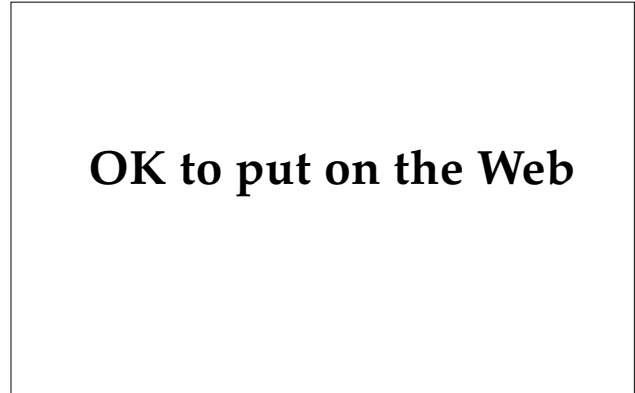
**Fig. 6-4.** Eastern poison oak (*Toxicodendron toxicarium*). Much smaller than western poison oak, this plant is found primarily in the southeastern United States. It is a small subshrub that does not climb, does not have aerial rootlets, and is found in sandy soil with poor mineral content. Leaflet morphology is extremely variable and may closely resemble white oak leaves. Reprinted courtesy of J. D. Guin, Department of Dermatology, University of Arkansas, Fayetteville, Ark.



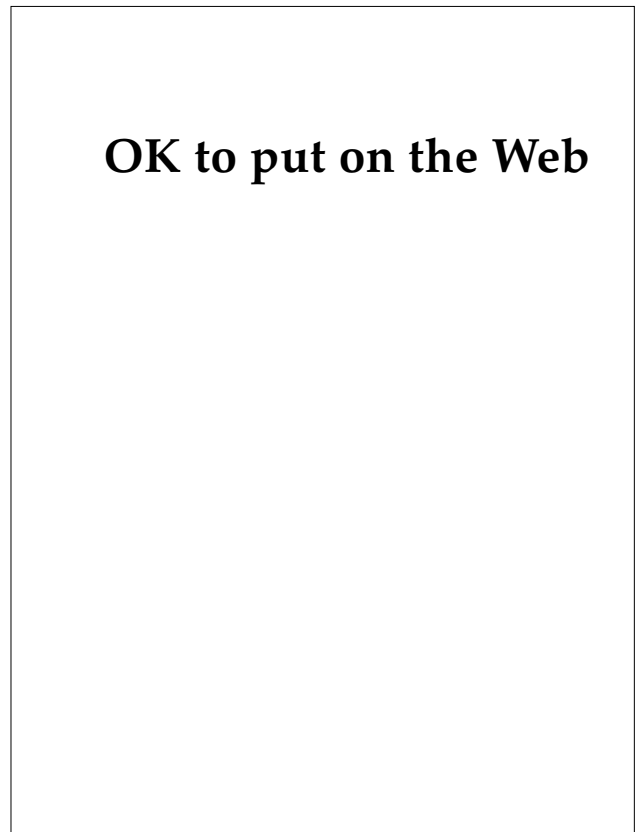**Fig. 6-5.** Rhus dermatitis. Oleoresin may be easily spread from the hands to other sites of the body, as in this patient. Severe facial dermatitis may also result when sensitized soldiers are exposed to smoke from burning toxicodendrons.



**Fig. 6-7.** Rhus dermatitis. The black deposit is residual oleoresin that has turned black on exposure to the air. Many members of the family Anacardiaceae possess this characteristic. Damaged trees and shrubs may develop black deposits as oleoresin oxidizes on exposure to the air.



**Fig. 6-6.** Rhus dermatitis involving the genital region. Oleoresins on the hands may be spread to this area of thin skin during the process of voiding, with unfortunate results. Severe perianal dermatitis may result when leaves are used to wipe the area following defecation. Reprinted courtesy of L. Lieblich, Department of Dermatology, State University of New York Downstate.



**Fig. 6-8.** Typical rhus dermatitis with linear vesicles, erythema, edematous papules, and bullae. The allergen that produces this dermatitis is an oleoresin, urushiol.



exposed at different times, resulting in the false impression that the eruption is spreading or is infectious. On rare occasions *Toxicodendron* exposure can result in urticaria or an erythema multiforme pattern.<sup>14</sup>

**Field Identification.** Several features of poison ivy, oak, and sumac may be useful in field identification. All species of poison ivy and oak have three leaflets per leaf (see Figures 6-1 through 6-4). Poison sumac contains 7 to 13 leaflets per leaf. The leaf stalk (petiole) has a groove where it attaches to the branch. Blooms and fruits arise in the angle between the leaf and the branch. Toxicodendrons change color earlier than most other plants. Old flower and fruit stalks often persist through the winter and the following growing season. Young leaves are frequently reddish in color and the mature fruit of toxicodendrons is tan or cream colored.<sup>13</sup>

The plant family Anacardiaceae has many other species that contain urushiol and also cross-react with poison ivy. The following plants are discussed because they represent a common source of sensitization in certain regions of the world or are of historical interest.

### Poison Sumac

Poison sumac (*T vernix*, *T pinnatum*, *Rhus venerata*) is a shrub or small tree usually only 2 to 3 m tall but occasionally as tall as 7 m. Compound leaves are up to 40 cm in length with 7 to 13 oval leaflets. Poison sumac is highly antigenic, resulting in severe contact dermatitis in sensitized soldiers. It is a native plant of eastern North America, growing in swampy areas. A related species, *T succedanea*, known as the wax tree, is native to Japan and China. *T succedanea* is used as a source of lacquer in Indochina and as a source of wax in Japan. Vernacular names include (English) poison sumac, poison dogwood, swamp sumac, poison elder; (French) *sumac vernig*, *bois chandler*; and (German) *Giftsumach*.<sup>10,13,14</sup>

### India Marking Nut Tree: "Dhobie Mark" Dermatitis

During World War II in the China-Burma-India theater of operations, service personnel developed an epidemic of patchy dermatitis caused by exposure to the India marking nut tree. The dermatitis consisted of circumscribed patches of intense pruritus, vesiculation, oozing, and, sometimes, a more chronic eczematoid reaction.<sup>17</sup>

In India and Malaysia, the black sap of the *Semecarpus anacardium* (also called the Ral or Bella

gutti [bhilawa]) tree is used as marking ink, hence its common name, marking nut tree. A pin is used to pierce the hard capsule of the nut and enough brown or black fluid is obtained to place a relatively permanent identifying mark on garments. Further investigation at the time revealed that this tree is a member of the Anacardiaceae family and is related to poison ivy. Shortly after their arrival, service personnel began having their clothes laundered by native washermen (dhobies). The service personnel developed patches of dermatitis at the site of the laundry (dhobie) mark.<sup>17</sup>

Fifteen to twenty percent of personnel whose clothes were laundered by dhobies developed dhobie mark dermatitis.<sup>17</sup> Most soldiers who react to poison ivy will develop an allergic dermatitis to the nut of the marking nut tree and to other plants and trees in this family. Before World War II, this condition had been known as dhobie itch or washerman's itch and was believed to result from a tropical dermatophytosis. In India and other countries, the terms dhobie itch and tinea cruris are sometimes used interchangeably.<sup>17</sup> However, it was never proved that cutaneous fungal infections resulted from having clothes washed by dhobies. Dhobie itch or dhobie mark dermatitis is a true ACD resulting from contact with a marking fluid that contains allergens very similar to those seen in poison ivy.<sup>17</sup>

The marking nut tree is a moderate-sized deciduous tree with large alternate, leathery oblong leaves measuring 20 to 60 cm long and 10 to 25 cm across. Flowers are small and greenish white, on stout, branching panicles about the same length as the leaves. The fruit is a 2.5-cm-long, smooth, black nut (Figure 6-9). The tree is native to India. Two related species (*S forstenii* and *S heterophylla*) located in Java and Sumatra are also potent sensitizers. About 60 related species are distributed from India to Ceylon, Burma, Thailand, Indochina, Taiwan, Australia, Micronesia, the Solomon Islands, New Caledonia, and Fiji. Contact dermatitis can result from contact with the stem, small branches, leaves, or juice of the nut. Vernacular names include (English) marking nut tree, bhilawa tree; (French) *anacarde d'orient*; and (German) *Tintenbaum*.<sup>1,10,17,18</sup>

### Japanese Lacquer Tree

The Japanese lacquer tree (*T verniciflua*) is 15 to 20 m tall with 25- to 50-cm-long leaves composed of 7 to 13 oblong or oval leaflets (Figure 6-10). The tree is native to Japan and central and western

## OK to put on the Web

**Fig. 6-9.** The nut of the marking nut tree or bhilawa of India (*Semecarpus anacardium*). Resins were removed by piercing the nut with a needle. As with other members of the family Anacardiaceae, the fluid turns black after exposure to the air. The black resin was used by washermen to mark clothing. This resulted in contact dermatitis at the site of the laundry mark. Reprinted courtesy of J. D. Guin, Department of Dermatology, University of Arkansas, Fayetteville, Ark.

## OK to put on the Web

**Fig. 6-10.** Japanese lacquer tree (*Toxicodendron verniciflua*). The tree grows up to 20 m in height and is native to Japan and central and western China. Leaves are odd-pinnate. Reprinted courtesy of J. D. Guin, Department of Dermatology, University of Arkansas, Fayetteville, Ark.

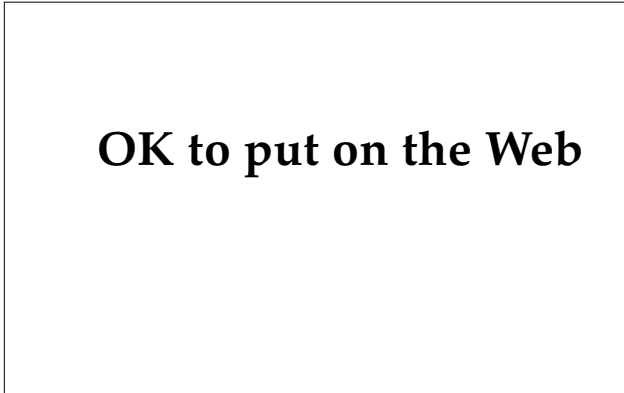
China. Its sap is used as lacquer in varnishes for floors and for lacquering boxes, tea pots, and furniture. "Lacquer dermatitis" affects areas of the body that come in contact with a lacquered surface. After World War II, American soldiers who were sensitive to poison ivy developed dermatitis after handling Japanese rifles that had been lacquered, and 12 American officers developed dermatitis on their arms from leaning on a recently varnished bar in Japan.<sup>19</sup> There are occasional reports of dermatitis to lacquered furniture even hundreds of years after application. Vernacular names include (English) Japanese lacquer tree, varnish tree; (French) *sumac a laque, vernis urai*; (German) *Lacksumach*; (Japanese) *urushi*; and (Chinese) *qi su*.<sup>10,20,21</sup>

### Mango

The mango (*Mangifera indica*) is a large tropical tree growing to heights of 15 to 18 m. The mango has wide, spreading branches, and produces a delicious greenish, yellowish, or reddish ovoid fruit measuring 10 to 20 cm in length (Figure 6-11). Some 35 species exist and are widely distributed naturally and through cultivation in Southeast Asia, India, Malaysia, and Burma. It is also extensively cultivated in tropical regions of southern Florida, Hawaii, and California, as well as Central and South America. Contact dermatitis develops most commonly in the perioral region (Figure 6-12) and on the hands and results from exposure to the peel, not the juice. The mango is eaten raw or made into jams, jellies, pickles, mango powder, and chutney. Timber is used for the production of furniture and boats, and for planking and plywood. The timber is known in some areas as asam. Vernacular names include (English) mango tree; (French) *manguier*; (German) *Mangobaum*; and many variations of mango such as mangii, mangga, manga, maga, and mangka.<sup>10,11</sup>

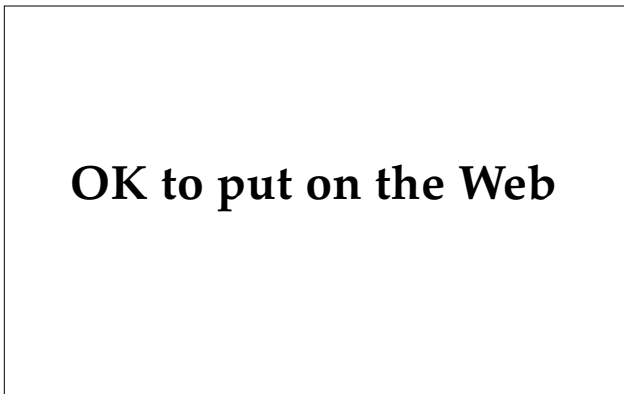### Cashew

The cashew (*Anacardium occidentale*) is a small (4–6 m) tree with a thick, crooked trunk that is native to Central America and northern South America and is cultivated throughout the tropical regions of the world and India. It is primarily cultivated for its nut, oil, and gum. Its timber, known as acajou, is used in house and boat building in South America. The wood produces a yellow gum that can blister the skin. Cashew sap blackens on exposure to the air and can produce contact dermatitis.

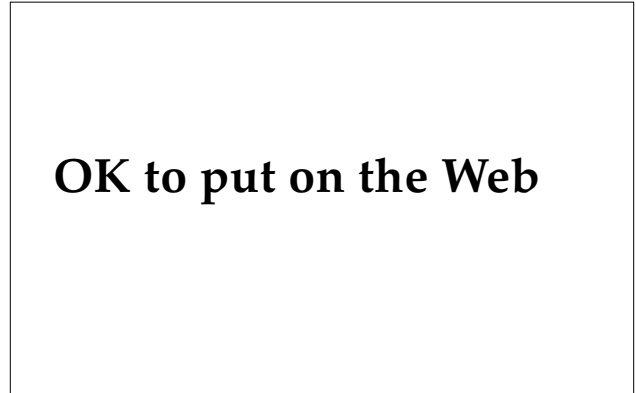


**Fig. 6-11.** Mango tree (*Mangifera indica*). Mango trees are widely distributed naturally and through cultivation. They grow to 18 m in height. Reprinted courtesy of J. D. Guin, Department of Dermatology, University of Arkansas, Fayetteville, Ark.

Apples from the cashew may be red or yellow, and the cashew nut dangles from the apex. The cashew “apple” is not a fruit, but the thickened stem at the base of the cashew nut. The cashew nut is innocuous unless contaminated with the shell oil; smoke from fires used to roast the freshly fallen nuts may be irritating to the skin and mucous membranes. The gum is used as a varnish to protect books and woodcarvings. Dermatitis may result from contact with all parts of the cashew tree except the roasted nut. Vernacular names include (En-



**Fig. 6-13.** Ginkgo (*Ginkgo biloba*). The ginkgo is an ornamental tree which may grow to 40 m. This a male ginkgo. The female is seldom planted as an ornamental tree because the fruits are foul smelling and can produce allergic contact dermatitis. Reprinted courtesy of J. D. Guin, Department of Dermatology, University of Arkansas, Fayetteville, Ark.

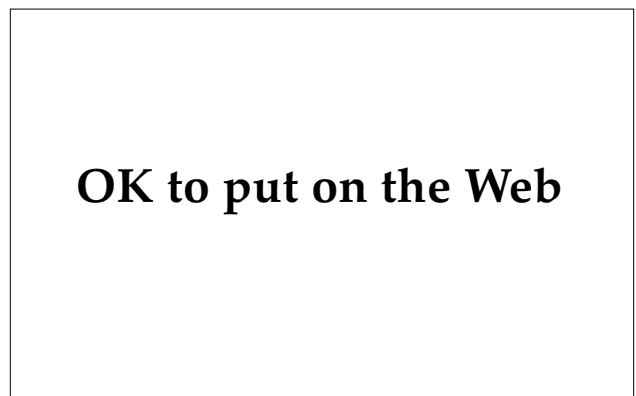

**Fig. 6-12.** Allergic contact dermatitis after consumption of a mango fruit. Dermatitis results from exposure to the peel, not the juice. Reprinted courtesy of R. Horn, Ithaca, N.Y.

glish) cashew nut tree; (French) *anacardier (noix et pomme d’acajou)*; and (German) *Kaschu, Acajuba, Acajoubaum, and Westindischer Nierenbaum*.<sup>10,22</sup>

### **Ginkgo**

The ginkgo (*Ginkgo biloba*) is now mostly grown as an ornamental tree in yards or along roadways in temperate regions. It is widely cultivated in Japan and is grown in Asia around Buddhist temples. The tree is sparsely branched and may grow to 40 m in height. Usually only the male plant is used in plantings because the female of the species produces yellowish fruits with a foul-smelling pulp and acidic outer coat (Figures 6-13 and 6-14). Epi-



**Fig. 6-14.** Ginkgo (*Ginkgo biloba*). Typical fan-shaped leaves and fallen fruit. Allergic contact dermatitis results from exposure to the fruit.

demic contact dermatitis may be produced in groups exposed to the fallen fruits.<sup>23</sup> The kernel of the fruit is sweet and edible. Ginkgolic acid is thought to be the possible allergen. Vernacular names include (English) maiden hair tree, ginkgo tree; (French) *arbre aux quarante écus, abricotier d'argent*; and (German) *Ginkyobaum*.<sup>10,23,24</sup>

### **Gluta**

The genus *Gluta* of the family Anacardiaceae includes approximately 30 species of trees and large shrubs that are distributed throughout most of Southeast Asia. In this region *Gluta* is a major cause of dermatitis. The timber of many species has blood-red heartwood and like many of the Anacardiaceae, the sap turns black on exposure to air.

Furniture made from wood of a *Gluta* species can produce dermatitis in sensitized individuals years after being harvested.<sup>15</sup> Even sitting under these trees may produce a dermatitis due to resins being washed down from the leaves in raindrops.

Some species grow in peat swamps and along rivers, where they may be the dominant vegetation. Individual trees are also widely scattered in lowland forest regions of Borneo. Vernacular names include *rengas* or *renghas* (Malaya) and *jitong*.<sup>15</sup> Other names include *hangus* (Penang), *rangus* (Sankar), *ruengas* (Sudan), *ingas* (Indonesia), and *angus* and *ligas* (Philippines). These names are also used for many trees in the genus *Melanorrhoea*, which is now combined with *Gluta*.<sup>20</sup>

### **Allergic Contact Dermatitis due to Plants: Geographical Distribution**

The standard approach for discussing plants that produce contact dermatitis is to identify a few important species, as was done in the preceding text. However, the military physician has a practical need to know which plants are common sensitizers in different climates and different continents. This regional report is not meant to serve local practitioners, who are usually well aware of the native plant offenders, but to help recently assigned medical officers, who are frequently unfamiliar with local flora. With the transplantation of exotic species to gardens in the United States, such a report also may benefit physicians in the United States. However, many factors make this approach difficult. Plant species can have a variety of common names and may vary markedly in appearance when grown in different climates within the same country. Limited botanical information is available from

some areas or this information may be buried in encyclopedic floral reviews. An excellent attempt at this type of review can be found in *Clinics of Dermatology*, April–June 1986.<sup>11</sup> It is beyond the scope of this chapter to provide more than a short review of the worldwide significance and distribution of certain allergenic plants.

### **Hawaii**

Although poison ivy, *T. radicans*, is not found in Hawaii, related plants in the family (Anacardiaceae) are the most common cause of ACD. The mango (*M. indica*) and the India marking nut tree (*Sanacardium*) are in this family and are found in Hawaii. The flower of the kahili tree (*Grevillea banksii*) is a significant cause of ACD in Hawaii, but contact with other parts of the plant does not result in dermatitis.<sup>25</sup> The kahili is a small tree originally from Australia that produces cylindrical spikes of red or white flowers.

A photosensitive contact dermatitis may result from exposure to furocoumarin- (psoralen-) containing members of the Rutaceae family. The peel of limes (*Citrus aurantifolia*) and black seeds and leaves of the mokihana tree (*Pelea anisata*) contain psoralens. The black mokihana seeds are strung into leis.<sup>26</sup>

Seaweed dermatitis results in intense itching and burning and affected over 100 people after swimming in the ocean on the windward shore of Oahu in 1958.<sup>27</sup> The areas of the body that were affected were always areas that had been covered by bathing suits. Symptoms developed a few minutes to several hours after exposure. The affected areas often resembled an acute burn. The etiology has been proven to be a blue-green algae, *Microcoleus lyngbyaceus*. This algae has a pantropic distribution, and episodic cases have been reported elsewhere in the Pacific and in Florida.<sup>27</sup>

Nettle dermatitis may occur from exposure to the native nettle, *Hesperocnide sandwicensis*, or to the stinging nettle, *Urtica ureus*, which was accidentally introduced from the continental United States.

### **The Americas and the Caribbean**

In North, Central, and South America and the Caribbean Islands, each region contains its own subspecies of Anacardiaceae with little or no cross-over into neighboring areas. For example,

- the subspecies of poison ivy found commonly in the United States extend no farther south than Florida, the northern Bahamas,

- and northern Baja California;
- the three subspecies of poison ivy in Mexico are found no farther north than the southern borders of Texas and Arizona;
- with few exceptions, dermatitis-producing Anacardiaceae of the genera *Metopium*, *Comocladia*, and *Pseudosmodium* are restricted to Central America; and
- only two species from the genera of South American dermatitis-producing Anacardiaceae are indigenous to southern Central America.

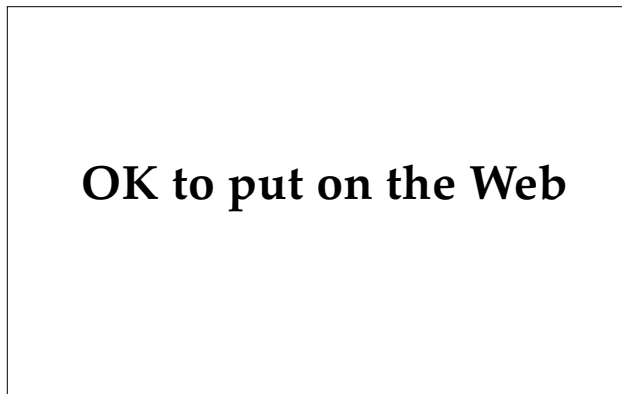Botanical information on Central America and the Caribbean is incomplete. Some flora studies<sup>11</sup> are being revised and few medical reports of plant dermatitis exist. Information is known about the introduced species such as the cashew, *A occidentale*, and the mango, *M indica*.<sup>11,22</sup> In addition, the Brazilian pepper tree, *Schinus terebinthifolius* (Figure 6-15), was introduced into these regions as an ornamental plant from South America. The cashew is found in much of the Caribbean and Central America. In these regions, the mango is the most popular fruit tree, having been introduced from tropical Asia. It is cultivated in areas of southern Florida, Texas, and California, and now grows throughout Central America and the Caribbean. *Laportea aestuans*, a stinging nettle with particularly persistent symptoms lasting a week or longer, has been accidentally introduced to southern Florida.<sup>28</sup>

Plants in the genus *Comocladia* are confined es-

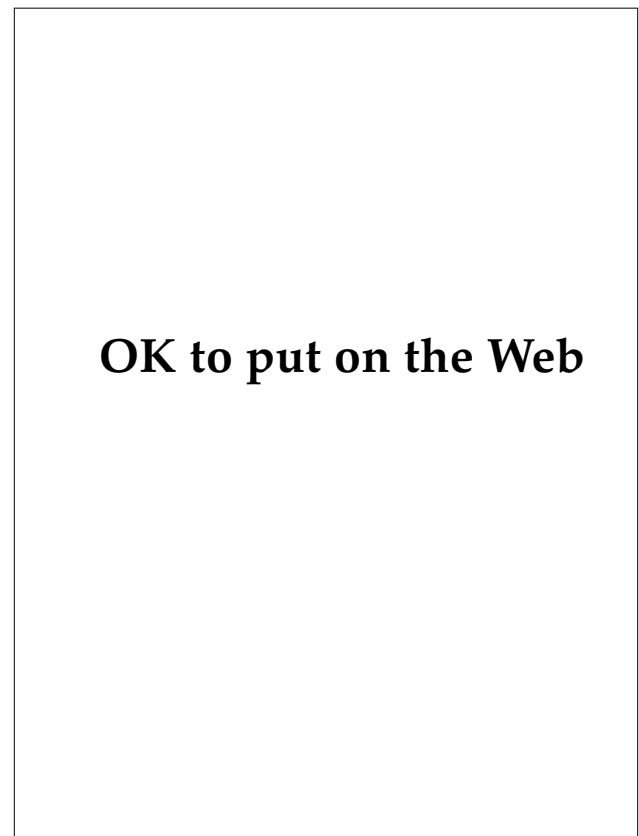entially to the Caribbean islands. *Comocladia glabra* is a small tree and like many plants that cause ACD, when damaged a whitish latex is produced that turns black on exposure to air.

*Metopium* consists of three species and is found in southern Florida, the West Indies, and Central America (southern Mexico, Belize, and Guatemala). Contact dermatitis can result from contact with all exterior parts of the tree except the pollen and wood (Figure 6-16). A large outbreak of dermatitis due to *Metopium* occurred among British Royal Air Force personnel clearing underbrush in the Bahamas.<sup>29</sup>

Four subspecies of *T radicans*, poison ivy, extend into southern Florida and Central America. *T striatum* is primarily a South American species, but it is very common in regions of Guatemala and



**Fig. 6-15.** Brazilian pepper tree (*Schinus terebinthifolius*). This tree is also known as Florida holly. Latex from the bark and crushed berries have been implicated as the most common cause of allergic contact dermatitis in south Florida. Reprinted courtesy of J. D. Guin, Department of Dermatology, University of Arkansas, Fayetteville, Ark.



**Fig. 6-16.** Poisonwood (*Metopium toxiferum*). This tree is found in the Florida Keys, the West Indies, and Central America. The leaves are pinnately compound, usually with five but sometimes three or seven leaflets. Allergic contact dermatitis results from exposure to all exterior parts of the tree. The bare wood and pollen are toxin free. Reprinted courtesy of J. D. Guin, Department of Dermatology, University of Arkansas, Fayetteville, Ark.

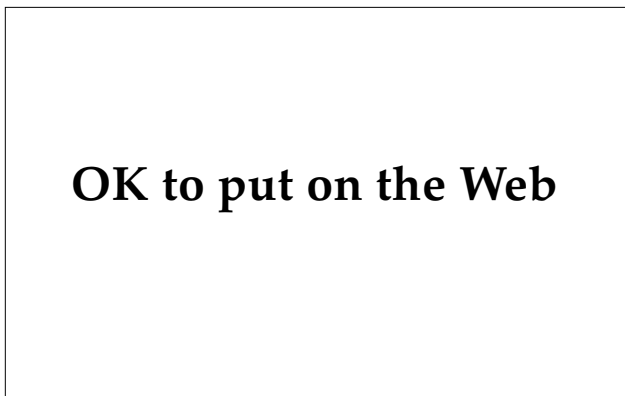Costa Rica. Newly formed leaves are bright red, pinnate, and have 11 to 15 leaflets.

The Brazilian pepper tree, *Schinus terebinthifolius* (see Figure 6-15), is found in Florida, the Bahamas, Cuba, Puerto Rico, and Mexico. In Florida, where it is known as Florida holly, it has been implicated as the most common cause of ACD.<sup>28</sup>

The manchineel tree, *Hippomane mancinella*, or beach apple, grows in southern Florida, the West Indies, and Central America. Because of its reputation for producing dermatitis,<sup>11,28</sup> it has been eradicated from the inhabited parts of Florida and persists only in remote areas of the Everglades.

Appearing in protected areas away from the seashore, the beach apple is a compact, densely leaved tree about 10 m tall. The deciduous leaves are elliptical and glossy. It produces large numbers of small, pleasant-smelling, crabapplelike fruits (Figure 6-17). The manchineel exudes a creamy white latex that produces an irritant dermatitis. Biting into the fruit produces severe oral pain, profuse salivation, and occasional dysphagia. Keratoconjunctivitis and possibly an ACD may also be produced. Rain or dew falling off the leaves has been reported to produce conjunctivitis and dermatitis.<sup>28</sup>

Few Anacardiaceae have been described in South America, with the majority coming from the genera *Toxicodendron*, *Lithraea*, *Maurin*, *Tapirira*, and *Loxopterigium*. The cashew, mango, and Brazilian pepper tree are widespread and abundant in much of South America and are all well-known sources of contact dermatitis.



**Fig. 6-17.** Manchineel or beach apple (*Hippomane mancinella*). The tree is compact and densely leaved, and grows to 10 m in height. Dermatitis can result from exposure to latex from the trunk, from the fruits, or from rain dripping from the leaves. Reprinted courtesy of J. D. Guin, Department of Dermatology, University of Arkansas, Fayetteville, Ark.

*T succedanea*, also known as charao or the Indochina lacquer tree, was introduced into Brazil from Indochina for the production of lacquer. *T verniciflua* and *T radicans* have also been cultivated in Brazil. *T diversilobum* has been cultivated in Argentina as an ornamental.

*Lithraea caustica*, or litre, is a large tree that grows abundantly in Chile and that to Chileans is synonymous with the family Anacardiaceae. Despite its high potential for causing contact dermatitis, it is burned as a source of heat and its hard wood is used in the construction of homes and boats. Several species of *Lithraea* cause contact dermatitis and all are generally restricted to southern South America.<sup>30</sup>

### Asia

As elsewhere, in Asia members of the family Anacardiaceae probably cause more dermatitis than all other families combined. Asia may well have the greatest number of dermatitis-producing species of any continent, with some 250 native species. The largest concentration of Anacardiaceae is in Southeast Asia. Five genera are well known as documented causes of ACD: *Anacardium*, *Gluta*, *Mangifera*, *Semecarpus*, and *Toxicodendron*. Another group of genera probably contain plants of similar allergenic potency, but are much less well studied: *Camptosperma*, *Drimycarpus*, *Holigarna*, *Melanochyla*, *Nothopegia*, *Pentaspadon*, and *Swintonia*. The genera *Buchanania*, *Lannea*, *Parishia*, and *Spondias* include plants that may cause contact dermatitis, but specific documentation is lacking.<sup>31</sup>

Most of the allergenic Anacardiaceae of tropical Asia are trees in primary forests. The genus *Anacardium* is represented by *A occidentale* (cashew), which is widely planted in the Asian tropics. The genus *Gluta* includes about 30 species of trees and large shrubs and is a major cause of plant dermatitis in Southeast Asia.<sup>31</sup> *M indica*, mango, is only one of the 35 or so species of *Mangifera* distributed throughout Southeast Asia.<sup>31</sup> Although a perioral dermatitis following ingestion of mangos is the most common occurrence (see Figure 6-12), dermatitis has also resulted from the sap, bark, smoke from bonfires, and raindrops that have dripped off the leaves of the more toxic species of *Mangifera*. Members of the genus *Semecarpus* include 60 species distributed from India through Southeast Asia to Fiji.<sup>31</sup> *S anacardium*, the India marking nut tree discussed previously, is only one example. Many species of *Toxicodendron* are found in China, Japan, and Southeast Asia. Several of these are used commercially as a source of lacquer. *T verniciflua* is generally known

in English as the Chinese lacquer tree, in Japanese as *krushi*, and in Chinese as *qi su*.<sup>31</sup>

### Australia

The flower of the kahili tree (*Grevillea banksii*, also found in Hawaii) can produce an ACD. An Australian stinging nettle, *Dendrocnide moroides*, produces piloerection, local vasodilation, sweating, and severe pain. Superficial lymphatics and proximal lymph nodes become tender.<sup>28</sup>

### Other Allergic Contact Dermatitis

Although less likely than toxicodendrons to produce numerous battlefield casualties, many products in the soldier's environment may produce acute, chronic, or recurrent dermatitis resulting in inconvenience to the soldier or temporary loss of his or her services from the unit: *p*-phenylenediamine, nickel, rubber, ethylenediamine, potassium chromate, and many other chemicals are major sources of ACD. Often the pattern of dermatitis in these cases is not instantly recognizable as ACD, and, unless the correct diagnosis is considered, the soldier may suffer recurrent, preventable episodes of dermatitis requiring further evaluation and lost time from the unit. Reactions to each individual item may be relatively uncommon, but ACD after exposure to these agents as a group is very common.

### Topical Drugs

Overtreatment with irritating and sensitizing drugs during World War II frequently caused more disability than the diseases that were being treated.<sup>3,5</sup> Tincture of iodine, Frazier's solution, topical penicillin, sulfonamide ointments, strong salicylic acid preparations, and Whitfield's ointment were frequently misused, resulting in increased casualties.<sup>3,5</sup> Ointments, pastes, and occlusives should be used with extreme care, particularly in warm tropical climates, because they may produce significant maceration. Frazier's solution, an antifungal agent supplied in jungle kits during World War II, was responsible for much overtreatment because of self-medication by soldiers.<sup>3</sup>

During World War II, topical use of penicillin resulted in frequent reports of allergic dermatitis. Since the banning of topical penicillin, neomycin has become the most sensitizing topical antibacterial preparation used.<sup>9</sup> Neomycin is particularly likely to result in sensitization when applied on

stasis ulcers, in chronic otitis externa, and on chronic eczematous dermatitis. Intermittent use of the drug on minor cuts and wounds probably is not associated with an increased risk of sensitization. Neomycin has been included as a topical antibiotic in many ointments, creams, and lotions (Figure 6-18). It cross-reacts with gentamicin, kanamycin, spectinomycin, streptomycin, and tobramycin. Neomycin-sensitive patients who are given these antibiotics intravenously may develop a severe systemic eczematous contact-type dermatitis. The soldier shown in Figure 6-19 developed itching and redness on the lower leg near the edge of the boot but was negative on patch testing to samples from the boots. The eruption proved to be an allergic reaction to neomycin that the soldier had used as self-medication for a local irritation. Patch testing for neomycin was strongly positive.

Skin eruptions resulting from topical antibiotics are not limited to neomycin. Topical bacitracin, polymyxin, gentamicin, clindamycin, erythromycin, chloramphenicol, tetracycline, and nystatin are all causes of allergic dermatitis, though somewhat rare.

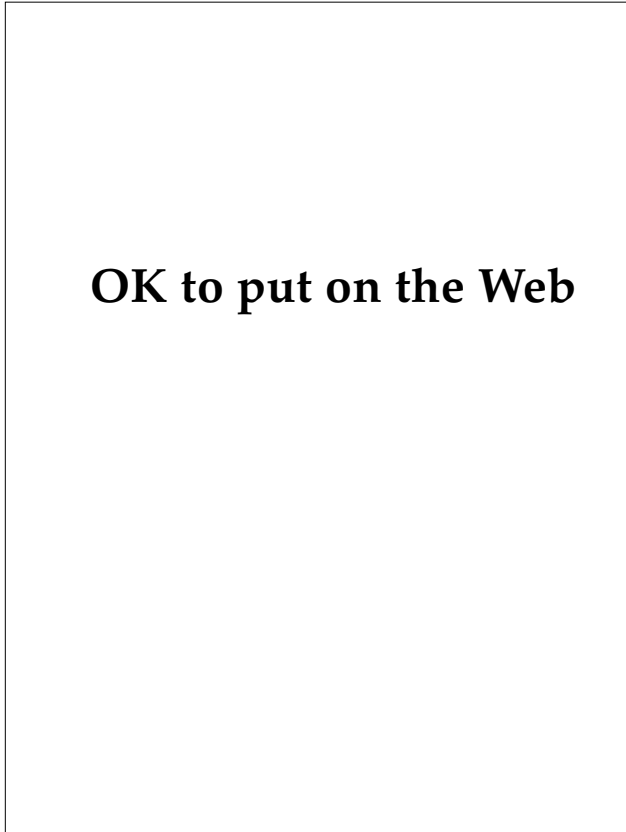
Whitfield's ointment contains 6% salicylic acid and 12% benzoic acid in petrolatum. It is a rare sensitizer, but the benzoic acid may produce a nonallergic contact urticaria, particularly when used in an intertriginous area. Antifungal agents such as tolnaftate, haloprogin, clotrimazole, miconazole, and econazole are very rare sensitizers but may cause an irritant dermatitis when used in intertriginous areas.

Benzocaine is a common and potent sensitizer found in hundreds of topical medications including

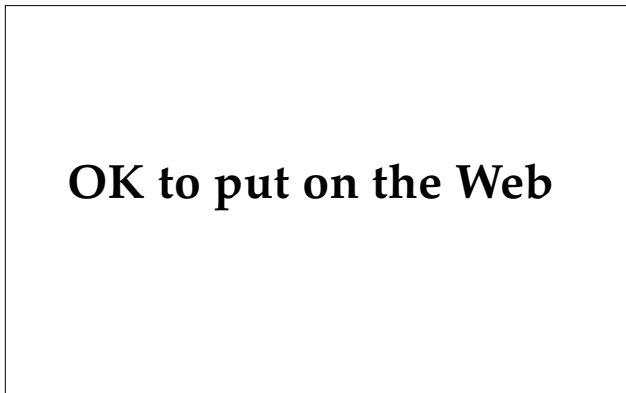

**OK to put on the Web**

**Fig. 6-18.** Allergic contact dermatitis to neomycin. Neomycin is included in numerous topical antibiotic creams and is a common sensitizer.



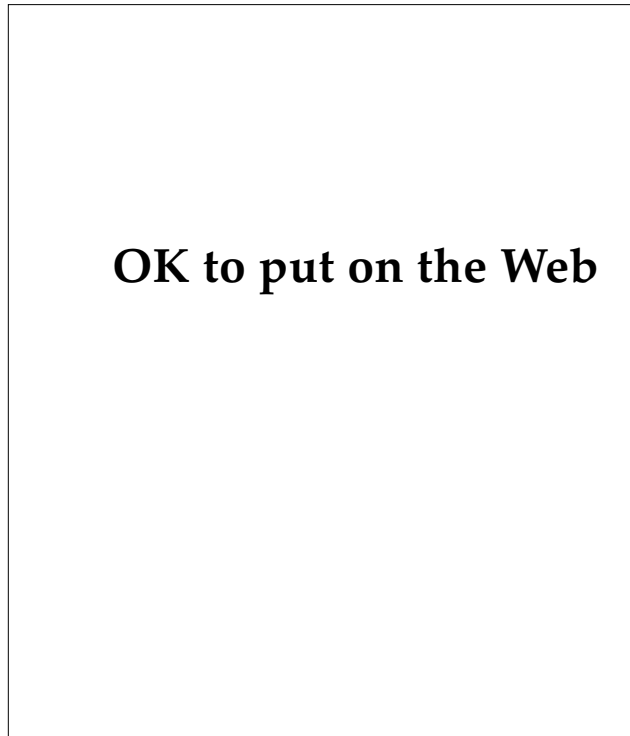
**Fig. 6-19.** Allergic contact dermatitis to neomycin. The soldier was initially felt to have an allergic reaction to material in his boots. That the soldier had been using an antibiotic cream containing neomycin was only discovered after negative testing of the boot material. Patch testing to neomycin was strongly positive.



**Fig. 6-20.** Allergic contact dermatitis to Lanacane (benzocaine). Benzocaine is an anesthetic in numerous topical preparations used to treat burns, bug bites, and abrasions.

burn remedies, athlete's foot therapies, topical analgesics, sore throat lozenges, astringents, wart remedies, and various antibacterial compounds (Figure 6-20). Eczematous, ulcerated, or burned skin is particularly likely to become sensitized to benzocaine. Because benzocaine cross-reacts with procaine, tetracaine, and cocaine, these should be avoided when treating the benzocaine-sensitive soldier. In addition, because benzocaine is a derivative of *p*-aminobenzoic acid (PABA), benzocaine-sensitive soldiers should avoid using sunscreens that contain PABA or glyceryl PABA (Figure 6-21). Benzocaine-sensitive soldiers can be safely treated with lidocaine, mepivacaine, prilocaine, pramoxine, and nupercaine. Amide anesthetics such as lidocaine, dibucaine and mepivacaine are very rare sensitizers. Methylparaben, a preservative found in some anesthetic solutions, is also a sensitizer.<sup>9</sup>

A variety of ingredients are added to topical agents including preservatives, stabilizers, antioxidants, and emulsifying agents. Ethylenediamine is a stabilizer in medicated creams. Mycolog cream



**Fig. 6-21.** Allergic contact dermatitis to PABA. *p*-Aminobenzoic acid (PABA) is an active ingredient in sunscreens and can produce allergic contact dermatitis in sensitized patients.

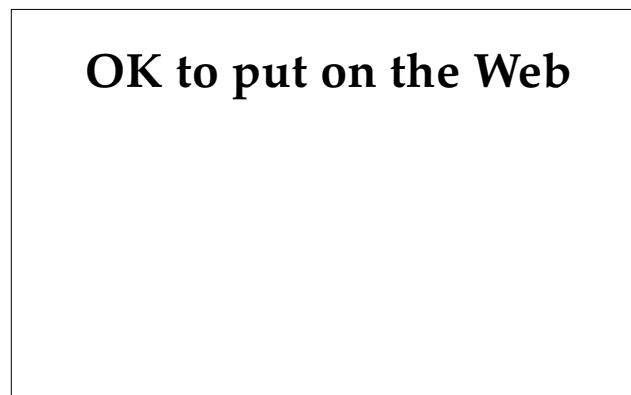


contained ethylenediamine and was a very common cause of sensitization until its replacement with Mycolog-II (nystatin and triamcinolone acetonide, manufactured by Westwood-Squibb, Buffalo, N.Y.), which lacks ethylenediamine, neomycin, or gramicidin (Figure 6-22). Ethylenediamine-sensitive soldiers should avoid aminophylline (which contains theophylline and ethylenediamine), hydroxyzine (Vistaril [manufactured by Pfizer, New York, N.Y.] or Atarax [manufactured by Roerig, New York, N.Y.]), and Vasocon-A eye drops (naphazoline hydrochloride and antazoline phosphate, manufactured by Cooper-Vision, Rochester, N.Y.).

**Sunscreens**

PABA, PABA esters, cinnamates, and benzophenones are used in sunscreens to block primarily ultraviolet B (UV-B) radiation. UV-B is that part of the sun’s radiation that is most responsible for producing sunburns. The longer wavelength light, ultraviolet A (UV-A), can potentiate the effects of UV-B. The UV-A-blocking ingredient, dibenzoylmethane, is used in Photoplex (avobenzone and padimate O, manufactured by Allergan Herbert, Irvine, Calif.). Opaque sunscreens such as zinc oxide, titanium dioxide, kaolin, talc, and iron oxide reflect and scatter UV radiation. The opaque sunscreens and dibenzoylmethanes rarely produce ACD.<sup>32</sup>

PABA and its esters can produce an ACD, and PABA-sensitive soldiers may develop cross-reactions on exposure to *p*-phenylenediamine, procaine, sulfonamides, and azo dyes.<sup>33</sup> The patient shown in



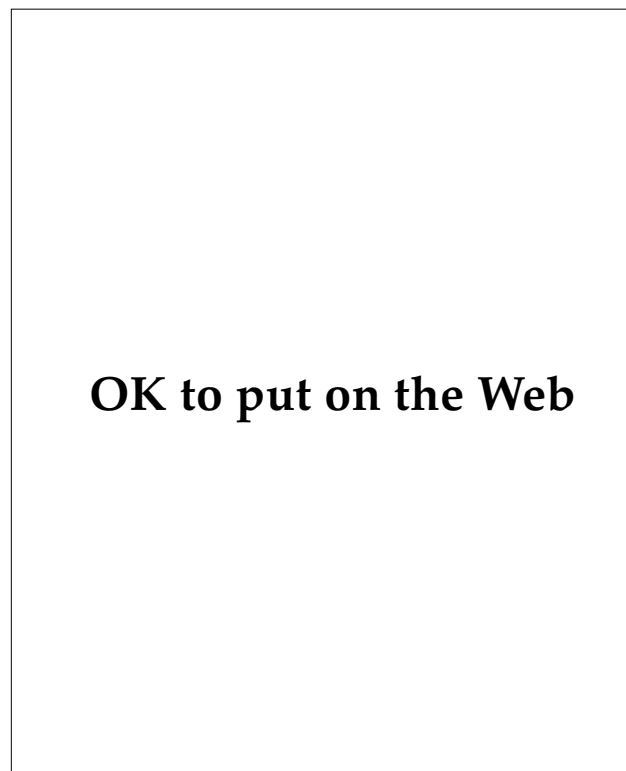
**Fig. 6-22.** Allergic contact dermatitis to Mycolog. Ethylenediamine is a very common sensitizer that was in Mycolog cream. It has been removed from Mycolog-II.

Figure 6-21 developed a severe perioral contact dermatitis from the PABA in RVPaba Lip Stick. Benzocaine is a PABA derivative and benzocaine-sensitive soldiers should be cautioned to avoid PABA or glyceryl sunscreens. PABA esters, digalloyl trioleate, or cinnamates also may produce an allergic photosensitization reaction.

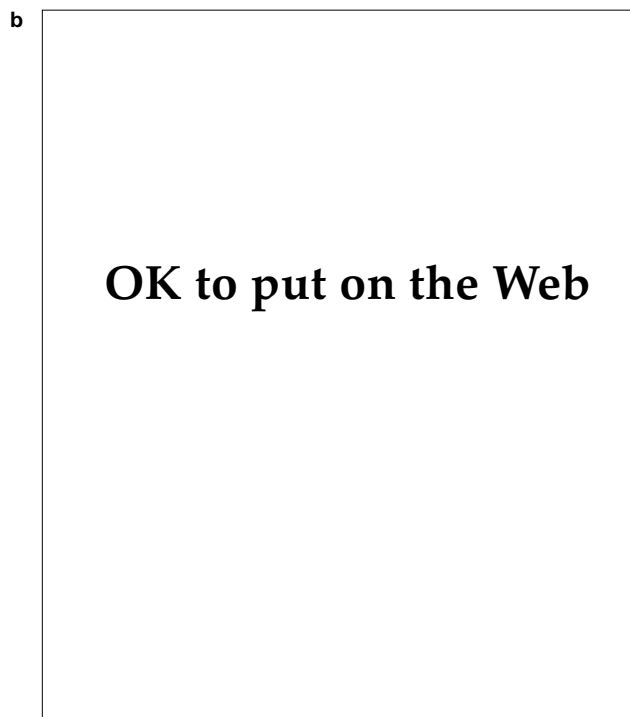
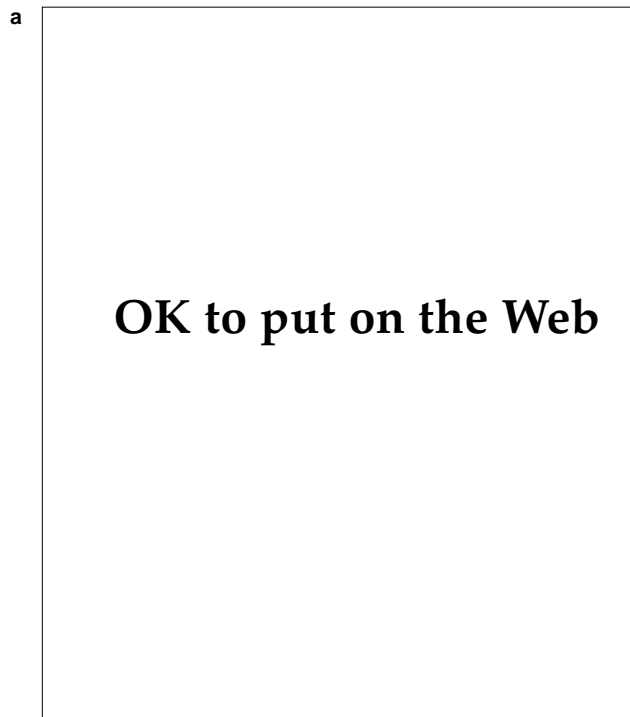
Benzophenones used in sunscreens can produce ACD, immediate urticarial reactions, and photoallergic reactions.<sup>34</sup> Benzophenones are also widely used in textiles and plastics to provide colorfastness and protection from UV radiation.<sup>9</sup>

**Metals**

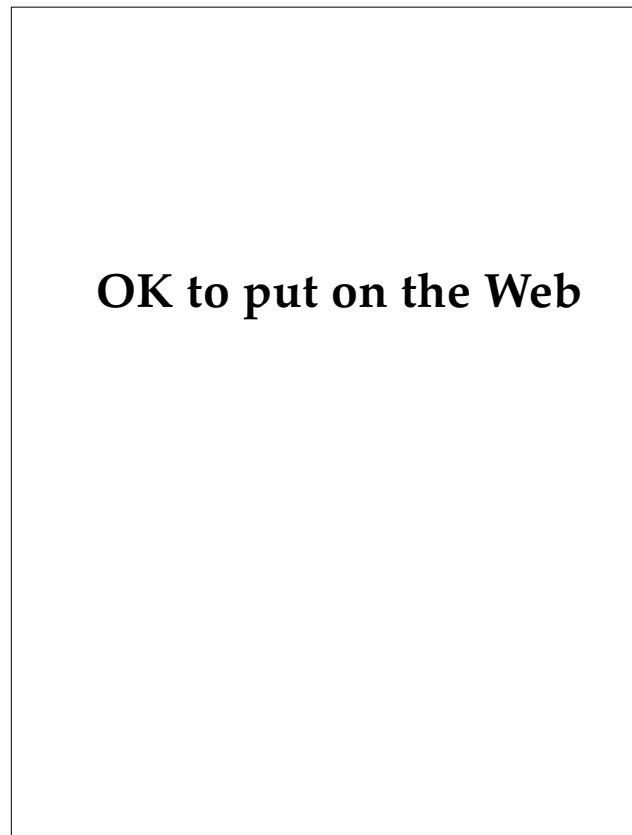
Metal dermatitis most frequently results after exposure to nickel, chromates, and mercury, but can also follow exposure to arsenic, gold, platinum, and other metallic compounds. With the exception of nickel, most pure metals do not cause ACD and must be in the form of a metallic salt in order to produce hypersensitivity. Positive patch test re-



**Fig. 6-23.** Allergic contact dermatitis to nickel. Nickel in chains that are used to hold identification tags and jewelry can produce dermatitis in sensitized soldiers.



**Fig. 6-24.** (a) Nickel dermatitis from metal buttons in clothing. Allergic contact dermatitis from nickel may result from exposure to metal buttons, zippers, snaps, coins, etc. (b) Closer view of nickel dermatitis from metal buttons in clothing. Reprinted courtesy of D. Cuzzo, Dermatology Service, Walter Reed Army Medical Center, Washington, D.C.

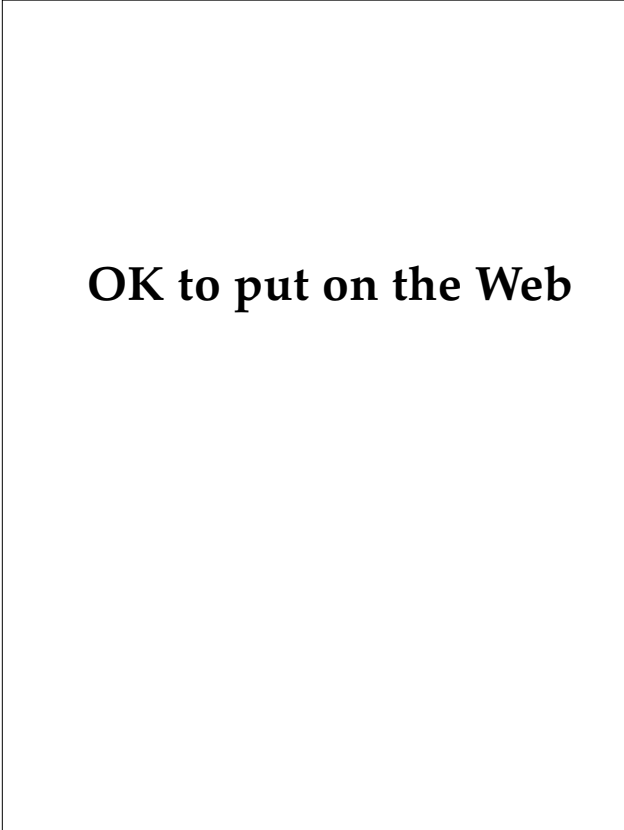


**Fig. 6-25.** Nickel dermatitis from a watch band and ring. Gold- or silver-plated jewelry may produce dermatitis when the plate is worn away, exposing underlying nickel.

sults to a metallic salt do not usually indicate sensitivity to the pure metal. Allergic sensitivity to metals is usually highly specific, and cross-sensitivity with other metals is exceptional.

**Nickel.** Nickel-containing products are extremely common and cause more cases of ACD than all other metals combined. Nickel dermatitis has resulted from contact with hair pins, earrings, spectacle frames, metal identification tags<sup>35</sup> (Figure 6-23), chains, metal buttons in clothing (Figure 6-24), zippers, metal coins carried in pockets, watch bands, bracelets, metal arch supports, and nickel in bullets and shrapnel. The patient shown in Figure 6-25 developed nickel dermatitis under both his watch and ring.

Women are more commonly allergic to nickel than men. The most common cause of nickel dermatitis in women is contact with jewelry that contains nickel. Women who have their ears pierced with nickel-plated instruments very frequently become sensitized. Earlobe dermatitis is almost pathognomonic for nickel dermatitis (Figure 6-



**OK to put on the Web**

**Fig. 6-26.** Nickel dermatitis of the earlobe. Earlobe dermatitis such as this is almost pathognomic for nickel sensitivity.

26).<sup>36,37</sup> Men tend to become sensitized to nickel more commonly through industrial exposures.

Perspiration containing sodium chloride can combine with nickel to form nickel chloride, resulting in a more severe dermatitis. Even extremely small quantities of the metal will produce dermatitis. Widespread nickel dermatitis may result when nickel contaminates perspiring fingers. Sweat, friction, and pressure will all increase the frequency of contamination and severity of the eruption. Prevention of sweating can decrease or prevent nickel dermatitis.

Patch testing for nickel is done with 5% nickel sulfate solution. The U.S. Indian head nickel can also be used in patch testing. Trace amounts of soluble nickel can be detected in suspected metal objects using the dimethylglyoxime (DMG) spot test. Two or three drops of 1% DMG and 10% ammonium hydroxide solution are placed on a white cotton-tipped applicator. This applicator tip is then rubbed against any objects that are suspected of

containing soluble nickel. Appearance of a pink color on the applicator tip is a positive result (Figure 6-27). This technique can be used to test jewelry, buttons, keys, scissors, door knobs, or other metallic objects. A positive test is proof of the presence of nickel. Although this test is sensitive, a negative test result does not absolutely eliminate the possibility that nickel is present.<sup>38-40</sup>

**Chromates.** Chrome salts are used in the processing of leather goods and may cause an allergic dermatitis. Chromates are corrosive and irritating as well as sensitizing. In addition to leather goods, exposure to chrome salts can occur during contact with matches, paints, cement, diesel engines, and photographic processing solutions. Chromium metal and stainless steel (which contains chromium) do not cause allergic dermatitis. Apparent contact dermatitis related to these metals may be due to associated nickel. Patch testing for chrome is performed with 0.5% potassium dichromate.

**Mercury.** Mercury salts can cause irritant or allergic dermatitis. Phenylmercuric salts are used



**OK to put on the Web**

**Fig. 6-27.** Dimethylglyoxime (DMG) spot test showing a positive (pink) reaction for nickel. The test is performed by adding a few drops of each test solution to a cotton swab and rubbing the metallic object.

as weed killers, fungicides, and insecticides and may cause an allergic dermatitis on exposed skin. Mercuric compounds may also be found in cosmetic creams, suppositories, dental amalgams, and solder used in dry batteries. Merthiolate is an organic mercurial compound that can result in sensitization. Patch testing is done with 0.05% mercuric bichloride.

**Arsenic.** Arsenic is a sensitizer in dyes used in wallpaper, chalk, artificial flowers, and fabrics, and in some disinfectants and weed killers. Arsenic is also used in embalming, animal skin preservation (tanning), printing, farming, and gardening.

**Gold.** Gold dermatitis is uncommon, but may occur as a result of exposure to gold salts in jewelry. In cases where gold dermatitis is suspected, the article of jewelry should be tested with dimethylglyoxime to assure that nickel is not present. Patch testing for gold salt allergy is done with 1% gold chloride solution.

Many cases of gold dermatitis were reported in association with gold rings manufactured using gold contaminated with radon. The source of the contamination was apparently gold from reclaimed, decayed radon-gold seeds. The contaminated gold rings may produce radiation dermatitis and squamous cell carcinoma of the finger.<sup>41</sup>

**Other Metal Dermatitides.** Platinum dermatitis may occur after exposure to platinum salts. Platinum in jewelry causes a dermatitis similar to that caused by nickel. Patch testing can be performed with 1% platinum chloride solution. Zinc, aluminum, copper, and antimony are rare sensitizers, but are frequent irritants.

### Shoes


Despite the warm, humid environment inside shoes, shoe dermatitis is relatively uncommon. To identify the likely allergens involved in shoe dermatitis, the healthcare provider must ascertain how the shoe is manufactured and what products and chemicals are used. Unfortunately, this task is frequently extremely difficult. Most shoes sold in the United States are now manufactured in part or wholly outside the United States. The combinations of glues, resins, fabric, rubber, dyes, metals, finishes, and leathers that may be combined in a modern shoe or boot make it impossible to identify every potential allergen. However, several specific agents are routinely used in patch testing when shoe dermatitis is suspected. These agents include antimildew agents (creosol, phenylmercuric nitrate, phenylphenol); nickel; dyes (aminoazobenzene,

lanolin, *p*-phenylenediamine); leather tanning agents (formaldehyde, glutaraldehyde, potassium dichromate); neoprene and neoprene cements; polyurethanes and polyurethane cements; and rubber and rubber cements (carba mix, thiuram mix, colophony, mercapto mix, mercaptobenzothiazole, and isopropyl-*p*-phenylenediamine [IPPD]).<sup>42,43</sup>

ACD caused by leather is usually related to tanning agents and dyes. Most cases are associated with chrome used in the tanning process.<sup>44,45</sup> ACD rarely results from formaldehyde and glutaraldehyde used as leather tanning agents or by leather dyes. Scutt<sup>46</sup> reported an epidemic of 86 cases of leather shoe dermatitis in sailors of the British Royal Navy assigned to the Far East. The dermatitis was caused by chromates in leather sandals that were worn in direct contact with the skin. A severe, debilitating dermatitis resulted. Contact dermatitis to trivalent chrome salts used in tanning is detected by patch testing with 0.5% potassium dichromate.

Although synthetic materials are replacing rubber in many shoes, rubber allergy is still the most common cause of shoe contact dermatitis in the United States. The rubber accelerators mercaptobenzothiazole and tetramethylthiuram disulfide are the most common allergens found in rubber shoe dermatitis. IPPD is a rubber antioxidant and is a less common cause of contact dermatitis, but it has been shown to produce a purpuric shoe dermatitis.

Patch testing can be done using pieces of the shoe soaked in water and applied under occlusion to the medial forearm or back for 48 hours. Depending on the location of the allergen in the shoe, dermatitis can involve the dorsal or plantar surface (Figure 6-28). The instep, toe webs, and flexural crease areas of the



**OK to put on the Web**

**Fig. 6-28.** Allergic contact dermatitis to shoes. Allergic shoe dermatitis may result from exposure to glues, resins, fabric, rubber, dyes, metals, finishes, or leather.

toes are usually spared. Involvement of these areas should suggest the possibility of a secondary bacterial infection or tinea pedis. The differential diagnosis also should include a mechanical irritant dermatitis, dyshidrosis, pustular psoriasis, lichen planus, and epidermolysis bullosa simplex.

### **Rubber Compounds**

One potentially very significant allergen in the military is the rubber liner in the standard-issue gas mask. The soldier whose arm is shown in Figure 6-29 gave a history of burning, pruritus, and erythema shortly after putting on her gas mask. A small sample of the black rubber liner was taped to her forearm. Within 2 hours she noted significant pruritus and within 24 hours she developed the erythema and vesiculation characteristic of ACD. The patient in Figure 6-30 developed a similar response from exposure to rubber chemical-protective gloves.

Soldiers may show either an acute contact urticaria or a delayed-type hypersensitivity reaction in response to rubber. Most reactions to rubber represent a delayed hypersensitivity reaction. With only rare exceptions, reactions to rubber are due not to the rubber itself, but to the chemicals added in the manufacturing process. Antioxidants and accelerators used in the manufacturing process cause most of the ACD associated with processed rubber. Antioxidants are added to help preserve the rubber; *p*-phenylenediamine is a common antioxidant and sensitizer. Vulcanization or curing of raw rubber results in cross-linking of polymer chains and is the process that gives rubber its elasticity. This process is hastened with accelerators such as disulfiram, thiuram, mercaptobenzothiazole, and diphenylguanidine. ACD may result from exposure to rubber in gloves, gas masks, condoms, tires, heavy-duty rubber goods, boats, and undergarments.

Patch testing is usually done using rubber chemical "mixes" rather than single ingredients. For soldiers with a proven allergic reaction to the rubber in gas masks, M4D silicon masks may be obtained from the U.S. Army Medical Research Institute for Chemical Defense (ICD), Aberdeen Proving Grounds, Aberdeen, Maryland 21010-5425.

### **Clothing**

Natural and synthetic fabrics used in the manufacture of clothing seldom result in dermatitis. When dermatitis does result, it is usually in response to products added to the fabric, with the most common culprits being dyes, rubber compounds,



**OK to put on the Web**

**Fig. 6-29.** Allergic contact dermatitis from the black rubber liner of a standard issue military gas mask. An M4D silicon gas mask should be obtained for soldiers with a documented allergic reaction to the standard issue gas mask.



**OK to put on the Web**

**Fig. 6-30.** Allergic contact dermatitis from a rubber chemical protective glove. Symptoms of allergic contact dermatitis developed a few hours after exposure. Reprinted courtesy of C. Samlaska, Dermatology Service, Tripler Army Medical Center, Honolulu, Hawaii

chromates, nickel, glues, permanent-press finishes (formaldehyde resins), or sizing.

Dermatitis from additives to the fabric of pants most commonly results in an eruption on the inner and anterior thighs or popliteal fossa. An eruption in the axillary folds and antecubital fossa can be caused by shirts or dresses. A local eruption may occur on the midabdomen from exposure to nickel in belt buckles.

Allergic dermatitis to natural wool is uncommon; however, irritant dermatitis, especially in atopic soldiers, commonly occurs at body sites where the wool is in contact with the skin. Woolen khaki shirts worn by soldiers in World War II were noted to cause an occasional purpuric eruption that probably resulted from exposure to lubricating oils used in the manufacture of the fabric.<sup>47</sup> Chrome also causes an allergic dermatitis when used in the dyeing process of green woolen military textiles.<sup>48</sup> Dermatitis caused by untreated man-made fibers such as nylon, dacron, orlon, and rayon is rare.

Pure spandex fibers are used as a rubber substitute in many undergarments because spandex is lighter in color and weight. It is an excellent substitute for soldiers who are allergic to rubber. The antioxidants and accelerators that cause most of the dermatitis from rubber are not used in the manufacture of spandex.

Many textile additives such as softeners, water repellents, biocides, antistatic agents, lubricants, moth proofers, and antislip finishes are not sensitizers. However, formaldehyde and formaldehyde resins used to make permanent-press finishes may cause allergic contact reactions. Dermatitis as a result of residual detergents after washing of clothes is uncommon<sup>49</sup> but can be related to perfumes in the detergents. Textile dyes may cause an ACD. Forty percent of textile dyes are azo dyes. Azo dyes are among the most common causes of textile dye dermatitis and may cross-react with *p*-phenylenediamine. Regardless, ACD resulting from exposure to dyes is rare.<sup>49</sup>

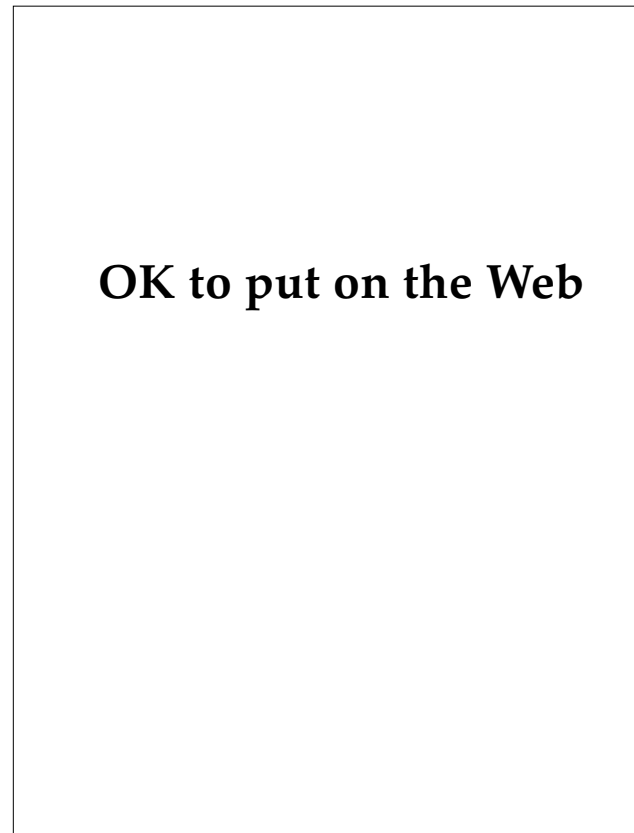
Skin eruptions may also result from occlusive, tightly fitting garments. Pressure urticaria, acneform eruptions, and exacerbation of preexisting eczematous skin conditions may result from clothing that fits too snugly. Patch testing for clothing dermatitis can be performed using a 1-in. square of fabric soaked in water for 10 minutes and applied under a closed patch on an uninvolved medial forearm or the back for 3 days.

Blousing garter dermatitis is a syndrome of hyperpigmentation of the ankles and feet below the

level of application of elastic garters used to keep fatigues neatly in place. Chronic pressure of this kind may result in mild edema and a subsequent form of stasis dermatitis with the associated deposition of melanin and hemosiderin. This condition is not a contact dermatitis.

### Preservatives

Quaternium-15 is a common preservative in cosmetics and creams and is a common cause of allergic dermatitis (Figure 6-31). Imidazolidinyl urea is a very common preservative used in cosmetics but is a less common sensitizer. Bronopol is another sensitizer but is a less commonly used preservative. Formaldehyde is a preservative used in shampoos, cosmetics, and many paper products. It is a significant sensitizer. Although sensitization after use of a formaldehyde-containing shampoo is uncommon, sensitized soldiers may develop an eruption after



**Fig. 6-31.** Allergic contact dermatitis from quaternium-15 in a moisturizing cream. Quaternium-15 is a common preservative in cosmetics and creams. Severe edema and pruritus developed a few hours after a single exposure.

contact with newspaper, magazines, books, paper towels, tissues, or photographic paper.<sup>50</sup>

Paraben esters (methyl, ethyl, propyl, and butyl *p*-hydroxybenzoates) are used in combinations as preservatives in some cosmetics, foods, drugs, and suppositories. Paraben sensitization is evaluated using a 12% paraben mix in petrolatum.

### Fragrances

Fragrances, or perfumes, are the leading cause of ACD due to cosmetics (Figure 6-32).<sup>51</sup> Besides being found in cosmetics, they are used in detergents, toothpastes, sanitary pads, fabric softeners, and many other products. In addition to allergic reactions, fragrances may produce photodermatitis (sun-related), contact urticaria, primary irritation, or depigmentation. Some of the more common offenders are cinnamic alcohol and aldehyde, hydroxycitronella, eugenol, and isoeugenol. Other fragrances that can cause dermatitis include coriander, geraniol, heliotropine, hydroxycitronella, jasmine, linalool, lavender, lemon, lemon grass, neroli, origanum, oil of cloves, peppermint, spearmint, and wintergreen.

### Other Sensitizers

*p*-Phenylenediamine is a common sensitizer used in hair dyes, photographic processing, and rubber vulcanization. *p*-Chloro-*m*-xylenol is a chlorinated phenol antiseptic sensitizer used in Absorbine Jr. (wormwood, thymol, and chloroxylenol, manufactured by W.F. Young, Springfield, Mass.), Desitin powder (talc, manufactured by Leeming/Pacquin, New York, N.Y.), and Unguentine spray (benzocaine, manufactured by Mentholatum Co., Buffalo, N.J.). Propylene glycol is widely used as a vehicle for cosmetics, emollient lotions, and topical medications. It is also used in brake fluids, automotive antifreeze, lubricants for food machinery; in additives for food colors; and in antiperspirants. Propylene glycol is both an irritant and a sensitizer.

Lanolin (wool fat, wool wax, wool alcohol) and

## OK to put on the Web

**Fig. 6-32.** Perfume dermatitis. Fragrances, or perfumes, are the leading cause of allergic contact dermatitis due to cosmetics and may be ingredients in many other products.

related compounds are found in many topical medications. Lanolin is a common sensitizer found in creams, hair products, lipsticks, moisturizers, ointments, soaps, furniture polishes, leather, shoe polishes, fur, and textile finishes. Lanolin is a significant cause of allergic dermatitis when it contacts eczematous skin. The risk of sensitization when contact is with normal skin is much lower.

Balsam of Peru is used widely in topical therapies. It has mild antibacterial activity and is used in toothpastes, sore throat lozenges, and dental cements. It may also be found in sunscreens, cosmetics, perfumes, and a variety of suppositories. Cross-reactions can occur with benzoin, rosin, benzyl alcohol, cinnamic acid, orange peels, clove, benzyl benzoate, and wood tars. Balsam of Peru is a well-documented sensitizer and also produces a nonallergic contact urticaria.<sup>9</sup>

Rosin (colophony) is a natural resin used widely in topical medications, adhesives, cements, and cleaners. It is used on violin bows and in rosin bags for baseball players. Rosin is a sensitizer, and sensitized soldiers may cross-react with Balsam of Peru. Thiuram is a common sensitizer in rubber products but may also be found in adhesives, fungicides, disinfectants, paints, pesticides, soaps, repellents, and putty.

## IRRITANT CONTACT DERMATITIS

Many substances produce a nonallergic inflammatory reaction of the skin. Any soldier exposed to sufficiently high concentrations of the substance will develop dermatitis. No prior exposure is required, and the effect is evident within minutes or a

few hours. Variations in severity of the reaction to these irritants—from soldier to soldier or from time to time in the same soldier—are due to the condition of the skin and the duration of exposure to a given concentration of irritant. Excessive humidity, heat,

cold, pressure, or friction may adversely affect the epidermal barrier, making the skin more vulnerable to the irritant effects of a substance. Cold weather and low humidity may produce chapping, excessive dryness, and pruritic skin and predispose to irritant dermatitis. High temperatures and humidity in the summer predispose to maceration and increased frequency of irritant dermatitis. Thick skin of the palms and soles is more resistant to irritants than thin skin. Repeated exposure of the skin to some mild irritants may, in time, produce a "hardening" effect, which makes the skin more resistant to an irritant.

### Alkalis and Acids

Alkalis are composed primarily of sodium hydroxide, potassium hydroxide, ammonium hydroxide, and calcium hydroxide compounds; they penetrate deeply and destroy the skin because they dissolve keratin. These agents are frequently associated with hand eczemas after exposure to soaps; detergents; bleaches; ammonia preparations; lye; and drain pipe, toilet bowl, and oven cleaners. Exposure to concentrated alkalis may be buffered by rinsing the site with a weak acid solution such as vinegar, lemon juice, or 0.5% hydrochloric acid.

Exposure to acids (eg, hydrochloric, nitric, sulfuric, and hydrofluoric) causes an irritant burn. Hydrochloric acid produces more superficial damage than the others and more frequently results in blister formation. Nitric acid, which is used in the production of some explosives, causes deep burns while turning the skin yellow. Sulfuric acid is used extensively in industry and results in a brownish charring of the skin, which ulcerates and heals slowly. Hydrofluoric acid is a very potent inorganic acid that will dissolve glass, but may be slow to cause dermatitis. If left in contact with the skin, progression from erythema to vesiculation, ulceration, and finally necrosis occurs.

Acid burns should be treated by rinsing with copious amounts of water. Alkalinization of the site can be done with sodium bicarbonate, calcium hydroxide (lime water), or soap solutions.

### Hydrocarbons

Hydrocarbons in crude petroleum and lubricating and cutting oils may cause an irritant dermatitis. Chronic exposure can also result in pruritus, folliculitis, calcifications, or acneform eruptions. Exposure to creosote, asphalt, and other tar prod-

ucts may result in melanoderma. Creosote is a contact irritant, sensitizer, and photosensitizer.

### Diethyltoluamide Dermatitis

Insect repellents containing diethyltoluamide (DEET) were first extensively used in a military conflict during the Vietnam conflict. Although it was not suspected of being capable of causing significant skin reactions, during the Vietnam conflict DEET was discovered to result in a bullous eruption in some personnel. Although this chemical was a relatively uncommon cause of significant dermatitis, it did result in pain, disability, and permanent scarring in some individuals.<sup>8,52,53</sup>

DEET eruptions were characterized by a distinctive clinical course and by their restriction to the antecubital fossae. The eruption was first noted by soldiers on morning awakening. A red, tender area in one or both antecubital fossae was noted. This area would evolve over 24 hours into blisters on a tender base. Lamberg and Mulrennan<sup>53</sup> showed in 1969 that about half the people tested will develop a reaction to DEET when it is applied to the antecubital fossa, but none of the 62 patients tested reacted to DEET applied to the upper inner arm. Besides proving that the eruption was an irritant reaction, not an allergic one, Lamberg and Mulrennan pointed out that when DEET is used in the antecubital fossae, a large percentage of the populace will be at risk for this eruption. Besides being capable of producing an irritant dermatitis, DEET produces contact urticaria in some individuals.<sup>52</sup>

### Chloracne

Chloracne was first described by Herxheimer in 1899 as a form of acne that is distinct from all other forms of acne, such as acne vulgaris and acne rosacea.<sup>54</sup> Chloracne may result from exposure to a variety of aromatic chlorinated hydrocarbons.

During the Vietnam conflict, Agent Orange was by far the most commonly used defoliant. The herbicide is composed primarily of a mixture of 2,4,5-trichlorophenoxyacetic acid (2,4,5-T) and 2,4-dichlorophenoxyacetic acid (2,4-D). These two products are potentially toxic, but a contaminant, 2,3,7,8-tetrachlorodibenzo-*p*-dioxin (TCDD), poses more significant health concerns. In addition to the many other health concerns associated with it, TCDD is a known chloracne-producing agent.

The distribution of lesions in soldiers with chloracne is of particular diagnostic importance.



The most frequently involved areas are on the face, below and lateral to the eyes, and behind the ears. These areas may be the only sites involved, and chloracne in these areas may persist for years after lesions in other parts of the body have resolved. The scrotum is also a particularly sensitive area. If the exposure is sufficient, lesions also may appear on the penis, shoulders, chest, back, and eventually, the buttocks and abdomen. The nose is uniformly spared and the distal extremities are seldom involved.

The primary lesion of chloracne is the comedo. With mild exposure, small numbers of comedones on the face may be all that is noted. With more severe exposure, soldiers also develop pale yellow cysts 1 to 10 mm in diameter that are mingled with the comedones. Soldiers may develop large inflammatory cysts and cold abscesses with very severe exposures, but even these cysts tend to be much less inflammatory than those seen in cystic acne.

The clinical course of chloracne varies depending on the method of exposure, chemical involved, and dose. Simple comedones usually do not develop until 2 to 4 weeks after exposure. After exposure ceases, most persons will clear all lesions within 4 to 6 months. However, some patients have shown chloracne lesions for 15 to 30 years after the last known exposure.<sup>54</sup>

Chloracne may be relatively unresponsive to therapy. Topical 0.05% Retin-A (tretinoin, manufactured by Ortho Pharmaceutical Corp., Raritan,

N.J.) may be effective with comedonal lesions, and oral retinoids may be tried in more severe cases.<sup>54</sup>

### Irritant Contact Dermatitis due to Plants

Numerous common plants and even edible fruits can cause an irritant contact dermatitis. The dermatitis frequently occurs only after exposure to a particular part of the plant, and the degree of toxicity may vary with the season, type of exposure, stage of maturity of the plant, locality, and anatomical factors such as thickness of the stratum corneum.

The majority of cases of irritant contact dermatitis can be traced to only a few plant families. The largest is the spurge family (Euphorbiaceae). Spurges such as the poinsettia (*Euphoria pulcherrima*), crown-of-thorns (*E splendens*), candelabra cactus (*E lactea*), and pencil tree (*E tirucalli*) contain a highly irritating, white, milky sap that may cause erythema, desquamation, and bulla formation. The active agent in the sap is known as euphorbin.<sup>14</sup> Another family of irritant plants, Brassicaceae, includes the mustard seed plant and butter cups. Calcium oxalate, another irritant, is found in a number of plants including *Dieffenbachia*, daffodils, hyacinths, and pineapples.

Many of these plants produce dermatitis only after chronic exposure and symptoms frequently consist only of erythema, burning, or pruritus. On rare occasions severe bullous eruptions occur, or oral exposure may result in oral or esophageal lesions.

## OTHER CONTACT DERMATITIDES

Certain skin disorders are not typically classified as either ACD or irritant contact dermatitis. These dermatitides include mechanical injury, pharmacological reactions, and contact urticaria.

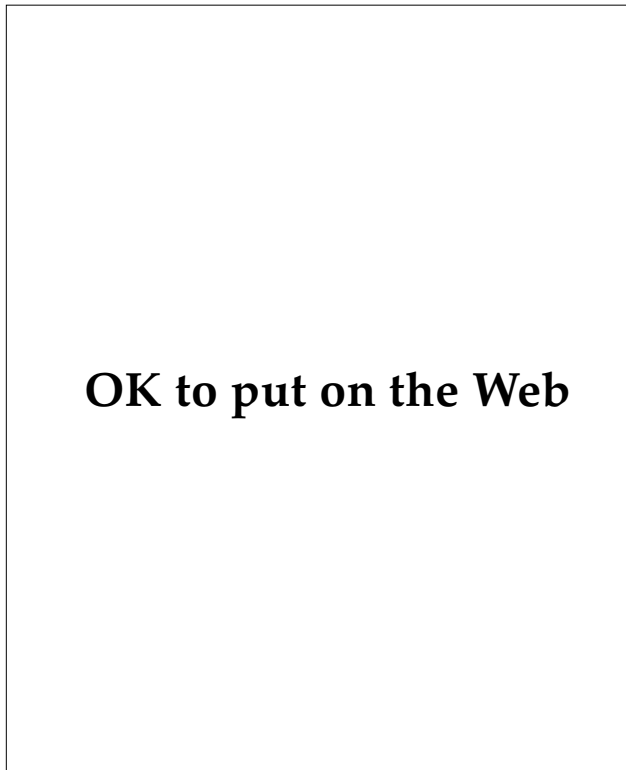
### Mechanical Injury

Aside from the obvious risks of a combat environment, the soldier may be exposed to a variety of natural agents that can result in direct trauma to the skin. Traumatic injury from plants is a frequent cause of dermatitis, but seldom requires the care of a medical officer. Secondary bacterial and fungal infections around implanted thorns, needles, splinters or spines are not uncommon, even though these injuries are frequently sterile. *Sporothrix schenckii* (a dimorphic, imperfect fungus) infection should be considered following wounds produced by roses,

trees, grasses, and sphagnum moss (Figure 6-33).<sup>55</sup> Cactus needles that remain imbedded in the skin may produce aseptic foreign-body granulomas. Coral cuts produced by the exoskeleton of the corals, order Milleporina, have a largely undeserved reputation for producing inflammatory lesions that heal slowly. This reputation is probably related chiefly to the injuries' location—most frequently on the feet—and the occasional implantation of small coral fragments. In general, coral cuts should be treated with vigorous cleansing as soon after the injury as is feasible.

### Pharmacological Reactions

On contact with the skin, some plants cause dermatitis through the release of pharmacologically active agents. Essentially all persons will develop a



**Fig. 6-33.** *Sporothrix schenckii* infection. Infection can follow wounds produced by roses, trees, grasses, and sphagnum moss.

reaction to significant exposure. Most of these reactions are produced by plants in the family Urticaceae. Stinging nettles (*Urtica ureus*), common in dry, disturbed soil or woodland margins, are characterized by sawtoothed, heart-shaped leaves and are densely covered with coarse, stinging hairs. The hairs consist of a tiny capillary tube that breaks off at a predetermined line on contact with the skin. Pressure on a small bladderlike base injects fluid containing histamine, acetylcholine, and serotonin. The result is a typical triple response (erythema, flare, and wheal) with pruritus noted in seconds and lasting a few hours. Most stings are benign and require little or no therapy.<sup>14</sup>

### Contact Urticaria

Contact urticaria may be defined as a wheal-and-flare reaction that occurs after topical exposure to an agent. It may be immunological, nonimmunological, or of unknown mechanism. The immunological type may be severe, with associated anaphy-

laxis. Nonimmunological contact urticaria is the most common and is caused by agents that directly stimulate the release of vasoactive substances from mast cells.

Agents that produce allergic contact urticaria include silk, wool, rubber, animal hair, dander, saliva, serum, seminal fluid, cockroaches, moths, insect stings, milk, eggs, fish, meat, fruits, potatoes, phenylmercuric propionate (as an antibacterial agent in the laundry), beer, penicillin, neomycin, nickel, formaldehyde, and rubber.

Contact urticaria from rubber occurs almost exclusively from the use of rubber gloves. Dentists, surgeons, operating room nurses, and numerous other healthcare providers may demonstrate a contact urticaria reaction to rubber gloves. The sensitization rate may be up to 10% in highly exposed personnel.<sup>56</sup>

Allergies to latex pose a risk to both the healthcare provider and his or her patients. Severe anaphylactic reactions have occurred in patients exposed to latex during surgery, obstetrical deliveries, and barium enemas. It is therefore recommended that before performing these procedures the history include questions regarding signs and symptoms of latex allergy. This point is of particular importance when the patient is a healthcare provider. Most of the patients who have developed intraoperative reactions to latex have been healthcare providers.<sup>56</sup> Many items in the operating room may be the source of latex. Sensitive individuals may react to latex in gloves, endotracheal tubes, syringes, intravenous tubing and bags, multidose vials, and enema and catheter tubing.

Agents that produce a nonimmunological contact urticaria include jellyfish, the Portuguese man-of-war, Balsam of Peru, caterpillar hair, moths, insect stings, benzoic acid, nettles (plants), dimethyl sulfoxide, cobalt chloride, trafulil, sorbic acid, and cinnamic acid.

Skin testing for contact urticaria is performed as an open patch test, and the suspected agent should initially be applied to previously uninvolved skin. If no reaction occurs, the agent can be placed on previously affected skin. If there is still no reaction, the agent may then be gently rubbed into a superficial scratch. Immediate contact urticarial reactions should be read at 20 minutes after application. Because anaphylaxis may result from such testing in highly allergic individuals, epinephrine and resuscitation equipment should always be available.

## CONTACT DERMATITIS BY ANATOMICAL SITE

Many areas of the body are particularly sensitive to contact allergens, and some areas are affected most commonly by a few specific allergens. From a practical standpoint, it is important to be aware of these associations. Some material from earlier in the chapter is repeated here in order to assist the medical officer in rapid diagnosis and treatment.

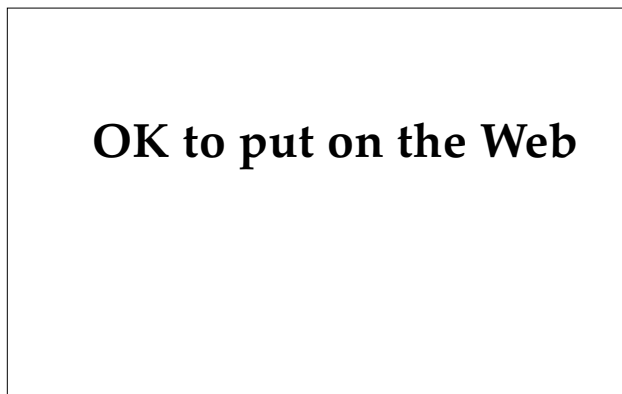### Eyelids

The eyelid is one of the most sensitive and frequently affected parts of the body (Figure 6-34). Any allergen that contacts the face, scalp, or hands may be inadvertently transferred to the lids, resulting in an eczematous dermatitis even when the primary sites remain clinically uninvolved. Eyelid dermatitis occurs most commonly from products applied to other parts of the body and then accidentally transferred to the lids. Frequently only one eyelid is involved. Severe edema of the eyelids is frequently associated with exposure to *T rydbergii* and *T radicans* (poison ivy). Preservatives in ophthalmic medications and contact lens solutions can produce eyelid dermatitis and conjunctivitis. The most common preservatives implicated include benzalkonium chloride, thimerosal, chlorobutanol, chlorhexidine, and phenylmercuric nitrate and acetate. Cosmetics such as mascara and eye shadow, lemon and orange peels, and exposure to phosphorous sesquisulfide in "strike anywhere" matches can cause eyelid dermatitis.<sup>57</sup> Airborne

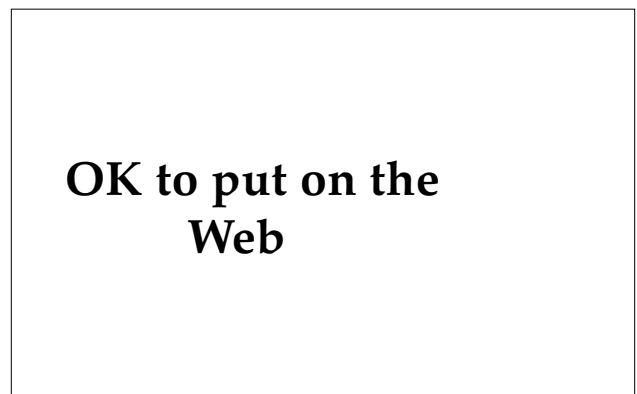contactants such as insecticides and volatile occupational chemicals can also produce a dermatitis of the lids.

### Face

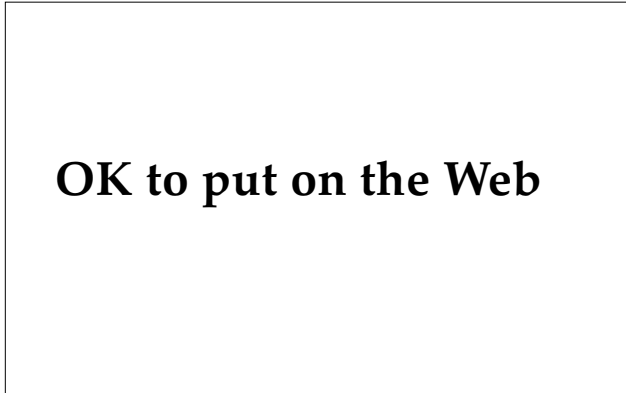
Contact dermatitis involving the face may result from direct contact or from inadvertent transfer of an allergen. In addition, sun- and plant-related dermatitis are often most severe on the face. Facial dermatitis due to rubber compounds may be of particular importance to military personnel. A severe eruption may occur after exposure to rubber used in gas masks (see Figure 6-29). Although the scalp is resistant to contact dermatitis, the forehead, ears, and posterior neck may become inflamed after contact with hair dye, hair spray, shampoo, and permanent-wave solutions. Dermatitis of the forehead may result from contact with leather or rubber compounds in hat bands or protective helmets. The forehead may also be affected after exposure to pomade hair straighteners. Pomade acne occurs primarily in black males and consists of closely packed, multiple, closed comedones along the hairline and temples (Figure 6-35). Perioral dermatitis may result from reactions to toothpaste or chewing gum. Earlobe dermatitis most commonly results from nickel found in earrings (see Figure 6-26). Severe contact dermatitis of the face may result after exposure to smoke from burning toxicodendrons (poison ivy). Other causes



**Fig. 6-34.** Allergic eyelid dermatitis. Eyelids are frequently sites of contact dermatitis. Allergens may be inadvertently transferred to the lids from the face, scalp, or hands.



**Fig. 6-35.** Pomade acne. Pomade hair straighteners can produce an acneform eruption along the hairline and temples.

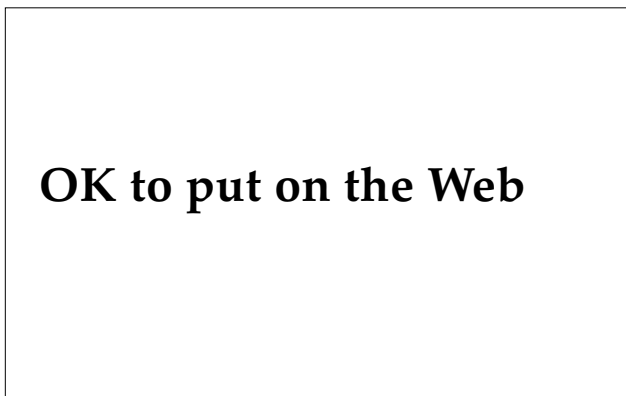


**Fig. 6-36.** Contact dermatitis produced by deodorant. Irritant reactions to aluminum salts can occur. Allergic reactions are most frequently due to fragrances.

of facial dermatitis include cosmetics, sunscreens, acne medications, aftershave lotion, and moisturizing creams.

### Neck

Nickel found in metal identification tags and chains and in necklaces may result in an underlying erythematous and eczematous eruption of the neck (see Figure 6-23). The dermatitis may occur just under the clasp of a necklace or just under the identification tag. An eruption in this area might also result from contact with rubber used to insulate or quiet the identification tag and chain. Dermatitis of the neck may result from



**Fig. 6-37.** Contact dermatitis from using spray deodorant. Dermatitis of the scrotum or groin area can result from inadvertent transfer or inappropriate application of irritants or allergens.

airborne allergens, perfume, and aftershave lotion (see Figure 6-32).

### Trunk

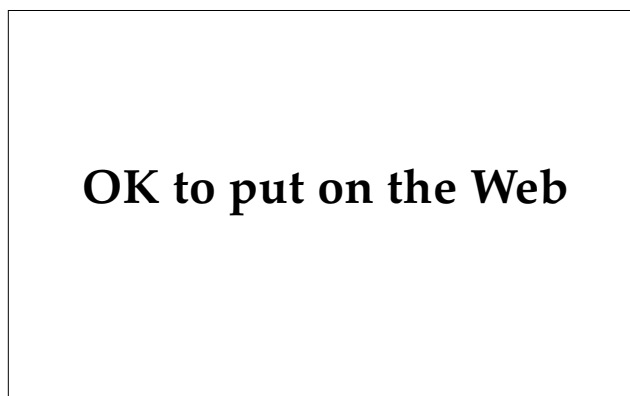The trunk is infrequently afflicted with contact dermatitis. Metal identification tags and related covering materials may result in a dermatitis of the central chest. Dye or finish in clothing may occasionally result in a dermatitis of the chest or axilla. Dermatitis of the axillary vault is seen in reactions to deodorants (Figure 6-36). Elastic materials or metal wires and snaps found in brassieres may result in a contact dermatitis. Other sensitizers can include topical medications or sunscreens.

### Abdomen

Dermatitis of the belt line may result from elastic material in undergarments. The central abdomen may develop a dermatitis under nickel-containing zippers, buttons, snaps, and belt buckles (see Figure 6-24).

### Groin

The penis or scrotum may become inadvertently exposed to poison ivy oleoresins on the hands, resulting in severe contact dermatitis (see Figure 6-6). The patient in Figure 6-37 developed a severe contact dermatitis after using spray deodorant in his genital area. Penile dermatitis may also result from condoms. The allergen in these cases is usually a rubber antioxidant or accelerator.



**Fig. 6-38.** Allergic contact dermatitis from hand cream. Hand dermatitis can result from exposure to foods, toxicodendrons, oils, solvents, metals, topical medications, rubber gloves, soaps, or detergents.

## Hands and Feet

Contact dermatitis of the feet most commonly results from leather, rubber, or adhesive materials used

in shoes and boots (see Figure 6-28). Hand dermatitis may result from exposure to foods, toxicodendrons, oils, solvents, metals, topical medications, rubber gloves, soaps, or detergents (Figure 6-38).

## PATCH AND USE TESTING

Although an extensive discussion of patch testing is beyond the scope of this text, Table 6-1 shows a list of agents frequently used in the process. Physicians experienced in performing patch tests frequently maintain their own stock of additional agents that can be used in patch testing. In addition, small samples of each of the ingredients in a product may be obtained from the manufacturer. Only standardized concentrations of each allergen should be applied. In no case should undiluted, nonstandardized mixes of chemicals be applied under occlusion.

Patch testing of solid objects may be performed by trimming off a small (0.5–1.0 cm<sup>2</sup>) sample and applying it to the skin, or if small enough, the object in question may be taped to the skin. Small pieces of shoes or clothing can be moistened and applied under occlusive hypoallergenic tape. Suspect agents are usually left against the skin for 48 hours. The agent is removed and the site is examined; the exam is repeated 48 hours later. A significant allergen will produce pruritus, erythema, edema, and even vesiculation at the site.

**TABLE 6-1**  
**STANDARD PATCH-TEST SCREENING TRAY**

Allergen	Common Sources of Exposure
Balsam of Peru 25%	Cosmetics, perfumes
Benzocaine 5%	Topical anesthetics, medications
Black rubber mix 0.6%	Rubber products
<i>p</i> -Tert-butylphenol formaldehyde resin 1%	Adhesives, rubber products
Carba mix 3%	Rubber cements and sealants
Cinnamic aldehyde 1%	Fragrance, flavorings
Colophony (rosin) 20%	Adhesives, cements, cleaners, topical medications
Epoxy resin 1%	Glue, pastes
Ethylenediamine dihydrochloride 1%	Mycolog, aminophylline, hydroxyzine, eye drops
Formaldehyde 1%	Glues, paper, clothing, cosmetics, leather
Imidazolidinyl urea 2%	Preservative in creams and cosmetics
Lanolin (wool) alcohol 30%	Cosmetics, medicated creams, leather, polishes, fur
Mercapto mix 1%	Shoes, rubber products
Mercaptobenzothiazole 1%	Rubber products
Neomycin sulfate 20%	Topical medications
Nickel sulfate 2.5%	Jewelry, metal fasteners, ID tags/chains, tools
<i>p</i> -Phenylenediamine 1%	Hair dyes, inks, rubber products
Potassium dichromate 0.25%	Cement, leather, green woolen military textiles
Quaternium-15, 2%	Cosmetics
Thimerosal 0.1%	Eye, ear, and nose preparations
Thiuram mix 1%	Rubber products

Data source: Fisher AF. *Contact Dermatitis*. Philadelphia, Pa: Lea & Febiger; 1986: 21–28.

Use testing may be performed with nonirritating creams, ointments, oils, and sprays that are believed to contain possible allergens by applying the material to the inner surface of the distal upper

arm three times a day for 1 week. If no reaction occurs, the test is considered negative, but false-negative results are not uncommon with this form of testing.

## TREATMENT

As with most medical conditions, making the correct diagnosis is crucial to providing appropriate therapy. The diagnosis of poison ivy dermatitis may be obvious in the soldier who presents with a linear bullous dermatitis on exposed skin. However, contact dermatitis may be neglected for several days, and a secondary infection may cloud the clinical picture. The medical officer must be alert to this possibility and attempt to come to the correct diagnosis with a thorough history and insightful physical examination. Once the correct diagnosis has been established, many affected soldiers' conditions will improve with adequate hygiene and avoidance of the primary contactant. Depending on the degree and duration of involvement, and the presence or absence of secondary infection, each of the following therapies may be considered.

### Removal of the Irritant

In cases of acute irritant dermatitis from strong irritating chemicals, the first goal must be to remove the irritant from the skin to prevent further damage. Oral and topical steroid therapy do not benefit the soldier who has a nonallergic, irritant contact dermatitis.

Acid burns from such agents as hydrochloric, nitric, and sulfuric acids should be treated immediately with copious amounts of water and alkalization with sodium bicarbonate or soap solutions. Alkalis such as soaps, detergents, bleaches, ammonia preparations, lye, and drain pipe, toilet bowl, and oven cleaners all can cause significant irritant contact dermatitis. Alkalis may cause deep tissue destruction because they dissolve keratin. Strong alkaline solutions may be neutralized by rinsing the skin with a weak acid solution such as vinegar, lemon juice, or 0.5% hydrochloric acid. The site should also be rinsed with large quantities of water.

### Nonsteroidal Therapy

Many cases of localized, mild contact dermatitis will respond well to cool compresses and adequate wound care. Cool, wet soaks applied for 5 to 10 minutes followed by air drying may significantly

reduce serous drainage from the site. Clean water, isotonic saline, and Burow's solution can all be used with good success. Topical calamine lotion usually is of limited benefit.

Affected sites should be cleared of adherent crusts and a thin coat of antibacterial ointment should be applied. Most episodes of contact dermatitis will not require antibiotic therapy, if they are treated promptly and adequate wound care can be provided. But oral antibiotics may be of benefit if a significant degree of purulent material or crust is present. Adequate coverage for staphylococci and streptococci can usually be achieved with a 5- to 10-day course of oral therapy with dicloxacillin, erythromycin, or Keflex (cephalexin, manufactured by Dista, Indianapolis, Ind.) at 250 mg four times a day.

Severe pruritus may respond to antihistamines such as Atarax (hydroxyzine, manufactured by Roerig, New York, N.Y.), 25 to 50 mg nightly, or chlorpheniramine, 4 to 8 mg nightly.

### Steroids

Potent topical steroids such as Temovate (clobetasol propionate, manufactured by Glaxo, Research Triangle Park, North Carolina) or Diprolene (betamethasone dipropionate, manufactured by Schering, Kenilworth, N.J.) applied twice daily for 1 to 2 weeks are effective in the therapy of small areas of moderate-to-severe ACD. However, the mainstay of therapy for the soldier with an acute episode of extensive ACD, or severe contact dermatitis involving the face and intertriginous areas, is systemic steroids. Without therapy, and barring secondary infection or reexposure, an episode of *Toxicodendron* dermatitis can be expected to persist up to 3 or 4 weeks. Early, adequate use of prednisone or intramuscular Kenalog (tri-aminolone acetonide, manufactured by Westwood-Squibb, Buffalo, N.Y.) can significantly shorten this course, allowing the soldier to return to duty. Prednisone should be started at 40 to 80 mg (1.0–1.2 mg/kg) per day as a single oral dose and tapered over approximately 3 weeks. Soldiers who stop prednisone therapy prematurely will frequently experience a relapse that

may result in additional days lost from service. The duration of prednisone therapy should be long enough that the soldier will complete therapy 2 to 3 weeks after the initial onset of symptoms. Alternatively, a single dose of 4 mg of Celestone (betamethasone sodium phosphate, manufactured by Schering, Kenilworth, N.J.) may be mixed with 40 to 60 mg of triamcinolone (Kenalog) for use as intra-

muscular therapy, providing fairly rapid onset of action and prolonged action over 2 to 4 weeks. Celestone expedites recovery and Kenalog provides the duration required to maintain clearance of symptoms. If used alone, the Celestone dose may be increased to 12 mg but must usually be repeated in 5 to 7 days. Intramuscular therapy is efficacious and ensures compliance.

## SUMMARY

Contact dermatitis may result from either an immunological or nonimmunological reaction of the skin after exposure to various agents. A common form of immunological reaction or ACD is produced when sensitized individuals are exposed to urushiol, the antigen in *Toxicodendron* species (eg, poison ivy, poison oak, and poison sumac). The concentration of the contactant required to produce dermatitis is very low, and not everyone who is exposed to the antigen will develop dermatitis. In contrast, irritant contact dermatitis is a nonimmunological process and will develop in all soldiers who are exposed to a sufficiently high concentration of the irritating substance.

Soldiers may also develop dermatitis after exposure to plants for reasons other than contact with allergens or irritants. Mechanical injury from plants may result in infection from bacteria and fungi or foreign body reactions to residual material such as cactus needles or coral fragments. Dermatitis may result from pharmacologically active agents such as histamine, acetylcholine, and serotonin found in stinging nettles. Contact urticaria can be produced by a variety of substances and may be immunological, nonimmunological, or of unknown mechanism. Contact urticaria can be severe, with associated anaphylaxis.

Contact dermatitis is a very common disorder, and a high index of suspicion should be maintained

in the evaluation of all cases of eczematous dermatitis. Contact dermatitis should be considered in cases of recurrent dermatitis or when dermatitis fails to respond to appropriate therapy. It should be considered in the evaluation of dermatitis that demonstrates patterns such as symmetry and linearity, or location at common sites of exposure to allergens such as the earlobes or belt buckle area. The evaluation of such dermatitis begins with a detailed history of exposure to plants, creams, lotions, solvents, and topical medications. The diagnosis may be strongly suspected based on the patient's history and may be confirmed in many cases with use testing or patch testing.

Effective therapy for contact dermatitis exists, and soldiers should report for medical intervention as soon as dermatitis develops. Early diagnosis and therapy may significantly shorten the course of the dermatitis, allowing the soldier to return to full duty with minimal delay.

The battlefield is a harsh environment for the skin, with many potential allergens and irritants. Some of these may be indigenous to the local area, while others may be imported with the troops. If the healthcare provider is alert to the clinical appearance of contact dermatitis, makes the proper diagnosis promptly, and institutes appropriate therapy, significant morbidity can be avoided and troop strength and readiness will be enhanced.

## REFERENCES

1. Winkenwerder WL. Allergy. In: Havens WP, ed. *Infectious Diseases and General Medicine*. In: Havens WP, Anderson RS, eds. *Internal Medicine in World War II*. Vol 3. Washington, DC: Medical Department, US Army, Office of The Surgeon General; 1968:192-193.
2. Pillsbury DM, Livingood CS. Dermatology. In: Havens WP, ed. *Infectious Diseases and General Medicine*. In: Havens WP, Anderson RS, eds. *Internal Medicine in World War II*. Vol 3. Washington, DC: Medical Department, US Army, Office of The Surgeon General; 1968: 620-626.
3. US Department of the Army. Skin diseases in the tropics. *US Army Med Department Bulletin*. 1944;80:10-12.

4. Kierland RR. Local use of penicillin preparations in cutaneous diseases. *Mil Surgeon*. 1945;97:57–59.
5. US Department of the Army. Dermatological problems in tropical theaters. *US Army Medical Department Bulletin*. 1945;4:299–300.
6. Woolhandler HW. Dermatology in an army station hospital. *Arch Derm Syph*. 1944;49:91–102.
7. Canizares O. Cutaneous diseases in Army Air Force Personnel. *Arch Derm Syph*. 1947;56:364–72.
8. Allen AM. *Skin Diseases in Vietnam, 1965–72*. In: Ognibene AJ, ed. *Internal Medicine in Vietnam*. Vol 1. Washington, DC: Medical Department, US Army, Office of The Surgeon General; 1977: 39, 136–139.
9. Fisher AF. *Contact Dermatitis*. Philadelphia, Pa: Lea & Febiger; 1986: 59, 220–223, 244–245.
10. Benezra C, Ducombs G, Sell Y, Fousseureau J. *Plant Contact Dermatitis*. Toronto, Canada: Mosby; 1985: 58, 68–86.
11. Guin JD, Beaman JH, eds. *Plant Dermatitis*. In: *Clinics in Dermatology*. Philadelphia, Pa: Lippincott; 1986: 137–147, 175–179.
12. Polunin I. Pineapple dermatosis. *Br J Dermatol*. 1951;63:441–455.
13. Guin JD, Gillis WT, Beaman JH. Recognizing the toxicodendrons (poison ivy, poison oak, and poison sumac). *J Am Acad Dermatol*. 1981;4:99–114.
14. Stoner JG, Rasmussen JE. Plant dermatitis. *J Am Acad Dermatol*. 1983;9: 1–15.
15. Beaman JH. Allergenic Asian Anacardiaceae. In: *Plant Dermatitis. Clinics in Dermatology*. Philadelphia, Pa: Lippincott; 1986: 196.
16. Guin JD. The black spot test for recognizing poison ivy and related species. *J Am Acad Dermatol*. 1980;2:332–333.
17. Livingood CS, Rogers AM, Fitz-Hugh T. Dhobie mark dermatitis. *JAMA*. 1943;123: 23–26.
18. Goldsmith NR. Dermatitis from *Semecarpus anacardium* (bhilawanol of the marking nut). *JAMA*. 1943;123:277–330.
19. Coomber RB. Dermatitis from contact with varnish of Japanese rifles. *Arch Dermatol*. 1947;55:110–111.
20. Mitchell JC, Rook A. *Botanical Dermatology: Plants and Plant Products Injurious to the Skin*. Vancouver, Canada: Greenglass; 1979: 63–93.
21. Little C. Dermatitis produced by Japanese lacquer. *Br Med J*. 1924;1:1112–1113.
22. Marks JG Jr, DeMelfi BS, McCarthy MA, et al. Dermatitis from cashew nuts. *J Am Acad Dermatol*. 1984;10:627–631.
23. Sowers WF, Weary PE, Collins OD, Cawley EP. Ginkgo tree dermatitis. *Arch Dermatol*. 1965;91:452–456.
24. Becker LE, Shipworth GB. Ginkgo tree dermatitis, stomatitis, and proctitis. *JAMA* 1975;231:1162–1163.
25. Menz J. Contact dermatitis from plants of the Grevillea family. *Austral J Dermatol*. 1985;26:74–78.
26. Elpern DJ, Mitchell JC. Photodermatitis from mokihana fruits (*Pelea anista* H. Mann, fam. Rutaceae) in Hawaiian lei. *Contact Dermatitis*. 1984;10: 224–226.
27. Grauer FH, Arnold HL Jr. Seaweed dermatitis: First report of a dermatitis-producing marine algae. *Arch Dermatol*. 1961;84:62–74.



28. Lampe KF. Dermatitis-producing plants of south Florida and Hawaii. In: Guin JD, Beaman JH, eds. *Plant Dermatitis*. In: *Clinics in Dermatology*. Philadelphia, Pa: Lippincott; 1986: 89.
29. Jackson, WPU. Plant dermatitis in the Bahamas. *Br Med J*. 1946;2:298–300.
30. Hurtado I. Poisonous Anacardiaceae of South America. In: Guin JD, Beaman JH, eds. *Plant Dermatitis*. In: *Clinics in Dermatology*. Philadelphia, Pa: Lippincott; 1986: 183.
31. Beaman JH. Allergenic Asian Anacardiaceae. In: Guin JD, Beaman JH, eds. *Plant Dermatitis*. In: *Clinics in Dermatology*. Philadelphia, Pa: Lippincott; 1986: 191.
32. Pathak MA. Sunscreens: Topical and systemic approaches for protection of human skin against harmful effects of solar radiation. *J Am Acad Dermatol*. 1982;7:285–312.
33. Mathias TCG, Maibach HI, Epstein J. Allergic contact photodermatitis to *p*-aminobenzoic acid. *Arch Dermatol*. 1978;114:1665–1666.
34. Thompson G, Maibach HI, Epstein J. Allergic contact dermatitis from sunscreen preparations complicating photodermatitis. *Arch Dermatol*. 1977;113:1252–1253.
35. Unger PN. Clinical abstracts of an unusual case of skin sensitivity to the metal tags worn by the troops in the field. *Mil Surgeon*. 1943;92:67–69.
36. Watts TL, Baumann RR. Nickel earlobe dermatitis. *Arch Dermatol*. 1968;98:155–158.
37. Guin JD. Metal sensitivity or the case of the oozing earlobes. *J Indiana State Med Assoc*. 1982;75:37–41.
38. Emmett EA, Risby TH, Jiang L, et al. Allergic contact dermatitis to nickel. *J Am Acad Dermatol*. 1988;19:314–322.
39. Fisher AA. Detection of nickel by dimethyl glyoxime spot test. *JAMA*. 1975;234:429–430.
40. Fisher AA. Nickel dermatitis. *Dermatology*. Dec 1981:19.
41. Stutzman CD, Schmidt GD. Squamous cell carcinoma from wearing radioactive rings. *J Am Acad Dermatol*. 1984;10:1075–1076.
42. Epstein E. Shoe contact dermatitis. *JAMA*. 1969;209:1487–1492.
43. Lynde CW, Warshawski L, Mitchell JC. Patch test results with a footwear screening tray in 119 patients, 1977–80. *Contact Derm*. 1982;8:423–425.
44. Mali JWH, Malten K, Van Neer, FCJ. Allergy to chromium. *Arch Dermatol*. 1966;93:41–44.
45. Farkas J. Chronic shoe dermatitis from chromium tanned leather. *Contact Derm*. 1982;8:140.
46. Scutt RWB. Chrome sensitivity associated with tropical footwear in the Royal Navy. *Br J Dermatol*. 1966;78:337–339.
47. Davies JH, Barker AN. Textile dermatitis. *Br J Dermatol Syphil*. 1944;56: 33–37.
48. Fregert S, Gruvberger B, Göransson K, Normark S. Allergic contact dermatitis from chromate in military textiles. *Contact Derm*. 1978;4:223–224.
49. Hatch K, Maibach HI. Textile dermatitis. *J Am Acad Dermatol*. 1985;12: 1079–1092.
50. De Groot AC, Bos JD, Jagtman BA, Bruyunzeel DP, Van Joost T, Weyland JW. Contact allergy to preservatives, Part 2. *Contact Derm*. 1986;15:218–222.

51. Eierman HJ, Larsen W, Maibach HI, Taylor JS. Prospective study of cosmetic reactions. *J Am Acad Dermatol.* 1982;6:909–917.
52. Reuveni H, Yagupsky P. Diethyltoluamide-containing insect repellent: Adverse effects in worldwide use. *Arch Dermatol.* 1982;118:582–583.
53. Lamberg SI, Mulrennan JA. Bullous reaction to diethyltoluamide (DEET) resembling a blistering insect eruption. *Arch Dermatol.* 1969;100:582–586.
54. Tindall JP. Chloracne and chloracnegens. *J Am Acad Dermatol.* 1985;13:539–560.
55. Grotte M, Younger B. Sporotrichosis associated with sphagnum moss exposure. *Arch Pathol Lab Med.* 1981;105:50–51.
56. Berky ZT, Luciano WJ, James WD. Latex glove allergy: A survey of the United States Army Dental Corps. *JAMA.* 1992;268(19):2695–2697.
57. Burge SM, Powell, SM. Contact urticaria to phosphorus sesquisulphide. *Contact Derm.* 1984;10:424–429.

# Chapter 7

## CUTANEOUS TRAUMA AND ITS TREATMENT

MICHAEL MULVANEY, M.D.<sup>\*</sup> AND ALLAN HARRINGTON, M.D.<sup>†</sup>

---

### INTRODUCTION

#### FRICTION BLISTERS

Pathogenesis  
Risk Factors  
Prevention and Treatment

#### CUTANEOUS TRAUMA

Anatomy  
Evaluation and First Aid  
Microbiology

#### SURGICAL INTERVENTION

Anesthesia  
Surgical Technique  
Wound Healing  
Wound Dressings  
Complications

### SUMMARY

<sup>\*</sup>2 Corporate Plaza, Albany, New York 12203; formerly, Major, Medical Corps, U.S. Army, Dermatology Service, Walter Reed Army Medical Center, Washington, D.C. 20307-5001

<sup>†</sup>Major, Medical Corps, U.S. Army; Dermatology Service, Walter Reed Army Medical Center, Washington, D.C. 20307-5001

## INTRODUCTION

The skin presents itself on the front lines of defense against the outside world, affected by the harsh effects of the environment: high and low humidity and temperature, solar radiation, wind, dirt, arthropods, and infectious agents. The soldier's skin may also be assaulted by nuclear, biological, and chemical agents. Finally, skin on the feet is frequently subjected to frictional forces, which causes blisters. Dermatologists have had a traditional role in caring for skin disease resulting from many of these insults.

With the advent of dermatologic surgery, knowledge and experience in caring for wounded skin has been established. Present requirements for dermatology residency mandate knowledge of principles and practical competence in basic skin surgery, including excisional surgery with simple and layered closures. Knowledge of principles is also man-

datory for scar revision, skin grafts, and local cutaneous flaps. It is a natural extension of this expertise for the dermatologist to be involved in caring for traumatic injury to the skin. Most of the dermatologists deployed during Operations Desert Shield and Desert Storm were in general medical officer positions. Those stationed at battalion aid stations were likely to receive and treat soldiers with traumatic skin injuries.

Treatment of cutaneous traumatic injuries draws on knowledge that is well established in dermatologic surgery: anatomy, anesthesia, microbiology, wound healing, surgical technique, dressings, and scar revisions. An approach based on this knowledge will be presented in this chapter. In addition, because of the prevalence of friction blisters in the military, a comprehensive review of this area will be presented.

## FRICION BLISTERS

Friction blisters are believed to be confined to humans, occurring with such frequency that they are considered one of the most common reactions to trauma.<sup>1</sup> Friction blisters are especially important in the military, where they can jeopardize mission performance by decreasing a soldier's work tolerance and increasing manpower loss. Friction blisters are also of significance in athletics, especially distance running, where they adversely affect performance. Finally, this type of blister can provide an important diagnostic clue to a group of inherited diseases called epidermolysis bullosa. This genodermatosis has as a hallmark blisters that are easily induced by friction.

Despite the prevalence of friction blisters, there has been a paucity of scientific study in this area. This deficiency stands in marked contrast to the well-researched classic bullous dermatoses (eg, pemphigoid, pemphigus, and dermatitis herpetiformis). The military has been an important contributor to the present fund of knowledge on friction blisters.

In the military, friction blisters have long been recognized as a significant medical problem.<sup>2</sup> The high incidence of friction blisters at military training centers is especially well documented. It has been estimated that 20% or more of soldiers sustain friction blisters during the early weeks of training.<sup>3</sup>

Even experienced and well-conditioned soldiers can have a blister rate approaching 50% as a result of a long march.<sup>4</sup>

Friction blisters of the feet may be a short-lived medical problem, but for soldiers they are not a trivial condition. The treatment of these blisters accounts for a significant loss of time for the medical staff and the troops. The morbidity associated with friction blisters sometimes extends beyond the pain and discomfort of the lesion. One study reported that 84% of the cellulitis treated in a navy recruit population was caused by friction blisters, with an average loss of 8 days per case.<sup>5</sup> Of note, cellulitis composed over 17% of all recruit admissions.

### Pathogenesis

To better understand the pathogenesis of friction blisters, it is first necessary to review briefly the superficial anatomy of the skin. The most superficial layer of the skin is the epidermis, consisting of several layers of cells, with the stratum corneum its outermost layer. The next layers are the stratum granulosum, followed by the stratum malpighian, and finally the stratum basale. The stratum basale is the deepest layer of the epidermis and is located adjacent to the dermis.

The histology of a friction blister has a characteristic pattern. One observes necrosis of keratinocytes in the stratum malpighian, which leads to separation of the epidermis. The cleavage plane always shows the roof of the blisters to consist of stratum corneum, stratum granulosum, and some cellular debris. The epidermis below the cleft does not show any significant cellular damage.<sup>6</sup>

A blister is not the only possible endpoint when friction is encountered. If the friction is applied in small amounts over a longer time (weeks to months), then the result is epidermal hypertrophy (thickening of the skin).<sup>2</sup> One example of this endpoint is a callus, which is known to protect against the development of friction blisters. If a significant friction force is applied acutely to areas of the body where the epidermis is not thick, then an abrasion results.<sup>1</sup> As a result, friction blisters typically form on the palms and soles, which have a very thick epidermis.

The most important forces in the formation of a friction blister are the dynamic shear forces. These are believed to be composed of interrelated forces consisting of vertical forces, fore and aft shear, lateral shear, and torque.<sup>7-9</sup> The complexity of the physics of shear force, along with the variability of gait and bone structure of the foot, make it impossible to quantify a specific force required to produce a blister.

Separation of the epidermis is determined not only by the net shear force transferred to the skin surface but also by the frictional characteristics of the skin-environment interface.<sup>2</sup> Knowledge of factors that can influence this frictional force is important in helping to understand and prevent the formation of friction blisters. The surface conditions of the skin influence the development of friction blisters by altering the coefficient of friction between the skin and the boot. Keeping the foot dry has been shown to reduce the formation of friction blisters by lowering the coefficient of friction.<sup>10</sup> Wet skin also lowers the coefficient of friction, decreasing the risk for friction blisters. Moderately moist skin, however, will tend to cause more blisters because the coefficient of friction is increased.<sup>10-12</sup>

### Risk Factors

In addition to moderately moist skin, several other risk factors are known to influence friction blister formation. Improperly fitting or poorly designed shoes have long been recognized as a contributing factor. Several studies of basic training soldiers have shown that the majority of blister problems appear in the first 2 to 3 weeks.<sup>13,14</sup> A

recent study done with Reserve Officer Training Corps (ROTC) cadets in initial officer basic training revealed less blister formation in officers who frequently ran long distances.<sup>15</sup> This same study showed no advantage to wearing broken-in boots on road marches.

Additional risk factors were identified when studying ROTC cadets at summer camp.<sup>15</sup> Females had a relative risk 1.6-fold greater than that of males. Cadets with a history of blisters in the 2 years before camp had an increased risk of blister formation. Cadets who reported wearing their boots less than 20 hours per week during the 2 weeks immediately before camp had an elevated risk of friction blister formation. One of the conclusions drawn from this study was that prevention of blisters primarily through conditioning the foot with a skin-thickening response was one of the most important steps that could be made in preventing friction blisters.

Another very important risk factor for friction blister formation is socks and their fiber composition.<sup>16</sup> Poorly fitting or worn-out socks have been identified as an important agent in the formation of friction blisters. Of even more significance is the information obtained after studying long-distance running. The results showed that an acrylic fiber sock was associated with fewer and smaller blisters when compared directly with cotton fiber socks. The Thor-lo brand of sock (manufactured by Thorneburg Hosiery Co., Inc., Statesville, N.C.) appears to have been associated with fewer blisters for army-tested soldiers when compared against the standard issued sock: acrylic wicks away moisture from the foot.<sup>17</sup> Socks made of natural fibers like cotton and wool absorb moisture, resulting in a harder, bulkier sock that promotes larger and more frequent blisters. It is important to note that the Thor-lo sock contains higher-density padding where frictional forces are greatest and snug-fitting, low-density padding in the arch area, to allow for better conformity. This differential in sock thickness may also be important in reduced blister formation. All acrylic socks do not possess this type of construction.

### Prevention and Treatment

Prevention of friction blister formation is the most important front-line approach in dealing with this common problem.<sup>1</sup> Preventive measures should begin with preenlistment evaluation for congenital or acquired anomalies of the feet and skin as well as assuring adequate fit of shoes. Foot-

care lectures to recruits and recruit commanders' stressing prevention and early recognition of blisters are also important strategies.

Prevention of friction blisters can be divided into two categories: toughening the skin and reducing shear force. Currently, no adequate commercially available topical products exist to harden the skin surface. The use of tincture of benzoin has been reported anecdotally but the inconvenience and the high incidence of contact dermatitis makes this impractical.<sup>3</sup> The development of epidermal hypertrophy through conditioning the skin results in a decreased susceptibility to friction blisters.<sup>15</sup> This approach is very effective when it can be implemented.

Shear force has been decreased with several modalities. Insoles and teflon sprays successfully reduce the shearing effect, but their limited availability and considerable expense make these items impractical for large-scale military use.<sup>3</sup> A study of U.S. Marine Corps recruits showed that the use of an antiperspirant foot powder resulted in fewer friction blisters.<sup>18</sup> This outcome was seen because a dryer foot has a decreased coefficient of friction. Similar results were revealed in a study of U.S. Army soldiers that showed a reduction in friction

blisters with the use of antiperspirant solutions.<sup>19</sup> However, the frequent finding of irritant dermatitis (38%) made this therapeutic option impractical.

The most exciting recent advances in the prevention of friction blisters have involved sock studies, as noted above. Acrylic socks with different padding densities have been shown to decrease the number and size of friction blisters in marathon runners and soldiers.<sup>16,17</sup>

The most common approach to the treatment of friction blisters involves first draining the blister with a sterile needle. A doughnut shape of moleskin is then cut to surround the blister, and a cap of moleskin is placed over the blister. Other aspects of treatment include daily cleaning, preferably with hydrogen peroxide, followed by the application of an antibacterial ointment. Surveillance for the development of lymphangitis or cellulitis is important. Finally, if the epidermal roof has been completely lost, then another membrane covering is needed to provide optimal conditions for wound healing. Some of the newer synthetic hydrocolloid dressings (eg, DuoDERM, manufactured by ConvaTec, Princeton, N.J.) or hydrogel dressings (eg, Vigilon, manufactured by C.R. Bard, Inc., Murray Hill, N.J.) are effective options.

## CUTANEOUS TRAUMA

Cutaneous trauma treated by a dermatologist is restricted to superficial soft-tissue injuries. Anatomically, all of these lesions have in common disruption of at least the epidermis. The dermis, subcutaneous fat, and superficial fascia can also be injured. Common examples of cutaneous trauma include lacerations, burns, blisters, and traumatic tattoos from blast injuries.

### Anatomy

Evaluating a wound for the extent of cutaneous damage and planning for repair rely heavily on a thorough knowledge of the injured area's anatomy. The initial evaluation should consider the possibility of underlying bone or visceral injury. In wounds confined to the skin and subcutaneous tissue, certain areas of the body contain extremely important nerves, arteries, muscles, and other specialized structures. These danger areas will be discussed in detail in this section. Discussion of the orbit, although vital, is beyond the scope of this chapter.

The face contains an abundance of superficially located structures that may be damaged by trauma.

The facial nerve exits the stylohyoid foramen at the base of the skull, entering the parotid gland near the angle of the jaw, where it separates into five branches. These branches fan out across the face, ranging from the temple and forehead down to the neck and mandible. The facial nerve supplies motor nerves for the muscles of facial expression. Injury to these branches will give a noticeable deficit to facial movement.<sup>20</sup>

The temporal branch of the facial nerve is the branch most superficially located and easily injured. The nerve exits the parotid gland and traverses the zygomatic arch and temporal region, terminating in the occipitofrontal muscle at the forehead. The nerve is located in the superficial temporalis fascia, which is covered by a thin subcutaneous tissue layer and overlying skin. This thin protective layer is easily breached by a laceration. Once the nerve has entered the occipitofrontal muscle fascia, it arborizes sufficiently to maintain function in the event of a localized injury to the forehead.

The zygomatic and buccal branches of the facial nerve supply motor nerves to the lower eyelid, nose, and lip elevators. These nerves exit the parotid

fascia under a fairly thick cheek fat pad and emerge at the undersurface of the facial muscles they innervate. Injury of the lateral (proximal) third of their route would involve the parotid gland. This would cause extensive loss of function from these branches and possibly others. Injury along the middle third would require a deep penetration into the cheek fat pad. This injury would also threaten Stenson's duct, which traverses the parotid gland inferior to the zygoma before entering the mouth at the buccal mucosa. Localized injury of the distal third of these branches may not yield significant loss of muscle function due to the extensive branching of these nerves.

The marginal mandibular nerve exits the parotid gland and usually runs behind the ramus of the mandible. In some cases, however, it may be lateral and inferior to the ramus, exposing it to injury. The branch then runs protected by the medial surface of the mandible. It reaches the body of the mandible and, along with the facial artery, travels medially and superiorly toward the lateral commissure of the mouth. The nerve arborizes and innervates the muscles around the mouth, especially the orbicularis oris and the downward depressors of the lips. The probable points of injury are the ramus and the body of the mandible. Injury of the body of the mandible could be accompanied by profuse hemorrhage if the facial artery were severed. The cervical branch of the facial nerve innervates the platysma and has little clinical significance.<sup>20</sup>

The sensory innervation of the face is supplied by the trigeminal nerves. The nerves exit foramina of the skull in distinct locations. The ophthalmic branch ( $V_1$ ) gives rise to the supraorbital and supratrochlear nerves, which provide sensory (afferent) function to the forehead and anterior scalp.

The infraorbital nerve of the maxillary branch ( $V_2$ ) surfaces at the infraorbital foramen 1 cm below the infraorbital ridge in the midpupillary line. The nerve spreads out to innervate the lateral nose, upper lip, medial cheek, and lower eyelid. The mental nerve arises from the mandibular branch ( $V_3$ ), passing through the mental foramen of the mandible approximately 1 cm above the jaw line in the same midpupillary line that aligns the supraorbital and infraorbital nerves.

The arterial supply of the face is provided mostly by the facial artery, a branch of the external carotid artery. The artery emerges from under the mandible and travels in a superior and medial direction along the lateral aspect of the mouth. The inferior and superior labial arteries branch medially to supply the lips. These arteries are on the posterior labial surfaces between the submucosa and the

orbicularis oris, and they can produce significant hemorrhage. They may bleed from both sides of a laceration. The angular artery continues after the labial arteries branch off the facial artery. It lies along the side of the nose in the nasofacial sulcus and passes into the medial canthal region, where it anastomoses with the dorsal nasal artery. This latter artery is a branch of the internal carotid artery, which exits the side of the nasal bone in the medial canthal region.<sup>20</sup>

The auriculotemporal artery, also a branch of the external carotid artery, progresses in the preauricular fold, branching into the superficial temporal artery. Other arteries travel along with the previously named sensory nerves. The scalp is a rich anastomotic plexus of arteries and veins.

In general, any artery that is transected can be ligated without concern for ischemia of the supplied skin, provided the other anastomotic connections are intact. If a strip of skin is partially avulsed, then the blood supply may be significantly compromised.

The neck contains several vital structures that, if damaged, are beyond the expertise of the dermatologic surgeon. The trachea, thyroid gland, carotid arteries, and jugular vein are located in the anterior neck. Injury to these structures is life threatening. The lateral and posterior neck are relatively free from subcutaneous vital structures. The architecture is defined by large muscles located deep to the skin and subcutaneous tissue. The only important nerve to be aware of in this region is the spinal accessory nerve, located posterior to the upper one third of the sternocleidomastoid muscle. This nerve travels posterocaudally into the trapezius muscle. It is located on the fascia overlying the scalenus muscle. Injury to this nerve would lead to a deficit in abducting the arm laterally and fixing the scapula.

Injuries to the skin and subcutaneous tissues of the trunk that do not penetrate into pleura, peritoneum, or muscle do not approach any significant arteries or nerves; therefore, potential damage is limited. Injury to the extremities must be carefully evaluated, especially in areas of the forearm, hand, and foot. Many arteries, nerves, tendons, and joint spaces are close to the skin surface and are easily injured. Surgeons with special competence, such as orthopedic surgeons, plastic surgeons, or podiatrists, would be logical choices for definitive care of these injuries. Detailed description of this anatomy is beyond the scope of this chapter.

The arms and thighs consist of large areas of skin covering muscle tissue. Except near the elbow and knee, most important structures are well protected by these muscles.

The genitalia have tremendous psychological importance in addition to their structural importance. Injury to the urethra or other deeper structures of the penis or scrotum would best be handled by a urologist or plastic surgeon. Superficial wounds, however, may be treated like those in any other area.

### Evaluation and First Aid

In emergent care, basic initial evaluation takes little time but may be lifesaving. Airway patency, breathing, and adequate circulatory system function should be evaluated first. Skin and soft-tissue injury care must be delayed until circulatory volume is adequate and internal injuries have been ruled out. With any significant facial trauma, cervical fracture should be suspected, even in the absence of symptoms.<sup>21</sup> Bleeding should be controlled by pressure until the patient is proved to be free of serious underlying injury. Casualties should be appropriately stabilized and triaged if further care is needed.

The types of wounds that a dermatologist would be most helpful with include abrasions, lacerations of the skin, and traumatic tattoos. Evaluation of these wounds requires a historical account of the injury. The nature of the wound, the amount of contamination that has entered the skin, the amount of delay in reaching care, and first aid rendered since the injury are ascertained. The medical status of the casualty including medications, significant medical problems such as diabetes or bleeding disorders, and tetanus immunization status are determined.

Examination of the wound proceeds with concern for loss of function, depth of injury, and cosmetic impact. Functional considerations include damage to major sensory or motor nerves, arterial supply, and muscle and tendon damage. These injuries would best be managed by a specialist with experience with such injuries. Similarly, injuries deeper than the skin and subcutaneous tissue are beyond the dermatologist's expertise. Highly specialized areas such as eyelids, hands, and genitalia would also be referred if the injury is extensive.<sup>21</sup>

Neurological testing of the surrounding skin may be hampered by the pain of the injury, but it needs to be thoroughly performed and documented before the area is anesthetized for debridement and closure. Knowledge of neuroanatomy is required to predict what motor nerves may be in the injured area. In an emergency, testing with standard pinpricks should be adequate for determining sen-

sory nerve function. Frequently, small cutaneous nerves will be transected by the injury. This finding should be documented before beginning any repair of the skin, and the patient should be reassured that sensory function usually returns. Regional loss of sensory function would mandate further evaluation by an experienced specialist in this form of injury. Nerve repair could then be done immediately, or in 10 to 12 days. Nerve grafts may also be indicated.

After the neurological exam is complete, the wound should be cleaned and debrided to evaluate the wound further. Local anesthesia, regional anesthesia, or both make the process comfortable and efficient. Anesthesia will be described later.

Irrigation with saline will remove blood and clots; dirt and other foreign-body material; and gross bacterial contamination. Antibacterial agents with detergents may also be used: Betadine (povidone-iodine, manufactured by Purdue Frederick, Norwalk, Conn.), Hibiclens (chlorhexidine gluconate, manufactured by Stuart, Wilmington, Del.), or pHisoHex (hexachlorophene, manufactured by Sanofi Winthrop, New York, N.Y.). To prevent further contamination of the wound, surgical aseptic technique should be employed, including sterile drapes, gloves, instruments, and bowls for solutions. Battlefield wounds should be assumed to be contaminated from injury and reasonable means should be undertaken to prevent further contamination, thereby reducing the chance of wound infection. In the military environment, several echelons of care may be used to treat an individual patient. Each manipulation of the wound will bring another chance for bacterial contamination. Therefore, all reasonable efforts should be made to reduce such contamination.<sup>22</sup>

With all the clots and foreign bodies removed, careful inspection with good lighting should reveal the extent of the injury. If bleeding is present, then control by means of electrocoagulation (biterminal) or electrodesiccation (monoterminal) should be effective.<sup>23</sup> Bleeding from larger skin arteries may need to be controlled by ligation. The artery is first clamped with a hemostat at its bleeding point, then a loop of absorbable suture is placed around the vessel and tied firmly. The hemostat is slowly released to check for the adequacy of the ligature. For major arteries, nonabsorbable suture is recommended. Hemostasis should be careful and complete. Bleeding after surgery may lead to hematoma formation. The surgeon should be aware that the addition of epinephrine to the anesthetic solution



may temporarily constrict vessels, which may then bleed several hours later.

Many arteries travel near nerve bundles. Overzealous electrosurgery or sloppy ligation may cause permanent damage to nearby nerves. All hemostasis should be meticulous and complete, especially in wounds that are to be closed by suture.

### Microbiology

It is reasonable to assume that all wounds are contaminated with bacteria and particulate matter. With aggressive wound irrigation and debridement, most of the foreign material is removed. The use of antibiotics to prevent clinically apparent infections may be helpful in some instances.<sup>21</sup>

From the history and examination of the wound, the approximate type and quantity of contamination can be determined. The length of time from injury to care will have a large impact on the wound. Many combat-related injuries will be delayed in receiving initial care. The healthcare delivery system in the field involves echelons of service. This contributes to multiple delays in transportation and evaluation. Most non-life-threatening soft-tissue injuries will be triaged less urgently than more serious wounds. The health of the individual also must be taken into account. Exhausted, poorly nourished soldiers who have had prolonged exposure to cold or heat may have less resistance to infection.

Bacteria that commonly have been found to cause wound infections in wartime are staphylococci (*S aureus* and *S epidermidis*), streptococci (hemolytic, nonhemolytic, and enterococci), coliforms (enteric Gram-negative rods), *Pseudomonas aeruginosa*, *Proteus* species, *Hemophilus influenza*, *Clostridium* species (*C tetanus* and *C perfringens*), and *Bacillus subtilis*. The type of organism encountered will vary with the type of contamination, climate, and the location of the wound.<sup>24</sup>

Animal bites may be contaminated with *Pasteurella multocida*.<sup>25</sup> Human bites contain a mixed

flora of streptococci (group A, non-group A), *Bacteroides* species, diphtheroids, *Hemophilus influenza*, and enterococci. Soil-contaminated wounds may have multiple organisms present including clostridia, *Bacillus* species, and various Gram-negative rods. Sandy soil is less contaminated with bacteria than nonsandy soil.<sup>26</sup>

Traumatic wounds should be treated with prophylactic antibiotics to prevent postoperative infections. The antibiotic is best given shortly before or within 2 hours after the procedure. However, this protocol is not possible with most traumatic wounds, which are usually hours or days old and heavily contaminated. The contaminating bacteria have had an opportunity to colonize or infect the wound before any prophylactic antibiotic could be utilized. Antibiotics in these cases would be used to prevent overt infection and sepsis. The potential causes of the infection must be adequately covered. The use of antibiotics should not replace the use of proper wound-management techniques including wound toilet, debridement, and careful surgical technique. In general, penicillin, erythromycin, and cephalosporins are useful against most of the common infecting organisms.<sup>27</sup> The exudate from overtly infected, draining wounds should be cultured and Gram-stained before antibiotic coverage is instituted.

Contaminated wounds that are left open are much less likely to become infected than those closed primarily. The wound may be closed 4 days or more after the initial evaluation with less risk of infection and sepsis, provided wound infection is not present at the time of delayed closure. If the wound exudate contains less than  $10^6$  organisms per milliliter, then clinical infection is unlikely. Experiments have been performed demonstrating that an inoculum of greater than  $10^6$  *S aureus* bacteria was necessary to produce pus, but lower numbers of bacteria produce redness and swelling.<sup>28</sup> Surgeons have commented<sup>29</sup> that what is surprising is not that wound infection occurs, but that it does not occur more frequently.

## SURGICAL INTERVENTION

The goals of surgical intervention on a traumatic wound are restoring function and achieving a cosmetically appealing result. Prevention of further morbidity due to the surgery is paramount and implicit. Through careful planning and meticulous techniques, all these objectives may be met.

Much of the planning should be preceded by

evaluation of the type of wound, extent of injuries, and anatomical considerations. The first question for the dermatologist should be whether the management of the wound exceeds his or her ability; if so, appropriate consultation or referral should be made. If the dermatologist feels competent, then the planning begins.

## Anesthesia

Any soft-tissue wound that is to be properly cleaned, debrided, and repaired must be anesthetized. For the wounds that a dermatologist would treat, local anesthesia, occasionally augmented with intravenous sedation, is all that should be needed. As was mentioned previously, a thorough neurological exam must precede the instillation of any anesthetic.

Because of the efficacy, safety, short duration of onset, and familiarity by dermatologists, lidocaine (1% or 2%) is the most anesthetic agent. Others have properties such as longer action (ie, bupivacaine), which may be desired. Etidocaine combines shorter duration of onset with longer duration of anesthesia.<sup>30</sup>

The addition of epinephrine (1:100,000–1:200,000) will control bleeding and increase the duration of anesthesia when combined with a local regional anesthetic. Caution must be used in areas where tenuous blood supply exists. Danger areas include acral skin, digital arteries, partially avulsed skin flaps, lower legs, and feet. Patients at high risk include those with significant vascular compromise due to diabetes, atherosclerosis, or other causes. If the patient is taking medications known to interact with epinephrine such as monoamine oxidase (MAO) inhibitors, propranolol, or tricyclic antidepressants, significant blood pressure elevation may result.<sup>29</sup>

The technique for anesthetizing the skin would be similar to that for elective soft-tissue surgery. The major difference is the pain the patient has prior to starting. Anxiety may also be much greater because of the circumstances of the injury and the pain present. Vocal anesthesia (ie, coaching) will make a tremendous impact on the success of the anesthetic experience. Reassurance, explanations, and compassion will relieve the anxiety and make the anesthetic administration easier for the patient and the physician. A recently described technique will significantly decrease the stinging effect of local anesthesia. The addition of sodium bicarbonate (1 mEq/mL) to the anesthetic solution will adjust the pH closer to the physiological range. This adjustment is accomplished by adding 1 mL of sodium bicarbonate solution for every 10 mL of anesthetic solution to be made. The solution should be used within 1 week of mixing to ensure effectiveness.<sup>31</sup>

Inserting a small-gauge needle (nos. 27–30) perpendicularly through the skin into the subcutaneous tissue will cause only slight discomfort. Slow instillation of anesthetic agent will decrease the

pain of injection. The needle is then advanced in the subcutaneous plane to minimize the number of needle sticks. Reinsertion of the needle should be through previously anesthetized areas. Rushing will greatly increase the pain for the patient.

A variety of strategies can be used for anesthetizing a skin wound. Wounds may be quite large, and regional nerve blocks can decrease both the amount of anesthetics used and the discomfort of large amounts of local infiltration. Knowledge of the sensory innervation of the skin will allow planning of appropriate blocks. When performing a regional block, the objective is to bathe around rather than to inject directly into the nerve bundles. This technique will lessen the pain of injection and prevent possible nerve damage.

Important regional facial sensory nerve blocks include supraorbital, supratrochlear, infraorbital, and mental. Digital blocks of the fingers are also useful. Unless one has experience with regional anesthesia of the extremities, these should not be attempted.

If individual nerves are not suitable for regional block, then a field block can be utilized. Also, by injecting initially into the proximal path of the nerve supply and then advancing distally, the physician can lessen the pain of anesthesia. Local infiltration of the wound should be performed last because injection of tender tissue is more painful than injection of normal tissue.

Once the area is anesthetized, cleaning, debridement, and wound repair can proceed. Instillation of a long-acting anesthetic such as bupivacaine may give postoperative pain relief for several hours.

## Surgical Technique

The decision to close the wound or to allow second-intention healing with possible delayed closure or grafting depends on several factors, including

- the length of time from injury to repair,
- the amount of contamination in the wound,
- the amount of devitalized or damaged tissue, and
- the location of the wound.

Although immediate closure offers quicker and easier repair of the defect, it greatly increases the risk of infection. Bacteria proliferate rapidly in the necrotic debris and clots of an open wound. Foreign bodies offer safe haven for these bacteria. The longer the time between injury and repair, the higher the bacterial counts. Wounds over 6 hours old

should be considered for second-intention healing or delayed repairs.

Contamination is inevitable in traumatic wounds. Relatively clean lacerations caused by glass or clean sharp objects may be cleaned of most foreign bodies and repaired. Grossly contaminated wounds, or those contacted by feces or saliva, should remain open. Devitalized tissue and necrotic skin are much more likely to harbor bacteria and, unless thoroughly excised, will lead to infection. Finally, the location of the wound or, more importantly, the adequacy of the blood supply also is considered in planning the closure. Wounds of the lower extremity are much more likely to be infected. These wounds are at high risk of infection if closed. However, due to the high volume of blood flow and generous collateral blood supply, facial and scalp lacerations are more resistant to infection and should be closed immediately.

The necrotic tissue and foreign body must be removed. Copious irrigation and direct scrubbing are very useful in preparing the wound. Irrigation should be carried out with a high-pressure system consisting of a 20- to 50-mL syringe with an 18- to 21-gauge needle. This will remove dirt and bacteria but will not embed these materials more deeply in the wound. Direct scrubbing with a sponge will remove gross material but probably does not reduce infection.

Clearly devitalized tissue should be excised carefully. Any recalcitrant foreign body should be removed also. The surface shape of the wound should be contoured to a smooth, symmetrical configuration. The sides of the wound should be at a 90° angle to the surface of the skin to prevent inversion of the scar. Reshaping should be tempered with the resultant defect's ability to close without undue tension or distortion at adjacent free edges such as eyelids, lips, or nostril rims. It may be more prudent to keep the wound small and irregular, with plans for later reconstruction, than to make a neat, but time-consuming, closure that may be both difficult to close and at greater risk for infection. Skin grafts, flaps, or reexcision with possible z-plasty, w-plasty, or v to y repairs may be done after healing is completed, under more controlled and less contaminated conditions.

Surgical debridement should remove all attached necrotic debris, devitalized tissue, and irregular jagged wound edges. On noncritical areas such as the trunk and extremities, the debridement can involve an excision around all wounded tissue. When vital structures such as nerves, muscles, and specialized structures of the face are close to the

wound, then conservative debridement is recommended. When tissue vitality is uncertain, a delay of several days will allow a demarcation to develop, thus guiding further debridement.

If the wound is to be closed primarily after debridement, one should evaluate the direction and shape of the wound. Traumatic wounds often do not conform to the relaxed skin tension lines (RSTLs). Shifting the direction of closure may require a z-plasty to put the tension of closure perpendicular to these RSTLs. This additional surgery may be best delayed until after healing of the first repair. Scar revision under more controlled conditions will decrease the risk of infection.

The choice of suture materials should minimize the risk of both infection and wound dehiscence. Subcuticular sutures such as vicryl, dextron, or polydioxone (PDS) should be reserved for relatively clean wounds and those under moderate tension. High-tension closures, hematoma, and gross contamination are risk factors for infection that will be compounded by the foreign body of absorbable suture. Attention should be given to the tension of the sutures. Careful approximation must be observed, and strangulation must be avoided. Low-tension wounds may be closed with a monofilament nonabsorbable suture such as prolene or nylon. Adhesive strips are also useful in superficial or low-tension wounds; they may be used without anesthesia, and negate surface removal. They also have a low incidence of wound infection compared with percutaneous sutures.<sup>32</sup> As with all surgical techniques, gentle handling of the tissue is mandatory. Gentle traction with skin hooks or delicate pressure from forceps with teeth will prevent further crushing of the tissue. Hemostasis should be complete, especially if immediate closure is anticipated. For small blood vessels, light electric desiccation or electrofulguration will produce less depth of necrosis than electrocoagulation. If larger vessels are encountered, then electrocoagulation or suture ligation should be considered.

If the wound closure is delayed, then a dressing is applied. (Opinions may differ as to whether to change the dressing daily or to leave it in place for several days.) After 4 to 7 days the wound will have gone through the inflammatory stage of wound healing and will be entering into the granulation tissue stage. This highly vascular state is resistant to infection. At this time, the wound can be closed or a flap or skin graft can be placed. Some wound construction may be started at this time, and more complicated or involved closure may be attempted. Healing may be completed by second intention.

## Wound Healing

The process of healing in the skin and subcutaneous tissue depends on the depth and nature of the injury. Superficial abrasions need only to restore the epidermis. Full-thickness skin lacerations, without loss of tissue, can be reapproximated easily and healed in a short period of time. Full-thickness defects of skin and subcutaneous tissue with significant tissue loss, which preclude primary closure, require a lengthy and involved process of wound repair. The defect must restore a volume of tissue before the epidermis can regrow or be grafted over the wound.

Despite these clinical differences in wound healing, many similarities are found in the biochemical and physiological stages. Several models for wound healing exist, most with three or four stages. Although these stages overlap in time and interact with the other stages, they are distinct enough in function to be separated. The classification in this chapter will include inflammation, granulation, fibroplasia and wound contraction, epidermization, and maturation.<sup>33</sup>

### *Inflammation*

Inflammation initiates all the subsequent steps of wound healing. It primes the wound for the construction phases of granulation, fibroplasia, and epidermization. Many authorities break this stage into early and late phases. The early inflammatory phase begins immediately with platelet aggregation and the release of vasoactive substances. Vasoconstriction of severed vessels aids in hemostasis, and vasodilation of local intact vessels allow for the influx of plasma proteins and neutrophils into the wound.<sup>33</sup>

The plasma proteins involved in the formation of fibrin help to stabilize the clot and also elaborate vasoactive and other biologically active substances. The platelets and fibrin pathway generate a multitude of products including prostaglandins, leukotrienes, growth factors, and kinins. Complement activation occurs, generating products including C3a and C5a. One of the first cellular responses to all of these substances is the influx of neutrophils, whose purpose is to destroy and phagocytize bacteria and foreign-body debris.

The late inflammatory stage is characterized by the arrival of the monocyte. This critical cell arrives at the wound at about the third day and is converted to a tissue macrophage. Because it can survive low oxygen tension and pH, it is able to survive in the wound and effectively clean up what the neutro-

phils have not been able to finish. Besides being a highly effective scavenger, the macrophage is also a manager of early fibroblast function and proliferation. Lymphocytes are also present at this time and, although not essential, have a control function in wound healing.<sup>33</sup>

### *Granulation*

The second stage of wound healing, granulation, is the beginning of reconstruction of the skin. Granulation tissue is composed of a rich plexus of new capillaries within a loose stroma of glycosaminoglycans, fibrin, fibronectin, and immature collagen. During the inflammatory phase, the fibrin clot forms a scaffolding matrix, which is then coated with fibronectin derived from serum and fibroblast sources. Activated fibroblasts and endothelial cell buds migrate over this fibronectin coating, which acts as a glue to the underlying fibrin. As the fibroblasts migrate into the fibrin matrix, they synthesize more fibronectin, glycosaminoglycans, and new collagen. Gradually, the fibrin is lysed and collagen replaces it. Endothelial cells and new capillaries also invade this matrix, driven by low oxygen and high lactate concentrations. Complete granulation tissue replacement of a deep wound may take several weeks.<sup>33</sup>

### *Fibroplasia and Wound Contraction*

In the third stage of wound healing, the fibroblast undergoes a morphologic change in order to migrate into the wound. The appearance of contractile proteins in the cytoplasm provides a mechanism for motility. Because these cells greatly resemble muscle cells, they are called myofibroblasts. Within 7 days, these myofibroblasts have penetrated the matrix enough to begin exerting their contractile force on the surrounding wound edges. This force increases as more cells participate, and clinically measurable contraction takes place. This phase lasts for several weeks, even after epidermization has occurred. The clinical effect is helpful in large wounds to decrease the size of the scar and to shorten healing time. Contracted scars can cause serious morbidity in function and appearance if they are located near joints or on the face near eyelids, lips, or other movable structures.<sup>33</sup>

### *Epidermization*

Epidermization begins within a few days in superficial wounds where the appendages are intact.

Hair follicles, sweat glands, and the surrounding wound edges all contribute to the advancing front of keratinocytes. In full-thickness wounds, this front must wait until granulation tissue has filled the defect, and the keratinocytes come only from the edge of the wounds.<sup>29</sup>

### Maturation

Maturation is the final stage of wound healing. It begins when all the other stages end and is variable in time, depending on the wound. The noticeable features are the loss of redness and induration from the wound. The scar becomes softer and white or skin-colored. Histologically, the fibroplasia and hypervascularity of the wound disappear, to be replaced by a hypocellular and hypovascular scar. The collagen produced early in wound healing is more soluble with less cross-linkage. With maturation, collagen bundles are thicker and less soluble with more cross-linking.<sup>33</sup>

Two clinically different types of wound healing exist: primary intention and second intention. An example of primary intention healing would be a simple laceration that is reapproximated by suture. The granulation and contraction stages are minimal, and epidermization is complete within a few days. Second intention healing involves a full-thickness loss of skin volume. The stages of wound healing as described previously must all occur.<sup>34</sup>

### Wound Dressings

The care of a wound in a military field setting will differ from care in a medical center. Resources such as time, personnel, and materials may be limited. The surgeon must pick from the available dressing materials, with the best choice based on the criteria discussed below.

Tremendous advances in the understanding of wound healing and technology have radically changed the approach to wound dressings. Whereas wounds were previously covered with dry gauze or left uncovered, it is now standard to use moist, semiocclusive dressings of ever-increasing sophistication.<sup>35</sup> Growth factors, bioactive dressings, and even cultured epidermal coverings are now being used in major medical centers to facilitate wound healing.<sup>34,36</sup> An effective dressing for wound healing should

- absorb drainage,
- prevent contamination,
- provide pressure to control bleeding,

- immobilize or splint the wound,
- prevent desiccation of tissue,
- be easy to change with minimal discomfort, and
- cushion the wound from further trauma.

In addition, the dressing should be readily available at reasonable cost.

No dressing is perfect for every wound. Grossly contaminated or actively draining wounds require that their dressings be changed more often and have greater absorption. Later, when the wound may be cleaner and have less drainage, a less-absorptive dressing needing less-frequent changes may be used.

### Complications

The most common and devastating problem of traumatic wounds is infection. As previously mentioned, many factors contribute to wound infection. These wounds are at risk for much greater problems such as sepsis, gas gangrene, and necrotizing fasciitis. Early recognition and treatment of these serious conditions is vitally important. With these more involved situations, consultation with a general surgeon will be required.

Prolonged bleeding and hematomas are also probable complications of traumatic wounds. Inadequate hemostasis at the time of surgery and delayed bleeding are the likely causes. Congenital or acquired coagulopathies would be unusual but should be considered in patients with persistent bleeding. Disseminated intravascular coagulation may be accompanied by sepsis in the wounded patient. The presence of excess blood in the wound, coupled with the pressure effects on tissue from a hematoma, will increase the likelihood of infection. Early hematomas should be drained and the offending vessels controlled. If a hematoma has been present for several days, drainage will be difficult until the clot liquefies. Drainage with a large bore needle may be attempted when the clot feels more fluid. Many hematomas will resolve spontaneously.<sup>24</sup>

Necrosis of skin is caused by inadequate blood flow to tissue. Contributing causes include excessive tension, hematoma, infection, crush injuries, desiccation, or severe disruption of the arterial supply of the skin.

Wound dehiscence may result from infection, hematoma, or excessive tension on the wound edges. It causes delayed healing and an unattractive spread scar.<sup>24</sup>

Traumatic scars frequently will benefit from some form of reconstructive procedure, which traditionally falls in the realm of the plastic and reconstructive surgeon. Experienced dermatologic surgeons may be able to accomplish many of these procedures.

Many dermatologists now perform dermabrasion for the improvement of surgical or acne scarring. An irregular scar surface may be planed smooth by a brief, simple procedure that utilizes local anesthesia. Dermabrasion may be performed for blast tattoo (ie, an accidental depositing of pigmented particles within the dermis, often as the result of an explosion) to remove the pigment. A field-expedient method employs a stiff toothbrush rather than a diamond fraise. Because proper dermabrasion equipment does not exist in the field, this method

allows prompt treatment of the tattoo before the pigment has been trapped by macrophages.<sup>37,38</sup>

Hypertrophic scars or keloids may develop on the trunk, extremities, or occasionally on the face. A nonsurgical scar improvement may be obtained by intralesional steroid injection. A concentration of 2.5 to 40 mg/mL of triamcinolone acetonide may be injected at 3- to 6-week intervals, depending on the size, location, and aggressiveness of the excess scar tissue.

Finally, many scars improve with time. In young individuals, the scar line will be red for several months to a year. Many thick scars will soften, and contracted scars will relax. Before attempting a significant surgical revision, the treatment of time should be allowed.

## SUMMARY

The skin is vulnerable to injury due to environmental hazards in the battlefield environment. Extremes of weather, ultraviolet radiation, arthropod bites, chemical agents, frictional forces and lacerations from missile injury or accidents all may alter the natural barrier we depend upon to protect us from life-threatening insults. Dermatologists possess the clinical fund of knowledge and soft-tissue surgical skills to make them critical participants in the care of traumatic injuries to the skin.

Friction blisters have long been recognized as a significant medical problem in the military. The morbidity associated with friction blisters sometimes extends beyond the pain and discomfort of the lesion: secondary bacterial infection is common and often extends time lost per case to as long as a week. The most important forces in the formation of a friction blister are dynamic shear forces. Moderately moist skin, improperly fitting or poorly designed shoes, poorly fitting or worn-out socks, and wearing boots less than 20 hours per week during the 2 weeks immediately before training are all recognized risk factors for friction blisters. Prevention of friction blister formation is the most important front-line approach in dealing with this common problem and involves techniques designed to toughen the skin and reduce shear force. The development of epidermal hypertrophy through conditioning the skin, the use of an antiperspirant foot

powder, and the use of acrylic socks are all important preventive strategies.

Cutaneous trauma treated by a dermatologist is restricted to superficial soft-tissue injuries. In emergent care, basic initial evaluation takes little time but may be lifesaving. Airway patency, breathing, and adequate circulatory system function should be evaluated first. Skin and soft-tissue injury care must be delayed until circulatory volume is adequate and internal injuries have been ruled out. The types of wounds that a dermatologist is helpful with include abrasions, lacerations of the skin, and traumatic tattoos. Battlefield wounds should be assumed to be contaminated from injury. Aggressive wound irrigation and debridement, and treatment with prophylactic antibiotics to prevent post-operative infections, are crucial for traumatic wounds. In general, penicillin, erythromycin, and cephalosporins are useful against most of the common infecting organisms.

The goals of surgical intervention on a traumatic wound are restoring function and achieving a cosmetically appealing result. Local anesthesia, cleansing, debriding, repair, and dressing of such injuries to the skin are all aspects of wound care for which dermatologists are well trained. They should be incorporated into the surgical care team as needed in the particular medical care setting to which they are assigned.

## REFERENCES

1. Sulzberger MB, Cortese TA, Fishman L, et al. Studies on blisters produced by friction. Part 1: Results of linear rubbing and twisting techniques. *J Invest Dermatol.* 1966;47:456–465.
2. Akers WA, Sulzberger MB. The friction blister. *Milit Med.* 1977;16:369–372.
3. Jagoda A, Madden H, Hinson C. A friction blister prevention study in a population of marines. *Milit Med.* 1981;146:42–45.
4. Coopers DS. Research into foot lesions among Canadian Field Forces. CDA 2. Directorate of Clothing, General Engineering and Maintenance, Ottawa, Canada. Prepared for the 13th Commonwealth Defense Conference on Operational Clothing and Combat Equipment. Malaysia, 1981.
5. Hoeffler DF. Friction blisters and cellulitis in a navy recruit population. *Milit Med.* 1975;140:332–337.
6. Lever WF, Schaumburg-Lever G. *Histopathology of the Skin.* Philadelphia, Pa: JB Lippincott Co; 1990: 142.
7. Spence WR, Shields MN. Prevention of blisters, callosities and ulcers by absorption of shearing forces. *J Am Podiatry Assoc.* 1968;58:428–435.
8. Naylor PF. The skin surface and friction. *Br J Dermatol.* 1955;67:230.
9. Root ML, Orien WP, Weed JH. *Normal and Abnormal Function of the Foot.* Los Angeles, Calif: Clinical Biomechanics Corporation; 1977.
10. Naylor P. The measurement of epidermal strength. *Trans St John Hosp Dermatol Soc.* 1952;31:29.
11. Naylor PE. Experimental friction blisters. *Br J Dermatol.* 1955;67:327–342.
12. Whitfield A. On development of callosities, corns and warts. *Br J Dermatol.* 1932;44:580.
13. Ressler RJ. Epidemiology of friction blisters. *J Assn Mil Derm.* 1972;2:13–17.
14. Marks JG, Miller WW, Garcia RL. March cellulitis. *Milit Med.* May 1978:314.
15. Patterson HS, Woolley TW, Lednar WM. Foot blister risk factors in an ROTC summer camp population. *Milit Med.* 1994;159:130–135.
16. Herring KM, Richie DH. Friction blisters and sock fiber composition: A double-blind study. *J Am Podiatr Med Assoc.* 1990;80:63–71.
17. Greene CA. Operational forces interface group soldier enhancement program. Final report on the phase 1 evaluation of the improved sock systems. Natick, Mass: US Army National Research Center. 9 March 1993.
18. Hamlet M. Analysis of USMC boot sock and foot powder evaluation. Washington, DC: Marine Corps Research, Development and Acquisition Command. December 1990.
19. Darringrand A, Reynolds K, Jackson R, et al. Efficacy of antiperspirants on feet. *Milit Med.* 1992;157:256.
20. Salasche SJ, Bernstein G, Senkarik M. *Surgical Anatomy of the Head and Neck.* Norwalk, Conn: Appleton & Lange; 1988: 100–139.

21. Schwartz GR, Cayten CG, Mangelsen MA, et al. *Principles and Practice of Emergency Medicine*. 3rd ed. Philadelphia, Pa: Lea & Febiger; 1992: 879–1141.
22. Bellamy RF, Zajtchuk R. The management of ballistic wounds of soft tissue. In: Bellamy RF, Zajtchuk R, eds. *Conventional Warfare: Ballistic, Blast, and Burn Injuries*. Part 1, Vol 5. In: *Textbook of Military Medicine*. Washington, DC: US Department of the Army, Office of The Surgeon General, and Center of Excellence in Military Medical Research and Education; 1991: Chap 5.
23. Boughton RS, Spencer SK. Electrosurgical fundamentals. *J Am Acad Dermatol*. 1987;16:862–867.
24. Salasche SJ. Acute surgical complication: Cause, prevention, and treatment. *J Am Acad Dermatol*. 1986;15:1163–1185.
25. Weber DJ, Wolfson JS, Swartz MN, et al. *Pasteurella multocida* infection: Report of 34 cases and review of literature. *Medicine*. 1984;63:133–154.
26. Noble WC. *Microbiology of Human Skin*. 2nd ed. London, England: Lloyd-Luke; 1981: 117.
27. Feingold DS, Wagner RF. Antibacterial therapy. *J Amer Acad Dermatol*. 1986;14:535–548.
28. Elek SD. Experimental staphylococcal infections in the skin of man. *Ann NY Acad Sci*. 1956;65:85.
29. Bennett RG. *Fundamentals of Cutaneous Surgery*. St. Louis: CV Mosby Company; 1988: 56, 144, 219.
30. Winton GB. Anesthesia for dermatologic surgery. *J Dermatol Surg Oncol*. 1988;14:41.
31. Tromouitch TA, Stegman SJ, Glogau RG, et al. How to make lidocaine injection painless. *The Schoch Letter*. 38:16,1988.
32. Bennett RG. Selection of wound closure materials. *J Amer Acad of Dermatol*. 1988;18:619–637.
33. Clark RF. Cutaneous wound repair: Molecular and cellular controls. *Progress in Derm*. 1988;22:1–12.
34. Carver N, Leighim IM. Keratinocyte grafts and skin equivalents. *Int J Dermatol*. 1991;30:540–551.
35. Nemeth AJ, Eaglestein WH, Taylor JR, et al. Faster healing and less pain in skin biopsy sites treated with an occlusive dressing. *Arch Dermatol*. 1991;127:1679–1683.
36. Brown GL, Curtsinger L, Jurkiewicz MJ, et al. Stimulation of healing of chronic wounds by epidermal growth factor. *Plast Reconstr Surg*. 1991;88:189–196.
37. James WD, Guiry CC. Treatment of wounds received during live fire exercises. *J Assoc Milit Dermatol*. 1984;10:632–634.
38. Notaro WA. Dermabrasion of the management of traumatic tattoos. *J Dermatol Surg Oncol*. 1983;9:916–919.



# Chapter 8

## ARTHROPOD AND OTHER ANIMAL BITES

MARK W. COBB, M.D.\*

---

### INTRODUCTION

### ARTHROPOD BITES: GENERAL CONSIDERATIONS

### CENTIPEDES AND MILLIPEDES

### INSECTS

Caterpillars and Moths

True Bugs

Lice

Mosquitoes and Flies

Beetles

Stinging Insects

Fleas

### ARACHNIDS

Ticks

Scabietic Mites

Nonscabietic Mites

Scorpions

Spiders

### REPTILES

Snakes

Gila Monsters

### CATS AND DOGS

### SUMMARY

\*Commander, Medical Corps, U.S. Navy; Dermatology Branch, National Naval Medical Center, Bethesda, Maryland 20814

## INTRODUCTION

The phylum Arthropoda contains more species than all other phyla combined, comprising literally billions of organisms. Only a small percentage of this myriad of creatures attack humans with any frequency. The consequences of these attacks, however, can be more than trivial, especially in the military setting. Cutaneous wounds inflicted by arthropods, although often insignificant in size, frequently become secondarily infected in the combat environment. In some cases, severe systemic reactions including anaphylaxis may result from the bite or sting. An additional concern, the role of arthropods as vectors of human disease, is discussed in Chapter 9, Arthropod Infestations and Vectors of Disease, and Chapter 11, Rickettsial Diseases.

Four classes of arthropods are of dermatologic interest and are covered in this chapter: Chilopoda, including centipedes; Diplopoda, including millipedes; Insecta, including caterpillars, moths, bedbugs, lice, flies, mosquitoes, beetles, bees, wasps, hornets, fire ants, and fleas; and Arachnida, including ticks, mites, scorpions, and spiders. Bites inflicted by reptiles, specifically snakes and lizards, and by mammals such as cats and dogs are also discussed.

Documents from three of the major military conflicts of this century (World War I, World War II, and Vietnam) underscore the significant role played by arthropods in wartime illness.<sup>1-3</sup> Among troops in France during the later stages of World War I, one army reported that 90% of all sickness was due to scabies, infections of the skin, and fevers of unknown origin. Because most cases of skin infection were associated with scabies, pediculosis, or both, these two infestations accounted for much of the illness of that army. Records from Number 25 General Hospital in Hardelot, France, a central hospital established for the care of skin diseases, showed that scabies was responsible for 65% of all forms of pyoderma. In the forward areas during times of active combat, infestation with *Pediculus humanus* var *corporis* (body louse) was of greater significance than scabies. One British division evacuated 11.5% of its troops to field hospitals for treatment of parasitic disease (primarily pediculosis) during the year 1918. The intimate contact of individuals, their clothing, and equipment, as well as the lack of clean clothing and bed linen during combat situations, promotes the spread of pediculosis and scabies. Of the two, the body louse is more easily transferred

from one individual to another and survives much more readily off humans.

During World War II, the majority of U.S. soldiers with dermatologic complaints were treated at company or camp dispensaries by medical officers with little or no training in dermatology.<sup>2</sup> This situation resulted in the overtreatment of minor dermatologic diseases including scabies and insect bites, frequently resulting in major disabilities. In 1945, a number of stateside hospitals organized to care for troops returning from overseas experienced a marked increase in the incidence of scabies, reflecting the frequency of the infestation in Europe. The dermatology clinic at Camp Lee, Virginia, had more cases of scabies in 1945 than any other skin disease (9.3% of cases).<sup>2</sup> In the European theater, scabies likewise accounted for a disproportionately large percentage of hospital admissions.

During the winter of 1942 to 1943 at the 21st Evacuation Hospital, 10% of all medical admissions were for dermatologic disease and, of these, 30% were scabies.<sup>2</sup> Among six hospitals in the Mediterranean theater surveyed in 1943, parasitic infestation accounted for 4% to 18.5% of the admissions to dermatologic services.<sup>2</sup> Once again, soldiers often presented with pyoderma such as furunculosis, cellulitis, and impetigo due to underlying parasitic infestation, so the actual percentages were much higher. Once the field medical officers were instructed on the diagnosis and treatment of scabies (benzyl benzoate and sulfur ointment were used), disability from the complications of scabietic infestation sharply decreased and hospitalization for this condition became uncommon. Pediculosis, unlike the case in World War I, was seen infrequently in World War II.<sup>1</sup>

During the 8-year span of significant U.S. military involvement in Vietnam (1965–1972), dermatologic disease accounted for 7.4% of all medical hospital admissions.<sup>3</sup> The annual incidence of hospitalization for skin disease was 3- to 5-fold higher than that seen among the active-duty army population in the continental United States over those 8 years. Pyoderma accounted for approximately one third of the cases. Interestingly, scabies and pediculosis were not reported as significant dermatologic diagnoses during the Vietnam conflict, and insect bites represented only about 1% of skin disease seen. One arthropod reaction reported,

however, was blister beetle dermatitis, a blistering eruption resulting from contact with cantharidin, a cutaneous irritant contained in certain beetles. Men

lying on the ground were most susceptible, and the resultant denuded skin was vulnerable to secondary bacterial infection.<sup>1-3</sup>

### ARTHROPOD BITES: GENERAL CONSIDERATIONS

The clinical reaction to an assault on human skin by an arthropod is influenced by a variety of factors.<sup>4</sup> The injury itself can be due to any combination of mechanical trauma, secondary infection, sensitization phenomena, and toxic effects. The nature of the host also plays a crucial role in the expression of clinical disease. Children tend to react more severely to toxins and superficial irritants and more frequently suffer secondary infection. They are more likely to handle and play with arthropods and pets harboring arthropods, and will present with bites on the hands and forearms more commonly than adults. The elderly may react more severely to toxic venoms but are less likely to develop hypersensitivity reactions to bites.

The human skin contains substances that both attract and repel insects. It has been demonstrated<sup>4</sup> that the attractants are found in sweat, while the repellents are concentrated in the epidermal lipids. The individual's immune status is critical in determining the reaction to an arthropod assault. This observation is perhaps most graphically illustrated in the condition known as Norwegian scabies. These patients are debilitated, immunosuppressed, or both, and when infested with *Sarcoptes scabiei*, develop extensive crusted, hyperkeratotic lesions that teem with mites.

In 1946, Mellanby described five stages of immunity to arthropod bites in the normal host<sup>5</sup>:

- First, in a person with no prior exposure to a particular arthropod, no reaction takes place.
- With repeated bites, a sensitivity develops that manifests as a delayed reaction beginning about 24 hours after the bite and subsiding in about a week.
- Weeks, months, or even years later, the bites may be followed by an immediate wheal reaction that clears in a few hours and is succeeded by a delayed papule.
- With further exposure, only the immediate wheal develops after the bite.
- Finally, a stage is reached where once again no reaction develops to the bite.

Antigens found in arthropod saliva are responsible for most of these immediate and delayed hypersensitivity reactions.

Toxic venoms found in salivary and sting secretions provide an important mechanism for cutaneous (and systemic) injury to arthropod bites. These venoms contain a variety of biologically active compounds including proteases, hyaluronidase, phospholipase A, kinins, histamine, 5-hydroxytryptamine, acetylcholine, adrenaline-like substances, neurotoxins, and hemolytic toxins. From this list, one can see that the result of envenomation can range from cutaneous inflammation, pain, and necrosis to severe and potentially life-threatening systemic reactions. Some arthropods secrete irritants onto the surface of the skin from body parts unrelated to feeding. Examples are the vesicants secreted by blister beetles and the urticants found on the hairs of some caterpillars.

The act of biting varies among different arthropods and may produce different clinical responses. Mosquitoes, with their fine proboscises, can penetrate capillaries with minimal damage, while tsetse flies cause significant laceration and bleeding. The mouthparts of ticks tend to break off within the skin and may cause a dense granulomatous or lymphoid dermal reaction that can be quite persistent.

Finally, environmental factors influence the nature of reactions to arthropod bites. The amount of clothing obviously determines the extent of exposed skin susceptible to bites. Some arthropods such as midges, black flies, and mosquitoes limit their attacks to exposed skin; fleas prefer covered areas. Body lice live in clothing and, therefore, their bites are found on covered skin as well. Pets and livestock can be a source of parasites, so grooming and disinfestation become important measures. Overcrowded living conditions, poor sanitation, and inadequate garbage disposal all facilitate the breeding of potentially harmful arthropods. Spiders and scorpions live in wood and litter piles as well as outhouses. Dark crevices in homes may also provide a breeding ground. In the construction of temporary military housing, infestation can be greatly reduced by such simple measures as providing mesh netting for doors and windows; elevating the floor from the ground; and separating livestock, wood piles, and latrine and garbage sites from living quarters.

## CENTIPEDES AND MILLIPEDES

American centipedes have a slender, segmented body that ranges in color from yellow to green to brown or black, and may vary in length from 1 to 30 cm (Figure 8-1).<sup>6</sup> While the *Scutigera* species found in the eastern United States does not sting humans, the *Scolopendra* species of the western United States and Hawaii can inflict a painful sting.<sup>7</sup> Centipedes are nocturnal carnivores and prefer a dark, moist environment like that found under rocks and logs. Envenomation occurs by means of two hollow fangs, each connected to a venom gland. The immediate reaction consists of local burning pain and a pair of hemorrhagic puncta surrounded by erythema and edema at the sting site. Occasionally, local necrosis, regional lymphangitis and lymphadenopathy, anxiety, irregular peripheral pulses, headache, and dizziness may develop. Therapy for a centipede sting should include cleansing the wound, injecting a local anesthetic into the wound, tetanus prophylaxis, and administering systemic antihistamines.

Millipedes are multisegmented, with a hard, often brightly colored exoskeleton. Some tropical species may reach 30 cm in length. They are nocturnal vegetarians and, like centipedes, prefer dark, moist environments. When disturbed, millipedes will coil into a tight spiral and can then secrete a toxic liquid from repugnatorial glands located on the sides of each segment. This liquid causes an immediate burning sensation when it contacts human skin. The skin then becomes yellow-brown, and in 24 hours develops intense erythema and often vesiculation. Erosions may develop but usually heal without scar formation unless secondarily infected. Dyspigmentation, however, is a common

### OK to put on the Web

**Fig. 8-1.** The centipede has a multisegmented body, with a pair of legs on each segment. Its color ranges from yellow to green or brown to black. It may grow to 30 cm in length. Photograph: Courtesy of Entomology Department, Walter Reed Army Institute of Research, Washington, D.C.

sequelae in dark-skinned patients. If the toxic liquid should come in contact with an eye, the result is instantaneous and severe pain lasting 2 to 3 days. A chemical conjunctivitis ensues and corneal ulceration may develop. Skin contact with the toxin should be treated immediately with copious lavage of the area. Alcohol is a good solvent for the contaminating liquid, but water may be used. Management of the blisters and erosions with a topical antibiotic is similar to that of a superficial second-degree burn. Topical corticosteroids may be helpful.

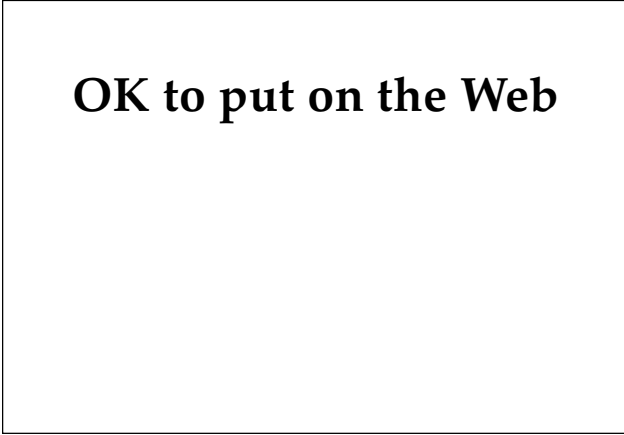## INSECTS

The class Insecta comprises arthropods whose adult forms have three pairs of legs. Injury to humans can be inflicted by bites, stings, and contact with noxious hairs, venom, or excretions.

### Caterpillars and Moths

Among the order of insects known as Lepidoptera, comprising butterflies and moths, contact with the poison hairs or spines of the larval form (caterpillars) or the poison hairs of the adult (moths) causes cutaneous disease.<sup>8,9</sup> In the United States, the venomous caterpillars (Figure 8-2) most frequently en-

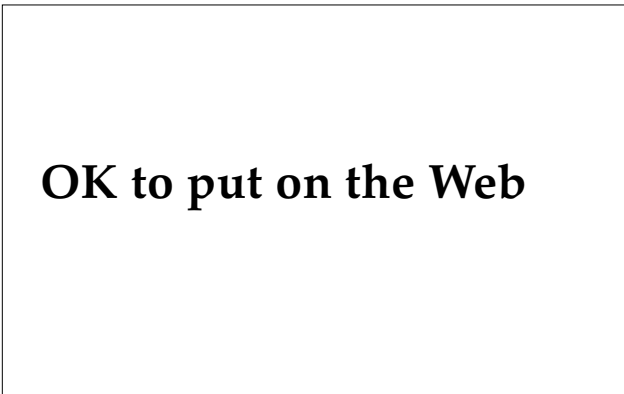
countered are the brown-tail moth caterpillar, puss caterpillar, saddleback caterpillar, crinkled flannel moth caterpillar, slug caterpillar, and flannel moth caterpillar. They are present most often in the autumn and are usually found in trees. Their poison hairs may come in contact with the skin and mucous membranes directly by handling the caterpillars; however, the contact is usually indirect, involving hairs falling from trees, free wind-borne hairs, or objects that have been contaminated by hairs. Cocoons and egg cases can also contain the hairs. Venomous moths causing dermatitis in the United States include the brown-tail, gypsy, puss,



**Fig. 8-2.** Caterpillars, the larval form of moths and butterflies, may have venomous spines and hairs as shown here. Photograph: Courtesy of Entomology Department, Walter Reed Army Institute of Research, Washington, D.C.

io, and tussock moths. In Latin America, a genus of moth known as *Hylesia* is a frequent cause of moth dermatitis (Figures 8-3 and 8-4). Epidemics have resulted from the dust produced by massive numbers of this particular moth.

The cutaneous reaction to contact with poison moth hairs can range from an immediate pruritic or burning sensation to a delayed painful eruption developing 2 to 12 hours later and persisting for up to 2 weeks. The skin lesions are most commonly found on exposed areas of the upper extremities and neck, less frequently on the face, and consist of erythematous wheals, papules, vesicles, or pus-



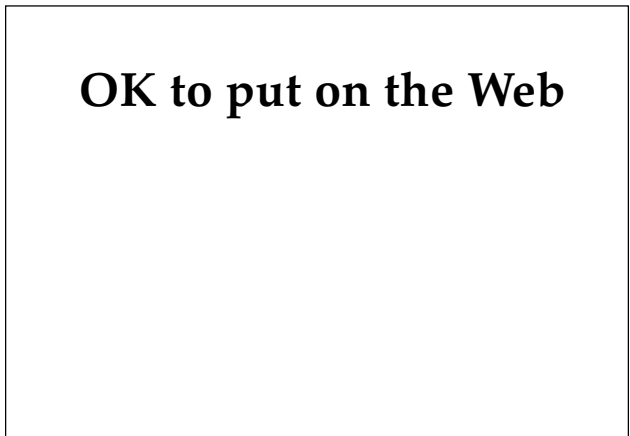
**Fig. 8-3.** This moth belongs to the genus *Hylesia*, a common cause of moth dermatitis in Latin America. Photograph: Courtesy of Entomology Department, Walter Reed Army Institute of Research, Washington, D.C.

tules. Conjunctivitis can result from contact with the eye. Contaminated clothing may cause widespread lesions associated with systemic symptoms including rhinitis, nausea, vomiting, and low-grade fever. The puss caterpillar can cause a painful hemorrhagic lesion with marked edema and regional lymphangitis and lymphadenopathy. In rare instances, hypotensive shock can develop.

Immediate treatment for contact with poison moth hair consists of stripping the skin with adhesive tape to remove the poison hairs. Cool compresses and oral antihistamines can be tried, and systemic corticosteroids may be useful in more serious cases. Oral analgesics are at times required for the pain.

### True Bugs

The order Hemiptera contains the true bugs, two of which commonly bite humans: the bedbug and the kissing bug. The bedbug, *Cimex lectularius*, is a worldwide parasite that feeds nocturnally on human blood.<sup>10</sup> It is a flat, oval, reddish brown insect that varies in length from 3 to 6 mm (Figure 8-5). A pair of mandibular stylets are used to pierce the skin, and a salivary anticoagulant is injected into the wound prior to the blood meal. The bedbug lives within crevices found in walls, floors, and furniture and can be detected by a characteristic pungent odor. The adult can survive more than a year without feeding and travels well in baggage. The initial bite is painless and the first manifestation may be the discovery of blood-stained bed



**Fig. 8-4.** An example of the dermatitis produced by contact with the hair of the *Hylesia* moth. Photograph: Courtesy of Entomology Department, Walter Reed Army Institute of Research, Washington, D.C.

## OK to put on the Web

**Fig. 8-5.** The bedbug, *Cimex lectularius*, is reddish brown and ranges in length from 3 to 6 mm. Photograph: Courtesy of Entomology Department, Walter Reed Army Institute of Research, Washington, D.C.

clothes and linen. Salivary antigens can elicit a hypersensitivity reaction producing urticarial papules with central hemorrhagic puncta. Lesions may be bullous and can become secondarily infected. Systemic hypersensitivity reactions including generalized urticaria, asthma, arthralgia, and even anaphylaxis have been reported. Of particular concern have been laboratory studies<sup>10</sup> showing that transmission of hepatitis B, *Rickettsia*, and *Leishmania* by these bugs is possible. Treatment of the bites includes topical antipruritic lotions, topical corticosteroids, systemic antihistamines, and antibiotic coverage if secondarily infected. Insecticides such as pyrethrins or malathion should be used to treat bedbugs' dwellings.

Kissing bugs comprise 14 genera of the Reduviidae insect family, several species of which are found in the western and southeastern United States.<sup>11</sup> These bugs are 1.5 to 2.5 cm long and brownish black with red or yellow stripes on the abdomen (Figure 8-6). They are nocturnal predators, falling on their prey from trees or the ceiling and feeding on exposed skin. In humans, the bite is often on the face, hence the name "kissing bug." The bites are usually painless and appear as grouped papules with hemorrhagic puncta or vesiculobullous lesions. A localized or generalized urticarial reaction may occur, probably secondary to salivary antigens. A variety of systemic effects including laryngeal edema, bronchospasm, angioedema, hypotension, syncope, generalized pruritus, vomiting, uterine bleeding, headache, and abdominal cramps have been reported.<sup>11</sup> In Latin America, this bug is a vector of *Trypanosoma cruzi*, the etiologic

agent of Chagas' disease (discussed in Chapter 12, Tropical Parasitic Infections). Treatment of the bite includes topical corticosteroids, systemic antihistamines, and antibiotics if secondarily infected.

### Lice

Three varieties of lice, *Pediculus humanus var capitis* (head louse), *Pediculus humanus var corporis* (body louse), and *Phthirus pubis* (pubic or crab louse), are obligate parasites of humans.<sup>4</sup> After attaching to human skin, they feed on blood that they suck.<sup>7</sup> These flattened, wingless insects have a tough integument that varies in color from gray to black. The body and head lice vary in length from 2.4 to 3.6 mm (Figures 8-7 and 8-8), while the shorter and wider pubic louse is about 2 mm long (Figure 8-9). The pubic louse is also distinguished by prominent claws on its second and third pair of legs.<sup>12</sup> Lice will die of starvation if kept off the body for more than 10 days. They are also killed by washing in water at 53.5°C for 5 minutes. The life span of a louse is about 30 to 45 days.

### Head Lice

Head lice primarily infest children, although adults certainly may be affected. Women are more commonly infested than men. The distribution of the disease is worldwide and tends to be much more

## OK to put on the Web

**Fig. 8-6.** Pictured here are various stages in the development of the kissing bug. The adult grows to 1.5 to 2.5 cm in length and is brownish black with red or yellow stripes in the abdomen. Photograph: Courtesy of Entomology Department, Walter Reed Army Institute of Research, Washington, D.C.

**OK to put on the Web**

**Fig. 8-7.** The body louse is a wingless, gray to black insect whose length ranges from 2.4 to 3.6 mm. Photograph: Courtesy of Entomology Department, Walter Reed Army Institute of Research, Washington, D.C.

**OK to put on the Web**

**Fig. 8-9.** The pubic louse is shorter (about 2 mm long) and wider than body or head lice. It has prominent claws on the second and third pairs of legs to grasp hair. Photograph: Courtesy of Entomology Department, Walter Reed Army Institute of Research, Washington, D.C.

prevalent in crowded urban centers. Once on the scalp, the female louse will lay her eggs (nits) at the base of the hair. The nits are cemented to the side of the hair shaft and move distally with hair growth (Figure 8-10). Often these nits are the only clinical evidence of infestation, as the lice are difficult to find. The nits are usually found in the warm areas

of the scalp such as behind the ears and on the posterior neck. Patients generally note an itching or pricking sensation and the hair may appear lusterless and dry. The scalp can become secondarily infected from scratching, presenting as an impetigo or folliculitis. Adequate treatment requires that both the adult lice and the nits be killed. Because

**OK to put on the Web**

**Fig. 8-8.** The head louse is similar in size and shape to the body louse. Its clawlike legs allow it to grasp the hair of its host. Photograph: Courtesy of Entomology Department, Walter Reed Army Institute of Research, Washington, D.C.

**OK to put on the Web**

**Fig. 8-10.** The oval eggs (nits) of a head louse are cemented onto hair shafts and move distally with hair growth. Photograph: Courtesy of Entomology Department, Walter Reed Army Institute of Research, Washington, D.C.

the nits hatch in 7 days, two treatments a week apart are recommended to ensure complete eradication of the lice. Although lindane (gamma benzene hexachloride, or Kwell [manufactured by Reed & Carnrick, Jersey City, N.J.]) shampoo or lotion is most frequently used, a recent study found malathion lotion to be significantly more effective in killing both adult lice and nits.<sup>13</sup> Natural pyrethrin products (A-200 [manufactured by SmithKline Beecham, Pittsburgh, Pa.], RID [manufactured by Pfizer, Parsippany, N.J.]), and synthetic permethrin (Nix, manufactured by Burroughs Wellcome, Research Triangle Park, N.C.) are also effective. The nits are best removed with a comb after soaking the hair in a vinegar solution. Family members and other personal contacts should also be treated.

### Body Lice

Unlike head lice, body lice live and lay eggs in the seams of clothing and contact human skin only to feed. They generally infest individuals with poor hygiene, producing what has been named vagabond's disease. This louse can be a vector for epidemic typhus, louse-borne relapsing fever, and trench fever. Patients present with pyoderma involving areas covered by clothing, most notably the trunk, axillae, and groin. Erythematous macules, papules, and wheals, as well as excoriations may also be seen. The most significant symptom is severe pruritus. In endemic cases, pediculocides are unnecessary and adequate treatment consists of a hot shower and clean clothes. A hot wash will kill the organisms on infested clothing. Antibiotics are necessary if secondary infection is present. For epidemics of body lice, as may be seen in wartime situations, heavy infestation requires the use of insecticides such as dichlorodiphenyltrichloroethane (DDT) powder, lindane 1% powder, or malathion 1% powder. Resistant organisms have emerged from all of these regimens, however.


### Pubic Lice

Pubic lice limit their infestation to areas where the hair is short and are found primarily in the pubic hair. They may, however, spread to body hair, axillary hair, beard hair, eyebrows, eyelashes, and occipital scalp hair. Pediculosis pubis is spread most commonly by sexual contact and should prompt a search for other sexually transmitted diseases. Patients can remain asymptomatic for up to a month before pruritus develops. Nits, similar to those in pediculosis capitis, are seen. The lice are

found wrapped around a single hair in the case of larvae; adults grasp two adjacent hairs. Blue macules (maculae ceruleae) are often seen on the surrounding skin and are believed to be produced by louse saliva acting on blood products. Pubic lice should be treated with lotions or shampoos containing 1% lindane, 0.3% pyrethrins, or 5% permethrin. These drugs should be applied topically, left on for 10 minutes, then reapplied once 7 to 10 days later. Infestation of the eyelashes has been treated in the past with physostigmine ointment or yellow ointment of mercury; however, plain petrolatum, applied two to five times daily for several days, appears to work as well and is much safer. Clothing should be washed in hot water.

### Mosquitoes and Flies

Mosquitoes and flies are two-winged, biting insects belonging to the order Diptera.<sup>7</sup> They all require a blood meal at some time in their development. To acquire this meal, they often attack human skin, causing a bite reaction.<sup>14</sup> These bites can manifest as immediate urticarial papules, delayed erythematous papules, or both, depending on the host's state of immunity, as discussed previously. Fly larvae (maggots) may also invade tissue, producing a condition known as myiasis. If the eggs are deposited on an open wound, the larvae cause wound myiasis; eggs deposited beneath the skin via a puncture cause furuncular myiasis.



OK to put on the Web

**Fig. 8-11.** Mosquitoes are characterized by their delicate wings, long, thin legs, and long feeding proboscises. The *Anopheles* mosquito is shown here. Photograph: Courtesy of Entomology Department, Walter Reed Army Institute of Research, Washington, D.C.



**TABLE 8-1**  
**MOSQUITOES AND FLIES AS VECTORS OF INFECTIOUS DISEASE**

Table 8-1 is not shown because the copyright permission granted to the Borden Institute, TMM, does not allow the Borden Institute to grant permission to other users and/or does not include usage in electronic media. The current user must apply to the publisher named in the figure legend for permission to use this illustration in any type of publication media.

Adapted with permission from Alexander JO. *Arthropods and Human Skin*. Berlin, Germany: Springer-Verlag; 1984: 117.

### *Mosquitoes*

Mosquitoes, belonging to the family Culicidae, are delicate winged insects with long proboscises and long, thin legs (Figure 8-11). They require water to mature through the larval and pupal stages, explaining the presence of mosquitoes near standing water. A number of factors attract mosquitoes to humans including moisture, warmth, carbon dioxide, estrogens, and L-lysine in sweat.<sup>15</sup> Mosquitoes can be the vector for filariasis, yellow fever, dengue fever, and malaria, among other diseases (Table 8-1). Cutaneous reactions to mosquito bites include urticarial wheals, delayed papules, bullous lesions, hemorrhagic necrotic lesions, excoriations, eczematous patches, and granulomatous nodules.<sup>16</sup> Mosquito bites can be treated with topical corticosteroid creams, antipruritic lotions, and/or a dilute solution of meat tenderizer (containing the enzyme papain, which provides rapid relief of pruritus). Bites can be prevented by repellents that contain diethyltoluamide (DEET, marketed as Off!, Sportsmate II cream, or Cutter Laboratories' Insect Repellent) or ethyl hexanediol (6-12 Plus). Interestingly, Avon's Skin-So-Soft moisturizer acts as an excellent repellent. Protective clothing and mosquito netting are both effective for the outdoor setting.

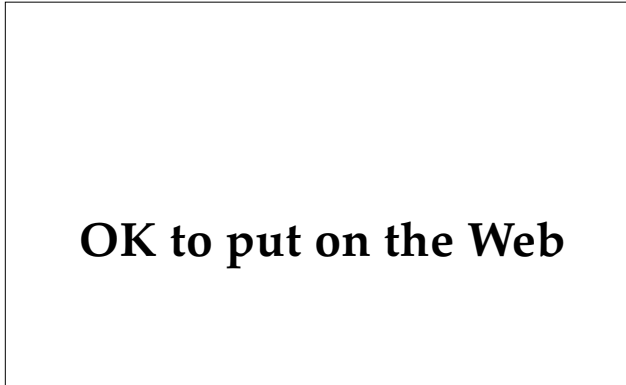### *Flies and Maggots*

A variety of flies commonly bite humans, including sandflies (*Phlebotomus* and *Lutzomyia* species),

black or buffalo flies (*Simulium* species), Ceratopogonidae (biting midges), members of the family Tabanidae (which includes the deerfly and horsefly), and tsetse flies (Figure 8-12). The common housefly does not bite, but rather feeds on the surface of the skin (Figure 8-13). A number of infectious diseases can be transmitted by biting flies (see Table 8-1). The cutaneous reaction to these bites, like those of mosquitoes, may be immediate, delayed, or both. Relief is provided by antipruritic lotions and topical corticosteroids. Repellents applied topically or impregnated in clothing can pre-

**OK to put on the Web**

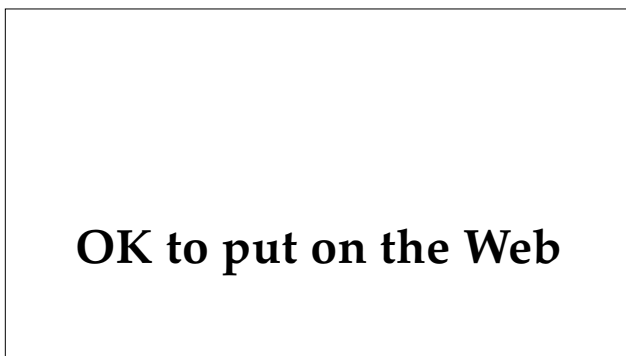
**Fig. 8-12.** The sandfly is a vector of leishmaniasis and bartonellosis. Photograph: Courtesy of Entomology Department, Walter Reed Army Institute of Research, Washington, D.C.



**Fig. 8-13.** The housefly feeds on the surface of the skin rather than biting. Photograph: Courtesy of Entomology Department, Walter Reed Army Institute of Research, Washington, D.C.

vent fly bites. DEET, ethyl hexanediol, chlorodiethyl benzamide, and Avon's Skin-So-Soft are all good topical repellents. An effective combination repellent is topical DEET and permethrin-impregnated clothing.

Myiasis, or infestation with fly maggots, has an almost worldwide prevalence, although it is more common in the tropics. The disorder is caused by many different species of fly and affects any exposed surface. Cerebral, facial, nasal, aural, oral, ophthalmological, urethral, rectal, and vaginal disease have all been reported.<sup>14</sup> In North America, wound myiasis is probably the most common form. Flies first lay their eggs on the injured surface where the soft larvae or maggots hatch. Some species ingest only necrotic material; others may attack adjacent normal tissue. A

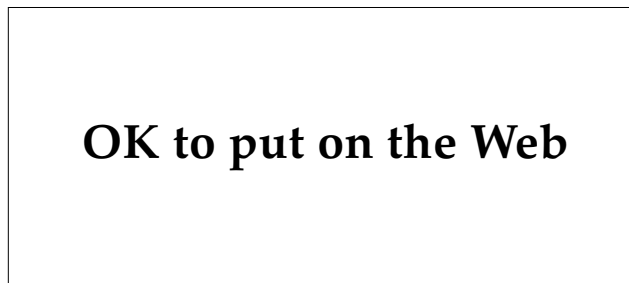


**Fig. 8-14.** The human botfly is the most common cause of furuncular myiasis in Latin America. Photograph: Courtesy of Entomology Department, Walter Reed Army Institute of Research, Washington, D.C.

variety called screwworms can burrow deeply into living tissue, causing extensive damage. In the past, larvae of the black blowfly were commercially available for wound debridement. Wound myiasis is treated by extraction of the maggots after prior application of 10% chloroform in vegetable oil or ether to the wound. For deep or extensive infestation, repeated chloroform irrigation may be required.<sup>4</sup>

Furuncular myiasis is produced when (a) adult flies puncture the skin to lay their eggs, (b) flies lay their eggs on the skin surface and hatched larvae burrow into the skin and subcutaneous tissue, or (c) fly eggs, which have been attached to the body of a mosquito, tick, or stable fly, are deposited on human skin and enter via the bite wound of these vectors. The human botfly, *Dermatobia hominis*, is the most common cause of furuncular myiasis in Central and South America (Figures 8-14 and 8-15). Infants and young children are the most frequently affected, although patients of all ages are seen.<sup>17</sup>

Clinically, a raised, erythematous papule develops at the site of the bite, most frequently on the distal extremity or scalp. Over the next 3 weeks it gradually enlarges to become an indurated nodule with a central punctum, which is the breathing tube for the larva (Figure 8-16). Serum and pus may be discharged from this highly pruritic and intermittently painful lesion. Regional lymphadenopathy, as well as a papulovesicular hypersensitivity eruption on the surrounding skin and hands, may be seen. In about 7 weeks, the larva will mature and emerge from the nodule, although patients usually seek treatment much earlier because of pain (Figure 8-17). Effective therapy requires surgical incision



**Fig. 8-15.** The larval form of the botfly burrows into the skin and subcutaneous tissue, producing a furuncular lesion (ruler in cm). Photograph: Courtesy of Entomology Department, Walter Reed Army Institute of Research, Washington, D.C.

## OK to put on the Web

**Fig. 8-16.** The furuncular lesion of myiasis is an indurated nodule with a central punctum, which serves as the breathing tube for the larva. Photograph: Courtesy of Entomology Department, Walter Reed Army Institute of Research, Washington, D.C.

of the nodule and extraction of the larva, after anesthetizing the lesion and larva with lidocaine or chloroform. Natives in endemic areas cover the lesions with a thick layer of pork fat, occluding the breathing tube. Within 24 hours, the larva migrates out and can easily be removed.

### Beetles

Blister beetles cause cutaneous injury when a potent vesicating agent, cantharidin, is released from their bodies and contacts human skin. When handled, these insects excrete the vesicant in hemolymph from their knee joints, prothorax, and genitalia.<sup>4</sup> *Lytta vesicatoria*, also known as “Spanish fly,” is the source of cantharidin, which is used medicinally for the treatment of warts. Two species, *Epicauta vittata* and *E pennsylvanica*, are found in the southern and southwestern United States.<sup>18</sup> They can be up to 1 in. long and are found in alfalfa fields, along fence rails, and in flower beds. Several minutes after contact with the vesicant, the patient experiences a tingling or burning. Blisters develop within a day, then dry up and desquamate in about a week (Figure 8-18). Extensive contact with cantharidin can cause toxic symptoms including stomatitis, salivation, hematemesis, abdominal pain, diarrhea, and dysuria. The affected skin should be washed immediately with alcohol, acetone, ether, or soap to dissolve or dilute the cantharidin. The blisters are treated with wet compresses and topical corticosteroids.

## OK to put on the Web

**Fig. 8-17.** A larva is shown emerging from a furuncular lesion. Patients are often unable to wait for this to occur because of the pain of the lesion. Photograph: Courtesy of Entomology Department, Walter Reed Army Institute of Research, Washington, D.C.

## OK to put on the Web

**Fig. 8-18.** Resolving lesions induced by the blister beetle desquamate in about 1 week. Photograph: Courtesy of Entomology Department, Walter Reed Army Institute of Research, Washington, D.C.

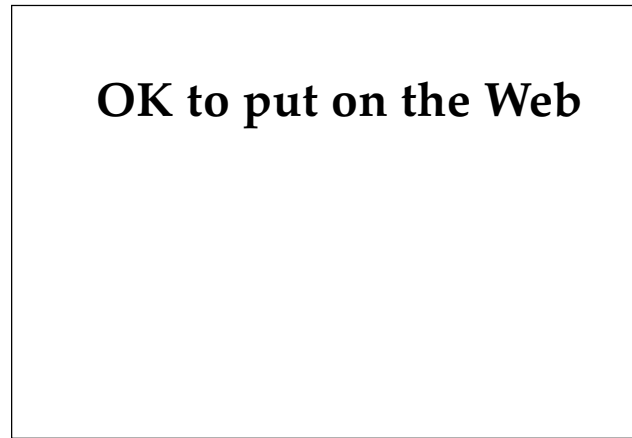
### Stinging Insects

Insects of the order Hymenoptera, including bees, wasps, hornets, and fire ants, are known for producing a painful sting that may, rarely, result in anaphylaxis and death.<sup>19</sup> The venoms of these insects have not been completely characterized, but contain biogenic amines (histamine, nor-epinephrine, dopamine, serotonin, and acetylcholine), enzymes (phospholipase A and B, hyaluronidase, esterases, and phosphatases), and other peptides (kinins and mast cell degranulation peptide).<sup>20</sup>

The reactions produced by Hymenoptera stings are classified as (a) local, (b) systemic toxic, (c) systemic allergic, and (d) other (Table 8-2). The common local reaction is erythema, edema, and pain at the site of the sting, resolving in several hours. The swelling can occasionally extend to involve a large area (eg, an entire limb) and last for several days. Wells' syndrome, consisting of erythematous, edematous plaques composed histologically of eosinophilic granulomatous dermatitis, may be related to stings.<sup>4,21</sup> Systemic toxic reactions are produced by the pharmacological action of a large dose of venom from multiple stings. Constitutional symptoms such as nausea, malaise, fever, and even anaphylactoid reactions may result. Systemic allergic reactions are produced when specific immunoglobulin (Ig) E antibodies fixed to the surface of basophils and mast cells bind to antigens in the venom, causing degranulation and the release of vasoactive

**TABLE 8-2**  
**REACTIONS TO HYMENOPTERA STINGS**

Type of Reaction	Effects
Local	Immediate erythema and edema, extensive swelling (may include entire extremity), eosinophilic cellulitis (Wells' syndrome)
Systemic toxic	Nausea and vomiting, malaise, fever, anaphylactoid reaction
Systemic allergic	Urticaria or angioedema, or both; nausea, vomiting, dizziness, and wheezing; anaphylaxis (hypotension, laryngeal edema, and bronchospasm)
Other	Serum sickness, acute renal failure, possible Guillain-Barré syndrome



**Fig. 8-19.** Honeybees are found around flowering plants and are unique among stinging insects, having a barbed stinger that causes it and venom sac to be left on the victim. The bee is eviscerated and dies after stinging. Photograph: Courtesy of Entomology Department, Walter Reed Army Institute of Research, Washington, D.C.

substances. Symptoms range from urticaria and angioedema, which may be associated with nausea, vomiting, dizziness, and wheezing, to a fully developed anaphylactic reaction including hypotension, laryngeal edema, and bronchospasm. Every year, insect allergy accounts for approximately 40 fatalities in the United States.<sup>21</sup> Severe allergic reactions are more common in men, especially when stung on the head and neck. Finally, there have been case reports<sup>21</sup> in which serum sickness, acute glomerulonephritis, and Guillain-Barré syndrome have been associated with Hymenoptera stings.

#### *Bees, Wasps, and Hornets*

The Apoidea family includes honeybees and bumblebees (Figure 8-19). Honeybees feed on flowering plants and can be encountered in the wild, such as on clover, or in commercial hives. They are unique among the stinging insects in that their stinger contains a barb, causing it to be left on the victim along with the venom sac. This act eviscerates and kills the bee and also allows the sting to be identified as that of a honeybee, for the venom sac is visible. In 1957, swarms of African bees escaped from a laboratory in Brazil, where they were being used in cross-breeding experiments attempting to improve honey production. These African or "killer" bees are known for their aggressive stinging behavior in defense of their colonies. Their steady march northward through Central America and Mexico has been well documented in the press.

Wasps, yellow jackets, and hornets are members of the Vespidae family. Paper wasps build hives under the eaves of buildings; yellow jackets are ground-nesting, and hornets reside in shrubs and trees. These insects are often found around trash containers or discarded food. They may sting multiple times, although usually only when provoked.

After a honeybee sting, care must be taken in removing the stinger and attached venom sac, for pressure will release more venom. Lateral scraping with a knife blade is recommended. The local reactions produced by Hymenoptera stings can be treated with ice packs, elevation, topical corticosteroids, systemic antihistamines, and, if necessary, analgesics. Application of a dilute solution of meat tenderizer will provide rapid pain relief. Systemic corticosteroids are helpful in the more extensive local reactions. Anaphylaxis is a medical emergency requiring airway protection and the maintenance of systemic blood pressure with parenteral epinephrine, intravenous fluids, and, in some cases, vasopressor agents. Individuals who have experienced an anaphylactic reaction should carry a bee-sting kit, such as Ana-Kit or Epi-Pen, which includes epinephrine and antihistamines. MedicAlert jewelry should also be worn. Individuals with Hymenoptera allergy, documented by history and skin testing, are candidates for hyposensitization therapy. This treatment involves venom immunotherapy, which generally provides partial protection. Outdoor dining and the wearing of brightly colored clothing should be avoided by these individuals.

### Fire Ants

Fire ants, included in the Formicidae family, are unique among the Hymenoptera in several ways. Their venom is composed primarily of nonimmunogenic, low-molecular-weight alkaloids with only a small percentage of the immunogenic proteins found in the venom of bees, wasps, and hornets. They sting by first biting the victim with their powerful set of pincer jaws, then swiveling about their attached head and stinging in a circular pattern. Fire ants may be red or black and live in ground colonies in the southeastern United States. They are aggressive and tend to attack in swarms, with up to 5,000 bites in a single attack being reported.<sup>22</sup> These painful stings are very distinctive clinically: two central hemorrhagic puncta are surrounded by a ring of erythematous papules that first become vesicles, then sterile pustules. Associated seizures and mononeuropathy have been reported.<sup>7</sup> Ana-

phylaxis may occur, but is less likely than with other Hymenoptera. Local therapy, including meat tenderizer,<sup>22</sup> is generally ineffective for these painful stings, and a specific antivenin is not available.

### Fleas

Fleas are wingless insects that, in pursuit of their blood meals, can infest most warm-blooded animals.<sup>7</sup> Humans may be bitten by the human flea (*Pulex irritans*) as well as by the cat, dog, rat, squirrel, mouse, chicken, and sand fleas. Among the various species are found the vectors for bubonic plague, endemic typhus, tularemia, and intestinal tapeworm.<sup>4</sup> Their distribution is cosmopolitan, favoring overcrowded environments. Although wingless, fleas are equipped with powerful legs that allow them to jump from host to host (Figure 8-20). Their bites are probably the most common skin lesions inflicted by arthropods (Figure 8-21).

Fleas often bite at the ankle, wrist, or waistline, where they encounter the edge of clothing. The bites are frequently grouped in twos and threes with a somewhat irregular distribution. The individual lesions are papules, vesicles, or bullae, often with a central hemorrhagic punctum and an erythematous halo. Due to their pruritic nature, they commonly become excoriated and secondarily impetiginized. Chronic reinfestation in a hypersensitive host can produce a variety of hivelike and

## OK to put on the Web

**Fig. 8-20.** Fleas are wingless insects with powerful legs allowing them to jump from host to host. Photograph: Courtesy of Entomology Department, Walter Reed Army Institute of Research, Washington, D.C.

## OK to put on the Web

**Fig. 8-21.** Flea bites are often encountered in areas at the edge of clothing, such as the ankle, wrist, and waistline. The lesions usually have a hemorrhagic central punctum and erythematous halo. Photograph: Courtesy of Entomology Department, Walter Reed Army Institute of Research, Washington, D.C.

persistent papules known as papular urticaria. Antipruritic lotions and topical corticosteroid creams will provide symptomatic relief for the cuta-

neous lesions. Antibiotics may be required for treatment of secondary infection. Topical repellents effective for fleas include DEET and pyrethrins, and clothes impregnated with benzyl benzoate. Household pets should be treated with a pesticide such as pyrethrin powder. Carpets, floors, furniture, and draperies need to be treated with a pesticide as well. Pyrethrins, malathion, and carbaryl are all effective and should be used monthly for two or three applications.

The sand flea (*Tunga penetrans*) produces a unique clinical lesion in humans. It is found in Central and South America, equatorial Africa, and the southern United States. The gravid female burrows into the skin and enlarges to the size of a pea. If allowed to remain in the skin, she extrudes her eggs through a surface opening after 1 to 2 weeks, then dies. The site of invasion is usually the feet, particularly around the toes, but can also be the thighs, perineum, and genitalia. The cutaneous lesion is a 1- to 2-cm, firm, tender nodule with a black spot in the center. Secondary infection and regional adenopathy may occur. Treatment of sand flea infestation (tungiasis) consists of excision or curettage of the flea, tetanus prophylaxis, and, if infection is present, antibiotic coverage.

## ARACHNIDS

The class Arachnida is composed of arthropods whose adult forms have four pairs of legs. They may cause human injury by biting, burrowing in and feeding on skin, stinging, and delivering toxic venom.

### Ticks

There are two families of ticks: the hard ticks (Ixodidae), with a hard chitinous dorsal shield, and the soft ticks (Argasidae), which lack this dorsal shield (Figures 8-22 and 8-23). Hard ticks can endure cold, humid weather, while soft ticks prefer drier environments.<sup>23</sup> Both types are frequently found in shrubby or wooded areas. Ticks are natural parasites of many different animals including mammals, birds, reptiles, and amphibians. Varieties from both tick families will occasionally attack humans. Once attached to human skin, they can remain feeding for several days until becoming so engorged with blood that they drop off. Although the cutaneous reaction from a tick bite may be quite symptomatic, ticks are most notorious as vectors for numerous infectious dis-

## OK to put on the Web

**Fig. 8-22.** A soft tick (*Dermacentor* sp). Photograph: Courtesy of Entomology Department, Walter Reed Army Institute of Research, Washington, D.C.

eases (Exhibit 8-1). The six-legged larvae, the eight-legged nymphs, and adult ticks can all transmit disease.

## OK to put on the Web

**Fig. 8-23.** Two hard ticks (*Ixodes scapularis*), the one on the right engorged with a blood meal. *I. scapularis* is the vector for Lyme disease. Photograph: Courtesy of Entomology Department, Walter Reed Army Institute of Research, Washington, D.C.

In addition to these infectious diseases, ticks may cause two syndromes, tick-bite alopecia and tick paralysis, both presumably due to secreted toxins.<sup>4</sup> The former is a patchy alopecia at the site of tick attachment that clinically resembles alopecia areata. The hair loss begins about 1 week after the tick is removed and may take up to 2 months to completely regrow. Tick paralysis is an ascending flaccid paralysis resembling Guillain-Barré syndrome. The onset is heralded by leg weakness and can progress to complete flaccid paralysis, resulting in dysarthria, dysphagia, respiratory failure, and death. The paralytic symptoms usually disappear rapidly if the tick is found and removed from the skin. Residual neurological sequelae after removal of the tick are very rare. These two syndromes are also discussed in Chapter 9, Arthropod Infestations and Vectors of Disease.

The initial bite of the tick is usually painless but becomes a pruritic, urticarial lesion in a few hours. If undetected, the tick can remain attached to the skin for over 1 week, becoming completely engorged with blood. While it feeds, the host may develop fever, chills, headache, abdominal pain, and vomiting (tick-bite pyrexia).<sup>7</sup> These symptoms resolve a day or two after the tick is removed. The cutaneous lesion is generally an erythematous papule with a red halo, but may become bullous or ulcerated. Firm, pruritic nodules lasting for months to years have been observed after tick bites. When examined histologically, these nodules can show worrisome features suggestive of cutaneous

lymphoma. Patients may also develop persistent gyrate (annular and polycyclic) erythemas after a tick bite.

Initial treatment consists of finding and removing the tick. This should be done with steady, gentle traction so as not to leave any broken-off tick parts in the skin. As with other arthropod bites, the pruritic skin lesion is treated with topical corticosteroids, antipruritic lotions, and systemic antihistamines. Persistent nodular lesions often require intralesional corticosteroid injection or even surgical excision. Protective clothing as well as an insect repellent such as DEET should be used when exposure to ticks is anticipated. The history of a tick bite should heighten the clinician's awareness for early signs and symptoms of associated infectious diseases, allowing for prompt treatment.

### EXHIBIT 8-1

#### INFECTIOUS DISEASES WITH TICKS AS VECTORS

Exhibit 8-1 is not shown because the copyright permission granted to the Borden Institute, TMM, does not allow the Borden Institute to grant permission to other users and/or does not include usage in electronic media. The current user must apply to the publisher named in the figure legend for permission to use this illustration in any type of publication media.

Adapted with permission from Alexander JO. *Arthropods and Human Skin*. Berlin, Germany: Springer-Verlag; 1984: 364.

## Scabietic Mites

Scabies is an infestation with the eight-legged human mite known as *Sarcoptes scabiei*. The adult scabietic mite is approximately 0.4 mm in length, barely visible to the naked eye as a black speck. Adult mites copulate on the skin, after which the female will burrow, laying her eggs along the way.<sup>24</sup> Six-legged larvae hatch and pass through several nymphal stages before becoming adults. This life cycle takes 10 to 14 days. Scabietic mites generally will survive off the human body for only 2 to 3 days under normal room conditions. Initial infestation is completely asymptomatic, and it is not until about 30 days later that an immune response develops to the mites or their excrement (scybala). At this point, pruritus and cutaneous inflammation appear. Although widespread skin lesions may be present with this infestation, it has been demonstrated that the average number of mites per patient is 11.<sup>25</sup> Mites are found most frequently on the hands, wrists, elbows, axillae, breasts, umbilicus, and genitalia. Scabies is usually spread by close personal contact with an infested individual. Although sexual intercourse is probably the most frequent mode of transmission among single adults, embracing, sharing a bed, or even shaking hands may also transmit the disease. Fomites (eg, clothing) can also play a role in the spread of scabies.

Two types of cutaneous lesions are seen with scabies: intact or excoriated burrows, which are produced by the adult female mite, and erythematous papules, which are believed to represent the host's immune response to the parasite. The burrows are slightly elevated, linear lesions that are best observed with a hand lens. At one end of the burrow, a black speck, vesicle, or pustule is sometimes observed, indicating the location of the female mite. The burrows are frequently excoriated and may become secondarily infected, resulting in crusting, pustule formation, or furunculosis. Burrows are often found in the digital web spaces, wrists, axillae, nipples, umbilicus, and genitalia. The erythematous papules are usually found on the trunk but may become widespread. Eczematous and urticarial lesions can also be seen as part of the immune response to scabies infestation. In adult patients, the scalp and face are uninvolved, although infants can develop lesions over the entire cutaneous surface.<sup>7</sup> The pruritus of scabies is generally severe and most noticeable at night. Diagnosis of this infestation rests on demonstrating the mites, eggs, larvae, or scybala on microscopical examination of lesional skin scrapings (Figure 8-24).

Scraping is best accomplished with a number 15 surgical blade coated with mineral oil. An intact burrow, generally found in the locations listed above, will provide the highest yield for identifying organisms.

Two clinical variants of scabies exist: nodular scabies and Norwegian scabies. In the former, one sees a few erythematous or violaceous, firm nodules that persist for weeks to months after treatment, long after the rest of the eruption has resolved. These nodules are commonly found on the male genitalia and axillary folds. Norwegian scabies is seen in immunocompromised or debilitated patients. Recently, it has been reported<sup>4</sup> in association with acquired immunodeficiency syndrome. These patients present with thick, scaling, crusted plaques that are found most commonly on the hands, feet, and scalp but may be generalized in distribution. Unlike those seen in common scabies, the lesions on these patients are teeming with mites, with one source<sup>4</sup> estimating the total body load of parasites and eggs to be 5 to 10 million! Patients with Norwegian scabies, often found in hospitals or nursing homes, are therefore highly contagious and can be responsible for local epidemics of scabies.

Treatment of scabies requires ridding the body of mites, relieving symptoms, and treating secondary infection. A variety of medications are available as scabicides, the most widely used being lindane cream or lotion. Neurotoxicity has been reported

## OK to put on the Web

**Fig. 8-24.** Microscopical examination of lesional skin scrapings from a patient with scabies reveals a larval mite form (with three pairs of legs) on the left and four ova on the right. The adult mite (not shown) is about 2- to 3-fold larger than the larva and has four pairs of legs. Photograph: Courtesy of Entomology Department, Walter Reed Army Institute of Research, Washington, D.C.



when lindane is applied to the eczematous skin of infants or when excessive amounts have been used inappropriately (eg, ingesting the liquid); however, lindane is generally safe. The drug should be applied to dry skin, covering the entire cutaneous surface from the neck down, and left on for 8 hours. Re-treatment 2 to 7 days later is suggested to kill any newly hatched nymphs. Opinions vary on the safety of lindane when used in children under the age of 2 years.<sup>26</sup> An alternative for this population, as well as pregnant women, is 5% to 10% precipitated sulfur in petrolatum applied nightly for 3 nights. Elimite cream (5% permethrin, manufactured by Herbert Laboratories, Irvine, Calif.) is a recent addition to the scabicides. Elimite (applied topically from the neck down, left on for 8 h, then reapplied in 48 h) is reported to be equal to or better than lindane and safe in infants older than 2 months.<sup>27</sup> Another agent, although less effective, is Eurax cream (25% crotamiton, manufactured by Westwood Pharmaceuticals, Buffalo, N.Y.), which should be applied topically from the neck down with a second application 24 h later. It is important to treat all close contacts and sexual partners of the patient with the chosen scabicide, for reinfection is a frequent problem. Because the mites survive off humans for only 2 to 3 days, it is necessary to wash only recently used bed linen and clothing in hot water.

Although killing the mites usually provides a rather dramatic reduction in pruritus, individuals with scabies may continue to itch for several weeks. Pruritus is controlled with systemic antihistamines as well as topical corticosteroids and antipruritics. Nodular scabies may require a one-time intralesional injection of a corticosteroid such as triamcinolone acetonide, 2.5 to 10 mg/mL. Any secondary skin infection should be treated with the appropriate antibiotic.

### Nonscabiatic Mites

In general, the reaction caused by nonscabiatic mites is due to a combination of secreted toxins and allergic sensitization. The cutaneous primary lesion is typically a red papule with a central hemorrhagic punctum or vesicle. However, due to their pruritic nature, the lesions often become crusted, eczematized, and secondarily infected. Occasionally, widespread eruptions develop, probably as an allergic phenomenon. These conditions include urticaria, angioedema, erythema, eczematous dermatitis, a varicelliform eruption, and an erythema multiforme-like reaction.<sup>28</sup> In most instances, the causative mites cannot be demonstrated on the patients. Unless indicated otherwise, the treatment of

bites from all these mites consists of topical corticosteroid creams and antipruritic lotions.

Variants of *Sarcoptes scabiei* can infest and produce cutaneous disease in many different animals including dogs, cats, horses, goats, pigs, sheep, and cattle.<sup>24</sup> Humans are infested after coming in contact with the host animal. These mites are unable to complete their life cycle on human skin and burrow only a short distance into the skin. Cutaneous lesions, consisting of intact and excoriated papules, occur on areas most closely in contact with the animal such as the arms, wrists, and abdomen. Skin scrapings from humans are almost always negative and the causative mite must be demonstrated in the host animal. The disease in humans is self-limited and is treated symptomatically. The infested animal should be treated by a veterinarian to prevent reinfestation.

A variety of mites are blood-feeding parasites (*Sarcoptes scabiei* feed on skin) that can prey on humans. Often the primary host is a bird, mammal, reptile, or even another arthropod, and humans are involved secondarily.<sup>28</sup> The tropical rat mite, *Ornithonyssus bacoti*, which commonly infests the black rat, is found in both tropical and temperate urban centers. When the rodents are exterminated, the mites seek alternative hosts and at this time humans are often bitten. The mites tend to accumulate in warm areas such as near appliances or heating systems. The bite of the tropical rat mite is characteristically painful and pruritic. Lesions appear as small hemorrhagic papules, usually on the arms and legs. These papules can become eczematized and secondarily infected after they have been scratched.

*Allodermmanyssus sanguineus* is a parasite of house mice, rats, and other small rodents, and its distribution is worldwide. This mite is medically important as the vector of *Rickettsia akari*, the agent responsible for rickettsialpox. Within the mites, the rickettsial organisms are transmitted transovarially from adult to the next generation. Adult mites transmit the disease to humans. The first lesion to appear is a crusted papulovesicle at the site of the bite. This lesion is followed in about a week by fever, chills, sweats, headache, backache, and generalized papulovesicular eruption that may resemble varicella.<sup>7</sup> Tetracycline (250 mg orally every 6 h for 14 d) is the drug of choice for rickettsialpox. For a detailed discussion of rickettsialpox, see Chapter 11, Rickettsial Diseases.

Several species of mites infest birds as their primary host. The northern fowl mite, *Ornithonyssus sylviarum*, is found in birds and domestic fowl of the

northern temperate areas. Bird handlers are most commonly bitten. Two mites, *Dermanyssus gallinae* and *Ornithonyssus bursa*, can infest domestic poultry. Consequently, pruritic and painful bites may be seen on individuals working in the poultry industry. These two mites also parasitize a number of wild birds including sparrows, starlings, and pigeons. When these birds leave their nests, as in times of migration, humans may be bitten.

The Pyemotidae family of mites have as their hosts a variety of insects that in turn infest grain, straw, seeds, other stored food products, timber, and furniture. The human victims of these mites include farm workers at harvest time, animal feed handlers, florists, and individuals exposed to infested furniture. Cutaneous lesions can be papular, urticarial, vesicular, or pustular.

Cheyletiellidae are nonburrowing mites that commonly infest domestic animals including dogs, cats, and rabbits. Often the pet appears asymptomatic, but on close inspection has "walking dandruff." Because of this, the pet is often overlooked as a source of the bites. Humans are bitten more commonly during the cold winter months when animals are brought indoors. The skin lesions are found on the forearms, thighs, chest, and abdomen where pets are held. They consist of small papules or pustules, frequently with a characteristic necrotic center. Urticarial lesions and widespread erythema may occur. The eruption will disappear when the pet is treated.

The final group of mites to be discussed are those from the family Trombiculidae, commonly known as chiggers, red bugs, or mower's mites. Only the six-legged larval form parasitizes other animals (Figure 8-25). These red larvae, found on the ground or in grass, will attach to a host, feed for 2 to 3 days, molt to the nymphal stage, and then leave the host. They feed through a tube called the stylostome, which is inserted into the epidermis. Bites are commonly seen between May and October when the larvae are active. As the host walks through infested vegetation, the larvae crawl up the legs and usually stop to feed where the clothing constricts, such as the ankles, thighs, or beltline. The initial bites are not felt and the skin lesions develop 3 to 24 hours later when an allergic reaction to mite saliva develops. These lesions appear as highly pruritic red papules grouped about the waist, thighs, and legs that can persist for several weeks. Prevention of bites includes the use of a repellent such as DEET and tucking long trouser legs into stockings.

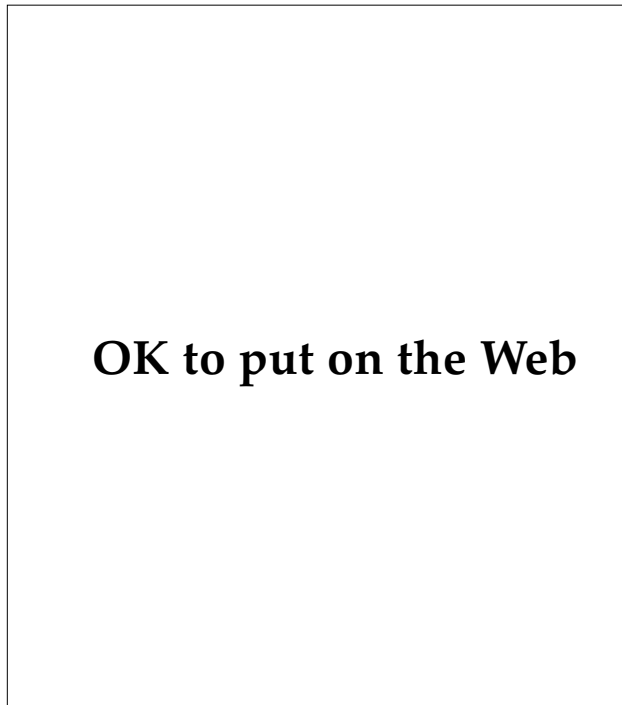
## OK to put on the Web

**Fig. 8-25.** A chigger is the larval form of mites belonging to the family Trombiculidae. It will attach to the host for 2 to 3 days, feeding on blood via a stylostome and producing highly pruritic papules on the legs, thighs, and waist. Some of the Trombiculidae are vectors for tsutsugamushi fever. Photograph: Courtesy of Entomology Department, Walter Reed Army Institute of Research, Washington, D.C.

Some of the Trombiculidae are vectors for scrub typhus or tsutsugamushi fever caused by *Rickettsia tsutsugamushi*. The primary host of these mites are field rats and, although they are probably not a reservoir of infection, the rats serve to maintain the mite population. As with the mite vector of rickettsialpox, *R. tsutsugamushi* are passed transovarially to the larvae. The constitutional symptoms of scrub typhus, namely fever, chills, and intense headache, occur about 10 days after the bite. These symptoms are followed by an erythematous macular rash that starts on the trunk and extends peripherally, and a pneumonitis. At the site of the original bite, an indurated papule develops that becomes necrotic. Tetracycline (250 mg orally every 6 h for 14 d) is the treatment of choice.

### Scorpions

Scorpions are large arachnids with an elongated abdomen that terminates in a stinger (Figure 8-26).<sup>7</sup> They have a pair of abdominal glands that release both neurotoxic and hemolytic venom into the stinger. The distribution of scorpions is worldwide, especially in the tropics. In the United States, the *Centruroides sculpturatus*, measuring 13 to 75 mm, is the most common stinging scorpion and is found in



**Fig. 8-26.** Scorpions have pincer claws, four pairs of legs, and an elongated abdomen that terminates in a stinger. In the United States they range in length from 1.5 to 7.5 cm. Photograph: Courtesy of Entomology Department, Walter Reed Army Institute of Research, Washington, D.C.

the Southwest.<sup>29</sup> Scorpions are nocturnal and hide during the daytime in dark places including closets, shoes, and under rocks and logs. They sting in self-defense, as when they are unwittingly stepped on. Immediately after the sting, the affected individual experiences pain and swelling at the site. The hemolytic venom usually produces little else, although in cases of severe envenomation, coagulopathy and cardiovascular symptoms may result. The neurotoxin, on the other hand, can cause a variety of symptoms including localized numbness, fasciculation, lacrimation, salivation, profuse sweating, urinary urgency, nausea, tongue paresthesia, restlessness, convulsions, and an increase in extraocular muscle activity. Anaphylaxis and death from cardiac or respiratory failure may occur, especially in children. Treatment of scorpion stings consists of first removing the stinger, then applying a tourniquet and cooling the site with ice. If available, specific antivenin should be administered. Barbiturates or diazepam can be given to control the central nervous system hyperactivity and convulsions. Atropine may be useful in blocking the

cholinergic side effects of the neurotoxin. A variety of pesticides such as malathion and diazinon have been used to eradicate scorpions.

## Spiders

Although spiders are notorious among the public as fierce and dangerous creatures and are hence feared (arachnophobia), in fact they are usually shy and tend to avoid contact with humans. Over 30,000 species of spiders have been identified, and yet fewer than 60 are of medical importance in the United States.<sup>30</sup> In this country, only the black widow spider (*Lactrodectus mactans*) and the brown recluse spider (*Loxosceles reclusa*) are known to cause death.<sup>31</sup> Worldwide, other potentially lethal spiders include the Australian funnel-web spider (*Atrax robustus* and *A formidabilis*), the South American banana spider (*Phoneutria fera*), and the South African *Harpactirella*.<sup>4</sup> Although almost all spiders are venomous, the overwhelming majority are unable even to penetrate human skin with their jaws. Those that can penetrate usually cause only minor local injury.

All spiders have a cephalothorax from which extend eight legs and an abdomen. A pair of jaws (chelicerae) are found at the anterior end of the cephalothorax. These jaws terminate in sharp, chitinized fangs from which venom is ejected. This pair of fangs produces the characteristic set of two small puncta found at the site of most spider bites. The venomous glands as well as the spider's multiple eyes (usually eight) are also located in the cephalothorax. On the ventral surface of the abdomen are the spinnerets, which release the web-forming silk. All spiders are carnivores, feeding primarily on insects.

Spiders can adapt to their local environment and live well in man-made structures and refuse. Webs may be found around old tires, garbage cans, outhouses, and lampposts.<sup>32</sup> Spiders are frequently encountered in woodpiles, junkyards, and cluttered attics and closets. They tend to relocate indoors when the weather becomes cold. Simple measures such as cleaning out closets and attics as well as maintaining woodpiles and refuse areas can discourage infestation by and contact with spiders.

Spiders can cause cutaneous and systemic injury in humans through a variety of different mechanisms. Most important is their venom, which can be either neurotoxic or dermonecrotic. These two types of venom are seen in the black widow and brown recluse, respectively, and will be discussed in more

detail below. Many species of tarantulas have hairs that produce urticaria when in contact with skin. Pet owners are the primary recipient of this dermatologic problem. The bite of most spiders, although inconsequential in terms of discomfort or cutaneous damage, may become secondarily infected, producing pustular, impetiginous, or cellulitic lesions. Finally, repeated spider bites can rarely cause allergic reactions including anaphylactic shock.

### **Brown Recluse Spider**

The brown recluse spider (*Loxosceles reclusa*) has a yellow-to-brown cephalothorax and a tan abdomen. The species is identified by a dark brown, violin-shaped marking on the dorsal aspect of the cephalothorax (Figure 8-27). Its body ranges from 1 to 1.5 cm in length, with a leg span of over 2.5 cm. These shy, nocturnal hunting spiders are found throughout the continental United States, and a closely related species, *L. laeta*, is found in South America. Within the United States, they are in greatest numbers in the south-central part of the country, preferring a warm, dry climate. They like protected places such as beneath rocks and boards or in animal burrows or caves where they spin small matted webs. In northern areas of the country, they are more frequently found indoors, in closets, attics, and garages. They avoid daylight and are not aggressive toward humans, attacking only when trapped or crushed against the skin.

## OK to put on the Web

**Fig. 8-27.** The brown recluse spider (*Loxosceles reclusa*) is 1 to 1.5 cm in length with a 2.5-cm leg span. Photograph: Courtesy of Entomology Department, Walter Reed Army Institute of Research, Washington, D.C.

## OK to put on the Web

**Fig. 8-28.** The bite of the brown recluse spider may produce full-thickness skin necrosis. This is usually preceded by a central area of blue-gray discoloration, a blanched halo from arterial spasm, and a large surrounding zone of reactive erythema. Photograph: Courtesy of Entomology Department, Walter Reed Army Institute of Research, Washington, D.C.

The venom from the brown recluse is more potent than that of a rattlesnake. Although different analyses of its contents have yielded conflicting results, the primary dermonecrotic factor appears to be a phospholipase, sphingomyelinase D. This interacts with and damages the plasma membrane of many cell types including erythrocytes, endothelial cells, and platelets. Other enzymes have been identified in the venom, such as alkaline phosphatase, hyaluronidase, collagenase, 5'-ribonucleotide phosphohydrolase, deoxyribonuclease, ribonuclease, and other proteases and esterases. These enzymes, as well as host factors including prostaglandins, leukotrienes, and complement, probably all play a role in the neutrophil chemotaxis, platelet aggregation, and tissue necrosis that occur as a result of the bite.

The clinical outcome of brown recluse spider bites varies widely, ranging from minor, inconsequential, cutaneous reactions to full-thickness skin necrosis and, in some instances, death (Figure 8-28). Multiple factors including host susceptibility, amount of venom injected, and location of the bite play a role in determining the extent of the reaction. Only 10% of patients develop a significant necrotic wound. The initial bite is often painless and unnoticed by the patient. Therefore, the spider is usually not seen and a brown recluse bite is suspected only on clinical grounds. Within 12 to 24 hours of the

bite, pain, erythema, violaceous mottling, swelling, induration, and blister or pustule formation may occur. A characteristic trizonal response takes place, with a central blue-gray area due to thrombosis, a blanched halo from arterial spasm, and a large surrounding area of reactive erythema. In the absence of any of these changes, the patient usually will not develop significant tissue necrosis. Once these changes are seen, however, there is often progression to eschar formation, dermal necrosis, and stellate ulceration. Healing is slow, in severe cases taking up to 6 months. Systemic symptoms include headache, fever, malaise, and arthralgias. A generalized maculopapular rash may be associated with the cutaneous changes. A much more severe systemic reaction due to hemolysis is a rare complication seen primarily in children, who may present with disseminated intravascular coagulation, hemoglobinuria with acute renal failure, convulsions, coma, and death. Patients with significant cutaneous necrosis (> 1 cm) should be tested for progressive hemolytic anemia.

The therapy for brown recluse spider bites has evolved but still remains somewhat controversial. Elements of immediate care include immobilization and elevation of the affected site and the application of ice compresses: the enzymes in the venom are rendered less active with a decrease in temperature. Tetanus toxoid should be administered, if indicated, and analgesics may be necessary. Intralesional injection of corticosteroid (triamcinolone, 25 mg) helps to relieve pain and reduce inflammation.<sup>33</sup> Early excision of the bite site was previously recommended, but this procedure may actually extend tissue damage and delay wound healing. Systemic corticosteroids do not seem to prevent or lessen the cutaneous necrosis but may be beneficial for the systemic manifestations. Dapsone (4,4'-diaminodiphenylsulfone), 100 mg daily, is effective in limiting the cutaneous necrosis; however, this drug must be used with care because it causes hemolysis, most notably in patients deficient in glucose-6-phosphate dehydrogenase. Wound excision and skin grafting should be considered only after the eschar has delineated itself and the wound is no longer enlarging. Systemic antibiotics may be necessary to treat secondary wound infection.

### ***Black Widow Spider***

Of the five species of *Latrodectus* found in the United States, *L mactans*, or the black widow, is the most common and has the widest distribution. These

## OK to put on the Web

**Fig. 8-29.** The black widow spider (*Latrodectus mactans*) has a body measuring up to 1.5 cm long, with a leg span up to 4 cm. Its black abdomen has a red hourglasslike marking on the ventral surface. Photograph: Courtesy of Entomology Department, Walter Reed Army Institute of Research, Washington, D.C.

spiders are found from the South to southern New England. Only the female of the species is capable of envenomating humans. They are jet black with a globose abdomen that has the characteristic red hourglasslike marking on the ventral surface (Figure 8-29). Measuring up to 1.5 cm in length with a 4-cm leg span, black widow spiders prefer a warm, dry environment and can be found both outdoors and inside buildings. The large, strong webs they spin are generally placed close to the ground in protected places like rodent burrows, under stones and logs, in the angles of doors and windows, and in cluttered areas such as dumps, garages, sheds, and outhouses. Although black widows will not aggressively attack humans, they bite when a person inadvertently comes in contact with the web. A notorious and not infrequent scenario is the biting of male genitalia by a black widow spider whose web is located beneath an outhouse seat.

The black widow's venom is a potent neurotoxin composed of proteins, lipids, and carbohydrates. One or more components of this venom bind to the synaptic membranes of nerve terminals, causing the release of large amounts of acetylcholine, catecholamines, or both at the neuromuscular junctions. Re-uptake of the neurotransmitters is also blocked and they are subsequently depleted. Motor nerves, as well as sympathetic and parasympathetic nerves, are affected by this toxin, explaining most of the signs and symptoms of black widow envenomation. This venom, unlike that of the brown

recluse spider, causes little local damage and no necrosis at the site of the bite.

The actual bite of the black widow is often perceived as a sharp pinprick. Two tiny red puncta are usually visible at the site. Mild erythema and edema then ensue, accompanied by a dull ache and numbness that spread from the inoculation site to the torso and, in some cases, the entire body. The systemic symptoms begin within an hour, peak at 1 to 6 hours, and can last 1 to 2 days. Severe myalgias and muscle cramping develop, first regionally, then in a general distribution. In the majority of victims, the abdominal musculature is involved and may simulate an acute surgical abdomen. Other systemic signs and symptoms include headache, restlessness, anxiety, fatigue, insomnia, diaphoresis, salivation, lacrimation, nausea, vomiting, tremors, fasciculation, paresthesias (burning of the plantar surface is characteristic), respiratory distress, shock, and coma. Patients have a characteristic facies that is grimaced, flushed, and diaphoretic, with accompanying blepharoconjunctivitis.<sup>34</sup> Although death from a black widow bite is extremely rare in an adult, it can occur in up to 50% of young children if left untreated.<sup>31</sup>

In the treatment of black widow spider bites, hospitalization should be considered for children, the elderly, those with underlying cardiac or pulmonary disease, or victims displaying severe systemic signs and symptoms. If the patient has no history of sensitivity to horse serum and exhibits severe systemic involvement, *L mactans* antivenin can be given. One ampule containing 2.5 mL, given intravenously or intramuscularly, will relieve most symptoms within 1 to 2 hours. Analgesia can sometimes be obtained with aspirin or acetaminophen, but in severe cases requires narcotics. Muscle relaxants and intravenous calcium gluconate have also been advocated.

### Tarantulas

Tarantulas are the largest of all spiders and belong to the family Theraphosidae (Figure 8-30). The name "tarantula" is actually a misnomer and properly belongs to the much smaller but equally hairy wolf spider found in Europe. In the United States, tarantulas are found throughout the Southwest, where they live in burrows during the day and hunt at night. Their leg span can reach 15 to 18 cm. Although the appearance of these large, hairy spi-

## OK to put on the Web

**Fig. 8-30.** Tarantulas are hairy spiders whose leg spans can measure up to 18 cm. Despite their intimidating appearance, they are usually not harmful to humans, biting only after significant provocation. Photograph: Courtesy of Entomology Department, Walter Reed Army Institute of Research, Washington, D.C.

ders is formidable, they are usually not harmful to humans. They will bite only after significant provocation. Even then, their bite produces only temporary pain without accompanying tissue damage. However, when threatened, tarantulas may flick some of their hair toward an aggressor. These hairs can penetrate the skin and cause a pruritic urticarial dermatitis that lasts several days. This reaction can be treated with topical corticosteroids and oral antihistamines or, if severe, with a brief course of systemic corticosteroids.

### *Chiracanthium*

The genus *Chiracanthium* includes the common garden spider and the common house spider. These spiders are green to brown and vary in length from 7 to 10 mm. They possess a venom that is similar to that of the brown recluse but inject a much smaller volume and, therefore, produce much less tissue damage. Bites occur most frequently at night on exposed parts of the body. The initial bite is usually painful, and a crusted, necrotic lesion can develop within several days. Surrounding erythema and induration are often seen. Occasionally, pain extends far beyond the site of the bite, suggesting a neurotoxin. Treatment includes immobilization and elevation of the site, tetanus prophylaxis, and analgesics. Antibiotics may be necessary for secondary infection.

## REPTILES

A number of reptiles are capable of inflicting significant bite wounds if provoked, and some species pose the additional threat of envenomation. Among the dangerous reptiles that humans may encounter are poisonous snakes and Gila monsters.

### Snakes

Venomous snakes can be encountered throughout the world. In the United States, the rattlesnake, cottonmouth moccasin, and copperhead, all belonging to the family Crotalidae, or pit vipers, account for the vast majority of bites. These pit vipers are found most frequently in the Southeast and Southwest. Other dangerous vipers found in Europe, North Africa, the Middle East, and Asia include the Leventine viper, the puff adder, and a variety of horned desert vipers and carpet vipers. Coral snakes, found in the southern United States, are members of the family Elapidae (including cobras, mambas, and kraits), and are responsible for less than 2% of all poisonous snake bites.<sup>35</sup> Although an estimated 45,000 people are bitten by snakes each year in this country, only 20% of these bites involve venomous snakes and fewer than 12 result in death.<sup>35</sup> Most fatalities are caused by rattlesnakes.

All the pit vipers bite with hollow fangs through which their venom is discharged.<sup>36</sup> Snake venom contains nearly 30 enzymes, most of which are hydrolases. An anticoagulant in the venom causes hemolysis and capillary leakage. Other components include neurotoxic, myotoxic, and cardiotoxic substances.

A wide variety of signs and symptoms may result from a snake bite and accompanying envenomation. Pain, edema, ecchymosis, vesiculation, petechiae, and tissue necrosis can develop at the site of the bite. Systemic manifestations include weakness, diaphoresis, nausea, vomiting, diarrhea, abdominal pain, dysesthesias, headache, fasciculation, hemorrhage, myonecrosis, and shock. Rarely, allergic reactions may be seen in individuals who handle and are repeatedly bitten by snakes.

Therapy for a venomous snake bite should initially consist of the first-aid measures of immobilization, maintenance of vital signs, and prompt transportation to a medical treatment facility. A

tourniquet tightened only enough to impede superficial venous and lymphatic flow can be applied proximally to the fang marks. The use of local ice packs should be avoided, for unlike brown recluse spider bites, tissue damage can actually be increased by this maneuver. Incising the wound and attempting to remove venom by suction is also discouraged because it does little more than delay prompt transportation. Every attempt should be made to identify the snake involved.

Once the snake-bitten patient is hospitalized, an evaluation for hemolysis and myonecrosis should include blood and platelet counts, coagulation studies, and urinalysis. If there is symptomatology or laboratory evidence of envenomation, Antivenin Polyvalent (manufactured by Wyeth-Ayerst Laboratories, Philadelphia, Pa.) should be administered via intravenous drip. Antivenin is available for both pit viper and coral snake bites. Antivenins for some other species of poisonous snakes can be obtained from the Oklahoma City Poison Control Center (405-271-5454). Prior to initiation of therapy, the patient should be skin-tested for hypersensitivity to horse serum because anaphylaxis may occur. Other adverse reactions include fever and serum sickness. Tetanus prophylaxis, analgesics, and appropriate antibiotic coverage for secondary infection are all often indicated. Surgical debridement of necrotic tissue should be done only after the patient is stabilized with normal coagulation parameters.

### Gila Monsters

Gila monsters are venomous lizards found in the southwestern United States.<sup>35,37</sup> They are large, sluggish creatures that will bite humans only when attempts are made to capture or handle them. Once provoked, however, their bite can be both strong and tenacious. Their venom contains phospholipase A, protease, hyaluronidase, and a kinin-releasing factor. If envenomation occurs, the victim may experience sharp local pain and accompanying edema. Other symptoms include weakness, dizziness, tinnitus, fasciculation, nausea, vomiting, and hypotensive shock. Therapy consists, foremost, of removing the lizard from the victim. The Gila monster's jaws are powerful, and a chisel or crowbar may be required to pry them open. The wound

is then irrigated with lidocaine and probed for broken tooth fragments. Tetanus prophylaxis, analgesics, and antibiotic coverage may all be neces-

sary. The victim should be monitored for hypotension and treated accordingly with intravenous fluids. No antivenin is available.

## CATS AND DOGS

Every year, an estimated 1 to 2 million dog bites and 400,000 cat bites are reported in the United States.<sup>38</sup> These injuries account for about 1% of all emergency room visits. Although most wounds are trivial, requiring little or no medical care, serious complications such as cellulitis, osteomyelitis, septic arthritis, and sepsis can occur. The hands and face are frequent sites for bites. The wound inflicted can be a scratch or puncture, but more severe injuries such as avulsions or crush injuries with tissue necrosis may be seen. The risk of wound infection increases with (a) victims older than 50 years of age, (b) immunosuppressed victims, (c) puncture wounds or crush injury, (d) bites to dependent areas, and (e) wounds that have not been promptly irrigated. Although approximately 85% of bite wounds will contain pathogenic bacteria, only 2% to 30% of patients with bites will develop wound infections. A wide variety of bacteria can be involved in wound infections, including both aerobic and anaerobic organisms. *Pasteurella multocida* is found in 20% to 25% of dog-bite wounds and 50% of cat-bite wounds.

Initially, a dog or cat bite should be promptly cleansed, liberally irrigated, and debrided of any devitalized tissue,<sup>39</sup> and tetanus toxoid should be administered. The affected area should be bandaged, elevated, and immobilized. Culturing the initial wound is generally not helpful either in pre-

dicting subsequent infection or in identifying the causative organism if infection should develop. Rather, aerobic and anaerobic cultures should be taken only after evidence of infection is present, with definitive antibiotic therapy guided by in vitro sensitivity assays. Initial empirical therapy should provide coverage against *P multocida*, *Staphylococcus aureus*, streptococci, Centers for Disease Control alphanumeric bacteria (eg, DF-2, EF-4), and anaerobic bacteria. Although penicillin (250 mg orally every 6 h for 10 d) has been the standard treatment, it provides poor coverage of *S aureus*, and a broader-spectrum agent such as amoxicillin-clavulanic acid (250 mg orally every 8 h for 10 d) should be considered. Doxycycline and minocycline (each at 100 mg orally every 12 h for 10 d) are good alternatives for penicillin-allergic individuals. In the absence of clinical infection, consideration should be given for empirical antibiotic therapy of severe wounds, crush injuries, puncture wounds, and wounds involving the hands, joints, or bones. Suturing of laceration wounds is controversial and is probably best reserved for clinically uninfected wounds treated less than 12 hours after the bite. Some authorities recommend initial approximation with adhesive strips and delayed closure.<sup>38</sup> Rabies vaccine (prophylactic, not therapeutic) should be considered if the bite is produced by an unknown domestic animal or a wild animal in which rabies is endemic.

## SUMMARY

Arthropods compose the largest phylum and have a worldwide distribution. Bites and stings inflicted by arthropods may cause significant morbidity in the military operational environment. Any break in the skin may serve as a portal of infection, especially in a humid tropical setting. The scratching that follows many arthropod bites further compromises the skin integrity; cutaneous pyodermas have been a significant cause of hospitalization during past military conflicts. Severe systemic reactions including anaphylaxis may result from a bite or sting. Arthropods also serve as the vectors for a number of infectious diseases, a topic covered in Chapter 9, Arthro-

pod Infestations and Vectors of Disease, and Chapter 11, Rickettsial Diseases. It therefore behooves the medical officer to become familiar with the arthropods found in his or her geographical setting.

Specific therapy exists for those arthropods taking up residence on the human skin such as scabies and lice. Topically applied insecticides such as 1% lindane and 5% permethrin will eradicate the organisms. In the majority of cases where the arthropod is only in contact with the skin long enough to bite or sting, the treatment is symptomatic, aimed at relieving pain and pruritus. A variety of methods exist for preventing arthropod bites.



General public health measures include separating livestock, wood piles, and latrine and garbage sites from living quarters. Doors and windows may be fitted with mesh netting and the floors elevated from the ground. Protective clothing reduces exposed skin. Insecticides such as malathion and the pyrethroids may be sprayed or powdered in living quarters and on furniture. Finally, a number of repellents are available for both topical application and impregnation in clothing. One of the best repellent combinations appears to be topically applied DEET and permethrin-impregnated clothing.

Although most cat and dog bites are minor

and require little or no medical care, they are a frequent cause of visits to the emergency room, and infection can arise without prompt wound cleaning and administration of antibiotics. Wounds inflicted by poisonous reptiles, although less common than cat and dog bites, can have serious consequences and require immediate first-aid treatment. Gila monsters have powerful jaws, and sometimes a crowbar is required to pry them from the victim; patients should then be monitored for hypotension. In the event of a poisonous snake bite, it is important to identify the variety of snake so that the proper antivenin can be administered.

#### REFERENCES

1. MacPherson WG, Horrocks WH, Beveridge WWO. *History of the Great War, Medical Services, Hygiene of the War*. Vol 2. London, England: His Majesty's Stationery Office, 1923: 327–340.
2. Pillsbury DM, Livingood CS. Dermatology. In: Havens WP, ed. *Infectious Diseases and General Medicine*. In: Havens WP, Anderson RS, eds. *Internal Medicine in World War II*. Vol 3. Washington, DC: Medical Department, US Army, Office of The Surgeon General; 1968: 543–673.
3. Allen AM. *Skin Diseases in Vietnam, 1965–72*. In: Ognibene AJ, ed. *Internal Medicine in Vietnam*. Vol 1. Washington, DC: Medical Department, US Army, Office of The Surgeon General and Center of Military History; 1977: 59–139.
4. Alexander JO. *Arthropods and Human Skin*. Berlin, Germany: Springer-Verlag; 1984: 3–9, 117, 364, 399–408.
5. Mellanby K. Man's reaction to mosquito bites. *Nature*. 1946;158:554.
6. Burnett JW, Calton GJ, Morgan RJ. Centipedes. *Cutis*. 1986;37:241.
7. Arnold HL, Odom RB, James WD. *Andrew's Diseases of the Skin*. Philadelphia, Pa: WB Saunders Company; 1990: 486–533.
8. Burnett JW, Calton GJ, Morgan RJ. Caterpillar and moth dermatitis. *Cutis*. 1986;37:320.
9. Rosen T. Caterpillar dermatitis. *Dermatol Clinics*. 1990; 8:245–252.
10. Burnett JW, Calton GJ, Morgan RJ. Bedbugs. *Cutis*. 1986;38:20.
11. Burnett JW, Calton GJ, Morgan RJ. *Triatoma*: The "kissing bug." *Cutis*. 1987;39:399.
12. Elgart ML. Pediculosis. *Dermatol Clinics*. 1990;8:219–228.
13. Meinking TL, Taplin D, Kalter DC, et al. Comparative efficacy of treatments for pediculosis capitis infestations. *Arch Dermatol*. 1986;122:267–271.
14. Elgart ML. Flies and myiasis. *Dermatol Clinics*. 1990;8:237–244.
15. Brown AWA. The attraction of mosquitoes to hosts. *JAMA*. 1966;196:159–162.
16. Kurgansky D, Burnett JW. Diptera mosquitoes. *Cutis*. 1988;41:317–318.

17. Burnett JW. Myiasis. *Cutis*. 1990;46:51–52.
18. Burnett JW, Calton GJ, Morgan RJ. Blister beetles: “Spanish fly.” *Cutis*. 1987;40:22.
19. Gayer KD, Burnett JW. Hymenoptera stings. *Cutis*. 1988;41:93–94.
20. Elgart GW. Ant, bee, and wasp stings. *Dermatol Clinics*. 1990;8:229–236.
21. Schorr WF, Tauscheck AL, Dickson KB, Melski JW. Eosinophilic cellulitis (Wells’ syndrome): Histological and clinical features of arthropod bite reactions. *J Am Acad Dermatol*. 1984;11:1043–1049.
22. Ross EV, Badame AJ, Dale SE. Meat tenderizer in the acute treatment of imported fire ant stings. *J Am Acad Dermatol*. 1987;16:1189–1192.
23. Modly CE, Burnett JW. Tick-borne dermatologic diseases. *Cutis*. 1988;41:244–246.
24. Elgart ML. Scabies. *Dermatol Clinics*. 1990;8:253–263.
25. Mellanby K. Biology of the parasite. In: Orkin M, Maibach HI, Parish LC, Schwartzman RM, eds. *Scabies and Pediculosis*. Philadelphia, Pa: JB Lippincott, 1977.
26. Lindane, a prudent approach. *Arch Dermatol*. 1987;123:1008–1010. Editorial.
27. Taplin D, Meinking TL, Porcelain SL, et al. Permethrin 5% dermal cream: A new treatment for scabies. *J Am Acad Dermatol*. 1986;15:995–1001.
28. Blankenship ML. Mite dermatitis other than scabies. *Dermatol Clinics*. 1990;8:265–275.
29. Burnett JW, Calton GJ, Morgan RJ. Scorpions. *Cutis*. 1986;36:393.
30. Wilson DC, King LE. Spiders and spider bites. *Dermatol Clinics*. 1990;8:277–286.
31. Wong RC, Hughes SE, Voorhees JJ. Spider bites. *Arch Dermatol*. 1987;123:98–104.
32. Spider bites. *Arch Dermatol*. 1987;123:41–43. Editorial.
33. Burnett JW, Calton GJ, Morgan RJ. Brown recluse spider. *Cutis*. 1985;36:197–198.
34. Burnett JW, Calton GJ, Morgan RJ. Lactrodectism: Black widow spider bites. *Cutis*. 1985;36:121.
35. McKoy KC, Moschella SL. Parasites, arthropods, hazardous animals, and tropical dermatology. In: Moschella SL, Hurley HJ, eds. *Dermatology*. Philadelphia, Pa: WB Saunders Company; 1985: 1731–1820.
36. Burnett JW, Calton GJ, Morgan RJ. Venomous snakebites. *Cutis*. 1986;38:299–300.
37. Burnett JW, Calton GJ, Morgan RJ. Gila monster bites. *Cutis*. 1985;35:323.
38. Goldstein EJC. Management of human and animal bite wounds. *J Am Acad Dermatol*. 1989;21:1275–1279.
39. Burnett JW. Bite wounds. *Cutis*. 1990;45:287.

# Chapter 9

## ARTHROPOD INFESTATIONS AND VECTORS OF DISEASE

CURT P. SAMLASKA, M.D.\*

---

### INTRODUCTION

### MITES AND TICKS

- Lyme Disease
- Relapsing Fever
- Rickettsial Diseases
- Tick Paralysis
- Tick-Bite Alopecia
- Tick-Bite Reactions

### FLEAS

- Plague
- Flea Bites
- Papular Urticaria
- Tungiasis

### OTHER INSECTS

- Lice
- Bedbugs
- Biting Flies

### SUMMARY

\*Lieutenant Colonel, Medical Corps, U.S. Army; Chief, Dermatology Service, Tripler Army Medical Center, Honolulu, Hawaii 96859

## INTRODUCTION

To an entomologist the word “insect” refers to the class Insecta, a group of organisms with six legs and three body segments: head, thorax, and abdomen. The layman and many in the medical community would also include spiders and mites (class Arachnida), both of which have eight legs and two body segments: head and abdomen. A more precise and inclusive term than insect is arthropod (phylum Arthropoda), comprising organisms from both classes, Insecta and Arachnida; these classes have as common features a hard, jointed exoskeleton and paired, jointed legs (Table 9-1). Some arthropods evolved into parasites, developing piercing-sucking mouth parts enabling them to obtain blood meals. Harwood and James<sup>1</sup> believe that in their evolution, arthropods began as scavengers of vertebrate-lair detritus. The host, in addition to providing a steady food source, provides

warmth and shelter. Synanthropy, in contrast to parasitism, is a loose form of dependence between insects (eg, cockroaches, some fly and ant species) and vertebrates in which direct host feeding does not occur.<sup>1</sup>

Insects are estimated to have preceded human existence by at least 400 million years. Documentation of human afflictions with insects dates back to prehistoric times.<sup>1</sup> Legends, art, and speech have preserved our earliest knowledge of these most numerous pests. Stoneware from Mexico (AD 1200) and Peru (AD 400–900) display detailed depictions of fleas and tungiasis.<sup>1</sup> Variations of the story of Pandora’s box attempt to explain human louse and flea infestations. In about AD 1200, Native American potters depicted mosquitoes poised for attack. In Exodus 8:24, the Bible refers to “a grievous swarm of flies into the house of Pharaoh, and into all the

**TABLE 9-1**  
**ARTHROPODS KNOWN TO BE VECTORS OF HUMAN INFECTIOUS DISEASES**

Class —Subclass	Order —Suborder	Families —Subfamilies	Common Names
Arachnida			
—Acari	Acarina	Ixodidae Argasidae	Hard ticks Soft ticks
—Acari	Acarina —Parasitiformis	Gamasidae	Mites
Insecta			
	Anoplura	Pediculidae	Head and body lice
	Pthiridae	Crab louse	
	Siphonaptera	Pulicidae Leptopsyllidae	Human flea Mouse flea
	Diptera	Muscidae Culicidae —Culicinae —Anophelinae Psychodidae —Phlebotominae Simuliidae	Tsetse fly <i>Aedes</i> mosquito <i>Anopheles</i> mosquito Sandflies Black flies
	Diptera —Brachycera	Tabanidae	Horse and deer flies
	Hemiptera	Reduviidae	Kissing bug

Data sources: (1) Harwood RF, James MT, eds. *Entomology in Human and Animal Health*. 7th ed. New York, NY: Macmillan Publishing Co; 1979: 117–392. (2) Alexander JO. *Arthropods and Human Skin*. Berlin, Germany: Springer-Verlag; 1984: 303.

land of Egypt: the land was corrupted by reason of the swarm of flies." That insects were vectors of human disease was first suggested in 1577 by Mercurialis, who believed that flies carried the "virus" of plague.<sup>1</sup> Subsequent observations by numerous investigators up to the early 1900s helped better understand vector transmission of yaws, Carrion's disease, bubonic plague, malaria, and yellow fever. Medical entomology began in 1909 and was the direct result of the development of the microscope, rejection of the spontaneous generation theory, formulation of the germ theory by Louis Pasteur, and establishment of controlled experimentation by Walter Reed.<sup>1,2</sup>

Diseases caused by insects and arachnids can be

the result of direct tissue injury, transmission of intermediate host parasites, or vector transmission of infectious and parasitic organisms.<sup>1</sup> Human diseases transmitted by insect vectors are some of the most ancient and deadly of all infectious disorders. During World War I, louse-borne typhus contributed to the collapse of the Russian and Balkan fronts.<sup>1</sup> Epidemics occurred also during World War II in Naples, Italy, and Germany; however, use of dichlorodiphenyltrichloroethane (DDT) greatly reduced the spread of disease.<sup>1</sup> War and natural disasters promote epidemics of these ancient disorders, as exemplified by the concerns that widespread epidemics would follow Operations Desert Storm and Desert Shield, 1991–1992.

### MITES AND TICKS

Three orders of medical importance are found within the class Arachnida: mites and ticks (Acarina), spiders (Araneida), and scorpions (Scorpiionida).<sup>3</sup> Of these, only mites and ticks are significant vectors of human disease. Infestations by gamasid mites have been suspected to transmit a variety of rickettsial and viral diseases (Figure 9-1).<sup>4</sup> *Ornithonyssus bacoti* has been implicated in the transmission of endemic typhus, rickettsialpox, and Q fever (which are discussed in Chapter 11, Rickettsial Diseases), as well as relapsing fever, St. Louis encephalitis, and western equine encephalitis. *Ornithonyssus sylvoiarum* can transmit western equine encephalitis and St. Louis encephalitis.

*Ornithonyssus bursa* has been shown to transmit western equine encephalitis and is suspected to be a vector for Q fever. *Demanyssus gallinae* is a vector for the transmission of endemic typhus and St. Louis encephalitis. Rickettsialpox outbreaks in New York have been reported to be transmitted by *Liponyssoides sanguineus* (house mouse mite).<sup>5</sup> Gamasid mites are parasitic for domestic and wild birds, rats, and mice. They have a worldwide distribution and are known to attack humans.

Scabies is an infestation with *Sarcoptes scabiei*, an eight-legged human mite. The disease is most frequently transmitted through sexual intercourse. Chiggers, from the family Trombiculidae, are nonscabiatic mites found on the ground or in grass. Their larvae can crawl up the legs as the host walks through infested vegetation. For a detailed discussion of mites and the dermatoses they transmit, see Chapter 8, Arthropod and Other Animal Bites.

Ticks are natural parasites of mammals, birds, reptiles, and amphibians (Table 9-2). Ticks consist of two groups: (1) the Ixodidae, which have a hard, chitinous, dorsal shield (ie, scutum), and (2) the Argasidae, or soft tick, which lacks a scutum. The natural life cycle is dependent on longer feeding cycles than those of other parasitic organisms such as flies, and ticks will feed until engorged with blood, reaching several times their original size (Figure 9-2).

As a group, most ticks fast for long periods because they cannot live on vegetable matter. A blood meal is acquired mostly by chance. Ticks climb to the top of grass stems or shrubs and await the passing of a suitable host. Sensory response to odor, vibration, air currents, interruption of inci-

**OK to put on the Web**

**Fig. 9-1.** Gamasid mites. These mites have a worldwide distribution, are known to attack man, and are suspect vectors of rickettsial and viral diseases.

**TABLE 9-2**  
**TICKS AS VECTORS OF HUMAN INFECTIOUS DISEASES**

Infectious Disease	Tick Vector	Distribution
Lyme disease	<i>Ixodes ricinus, I pacificus, I scapularis</i>	Worldwide
Relapsing fever	<i>Ornithodoros</i> spp	Africa, Asia, United States, Europe, Near East, Mediterranean, Canada, Central and South America
Tularemia	<i>Dermacentor andersoni, Ixodes</i> spp	Americas, Europe, Japan, Israel, Africa
Arboviruses		
Omsk hemorrhagic fever	<i>Dermacentor pictus, D marginatus, Ixodes persulcatus, I apronophorus</i>	Siberia
Russian spring-summer encephalitis	<i>Ixodes persulcatus</i>	Central Europe, former USSR
Louping ill	<i>Ixodes ricinus</i>	British Isles, Spain
Powassan	<i>Dermacentor andersoni, Ixodes spinipalpis</i>	United States, Canada
Kyasanur forest disease	<i>Haemaphysalis</i> spp, <i>Ixodes</i> spp <i>Rhipicephalus turanicus</i>	India
Crimean-Congo hemorrhagic fever	<i>Hyalomma marginatum</i>	Asia, Europe, former USSR, Mediterranean, China, Middle East, Africa
Colorado tick fever	<i>Dermacentor andersoni, Ixodes</i> spp	United States, Canada
Ungrouped or other viruses		
Lymphocytic choriomeningitis*	<i>Amblyomma variegatum, Rhipicephalus sanguineus, Dermacentor andersoni</i>	Ethiopia, Canada
Rickettsia		
Rocky Mountain spotted fever	<i>Ixodes</i> spp, <i>Dermacentor andersoni</i>	United States, Canada, Mexico, South America
Siberian tick typhus	<i>Ixodes</i> spp	Former USSR, Japan, Far East
Boutonneuse fever	<i>Rhipicephalus sanguineus, Haemaphysalis</i> spp, <i>Ixodes</i> spp, <i>Hyalomma</i> spp, <i>Amblyomma</i> spp, <i>Boophilus</i> spp, <i>Dermacentor</i> spp	Africa, Europe, Asia, Mediterranean, Turkey, Crimea, Israel
Queensland tick typhus	<i>Ixodes holocyclus</i>	Queensland, Australia
Epidemic (louse-borne) typhus	<i>Pediculus humanus corporis</i>	Ethiopia
Q fever*	<i>Hyalomma asiaticum</i>	Europe, Mediterranean, Black Sea, Asia, Africa, North America, Australia
Tick-bite fever*	<i>Haemaphysalis leachi</i>	South Africa
Sennetsu fever*	Tick spp	Japan
Ehrlichiosis*	Tick spp	United States
Piroplasmosis		
Human babesiosis	<i>Ixodes scapularis</i>	Eastern and midwestern United States

\* Association with human transmission by tick vectors yet to be proven.

Data sources: (1) Harwood RF, James MT, eds. *Entomology in Human and Animal Health*. 7th ed. New York, NY: Macmillan Publishing Co; 1979: 371-416. (2) Samlaska CP. Arthropod-borne virus infections and virus hemorrhagic fevers. In: Demis DJ, ed. *Clinical Dermatology*. New York, NY: JB Lippincott; 1991: Unit 14-22; 1-15. (3) Gear JH, Wagner JM, Dyssel JC, et al. Severe tick-bite fever in children. *S Afr Med J*. 1990;77:84-87.

## OK to put on the Web

**Fig. 9-2.** Normal (on left) and engorged (on right) eastern wood ticks. When engorged with blood, ticks expand to several times their normal size.

dent light, warmth, and even moisture signal the presence of a potential host. The tick lacerates the host's skin with rigid, toothed chelicerae. Salivary solutions soften the surrounding tissues. As the tick penetrates the skin, it assumes a more vertical position (Figure 9-3). A cementlike substance is secreted into the wound, securing the hypostome into place. Frequently, hemorrhage takes place around the hypostome due to the cytolytic and anticoagulant action of secreted saliva. Feeding is usually complete within 6 to 7 days, but the tick can remain attached to the host for an unspecified period. Some ticks can live for 15 to 16 years.<sup>3</sup>

Ticks require a blood meal before they can lay eggs, with the number of eggs laid ranging from 300 to 7,000 depending on the species. There are four stages of development: egg, larva, nymph, and adult. The interval of development between the various stages can be considerable (66–359 d).

Caution should be exercised when removing ticks; at no time should they be forcibly removed. Forceful removal promotes breaking off of mouthparts and the subsequent development of a foreign-body granuloma. The preferred method for tick removal is by forceps.<sup>6,7</sup> The forceps are pressed to the sides of the tick's mouth parts and with a levering and lifting motion the tick is detached. Care should be taken to avoid squeezing the body of the tick.

Numerous other methods of tick removal are available.<sup>3</sup> Application of liquid paraffin to the tick results in blocking tick respirations. This technique requires 2 or more hours to work. Applying chloroform or ether to the tick results in quicker removal; however, there is a distinct risk of burn injury if unexpectedly ignited. Application of a warm match or match flame also works quickly, but has the same

risk of igniting hair. Excisions or punch biopsies under local anesthesia are quite successful but are more invasive than other methods.

Because rapid deployment and high mobility are required of today's military, regional control of tick vectors for military personnel in the field is unlikely to prove effective. Therefore, individual preventive measures are most important. Use of permethrin-based repellents on clothing and applications of diethyltoluamide (DEET) on the skin are helpful. A recent study performed by the U.S. Army Environmental Hygiene Agency<sup>8</sup> clearly demonstrated that military uniforms impregnated or sprayed with permethrin more successfully controlled tick infestations than DEET applied to uniforms or skin. Duration of tick attachment has been shown to correlate with the probability of disease transmission; therefore, diligent daily searches for ticks should be performed.<sup>9</sup> In endemic areas, prophylactic antibiotics can be administered to soldiers who have been bitten by a tick.<sup>9</sup>

### Lyme Disease

Lyme disease is an inflammatory disorder caused by the spirochete *Borrelia burgdorferi* and transmitted by Ixodes ticks. An early manifestation of the disease is an annular cutaneous lesion known as erythema chronicum migrans; however, the nervous system, heart, and joints may also become

## OK to put on the Web

**Fig. 9-3.** Tick feeding on human subject. Note vertical positioning of the engorged tick body.

involved. For a detailed discussion of Lyme disease, see Chapter 13, Bacterial Skin Diseases.

### Relapsing Fever

Relapsing fever is either endemic and transmitted by ticks or epidemic and transmitted by lice. Endemic tick-borne relapsing fever is caused by many species of *Borrelia* and is transmitted to humans by the soft *Ornithodoros* ticks. Relapsing fever transmitted by ticks is endemic in the western United States, where infected ticks reside in dead wood or are carried by wild rodents and domestic animals. Infection occurs during the summer months in the United States. Tick bites are often not recognized because they are painless; moreover, *Ornithodoros* ticks are night feeders and drop off quickly. The infective agents of tick-borne relapsing fever can vary their major surface antigens and thus evade the host's immune response.<sup>10</sup> *Borrelia* organisms infesting tick vectors are maintained in nature in the tick, which frequently has a long life (*Ornithodoros* ticks can live up to 13 y), by trans-ovarian transmission in some tick species, and by transmission to rodent reservoir hosts.<sup>11</sup>

Epidemic louse-borne relapsing fever is caused by *Borrelia recurrentis* and is transmitted to humans by the body louse *Pediculus corporis*.<sup>10</sup> Louse-borne relapsing fever was associated with large epidemics during World War II, with over 50,000 reported deaths.<sup>9</sup> Lice remain infective for their lifetime, and have no apparent natural vertebrate hosts.

The clinical manifestations of tick-borne and louse-borne relapsing fevers are the same. After a short incubation period of 3 to 10 days, the patient presents with sudden onset of fever associated with constitutional symptoms of cough, headache, lethargy, myalgias, and arthralgias. The fever terminates abruptly after a few days but is followed 3 to 10 days later by another febrile episode; this pattern persists, particularly in the tick-borne form, as new major surface antigens appear. The organisms are found in the blood and other bodily fluids during these febrile episodes. The severity and duration of the attacks decrease with time.<sup>9,11</sup>

An erythematous papular or petechial eruption may occur on the trunk during the last 1 to 2 days of the initial febrile episode. Up to 30% of patients develop neurological complications including cranial nerve palsies, meningitis, seizures, hemiplegia, and coma. Eye complications such as iritis and iridocyclitis occur in 15% of reported cases. Severe involvement resulting in death from fulminant liver failure and myocarditis have also been reported.<sup>9</sup>

The diagnosis of relapsing fever is confirmed on demonstration of *Borrelia* organisms in blood smears during febrile episodes. Wright- or Giemsa-stained dried blood smears, or dark-field examination of wet blood smears, yield positive results in up to 70% of patients. False-positive serologic tests for syphilis occur in up to 5% to 10% of cases.<sup>9</sup>

Antibiotics are effective treatment modalities for relapsing fever, including tetracycline (500 mg orally twice a day for 10–21 d), penicillin G (0.5–5 mU every 6 h intravenously for 10 d), erythromycin (250 mg orally 4 times a day for 10–21 d), and chloramphenicol (500 mg orally 4 times a day for 10–21 d). Louse-borne disease can be treated with a single 500-mg dose of erythromycin or tetracycline.

### Rickettsial Diseases

*Rickettsia* is a Gram-negative genus of bacteria capable of causing a number of diseases in humans. These disorders are reviewed in detail in Chapter 11, Rickettsial Diseases; however, some of the more common human infections are worth mentioning briefly here.

Tick-bite fever is caused by *Rickettsia conorii* and is believed to be transmitted to humans by the dog tick, *Haemaphysalis leachi*. The disease affects predominantly children in South Africa and is usually benign and self-limited. In adults and some children, however, the disease may be fulminant, with a profuse maculopapular eruption, hepatitis, renal failure, and a hemorrhagic diathesis manifested as petechial hemorrhages, thrombocytopenia, and disseminated intravascular coagulation.<sup>12</sup>

Ehrlichiae are members of the family Rickettsiaceae, first isolated from infected dogs in 1935.<sup>6</sup> Until recently, the only known human disease was Sennetsu fever, caused by *Ehrlichia sennetsu*. The disease was first described and the organism first isolated in the 1950s in Japan. Characteristic features of the illness include remittent fever, generalized lymphadenopathy, hepatosplenomegaly, and increased circulating mononuclear cells and atypical lymphocytes similar to those observed in infectious mononucleosis. Other features of mononucleosis, such as fatigue, anorexia, chills, headache, and myalgias, have been reported. Cutaneous eruptions are unusual for this disorder. Although yet unproven, the disease is believed to be transmitted to humans through tick bites.<sup>6</sup>

During the Vietnam conflict in the late 1960s, a fatal epizootic hemorrhagic illness (called tropical canine pancytopenia) caused the deaths of many dogs attached to U.S. forces in the region.<sup>13</sup> The



illness correlated with heavy infestations of the tick *Rhipicephalus sanguineus*, and the causative organism was shown to be *Ehrlichia canis*. In 1987, the first case of human ehrlichiosis caused by *E. canis* was reported.<sup>14</sup> Patient serum samples submitted for evaluation for suspected Rocky Mountain spotted fever are confirmed positive for *Rickettsia rickettsii* only 10% to 20% of the time.<sup>6</sup> Many of these seronegative cases are now believed to be due to Ehrlichiae. The majority of human ehrlichiosis cases have been reported in the southeastern, south central, and mid-Atlantic United States. The predominant clinical findings include fever (85%–99%); headache (83%–94%); myalgia (47%–82%); anorexia (81%–83%); nausea, vomiting, or both (42%–60%); rash (0%–60%); diarrhea (38%–50%); abdominal pain (19%–33%); confusion (12%–33%); and lymphadenopathy (0%–19%).<sup>6,15</sup> When present, the cutaneous eruption may be petechial or macular and distributed over the trunk or extremities. Leukopenia, thrombocytopenia, anemia, and elevated aminotransferase levels may occur. Currently, confirmation of ehrlichiosis requires acute and convalescent sera for indirect immunofluorescence. Due to the retrospective nature of this form of confirmation, early diagnosis is based on clinical findings. Tetracycline (250 mg orally four times a day for 10 d) and tetracycline derivatives are the drugs of choice, although chloramphenicol (500 mg orally four times a day for 10 d) has also been used successfully.<sup>6,15</sup>

### Tick Paralysis

Tick paralysis in animals was first identified in Australia in 1824.<sup>3</sup> The first human case was reported by Bancroft<sup>16</sup> in 1884 in Queensland, Australia, and subsequent cases have been described in the United States, British Columbia, South Africa, France, Germany, Yugoslavia, and Crete (Table 9-3). The acute, ascending, lower-motor-neuron paralysis is due to a toxin produced by certain species of ticks. The toxin causes a conduction block at the myoneural junction similar to that observed with curare; it has been partially purified from the Australian tick *Ixodes holocyclus* and is resistant to digestion by pepsin, papain, and trypsin.<sup>3,17</sup> Parenteral injection into dogs results in paralysis within 48 hours. Tick paralysis results only from the bite of gravid female ticks.<sup>17</sup>

Children are more frequently afflicted with tick paralysis than adults. Although dark-haired individuals are said to be more susceptible, perhaps dark hair only makes the tick more difficult to find, and consequently the diagnosis is delayed.<sup>17</sup> Pain

or numbness may precede the onset of motor weakness and, in children, restlessness, irritability, malaise, anorexia, and vomiting are not uncommon presenting complaints. Fever is not a feature of tick paralysis. The paralysis begins 2 or more days after the tick attaches, with weakness of the lower extremities progressing in hours to falling episodes and incoordination. True ataxia is rarely observed, and incoordination is attributed to motor weakness. Some cases of more proximal motor weakness have been described. Cranial nerve findings may ensue, manifested as dysarthria and dysphagia progressing to bulbar paralysis. Localized paralysis can sometimes occur, resulting in facial paralysis (tick attached to external auditory meatus), photophobia or blurred vision (tick attached behind the ear), or frontalis and orbicularis oculi paralysis (tick attached to frontal region).<sup>3</sup> The weakness is symmetrical and flaccid, and diffuse areflexia is present. The pupils remain reactive and sensory examination is normal. Patients usually succumb to respiratory failure.

Removal of the tick and supportive medical care, including respiratory support, form the cornerstone of therapy. The tick is usually found in the scalp. More than one tick may be present; therefore, a thorough examination is imperative. Clinical improvement usually begins within hours after tick removal, and full recovery occurs in 3 to 11 days for most patients. At times, however, recovery may be slower, requiring weeks to months. Permanent paralysis is exceedingly rare.

The differential diagnosis of tick paralysis includes Lyme disease, Guillain-Barré syndrome, myasthenia gravis, porphyria, botulism, and transverse myelitis.<sup>7</sup> The most common disease in this group is Guillain-Barré syndrome, which can be

**TABLE 9-3**  
**GEOGRAPHIC DISTRIBUTION OF TICK VECTORS IMPLICATED IN HUMAN TICK PARALYSIS**

Geographic Location	Ticks
Australia	<i>Ixodes holocyclus</i> , <i>I. cornatus</i>
British Columbia	<i>Dermacentor andersoni</i>
United States	<i>Dermacentor andersoni</i>
South Africa	<i>Rhipicephalus evertsi evertsi</i>

Data source: Kincaid JC. Tick bite paralysis. *Semin Neurol*. 1990;10:32–34.

differentiated from tick-bite paralysis by elevation of spinal fluid protein and slowed nerve-conduction velocities. Although Lyme disease may involve similar neurological complaints, they occur weeks to months after the tick bite. A negative enzyme-linked immunosorbent assay (ELISA) for *Borrelia burgdorferi* would also be helpful in differentiating the two diseases.

### Tick-Bite Alopecia

Tick-bite alopecia has been well established in the medical literature since Ross and Friede<sup>18</sup> described the first human case in 1955. The condition is believed to be due to direct toxic effects from tick saliva.<sup>19</sup> A history of tick bite is noted, or a tick may be found in the center of the site of alopecia. The hair usually begins to fall out 1 week after the tick bite, coinciding with induction of telogen hairs.<sup>3</sup> Necrosis at the site of the tick bite is frequently observed, surrounded by a 1- to 4-cm patch of alopecia.<sup>20,21</sup> Exclamation mark hairs similar to those observed in patients with alopecia areata have been reported.<sup>20</sup> Regrowth begins within 2 weeks and is complete within 2 months.<sup>3</sup> Scarring centrally from the original tick bite may result in residual scarring alopecia.

### Tick-Bite Reactions

The most frequent sites of tick-bite reactions in children are the head and neck; in adults, the trunk and legs.<sup>3</sup> Local effects include swelling, erythema, paresthesia, blistering, pruritus, ecchymosis, indu-

Fleas evolved as highly specialized, bloodsucking parasites at least 60 million years ago.<sup>22</sup> Their ancestors may originally have had wings, but these would have inhibited movement through the host's fur; thus, jumping provided an alternative means of locomotion. Fleas are amazingly resilient: various species can jump 150-fold their own length (vertically or horizontally equivalent to a human's jumping 900 ft); survive months without feeding; accelerate 50-fold faster than the space shuttle; withstand enormous pressure; and remain frozen for a year, then revive. The amazing ability of the flea to jump so well is due to a superelastic protein located in the thorax known as resilin. The leg and thorax muscles compress a tiny pad of resilin, which is suddenly released, resulting in the explosive unleashing of

## OK to put on the Web

Fig. 9-4. Tick-bite reaction. These lesions are characterized by a large zone of erythema.

ration, nodule formation (prurigo-like lesions), and necrosis (Figure 9-4). *Ixodes racinus* bites may cause local gangrene, erysipelatoid swelling, generalized erythema, generalized urticaria, or psoriasiform eruptions. Healing of tick bites usually occurs in 2 to 3 weeks but may take longer. Systemic symptoms include nausea, vomiting, diarrhea, pulse irregularities, dyspnea, fever, gastrointestinal irritation, restlessness, muscular weakness, drooping eyelids, photophobia, delirium, hallucinations, and generalized pain of tick typhus. Some of these symptoms overlap with those reported for tick paralysis. Most of these complaints resolve with removal of the tick.<sup>3</sup>

## FLEAS

kinetic energy.<sup>22</sup>

More than 2,400 species and subspecies have been described. The order Siphonaptera contains only 2 flea families of medical importance: Pulicidae (human, cat, dog, and bird fleas) and Sarcopsylidae (also called Tungidae), the sand flea, which causes tungiasis.<sup>22,23</sup> The human flea is *Pulex irritans*. Fleas are wingless, laterally compressed insects with a hard, shiny integument. The body has 3 regions: the head, thorax, and abdomen. Mouth parts are modified (paired maxillary palpi) for piercing and sucking. The head is applied directly to the three-segmented thorax (no neck). A "comb" may be present or absent at the posterior margin of the first segment and is a major feature for classification (Figure 9-5). A pair of legs is attached to each thoracic

## OK to put on the Web

**Fig. 9-5.** *Pulex irritans*, the human flea. Note the comb at the posterior margin of the first segment, a major feature for classification.

segment, resulting in 3 pairs of legs. Each leg has 5 distinct parts. The abdomen has 9 to 11 segments.<sup>23,24</sup> Fleas require a blood meal to perpetuate their species. In some cases the blood meal must be from a specific

host, but in others any suitable host is sufficient. Eggs are deposited on the ground. In some species, such as the rabbit flea (*Siphonopsyllus cuniculi*), the female flea responds to hormonal changes in the pregnant rabbit host, resulting in synchronized rabbit-flea procreation cycles. In animals with thick fur, fleas tend to infest for long periods of time, utilizing the warmth and protection of the fur. In humans, however, the flea is only a transient visitor for the purpose of feeding. The life cycle for adult fleas varies considerably: the human flea, *Pulex irritans*, lives 4 to 6 weeks; *Tunga penetrans* lives about 17 days. The individual stages can be modified by adverse conditions, extending the flea life cycle to beyond 200 days. Likewise, the pupal stage can vary from 7 days to 1 year. At all stages of development, the flea can withstand starvation for long periods. The stimulus for sudden, famished flea activity may be initiated by footstep vibrations. Fleas jump, on average, about 20 cm; however, when searching for food or attempting to escape enemies, they can reach a height of 2 m or more.<sup>23</sup> Fleas are important vectors of disease and transmit some of the most deadly infectious diseases ever known (Table 9-4).

**TABLE 9-4**  
**FLEAS AS VECTORS OF HUMAN INFECTIOUS DISEASES**

Table 9-4 is not shown because the copyright permission granted to the Borden Institute, TMM, does not allow the Borden Institute to grant permission to other users and/or does not include usage in electronic media. The current user must apply to the publisher named in the figure legend for permission to use this illustration in any type of publication media.

\*Fleas are definite vectors.

†Fleas are possible vectors.

‡Ticks are usual vectors, but the infectious organism has been isolated from fleas.

Adapted with permission from Alexander JO. *Arthropods and Human Skin*. Berlin, Germany: Springer-Verlag; 1984: 159.

## Plague

Plague is a zoonotic disease caused by *Yersinia pestis* and usually transmitted to humans by rodents and their fleas. The condition is characterized by a bubo, a mass of lymph nodes that become matted together and drain purulent material. A detailed discussion of plague can be found in Chapter 13, Bacterial Skin Diseases.

## Flea Bites

Flea bites are the most common arthropod bites known. One flea can bite two to three times over a small area. It is not uncommon to see three flea bites in a row, described as breakfast, lunch, and dinner (Figure 9-6).<sup>25</sup> The bites produce irregular, pruritic, red wheals up to 1 cm in diameter. Some patients may present with a surrounding halo with a central papule, vesicle, or bulla. Others react by forming hemorrhagic macules, papules, vesicles, or bulla. In individuals immune to flea bites, an evanescent erythema with a central hemorrhagic punctum appears. A purpuric halo that persists for 3 to 4 days has also been observed. The lesions usually subside within 2 to 3 days. Bites usually are seen at points of access, such as the ankles or wrist; however, the first meal may occur at any site. The scalp and face are rarely affected.<sup>23</sup> Treatment is usually supportive with mild to moderate topical steroids.

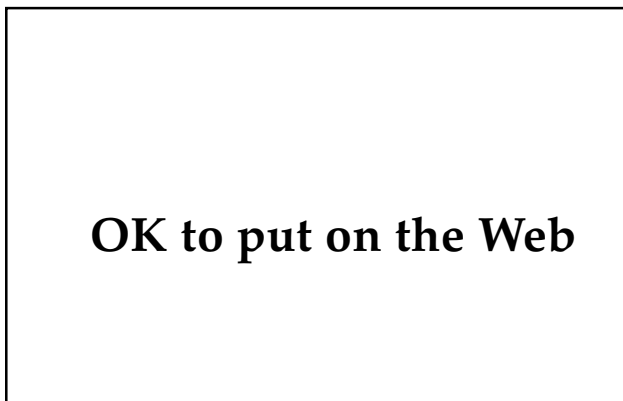
## Papular Urticaria

Chronic reinfestation by fleas may result in urticarial lesions that appear in irregular crops; these lesions are frequently observed on the limbs and

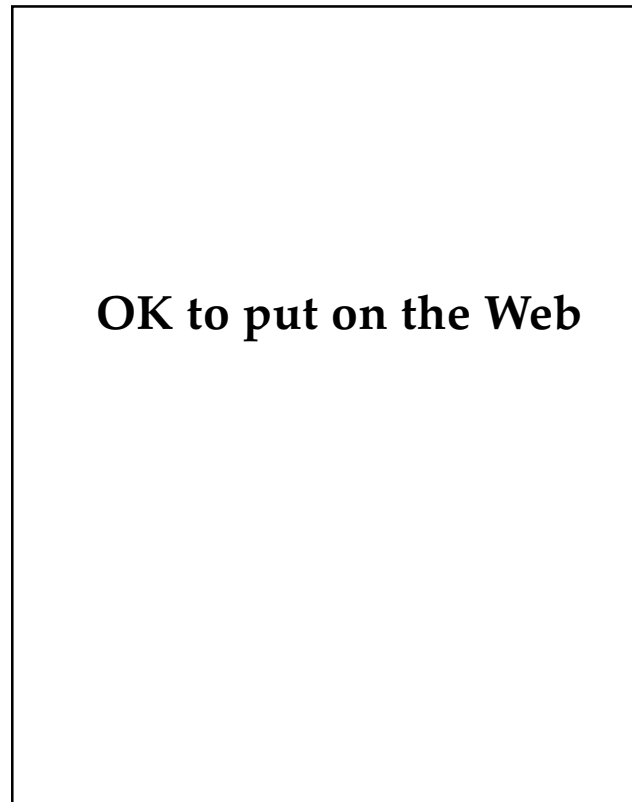
around the waist. They have also been reported to involve the trunk, buttocks, neck, hands, and feet.<sup>23</sup> The distribution is characteristically bizarre, with lesions exhibiting two features: (1) new lesions appear in small groups, all in the same stage as earlier lesions, and (2) new lesions tend to cluster around the waistline, where tight clothing prevents further flea migration (Figure 9-7).<sup>23</sup> Postinflammatory changes and scarring from scratching are not uncommon. Papular urticaria has also been reported<sup>23</sup> to result from the bites of other arthropods, such as mites. Treatment involves removing the soldier from the infested area. In cases of severe pruritus, systemic steroids may be required.

## Tungiasis

*Tunga penetrans*, also called sand flea, chigoe, and jigger flea, is the only member of the family Tungidae known to attack humans.<sup>26</sup> Tungiasis originated in Central and South America and was reported to infest sailors from Columbus' voyage in 1492.<sup>23</sup> It spread to Africa, where it was first recorded in



**Fig. 9-6.** These lesions resulted from flea bites. They display the characteristic “breakfast, lunch, and dinner” pattern.



**Fig. 9-7.** Papular urticaria secondary to flea bites. These lesions tend to cluster around the waistline.

1634.<sup>23</sup> A major outbreak occurred in Brazil in 1872, and tungiasis was shortly thereafter introduced into Angola. It has been reported in Central and East Africa, Madagascar, the west coast of Pakistan, and India.<sup>27</sup>

Tungiasis is caused by the female sand flea, which burrows into human skin at the point of contact, usually the feet. The larva, adult males, and virgin females live in dry, sandy soil around pigsties, poultry runs, and stables, where they feed on vegetable matter. The sand flea is the smallest known flea (1 mm long) and has a 3- to 4-week life cycle. The male dies shortly after copulation. The gravid female jumps, reaching heights of 35 cm, in an attempt to find a suitable host. On contact with human or animal skin, the flea penetrates with its pointed head and burrows into the skin. The female enlarges to the size of a pea over a 7- to 14-day period. After discharging up to 300 eggs through the skin's surface, the female flea collapses and dies.<sup>23,26</sup>

Tremendous flea burdens can incapacitate an individual by causing pain and superinfection. Individual lesions consist of a firm, indurated, slightly tender nodule with a flat surface of whitish-yellow keratin (Figure 9-8). A minute black spot in the center (the posterior end of the flea abdomen) may be noted. Secondary infections may result in adenopathy, cellulitis, and erysipelas. Thrombo-phlebitis, bone necrosis, and autoamputation of toes have been reported.<sup>23</sup> Tetanus and gas gangrene are also potentially life-threatening complications.

Treatment of tungiasis involves surgical removal of the parasites. During the first 48 hours after the female imbeds herself, a sterile needle may be sufficient. Curettage and cautery frequently works for intermediate stages of development. However, the entire flea that has been in place for 7 to 14 days should be surgically removed. Antibiotic treatment may be required for secondary infections.<sup>23</sup>

Figure 9-8 is not shown because the copyright permission granted to the Borden Institute, TMM, does not allow the Borden Institute to grant permission to other users and/or does not include usage in electronic media. The current user must apply to the publisher named in the figure legend for permission to use this illustration in any type of publication media.

**Fig. 9-8.** Primary cutaneous lesion caused by *Tunga penetrans*. Note the white circular area with central black dot. Reprinted with permission from Zalar GL, Walther RR. Infestation by *Tunga penetrans*. *Arch Dermatol*. 1980;116:81. Copyright 1980, American Medical Association.

In areas where tungiasis is endemic, use of good protective footwear should be encouraged, and for the soldier in the field, boots are adequate. Individual cutaneous inspections should be encouraged. Known infested sites should be treated with lindane, dimethyl phthalate, or dimethyl carbamate. Use of flypaper low to the ground to collect jumping fleas is another measure that may help to curb disease, and also is a good test for determining the effectiveness of the insecticide being used.<sup>23</sup>

## OTHER INSECTS

### Lice

Pediculosis, or lice infestation, is caused by three types of lice: *Pediculus humanus capitis* (head louse), *Pthirus pubis* (pubic or crab louse), and *Pediculus humanus corporis* (body louse). After attaching to the skin, these flattened, wingless insects feed on human blood and can cause intense itching. For a detailed discussion of pediculosis, see Chapter 8, Arthropod and Other Animal Bites.

### Bedbugs

Members of the insect order Hemiptera include bedbugs, which are vectors for the transmission of *Trypanosoma cruzi*, the infective agent for Chagas' disease (also called South American trypanosomiasis), which is discussed in Chapter 12, Tropical Parasitic Infections.<sup>28</sup> Its best-known vectors are the assassin bugs, family Reduviidae, including *Rhodnius prolixus* (northeastern South America) and

*R. pallescens* (Brazil and Panama). Other Hemiptera, such as *Triatoma infestans* (Argentina and Brazil), *T. barberi* (Mexico), *T. dimidiata* (Mexico, Ecuador, and Central America), *T. maculata* (Venezuela), and *Panstrongylus megistus* (Brazil and Guyana) are also important vectors of Chagas' disease.<sup>29</sup>

### Biting Flies

Infectious diseases may also be transmitted to humans by dipterous insects, which include biting flies and mosquitoes. A detailed list of mosquitoes as vectors of viral diseases is provided in Chapter 10, Viral Hemorrhagic Fevers. Myiasis (infestation with fly maggots) is discussed in Chapter 8, Arthropod and Other Animal Bites.

Bartonellosis (Carrion's disease), with its two clinical forms, Oroya fever and verruga peruana, is transmitted by sandflies, *Lutzomyia verrucarum* and *L. colombiana* (Figure 9-9). The bacterial agent is *Bartonella bacilliformis*, which is restricted to endemic areas.<sup>26</sup> Both visceral (kala azar) and dermal leishmaniasis are transmitted to humans by sandflies, *Phlebotomus* species (Old World) and *Lutzomyia* species (New World). Leishmania organisms are flagellate protozoa in the genus *Leishmania* and are composed of two visceral forms (*Leishmania donovani* and *L. infantum*) and three cutaneous forms (*L. tropica*, *L. braziliensis*, and *L. mexicana*).<sup>30</sup>

The large collection of flies in the family Tabanidae contains over 3,000 species.<sup>29</sup> They are blood-sucking flies and include horseflies, deerflies, clegs, breeze flies, greenheads, and mango flies.<sup>25</sup> Taban-

Organisms from the arthropod classes Arachnida and Insecta have a hard-jointed exoskeleton and paired, jointed legs. In most instances, arthropod bites are nothing more than a nuisance, resulting in localized, cutaneous reactions and pruritus. However, some of these organisms are medically important: fleas, lice, and ticks can transmit lethal epidemic disorders, such as bubonic plague, typhus, Crimean-Congo hemorrhagic fever, Rocky Mountain spotted fever, and boutonneuse fever.

Many of these vector-transmitted diseases are endemic in various regions of the world. Medical officers need to know which of these ancient afflictions are endemic to the region and treat infected troops appropriately. Medical officers also need to

## OK to put on the Web

Fig. 9-9. The sandfly is capable of transmitting bartonellosis as well as dermal and visceral leishmaniasis.

idae are important vectors for the spread of the microfilaria *Loa loa* (loiasis) in Africa, and the bacterial pathogens of anthrax (*Bacillus anthracis*) and tularemia (*Francisella tularensis*) in the United States.<sup>25,4</sup> They are also important vectors for the spread of animal trypanosomiasis worldwide. Glossinidae are composed of 22 species of the tsetse fly, which is well known for transmission of African trypanosomiasis.

### SUMMARY

be aware of other medical complications of arthropod bites, such as tick-bite alopecia and tick paralysis. Tick paralysis may be particularly challenging, and when progressive, lower-extremity weakness is present, a vigorous search should be undertaken to find and remove the tick. This simple procedure can be lifesaving.

In a fast-moving wartime environment, regional control with pesticides is unlikely to control insect vectors. It is thus up to the individual soldier to minimize exposure. Reducing exposure can be accomplished through repeated use of permethrin-based repellents or diethyltoluamide (DEET) applied to clothing or the skin. In addition, permethrin-impregnated uniforms are even more effective than DEET applications to skin or uniforms. Therefore,

uniform impregnation with permethrin-based repellents should be strongly considered in field environments where the risk of vector-transmitted diseases is high.

#### REFERENCES

1. Harwood RF, James MT, eds. Introduction. In: *Entomology in Human and Animal Health*. 7th ed. New York, NY: Macmillan Publishing Co; 1979:1–14.
2. Bean WB. Walter Reed and yellow fever. *JAMA*. 1983;250:659–662.
3. Alexander JO. The effects of tick bites. In: *Arthropods and Human Skin*. Berlin, Germany: Springer-Verlag; 1984: 363–382.
4. Harwood RF, James MT, eds. Horse flies, deer flies, and snipe flies. In: *Entomology in Human and Animal Health*. 7th ed. New York, NY: Macmillan Publishing Co; 1979: 234–247.
5. Alexander JO, ed. Infestation with gamasid mites. In: *Arthropods and Human Skin*. Berlin, Germany: Springer-Verlag; 1984: 303–315.
6. Harkess JR. Ehrlichiosis. *Infect Dis Clinics N Am*. 1991;5:37–51.
7. Tibbals J, Cooper SJ. Paralysis with *Ixodes cornatus* envenomation. *Med J Aust*. 1986;145:37–38.
8. Evans SR, Korch GW Jr, Lawson MA. Comparative field evaluation of permethrin and DEET-treated military uniforms for personal protection against ticks (Acari). *J Med Entomol*. 1990;27:829–834.
9. Abele DC, Anders KH. The many faces and phases of borreliosis. Part 1: Lyme disease. *J Am Acad Dermatol*. 1990;23:167–186.
10. Horton JM, Blaser MJ. The spectrum of relapsing fever in the Rocky Mountains. *Arch Intern Med*. 1985;145:871–875.
11. Harwood RF, James MT, eds. Ticks and tick-associated diseases. In: *Entomology in Human and Animal Health*. 7th ed. New York, NY: Macmillan Publishing Co; 1979: 371–416.
12. Gear JH, Wagner JM, Dyssel JC, et al. Severe tick-bite fever in young children. A report of 3 cases. *S Afr Med J*. 1990;77:84–87.
13. Huxsoll DL, Hildebrandt PK, Nims RM, et al. Tropical canine pancytopenia. *J Am Vet Med Assoc*. 1970;157:1627–1632.
14. Maeda K, Markowitz N, Hawley RC, et al. Human infection with *Ehrlichia canis*. *N Engl J Med*. 1987;316:853–856.
15. Harkess JR, Ewing SA, Brumit T, Mettry CR. Ehrlichiosis in children. *Pediatrics*. 1991;87:199–203.
16. Bancroft J. Queensland ticks and tick blindness. *Aust Med Gaz*. 1984;4:37–38.
17. Kincaid JC. Tick bite paralysis. *Seminars Neurol*. 1990;10:32–4.
18. Ross MS, Friede H. Alopecia due to tick bite. *Arch Dermatol*. 1955;71:524–525.
19. Marshall J. Ticks and the human skin. *Dermatologica*. 1967;135:60–65.
20. Heyl T. Tick bite alopecia. *Clin Exp Dermatol*. 1982;7:537–542.
21. Piesman J, Mathier TN, Sinsky RJ, et al. Duration of tick attachment and *Borrelia burgdorferi* transmission. *J Clin Microbiol*. 1987;25:557–558.

22. Duplaix N. Fleas, the lethal leapers. *National Geographic*. 1988;173:672–694.
23. Alexander JO. Flea bites and other diseases caused by fleas. In: *Arthropods and Human Skin*. Berlin, Germany: Springer-Verlag; 1984: 159–176.
24. Harwood RF, James MT, eds. Fleas. In: *Entomology in Human and Animal Health*. 7th ed. New York, NY: Macmillan Publishing Co; 1979: 319–341.
25. Rees RS, King LE. Arthropod bites and stings. In: Fitzpatrick TB, Wisen AZ, Wolff D, Freedberg IM, Austen KF, eds. *Dermatology in General Medicine*. 3rd ed. New York, NY: McGraw-Hill; 1987: 2495–2506.
26. Fimiani M, Reimann R, Alessandrini C, Miracco C. Ultrastructural findings in tungiasis. *Int J Dermatol*. 1990;29:220–222.
27. Hoeppli R. Early references to the occurrence of *Tunga penetrans* in tropical Africa. *Acta Trop* (Basel). 1963;20:143–153.
28. Alexander JO. Infestation by Hemiptera. In: *Arthropods and Human Skin*. Berlin, Germany: Springer-Verlag; 1984: 57–74.
29. Alexander JO. Reactions to dipterous biting flies. In: *Arthropods and Human Skin*. Berlin, Germany: Springer-Verlag; 1984: 115–133.
30. Harwood RF, James MT, eds. Gnats, black flies, and related forms. In: *Entomology in Human and Animal Health*. 7th ed. New York, NY: Macmillan Publishing Co; 1979: 142–168.



# Chapter 10

## VIRAL HEMORRHAGIC FEVERS

CURT P. SAMLASKA, M.D.\*

---

### INTRODUCTION

#### HEMORRHAGIC FEVERS CAUSED BY FLAVIVIRIDAE

- Dengue Hemorrhagic Fever
- Yellow Fever
- Kyasanur Forest Disease
- Omsk Hemorrhagic Fever

#### HEMORRHAGIC FEVERS CAUSED BY BUNYAVIRIDAE

- Rift Valley Fever
- Crimean-Congo Hemorrhagic Fever
- Hemorrhagic Fever with Renal Syndrome

#### HEMORRHAGIC FEVERS CAUSED BY ARENAVIRIDAE

- Lassa Fever
- Argentine Hemorrhagic Fever
- Bolivian Hemorrhagic Fever

#### HEMORRHAGIC FEVERS CAUSED BY FILOVIRIDAE

- Ebola Hemorrhagic Fever
- Marburg Hemorrhagic Fever

### SUPPORTIVE TREATMENT

### PREVENTION

### SUMMARY

\*Lieutenant Colonel, Medical Corps, U.S. Army; Dermatology Service, Tripler Army Medical Center, Honolulu, Hawaii 96859

## INTRODUCTION

The United States' involvement in Operations Desert Storm and Desert Shield (1990–1991) emphasizes the need for our armed forces to be ready for worldwide deployment at a moment's notice. This requirement often arouses much trepidation in military medical personnel who suddenly find themselves in a hostile environment that demands expertise in areas of medicine that are little known to most practicing physicians. Unlike trauma and surgical support of war wounds, which changes little from region to region, the general medical officer will need to know the infectious and parasitic diseases endemic in the region of conflict. Few of these diseases will be more challenging and potentially more lethal than the hemorrhagic fever viruses.

Hemorrhagic fever viruses are a diverse group of infections in which a hemorrhagic diathesis can result in significant morbidity and mortality. Most hemorrhagic fevers are zoonoses, with transmission to humans occurring through mosquito or tick

vectors or through aerosol from infected rodent hosts (Table 10-1). Twelve distinct viral groups are associated with hemorrhagic fevers in humans and are found in both temperate and tropical habitats.<sup>1</sup> These viruses belong to four families: Flaviviridae, Bunyaviridae, Arenaviridae, and Filoviridae.

The viral hemorrhagic fevers within each family generally have similar epidemiological traits; however, the viruses are individually diverse and can be grouped by other shared characteristics. For example, the African viral hemorrhagic fevers occur mostly in southern Africa and consist of Rift Valley fever, Marburg virus disease, and Crimean-Congo hemorrhagic fever.<sup>2</sup> Ebola hemorrhagic fever is not included with the African viral hemorrhagic fevers because it has not been isolated in southern Africa. Significant outbreaks of hemorrhagic disease with person-to-person transmission have been associated with Lassa, Marburg, Ebola, and Crimean-Congo viral disease.<sup>3</sup> This chapter will address the hemorrhagic fevers by viral family.

### HEMORRHAGIC FEVERS CAUSED BY FLAVIVIRIDAE

Flaviviruses are transmitted by mosquitoes or ticks. They can infect a multitude of vertebrate hosts and cause primarily encephalitis and hemorrhagic fevers.<sup>4</sup> Hemorrhagic fevers caused by Flaviviridae include dengue hemorrhagic fever, yellow fever, Kyasanur Forest disease, and Omsk hemorrhagic fever.

#### Dengue Hemorrhagic Fever

Epidemic illnesses that clinically resemble dengue have been reported in tropical and subtropical areas of the world since the 17th century.<sup>5</sup> In 1635, a disease was described in the West Indies that may have been dengue. Numerous outbreaks during the 18th and 19th centuries were described in Java, Egypt, India, Spain, Caribbean Islands, Americas, Indochina, and Southeast Asia.<sup>6</sup> In 1906, Bancroft<sup>7</sup> suggested that transmission to man may be through mosquito vectors. This hypothesis was conclusively shown by Cleland et al<sup>7</sup> in 1916 and 1919 in *Aedes aegypti*. Other vectors include *A albopictus* and *Culex fatigans*.<sup>8</sup> Dengue, endemic to some areas in the Pacific during World War II, was known to be a major threat to nonindigenous troops.<sup>7</sup> In 1944, for example, 24,079

cases were reported among U.S. troops in New Guinea and 20,000 cases were reported among military personnel on Saipan.<sup>5</sup> Transportation of men and supplies throughout the Pacific resulted in outbreaks in Japan, Hawaii, Australia, and many other Pacific islands. During the Vietnam conflict, dengue was reported in Burma, Cambodia, Vietnam, the Philippines, Indonesia, and India.<sup>5</sup>

Synonyms for dengue include dengue fever, break-bone fever, dandy fever, dengue, bouquet fever, giraffe fever, polka fever, 5-day fever, 7-day fever, hemorrhagic dengue (dengue hemorrhagic fever), and dengue shock syndrome (in the Philippines and Thailand).<sup>6</sup> Dengue hemorrhagic fever is actually a more severe form of dengue with hemorrhagic manifestations. The first reported outbreaks of dengue hemorrhagic fever were observed in the Philippines in 1953 and 1956.<sup>1</sup> The disease is strongly associated with urban environments and breeding of *A aegypti* vectors in domestic water containers. Dengue hemorrhagic fever has developed into a major pediatric disease in Southeast Asia and the Western Pacific, with over 600,000 hospital admissions and over 20,000 deaths in these regions over the past 20 years.<sup>1</sup> An outbreak in Cuba in 1981

**TABLE 10-1**  
**HEMORRHAGIC FEVER VIRUSES ASSOCIATED WITH HUMAN DISEASE**

---

Table 10-1 is not shown because the copyright permission granted to the Borden Institute, TMM, does not allow the Borden Institute to grant permission to other users and/or does not include usage in electronic media. The current user must apply to the publisher named in the figure legend for permission to use this illustration in any type of publication media.

---

\*High viral antibody titers; viral isolation yet to be achieved  
Adapted with permission from Samlaska CP. Arthropod-borne virus infections and virus hemorrhagic fevers. In: Demis, DJ, ed. *Clinical Dermatology*. New York, NY: JB Lippincott; 1991: Unit 14-22; 6.

resulted in over 340,000 cases and 156 deaths, the first outbreak in the Americas of the disease in its hemorrhagic form. Recent epidemics have occurred in China in 1978, 1980, and 1986, with hemorrhagic disease involving both children and adults.<sup>8</sup> All four serotypes are associated with disease; however, they are not cross-protective. Some authors<sup>9</sup> believe that subsequent infection with a heterologous dengue virus results in a much greater risk of developing life-threatening dengue hemorrhagic fever. Humans are considered to be the main reservoir for the virus.

### Signs and Symptoms

Classic dengue begins abruptly after an incubation period of 5 to 6 days. Fever may be of the "saddleback" type, in which remission of all symptoms occurs after 2 to 3 days, followed by a second phase of mild fever and less severe symptoms lasting 1 to 2 days. The single-phase type is more commonly observed in epidemics, with fevers lasting for 3 to 8 days, accompanied by dizziness, headache, back pain, arthralgias, weakness, and eye pain. Flushing of the face and conjunctival injection are common features. An enanthem consisting of tiny glistening vesicles on the soft palate may be seen within 12 hours of onset. Dengue can occur with no obvious exanthem. More often, a morbilliform eruption begins on the third to fifth day on the inner surfaces of the upper arms, the lateral surface of the thorax, and in the lumbar area. The macular or scarlatiniform rash spreads to the face, neck, shoulders, and thorax (Figure 10-1). Pruritus can occur if the hands and feet are involved. In some cases, a petechial eruption is noted on the dorsa of the feet, legs, hands, and wrists. Cervical lymphadenopathy is frequently observed. Bradycardia may occur late in the illness and persist through convalescence. Recovery often requires 1 to 2 weeks and almost invariably is dominated by neurasthenia, mental depression, insomnia, and anorexia.

Hemorrhagic manifestations of dengue are seen predominantly in children. The symptoms are variable and include petechiae, purpura, oozing from venipuncture and injection sites, gingival bleeding, epistaxis, hemoptysis, hematemesis, melena, hematochezia, hematuria, uterine bleeding, and intracranial hemorrhage.<sup>8</sup> Shock can occur after several days of symptoms and is characterized by clinical and laboratory signs of hypovolemia. Hemorrhagic manifestations have been reported with all four serotypes.

## OK to put on the Web

**Fig. 10-1.** Scarlatiniform eruption of dengue fever. Note the "white islands within a sea of red," a classic description for the cutaneous findings of dengue fever. Photograph: Courtesy of Thomas P. Monath, M.D.; formerly, Walter Reed Army Institute of Research, Washington, D.C.

### Laboratory Findings and Treatment

Laboratory features of dengue include leukocytosis, atypical lymphocytes, and thrombocytopenia.<sup>10</sup> Dengue virus inhibits marrow proliferation early in the course of disease but not in later stages. Although laboratory evidence of disseminated intravascular coagulation can be detected in severe cases of dengue hemorrhagic fever, morphologic evidence is usually found only in adolescents and adults.<sup>10</sup> Coagulation defects include prolongations of the partial thromboplastin time, prothrombin time, and thrombin time, as well as decreased factors II, V, VII, VIII, IX, and X. Disseminated intravascular coagulation is not central to the pathogenesis of dengue hemorrhagic fever, because treatment with heparin has not proved successful.

Treatment of dengue hemorrhagic fever is supportive. Live attenuated vaccines are currently being developed. The need for vaccination against all four known serotypes of dengue virus is dependent on the relative risk of developing hemorrhagic disease during subsequent infections with a different serotype.<sup>9</sup>

### Yellow Fever

Military medicine has provided significant contributions to science and the understanding of human disease. One of the most significant of these contributions came from U.S. Army Major Walter Reed and his studies on yellow fever in the late 1800s. In 1878, Charles Finlay was the first to suggest that

yellow fever was spread by mosquito bites, particularly *A aegypti*, instead of alkaline earth.<sup>11</sup> Many physicians were skeptical, and due to the lack of well-planned experimental medicine as well as incorrect assumptions, Finlay was unable to prove the association over 20 years of work. Through well-controlled experiments, Walter Reed was able to show that

- the mosquito could pick up the “poison” from an infected victim during the first 2 to 3 days of illness,
- the mosquito had to live for at least 12 days before the disease could be transmitted to man,
- blood taken from an infected person could produce infection in normal subjects if injected into their bloodstream, and
- the offending agent was not bacterial because filtered blood failed to stop infection of injected normal subjects.

Initiation of mosquito control measures in Havana subsequently resulted in a marked reduction in the disease. For his meticulous studies and implementation of informed consent, Walter Reed is known as the founder of modern and ethical clinical experimentation.<sup>11</sup>

Although a safe and effective vaccine against yellow fever has been available for 50 years, the disease continues to occur in Africa and South America.<sup>12</sup> In the Americas, the disease remains confined to the Amazon, Orinoco, Catatumbo, Atrato, and Magdalena river basins.<sup>13</sup> The virus is sustained in *Aedes* mosquito vectors, monkeys, and marmosets. The Pan American Health Organization received reports of 2,255 cases of sylvatic yellow fever between 1965 and 1983. In Africa, yellow fever occurs sporadically in forested areas and in large outbreaks, usually in savanna regions; 2,840 cases of yellow fever were reported in Africa between 1965 and 1983. Several large epidemics have occurred in West Africa, Nigeria (1969, 1970, 1986), Gambia (1978–1979), and Burkina Faso (1983).<sup>12</sup> The true incidence of the disease is grossly underestimated, based on postmortem collections of liver samples in Brazil.<sup>6,13</sup>

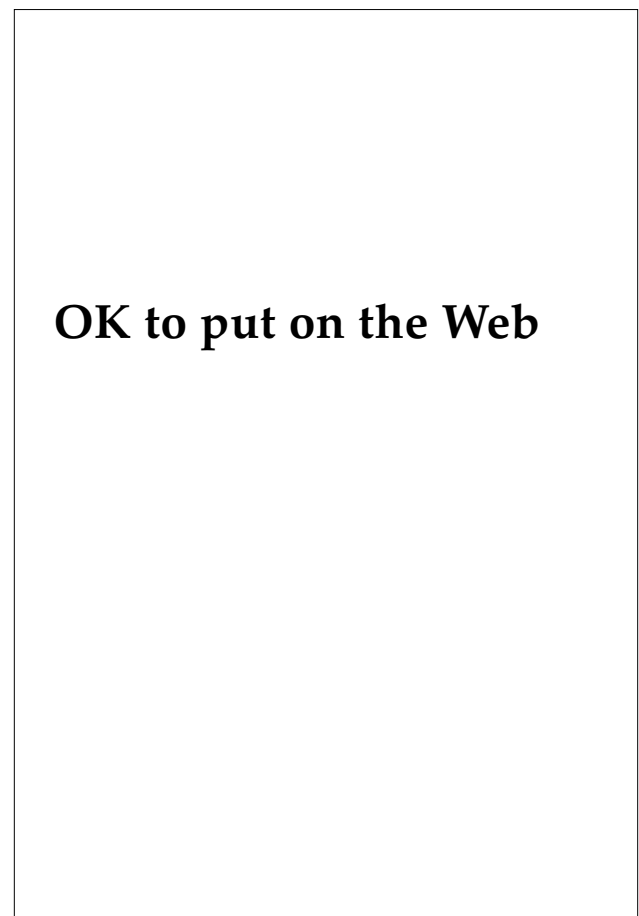
### ***Signs and Symptoms***

Yellow fever shares many of the clinical manifestations observed in other hemorrhagic fevers; however, in yellow fever, severe hepatic involvement is characteristic. Three clinical phases are found in patients with yellow fever: (1) infection, (2) remission, and (3) intoxication. Infection begins abruptly

with fever, headache, generalized malaise and weakness, lumbosacral pain, nausea, and vomiting. During the 3 days of symptoms, the virus can easily be isolated from blood. Bradycardia, called Faget’s sign when accompanied by fever, can be a significant physical finding. Remission may last as long as 24 hours, followed by intoxication, which can progress to death 7 to 10 days after presentation. Features of intoxication include jaundice and scleral icterus (Figure 10-2), as well as albuminuria, oliguria, cardiovascular instability, and hemorrhagic manifestations. Neurological features include delirium, stupor, convulsions, and coma. The case-fatality rate for severe yellow fever is 50%.<sup>13</sup>

### ***Laboratory Findings and Treatment***

Laboratory findings for yellow fever are diverse and complex, reflecting fulminant hepatitis, dis-



**Fig. 10-2.** Jaundice and scleral icterus in a patient with yellow fever. Photograph: Courtesy of Thomas P. Monath, M.D.; formerly, Walter Reed Army Institute of Research, Washington, D.C.

seminated intravascular coagulation, and renal failure. Death is usually due to refractory hypoglycemia and metabolic acidosis, although fulminant infections resulting in death within 2 to 3 days of onset have been reported. The diagnosis can be confirmed by use of an immunoglobulin (Ig) M-capture enzyme-linked immunosorbent assay (ELISA) or complement-fixation test.<sup>12</sup> The differential diagnosis of yellow fever includes other forms of hemorrhagic fever, malignant malaria, leptospirosis, and viral hepatitis. Treatment is supportive and may require intensive care.

### Kyasanur Forest Disease

Kyasanur Forest disease was first reported in 1957 as a fatal epizootic disease in monkeys in the Shimoga District, Karnataka State, India.<sup>14</sup> Although the virus has been isolated from ticks, major outbreaks of the disease are usually related to exposure to infected regions as a consequence of clearing forested areas or shipping infected monkeys.<sup>15</sup>

The incubation period for Kyasanur Forest disease is 3 to 8 days and is followed by an acute onset of fever, headache, and severe myalgias. Diarrhea and vomiting are frequently experienced by the third or fourth day. Significant early physical findings include severe prostration, conjunctival suffu-

sion, photophobia, cervical and axillary adenopathy, and, rarely, splenomegaly or hepatosplenomegaly. Papulovesicular lesions involving the soft palate are seen in most patients. Bronchiolar involvement can result in blood-tinged sputum and evidence of pneumonia. Although hemorrhagic manifestations were commonly observed in initial patients, hemorrhagic involvement in more recent cases is rarely observed. This difference has been attributed to a large number of individuals with secondary diseases, such as tuberculosis and heavy helminthic infections,<sup>15</sup> in earlier series. In addition, although neurological manifestations were initially thought to be rare, more recently documented infections show clear evidence of neurological involvement. The mortality rate is 5% to 10%. An ELISA has been developed for Kyasanur Forest disease virus.<sup>16</sup> Treatment is supportive.

### Omsk Hemorrhagic Fever

Omsk hemorrhagic fever was first reported to infect muskrat trappers and skimmers in the Asian portions of the Soviet Union during the 1940s and 1950s.<sup>1</sup> Aerosol transmission and ticks have been implicated in its spread. The virus has virtually disappeared and little is known about its current reservoir status.

## HEMORRHAGIC FEVERS CAUSED BY BUNYAVIRIDAE

Bunyaviridae is a family of arthropod-borne viruses composed of five genera: *Phlebovirus* (eg, Rift Valley fever), *Nairovirus* (eg, Crimean-Congo hemorrhagic fever), *Hantavirus* (eg, hemorrhagic fever with renal syndrome), *Uukuvirus*, and *Bunyavirus*.<sup>4</sup> Bunyaviruses share several basic characteristics with arenaviruses, such as having similar replication cycles. Bunyaviridae and Arenaviridae are not as well studied as viruses in other families.<sup>17</sup>

### Rift Valley Fever

The first reported outbreaks of Rift Valley fever occurred in 1951 in South Africa when three veterinarians and two residents became ill after postmortem examination of a berserk bull that suddenly died. The virus has subsequently been isolated from cattle, sheep, and antelope. Epidemics are associated with these animal reservoirs and mosquito vectors, most commonly *Aedes caballus* and *Culex theileri*. Rift Valley fever virus can be maintained by mosquitoes alone through transovarial

transmission.<sup>1</sup> Numerous cases have been associated with handling carcasses, meat, and internal organs of infected animals.<sup>1,18</sup> Recent epidemics include the 1987 outbreak in Mauritania and the 1977 outbreak in Egypt.<sup>18</sup> Currently, three antigenic strains of Rift Valley fever virus have been identified.

### Signs and Symptoms

The initial clinical manifestation of Rift Valley fever is a biphasic fever, the first bout lasting 4 days. After 1 or 2 days of normal temperatures, the second fever spike occurs, lasting 2 to 4 days. The most common complication of Rift Valley fever (10% of patients) is retinitis characterized by macular cotton-wool exudates, which can permanently impair vision if bilateral involvement is present. Hemorrhagic features occur toward the end of the first week of illness, manifested by epistaxis, hematemesis, and/or melena. Massive gastrointestinal hemorrhage due to acute hepatic necrosis is often

fatal. Additional clinical features include jaundice, encephalitis, and disseminated intravascular coagulation. Rift Valley fever virus has been associated with spontaneous abortions in ewes and may be associated with human abortions and congenital malformations.<sup>19</sup>

### **Laboratory Findings and Treatment**

The laboratory features of Rift Valley fever are similar to those found in other hemorrhagic fevers and depend on the severity of disease. Although an IgM-capture ELISA is available for Rift Valley fever virus, the assay has a low sensitivity, reported at 26%.<sup>20</sup> Inoculation of sera into *Aedes pseudoscutellaris* cells is the most sensitive method of confirming the disease. Inoculation intracerebrally into suckling mice and detection of type IgM gamma globulins can also be used.

Interferon<sup>21</sup> and ribavirin (2 g intravenous [IV] loading dose, followed by 1 g every 6 h for 4 d, then 0.5 g every 8 h for an additional 6 d)<sup>22</sup> have been shown in animal models to be effective therapeutic agents. A live attenuated vaccine is available; however, it should be used with caution in women of childbearing age due to the reported association with microcephaly and hydrops amnii.<sup>19</sup>

### **Crimean-Congo Hemorrhagic Fever**

The first reported cases of Crimean-Congo hemorrhagic fever occurred in 1944 on the Crimean peninsula.<sup>3</sup> It has become a prominent pathogen in Europe, Asia, and Africa.<sup>23</sup> The tick vectors are species of *Hyalomma*. Natural reservoirs are currently unknown.

### **Signs and Symptoms**

The incubation period of Crimean-Congo hemorrhagic fever is 2 to 7 days.<sup>2</sup> Clinical features include an abrupt onset with violent headaches, lumbosacral muscle spasms, dizziness, sore eyes, photophobia, fever, rigors, chills, leg pains, nausea, vomiting, sore throat, abdominal pain, and diarrhea. Patients often have injected and flushed conjunctiva or chemosis. Half the patients will have hepatomegaly. A petechial eruption is common.<sup>3</sup> In severe cases, a hemorrhagic diathesis develops by the third to fifth day, manifested by petechiae, purpura (Figure 10-3), epistaxis, hemoptysis, hematemesis, melena, and hematuria. The disease can progress to hepatorenal failure, resulting in jaundice, mental obtundation, stupor and eventual

## **OK to put on the Web**

**Fig. 10-3.** Crimean-Congo hemorrhagic fever with purpura involving the axillae and arms. Photograph: Courtesy of David I. H. Simpson, Department of Microbiology and Immunobiology, The Queen's University of Belfast.

coma, and death. The mortality rate is reported to range from 15% to 70%.<sup>3</sup>

### **Laboratory Findings and Treatment**

Laboratory data reflect the degree of hepatorenal dysfunction and coagulopathy caused by the disease. Leukopenia, thrombocytopenia, and raised serum transaminases are usually present. Disseminated intravascular coagulation is an early and prominent feature of Crimean-Congo hemorrhagic fever. The diagnosis can be confirmed by injecting serum intracerebrally into day-old mice for virus isolation, ELISA (the most sensitive), indirect immunofluorescence tests, and complement-fixation tests.

Treatment is usually supportive. Ribavirin (2 g IV loading dose, followed by 1 g every 6 h for 4 d, then 0.5 g every 8 h for an additional 6 d) may have clinical utility.<sup>22</sup>

### **Hemorrhagic Fever with Renal Syndrome**

Synonyms for hemorrhagic fever with renal syndrome include Korean hemorrhagic fever, Far Eastern hemorrhagic fever, epidemic hemorrhagic fever, hemorrhagic nephrosonephritis, Songo fever, epidemic nephritis, and neuropathia epidemica. Korean hemorrhagic fever was first appreciated in 1951 during the Korean conflict, when United Nations troops were afflicted with a hemorrhagic disorder previously unknown to Western medicine.<sup>24,25</sup> By 1954, more than 3,200 cases were confirmed,

with 480 deaths. The disease may have existed in Asia for at least 1,000 years, documented in a Chinese medical book written about AD 960. The pathophysiology of the disease was little known until 1976, when culturing of the prototype Hantaan virus resulted in the development of an immunofluorescent antibody assay for serologic diagnosis.<sup>24</sup> The subsequent 14 years have resulted in an explosion of medical knowledge on Hantaan virus diseases and their epidemiology. We now know that the Hantaan virus has a worldwide distribution and is frequently found in healthy wild rodents.<sup>6</sup>

Three serotypes of Hantaan virus are associated with hemorrhagic fever with renal syndrome and can cause disease ranging from mild to severe. Transmission to man occurs through the aerosol form of urine, feces, and saliva from infected rodents.

- Hantaan virus serotype is associated with the most severe forms of hemorrhagic fever with renal syndrome and occurs in Korea, China, and southeastern Siberia.<sup>26</sup> The rodent host is the field mouse *Apodemus agrarius*. In the Far East, two peaks of human disease occur in the spring and summer.
- The Seoul serotype is associated with a less severe form of hemorrhagic fever with renal syndrome and causes urban outbreaks due to infestation of rats: *Rattus rattus* and *R norvegicus*. Rat infestation has been documented worldwide, including in the United States.
- Puumala virus infections result in the mildest form of the disease, called nephropathia epidemica.<sup>27</sup> It is most frequently docu-

mented in Europe and the western part of the former USSR. The natural host is the bank vole, *Clethrionomys glareolus*. The peak incidence of disease is in the mid-to-late summer.

Additional serotypes are being identified. Prospect Hill virus was isolated from a meadow vole on Prospect Hill in Frederick, Maryland. Another serotype called Leakey virus has been isolated from domestic mice in West Virginia. Neither virus (Prospect Hill or Leakey) has yet been proven to be associated with human disease. It should be noted that a number of human infections have occurred in Korea and Japan among personnel working in medical center animal rooms.<sup>24</sup> The potential for transmission of the disease by importing infected animals to research centers further underscores the worldwide nature of this disease.

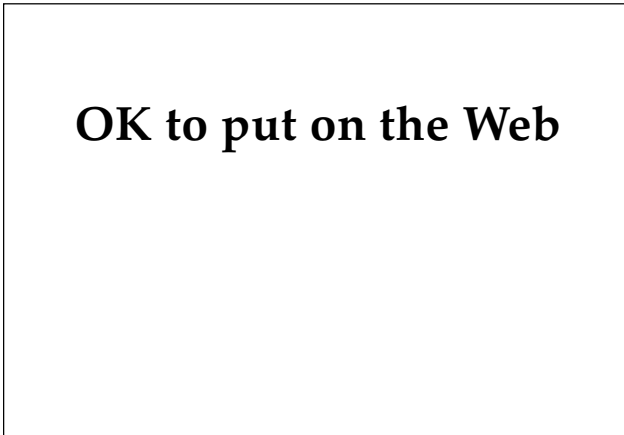
### Signs and Symptoms

In the severe forms of hemorrhagic fever with renal syndrome, five distinct clinical phases exist: (1) febrile, (2) hypotensive, (3) oliguric, (4) diuretic, and (5) convalescent. The incubation period is 2 to 3 weeks but can range from 4 to 42 days.<sup>28</sup> The febrile phase begins abruptly and lasts 3 to 7 days. Additional clinical features include chills, malaise, weakness, myalgias, anorexia, dizziness, headache, and eyeball pain. A characteristic facial flushing extending to the neck and chest is frequently observed. Conjunctival hemorrhage (Figure 10-4) and fine petechiae distributed over the axillary folds, face, neck, soft palate (Figure 10-5), and anterior



**OK to put on the Web**

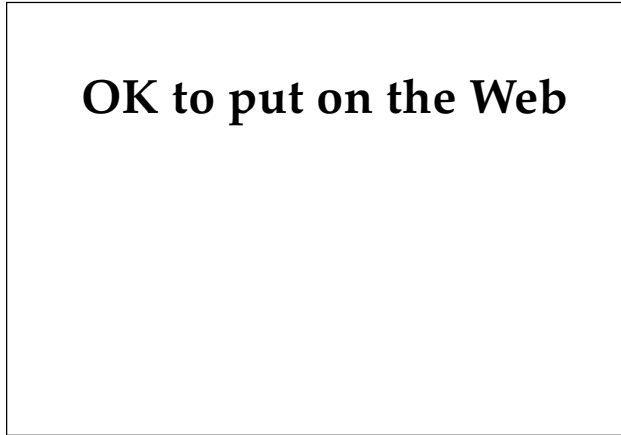**Fig. 10-4.** Conjunctival hemorrhage in a patient with hemorrhagic fever with renal syndrome.



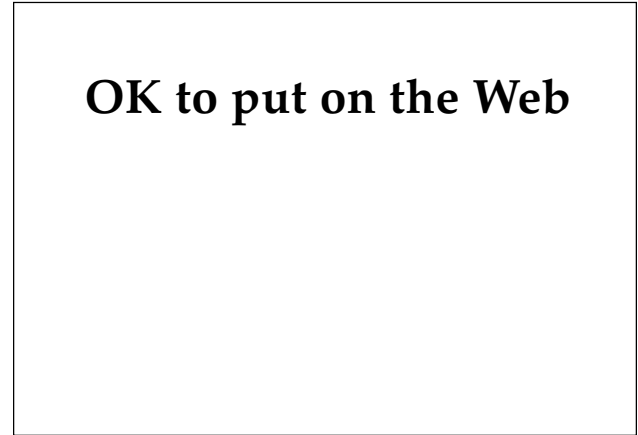**OK to put on the Web**

**Fig. 10-5.** Petechiae involving the palate in a patient with hemorrhagic fever with renal syndrome.





**Fig. 10-6.** Purpura in a patient with hemorrhagic fever with renal syndrome.



**Fig. 10-7.** Purpura involving the elbow in a patient with hemorrhagic fever with renal syndrome.

chest wall are frequently observed toward the end of this phase, as is purpura (Figures 10-6 and 10-7).

The hypotensive phase begins abruptly and can last for several hours to 2 days. Clinical manifestations include depressed sensorium, confusion, tachycardia, narrowed pulse pressure, hypotension, and cardiac arrest.<sup>24</sup> In severe disease, shock results in death in one third of the cases. In moderate disease, recovery usually occurs within 1 to 3 days.

The oliguric phase lasts from 3 to 7 days, and up to 60% of patients develop hypervolemia and hypertension. Symptoms and clinical features at this time include nausea, vomiting, epistaxis, conjunctival hemorrhage, cerebral hemorrhage, gastrointestinal hemorrhage, central nervous system symptoms (severe cases), and pulmonary edema (severe cases). Approximately 50% of the fatalities occur during the oliguric phase of the disease.

The onset of the diuretic phase is a good prognostic sign; however, recovery can be delayed because of marked dehydration, electrolyte imbalance, or secondary infections. The diuretic phase lasts for days to weeks.

Frequently, 2 to 3 months are required for the convalescent phase. This period is noted for a progressive increase in glomerular filtration rate

resulting in up to 70% return of renal function within 6 months after the onset of disease. Vertical transmission from mother to child resulting in spontaneous abortion has been reported.<sup>28</sup>

#### **Laboratory Findings and Treatment**

Laboratory abnormalities reflect the degree of renal dysfunction at each stage of the disease; thrombocytopenia, anemia, azotemia, proteinuria, hematuria, hyperkalemia, and rising creatinine are typically observed toward the end of the hypotensive phase and through most of the oliguric phase. Many types of tests are available for serologic confirmation. The most sensitive and easy to perform is the ELISA; however, it can not distinguish between the Hantaan and Seoul variants.<sup>28</sup> Plaque-reduction neutralization tests are more specific for the serotypes. The differential diagnosis includes other forms of hemorrhagic disease, leptospirosis, scrub typhus, viral hepatitis, hemorrhagic glomerulonephritis, influenza, and many other disorders that can cause thrombocytopenia and acute renal failure.<sup>28</sup> Treatment is supportive, although ribavirin (2 g IV loading dose, then 1 g every 6 h for 4 d, followed by 0.5 g every 8 h for 6 d) may have clinical utility.<sup>22</sup>

### **HEMORRHAGIC FEVERS CAUSED BY ARENAVIRIDAE**

The Arenaviridae family includes several viruses that cause often fatal hemorrhagic fevers (eg, Lassa, Argentine, and Bolivian hemorrhagic fevers).<sup>4</sup> Arenaviruses frequently use rodents as a reservoir.<sup>29</sup>

#### **Lassa Fever**

Due to the extremely contagious nature of the virus, Lassa fever has a propensity for infecting medical personnel. The first reported cases occurred in

northern Nigeria in 1969, when two of three nurses afflicted with the disease died.<sup>3</sup> Since then, numerous laboratory personnel have been infected with the Lassa virus. Naturally occurring infections resulting in nosocomial outbreaks have occurred in Nigeria, Sierra Leone, Guinea, and Liberia.<sup>30</sup> At least 10 instances of imported Lassa fever have been reported; however, none of these episodes has resulted in human disease.<sup>3</sup> The natural reservoir is the rodent *Mastomys natalensis*, and transmission to man is by aerosol.<sup>22</sup> Person-to-person transmission is important in nosocomial infections. In areas where the virus is endemic, Lassa fever occurs in higher frequency during the dry season.

### Signs and Symptoms

The clinical spectrum of disease in Lassa fever is variable, with 9% to 26% of infections resulting in illness. The incubation period is between 1 and 3 weeks. Onset is frequently insidious, with fever, sore throat, weakness, and malaise followed by low back pain, headache, and a nonproductive cough. Additional variable features include retrosternal or epigastric pain, vomiting, diarrhea, and abdominal discomfort. Physical findings include fever, exudative pharyngitis, conjunctival injection, and, rarely, jaundice, petechiae, and cutaneous eruptions. Pulmonary manifestations can be significant, resulting in rales, pleural and pericardial friction rubs, and adult respiratory distress syndrome.<sup>3</sup> In the most severe form of the disease, patients can exhibit facial and neck edema, conjunctival hemorrhages, mucosal bleeding, melena, hematochezia, hematuria, vaginal bleeding, hematemesis, central cyanosis, encephalopathy, shock, and death. Women infected during pregnancy have the highest mortality rate, 16%.<sup>30</sup> A high incidence of fetal wastage also exists, particularly if the infection occurs during the third trimester.<sup>3</sup> Recovery usually begins a week after onset and about 20% of individuals will develop sensorineural deafness. The overall case-fatality rate is 1% to 2%.<sup>3</sup>

### Laboratory Findings and Treatment

Laboratory abnormalities in Lassa fever are often nonspecific and include proteinuria, transient thrombocytopenia, and elevated transaminases, with aspartate aminotransferase values exceeding those of alanine aminotransferase. Although an IgM-capture ELISA is available for the detection of

the disease, the indirect fluorescent antibody technique is the diagnostic test of choice. The differential diagnosis includes other forms of hemorrhagic fever, typhoid fever, gastroenteritis, pneumonia, pyelonephritis, postpartum sepsis, septic abortion, encephalitis, meningitis, and hepatitis. Treatment is supportive, although ribavirin (2 g IV loading dose, then 1 g every 6 h for 4 d, followed by 0.5 g every 8 h for 6 d) has been shown to be effective treatment in animal studies if administered before the seventh day of illness.<sup>22</sup>

### Argentine Hemorrhagic Fever

Argentine hemorrhagic fever is caused by the Junin virus, a single-stranded RNA virus.<sup>31</sup> The disease is endemic in agricultural and cattle-raising areas of Argentina, with the first reported outbreaks occurring in 1955 in Bragado city. Annual epidemics occur between January and August.<sup>1</sup> The primary reservoir hosts are the rodents *Calomys laucha* and *C musculus*. Transmission to man occurs through aerosols from urine or feces. Junin virus can also infect through contact with abraded skin.<sup>31</sup>

### Signs and Symptoms

The clinical manifestations of Argentine hemorrhagic fever range from subclinical to severe. After an 8- to 12-day incubation, an abrupt onset of fevers, asthenia, dizziness, retroocular and muscular

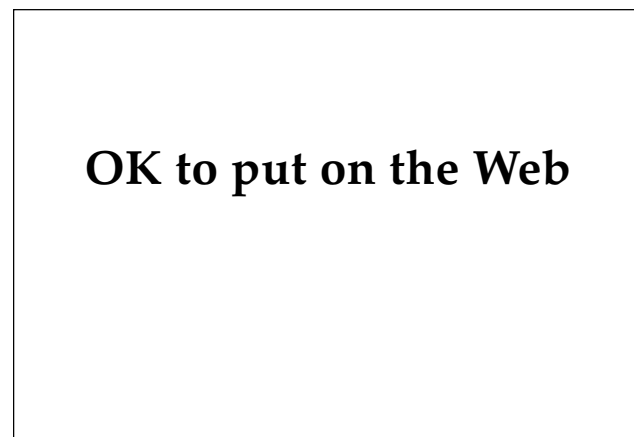

Fig. 10-8. Maculopapular eruption in a patient with Argentine hemorrhagic fever. Photograph: Courtesy of David I. H. Simpson, Department of Microbiology and Immunobiology, The Queen's University of Belfast.

## OK to put on the Web

**Fig. 10-9.** Petechiae in a patient with Argentine hemorrhagic fever. Photograph: Courtesy of David I. H. Simpson, Department of Microbiology and Immunobiology, The Queen's University of Belfast.

pain, lymphadenopathy, maculopapular eruptions, and cutaneous as well as pharyngeal petechiae takes place (Figures 10-8 and 10-9). Hemorrhagic manifestations are variable, resulting in conjunctival hemorrhage (Figure 10-10), hemorrhagic gingivitis, epistaxis, hematuria, metrorrhagia, and gastrointestinal bleeding.<sup>32</sup> In severe cases, bradycardia, hypotension, and shock can be observed. Neurological manifestations frequently occur, resulting in tremor (including of the tongue), areflexia, hyporeflexia, muscular hypotonia, ataxia, extrapyramidal signs, mental depression, and coma.<sup>32</sup> The acute phase of the illness lasts for 10 days. Approximately 10% to 16% of those infected die from their disease, usually as a result of severe central nervous system involvement.<sup>31</sup>

### Laboratory Findings and Treatment

Laboratory abnormalities of Argentine hemorrhagic fever include leukopenia, thrombocytopenia, and bone marrow suppression early in the disease. Blood coagulation studies are variable; however, no evidence of disseminated intravascular coagulation has been found.<sup>32</sup> Renal involvement results in albuminuria, hyalin and granular casts, and Milani cells. Recent studies have demonstrated that the ELISA is more specific than indirect immunofluorescence tests.<sup>33</sup>

Treatment is supportive, although infusion of antibody-rich convalescent plasma is reported to

## OK to put on the Web

**Fig. 10-10.** Conjunctival hemorrhage in a patient with Argentine hemorrhagic fever. Photograph: Courtesy of David I. H. Simpson, Department of Microbiology and Immunobiology, The Queen's University of Belfast.

decrease the mortality rate to 1% to 2%.<sup>31</sup> Animal studies suggest that ribavirin (2 g IV loading dose, then 1 g every 6 h for 4 d, followed by 0.5 g every 8 h for 6 d) may be useful in treating Argentine hemorrhagic fever.<sup>34</sup>

### Bolivian Hemorrhagic Fever

In 1959, cases resembling Argentine hemorrhagic fever were reported in Bolivia. The causative agent was determined to be the Machupo virus, and the natural reservoir the rodent host *Calomys callosus*.<sup>1</sup> Machupo virus is transmitted to man by aerosolized rodent excreta, although person-to-person transmission has been reported. The virus is restricted to Bolivia, and rodent-control measures have greatly reduced the incidence of human disease.

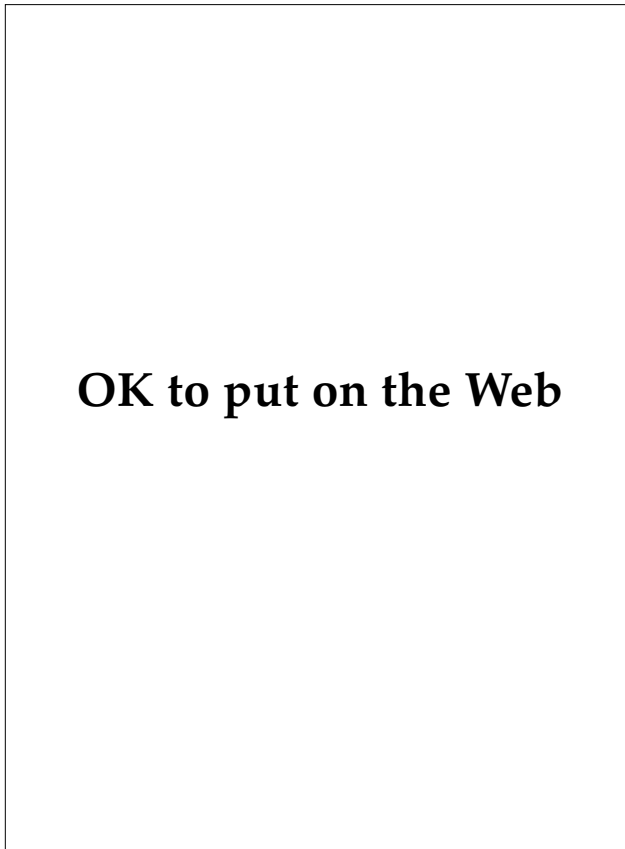
The illness, known as Bolivian hemorrhagic fever, begins with 1 or 2 days of prodromal symptoms that consist of malaise, fatigue, headaches, and myalgias.<sup>35</sup> The febrile phase lasts 7 to 10 days and is characterized by severe headaches, excruciating back pain, and diffuse joint and muscle aches. A cutaneous hyperesthesia similar to a sunburn can be observed. Additional clinical features include upper-body flushing, conjunctivitis, cardiovascular lability, periorbital edema, gastrointestinal bleeding, encephalopathy, and proteinuria. Platelet counts are frequently depressed. Treatment is usually supportive. Clinically, little has been written about Bolivian hemorrhagic fever since the early 1970s.

## HEMORRHAGIC FEVERS CAUSED BY FILOVIRIDAE

The morphologic structure of filoviruses is unique; they are the only mammalian viruses that are filamentous.<sup>36</sup> Ebola and Marburg viruses are the only members of this family and are among the most lethal of human viruses.<sup>4</sup>

### Ebola Hemorrhagic Fever

Ebola virus is a single-stranded RNA virus named after a small river in northwestern Zaire. Ebola hemorrhagic fever, also known as Yambuku hemorrhagic fever, was first identified in 1976 when two epidemics occurred in southern Sudan and northwestern Zaire.<sup>3,37</sup> In 284 cases in the Sudan epidemic, the mortality rate was 53%. In the hospital-based Zaire epidemic, 88% of 318 infected patients died (Figure 10-11). Sporadic cases have been described in



**Fig. 10-11.** Ebola infection in African patient 24 hours prior to death. Photograph: Courtesy of Thomas P. Monath, M.D.; formerly, Walter Reed Army Institute of Research, Washington, D.C.

Sudan and Zaire, and Ebola virus may also be endemic in other parts of eastern and central Africa. The mode of transmission and natural reservoir hosts are unknown, although epidemiological studies suggest that spread of the disease occurred through casual contact or aerosol transmission.<sup>3</sup>

In November 1989 at Hazleton Research Products in Reston, Virginia, 16 imported cynomolgus monkeys died from a hemorrhagic disorder.<sup>38</sup> Virological analysis resulted in the identification of a filovirus antigenically indistinct from Ebola virus. The monkeys had been imported from the Philippines, a previously unreported site for Ebola infections. This incident marked the first time a filovirus had been isolated from a nonhuman host not experimentally induced. Epidemiological analysis identified seven shipments of infected monkeys from the Philippines.<sup>39</sup> Four animal handlers were seropositive for the filovirus; however, none could identify an associated illness. Although cross-reactivity exists between this virus and Ebola, researchers at the Centers for Disease Control believe the virus is antigenically and genetically distinguishable from Ebola virus.<sup>39</sup> The lack of associated human disease suggests that this hypothesis is correct. Another possibility is that the virus is an attenuated form of Ebola; one might speculate on its possible use as a vaccine.

### *Signs and Symptoms*

The incubation period of Ebola hemorrhagic fever ranges from 2 to 21 days. The onset of disease is abrupt, with symptoms resembling influenza, including fever, headache, malaise, myalgias, joint pains, sore throat, diarrhea, and abdominal pain. A fleeting morbilliform eruption often appears within the first week of illness, followed by desquamation (Figure 10-12). Additional physical findings include pharyngitis, conjunctivitis, jaundice, and edema (Figure 10-13). Hemorrhagic manifestations can develop after the third day of illness, manifested by petechiae, ecchymosis, conjunctival hemorrhage, gingival bleeding, oropharyngeal bleeding ulcerations, vaginal bleeding, bleeding from injection sites, hematemesis, and melena.<sup>37</sup>

### *Laboratory Findings and Treatment*

Laboratory findings for Ebola virus include

## OK to put on the Web

**Fig. 10-12.** Morbilliform eruption in a patient with Ebola hemorrhagic fever. Photograph: Courtesy of Thomas P. Monath, M.D.; formerly, Walter Reed Army Institute of Research, Washington, D.C.

proteinuria and elevated transaminases, with aspartate aminotransferase values exceeding those of alanine aminotransferase.<sup>3</sup> The diagnosis is confirmed on identification of IgM or rising IgG antibodies by indirect immunofluorescence, Western blot analysis, or ELISA, or any combination of the three.

Treatment is supportive and, as with all forms of severe viral hemorrhagic disease, may require intensive care. In the hospital setting, extreme care must be provided when handling any body secretions or blood products. The patient should be isolated and strict barrier-nursing techniques should be enforced. Recent evidence in animal models suggests that ribavirin (2 g IV loading dose, then 1 g every 6 h for 4 d, followed by 0.5 g every 8 h for 6 d) may have clinical utility in treating the disorder.<sup>3</sup>

### Marburg Hemorrhagic Fever

Marburg is a single-stranded RNA virus that is morphologically similar to Ebola virus but is antigenically distinct. The virus is named after a small German town where the first cases were described, but the virus is found in nature in Zimbabwe, Kenya, and South Africa.<sup>3</sup> In Europe in 1967, 25 people became acutely ill after handling material from African green monkeys imported from Uganda. An Australian traveler died from Marburg hemorrhagic fever in 1975 after exposure in South Africa; two other patients survived. A third outbreak occurred in Kenya in 1980, resulting in one fatality and one survivor. Another isolated case occurred in South Africa in 1982. The most recent episode was re-

## OK to put on the Web

**Fig. 10-13.** Jaundice in a patient Ebola hemorrhagic fever. Photograph: Courtesy of Thomas P. Monath, M.D.; formerly, Walter Reed Army Institute of Research, Washington, D.C.

ported in Kenya in 1987 and resulted in the death of a boy. The mode of primary transmission is unknown. Secondary spread of disease can occur through close contact with infected persons including sexual transmission.<sup>3</sup>

The incubation period of Marburg hemorrhagic fever ranges from 3 to 10 days. The clinical and laboratory features are indistinguishable from those of Ebola hemorrhagic fever (Figure 10-14). The diagnosis is confirmed by detecting IgG or IgM antibodies to Marburg hemorrhagic fever antigens by indirect immunofluorescence. Treatment is the same as for Ebola hemorrhagic fever.

## OK to put on the Web

**Fig. 10-14.** Hemorrhagic diathesis observed in a patient with Marburg hemorrhagic fever. Photograph: Courtesy of David I. H. Simpson, Department of Microbiology and Immunobiology, The Queen's University of Belfast.

## SUPPORTIVE TREATMENT

The severity of the various hemorrhagic fevers is quite variable. Many cases are initially categorized as fevers of unknown etiology until additional clinical findings become manifest. For example, during the Vietnam conflict, 3.4% to 28% of all patients hospitalized for fever of unknown etiology were eventually shown to have dengue.<sup>5</sup>

Intravascular volume should be maintained by intravenous infusion of plasma expanders such as normal saline. Oral fluid support is also important; however, protracted vomiting can be a clinical complication, necessitating even more aggressive intravenous support. Hemorrhagic manifestations and thrombocytopenia should be treated with platelet transfusions, intravenous plasma infusions, or both. If bleeding is severe and fractionated blood components are unavailable, whole blood should be transfused. Metabolic acidosis may require intravenous sodium bicarbonate, and a rising hemoglobin is

treated with infusion of plasma. Acute renal failure should be treated with close monitoring of intravascular volume, close monitoring of intake and output with replacement of free water losses only (including insensible losses), and avoidance of volume expanders such as sodium-containing products. In severe cases, hemodialysis should be considered, if available.

Patients with hemorrhagic fever with renal syndrome also experience a diuretic phase, necessitating aggressive intravenous support to maintain intravascular volume. Antiviral therapy with ribavirin (2 g IV loading dose, then 1 g every 6 h for 4 d, followed by 0.5 g every 8 h for 6 d) may prove to be good adjunct therapy for supportive medical care in some viral hemorrhagic fevers. Adrenocortical steroids, antibiotics, and vasoactive agents have not been shown to alter the clinical course of disease.<sup>5</sup>

## PREVENTION

The prevention of viral hemorrhagic fevers is based on two possible plans of action: (1) development of vaccines providing immunity and (2) control of the vectors or rodent hosts. Many vaccines are currently being developed; however, few are available. Control of mosquito vectors is an old concept spawned from Dr. Walter Reed's research on yellow fever. Because mosquitoes breed in open water, elimination of standing water sites around military installations helps to control regional disease. Use of insecticides such as malathion is effective, reducing vector populations in limited areas. Knowledge of vector feeding habits is also helpful; for example, the mosquito *A aegypti* prefers to feed indoors during daylight. Therefore, insect nets around beds are little protection against this vector,

and windows should be screened securely.<sup>5</sup>

These measures are good for established regional areas; however, they cannot be implemented when the soldier is in the field. Most of the cases of dengue experienced during the Vietnam conflict were contracted by support troops who had contact with civilian populations.<sup>5</sup> The speed with which modern warfare is undertaken, exemplified by Operations Desert Storm and Desert Shield, also results in a much higher risk of contracting disease because of increased contact with civilians over large regions and the lack of preventive vector-control measures. These facts emphasize the need for development of effective vaccines that will essentially remove the potential for disease in high-risk areas.

## SUMMARY

Hemorrhagic fever viruses are transmitted to humans by arthropods and through rodent excreta. The twelve viral groups producing hemorrhagic fever in humans are found in both temperate and tropical climates. Some of the hemorrhagic fever viruses are associated with large-scale epidemics. All of them can cause life-threatening hemorrhagic disease.

Although serologic tests such as ELISA are available, the diagnosis is dependent more on clinical presentation because of the acute nature of these diseases. Treatment is supportive in most patients and often requires intensive care. Ribavirin may have clinical utility in treating Rift Valley fever, Crimean-Congo hemorrhagic fever, hemorrhagic fever with renal syndrome, Lassa fever, and Argen-

tine, Ebola, and Marburg hemorrhagic fevers.

Prevention is based on development of vaccines or control of the arthropod and animal vectors. Because of the rapid mobility of modern warfare,

the best possible preventive measure is vaccination; however, few vaccines are currently available. The medical officer in the field must be aware of the potential risk of these frequently fatal viral infections.

## REFERENCES

1. Rehle TM. Classification, distribution and importance of arboviruses. *Trop Med Parasit.* 1989;40:391–395.
2. Gear JHS. Clinical aspects of African viral hemorrhagic fevers. *Rev Infect Dis.* 1989;2(suppl):S777–S782.
3. Centers for Disease Control. Management of patients with suspected viral hemorrhagic fever. *MMWR.* 1988;37:1–15.
4. Joklik W. Structure, components, and classification of viruses. In: Joklik W, Willett H, Amos D, Wilfert C, eds. *Zinsser Microbiology.* 20th ed. Norwalk, Conn: Appleton and Lange; 1992: 775, 777–779.
5. Russell PK, Ognibene AJ. Group B arboviruses. In: Ognibene AJ, Barrett O Jr, eds. *General Medicine and Infectious Diseases.* In: Ognibene AJ, ed. *Internal Medicine in Vietnam.* Vol 2. Washington, DC: Medical Department, US Army, Office of The Surgeon General and Center of Military History; 1982: 91–98.
6. Samlaska CP. Arthropod-borne virus infections and virus hemorrhagic fevers. In: Demis, DJ, ed. *Clinical Dermatology.* New York, NY: JB Lippincott; 1991: Unit 14-22; 1–15.
7. Capps RB. Dengue. In: Havens WP Jr, ed. *Infectious Diseases.* In: Coates JB Jr, ed. *Internal Medicine in World War II.* Vol 2. Washington, DC: Medical Department, US Army, Office of The Surgeon General; 1963: 59–76.
8. Fan W, Yu S, Cosgriff TM. The reemergence of dengue in China. *Rev Infect Dis.* 1989;2(suppl):S847–S853.
9. Rosen L. Disease exacerbation caused by sequential dengue infections: Myth or reality? *Rev Infect Dis.* 1989;2(suppl):S840–S842.
10. Bhamarapravati N. Hemostatic defects in dengue fever. *Rev Infect Dis.* 1989;2(suppl):S826–S829.
11. Bean WB. Walter Reed and yellow fever. *JAMA.* 1983;250:659–662.
12. De Cock KM, Naside A, Enriquez J, et al. Epidemic yellow fever in eastern Nigeria. *Lancet.* 1986;1:630–633.
13. Monath TP. Yellow fever: A medically neglected disease. Report on a seminar. *Rev Infect Dis.* 1987;9:165–175.
14. Pavri K. Clinical, clinicopathologic, and hematologic features of Kyasanur Forest disease. *Rev Infect Dis.* 1989;2(suppl):S854–S859.
15. Rodrigues FM, Bhat HR, Prasad SR. A new focal outbreak of Kyasanur Forest disease in Belthangady Taluk, South Kanara District, Karnataka State. *NIV Bull.* 1983;1:6–7.
16. Geetha PB, Ghosh SN, Gupta NP, Shaikh BH. Enzyme-linked immunosorbent assay (ELISA) using beta-lactamase for the detection of antibodies to KFD virus. *Indian J Med Res.* 1980;71:329–332.
17. Joklik W. The virus multiplication cycle. In: Joklik W, Willett H, Amos D, Wilfert C, eds. *Zinsser Microbiology.* 20th ed. Norwalk, Conn: Appleton and Lange; 1992: 828.
18. Saluzzo JF, Anderson GW Jr, Hodgson LA, Digoutte JR, Smith JF. Antigenic and biological properties of Rift Valley fever virus isolated during the 1987 Mauritanian epidemic. *Res Virol.* 1989;140:155–164.
19. Parsonson IM, Della-Porta AJ, Snowdon WA. Developmental disorders of the fetus in some arthropod-borne

- virus infections. *Am J Trop Med Hyg.* 1981;30:660–673.
20. Digoutte JP, Jouan A, Le Guenno, et al. Isolation of the Rift Valley fever virus by inoculation into *Aedes pseudoscutellaris* cells: Comparison with other diagnostic methods. *Res Virol.* 1989;140:31–41.
  21. Morrill JC, Jennings GB, Cosgriff TM, Gibbs PH, Peters CJ. Prevention of Rift Valley fever in rhesus monkeys with interferon-alpha. *Rev Infect Dis.* 1989;2(suppl):S815–S825.
  22. Huggins JW. Prospects for treatment of viral hemorrhagic fevers with ribavirin, a broad-spectrum antiviral drug. *Rev Infect Dis.* 1989;2(suppl):S750–S761.
  23. Swanepoel R, Gill DE, Shepherd AJ, Leman PA, Mynhardt JH, Harvey S. The clinical pathology of Crimean-Congo hemorrhagic fever. *Rev Infect Dis.* 1989;2(suppl):S794–S800.
  24. Lee HW, van der Groen G. Hemorrhagic fever with renal syndrome. *Prog Med Virol.* 1989;36:62–102.
  25. Bruno P, Hassell H, Brown J, Tanner W, Lau A. The protean manifestations of hemorrhagic fever with renal syndrome: A retrospective review of 26 cases from Korea. *Ann Intern Med.* 1990;113:385–391.
  26. Cosgriff TM. Hemorrhagic fever with renal syndrome: Four decades of research. *Ann Intern Med.* 1989;110:313–316.
  27. Bruno P, Hassell H, Quan J, Brown J. Hemorrhagic fever with renal syndrome imported to Hawaii from West Germany. *Am J Med.* 1990;89:232–234.
  28. Lee HW. Hemorrhagic fever with renal syndrome in Korea. *Rev Infect Dis.* 1989;2(suppl):S864–S876.
  29. Johnson K. Lymphocytic choriomeningitis virus, Lassa virus (Lassa fever), and other arenaviruses. In: Mandell G, Douglas R, Bennett J, eds. *Principles and Practice of Infectious Diseases*. 3rd ed. New York: Churchill Livingstone; 1990: 1329–1330.
  30. Frame JD. Clinical features of Lassa fever in Liberia. *Rev Infect Dis.* 1989;2(suppl):S783–S789.
  31. Carballal G, Videla CM, Merani MS. Epidemiology of Argentine hemorrhagic fever. *Eur J Epid.* 1988;4:259–274.
  32. Molinas FC, de Bracco ME, Maiztegui JI. Hemostasis and the complement system in Argentine hemorrhagic fever. *Rev Infect Dis.* 1989;2(suppl):S762–S770.
  33. Garcia Franco S, Amrosio AM, Feuillade MR, Maiztegui JI. Evaluation of an enzyme-linked immunosorbent assay for quantitation of antibodies to Junin virus in human sera. *J Virol Methods.* 1988;19:299–305.
  34. McKee KT Jr, Huggins JW, Trahan CJ, Mahlandt BG. Ribavirin prophylaxis and therapy for experimental Argentine hemorrhagic fever. *Antimicrob Chemother.* 1988;32:1304–1309.
  35. Stinebaugh BJ, Schloeder FX, Johnson KM, Mackenzie RB, Entwisle G, De Alba E. Bolivian hemorrhagic fever: A report of four cases. *Amer J Med.* 1966;40:217–230.
  36. McCormick J. Rhabdoviruses and filoviruses. In: Joklik W, Willett H, Amos D, Wilfert C, eds. *Zinsser Microbiology*. 20th ed. Norwalk, Conn: Appleton and Lange; 1992: 1031.
  37. Sureau PH. Firsthand clinical observations of hemorrhagic manifestations in Ebola hemorrhagic fever in Zaire. *Rev Infect Dis.* 1989;2(suppl):S790–S793.
  38. Jahrling PB, Geisbert TW, Dalgard DW, et al. Preliminary report: Isolation of Ebola virus from monkeys imported to USA. *Lancet.* 1990;335:502–505.
  39. Centers for Disease Control. Update: Filovirus infection in animal handlers. *MMWR.* 1990;39:221.



# Chapter 11

## RICKETTSIAL DISEASES

VINCENT L. ANGELONI, M.D.\*

---

### INTRODUCTION

#### SPOTTED FEVER SEROGROUP

Rocky Mountain Spotted Fever  
Boutonneuse Fever  
Rickettsialpox

#### TYPHUS SEROGROUP

Epidemic Typhus  
Recrudescence Typhus (Brill-Zinsser Disease)  
Endemic (Murine) Typhus

#### SCRUB TYPHUS, TRENCH FEVER, AND Q FEVER SEROGROUPS

Scrub Typhus  
Trench Fever  
Q Fever

#### EHRlichiosis SEROGROUP

Ehrlichiosis  
Sennetsu Fever

### SUMMARY

\*Major, Medical Corps, U.S. Army; Staff Immunodermatologist, Dermatology Clinic, Brooke Army Medical Center, Fort Sam Houston, Texas 78234-6200

## INTRODUCTION

Rickettsiae are pleomorphic, rod-to-coccoid-shaped organisms that stain poorly with Gram's stain but are morphologically typical of Gram-negative bacteria. They are unique in that, except for the genus *Rochalimaea*, they are obligate intracellular parasites. Living cells are required for the culture of all rickettsiae (with the exception of *Rochalimaea quintana*, the rickettsia that causes trench fever). This is a hazardous undertaking done by only a few specially equipped laboratories.

Within the family Rickettsiaceae, four genera—*Rickettsia*, *Coxiella*, *Rochalimaea*, and *Ehrlichia*—are capable of producing disease in humans. The rickettsiae are grouped by the clinical infections they induce, their etiologic agents, vectors, serologic reactions, and epidemiological factors. Their antigenic differences have allowed these organisms to be classified into genera, groups, and species. The pathogenic members of the family Rickettsiaceae can be divided into six serogroups: spotted fever, typhus, scrub typhus, trench fever, Q fever, and ehrlichiosis (Table 11-1). In the spotted fever group, the typhus group, and in scrub typhus, rickettsiae are found within the cytoplasm of the infected cell. Spotted fever serogroup organisms may also grow within the nucleoplasm of the cell.<sup>1</sup> *Ehrlichia* species exist within a phagosome in the host cell, and *Coxiella* within a phagolysosome; *Rochalimaea* species are

epicellular parasites that cling to the exterior of cells.

The transmission of rickettsial diseases to humans usually requires an insect or arachnid vector, and rickettsiae survive only briefly outside the host or vector. Human infection is incidental (except for epidemic typhus) and is of no benefit to the infecting rickettsial organism. Rickettsiae do not penetrate intact skin but can cause infection in abraded skin or can be transferred by the fingers to mucosal surfaces, which are readily infected. In humans, rickettsial diseases can be mild or life threatening and are characterized by fever and skin rash. The genus *Coxiella*, however, is an exception to the above generalizations. *Coxiella* is extremely resistant to desiccation and survives for long periods outside the host; its spread does not involve a vector but occurs via inhalation of the organism, and it is usually not associated with a skin rash. Rocky Mountain spotted fever (RMSF), caused by *Rickettsia rickettsii*, is the most common rickettsial disease in the United States<sup>2</sup> and carries the threat of significant morbidity and mortality if the diagnosis is not made promptly. Other rickettsial diseases that are indigenous to the United States include murine typhus, rickettsialpox, and *R. prowazekii* infections associated with flying squirrels.<sup>3,4</sup> However, imported cases of boutonneuse fever<sup>5</sup> or scrub typhus<sup>6</sup> are not unusual.

## SPOTTED FEVER SEROGROUP

Rickettsiae in the spotted fever serogroup are genetically related but differ in their surface antigens. There are several nonpathogenic members of this group. The spotted fever group organisms are maintained in nature in Ixodid ticks and animals. They induce a widespread vasculitis that involves both skin and internal organs, producing the clinical manifestations of rash and dysfunctions of brain, heart, lungs, and kidneys. The diseases produced by the spotted fever serogroup include RMSF, boutonneuse fever, and rickettsialpox. RMSF is generally the most severe infection of the group, although fatalities may also occur with infections of other spotted fever serogroup organisms. These other organisms produce diseases that induce headache, myalgia, fever, and maculopapular eruptions that may become petechial similar to RMSF, but the

diseases are usually milder and may have an eschar at the site of tick attachment.

### Rocky Mountain Spotted Fever

RMSF is an acute, severe, infectious disease. It is the most prevalent of the rickettsial diseases in the United States and is identical to Sao Paulo fever, Colombian spotted fever, *fièvre maculosa*, *fièvre petequiale*, and *fièvre manchada* of Mexico. RMSF was first described in the 1890s, when a series of cases was described in the Bitterroot valley of Montana. The first published account was by a U.S. Army surgeon in 1896,<sup>7</sup> although the impact of RMSF on military campaigns has been insignificant. From 1942 through 1945, only 135 cases were reported among army personnel; all of these occurred in the

**TABLE 11-1**  
**RICKETTSIAL DISEASES OF MEDICAL IMPORTANCE**

Serogroup	Disease	Organism	Vector	Reservoir	Geographical Location
Spotted Fever	Rocky Mountain Spotted Fever (Brazilian and Mexican spotted fevers)	<i>Rickettsia rickettsii</i>	Tick	Ticks, rodents, dogs	Western hemisphere
	Boutonneuse Fever (Mediterranean fever, South African Tick Bite fever, Kenya tick typhus, Indian tick typhus, Marseilles fever)	<i>R conorii</i>	Tick	Ticks, rodents, dogs	Europe, Africa, Asia
	Siberian Tick Typhus North Asian tick-borne rickettsial disease	<i>R sibirica</i>	Tick	Rodents, ticks	Siberia, Mongolia
	Queensland Tick Typhus	<i>R australis</i>	Tick	Rodents, marsupials	Australia
	Rickettsialpox	<i>R akari</i>	Mouse mite	House mouse	North America, Europe, former Soviet Union, Korea
Typhus	Epidemic Typhus	<i>R prowazekii</i>	Body louse	Human	Worldwide (war, famine associated), rare in the United States
	Recrudescant Typhus (Brill-Zinsser Disease)	<i>R prowazekii</i>	None	Human	Worldwide
	Endemic (Murine) Typhus	<i>R typhi</i>	Rat flea	Rat	Worldwide
Scrub Typhus	Scrub Typhus	<i>R tsutsugamushi</i>	Mite	Rodents, trombiculid mites	Asia, Australia, Pacific islands, Malaysia
Trench Fever	Trench Fever	<i>Rochalimaea quintana</i>	Body louse	Human	Europe, Africa, Central and South America (war associated)
Q Fever	Q Fever	<i>Coxiella burnetii</i>	None (airborne)	Ticks, sheep, goats, cattle	Worldwide
Ehrlichiosis	Ehrlichiosis	<i>Ehrlichia chaffeensis</i>	Tick?	Unknown	Southeastern, south-central United States
Sennetsu Fever	Sennetsu Fever	<i>E sennetsu</i>	Tick?	Unknown	Japan, Malaysia

continental United States.<sup>8</sup> Several large military bases (eg, Fort Sill, Oklahoma; Fort Bragg, North Carolina) are located in areas of the United States that have some of the highest rates reported for RMSF. Therefore, it is possible that medical officers in these areas will see patients with this disease.

### Microbiology

*Rickettsia rickettsii* is a small (0.3 × 1 μm), pleomorphic, coccobacillary organism and is an obligate intracel-

lular, bacterial parasite. It may be stained with Geimsa, Machiavello's, or Castaneda's stains. Although *Rickettsia rickettsii* stains poorly with the Gram's stain, it is Gram-negative. This fairly fragile organism is killed by drying, moist heat (50°C), formalin, and phenol. Freezing does not kill the organism, and it may remain viable in the frozen state for long periods. Because *Rickettsia rickettsii* grows only in the cytoplasm or nucleoplasm of eukaryotic cells, culturing is done in guinea pigs and mice, yolk sacs of embryonated hen's eggs, or tissue culture. The organ-

isms grow directly in the cytoplasm of the host, without being surrounded by a host cell membrane. The outer membrane of the organism has a slime layer, which is thought to play a role in virulence. After the organism divides by binary fission a few times within the cell, some of the rickettsiae exit the cell to infect other cells. In contrast, *R prowazekii* replicates until the host cell finally bursts.<sup>9</sup> *Rickettsia* species proliferate best at temperatures of 32°C to 38°C, which may explain the accentuated rash on the extremities and scrotum.<sup>10</sup>

Various tick species serve as the primary reservoir, hosts, and vectors. Rickettsial growth in the tick's ovaries results in transovarial transmission to at least some of the female tick's offspring.<sup>11</sup> Whether the infection is obtained transovarially or through feeding on an infected mammal, the infection persists for the life of the tick. This may be several years. Tick species harboring *Rickettsia* are characterized by a life cycle with three stages: larva, nymph, and adult. Only the adult ticks feed on humans. When the tick is attached to and feeding on a human, a "reactivation" process occurs in the rickettsial organism and it transforms from a dormant, avirulent state to a highly pathogenic one. This reactivation requires several hours. A certain interval of time is also required for the organisms to be inoculated into human skin after their release from the tick's salivary gland.<sup>12</sup> In the tick, infection with the organism begins in the gut wall, which is eventually penetrated and a generalized infection is produced. Transstadial transmission (ie, transmission of the organism from the larva to the nymph and from the nymph to the adult) also occurs in these ticks.

In humans, inoculated rickettsiae spread via the blood and lymphatic system to infect endothelial cells in all parts of the body. The organisms proliferate within the endothelial cells with some of the organisms exiting the infected cells, causing infection in other endothelial cells or vascular smooth muscle cells. Infection in humans is a biological dead end for the organism.

### Epidemiology and Vectors

Humans are only incidentally involved with *Rickettsia*. Transmission of disease occurs when an infected tick bites a human or the tick is crushed and contaminates the skin with rickettsiae. Rickettsiae are present in the hemolymph and feces of infected ticks. Aerosol spread of the disease is unlikely because the organism loses infectiousness rapidly in such material,<sup>11</sup> but this has been reported in labora-

tory accidents.<sup>13</sup> In one case, RMSF was acquired via blood transfusion when the infected donor was phlebotomized 3 days prior to the onset of illness.<sup>14</sup>

When the tick attaches for its first meal after hibernation, a reactivation process is initiated in the rickettsial organism, which adds several hours to the time needed for the transmission of the infection.<sup>15</sup> Later in the season, only 6 to 10 hours of attachment may be needed for transmission.<sup>16,17</sup> *Dermacentor andersoni* (the wood tick) requires 10 to 24 hours of feeding to transmit the infection.<sup>11</sup> In endemic areas, screening children for ticks twice a day is recommended to prevent infection.<sup>18,19</sup>

In the continental United States, several species of ticks have been identified as carriers of RMSF. *D andersoni* is the primary vector in the West, while *D variabilis* (the dog tick) is implicated in the South and the East. *Amblyomma americanum* (the Lone Star tick) has been implicated as a possible vector in the Southwest. In Brazil and Colombia, *Amblyomma cajennense* is the vector. *Rhipicephalus sanguineus* (brown dog tick) is a vector in southern regions of Mexico and the United States.<sup>16,20</sup> Most species of vector ticks appear to have a low rate of infection. The prevalence of *Rickettsia* infection among ticks has been estimated at 1 in 1,000.<sup>12</sup>

Several other ticks have been found to be infected with *Rickettsia* but, because they rarely attack humans, are not important as vectors. These are *Hemaphysalis leporispalustris*,<sup>12</sup> *Dermacentor parumapertus*, *Ixodes dentatus*, *I brunneus*, and *I texanus*. Several species can be considered potential vectors, however; they attack humans and have been found to contain *Rickettsia* or a closely related organism,<sup>11</sup> but they have not yet been documented as a cause of RMSF (Exhibit 11-1).

*Rickettsia* has also been found in numerous small mammals (eg, chipmunks, opossums, rabbits, squirrels, mice, and rats). This is due largely to the feeding habits of the various tick hosts. Some of these small mammals develop rickettsemia to a degree that would allow them to cause new infections in uninfected ticks that feed on them. These mammals probably play an important role in maintaining the organisms in nature. Infection in ticks tends to be limited in subsequent generations because the rickettsial infection may cause decreased viability and fecundity in tick offspring after several generations. Thus, the presence of small mammals provides a survival advantage for the organism by establishing new lines of infection, thereby overcoming the limitation of the infection that would be expected by the decreased reproductive ability or survival of future tick generations.<sup>15,21</sup>

**EXHIBIT 11-1****VECTORS OF ROCKY MOUNTAIN SPOTTED FEVER****Known Vectors**

*Dermacentor andersoni*  
*D variabilis*  
*Amblyomma cajennense*  
*Rhipicephalus sanguineus*

**Potential Vectors**

*Amblyomma americanum*  
*D maculatum*  
*D occidentalis*  
*Ixodes scapularis*  
*I pacificus*

Data source: Burgdorfer W. Ecological and epidemiological considerations of Rocky Mountain spotted fever and scrub typhus. In: Walker DH, ed. *Biology of Rickettsial Diseases*. Vol 1. Boca Raton, Fla: CRC Press; 1988: 33–50.

Although the name RMSF persists, it has become a misnomer. Prior to the 1940s, most cases were reported from the western mountain states. Now, however, the most common sites in the United States are the eastern, southeastern, and south-central regions.<sup>22</sup> The incidence appears to be highest in areas characterized by eastern deciduous forests made up largely of pine, oak, or hickory trees.<sup>18</sup> The disease may also occur in urban areas and, rarely, urban endemic foci have been described.<sup>23</sup> All states in the United States except Maine, Alaska, and Hawaii are considered endemic areas.<sup>24</sup> States with the highest rates of infection are Oklahoma, North Carolina, and South Carolina.<sup>12,18</sup> High incidences are also seen in Maryland, Virginia, Georgia, Tennessee, Ohio, Missouri, Arkansas, Texas, and Kansas.

Human males and females of all ages are susceptible to RMSF. The age distribution and gender of patients tend to be related to the occupational or recreational activities in the area. Rural areas have higher incidences of disease and in the West, infection seems to occur more often in persons following outdoor occupations. Adults are primarily affected in the Rocky Mountain area, but in the southern United States, children make up a large number of cases, probably because the dog tick is the main vector in that area.

Seasonal variations in the number of reported cases are related to the responsible tick vector's periods of activity. Most cases occur between April and October although sporadic cases occur through-

out the year, even in winter.<sup>25</sup> July is typically the month with the highest number of reported cases. Even with effective antibiotics available, the fatality rate for RMSF remains in the 3% to 7% range.<sup>2,10,16,22,26</sup>

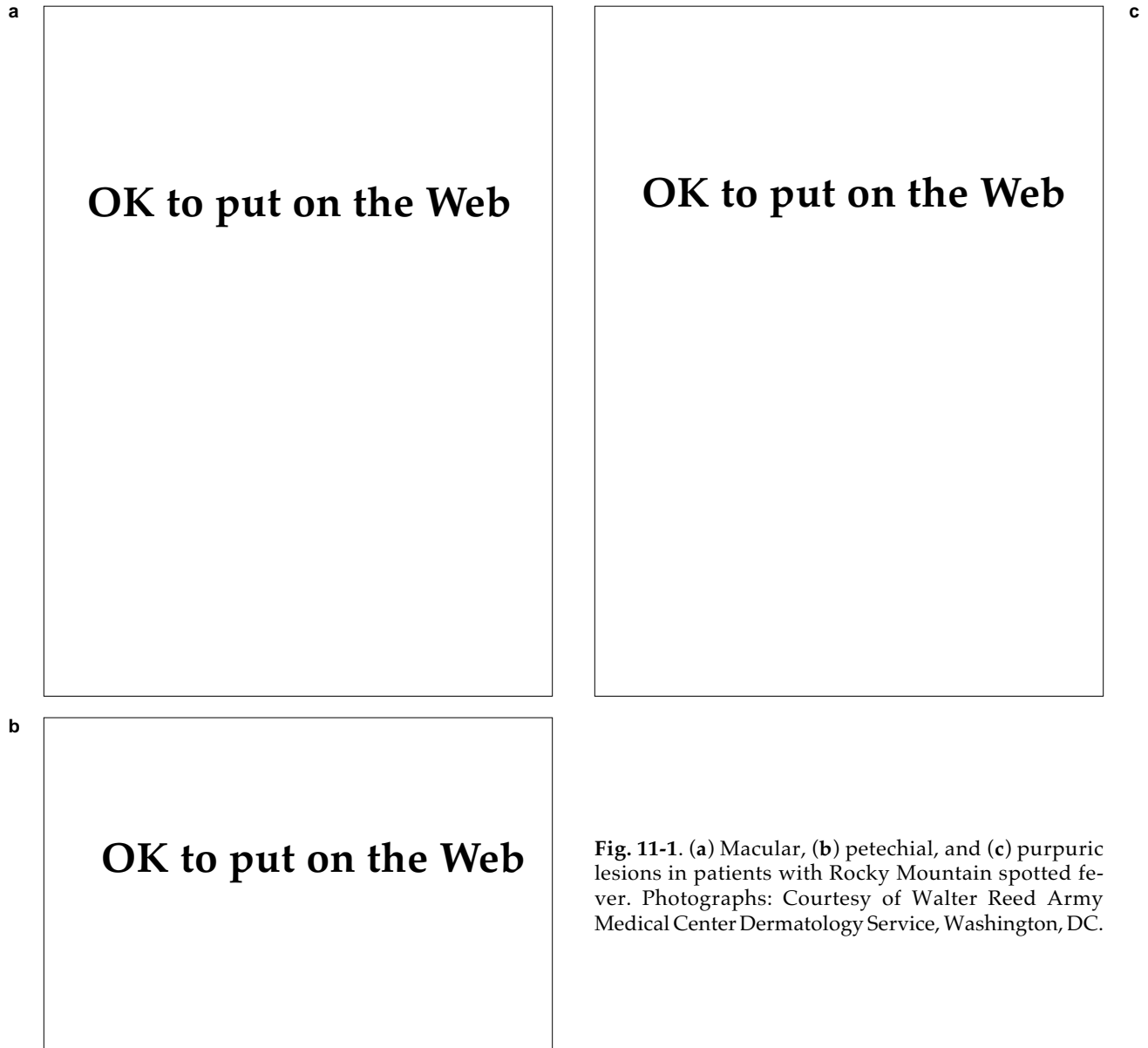
**Clinical Manifestations**

The incubation period lasts 4 to 8 days (range 2–14 d). The prodromal period lasts 2 to 3 days and is characterized by headache, malaise, anorexia, photophobia, chills, fever, arthralgia, and myalgia. Symptoms may appear gradually or rather suddenly with rigors, prostration, and severe headache, backache, and abdominal pain. At this point, the observed symptoms are nonspecific and the disease is difficult to distinguish from more common illnesses. Asymptomatic infection has not been conclusively demonstrated.<sup>12</sup>

Because RMSF causes widespread capillary damage, the signs and symptoms of the disease are protean. Although the presence of the RMSF classic triad (fever, rash, history of tick bite) would seem to be very helpful, only 3% of patients will have these findings during the first 3 days of illness.<sup>2</sup>

Fever, rash, and edema are common clinical findings. The fever is characterized by morning remissions, may reach 106°F, and can last up to 3 weeks in severe cases. Restlessness, insomnia, and delirium can be seen when the fever peaks. The pulse rate usually parallels the temperature and a sudden elevation of pulse rate over a 24-hour period may herald the appearance of circulatory failure. Myalgia, hyperesthesia, slight nonproductive cough, and epistaxis are also seen frequently.

The rash is an important, although not always a completely reliable, diagnostic sign (Figure 11-1). It may appear from 2 to 14 days after onset, occurring most often around the fourth day. An eschar is not typical of RMSF, although it has been described rarely.<sup>27</sup> The rash first appears on the cooler portions of the body such as the distal extremities or scrotum.<sup>19</sup> Initially, it is macular and blanches with pressure. In some cases, it may appear first on the trunk, but even in these patients it tends to become accentuated on the extremities.<sup>18</sup> The lesions spread in a centripetal fashion with involvement of the trunk, buttocks, neck, axilla, and face. Within 2 to 3 days, the rash assumes a petechial or purpuric character. At this time, while the rash is petechial, the Rumpel-Leede phenomenon may be seen: when a tourniquet or sphygmomanometer cuff is applied to the extremity for 3 to 5 minutes, petechiae can be seen below the site of compression. The Rumpel-Leede phenomenon is not specific for RMSF and



**Fig. 11-1.** (a) Macular, (b) petechial, and (c) purpuric lesions in patients with Rocky Mountain spotted fever. Photographs: Courtesy of Walter Reed Army Medical Center Dermatology Service, Washington, DC.

also can be seen in platelet disorders and sometimes scarlet fever. After the petechial stage, lesions may coalesce and form ecchymotic areas. Necrotic or gangrenous changes may follow, occurring over bony prominences, the scrotum, penis, vulva, ears, and, in severe cases, the extremities. In mild cases, the rash may never become petechial and the macules can disappear, especially after antibiotic treatment has been initiated. Estimates of the percentage of cases with petechial rashes are in the range of 40% to 60%. Only one third of patients will have fever, headache, and petechial skin lesions.<sup>28</sup> The rash may not involve the palms and soles in a substantial number of cases.<sup>12,29</sup>

Unfortunately, the late appearance of the rash often causes a delay in diagnosis that could have catastrophic consequences. In approximately 10% of patients, the rash may be completely absent.<sup>22</sup> "Spotless" spotted fever is seen more often in older patients, fatal cases, and black people whose heavy pigmentation obfuscates the rash.

Nonpitting edema occurs frequently. It may be generalized or strictly limited to the periorbital region, face, or extremities. This usually worsens as the disease progresses and is a direct result of the vascular damage caused by the organism.

Nonproductive cough may be noted. Chest radiography may reveal patchy interstitial infiltrates in

approximately one third of patients. The pulmonary edema seen in severe cases is due to increased permeability in the pulmonary vessels caused by rickettsial infection of the endothelial cells.<sup>10</sup> Severe pulmonary edema and development of adult respiratory distress syndrome is a life-threatening complication.

Eye findings include conjunctivitis (in 30%), photophobia, and sometimes petechial lesions. In severe disease, ocular palsy, hemorrhage, venous engorgement, vascular occlusion, and papilledema may occur. The latter is seen in 1.5% of patients, can occur with normal cerebrospinal fluid pressure,<sup>2,29,30</sup> and is thought to be due to vascular involvement of the optic nerve head.

Electrocardiographic findings are usually nonspecific; however, myocarditis occurs and can trigger arrhythmias in approximately 7% of patients.<sup>2</sup> There have also been isolated reports of creatine kinase–myocardial band elevations.<sup>29</sup> In general, the myocarditis is rather mild and often completely overshadowed by pulmonary problems.<sup>29</sup>

Abdominal pain is not unusual and could be severe enough to cause misdiagnosis and unnecessary laparotomy for suspected appendicitis,<sup>31</sup> ruptured diverticula, or acute cholecystitis.<sup>12,32</sup> Anorexia, nausea, vomiting, and diarrhea are the most frequent gastrointestinal complaints.<sup>33</sup> Probably the most common misdiagnosis is gastroenteritis. Guaiac-positive stools and vomitus can be seen in approximately 10% of patients.<sup>34</sup> Fatal gastrointestinal hemorrhages may occur.<sup>9</sup> Splenomegaly can occur later in the first week of illness. Jaundice is seen infrequently, and the liver is usually not severely damaged. Hypotension due to peripheral circulatory failure results in prerenal azotemia that sometimes progresses to acute oliguric renal failure.<sup>29,35</sup>

Neurological manifestations are common and can mimic encephalitis or meningitis. Mild nuchal rigidity and Kernig's sign may be present. Early in the disease, mental status changes consisting of confusion, dulling of the senses, and restlessness are possible. Lethargy, delirium, and coma may follow. Loss of sphincter control and transient deafness are rare complications. Abnormal neurological findings such as ankle clonus or a positive Babinski sign can appear as the condition worsens. Other neurological manifestations include tremor, rigidity, meningismus, opisthotonus, central blindness, convulsions, pyramidal tract signs, aphasia, dysarthria, ataxia, unilateral corticospinal signs, hemiplegia, paraplegia, neurogenic bladder, and cerebral hemorrhage.<sup>18,28,29,36</sup> Psychiatric symptoms may complicate the picture; hallucinations, para-

noid behavior, and involuntary commitment have been reported.<sup>28</sup>

Initially, the illness appears nonspecific and is difficult to distinguish from other illnesses associated with fever, headache, and myalgia. In RMSF, however, symptoms usually progress. Overwhelming infections may result in death within a few days, especially in patients with glucose-6-phosphate dehydrogenase (G6PD) deficiency. In fatal cases, patients are usually comatose and may show signs of neurological embarrassment, circulatory collapse, and renal failure.

Severe disease may be associated with thrombocytopenia resulting in various hemorrhagic phenomena such as purpura or secondary hemorrhage in the brain or lungs. Necrotic gangrene may occur in dependent areas such as the fingers, toes, scrotum, and earlobes. Massive skin necrosis requiring skin grafts has also been reported.<sup>37</sup> Secondary bacterial infection may also complicate the picture: pneumonia, otitis media, and parotitis may occur.<sup>16</sup> Convalescence is usually rather slow, requiring weeks to months.

Most patients without complicated courses will have no sequelae.<sup>28</sup> Neurological sequelae include symptoms ranging from "nervousness" to convulsions. Abnormal electroencephalogram findings may persist. In children, the risk of learning disability is increased.<sup>18</sup> Deafness and impaired vision can be permanent. Severely ill patients may have impairment of fine motor control, hypotonia, hyperreflexia, ataxia, mental retardation, aphasia, paraplegia, neurogenic bladder, transverse myelitis, depression, learning disabilities, and decreased intelligence.<sup>29</sup>

### Laboratory Findings

There are no diagnostic laboratory findings in RMSF. Early in the disease, leukopenia or a normal white blood cell count may be seen with increased band forms that later evolve into a leukocytosis.<sup>18,28</sup> Mild, normocytic, normochromic anemia may also be found. Hemolysis occurs rarely, mainly in patients who are deficient in G6PD.<sup>26,38</sup> Thrombocytopenia may occur in 32% to 52% of patients<sup>16</sup> and may be related to an increased adherence and margination of platelets, to vascular endothelium at foci of infection.<sup>39</sup> Evidence of coagulation disturbances can be found. Hypofibrinogenemia, elevated fibrin degradation product levels, and prolonged prothrombin and partial thromboplastin times can occur and may not be associated with disseminated intravascular coagulation (DIC) or bleeding.<sup>28</sup> Al-

though laboratory findings are compatible with intravascular coagulation, true DIC in RMSF probably occurs only rarely. Normal or elevated plasma fibrinogen levels can be seen in RMSF, an exceptional finding in cases of DIC.<sup>10</sup> In true DIC, occlusive thrombi occur in normal blood vessels and heparin is effective therapy. In RMSF, heparin therapy may result in increased hemorrhage.<sup>40</sup> Thrombi in RMSF are found only in vessels where there is severe injury, and bleeding occurs more often without coagulopathy. The preferred treatment is with antirickettsial antibiotics.<sup>9,12</sup>

Hyponatremia is common. Abnormal liver function tests may be noted; aspartate aminotransferase, alanine aminotransferase, and bilirubin may be increased.<sup>29,33</sup> Blood urea nitrogen may be increased. The urine is usually normal except in cases where renal failure is developing. Inappropriate secretion of antidiuretic hormone has been reported<sup>41</sup>; however, inappropriate secretion cannot be diagnosed with certainty when hypotension, hypovolemia, or edema are present.<sup>42</sup> What appears to be elevated may actually be *appropriate* secretion of antidiuretic hormone followed by a dilutional hyponatremia.<sup>29</sup>

Cerebrospinal fluid findings are variable. Moderate lymphocytic pleocytosis is not uncommon although cells may be absent. Glucose is usually normal and protein may be normal to moderately elevated.<sup>28</sup>

In severe cases, elevation of creatine kinase and aldolase enzymes may be noted, reflecting muscle involvement.<sup>29</sup>

### **Prognostic Factors**

Two important factors in the prognosis of RMSF are the rapidity with which the diagnosis is made or suspected and when treatment is started. Typically, patients who are treated before the fifth day of illness do well, whereas those who are not treated until the sixth day have a 25% mortality.<sup>43</sup> Factors that result in delayed diagnoses include the late appearance or absence of the rash, late reporting or lack of tick-bite history, and an initial diagnosis other than RMSF.

Age is also important: patients over 40 do significantly worse than younger patients. Mortality for patients younger than 40 years of age is approximately 13%, whereas patients older than 40 have a 41% mortality.<sup>18</sup> The presence of other underlying diseases complicates management and adversely affects prognosis. The infective burden and the virulence of the organisms also play a role. This is

reflected by a short incubation period and increased severity of symptoms. Patients with G6PD deficiency can have particularly fulminant courses.<sup>44</sup>

The need for mechanical ventilation, the presence of coma, or acute renal failure portend a poor prognosis. In one study, 9 of 10 patients who needed mechanical ventilation died.<sup>30</sup> Of patients who lapse into coma, 86% have fatal outcomes.<sup>12</sup> Acute renal failure complicates fluid management and may require dialysis.<sup>12</sup>

Men tend to do worse than women. Black men also seem to have more severe illness, a finding that is unrelated to skin color or socioeconomic class.<sup>29,38</sup> When the role that dark pigmentation plays in delaying recognition of the RMSF rash, and therefore delaying treatment, is eliminated, black men are still found to have a significantly higher mortality. Thus, in a study comparing mortality data in black women to age-matched white women with RMSF, the mortality rates are very similar. However, when black men are compared to an age-matched white control population with RMSF, the black men have a strikingly higher mortality rate than their white counterparts.<sup>38</sup> Case fatality rates for blacks are more than 3-fold higher than for whites, with black men over the age of 40 at high risk for a fatal outcome.<sup>22,26</sup>

### **Diagnosis**

**Serologic Diagnosis.** Serology is the principal diagnostic tool for rickettsial diseases used in most laboratories. It is, however, a retrospective method that compares acute titers of antibodies to convalescent titers obtained weeks later. Treatment should not be withheld while waiting for antibody titers. Because immunity to infection is lifelong, confirming the diagnosis of RMSF is important for both the physician and the patient. Samples should be collected as early as possible in the illness, during the second week, and again 4 to 6 weeks after the onset. Serologic studies should be repeated even after successful treatment, because negative results imply that the patient does not have immunity.<sup>19</sup>

Diagnostic testing for RMSF includes commercially available tests such as latex agglutination and Proteus OX-19 and OX-2 agglutination (the Weil-Felix test). Indirect fluorescent antibody, indirect hemagglutination, and complement fixation tests are available through reference laboratories. There is cross-reactivity of the antibodies identified by indirect hemagglutination, indirect fluorescent antibody, and latex agglutination among other mem-



bers of the spotted fever serogroup (*R akari*, *R conori*, *R sibirica*, and *R australis*), typhus serogroup (*R prowazekii*, *R typhi*), and scrub typhus serogroup (*R tsutsugamushi*). The indirect hemagglutination and indirect fluorescent antibody tests appear to be the most sensitive of those currently in use.<sup>45</sup>

The indirect fluorescent antibody test is the current standard for serologic tests, with a sensitivity of 94% to 100% and a specificity of 100%. Antibody titers of 1:64 or greater are considered to be diagnostic when detected 7 to 10 days after the onset of RMSF-like symptomatology.<sup>10</sup> Indirect fluorescent antibody titers tend to be more persistent, allowing the test to be used to screen for disease prevalence. In addition, the test can be used to quantitate the immunoglobulin M and immunoglobulin G response, which is necessary to distinguish epidemic typhus from recrudescent typhus (Brill-Zinsser disease, which is discussed later in this chapter).<sup>16</sup> The main disadvantages of the indirect fluorescent antibody test are that it is technically difficult to perform and requires a fluorescent microscope. Reproducibility can also be a problem due to variations induced by different fluorescent conjugates, light sources, and optical systems.

Complement fixation testing is used less often today, although previously it was the principal serologic test with fairly high specificity. However, low sensitivity in early disease was a major problem with this test. The Centers for Disease Control and Prevention have stopped providing rickettsial antigen for this test.<sup>10</sup> Complement fixation antibody titers can persist at low levels for years. Spotted fever group and typhus group cross-reactions are observed frequently.

The indirect hemagglutination test can detect antibodies earliest in the disease, showing a sharp rise in convalescent titers after days 7 through 9 of illness. However, few RMSF patients have diagnostic titers in the acute stages of illness.<sup>12</sup> Cross-reactions are seen with RMSF, rickettsialpox, and boutonneuse fever. Sensitivity in convalescent sera is very high but in the acute stages it is low.

Latex agglutination is a rapid, simple, commercially available test that requires no special equipment to perform.<sup>46</sup> Titers fall below levels of significance after approximately 2 months. Only active RMSF infections are detected and a single high titer (1:128) is usually diagnostic.<sup>47,48</sup> Specific latex agglutination tests for murine typhus, epidemic typhus,<sup>49</sup> and boutonneuse fever have also been developed.<sup>50</sup>

*Proteus* agglutination (Weil-Felix) tests were initially described in 1916 and depend on cross-re-

acting antigens present on *Proteus vulgaris* strains. These antibodies appear in the sera of patients 5 to 12 days after RMSF develops and cause agglutination with *Proteus* strains OX-19 and OX-2. The Weil-Felix test has also been used in the diagnosis of murine typhus, epidemic typhus, boutonneuse fever, and other rickettsial diseases. Patients with rickettsialpox and recrudescent typhus fever do not develop Weil-Felix antibodies. The sensitivity and specificity are low when compared to more current serologic tests that detect specific rickettsial antibodies. False-positive results have been reported in cases of leptospirosis, *Proteus* infections, brucellosis, tularemia, enteric, relapsing, and rat bite fevers,<sup>16</sup> atypical measles,<sup>51</sup> and healthy people.<sup>12</sup> Most people who are found to have positive Weil-Felix antibody titers early in the disease course are subsequently proven *not* to have RMSF.<sup>12</sup> Weil-Felix testing is no longer considered by the Centers for Disease Control and Prevention as a criterion for the laboratory diagnosis of RMSF, and some authorities have recommended its abandonment.<sup>10,52</sup>

The Centers for Disease Control and Prevention criteria for confirming the laboratory diagnosis of RMSF, which were established in 1981, are the following<sup>45</sup>:

- a 4-fold increase in serum antibody titers from the acute to the convalescent phase, as determined by complement fixation, indirect fluorescent antibody, indirect hemagglutination, latex agglutination, or microagglutination tests;
- a single, high, acute-phase titer using latex agglutination, which is confirmatory only when acute and convalescent titers are not available;
- a single convalescent titer of 1:16 or higher by complement fixation or 1:64 or higher by indirect fluorescent antibody testing in clinically compatible cases;
- isolation of rickettsiae; and
- fluorescent antibody staining of biopsy of autopsy specimens.

Notable is the absence of the Weil-Felix test in this diagnostic scheme. Weil-Felix positivity is only a probable indicator of disease, and should be confirmed with more-specific tests.

**Rickettsial Isolation.** Isolation of the rickettsial organism is not feasible in most situations, as this technique is practiced by only a few research laboratories. Rickettsiae may be grown in guinea

pigs and mice, cell culture, and yolk sacs of embryonated hen's eggs. Guinea pigs inoculated intraperitoneally develop fever, erythema, edema, and sometimes hemorrhagic necrosis of the scrotum. The animals are sacrificed on day 3 of fever, and diagnosis may be attempted by staining smears of tunica vaginalis, or frozen sections of epididymis or spleen, with fluorescein-conjugated antibody. Alternatively, specimens may be frozen at  $-70^{\circ}\text{C}$  and sent to a reference laboratory for confirmation of diagnosis.<sup>10</sup>

**Identification of *Rickettsiae* in Tissue.** Attempts to visualize rickettsiae in tissue using standard or modified histochemical stains (eg, Giemsa, modified Brown-Hopps) have been made. However, because the number of organisms in tissue may be small, using these techniques to identify organisms is tedious and fraught with error.

A more-acceptable method is the use of 3-mm punch biopsies of lesional skin, followed by staining with specific immunofluorescent antibodies or indirect immunofluorescent techniques. Sensitivity of the direct immunofluorescent technique is 70% and specificity is 100%. The reliability of the results may directly correlate with the experience of the pathologist. In any case, negative results do not rule out the diagnosis. Rickettsiae appear to be most numerous in endothelial cells at the center of the petechial lesion. Therefore, step sections through the middle of the frozen specimen are more likely to demonstrate the organisms. Antirickettsial antibiotic treatment appears to have little effect on the sensitivity of the biopsy if used for less than 24 hours. After 24 hours of antiobiotic therapy, the number of organisms in the tissue appears to be dramatically reduced, making the biopsy unreliable. Punch biopsy and immunofluorescence can also be used to diagnose boutonneuse fever, murine typhus, and epidemic typhus.<sup>10</sup> The disadvantages of the immunofluorescent technique are the following:

- this technique is not widely available,
- a fluorescent microscope is necessary,
- the results may depend on the experience of the pathologist, and
- a rash must be present and a biopsy of a petechial lesion is the preferred specimen.

Rickettsiae can be demonstrated in formalin-fixed, paraffin-embedded tissue. This technique can be employed to make a diagnosis the same day or the next day, but it has not been routinely used as of this time.<sup>53-55</sup>

### Pathological Findings

There are no diagnostic histopathological findings in RMSF and the pathological findings are similar to those caused by other *Rickettsia* species. The major sites of involvement are the capillaries and venules. The arteriolar damage may be more prominent owing to the infiltration of the media by *R. rickettsii*. Endothelial swelling and perivascular and interstitial infiltration of lymphocytes, macrophages, and a few neutrophils are seen. Although this may have the appearance of a leukocytoclastic vasculitis, it is not the result of immune complexes. Thrombi may be seen in a small number of vessels and microinfarcts are found infrequently.<sup>10</sup>

Similar histopathological patterns are seen in affected organs such as skin, kidney, heart, lung, liver, muscle, esophagus, stomach, intestines, pancreas, testis, and epididymis. The most characteristic lesion is the *glial* or *typhus nodule* that occurs in the central nervous system, where perivascular lymphocytes and macrophages infiltrate the subendothelium and neuropil. This lesion is not diagnostic of rickettsial infection, as it is seen in various encephalitides.<sup>10</sup>

Myocardial changes are typified by interstitial inflammation with occasional necrosis of myocardial cells. Conduction fibers involvement may result in electrocardiographic abnormalities.<sup>56</sup>

### Differential Diagnosis

The presumptive diagnosis of RMSF should be entertained in a febrile patient with a recent history of a tick bite or having crushed a tick. Especially in endemic areas, the absence of this history should not decrease the medical officer's index of suspicion. Because in some areas more than 50% of the populace may have a history of tick bite, a positive history may not be particularly helpful either.<sup>57</sup> Problems arise when patients are initially misdiagnosed and are given an antibiotic that is ineffective against rickettsiae. When such patients return to the physician because their symptoms have progressed and a rash has developed, the diagnosis of drug eruption—rather than RMSF—is likely to be made, further delaying treatment. Inappropriate antibiotic therapy is associated with a mortality of 20%.<sup>2</sup> Within the first week of illness, finding a marked left shift in the differential count with a near-normal number of leukocytes should suggest consideration of the diagnosis. Biopsy of a skin lesion (preferably petechial) for immunofluorescent staining could help in making a rapid diagno-

sis if the results are positive but is not helpful if negative.<sup>19</sup>

The rash may be a helpful clinical sign, but it is not always classic or diagnostic in its presentation. Other illnesses that present with fever and petechial lesions must be considered: meningococemia, murine and epidemic typhus, typhoid fever, measles (especially atypical measles), and enteroviral infection with an exanthem.

The rash of meningococemia becomes purulent or necrotic within a day or two of onset. It is additionally distinguished by abnormal cerebrospinal fluid findings; positive culture of organisms from the cerebrospinal fluid, blood, or skin lesions; and positive counterimmunoelectrophoresis or latex agglutination of cerebrospinal fluid or urine.<sup>43</sup> If the diagnosis is in doubt, then treatment to cover both RMSF and meningococcus infection should be started using tetracycline with the addition of penicillin, or with chloramphenicol alone.

Measles usually has a distinctive prodrome with coryza, respiratory symptoms, photophobia, and Koplik's spots. Atypical measles can mimic RMSF more closely with fever, myalgia, and headache, followed by a rash and elevated Weil-Felix OX-19 titers.<sup>51</sup> The rash is maculopapular and petechial, starts on the extremities, and spreads centripetally. Urticarial or vesicular lesions may be noted, differing from RMSF. Koplik's spots are absent and pneumonia may occur. Atypical measles is a diagnostic consideration only in adults: it depends on the patient's having received the inactivated measles vaccine during the years 1963 through 1967.<sup>18</sup>

Enteroviral infections can be confusing owing to their seasonal occurrence and the faint maculopapular rash that may accompany them. These patients usually have a milder, self-limiting illness. The rash usually

- starts on the trunk,
- may be petechial on occasion, and
- can involve the palms and soles.

The occurrence of aseptic meningitis can further confuse the clinical picture. When the diagnosis is in doubt, treatment for RMSF is indicated.

Murine typhus, which is usually a milder disease, occurs more often during the winter and in urban areas, and is rarely purpuric. Epidemic typhus can produce many of the same findings as RMSF, but the rash is rarely seen on the palms, soles, and face, and usually is first seen on the trunk, spreading centrifugally to the arms and thighs. The individual lesions initially begin as pink, blanchable

macules but as the exanthem progresses, petechiae are found. As in RMSF, skin lesions may progress to necrosis or gangrene. Cases of RMSF that occur during the winter should be scrutinized closely to rule out epidemic typhus, although therapy for these diseases is the same.<sup>58</sup>

In the western United States, Colorado tick fever is more common than RMSF. Caused by a virus that is transmitted by *D andersoni*, Colorado tick fever is characterized by fever, headache, backache, and leukopenia, but it does not produce an exanthem. Thus, it may be confused with RMSF early in the disease, before the rash is seen. Episodes of fever followed by 2 to 3 afebrile days, with subsequent return of fever, suggests Colorado tick fever. This is usually not a severe illness.<sup>59</sup>

Other diagnostic considerations include immune complex vasculitis, idiopathic thrombocytopenic purpura, thrombotic thrombocytopenic purpura, disseminated gonococcal infection, secondary syphilis, leptospirosis, rubella, and drug eruptions.

### Treatment

The antibiotics tetracycline and chloramphenicol are effective in treating RMSF. These agents are bacteriostatic, not bacteriocidal, and if administered late in the course of disease, the infection may still prove to be fatal. Most patients who are treated 4 to 5 days after the onset of symptoms will survive, with the exception of the rare patient with both G6PD deficiency and RMSF. Because G6PD deficiency predisposes to severe infection, patients with this history may require presumptive therapy with doxycycline as soon as they present with signs and symptoms even *slightly* suggestive of RMSF.<sup>19</sup> Results are usually seen within days of initiating treatment. Therapy is generally continued until 4 days after the patient becomes afebrile, or for a 7- to 10-day course. Sulfonamides are contraindicated if RMSF is suspected because they enhance the infection.

Antibiotic therapy for patients older than 9 years of age who are stable with mild disease and who do not have significant nausea or vomiting should consist of oral tetracycline or doxycycline. The dose of tetracycline should be 30 to 40 mg/kg/d, administered every 6 hours (the maximum dose is 2 g/d). Doxycycline should be administered with a loading dose of 4.4 mg/kg/d divided every 12 hours the first day, followed by a maintenance dose of 2.2 mg/kg/d divided every 12 hours. The maximum dose of doxycycline is 300 mg/d.<sup>43</sup> Doxycycline is the recommended tetracycline if azotemia is present.<sup>60</sup>

More severely ill patients who require hospital care should be given intravenous antibiotics. Tetracycline is the drug of choice, especially in patients with hematologic complications (ie, thrombocytopenia). The intravenous dose of tetracycline is also 20 to 30 mg/kg/d in divided doses administered every 12 hours. Chloramphenicol is administered intravenously or orally in a dose of 50 to 100 mg/kg/d, divided every 6 hours (the maximum dose is 3 g/d). Chloramphenicol has the advantage of also covering meningococcal disease and is the preferred drug for pregnant women. Hematologic parameters must be monitored with chloramphenicol therapy to screen for the development of blood dyscrasias.

Therapy for pediatric patients younger than 9 years of age is controversial. Some authorities prefer chloramphenicol because enamel hypoplasia can occur with tetracycline therapy in this age group.<sup>61</sup> However, the fact that chloramphenicol has been associated with bone marrow aplasia causes some experts to recommend tetracycline despite tooth discoloration.<sup>61,62</sup> Dental abnormalities associated with tetracycline are more likely with repeated or prolonged exposures to the drug. Doxycycline may be preferred over tetracycline because it binds less to calcium, decreasing its potential to affect the tooth enamel. Whichever antibiotic is chosen, adequate documentation should be included in the patient's record specifically addressing the discussion of the side effects with the patient's parents (Figure 11-2).<sup>61</sup>

Ancillary and supportive care can be difficult in some cases. Fluid management can be a troublesome problem due to the vascular damage sustained during the course of the illness. Albumin or plasma may be needed in addition to electrolyte solutions. Injudicious use of fluids may lead to circulatory overload, increasing edema and cardiopulmonary failure. Hematologic parameters, including platelets, should be monitored closely, and transfusions may be needed in some cases. Management of DIC is best handled by its prevention, using appropriate antibiotic treatment early to control the infection. Standard heparin therapy for DIC may be ineffective in patients with RMSF.<sup>1,16,62</sup>

Treatment with systemic corticosteroids is controversial but may be useful in patients with widespread vasculitis and encephalitis with cerebral edema.<sup>24,62</sup>

### Prevention

Because a commercial vaccine for RMSF is not currently available, preventive efforts are aimed at

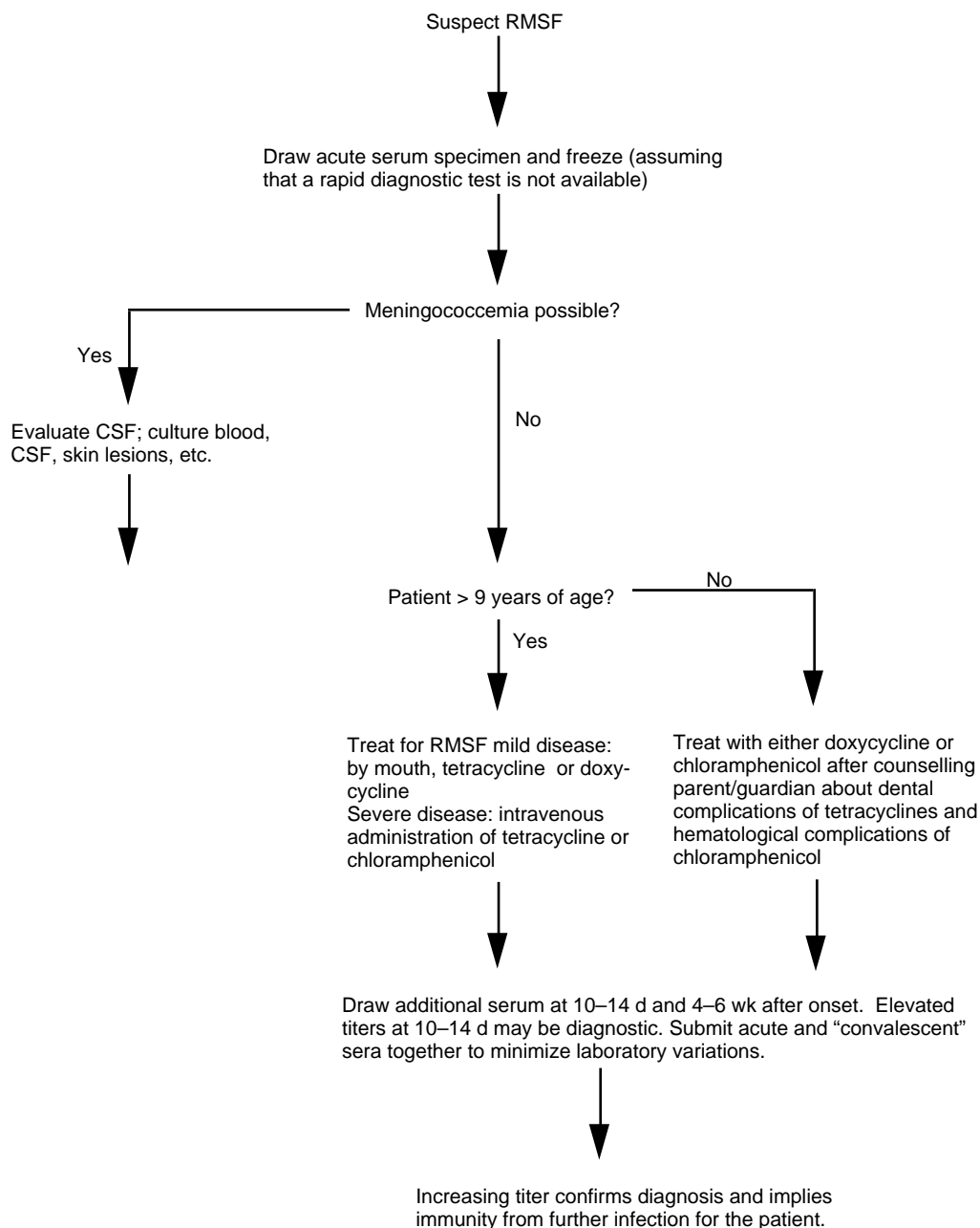
avoiding or reducing contact with ticks. Insecticides such as dichlorodiphenyltrichloroethane (DDT), dieldrin, chlordane, toxophene, and malathion have been used successfully in the past. However, environmental concerns have limited the use of residual insecticides such as chlordane or dieldrin for tick control in large areas. Dipping domestic animals, rodent control, and clearing brush may help control the tick population.

Avoidance of ticks is the primary personal preventive measure. Repellents such as *N,N*-diethyl-*m*-toluamide (DEET), dimethyl phthalate, or permethrin should be applied to clothing and exposed body parts and should be reapplied after swimming or perspiring heavily. Applying the repellent to clothing may produce longer periods of effectiveness.<sup>59</sup> The acaricide permethrin (ie, a synthetic permethrin) is an effective repellent that may be applied to clothing and remains effective for several weeks, even after one or more washings.<sup>60</sup> Ticks may be easier to detect on lighter-colored apparel, and clothing should cover the legs and arms. Pants should remain tucked into socks. Even with these precautions, it is important to inspect the entire body for ticks every 4 hours.<sup>63</sup> It is not uncommon for people to be totally unaware of ticks crawling on their skin and biting. Because ticks must remain attached for several hours to transmit the infection, periodic examination and removal of attached ticks may prevent transmission.

Engorged ticks must be removed with care. The most successful method appears to be using fine-tipped forceps to grasp the tick near the insertion of the mouthparts into the skin. Steady, gentle traction with the forceps is then applied in an attempt to dislodge the tick.<sup>64</sup> The site should then be disinfected with soap and water or alcohol. Whether using forceps or fingers, it is important not to crush the tick since this could contaminate the skin with rickettsiae. A more-recent study suggests that a twisting motion with forceps held as close to the skin as possible is a more-effective and safer method for removing the tick.<sup>65</sup> If the fingers are used for deticking, the skin should be protected with gloves, cloth, or tissue that can be discarded. The hands should always be washed immediately after deticking.

Dogs should be deticked and wear tick-repellent collars. Treating the baseboards and cracks in human and dog quarters with a residual insecticide will help.

Prophylaxis is not a routine practice even after a recognized tick bite. Only 2% to 5% of ticks carry rickettsiae,<sup>21</sup> and only 1%<sup>12</sup> of these rickettsiae are *R*



**Fig. 11-2.** Rocky Mountain spotted fever treatment algorithm. RMSF: Rocky Mountain spotted fever; CSF: cerebrospinal fluid.

*rickettsii*. Therefore, most patients with tick bites would be treated unnecessarily.<sup>29</sup> Experimental work with guinea pigs also does not support prophylaxis.<sup>66</sup>

### Boutonneuse Fever

The boutonneuse group of spotted fevers (which have various names wherever they occur) are caused by *R conorii*. The rash becomes maculopapular and

sometimes even nodular, resulting in the name boutonneuse (ie, buttonlike).

### Microbiology

*R conorii*, the most ubiquitous of the spotted fever serogroup rickettsiae, is easily identified in ticks by means of (a) the light microscope and Giemsa and Stamp stains or (b) immunofluorescence. *R conorii* is antigenically distinct and is less virulent for ani-

mals and humans than *R rickettsii*. Growth in cell cultures is similar to other rickettsiae of the spotted fever group, and it is cultivated in the same ways as *R rickettsii*. The various strains of *R conorii* isolated throughout the world appear to be antigenically identical.

**Epidemiology, Vectors, and Hosts**

Varieties of boutonneuse fever are found in almost every country. The reservoirs are field rodents or dogs. The vector is the brown dog tick, *Rhipicephalus sanguineus*. African tick-bite fever is seen in every region of southern Africa except semi-desert environments. The common veld ticks transmit the disease in rural areas, whereas the dog tick (*Hemaphysalis leachi*) transmits the disease in the suburbs. Other species may be more important in certain geographical areas (Table 11-2). The reservoirs are *Rhabdomys pumilio* (striped mouse), *Otomys irroratis* (vlei rat), and *Rattus rattus*.<sup>67</sup> Dogs and humans acquire the infection incidentally. Adult ticks rarely transmit the infection because they are (a) more host specific and (b) large enough to be felt crawling on the skin, making it likely that they will be removed before they have a chance to attach. Larval ticks are almost invisible and are the primary vectors of this disease, as they are not very host specific and are too small to be felt crawling on the skin. Transovarian transmission occurs in these ticks.<sup>68</sup>

Transmission to humans occurs either via a tick bite or contamination of the conjunctiva with tick juice or excretions. The tache noire is the character-

istic lesion; it manifests as a raised red lesion with a black central crust, but is not seen when the mode of transmission is conjunctival contamination. Typically, the tache noire causes regional lymphadenopathy, systemic manifestations, and rash. The illness lasts approximately 1 to 2 weeks in untreated patients.

Patients can be from urban or rural areas and often have had contact with dogs.<sup>69</sup> In endemic areas such as Sicily, as many as 20% of the populace are serologically positive. However, many of these people do not have any history of boutonneuse fever, making it possible that asymptomatic illness is fairly common or that nonpathogenic strains of *R conorii* exist.<sup>70</sup> The peak period in which boutonneuse fever occurs is June through October.

**Clinical Findings**

Most patients report that they have been in tick-infested areas or that a tick may have been found in their clothing or bed linen within the last few weeks. After an incubation period of approximately 7 days, the tick bite becomes a red papule progressing to black and necrotic. This lesion is completely painless and only rarely pruritic; it may be seen in 30% to 90% of patients and is usually pathognomonic when found with a compatible rash and symptoms. Multiple taches noires have also been reported.<sup>69,71</sup> Some patients with the disease will have only a febrile illness lacking both the eschar and the rash, while others have the tache noire without other signs or symptoms.<sup>70</sup> In adults, the tache noire is usually found on the lower limbs,

**TABLE 11-2**  
**RICKETTSIAE OF SPOTTED FEVER GROUP DISEASES (EXCLUDING RMSF)**

Organism	Disease	Tick
<i>R australis</i>	Queensland tick typhus	Ixodid ticks
<i>R conorii</i>	Boutonneuse fever (Marseilles fever, Mediterranean fever)	Ixodid: <i>Rhipicephalus sanguineus</i>
<i>R conorii</i>	East African tick typhus	<i>Rhipicephalus simus</i> or <i>Hemaphysalis leachi</i>
<i>R conorii</i>	Indian tick typhus	Ixodid ticks, especially <i>Hemaphysalis</i>
<i>R conorii</i> var <i>pyperi</i>	South African tick-bite fever	Ixodid: <i>Rhipicephalus</i> and <i>Amblyomma</i> spp, and <i>H leachi</i>
<i>R sibirica</i>	North Asian tick typhus	Various Ixodid ticks of <i>Hemaphysalis</i> and <i>Dermacentor</i> spp

RMSF: Rocky Mountain spotted fever. Data source: Gear JHS. Other spotted fever group rickettsial diseases: Clinical signs, symptoms, and pathophysiology. In: Walker DH, ed. *Biology of Rickettsial Diseases*. Vol 1. Boca Raton, Fla: CRC Press; 1988: 101–114.

groin, or lower abdomen. In infants, the scalp is a common site.<sup>69</sup> In patients who do not have a clinically obvious tache noire, close examination of the skin drained by enlarged nodes may reveal the lesion. Conjunctival transmission should be suspected in patients with severe unilateral conjunctivitis. Edema of the eyelid may be severe enough to cause chemosis. Shallow ulcers may be apparent on the conjunctiva, and the preauricular nodes on the affected side may be enlarged. One day after the bite, some patients will experience malaise; chills, anorexia, muscle and joint pain, headache, and fever follow. The fever peaks on day 2 or 3 and continues for approximately 10 days. In mild cases, fever may last only 1 to 7 days. The rash appears on days 3 through 5; it is first noted on the extremities, then spreads to the trunk. The rash appears in crops, with new macules and papules noted approximately every 1 to 3 days. The papules tend to be rather coarse and may feel like shotty nodules in the skin. The lesions are pink at first, and later become darker. Characteristically, the patient's palms, soles, and even face are involved.<sup>68</sup> The profuseness of the rash correlates to the severity of the illness. In more-severe cases, the rash may be petechial and dusky.

Usually, boutonneuse fever is a benign, uncomplicated disease with recovery the norm. On occasion it is severe—more often in elderly patients in whom complications are common—and may be fatal if untreated. Adverse prognostic indicators in addition to old age include chronic alcoholism, underlying disease, generalized purpuric exanthema, abnormalities of serum electrolytes, renal failure, and prolonged prothrombin time.<sup>71,72</sup> The most frequent complication is deep venous thrombosis that may or may not be accompanied by pulmonary embolus. Thrombosis may occur in other areas; vision changes may be due to involvement of the retinal veins. Myocarditis can occur, as can electrocardiographic abnormalities, pericarditis, and heart failure.<sup>69</sup> Gangrene of the fingers and toes may also be seen. Severely ill patients may have hypotension; a cyanotic, dusky appearance; and, rarely, may develop a hemorrhagic state. Epistaxis, hemoptysis, hematemesis, melena, and petechial hemorrhages in the skin may be manifestations of this coagulopathy. Jaundice can be seen in more-severe cases. Renal failure is more likely to occur in patients with preexisting renal disease. Death may be due to a combination of severely increased vascular permeability, shock, pulmonary embolism, uremia, and hemorrhage.<sup>68</sup>

As occurs in patients with RMSF (and also in murine typhus and scrub typhus, which are dis-

cussed later), G6PD deficiency may be associated with increased severity of disease.<sup>73</sup> The malignant form of boutonneuse fever bears a clinical resemblance to RMSF with a petechial rash and neurologic, renal, and cardiac involvement.<sup>74</sup>

In Israel, an endemic disease similar to boutonneuse fever is caused by *R sharonii*, which is antigenically distinct from *R conorii*. The Israeli variant is also characterized by fever and rash, but lacks a tache noire.<sup>75</sup>

North Asian tick typhus (also called tick-borne rickettsiosis) is caused by *R sibirica*. This disease is characterized by fever, eschar, regional adenitis, and a macular and papular rash. Some patients may have petechial lesions. Severe forms are uncommon.

Queensland tick typhus is caused by *R australis* and is found only in Australia. It is similar to boutonneuse fever with an eschar seen in most cases. This illness is usually benign, although fatalities have been reported.<sup>76</sup>

### Laboratory Findings

In mild cases of boutonneuse fever and similar diseases, the hemoglobin and hematocrit are unaffected. Anemia can be seen in one third of patients and severe anemia may be seen in patients with underlying diseases or the malignant form of the disease. Leukocyte counts are usually near normal, but neutrophilia may be noticed more often in the elderly, and leukopenia with a relative lymphocytosis is common in adolescents and children. Platelets may be slightly to severely decreased with a decreased prothrombin time in some cases. More severely ill patients can have abnormal liver function tests, especially aspartate transferase and alanine transferase or increased bilirubin. Urinalysis may reveal proteinuria and hematuria. If renal failure ensues, increased creatinine and blood urea nitrogen, oliguria, and anuria may be found. Hyponatremia is seen in roughly one fourth of patients.<sup>77</sup>

### Differential Diagnosis

Secondarily infected insect bites with local adenopathy can cause confusion in making the differential diagnosis. Diseases to be considered, depending on the geographical location, are anthrax, bubonic plague, sporotrichosis, trypanosomiasis, venereal disease (herpes simplex, lymphogranuloma venereum, chancroid, syphilis), coxsackie A or echovirus infections in children, and arbovirus infections.

### Diagnostic Tests

The diagnosis of boutonneuse fever is usually made clinically. When available, direct immunofluorescence of skin biopsy specimens can be used.

Rickettsiae can be demonstrated in the skin, using tissue obtained from the periphery of the tache noire<sup>70</sup> or macular elements of the rash.<sup>78</sup> This provides the earliest diagnosis but is usually only available from reference labs. Isolation of the organism may be attempted in guinea pigs. Such testing is useful before antibiotics are administered, in more-severe cases, and in questionable cases that lack the tache noire.<sup>79</sup>

Serologic diagnosis is accomplished using specific tests such as complement fixation, latex agglutination,<sup>80</sup> indirect fluorescent antibody,<sup>50</sup> or microimmunofluorescence. Microimmunofluorescence is not readily available and is difficult and time consuming to perform. Antibody titers become positive after 10 days and may persist for years after the initial attack.<sup>68,81,82</sup>

Weil-Felix testing should be used for screening purposes only.<sup>68</sup> Equal titers of OX-19 and OX-2 are usually found. If OX-19 is found singly, or if the titer of OX-2 is much greater than that of OX-19, then the diagnosis of tick typhus is probable. If OX-19 titer is much higher than OX-2, then both epidemic and murine typhuses would be more likely considerations (epidemic and endemic typhuses are discussed later in this chapter). The Weil-Felix test is not specific and should *not* be relied on for diagnosis. Low titers are often seen in healthy people in areas where this infection is common.

### Therapy

Quarantine of patients is unnecessary. Ironing all clothing and bed linens will kill any remaining larvae. Most patients will respond promptly to antibiotic therapy and show improvement within 48 hours. Tetracycline is the antibiotic of choice and chloramphenicol is a useful alternative. Treatment with two 200-mg doses of doxycycline may be as effective as the usual 10-day treatment with tetracycline.<sup>72</sup>

### Prevention

Control measures for these tick-borne diseases are the same as those for RMSF. Infested dogs, cats, and rats should not be allowed inside dwellings. Tick repellents and proper clothing are also helpful. Vaccines have been developed and may be considered for military operations.

### Rickettsialpox

Rickettsialpox is a febrile illness that is characterized by cutaneous eschar followed by a papulovesicular exanthem. This disease was not discovered until after World War II, so there are no figures regarding its occurrence among troops.<sup>83</sup>

### Microbiology

*R akari*, which causes rickettsialpox, is a coccobacillary organism that is morphologically similar to *R rickettsii*. It is serologically cross-reactive with other spotted fever organisms due to the presence of a group-specific antigen. The *R akari* organism is a small, coccobacillary, obligate intracellular parasite that stains with Giemsa and Machiavello's stains. It is infective for mice and guinea pigs and grows in the developing chick embryo. The mouse is highly susceptible to infection and is considered to be the animal of choice for isolation.

### Epidemiology, Vectors, and Hosts

The vector for rickettsialpox is the mouse mite, *Allodermanyssus sanguineus*. The host is the house mouse, *Mus musculus*. The disease is transmitted to humans by the bite of the mite. This illness is rarely seen outside cities in the United States, where improvements in housing have limited the scope of the house mouse and its mites. Rickettsialpox has become a disease of the inner city, with most cases now seen in New York City.<sup>59</sup> All ages and both sexes are equally susceptible to infection.

### Clinical Findings

Estimates on the incubation period are difficult because the bite of the vector, *Allodermanyssus sanguineus*, is painless and the mite is microscopic, so it cannot be felt on the skin. Laboratory accidents and cases that have been well documented after exposure suggest that the incubation period is 7 to 14 days.<sup>84</sup>

A papule at the bite site may appear within 1 to 2 days. This lesion is usually asymptomatic although some patients will complain of pruritus. A vesicle develops over the papule, which subsequently dries and forms a crust or eschar. Induration surrounds the lesion and there is regional lymphadenopathy. The eschar can appear anywhere, but areas covered with clothing seem to be preferred by the mite.<sup>84</sup>



Fever and malaise are common, with temperature elevation as high as 106°F reported. Morning remissions are common. Headache, stiff neck, backache, myalgias, and photophobia may also be seen. Occasionally, cough, nausea, vomiting, and abdominal pain are reported.<sup>84</sup>

The rash usually appears 2 to 3 days after systemic symptoms are seen. The typical morphology of the early lesions is a firm, erythematous, nonpruritic papule. A small vesicle or pustule will be present in some of the lesions, although not all will vesiculate. Rarely, the lesions may resemble “rose spots” of typhoid, presenting as faint macules. The vesicular lesions resolve without scarring. The lesions are seen on the face, trunk, and extremities most commonly, but palms, soles, and mucous membranes may also be involved.<sup>84</sup>

### Laboratory Findings

Routine laboratory findings are nonspecific in this disease. Leukopenia is common in the early stages.

Histological examination of the eschar will show swollen endothelial cells, capillary fibrin thrombi, and a dense perivascular infiltrate of lymphocytes, mononuclear cells, and a few polymorphonuclear cells. Rickettsial organisms have not been identified in cutaneous lesions. Histologically, the vesicles show a mononuclear infiltrate along the subepider-

mal region, with vacuolar changes in the basal cells. The vesicle seems to form subepidermally,<sup>9</sup> but intraepidermal locations have been described.<sup>84</sup>

### Differential Diagnosis and Treatment

Other rickettsial diseases with eschars (taches noires) should be considered; scrub typhus, tick typhus (Siberian or Queensland), and boutonneuse fever may have eschars that cannot be distinguished from that of rickettsialpox. Chickenpox is commonly confused, but the lack of an eschar and the finding of multinucleated giant cells on the Tzanck preparation should make this diagnosis. Direct fluorescent antibody staining for varicella-zoster virus could also be used to confirm varicella.

Complement fixation or indirect fluorescent antibody testing can be used to identify this infection. Cross-reactions with other spotted fever group rickettsiae occur. A cross-absorption technique using *Rickettsia* and *R. akari* antigens can be performed to allow more-accurate diagnosis.<sup>85</sup> In most cases, the clinical syndrome and a rise in group-specific indirect fluorescent antibody titers will make the diagnosis. Weil-Felix antibodies do not develop in this disease.

This is a mild illness from which even untreated patients recover without difficulty. Treatment with tetracycline will speed defervescence and recovery.

## TYPHUS SEROGROUP

Typhus serogroup organisms are responsible for epidemic typhus, the recrudescence form of epidemic typhus called Brill-Zinsser disease, and endemic (murine) typhus. The organisms are characterized by a common, group-specific antigen and intracytoplasmic growth. The pathology of these diseases is also that of a vasculitis, as in spotted fever group infections. Both epidemic and endemic typhuses have a rash that begins on the trunk and spreads to the extremities, in contrast to the rash of RMSF, which is found first on the extremities.

### Epidemic Typhus

Epidemic typhus has many common names: louse-borne typhus, classic typhus, typhus exanthematicus, tarbardillo, fleckfieber, and jail fever. Both the primary disease and its recrudescence form (Brill-Zinsser disease) are caused by *R. prowazekii*. Clinically, epidemic typhus is quite similar to murine typhus except that it tends to be

more severe. Epidemic typhus can also be similar to RMSF, except that the truncal distribution of the rash characterizes epidemic typhus. Mortality rates for this disease vary from 10% to 40% in untreated patients.<sup>86</sup> Epidemic typhus associated with flying squirrels (ie, sylvatic typhus) generally tends to be a milder disease.

Several important investigators perished while studying this disease, the most notable being Howard T. Ricketts, who died in 1910 while studying typhus in Mexico,<sup>87,88</sup> and Stanislaus von Prowazek, who died in 1915 while studying typhus in Siberia and Turkey.<sup>86,89</sup>

### Military Significance

Although typhus infections have played an important role in every major European military campaign since the 16th century, epidemic typhus has never been a serious problem for the U.S. military.<sup>90</sup> Early accounts of the disease are difficult to classify

definitively as typhus. In 1492, a malignant spotted fever in Spain killed 17,000 troops during the conquest of Granada. This number is roughly 5-fold greater than the number of battlefield casualties. Typhus was also a major factor in Napoleon I's invasion of Russia in 1812. In a period of approximately 7 weeks, more than 60,000 Russian troops died, mostly from typhus. The disease was then spread throughout Europe by French and Russian prisoners of war. In Germany during 1813 and 1814, 2 million people are estimated to have contracted the disease and 250,000 died.<sup>88</sup>

During the American revolution, a typhuslike illness forced continental forces in New York to retreat from the British, prolonging the war by an estimated 2 years.<sup>91</sup> There was little typhus noted among the soldiers in the Civil War; however, well-described cases underscore the difficulties of medical practice in the preantibiotic era. The commonly used medications included quinine, turpentine emulsion, brandy, whiskey, tannin, and beef soup.<sup>92</sup>

The toll extracted by typhus during World War I was great. An epidemic of typhus in Serbia claimed an estimated 180,000 to 210,000 lives in 1915, including one third of the Serbian physicians.<sup>93</sup> In 1909, the body louse was discovered to be the vector of the disease.<sup>88</sup> This discovery led to the quarantine of louse-infested patients and the burning of infested clothing. However, 3 million deaths and 25 million cases of typhus were reported in Russia from 1917 through 1925.<sup>88</sup> Surprisingly, little or no typhus was reported among U.S. military personnel despite widespread lousiness (pediculosis) among the troops.<sup>83</sup>

Significant advances were made in the control of rickettsial diseases, especially epidemic typhus, during World War II. (The mild, recrudescing form of typhus, Brill-Zinsser disease, had no effect on military operations.<sup>83</sup>) DDT was first used as a dusting agent on the clothes of infested persons during the winter of 1943 and 1944, when an epidemic in Naples, Italy, was suppressed with its use.<sup>83</sup> Scrub typhus was similarly controlled in the Pacific using miticidal dusting agents.<sup>18</sup> Much of this progress resulted from investigations done under the auspices of the U.S. Typhus Commission, which was established in 1942. Contributions made by this commission led to a better understanding of the disease and resulted in improved louse control, personal hygiene, treatment, and vaccines. U.S. Army research played a key role in these accomplishments, especially in the development of the vaccine and purifying the antigen, which allowed the diagnostic serologic test to be developed.<sup>94</sup> Vac-

inations started in January of 1942.<sup>83</sup> During 1942 alone, there were 23,000 civilian cases of typhus in Egypt and 77,000 cases in French North Africa. From 1942 through 1945, U.S. troops had only 30 cases, none of which was fatal.<sup>88,93,95</sup> These numbers are truly amazing, considering that when the Allied forces undertook the North African invasion, there were estimates that the unreported cases of typhus may have totalled over 500,000.<sup>83</sup>

During World War II, Polish physicians used their knowledge of immunology to keep German authorities away from several villages. Knowing that the Germans did not wish to have their personnel in an epidemic area, the Polish physicians administered Proteus OX-19 antigen to persons in these villages who showed symptoms that might be compatible with typhus. German health authorities were then given sera from these patients to test, and they found high titers against OX-19, suggesting louse-borne typhus. Due to the number of positive sera the Germans tested, they considered the villages to be epidemic areas. Fortunately for the Poles, the Germans never examined any of the patients, nor were they suspicious of the uniformly high initial titers in all the patients.<sup>96,97</sup>

German concentration camps reportedly had thousands of cases of typhus. When camps were liberated, extensive delousing efforts were necessary to prevent spread of the infection throughout Europe. These efforts were complicated by the fact that many of the prisoners fled the camps and scattered throughout the countryside.<sup>83</sup>

The U.S. Army was not affected by typhus during the Korean and Vietnam conflicts.<sup>93</sup>

### Microbiology

*R prowazekii* is an obligate intracellular bacterium that appears antigenically to be closely related to *R typhi*. It is classically described as a coccobacillary form measuring approximately 0.25 × 0.35 μm, although it is the most pleomorphic of the rickettsiae. It also stains with Geimsa and Machiavello's stains. The organism is infective for mice, guinea pigs, and embryonated eggs. Stored at -70°C, *R prowazekii* may remain viable for years, but it is destroyed by phenol, formalin, merthiolate, and other antiseptics.<sup>98</sup>

### Epidemiology, Hosts, and Vectors

Epidemic typhus is a disease of the colder months, poor sanitation, wars, and times of social upheaval. These conditions favor poor hygiene and crowding,

factors conducive to the spread of louse infestation. The last reported epidemic of louse-borne typhus occurred in the United States in 1922. Sporadic cases of the disease have occurred since then, as have cases of the recrudescence type (Brill-Zinsser disease) or typhus associated with flying squirrels.<sup>99</sup>

Hosts for *R. prowazekii* include humans, the flying squirrel (*Glaucomys volans*),<sup>3</sup> and the body louse (*Pediculus humanus corporis*).

Lice are very host specific; usually they remain on the same host and do not leave voluntarily unless the host's temperature changes significantly. Thus, lice tend to leave hosts who are febrile and those who have died. Transfer between humans occurs during conditions of close contact, poor sanitation, and overcrowding. Both the human body louse (*Pediculus humanus humanus*) and the head louse (*P. humanus capitis*) can be infected with *R. prowazekii*. The head louse has not been implicated in the transmission of typhus, leaving the body louse as the main vector for humans. The louse acquires the infection from feeding on an infected human and becomes infective itself in 5 to 7 days. The infected louse then feeds on an uninfected human, defecating while feeding. Transmission to humans occurs by contamination of the bite site with the infected feces, not from the bite itself. Transmission may also occur when infective louse feces contaminate the conjunctiva or mucous membranes or when the louse is crushed. Aerosolized spread is possible if infected louse feces become airborne when clothing is shaken.<sup>100</sup>

Lice feed approximately every 5 hours. They will acquire *R. prowazekii* 60% to 80% of the time after a single feeding, so the ultimate rate of acquisition of infection is near 100%. However, patients with Brill-Zinsser disease will infect lice with *R. prowazekii* only 1% to 5% of the time.<sup>101</sup>

Once *R. prowazekii* enters the louse, infection is limited to the gut epithelial cells, which eventually become full of rickettsiae and rupture, discharging the organisms into the feces. The feces remain infective for up to 100 days. Infected lice die within 14 days.<sup>101</sup>

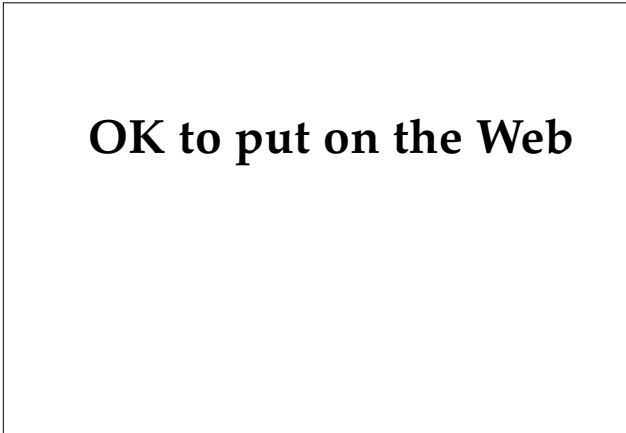
In the flying squirrel, the infection is transmitted by the squirrel louse, *Neohaematopinus sciuropteri* and, to a lesser degree, by the squirrel flea, *Orchopeas howardii*. Most cases of human infection occur in the eastern United States when flying squirrels enter attics in the winter months. The exact mechanism of transmission of the disease is unknown but could involve the squirrel flea, which has been reported to parasitize humans.<sup>99</sup> The squirrel louse does not feed on humans and is unlikely to be involved.

Ground squirrels (eg, chipmunks, prairie dogs) or tree squirrels (ie, gray squirrels) are not hosts for *R. prowazekii*. When infections due to flying squirrels are encountered, they are not associated with human-to-human spread, because pediculosis is not a major health problem in the eastern United States.<sup>4,99</sup> Several cases of epidemic typhus thought to involve the flying squirrel have been reported.<sup>4,102,103</sup>

### Clinical Findings

The incubation period is usually approximately 7 days (range 3–11 d). Compared with murine typhus (which is discussed later), the onset of epidemic typhus is more dramatic; prostration occurs early with more-severe symptoms noted. The temperature rises rapidly over the next 1 to 2 days, and the rash may appear on approximately day 5 of the illness. The rash is first seen on the trunk and axillary folds as erythematous macules (Figure 11-3). These become petechial in a day or so. During the second week of illness, the lesions tend to become confluent, hemorrhagic, and occasionally necrotic. The lesions spread in a centrifugal pattern from the trunk to the extremities, but they are only rarely seen on the palms, soles, or face. As in RMSF, the eruption may be absent in 10% of patients.<sup>98</sup>

Neurological involvement can be significant. Severe delirium, maniacal episodes, or coma can occur. Respiratory involvement is fairly common, with a hacking, nonproductive cough. Hemoptysis may occur secondary to bronchial erosion. Rales



**OK to put on the Web**

**Fig. 11-3.** The petechial lesions seen on the trunk are characteristic of epidemic typhus, which developed in this patient during World War II. Photographs: Courtesy of Walter Reed Army Medical Center Dermatology Service, Washington, DC.

may be appreciated in the lower lung fields, usually during the second week of illness. Cardiovascular involvement characteristically produces hypotension with a weak, rapid pulse. Peripheral cyanosis and cold sweats occur, as they do in murine typhus. Abnormalities may be found on the electrocardiogram. Photophobia, eye suffusion, conjunctival injection, and deep eye pain may be present. Transient partial deafness is common in patients with epidemic typhus. Gastrointestinal findings include nausea, vomiting, abdominal pain, constipation, and splenomegaly. The liver is usually not enlarged.<sup>104</sup>

Otitis media, parotitis, and pneumonia can occur due to secondary bacterial infections. In addition, bronchiolitis, vascular collapse and shock, gangrene, and azotemia may be observed in untreated individuals. With treatment, mortality from epidemic typhus is essentially zero.<sup>105</sup>

### Laboratory Findings

Leukopenia can be found early in the illness; the leukocyte count is normal late in the disease. Urinalysis findings include albuminuria and, rarely, hematuria. Serum chemistry may be remarkable for hypochloridemia and hypoalbuminemia. Azotemia may also be noted.

### Differential Diagnosis

Typhoid, meningococemia, boutonuse fever (without eschar), malaria, measles, yellow fever, relapsing fever, and epidemic typhus acquired from flying squirrels all may need to be considered in the differential diagnosis. Suspicion regarding epidemic typhus should be raised when medical officers encounter patients who seem to have atypical cases of RMSF or murine typhus. When diseases resembling RMSF occur during an unusual season (ie, winter) or in an area with an extremely low incidence of RMSF, serologic data should be closely scrutinized. Additionally, patients (a) with compatible symptoms who lack a history of tick bite or exposure, (b) without a rash, or (c) who have a centrifugally spreading rash should also be suspected of having epidemic typhus.<sup>4</sup>

### Laboratory Diagnosis

Immunofluorescent staining can detect *R prowazekii* in the gut of lice that have been collected from patients suspected of having classic epidemic typhus. This could allow the diagnosis to be made within a matter of hours.<sup>106</sup>

Serologic testing using either complement fixation or the indirect immunofluorescent test will also confirm this diagnosis. Note that cross-reactions with murine typhus and spotted fever serogroup organisms are possible; the toxin neutralization test can help distinguish cross-reactions to murine typhus.<sup>4</sup> Titers for *R rickettsii* are usually much lower than those to *R prowazekii*. The same tests are also used for diagnosing epidemic typhus associated with flying squirrels.

Weil-Felix testing shows positive titers for only OX-19, usually after 10 to 14 days. False-positive reactions may make interpretation difficult in certain areas (see the previous discussion of the serologic diagnosis of RMSF).

Isolation of the organism should be attempted only by experienced personnel with the proper facilities. Storing clotted blood from an infected patient at  $-70^{\circ}\text{C}$  will maintain the viability of the organisms for years. Refrigerated clots must be used for isolation attempts within a few days.

### Treatment

Tetracycline or chloramphenicol in appropriate doses should be continued until the patient is afebrile for more than 24 to 48 hours. Relapses may occur, especially when treatment is started early in the course. Because antibiotic resistance does not develop, relapses usually respond to continuation of the antibiotic. In some situations (eg, natural disasters, refugee populations), single-dose therapy with doxycycline (100–200 mg) is an effective therapy that may be preferable if medical supplies are limited. The severe headache does not respond to the usual drugs. Severely toxic patients may require treatment with systemic steroids.<sup>107</sup>

### Control Measures

Where conditions favor lousiness, an effective residual insecticide should be applied to the body and clothing. Personal hygiene should be maintained at adequate levels. Typhus vaccine that prevents or attenuates the disease is available but is not routinely administered to military personnel.<sup>105,107</sup>

Epidemic typhus is a reportable illness and local health authorities must be notified. Isolation of patients is not necessary; however, the patient should be deloused as should the patient's clothing, quarters, and close contacts. Disinfection should include insecticide powder and treatment of nits using pyrethrin shampoo or lindane. Even the

corpses of patients who die before delousing should be deloused appropriately.

Louse-infested persons who are both susceptible and exposed to typhus fever should be deloused with residual insecticides and observed for 15 days. All immediate contacts should be deloused, if necessary, and observed for 2 weeks.<sup>63,98</sup>

### Recrudescence Typhus (Brill-Zinsser Disease)

Brill-Zinsser disease, the recurrent form of epidemic typhus, appears years after the original infection. Brill-Zinsser disease is not related to louse infestation and has been reported only sporadically in the United States. It should be suspected in patients with a previous history of epidemic typhus, especially among survivors of concentration camps or immigrants from eastern Europe.<sup>108</sup> The disease is caused by the reactivation of *R prowazekii* that remains in the lymphoid tissue of previously infected persons. Thus, humans act as a reservoir for epidemic typhus, since infected patients may be responsible for transmitting the infection to uninfected body lice. Clinically, Brill-Zinsser disease is much milder than the original illness and the rash is usually absent. Serologic testing will reveal extremely high immunoglobulin G titers for *R prowazekii* because the recrudescence is an amnestic antibody response. Titers of immunoglobulin M antibody will be low or absent. Weil-Felix testing is negative in patients who have Brill-Zinsser disease.

### Endemic (Murine) Typhus

Murine typhus is a phylogenetically older and milder disease than epidemic typhus. Both the vector (the rat flea) and the reservoir (the rat) survive the infection by *R typhi* without ill effects, whereas infection with *R prowazekii* causes the death of the louse and more severe illness in humans.

Murine typhus usually occurs sporadically rather than in epidemics. Prior to 1940, all forms of typhus were considered together in U.S. Army medical statistics. During World War II, 787 cases of typhus were reported, with 15 deaths.<sup>93,109</sup> Troops on maneuvers in the southern United States at this time accounted for 497 of these patients. Troops stationed in the Hawaiian Islands accounted for 123 cases during 1942 through 1945.<sup>83</sup>

Data on the incidence of murine typhus during the Korean conflict are not available, but murine typhus was the second-most-common cause of febrile illness in U.S. Army personnel in Vietnam.<sup>110</sup>

Murine typhus can also be a major cause of fe-

brile illnesses in refugee camps. One study of adults in a camp in Thailand for displaced Khmers (Cambodians) found the 1-month attack rate for adults to be 185 per 100,000.<sup>111</sup>

### Microbiology

*R typhi* (*R mooseri*) measures 0.4 by 1.3  $\mu\text{m}$ , and is a Gram-negative, obligate intracellular parasite. It is less pleomorphic than *R prowazekii* and shares common soluble antigens with that organism. *R typhi* is destroyed by formalin, phenol, and temperatures greater than 56°C for 30 minutes. *R typhi* is infective for rats, mice, guinea pigs, and yolk sacs of embryonated eggs<sup>98</sup> and is more virulent than *R prowazekii* for guinea pigs and mice.

### Epidemiology, Vectors, and Hosts

Murine typhus is common in the United States, and this disease has the highest worldwide prevalence of all the rickettsial diseases. It is seen on every continent except Antarctica.<sup>110</sup>

The hosts in this disease include a large spectrum of animals. Rats (*Rattus norvegicus* and *Rattus rattus*) are the animal reservoir. Shrews, skunks, opossums, mice, and cats are fed on by various arthropod vectors and can serve as hosts.<sup>110,112</sup> In rats, infection is nonfatal and rickettsemia lasts only 1 to 2 weeks.<sup>101</sup> The infection is spread when fleas feed on infected rats. *R typhi* infects the gut epithelial cells and is excreted in the feces. Infection is not fatal for the flea and persists for life without affecting life span. Transmission to humans occurs when the skin, respiratory tract, or conjunctiva are contaminated with infected flea feces. *Xenopsylla cheopis* (the oriental rat flea) is the major vector. *Leptopsylla segnis* (the mouse flea), *Ctenocephalide felis* (the cat flea), and *Pulex irritans* (the human flea) are also implicated as potential vectors based on laboratory data. *L segnis* fleas are not thought to be an important vector in the United States, owing to their semisessile nature, but they may be more important in locations where *X cheopis* fleas are absent.<sup>101</sup> Transmission is thought to occur when infected feces are rubbed into the bite, but recent investigators have shown that the organism can be transmitted by flea bites alone.<sup>110</sup> Infection via inhalation of dust from rat-infested buildings may occur.<sup>110</sup> In the wild, however, fecal contamination remains the most important means of transmission. The infection may be transmitted transovarially in fleas, suggesting that fleas may also serve as reservoirs for the disease.<sup>113</sup>

Most cases are reported between late spring and early autumn when *X cheopis* is abundant. Endemic areas are primarily urban settings associated with commensal rats and their fleas. Rural areas may also be affected, however. Sea ports and coastal areas are favored. People whose occupation or living conditions bring them into close contact with rats or rat runs are primarily affected, especially in food-storage areas or granaries. Most human cases are acquired indoors where rats are present. Areas with higher incidences of this disease include South America, Mexico, Ethiopia, Malaya, Australia,<sup>98</sup> Thailand, India, Pakistan, and the southern United States.<sup>112</sup>

### **Clinical Manifestations**

The typical incubation period is approximately 11 days (range 8–16 d). Prodromal symptoms begin with frontal headache, severe backache, and arthralgias approximately 4 to 6 days after exposure.<sup>104</sup> Usually, the patient notes a sudden, shaking chill but may have only a chilly sensation. Headache, fever, nausea, and vomiting are seen in nearly all patients. The patient's temperature increases steadily over the first few days and may become intermittent when the rash appears, with the morning temperature tending to be normal. Children may have fevers as high as 106°F, while that of adults peaks at 103°F to 104°F. Fever usually lasts approximately 12 days.

The rash makes its appearance after approximately 5 days of illness. It is seen first in the axillae and inner arms. Dull, red macules develop rapidly on the abdomen, shoulders, chest, arms, and thighs. The earlier lesions tend to be macular while older lesions are slightly raised. Approximately 20% of patients will lack the rash.<sup>104</sup> The spread of this rash is from trunk to extremities, the opposite of that seen in patients with RMSF. Only rarely will the rash involve the palms, soles, or face. Petechiae may develop in some cases, and the lesions may become hemorrhagic.<sup>114</sup>

Of the neurological findings, headache usually predominates. Patients with more severe illness may progress to stupor, prostration, and lethargy. Some may have neck stiffness, but Kernig's sign is usually not present. Transient, partial deafness and weakness have been reported.<sup>104</sup>

A hacking, nonproductive cough is not uncommon. Rales may be appreciated in the lower lung fields. Hypotension occurs, especially in the early stages. Clinical evidence of cardiac failure is unusual, however. Minimal electrocardiographic ab-

normalities, peripheral cyanosis, and cold sweating can be seen. Nausea, vomiting, abdominal pain, constipation, and splenomegaly are fairly common findings.

Although secondary bacterial infections leading to otitis media, parotitis, and pneumonia can complicate the illness, murine typhus is a benign disease for most, with complete recovery the norm.

### **Laboratory Findings**

Laboratory findings are nonspecific for murine typhus. Moderate leukopenia may be noted initially, with a normal leukocyte count later in the illness (except when secondary bacterial infection occurs). Urinalysis may show albuminuria and, rarely, hematuria. Hypochloridemia and azotemia can occur.

### **Differential Diagnosis**

Other diseases to be considered are typhoid, meningococemia, boutonneuse fever (when lacking an eschar), mild epidemic typhus, flying squirrel-associated epidemic typhus, RMSF, and scrub typhus.

### **Diagnosis**

Indirect fluorescent antibody can be used to diagnose murine typhus, but it requires cross-absorption with homologous and heterologous antigens to distinguish murine from epidemic typhus. Patients who have been previously vaccinated against epidemic typhus respond to murine typhus with antibodies that react in higher titers with *R prowazekii*.<sup>50</sup> Clotted blood obtained prior to antibiotic therapy can be used for attempted isolation of the organism. After the blood has clotted and the serum has been removed, the clot may be stored at -70°C.<sup>115</sup>

### **Treatment**

Tetracycline or chloramphenicol are administered in appropriate doses until the patient is afebrile for longer than 24 hours. For critically ill patients who do not present until late in the illness, systemic steroids administered for 2 or 3 days may be a useful additional therapy; however, this regimen is not recommended for mild or moderately ill patients.<sup>104</sup> After recovery, permanent immunity to murine typhus exists, with cross-immunity to epidemic typhus.

### Control Measures

Flea populations should be reduced, using insecticides to prevent additional exposure to fleas. After this is accomplished, insecticide powders with residual action should be used on rat runs and

burrows. Attempts to treat rat-infested areas before the flea population is controlled will result in additional cases of disease when hungry fleas turn to humans in the absence of their usual host.<sup>112</sup> Isolation or quarantine are not necessary for the patient or his or her contacts.<sup>63</sup>

## SCRUB TYPHUS, TRENCH FEVER, AND Q FEVER SEROGROUPS

Scrub typhus, trench fever, and Q fever each comprise a separate serogroup. These diseases are distinct from each other and from other rickettsial diseases; they are grouped together in this chapter for convenience only.

### Scrub Typhus

Scrub typhus, caused by *R tsutsugamushi*, is in a distinct serogroup separate from the typhus and spotted fever serogroups. The disease is also known as tsutsugamushi disease, tropical typhus, rural typhus, Japanese river fever, and Kendani fever.<sup>95</sup> The mortality rate varies in untreated patients, ranging from 1% to 60%; with treatment, however, the mortality is less than 5%.<sup>98</sup> Aside from the antigenic differences that were discussed earlier in this chapter, this organism possesses a distinctive cell wall structure when compared to other rickettsiae. In addition, scrub typhus is transmitted by the larval form of trombiculid mites, which are commonly called chiggers. Trombiculid mites also serve as a reservoir for this disease.

### Military Significance

Scrub typhus affects not only military personnel but also indigenous rural populations. The chigger that is the vector for this disease is found in southeast Asia, Japan, Malaysia, China, eastern Russia, Australia, Sri Lanka, Indonesia, Korea, India, and the Philippines. The term "scrub typhus" was used by Allied troops to describe the vegetation where the mites are usually found. Scrub typhus was feared by military personnel during World War II because there was no effective therapy and death was possible. Full convalescence often took more than 2 months and had significant impact on affected units.

Among Allied troops in World War II, 18,000 cases of this disease were reported, with a fatality rate that varied from 1% to 35%. According to U.S. Army statistics, 5,718 cases occurred in the south-

west Pacific area.<sup>90</sup> In some areas the attack rate was quite high, with 25% to 33% of two U.S. Army Air Force squadrons in this region hospitalized in 1944.<sup>88</sup> Cases of scrub typhus were also reported from the Philippines and the India-Burma theater.<sup>95</sup> During this time, scientists from the United States and Britain investigated this disease and advanced our knowledge of the epidemiology and treatment of scrub typhus. In 1948, a U.S. Army-sponsored investigative team working at Walter Reed Army Institute of Research (WRAIR), Washington, D. C., and Kuala Lumpur, Malaya, discovered that chloramphenicol was an effective treatment for scrub typhus. Joseph E. Smadel and his colleagues at WRAIR and the University of Maryland showed that this drug also cured murine typhus and RMSF.<sup>94</sup>

Scrub typhus had little effect on military operations in Korea.<sup>93</sup> During the Vietnam conflict, the incidence of scrub typhus was dwarfed by the incidence of malaria and diarrheal illnesses in this region.<sup>116</sup> Still, a 6% incidence of scrub typhus was found in patients hospitalized for malaria.<sup>90</sup> The actual number of reported cases is probably underestimated because the Weil-Felix test was positive only half the time with scrub typhus, and many cases were diagnosed and treated without serologic confirmation or even hospitalization. No deaths were reported from this disease.<sup>90</sup> The use of a repellent seems to have helped prevent chigger infestation, but sometimes soldiers did not use repellents for fear that the enemy would detect the odor.<sup>117</sup>

### Microbiology

Several strains of *R tsutsugamushi* are antigenically similar, producing short-lived cross-immunity. Three major serotypes (ie, Karp, Gilliam, and Kato) have a sufficient degree of cross-reactivity with other strains to allow the indirect immunofluorescent test to be used diagnostically. This obligate intracellular parasite is distinguished from other rickettsiae by its growth in the cytoplasm without a surrounding vacuolar membrane. In

addition, the outer layers of *R tsutsugamushi* are significantly different from those of other rickettsiae. The outer leaflet is very thick with a thin inner layer, the opposite of other rickettsiae. *R tsutsugamushi* can be stained with Giemsa's stain or by using the modified Gimenez procedure that is used for other rickettsiae.

### **Epidemiology and Vectors**

Several mites of the genus *Leptotrombidium* are vectors of scrub typhus: *L akamushi*, *L arenicola*, *L deliense*, *L fletcheri*, *L pallidum*, *L pavlovskyi*, and *L scutellare*. The mites are parasitic for humans only as larvae. They do not exhibit specific host-seeking behavior. Instead, they wait patiently on grass stems or leaves for a host to walk by. They tend to congregate in small areas, creating "mite islands." Shrubs or transitional vegetation are their preferred environment. In particular, overgrown fields, border areas at the edges of forests, and margins of streams are areas where the mites may be found in great numbers. Two days after hatching, the mites feed on tissue juices of the host for 2 to 12 days, then drop off the host and enter a pupalike stage that lasts for 5 to 7 days. Then they become nymphs and enter a second pupalike stage, after which they emerge as adults. The nymphs and adults are scavengers of the forest floor and do not feed on humans.<sup>11</sup>

The host for *R tsutsugamushi* is the genus *Rattus*, in which long-lasting infection is produced. Chiggers also feed on pigs, rabbits, shrews, and birds; these animals can also carry the organism.

Infection in the larva is acquired as an egg in the infected female; the larva is the only stage capable of transmission, and the larva feeds on a host only once. Transovarial transmission seems to be the only mechanism for the maintenance of the organism in nature.

Scrub typhus is a disease of the Far East that has not been found in the western hemisphere. People whose occupations place them in contact with infected mites remain the most susceptible group for this infection.

### **Clinical Findings**

An eschar, which is seen in scrub typhus, tick typhus, and rickettsialpox, begins as a red papule and becomes a punched-out ulcer that develops a hard crust (Figure 11-4). The crust may be lacking in moist intertriginous areas.<sup>116</sup> This lesion is pain-

less and is seen in 95% of patients with rickettsialpox but only in approximately 50% of patients with scrub typhus.<sup>104</sup>

The rash—a maculopapular eruption that is neither hemorrhagic nor petechial—may be prominent or completely absent; it was reported in fewer than 40% of Americans in Vietnam.<sup>117</sup> However, the rash is uncommon when the disease occurs in the indigenous population.

A prodrome of headache, chills, and anorexia begins insidiously. Later, fever, cough, and generalized lymphadenopathy are seen. Characteristic clinical findings in patients without eschars are lacking, making this disease difficult to diagnose in such cases.<sup>118</sup>

### **Laboratory Findings**

Routine laboratory findings are not helpful diagnostically. Lymphocytosis is common, with atypical lymphocytes seen somewhat frequently. There may be mild elevations of the liver function tests.

### **Differential Diagnosis**

Other diseases to be considered and ruled out are murine typhus, leptospirosis, arborviral infection, typhoid, and malaria. When the rash is absent, generalized lymphadenopathy and the presence of atypical lymphocytes may suggest the diagnosis of infectious mononucleosis.<sup>116</sup>



**OK to put on the Web**

**Fig. 11-4.** Characteristic eschar (tache noire) of scrub typhus. Similar lesions are seen in tick typhus, boutonneuse fever, and rickettsialpox. Photographs: Courtesy of Walter Reed Army Medical Center Dermatology Service, Washington, DC.



## Diagnosis

An indirect fluorescent antibody titer of 1 to 400 or greater is 96% specific and 48% sensitive for the diagnosis of scrub typhus.<sup>50</sup> In poorer regions that lack funds for fluorescent microscopes, an alternative test, the indirect immunoperoxidase kit, is available. This kit has been in use in the Malaysian region since 1986 and has been shown to have acceptable sensitivity and specificity as well as a long shelf life.<sup>119</sup> The indirect immunoperoxidase kit and the indirect fluorescent antibody test were the recommended tests endorsed by the World Health Organization, which specifically advised against the use of the Weil-Felix reaction when other, more sensitive tests are available.<sup>120</sup>

Weil-Felix tests in patients with scrub typhus will reveal positive OX-K agglutinins in some, but in general, the sensitivity is rather low; positive results are seen in only 40% to 60% of patients.<sup>6,116</sup> However, because it is a simple test to perform, the Weil-Felix test is still the main test used in some areas of the world.

## Treatment

Chloramphenicol can be given in a dose of 500 mg every 6 hours for 7 days, and has the advantage of covering both typhoid and meningococcus infections. Tetracycline seems to be more efficacious and is given in a dose of 500 mg every 6 hours for 7 days. Doxycycline has been used successfully as a single, oral dose in treating both louse-borne and scrub typhus.<sup>121,122</sup>

Recrudescence is likely when the patient is treated within the first 3 days of illness; a second course of antibiotics may be required. Recrudescence may also occur with single-dose therapy under similar circumstances.<sup>63,116,123</sup>

## Control Measures

Effective chigger repellents that can be applied to the body include diethyltoluamide and dimethylphthalate. Clothing and bed linen should be impregnated with permethrin and benzyl benzoate, which are miticidal. Mite-infested areas may be treated with lindane, dieldrin, or chlordane.<sup>63</sup> Experimental evidence indicates that chiggers may need to remain attached to humans for 6 to 8 hours before *R tsutsugamushi* is transmitted.<sup>124</sup> Therefore, bathing after exposure may be helpful in preventing the disease. Chemoprophylaxis against scrub

typhus and leptospirosis is possible using doxycycline in weekly doses of 200 mg. This prophylactic regimen is not used routinely for indigenous populations but would be beneficial for soldiers engaged in military operations.<sup>124</sup> Due to the existence of numerous antigenically different strains of *R tsutsugamushi*, an effective vaccine is not yet available.

## Trench Fever

Except during outbreaks associated with wars, trench fever is a rarely reported disease. It has also been known as Wolhynian fever, Meuse fever, His-Werner disease, shin bone fever, shank fever, and quintan or 5-day fever.<sup>125</sup> *Rochalimaea quintana*, the rickettsia that is the causative agent, has also been identified as one of the etiologic agents in bacillary angiomatosis, a disease that was first described in patients with acquired immunodeficiency syndrome.<sup>126</sup>

In modern times, this disease was first recognized and described in 1915 as "trench fever" and "5-day fever." Epidemics were seen among soldiers of all armies along the western, eastern, and Balkan fronts with at least 1 million men stricken in western Europe.<sup>127</sup> Although the disease is relatively mild, trench fever accounted for more lost man-days for the U.S. armed forces than any other disease except influenza.<sup>125</sup> Each affected person was unfit for duty an average of 60 to 70 days. Fatalities were low, but many individuals experienced one or several relapses of the disease.<sup>93</sup> In peacetime, the disease is reported only sporadically in minor outbreaks. During World War II, epidemics again appeared with 80,000 cases in eastern Europe.<sup>127</sup>

## Microbiology

*Rochalimaea quintana* is a short rod (0.5–1.5  $\mu\text{m}$ ) that resembles other rickettsiae in morphology and staining properties. It is unusual in that it can be cultured in host cell-free media. The organism can be cultured in axenic media and the yolk sac of chicken embryos. Laboratory animals are not susceptible to infection.

## Epidemiology, Vectors, and Host

*Rochalimaea quintana* is still considered to be a member of the family Rickettsiaceae, although it is now classified in the genus *Rochalimaea*. Trench fever is distributed worldwide, although it is pri-

marily associated with wars, overcrowded conditions, and poor sanitation. Humans are the reservoir and body lice are the vectors. As with epidemic typhus, when the gut epithelium of the louse is infected, *R quintana* are excreted in the louse's feces. Humans acquire the organism when the feces are scratched into the bite wound.

### Clinical Findings

The onset of trench fever is often sudden and a prodromal period is usually lacking. The incubation period varies from 3 to 38 days and the illness begins with chills followed by fever. The fever has three clinical forms: abortive, periodic, and continuous. Some patients will lack fever or show only rudimentary febrile episodes. Abortive fever is typified by continuous fever for approximately 4 to 5 days. Periodic fever is typified by paroxysms of fever alternating with normal temperatures at intervals of 5 days. There may be 3 to 8 cycles of this pattern, which is the characteristic febrile pattern for the disease. Continuous fever is uninterrupted for 2 to 3 weeks or longer. This type is associated with more severe symptoms.<sup>127</sup>

Chills, tachycardia, headache, retroorbital pain, vertigo, nystagmus, myalgia, exanthem, and hepatosplenomegaly can be seen. The rash is composed of erythematous macules and papules that are seen on the chest, abdomen, and back.<sup>125</sup> Characteristically, the disease will relapse days, weeks, months, or even years after the initial infection. Symptoms during these relapses are generally milder than those previously experienced. Leukocytosis and albuminuria may be present during the relapse.

### Diagnosis and Treatment

Influenza, malaria, relapsing fever, typhus, rat bite fever, enteric fever, brucellosis, and other diseases may need to be considered. The characteristic fever pattern is helpful in making the diagnosis. Serologic testing using complement fixation, microagglutination, or indirect immunofluorescence are helpful in confirming the clinical diagnosis. An indirect hemagglutination test has also been developed that has a specificity greater than 99% and does not cross-react with other rickettsiae.<sup>50</sup>

Tetracycline and doxycycline are effective drugs for treatment of trench fever. As with other rickettsial diseases, chloramphenicol is an acceptable alternative.

### Prevention and Control

Residual insecticides should be dusted on clothing and bedding. In areas where DDT resistance is encountered, lindane or malathion is recommended; however, these chemicals will not kill organisms in louse feces. Clothing and bedding should be sterilized at 100°C for at least 30 minutes.<sup>127</sup> Sputum and urine have been reported to contain viable organisms and should be disposed of as infective waste.<sup>98</sup>

### Q Fever

Q fever, the sole member of the Q fever serogroup, was first described in 1937 and was designated "Q" for query.<sup>128</sup> At that time, the infectious particle was tentatively identified as a rickettsial organism, which is now known as *Coxiella burnetii*.<sup>129</sup> This is the only rickettsial disease that does not typically produce a rash. Most commonly, Q fever is a self-limited, mild, febrile illness. Other manifestations, in descending order of frequency, are pneumonia, endocarditis, and granulomatous hepatitis. Rarely, the disease may present with unusual manifestations (Exhibit 11-2).<sup>130</sup>

Q fever was called "Balkan grippe" when it occurred in British paratroops in Greece during World War II.<sup>93</sup> The disease occurred during the winter of 1944 and spring of 1945 in the North Apennine region of Italy, which is endemic for the disease.<sup>131,132</sup> An epidemic also affected five squadrons of the 449th Bomb Group in Italy; troops returning home to the United States from Italy had an attack rate of 38%.<sup>133</sup> In the process of isolating the organism from these soldiers, outbreaks of the disease occurred among laboratory personnel.<sup>134</sup>

### Microbiology

*C burnetii* is a well-adapted organism that grows within the phagolysosome of the cell, requiring an acid pH. A sporelike form has been described, which accounts for the organism's longevity after dessication.<sup>135</sup> *C burnetii* is a highly infectious organism; a single organism may initiate the disease in humans. It is well adapted to survive harsh conditions, remaining viable after dessication on wool at 15°C to 20°C for 7 to 10 months, cold storage on fresh meat for 1 month, and after 40 months in skim milk at room temperature. The organism can be isolated from infected tissues stored in formaldehyde after 4 to 5 months and even from fixed paraffin-embedded tissue, although it is destroyed by 2%

formaldehyde.<sup>136</sup> There is no genotypic relationship and very little phenotypic similarity between *Rickettsia* and *Coxiella*. Essentially, *Coxiella* remains in the genus as a matter of history and convenience.

### Epidemiology

Q fever is a zoonosis whose reservoirs are primarily cattle, sheep, and goats. The organism is shed in the animals' urine, feces, milk, and birth products and is extremely resistant to desiccation. Evidence of *C burnetii* infection has also been found in horses, swine, water buffalo, dogs, camels, pigeons, chickens, ducks, geese, turkey, and several species of wild birds.<sup>136</sup> Cats and rabbits may be the most important vectors in some areas. Squirrels, meadow mice, deer mice, harvest mice, and deer may also harbor the organism. Infected domestic animals rarely show signs of infection. *C burnetii* is a hearty, widespread organism that has been isolated in 39

species and 10 genera of Ixodidae (hard ticks) and Argasidae (soft ticks). Q fever has been reported in 51 countries on five continents.<sup>136</sup> Arthropods maintain the organism in nature.

The placenta of infected animals is heavily contaminated with *C burnetii*, and after the placenta desiccates, the organisms are aerosolized. Viable organisms can be detected in the soil for 150 days. Humans are infected when they inhale the aerosolized organism, ingest raw milk, or handle contaminated straw or manure. Contaminated clothing may also be a source of exposure.<sup>130</sup> This disease usually affects those who are in contact with infected animals such as farmers, veterinarians, and abattoir workers. However, outbreaks may be seen in others through ingestion of contaminated raw milk, skinning infected wild animals, blood transfusion, or exposure to parturient cats.<sup>136</sup> Outbreaks of infection among laboratory workers are not unusual with this organism.<sup>33</sup> Rarely, cases of human-to-human transmission have been reported.<sup>98</sup>

### Clinical Findings

The self-limited form of Q fever is similar to influenza with fever, myalgia, anorexia, headache, and retroorbital pain. The pneumonic form can present as an atypical pneumonia, a rapidly progressive pneumonia, or a febrile illness with pneumonia found only incidentally. Included in the differential diagnosis of atypical pneumonias are *Mycoplasma pneumoniae*, *Legionella pneumophila*, *Chlamydia psittaci*, pneumonic tularemia, and cytomegalovirus and other viral pneumonias, as well as Q fever. The incubation period is 9 to 17 days.

A clue to the diagnosis is often the severe headache, which may be overrepresented as a symptom. Cough, fatigue, nausea, anorexia, myalgia, sweats, retroorbital pain, and pleuritic chest pain are common findings. One third of patients have vomiting and diarrhea. Rarely, sore throat may be a complaint. The physical exam may reveal inspiratory rales or may lack auscultatory findings completely. Although Q fever characteristically produces no rash, an erythematous macular eruption on the trunk has been described in a few patients.<sup>137</sup>

Hepatomegaly or splenomegaly may affect approximately 5% of patients. Nuchal rigidity or confusion is reported in a small number of patients. Rapidly progressive pneumonia is seen in approximately 20% of patients. These patients are usually extremely ill and hypoxemic. The chest radiograph may show multiple round opacities, pleural effu-

#### EXHIBIT 11-2

#### RARE PRESENTATIONS OF Q FEVER

---

Arteritis  
 Arthritis  
 Aseptic meningitis  
 Dementia  
 Encephalitis  
 Epididymitis  
 Extrapyrimalidal disease  
 Fetal infection  
 Manic psychosis  
 Myocarditis  
 Nephritis  
 Orchitis  
 Osteomyelitis  
 Parotitis  
 Pericarditis  
 Thrombophlebitis  
 Thyroiditis  
 Toxic confusional states

---

Data source: Marrie TJ. Q fever: Clinical signs, symptoms, and pathophysiology. In: Walker DH, ed. *Biology of Rickettsial Diseases*. Vol 2. Boca Raton, Fla: CRC Press; 1988: 1–16.

sions, or increased interstitial markings. The erythrocyte count may be elevated in one third of patients, but most are normal. Hepatic transaminases increase in almost all patients and the syndrome of inappropriate antidiuretic hormone secretion may occur.<sup>130</sup>

Some patients with Q fever present with an illness resembling typical hepatitis, or possibly with a fever of unknown origin with mild liver function test elevations. Hypercalcemia may be seen. Liver biopsy reveals a "doughnut granuloma" (a dense fibrin ring surrounding a central lipid vacuole), which can also be seen in patients with Hodgkin's disease or infectious mononucleosis.

Endocarditis usually involves previously abnormal valves and patients may present with a fever of unknown origin or with culture-negative endocarditis. This very serious manifestation of Q fever is the most common manifestation of chronic Q fever. Fever, clubbing (50%), cardiac murmur, purpuric rash (22%), and arterial emboli (35%) occur.<sup>130</sup> Histologically, the rash is a leukocytoclastic vasculitis, which is thought to be due to the extremely high levels of circulating immune complexes that characterize the disease. Prosthetic valves and the aortic and mitral valves are the usual sites of Q fever endocarditis. Thrombocytopenia and increased hepatic transferases and alkaline phosphatase are common.<sup>130</sup>

### Definitive Diagnosis

*Coxiella* undergoes a phase variation. In the natural state and in the laboratory, it exists in what is called phase I, in which *C burnetii* cells react strongly with late (45-d) convalescent guinea pig sera and weakly with early (21-d) guinea pig convalescent sera. Phase II organisms are produced when the organism is passed repeatedly in embryonated chicken eggs. The phase II form is avirulent and differs from the phase I organism in the sugar com-

position of its lipopolysaccharide and several other characteristics.<sup>136</sup> The diagnosis of chronic Q fever culture-negative endocarditis is made when phase I titers are markedly higher than phase II titers.<sup>136,138</sup> This is the opposite of what one would see in acute Q fever infections.

Various serologic tests such as complement fixation, microimmunofluorescence, and the enzyme-linked immunosorbent assay are used to diagnose Q fever.<sup>138</sup> As it has in other diseases where organisms are difficult or dangerous to isolate, the polymerase chain reaction may find future application in the diagnosis of Q fever.<sup>139</sup>

### Treatment

Tetracycline is the drug of choice, although trimethoprim-sulfamethoxazole and rifampin have been used successfully. Erythromycin with rifampin is the preferred regimen for patients in whom the diagnosis of atypical pneumonia caused by Q fever is considered.<sup>140</sup> Patients with rapidly progressive pneumonia should be treated with tetracycline.

For endocarditis, the combination of tetracycline and clotrimazole is effective. Rifampin is also useful. Some authorities recommend indefinite treatment because relapses are common and replacement of the valve may be necessary.<sup>136</sup> If and when treatment is discontinued, the patient's complement fixation titers should be followed carefully every 6 months.<sup>130</sup>

Q fever hepatitis usually responds to a 2-week course of therapy with tetracycline.

### Prevention

Australian abattoirs have long had problems with Q fever. Trials there have proven a vaccine effective in preventing disease with a minimum of adverse reactions.<sup>141-143</sup> A purified preparation of *C burnetii* is currently being tested by U.S. Army researchers.<sup>140</sup>

## EHRlichiosis SEROGROUP

Ehrlichiae are bacteria grouped within the family Rickettsiaceae; ehrlichial diseases are categorized in the ehrlichiosis serogroup. Ehrlichiae are presumed to be tick-borne and are well known as veterinary pathogens. Until recently, *Ehrlichia sennetsu* and *E canis* were thought to be the only species of *Ehrlichia* causing human disease; however, *E chaffeensis* has recently been identified as the sole etiologic agent of ehrlichiosis in the United

States (Table 11-3). Other species cause infections in horses, dogs, sheep, cattle, bison, and deer. Ehrlichiae differ from other rickettsiae antigenically and in their preference for infecting leukocytes over vascular endothelial cells. They also grow and replicate within a phagosomal vacuole in the host cell. With the exception of *Coxiella* and *Ehrlichia*, rickettsiae grow in the cell without a surrounding membrane or vacuole.

**TABLE 11-3**  
**EHRlichIOSES OF MEDICAL AND VETERINARY IMPORTANCE**

Organism	Host	Vector	Disease
<i>E equi</i>	Horse	Unknown	Equine ehrlichiosis
<i>E canis</i>	Dog	<i>Rhipicephalus sanguineus</i>	Canine ehrlichiosis (tropical canine pancytopenia)
<i>E chaffeensis</i>	Unknown	Tick*	Human ehrlichiosis
<i>E phagocytophila</i>	Sheep, cattle, bison, deer	<i>Ixodes ricinus</i>	Tick-borne fever
<i>E risticii</i>	Cat,* horse	Unknown	Potomac horse fever
<i>E sennetsu</i>	Human*	Tick*	Sennetsu fever

\*Not proven

### Ehrlichiosis

Clinically, ehrlichial diseases range from asymptomatic or mild to severe or fatal. Diagnosis presently relies on detection of antibodies, which takes weeks. In the future, more rapid diagnosis of ehrlichial infections may be accomplished through the use of the polymerase chain reaction once appropriate probes are sequenced. Although still only a research procedure, this has already been done for *E risticii*, the agent of Potomac horse fever.<sup>144</sup>

Ehrlichiae have not been reported to have a significant impact on military campaigns. However, in 1968, sentry dogs used by U.S. troops in Vietnam developed an epizootic of a fatal disease called tropical canine pancytopenia.<sup>145,146</sup> This was characterized by debilitation, fever, anemia, and leukopenia, and hemorrhage. The disease is more severe in German shepherds; 200 to 300 dogs were lost to this disease during the war.<sup>147</sup> The cost of the dogs alone was estimated to be a minimum of \$1 million.<sup>147</sup> Military units that relied on these animals were also compromised. During 1969, many units (usually military police) had more than one-half their dogs classified as possibly infected, resulting in loss of the units' operational capabilities.<sup>147</sup> The etiologic agent was postulated by investigators at WRAIR to be an ehrlichia-like organism,<sup>148,149</sup> and the organism was subsequently proven to be *E canis*.<sup>150</sup> The illness was responsive to tetracycline therapy.<sup>151</sup>

### Microbiology

Ehrlichiae are obligate intracellular, bacterial parasites. They are small, Gram-negative organisms that preferentially infect mononuclear cells or

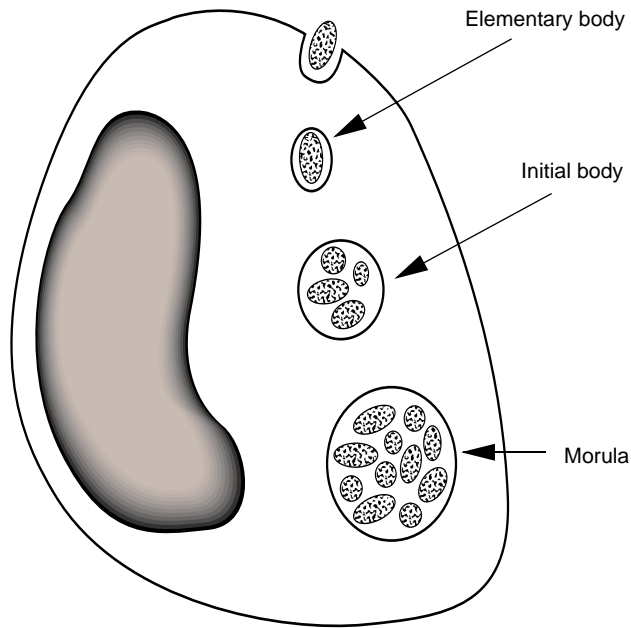
polymorphonuclear leukocytes and grow within a phagosome in the cell cytoplasm. Their development within the cell is similar to that of chlamydiae, with three stages described (Figure 11-5).

Based on serologic testing of infected patients, *E canis* was originally believed to be the pathogen causing human ehrlichiosis. Because serology does not specifically identify the causative agent because of the possibility of cross-reactions with an antigenically related organism, *E canis* was characterized as a tentative etiologic agent. However, *E chaffeensis*, a newly described ehrlichia that is closely related to *E canis*, was identified in 1991 as the causative agent of human ehrlichiosis in the United States. The organism was named for Fort Chaffee, Arkansas, where it was isolated from a U.S. Army recruit with human ehrlichiosis.<sup>152</sup>

### Vectors and Reservoirs

*Rhipicephalus sanguineus*, the brown dog tick, is the vector of canine ehrlichiosis, but it is not a reservoir for the organism. Larval and nymph forms of the tick acquire the infection after feeding on chronically infected dogs and later, as adults, transmit the infection to uninfected dogs. Recent studies have failed to document transovarial transmission.<sup>153,154</sup> The most likely reservoir for canine ehrlichiosis would seem to be chronically infected canids, although this has not been proven. Other vertebrates or ticks may eventually be shown to be reservoirs.<sup>153</sup>

No specific tick has been identified as the vector for human ehrlichiosis. Epidemiological data that were generated when *E canis* was the suspected pathogen indicate that the disease is not acquired from dogs directly. In the United States, serologic



**Fig. 11-5.** In the first stage of the development of erlichia, *elementary bodies* (individual organisms) are phagocytized by host monocytes. Fusion of the phagosome with a lysosome does not occur, however. Elementary bodies grow within the phagosome and replicate by binary fission. After 3 to 5 days, the elementary bodies packed into the phagosome are (a) approximately 1.0 to 2.5  $\mu$ m in size, (b) recognizable as pleomorphic inclusions within the cell, and (c) called *initial bodies*. With additional growth over the next 7 to 12 days, *morulae* (mature inclusions) form and can be visualized via light microscopy. Each infected monocyte contains several morulae, which break up into initial bodies when the cell ruptures, allowing the infectious cycle to be repeated. Illustration source: Adapted from McDade JE. Ehrlichiosis—a disease of animals and humans. *J Infect Dis.* 1990;161(4):609–617. Legend source: Nyindo MBA, Ristic M, Huxsoll DL, Smith AR. Tropical canine pancytopenia: In vitro cultivation of the causative agent—*Ehrlichia canis*. *Am J Vet Res.* 1971;32:1651–1658.

evidence of *E canis* infection has been found in dogs in all geographical areas.<sup>155,156</sup> The geographical distribution of human cases corresponds to the distribution of the Lone Star tick, *Amblyomma americanum*. Additionally, the onset of cases in spring and early summer corresponds to the time of greatest activity for *A americanum* and for the dog tick, *Dermacentor variabilis*.<sup>157</sup> *R sanguineus* is more widely distributed than *A americanum* and bites humans less often.<sup>158</sup> However, evidence of *R sanguineus* bites have been documented in Texas, suggesting the possibility of an increasing anthropophilicity in these ticks.<sup>159</sup> The vector and reservoir for *E chaffeensis* are yet to be definitively determined; however, *E chaffeensis* has been found in a single *D variabilis* tick from an opossum. This evidence awaits confirmation and studies to document that *D variabilis* can transmit the infection.<sup>152</sup>

### Epidemiology

Most cases of human ehrlichiosis are reported in rural areas from the spring to fall. As a group, patients tend to be older than those with RMSF. Cases appear to be most common in the months of May through June. Most patients report either an actual tick bite or exposure to ticks within a few weeks of infection.<sup>160,161</sup>

This may be a disease that is actually more common than would be suspected from the number of cases reported. In some areas, the incidence of ehrlichiosis may match or exceed that of RMSF.<sup>161</sup>

Approximately 10% to 12% of specimens submitted with the tentative diagnosis of RMSF and that tested negatively for RMSF were found to be positive for *E canis* (the agent implicated serologically when these studies were done).<sup>160,162</sup> In a study of hospitalized, febrile patients in southeast Georgia, 10.7% of the patients were found to have a 4-fold rise or fall in titers to *E canis*.<sup>161</sup>

Currently, the predominant regions where ehrlichiosis has been reported include the south-central, southeastern, and mid-Atlantic states. States with high incidences are Oklahoma, Arkansas, Missouri, Virginia, and Tennessee.<sup>158</sup>

People in older age groups are at higher risk for ehrlichial infections in general and also have higher rates of serious complications and hospitalization.<sup>158</sup> Human ehrlichiosis can be rather mild in many cases. Of 74 U.S. Army reservists who were exposed to ticks, 12% had serologic evidence of ehrlichial infection. None required hospitalization and most experienced only mild symptoms. Two patients were asymptomatic.<sup>163</sup> Investigation of ehrlichiosis in Oklahoma revealed that fewer than half the patients required hospitalization<sup>160</sup>; however, hospitalization rates of up to 88% have been reported.<sup>164</sup> In cases reported in 1988, 6% of patients died.<sup>164</sup>

Ehrlichial infections in dogs appear to be widespread in both the size of the population affected (11%-58%)<sup>165</sup> and the geographical area. Cats have also been found to have infections with ehrlichial-like organisms.<sup>166</sup>

### Clinical Findings

More than 80% of patients will recall exposure to ticks during the 3-week period before the onset of illness.<sup>158</sup> The incubation period averages approximately 9 days (range 4–33 d).<sup>164</sup>

Clinical manifestations tend to be nonspecific. Fever, chills, headache, myalgias, anorexia, and nausea and vomiting may appear abruptly or subacutely. A rash may occur 4 to 13 days after the onset of illness but is seen within the first week in only a minority of patients. The rash may be maculopapular or petechial and may involve various aspects of the body. Most children will develop the rash, whereas only one third of adult patients do. The rash does not appear to be a reliable marker for this disease because it is so variable in location and appearance.<sup>158,167</sup>

Serious complications may occur. Meningitis was reported in a pediatric patient.<sup>168</sup> Pulmonary complications may necessitate intubation and mechanical ventilation. Encephalopathy, mental status changes, coma, and acute renal failure can occur. Death may occur, especially in those with preexisting medical problems.<sup>158</sup>

### Laboratory Findings

In studies of hospitalized patients, lymphocytopenia, leukopenia, and thrombocytopenia were fairly common. Although the hematologic findings may be characterized as a transient pancytopenia, leukopenia is noted first because of the shorter life span of these cells. Over one half the patients developed anemia at some time during their hospitalization, but usually not within the first week.<sup>158,161,162</sup> Various abnormalities of the bone marrow have been described<sup>158,162,169,170</sup> but the marrow of many patients is normal. The findings of normal bone marrows suggest sequestration or peripheral destruction as etiologies for the hematologic abnormalities.<sup>171</sup> Studies of dogs reveal a paucity of infected cells in the marrow, supporting this contention.<sup>172</sup>

Inclusion bodies may rarely be noted in the patients' leukocytes. Animals infected with *E canis* usually lack leukocyte inclusions.<sup>162</sup> Geimsa-stained, buffy-coat preparations may be helpful in finding inclusions, which can be found in lymphocytes, atypical lymphocytes, band neutrophils, segmented neutrophils, and monocytes. However, only 1% to 2% of cells will contain inclusions. The inclusions are purple, round, or ovoid structures 2 to 5  $\mu\text{m}$  in size. Usually only one inclusion is seen, although

up to four may be present in the cell. With electron microscopy, the inclusions are seen to be made up of numerous electron-dense organisms surrounded by a vacuolar membrane.<sup>173</sup> Because demonstrating inclusions is not dependable, serologic testing is more important in confirming this diagnosis.

Serum transaminase levels are elevated in most patients during the acute phase of the illness. Elevations of alkaline phosphatase, bilirubin, creatinine, and blood urea nitrogen are less common. Cerebrospinal fluid pleocytosis, with predominant lymphocytes and elevated protein, has been reported.<sup>158,174</sup>

### Differential Diagnosis

Other febrile illnesses associated with ticks should be considered. These include Lyme disease, tularemia, babesiosis, and RMSF. Babesiosis is distinguished by the presence of parasites in erythrocytes on blood-smear examinations. Tularemia and Lyme disease should be distinguishable on a clinical basis. RMSF can be difficult to distinguish in early cases, especially those without a rash.

### Diagnostic Testing

An indirect fluorescent antibody test for detecting *E canis* in dogs has been adapted for use in humans.<sup>160</sup> Positive results are indicated by at least a 4-fold rise or fall in acute and convalescent titers. In one series, 24% of patients with positive tests for *E canis* had confirmed diagnoses which were inconsistent with ehrlichiosis. False-positive results were seen in patients with streptococcal pharyngitis, mononucleosis, hepatic cirrhosis, urosepsis, tularemia,<sup>160</sup> and hepatitis A.<sup>175</sup> The CDC no longer uses *E canis* as the antigen for the indirect immunofluorescent antibody assay, but now uses *E chaffeensis* instead.<sup>176</sup>

Antibody titers rise sharply during the first 3 weeks of illness and peak at approximately 6 weeks. Acute-phase samples should be collected as early as possible in the course of the illness and convalescent titers should be drawn 3 to 4 weeks later. If the initial serum sample is not obtained until after the third week of illness, attempts to demonstrate a 4-fold decrease in titer can provide confirmatory evidence of infection. Serum must be collected during weeks 4 through 7 after onset of illness and again 6 weeks later. Other tick-borne illnesses should also be excluded serologically to confirm the diagnosis of ehrlichiosis. Most patients will seroconvert only to *E canis*, but some will show cross-reactions with

other rickettsiae (*R typhi*, *R rickettsii*, *C burnetii*).<sup>177</sup> Simultaneous infection with other tick-borne illness is possible, as exemplified by patients with ehrlichiosis and Lyme disease.<sup>178,179</sup>

### Treatment

Therapy for human ehrlichiosis is similar to that for RMSF, with tetracycline being the drug of choice. It has proven efficacy in ehrlichiosis in dogs<sup>151</sup> and appears to be efficacious in humans also. Although no formal controlled studies have been done, some patients treated with chloramphenicol appear to do as well as those treated with doxycycline, but some adult patients have gotten worse or died with chloramphenicol.<sup>173,180</sup> A recent in vitro study showed that *E chaffeensis* is resistant to chloramphenicol, bringing into question the usefulness of this agent.<sup>181</sup> This same study found that *E chaffeensis* was susceptible in vitro to rifampin, which offers a possible alternative therapy. Confirmatory studies are needed to define the role of chloramphenicol and rifampin in the treatment of this infection. In patients who have prominent thrombocytopenia and leukopenia, tetracycline is a better alternative. Treatment should be instituted as early as possible. As it is in the treatment of children with RMSF, the use of these antibiotics in children under 9 years of age who have ehrlichiosis is controversial.

### Sennetsu Fever

The causative agent of Sennetsu fever, *Ehrlichia sennetsu*, was originally isolated in 1953 from the peripheral blood, lymph nodes, and bone marrow of a patient with infectious mononucleosis-like

symptoms. At the time, it was thought to be a new rickettsia. Subsequent studies revealed it to be related to *E canis* both antigenically and morphologically. A significant difference is that *E sennetsu* is readily propagated in mice, primary cell cultures, and several continuous cell lines, whereas *E canis* propagates in canine monocytic cell lines only.<sup>153</sup> *E sennetsu* seems to grow in human monocytes in a manner similar to that of *E canis* in canine monocytes. Morulae and individual organisms are observed within cells in membrane-lined vacuoles.<sup>182</sup>

Western Japan and Malaysia are the most commonly reported areas affected by Sennetsu fever.<sup>183,184</sup> The actual geographical area involved may be more extensive than this, as serologic testing for this agent is usually not attempted elsewhere in the world. The vector of Sennetsu fever is presumed to be a tick, although this has not been conclusively proven.

Sennetsu fever appears to be a rather mild, mononucleosis-like disease. Patients may present with fever, postauricular and posterior cervical lymphadenopathy, malaise, and anorexia. An exanthem is rarely seen, but generalized erythematous or localized petechial lesions have been described. Hepatosplenomegaly is seen in one third of patients. Fatalities have not been reported.<sup>183</sup>

Leukopenia with increased numbers of neutrophils is reported early in the disease. Later, lymphocytosis and atypical lymphocytes are seen.

The diagnosis may be confirmed using the complement fixation or indirect fluorescent antibody tests.

Sennetsu fever is treated with tetracycline. Improvement is prompt, with defervescence noted in 2 to 3 days and resolution of other symptoms shortly thereafter.

## SUMMARY

The rickettsiae are grouped taxonomically in a unique family of bacteria that can cause diseases with a spectrum of effects ranging from rather benign to rapidly fatal. Because military personnel may be deployed to parts of the world that are endemic for some rickettsial diseases, these diseases pose particular challenges for medical officers. Diseases such as epidemic typhus have played crucial roles in military history. Although most military physicians have had no previous experience with this disease, it is one that is commonly associated with wartime conditions so we must be

familiar with its presentation, treatment, prevention, and control. Some military bases are located in regions of the world where rickettsial diseases that are not seen in the United States (eg, boutonneuse fever and scrub typhus) are endemic. RMSF and ehrlichiosis are threats to soldiers who are training at bases in the continental United States that are in areas endemic for these diseases. In-depth knowledge and understanding of the diagnosis, treatment, and prevention of rickettsial diseases will allow medical officers to deal competently with these illnesses.



## REFERENCES

1. Woodward TE, Osterman JV. Rickettsial diseases. In: Warren KS, Mahmoud AAF, eds. *Tropical and Geographical Medicine*. New York: McGraw-Hill; 1990: 918–930.
2. Helmick CG, Bernard KW, D'Angelo LJ. Rocky Mountain spotted fever: Clinical, laboratory, and epidemiological features of 262 cases. *J Infect Dis*. 1984;150(4):480–488.
3. Bozeman FM, Masiello SA, Williams MS, Elisberg BL. Epidemic typhus rickettsiae isolated from flying squirrels. *Nature*. 1975;255:545–547.
4. Duma RJ, Sonenshine DE, Bozeman FM, et al. Epidemic typhus in the United States associated with flying squirrels. *JAMA*. 1981;245(22):2318–2323.
5. Harris RL, Kaplan SL, Bradshaw MW, Williams TW Jr. Boutonneuse fever in American travelers. *J Infect Dis*. 1986;153:126–128.
6. McDonald JC, MacLean JD, McDade JE. Imported rickettsial disease: Clinical and epidemiologic features. *Am J Med*. 1988;85(6):799–805.
7. Kohls GM. Rocky Mountain spotted fever. In: Hoff EC, ed. *Communicable Diseases: Arthropodborne Diseases Other Than Malaria*. Vol 2. In: Coates JB Jr, ed. *Preventive Medicine in World War II*. Washington, DC: Office of The Surgeon General, US Army Medical Department, Department of the Army; 1964: 349–356.
8. Philip CB. Scrub typhus and scrub itch. In: Hoff EC, ed. *Communicable Diseases: Arthropodborne Diseases Other Than Malaria*. Vol 2. In: Coates JB Jr, ed. *Preventive Medicine in World War II*. Washington, DC: Office of The Surgeon General, US Army Medical Department, Department of the Army; 1964: 275–348.
9. Walker DH. The pathogenesis and pathology of the hemorrhagic state in viral and rickettsial infections. In: Gear JHS, ed. *CRC Handbook of Viral and Rickettsial Hemorrhagic Fevers*. Boca Raton, Fla: CRC Press; 1988: 22–45.
10. Walker DH. Diagnosis of rickettsial diseases. *Pathol Annu*. 1988; 2(69):69–96.
11. Burgdorfer W. Ecological and epidemiological considerations of Rocky Mountain spotted fever and scrub typhus. In: Walker DH, ed. *Biology of Rickettsial Diseases*. Vol 1. Boca Raton, Fla: CRC Press; 1988: 33–50.
12. Walker DH. Rocky Mountain spotted fever: A disease in need of microbiological concern. *Clin Microbiol Rev*. 1989;2(3):227–240.
13. Oster CN, Burke DS, Kenyon RH, et al. Laboratory acquired Rocky Mountain spotted fever. *N Engl J Med*. 1977;297:859–863.
14. Wells GM, Woodward TE, Fiset P, Hornick RB. Rocky Mountain spotted fever caused by blood transfusion. *JAMA* . 1978;239:2763–2765.
15. Rehacek J. Ecological relationships between ticks and rickettsiae. *Eur J Epidemiol*. 1989;5(4):407–413.
16. Woodward TE. 1988. Rocky Mountain spotted fever and typhus fever. In: Gear JHS, ed. *CRC Handbook of Viral and Rickettsial Hemorrhagic Fevers*. Boca Raton, Fla: CRC Press; 1988: 201–214.
17. Raoult D, Walker DH. *Rickettsia rickettsii* and other spotted fever group rickettsiae (Rocky Mountain spotted fever and other spotted fevers). In: Mandell GL, Douglas RG Jr, Bennett JE, eds. *Principles and Practice of Infectious Diseases*. New York: Churchill Livingstone; 1990: 1465–1471.
18. Riley HD Jr. Rickettsial diseases and Rocky Mountain spotted fever. Part 1. *Curr Probl Pediatr*. 1981;11(5):1–46.

19. Fischer JJ. Rocky Mountain spotted fever: When and why to consider the diagnosis. *Postgrad Med.* 1990;87(4):109–118.
20. Burnett JW. Rickettsioses: A review for the dermatologist. *J. Am. Acad. Dermatol.* 1980;2(5):359–373.
21. McDade JE, Newhouse VF. Natural history of *Rickettsia rickettsii*. *Annu Rev Microbiol.* 1986;40(287):287–309.
22. Helmick CG, Winkler WG. Epidemiology of Rocky Mountain spotted fever 1975–1979. In: Burgdorfer W, Anacker RL, eds. *Rickettsiae and Rickettsial Diseases*. New York: Academic Press; 1981: 547–557.
23. Salgo MP, Telzak EE, Currie B, et al. A focus of Rocky Mountain spotted fever within New York City. *N Engl J Med.* 1988;318:1345–1348.
24. Woodward TE. Rocky Mountain spotted fever: Epidemiological and early clinical signs are keys to treatment and reduced mortality. *J Infect Dis.* 1984;150(4):465–468.
25. Lange J V, Walker DH, Wester TB. Documented Rocky Mountain spotted fever in wintertime. *JAMA.* 1982;247(17):2403–2404.
26. Walker DH. The role of host factors in the severity of spotted fever and typhus rickettsioses. *Ann NY Acad Sci.* 1990;590:10–19.
27. Walker DH, Gay RM, Valdes-Dapena M. The occurrence of eschars in Rocky Mountain spotted fever. *J Am Acad Dermatol.* 1981;4:571–576.
28. Kirk JL, Fine DP, Sexton DJ, Muchmore HG. Rocky Mountain spotted fever: A clinical review based on 48 confirmed cases, 1943–1986. *Medicine (Baltimore).* 1990;69(1):35–45.
29. Walker DH, Lane TW. Rocky Mountain spotted fever: Clinical signs, symptoms and pathophysiology. In: Walker DH, ed. *Biology of Rickettsial Diseases*. Vol 1. Boca Raton, Fla: CRC Press; 1988: 63–78.
30. Kaplowitz LG, Fisher JJ, Sparling PF. Rocky Mountain spotted fever: A clinical dilemma. *Curr Clin Top Infect Dis.* 1981;2:89–108.
31. Davis AE Jr, Bradford WD. Abdominal pain resembling acute appendicitis in Rocky Mountain spotted fever. *JAMA.* 1982;247(20):2811–2812.
32. Walker DH, Lesesne HR, Varma VA, Thacker WC. Rocky Mountain spotted fever mimicking acute cholecystitis. *Arch Intern Med.* 1985;145(12):2194–2196.
33. Meiklejohn G, Reimer LG, Graves PS, Helmick C. Cryptic epidemic of Q fever in a medical school. *J Infect Dis.* 1981;144(2):107–113.
34. Middleton DB. Rocky Mountain spotted fever: Gastrointestinal and laboratory manifestations. *South Med J.* 1978;71:629–632.
35. Walker DH, Mattern WD. Acute renal failure in Rocky Mountain spotted fever. *Arch Intern Med.* 1979;139:443–448.
36. Massey EW, Thames T, Coffey CE, Gallis HA. Neurologic complications of Rocky Mountain spotted fever. *South Med J.* 1985;78(11):1288–1290.
37. Griffith GL, Luce EA. Massive skin necrosis in Rocky Mountain spotted fever. *South Med J.* 1978;71:1337–1340.
38. Walker DH, Kirkman HN, Wittenberg PH. Genetic states possibly associated with enhanced severity of Rocky Mountain spotted fever. In: Burgdorfer W, Anacker RL, eds. *Rickettsiae and Rickettsial Diseases*. New York: Academic Press; 1981: 621–630.

39. Silverman DJ. Adherence of platelets to human endothelial cells infected by *Rickettsia rickettsii*. *J Infect Dis*. 1986;153(4):694–700.
40. Adams JS, Walker DH. The liver in Rocky Mountain spotted fever. *Am J Clin Pathol*. 1981;75:156–161.
41. Torres J, Humpreys E, Bisno AL. Rocky Mountain spotted fever in the mid-South. *Arch Intern Med*. 1973;132:340–347.
42. Kaplowitz LG, Robertson GL. Hyponatremia in Rocky Mountain spotted fever: Role of antidiuretic hormone. *Ann Intern Med*. 1983;98(3):334–335.
43. Crockett RK. Life-threatening rashes. In: Harwood-Nuss A, ed. *The Clinical Practice of Emergency Medicine*. Philadelphia: JB Lippincott; 1991: 756–757.
44. Walker DH, Hawkins HL, Hudson P. Fulminant Rocky Mountain spotted fever: Its pathologic characteristics associated with glucose-6-phosphate dehydrogenase deficiency. *Arch Pathol Lab Med*. 1983;107:121–125.
45. Kaplan JE, Schonberger LB. The sensitivity of various serologic tests in the diagnosis of Rocky Mountain spotted fever. *Am J Trop Med Hyg*. 1986;35(4):840–844.
46. Hechemy KE, Anacker RL, Philip RN, et al. Detection of Rocky Mountain spotted fever antibodies by a latex agglutination test. *J Clin Microbiol*. 1980;12(2):144–150.
47. Hechemy KE, Michaelson EE, Anacker RL, et al. Evaluation of latex-*Rickettsia rickettsii* test for Rocky Mountain spotted fever in 11 laboratories. *J Clin Microbiol*. 1983;18(4):938–946.
48. Hechemy KE, Rubin BB. Latex-*Rickettsia rickettsii* test reactivity in seropositive patients. *J Clin Microbiol*. 1983;17(3):489–492.
49. Hechemy KE, Osterman JV, Eisemann CS, Elliot LB, Sasowski SJ. Detection of typhus antibodies by latex agglutination. *J Clin Microbiol*. 1981;13(1):214–216.
50. Walker DH, Peacock MG. Laboratory diagnosis of rickettsial diseases. In: Walker DH, ed. *Biology of Rickettsial Diseases*. Vol 1. Boca Raton, Fla: CRC Press; 1988: 135–156.
51. Zaki MH. Rocky Mountain spotted fever: Epidemiologic and clinical features. *NY State J Med*. 1979;79:64–65.
52. Hechemy KE, Stevens RW, Sasowski S, et al. Discrepancies in Weil-Felix and microimmunofluorescence test results for Rocky Mountain spotted fever. *J Clin Microbiol*. 1979;9(2):292–293.
53. Hall WC, Bagley LR. Identification of *Rickettsia rickettsii* in formalin-fixed, paraffin-embedded tissues by immunofluorescence. *J Clin Microbiol*. 1978;8(2):242–245.
54. Walker DH, Cain BG. A method for specific diagnosis of Rocky Mountain spotted fever on fixed, paraffin-embedded tissue by immunofluorescence. *J Infect Dis*. 1978;137(2):206–209.
55. Dumler JS, Gage WR, Pettis GL, Azad AF, Kuhadja FP. Rapid immunoperoxidase demonstration of *Rickettsia rickettsii* in fixed cutaneous specimens from patients with Rocky Mountain spotted fever. *Am J Clin Pathol*. 1990;93(3):410–414.
56. Bradford WD, Hackel DB. Myocardial involvement in Rocky Mountain spotted fever. *Arch Pathol Lab Med*. 1979;102:357–359.
57. Wilfert CM, MacCormack JN, Kleeman K, et al. Epidemiology of Rocky Mountain spotted fever as determined by active surveillance. *J Inf Dis*. 1984;150(4):469–479.
58. Kaplan JE, McDade JE, Newhouse VF. Suspected Rocky Mountain spotted fever in the winter: Epidemic typhus? *N Engl J Med*. 1981;305(27):1648.

59. Gove S, Slutkin G. Infections acquired in the fields and forests of the United States. *Emerg Med Clin North Am.* 1984;2(3):623–633.
60. Zaki MH. Selected tickborne infections: A review of Lyme disease, Rocky Mountain spotted fever, and babesiosis. *N Y State J Med.* 1989;89(6):320–335.
61. Abramson JS, Givner LB. Should tetracycline be contraindicated for therapy of presumed Rocky Mountain spotted fever in children less than 9 years of age? *Pediatrics.* 1990;86(1):123–124.
62. Riley HD Jr. Rocky Mountain spotted fever. In: Rakel RE, ed. *Conn's Current Therapy 1991.* Philadelphia, Pa: WB Saunders Co; 1991: 105–107.
63. Benenson AS. *Control of Communicable Diseases in Man.* Washington, DC: American Public Health Association; 1990: 372–376.
64. Needham GR. Evaluation of five popular methods for tick removal. *Pediatrics.* 1985;75:997–1002.
65. De Boer R, Van Den Bogaard AEJM. Removal of attached nymphs and adults of *Ixodes ricinus* (Acari: Ixodidae). *J Med Entomol.* 1993;30(4):748–752.
66. Kenyon RH, Williams RG, Oster CN, Pedersen CE Jr. Prophylactic treatment of Rocky Mountain spotted fever. *J Clin Microbiol.* 1978;8(1):102–104.
67. Gear JHS. Tick typhus. In: Gear JHS, ed. *CRC Handbook of Viral and Rickettsial Hemorrhagic Fevers.* Boca Raton, Fla: CRC Press; 1988: 22–45.
68. Gear JHS. Other spotted fever group rickettsioses: Clinical signs, symptoms, and pathophysiology. In: Walker DH, ed. *Biology of Rickettsial Diseases.* Vol 1. Boca Raton, Fla: CRC Press; 1988: 101–114.
69. Font-Creus B, Bella-Cueto F, Espejo-Arenas E, Vidal-Sanahuja R, Muñoz-Espin T. Mediterranean spotted fever: A cooperative study of 227 cases. *Rev Infect Dis.* 1985;7(5):635–642.
70. Mansueto S, Tringali G, Di Leo R, et al. Demonstration of spotted fever group rickettsiae in the tache noire of a healthy person in Sicily. *Am J Trop Med Hyg.* 1984;33(3):479–482.
71. Segura-Porta F, Font-Creus B, Espejo-Arenas E, Bella-Cueto F. New trends in Mediterranean spotted fever. *Eur J Epidemiol.* 1989;5(4):438–443.
72. Bella-Cueto F, Font-Creus B, Segura-Porta F, et al. Comparative, randomized trial of one-day doxycycline versus 10-day tetracycline therapy for Mediterranean spotted fever. *J Infect Dis.* 1987;155(5):1056–1058.
73. Raoult D, Lena D, Perrimont H, Gallais H, Walker DH. Haemolysis with Mediterranean spotted fever and glucose-6-phosphate dehydrogenase deficiency. *Trans R Soc Trop Med Hyg.* 1986;80(6):961–962.
74. Raoult D, Weiller PJ, Changnon A, et al. Mediterranean spotted fever: Clinical, laboratory, and epidemiologic features of 199 cases. *Am J Trop Med Hyg.* 1986;35(4):845–850.
75. Shaked Y, Samra Y, Maier MK, Rubinstein E. Relapse of rickettsial Mediterranean spotted fever and murine typhus after treatment with chloramphenicol. *J Infect.* 1989;18(1):35–37.
76. Sexton DJ, King G, Dwyer B. Fatal Queensland tick typhus. *J Infect Dis.* 1990;162(3):779–780.
77. Drancourt M, Raoult D, Harlé JR, et al. Biological variations in 412 patients with Mediterranean spotted fever. *Ann N Y Acad Sci.* 1990;590:39–50.
78. De Micco C, Raoult D, Toga M. Diagnosis of Mediterranean spotted fever by using an immunofluorescence technique. *J Infect Dis.* 1986;153(1):136–138.

79. Raoult D, de Micco C, Gallais H, Toga M. Laboratory diagnosis of Mediterranean spotted fever by immunofluorescent demonstration of *Rickettsia conorii* in cutaneous lesions. *J Infect Dis*. 1984;150(1):145–148.
80. Hechemy KE, Raoult D, Eisemann C, Han YS, Fox JA. Detection of antibodies to *Rickettsia conorii* with a latex agglutination test in patients with Mediterranean spotted fever. *J Infect Dis*. 1986;153(1):132–135.
81. Walker DH, Gear JHS. Correlation of the distribution of *Rickettsia conorii*, microscopic lesions, and clinical features in South African tick bite fever. *Am J Trop Med Hyg*. 1985;34(2): 361–371.
82. Mansueto S, Vitale G, Bentivegna M, Tringali G, Di Leo R. Persistence of antibodies to *Rickettsia conorii* after an acute attack of Boutonneuse fever. *J Infect Dis*. 1985;151(2):377.
83. Bayne-Jones S. Typhus fevers. In: Hoff EC, ed. *Communicable Diseases: Arthropodborne Diseases Other Than Malaria*. Vol 2. In: Coates JB Jr, ed. *Preventive Medicine in World War II*. Washington, DC: Office of The Surgeon General, US Army Medical Department, Department of the Army; 1964: 175–274.
84. Brettman LR, Lewin S, Holzman RS, et al. Rickettsialpox: Report of an outbreak and a contemporary review. *Medicine (Baltimore)*. 1981;60(5):363–372.
85. Saah AJ. *Rickettsia akari* (rickettsialpox). In: Mandell GL, Douglas RG Jr, Bennett JE, eds. *Principles and Practice of Infectious Diseases*. New York: Churchill Livingstone; 1990: 1471–1472.
86. McDade JE. Evidence supporting the hypothesis that rickettsial virulence factors determine the severity of spotted fever and typhus group infections. *Ann N Y Acad Sci*. 1990;590:20–26.
87. Lederberg J, ed. *Encyclopedia of Microbiology*. Vol 3. San Diego, Calif: Academic Press; 1992: 585.
88. Weiss K. The role of rickettsioses in history. In: Walker DH, ed. *Biology of Rickettsial Diseases*. Vol 1. Boca Raton, Fla: CRC Press; 1988: 1–14.
89. Lechvalier HA, Solotorovsky M. *Three Centuries of Microbiology*. New York, NY: McGraw-Hill; 1965: 332.
90. Barrett O’N Jr, Stark FR. Rickettsial diseases and leptospirosis. In: Ognibene AJ, Barrett O’N Jr, eds. *General Medicine and Infectious Diseases*. Vol 2. In: Ognibene AJ, ed. *Internal Medicine in Vietnam*. Washington, DC: Medical Department, US Army; Office of The Surgeon General; Center of Military History; 1982: 133–158.
91. Woodward TE. A historical account of the rickettsial diseases with a discussion of unsolved problems. *J Infect Dis*. 1973;127(5):583–594.
92. Smart C. *The Medical and Surgical History of the War of the Rebellion*. Vol 1. Washington, DC: Government Printing Office; 1888: 268–270.
93. Moe JB, Pederson CE Jr. The impact of rickettsial diseases on military operations. *Milit Med*. 1980;145:780–785.
94. Woodward TE. The public’s debt to military medicine. *Milit Med*. 1981;146(3):168–173.
95. Zarafonitis CJD, Baker MP. Scrub typhus. In: Havens PW, ed. *Infectious Diseases*. In: Coates JB Jr, ed. *Internal Medicine in World War II*. Vol 2. Washington, DC: Medical Department, US Army; Office of The Surgeon General; Department of the Army; 1963: 111–142.
96. Woodward TE. Rickettsial diseases: Certain unsettled problems in their historical perspective. In: Burgdorfer W, Anacker RL, eds. *Rickettsiae and Rickettsial Diseases*. New York: Academic Press; 1981: 17–40.
97. Anonymous. Deception by immunisation. *Br Med J*. 1977;2(6089):716–717.
98. Riley HD Jr. Rickettsial diseases and Rocky Mountain spotted fever. Part 2. *Curr Probl Pediatr*. 1981;11(6):1–38.

99. McDade JE, Shepard CC, Redus MA, Newhouse VF, Smith JD. Evidence of *Rickettsia prowazekii* infections in the United States. *Am J Trop Med Hyg.* 1980;29(2):277–284.
100. McCalmont C, Zanolli MD. Rickettsial diseases. *Dermatol. Clin.* 1989;7(3):591–601.
101. Azad AF. Relationship of vector biology and epidemiology of louse- and flea-borne rickettsioses. In: Walker DH, ed. *Biology of Rickettsial Diseases*. Vol 1. Boca Raton, Fla: CRC Press; 1988: 51–62.
102. Ackley AM, Peter WJ. Indigenous acquisition of epidemic typhus in the eastern United States. *South Med J.* 1981;74(2):245–247.
103. Russo PK, Mendelson DC, Etkind PH, et al. Epidemic typhus (*Rickettsia prowazekii*) in Massachusetts: Evidence of infection. *N Engl J Med.* 1981;304(19):1166–1168.
104. Woodward TE. Murine typhus fever: Its clinical and biologic similarity to epidemic typhus. In: Walker DH, ed. *Biology of Rickettsial Diseases*. Vol 1. Boca Raton, Fla: CRC Press; 1988: 79–92.
105. Saah AJ. *Rickettsia prowazekii* (epidemic or louse borne typhus). In: Mandell GL, Douglas RG Jr, Bennett JE, eds. *Principles and Practice of Infectious Diseases*. New York: Churchill Livingstone; 1990: 1476–1478.
106. Brezina R. Diagnosis and control of rickettsial diseases. *Acta Virol. (Praha)* 1985;29(4):338–349.
107. Sawyer WD. Typhus fevers. In: Rakel RE, ed. *Conn's Current Therapy 1991*. Philadelphia: W. B. Saunders Co; 1991: 124–126.
108. Green CR, Fishbein D, Gleiberman I. Brill-Zinsser: Still with us. *JAMA* 1990;264(14):1811–1812.
109. Zarafonetis CJD. The typhus fevers. In: Havens PW, ed. *Infectious Diseases*. In: Coates JB Jr, ed. *Internal Medicine in World War II*. Vol 2. Washington, DC: Medical Department, US Army; Office of The Surgeon General; Department of the Army; 1963: 143–224.
110. Azad AF. Epidemiology of Murine typhus. *Annu Rev Entomol.* 1990;35(553):553–569.
111. Duffy PE, Le Guillouic H, Gass RF, Innis BL. Murine typhus identified as a major cause of febrile illness in a camp for displaced Khmers in Thailand. *Am J Trop Med Hyg.* 1990;43(5):520–526.
112. Traub R, Wisseman CL, Fahrang-Azad A. The ecology of Murine typhus—a critical review. *Trop Dis Bull.* 1978;75(4):237–317.
113. Fahrang-Azad A, Traub R, Baqar S. Transovarial transmission of Murine typhus rickettsiae in *Xenopsylla cheopis* fleas. *Science.* 1985;227(4686):543–545.
114. Stasko T, De Villez RL. Murine typhus: A case report and review. *J Am Acad Dermatol.* 1982;7:377–381.
115. Saah AJ. *Rickettsia typhi* (Endemic or Murine typhus). In: Mandell GL, Douglas RG Jr, Bennett JE, eds. *Principles and Practice of Infectious Diseases*. New York: Churchill Livingstone; 1990: 1478–1480.
116. Berman SJ, Kundin WD. Scrub typhus in South Vietnam: A study of 87 cases. *Ann Intern Med.* 1973;79:26–30.
117. Hazlett DR. Scrub typhus in Vietnam: Experience at the 8th field hospital. *Milit Med.* 1970;1:31–34.
118. Brown GW, Robinson DM, Huxsoll DL, Ng TS, Lim KJ. Scrub typhus: A common cause of illness in indigenous populations. *Trans R Soc Trop Med Hyg.* 1977;70(5,6):444–448.
119. Kelly DJ, Wong PW, Gan E, et al. Multi-laboratory evaluation of a Scrub typhus diagnostic kit. *Am J Trop Med Hyg.* 1990;43(3):301–307.

120. Kawamura AJ, Tanaka H. Rickettsiosis in Japan. *Jpn J Exp Med*. 1988;58(4):169–184.
121. Brown GW, Saunders JP, Singh S, Huxsoll DL, Shirai A. Single dose doxycycline therapy for Scrub typhus. *Trans R Soc Trop Med Hyg*. 1978;72(4):412–416.
122. Olson JG, Bourgeois AL, Fang RCY, Coolbaugh JC, Dennis DT. Prevention of Scrub typhus. Prophylactic administration of doxycycline in a randomized double blind trial. *Am J Trop Med Hyg*. 1980;29(5):989–997.
123. Olson JG, Bourgeois AL, Fang RCY, Dennis DT. Risk of relapse associated with doxycycline therapy for Scrub typhus. In: Burgdorfer W, Anacker RL, eds. *Rickettsiae and Rickettsial Diseases*. New York: Academic Press; 1981: 201–210.
124. Brown GW. Scrub typhus: Pathogenesis and clinical syndrome. In: Walker DH, ed. *Biology of Rickettsial Diseases*. Boca Raton, Fla: CRC Press; 1988: 93–100.
125. Warren J. Trench fever rickettsia. In: Horsfall FL, Tamm I, eds. *Viral and Rickettsial Infections of Man*. Philadelphia, Pa: JB Lippincott; 1965: 1161–1163.
126. Koehler JE, Quinn FD, Berger TG, LeBoit PE, Tappero JW. Isolation of *Rochalimaea* species from cutaneous and osseous lesions of bacillary angiomatosis. *N Eng J Med*. 1992;327:1625–1631.
127. Liu WT. Trench fever: A résumé of literature and a note on some obscure phases of the disease. *Chin Med J*. 1984;97(3):179–190.
128. Derrick EH. “Q” fever. A new fever entity: Clinical features, diagnosis and laboratory investigation. *Med J Aus*. 1937;2:281–299.
129. Burnet FM, Freeman M. Experimental studies on the virus of “Q” fever. *Med J Aus*. 1937;2(8):299–305.
130. Marrie TJ. Q fever: Clinical signs, symptoms, and pathophysiology. In: Walker DH, ed. *Biology of Rickettsial Diseases*. Vol 2. Boca Raton, Fla: CRC Press; 1988: 1–16.
131. Berge TO, Lennette EH. World distribution of Q fever: Human, animal and arthropod infection. *Am J Hyg*. 1953;57(2):125–143.
132. Robbins FC, Gauld RL, Warner FB. Q fever in the Mediterranean area: Report of its occurrence in Allied troops. Part 2. Epidemiology. *Am J Hyg*. 1946;44(1):23–50.
133. Feinstein M, Yesner R, Marks JL. Epidemics of Q fever among troops returning from Italy in the spring of 1945. Part 1. Clinical aspects of the epidemic at Camp Patrick Henry, Virginia. *Am J Hyg*. 1946;44(1):73–87.
134. Ragan CA Jr. Q fever. In: Havens PW, ed. *Infectious Diseases*. In: Coates JB Jr, ed. *Internal Medicine in World War II*. Vol 2. Washington, DC: Medical Department, US Army; Office of The Surgeon General; Department of the Army; 1963: 103–108.
135. Wisseman CL Jr. Selected observations on Rickettsiae and their host cells. *Acta Virol*. (Praha) 1986;30:81–95.
136. Marrie TJ. *Coxiella burnetii* (Q fever). In: Mandell GL, Douglas RG Jr, Bennett JE, eds. *Principles and Practice of Infectious Diseases*. New York: Churchill Livingstone; 1990: 1472–1476.
137. Spelman DW. Q fever: A study of 111 consecutive cases. *Med J Aus*. 1982;1:547–553.
138. Embil J, Williams JC, Marrie TJ. The immune response in a cat-related outbreak of Q fever as measured by the indirect immunofluorescence test and the enzyme-linked immunosorbent assay. *Can J Microbiol*. 1990;36(4):292–296.
139. Mallavia LP, Whiting LL, Minnick MF, et al. Strategy for detection and differentiation of *Coxiella burnetii* strains using the polymerase chain reaction. *Ann N Y Acad Sci*. 1990;590:572–581.

140. Rauch AM. Q fever. In: Rakel RE, ed. *Conn's Current Therapy 1991*. Philadelphia, Pa: W. B. Saunders Co; 1991: 93–94.
141. Marmion BP, Ormsbee RA, Kyrkou M, et al. Vaccine prophylaxis of abattoir-associated Q fever: Eight years' experience in Australian abattoirs. *Epidemiol Infect.* 1990;104(2):275–287.
142. Marmion BP, Kyrkou M, Worswick D, et al. Vaccine prophylaxis of abattoir-associated Q fever. *Lancet.* 1984;8417(8): 1411–1414.
143. Shapiro RA, Siskind V, Schofield FD, et al. A randomized, controlled, double-blind, cross-over, clinical trial of Q fever vaccine in selected Queensland abattoirs. *Epidemiol Infect.* 1990;104(2):267–73.
144. Biswas B, Dutta SK, Mattingly-Napier B. Gene amplification by polymerase chain reaction for detection of *Ehrlichia risticii* DNA in Potomac horse fever. *Ann N Y Acad Sci.* 1990;590: 582–583.
145. Walker JS, Rundquist JD, Taylor R, et al. Clinical and clinicopathologic findings in tropical canine pancytopenia. *J Am Vet Med Assoc.* 1970;157:43–55.
146. Nims RM, Ferguson JA, Walker JL, et al. Epizootiology of tropical canine pancytopenia in Southeast Asia. *J Am Vet Med Assoc.* 1971;158:53–63.
147. Kelch WJ. The canine ehrlichiosis (tropical canine pancytopenia) epizootic in Vietnam and its implications for the veterinary care of military working dogs. *Milit Med.* 1984;149:327–331.
148. Huxsoll DL, Hildebrandt PK, Nims RM, Ferguson JA, Walker JS. *Ehrlichia canis*—the causative agent of a haemorrhagic disease of dogs? *Vet Rec.* 1969;85:587.
149. Huxsoll DL, Hildebrandt PK, Nims RM, Walker JS. Tropical canine pancytopenia. *J Am Vet Med Assoc.* 1970;157(11):1627–1632.
150. Nyindo MBA, Ristic M, Huxsoll DL, Smith AR. Tropical canine pancytopenia: In vitro cultivation of the causative agent—*Ehrlichia canis*. *Am J Vet Res.* 1971;32:1651–1658.
151. Buhles WCJ, Huxsoll DL, Ristic M. Tropical canine pancytopenia: Clinical, hematologic, and serologic responses of dogs to *Ehrlichia canis* infection, tetracycline therapy, and challenge inoculation. *J Infect Dis.* 1974;130(4):357–367.
152. Anderson BE, Dawson JE, Jones DC, Wilson KH. *Ehrlichia chaffeensis*, a new species associated with human ehrlichiosis. *J Clin Microbiol.* 1991;29(12):2838–2842.
153. McDade JE. Ehrlichiosis—a disease of animals and humans. *J Infect Dis.* 1990;161(4):609–617.
154. Brouqui P, Raoult D. In vitro antibiotic susceptibility of the newly recognized agent of ehrlichiosis in humans, *Ehrlichia chaffeensis*. *Antimicrob Agents and Chemotherapy.* 1992;36(12):2799–2803.
155. Conrad ME. *Ehrlichia canis*: A tick-borne rickettsial-like infection in humans living in the southeastern United States. *Am J Med Sci.* 1989;297(1):35–37.
156. Keefe TJ, Holland CJ, Salyer PE, Ristic M. Distribution of *Ehrlichia canis* among military working dogs in the world and selected civilian dogs in the United States. *J Am Vet Med Assoc.* 1982;181:236–238.
157. Harkess JR, Ewing SA, Brumit T, Mettry CR. Ehrlichiosis in children. *Pediatrics.* 1991;87(2):199–203.
158. Eng TR, Harkess JR, Fishbein DB, Dawson JE, Greene CN. Epidemiologic, clinical, and laboratory findings of human ehrlichiosis in the United States, 1988. *JAMA.* 1990;264(17):2251–2258.
159. Goddard J. Focus of human parasitism by the brown dog tick, *Rhipicephalus sanguineus* (Acari: Ixodidae). *J Med Entomol.* 1989;26(6):628–629.



160. Harkess JR, Ewing SA, Crutcher JM, et al. Human ehrlichiosis in Oklahoma. *Infect Dis*. 1989;159(3):576–579.
161. Fishbein DB, Kemp A, Dawson JE, et al. Human ehrlichiosis: Prospective active surveillance in febrile hospitalized patients. *J Infect Dis*. 1989;160(5):803–809.
162. Fishbein DB, Sawyer LA, Holland CJ, et al. Unexplained febrile illness after exposure to ticks: Infection with an *Ehrlichia*? *JAMA*. 1987;257:3100–3104.
163. Petersen LR, Sawyer LA, Fishbein DB, et al. An outbreak of ehrlichiosis in members of an Army Reserve unit exposed to ticks. *J Infect Dis*. 1989;159(3):562–568.
164. Eng TR, Fishbein DB, Dawson JE, Greene CR, Redus M. Surveillance of human ehrlichiosis in the United States: 1988. *Ann N Y Acad Sci*. 1990;590:306–307.
165. Brouqui P, Raoult D, Vidor E. Lack of co-transmission of *Rickettsia conorii* and *Ehrlichia canis* in human beings in the south of France. *Eur J Epidemiol*. 1989;5(1):110–112.
166. Buoro IB, Atwell RB, Kiptoon JC, Ihiga MA. Feline anaemia associated with Ehrlichia-like bodies in three domestic short-haired cats. *Vet Rec*. 1989;125(17):434–436.
167. Edwards MS, Jones JE, Leass DL, Whitmore JW, Dawson JE. Childhood infections caused by *Ehrlichia canis* or a closely related organism. *Pediatr Infect Dis J*. 1988;7(9):651–654.
168. Golden SE. Aseptic meningitis associated with *Ehrlichia canis* infection. *Pediatr Infect Dis J*. 1989;8(5):335–337.
169. Doran TI, Parmley RT, Logas PC, Chamblin S. Infection with *Ehrlichia canis* in a child. *J Pediatr*. 1989;114(5):809–812.
170. Pearce CJ, Conrad ME, Nolan PE, Fishbein DB, Dawson JE. Ehrlichiosis: A cause of bone marrow hypoplasia in humans. *Am J Hematol*. 1988;28:53–55.
171. Harkess JR. Correspondence. *Am J Hematol*. 1989;30:265–266.
172. Aronson J, Scimeca J, Harris D, Walker DH. Immunohistologic demonstration of *Ehrlichia canis*. *Ann N Y Acad Sci*. 1990;590:148–156.
173. Maeda K, Markowitz N, Hawley RC, et al. Human infection with *Ehrlichia canis*, a leukocytic rickettsia. *N Engl J Med*. 1987;316(14):853–856.
174. Dimmitt DC, Fishbein DB, Dawson JE. Human ehrlichiosis associated with cerebrospinal fluid pleocytosis: A case report. *Am J Med*. 1989;87:677–678.
175. Rohrbach BW, Harkess JR, Ewing SA, et al. Epidemiologic and clinical characteristics of persons with serologic evidence of *E. canis* infection. *Am J Public Health*. 1990;80(4):442–445.
176. Spach DH, Liles WC, Campbell GL, Quick RE, Anderson DE, Fritsche TR. Tick-borne diseases in the United States. *N Eng J Med*. 1993;329:936–947.
177. Dawson JE, Fishbein DB, Eng TR, Redus MA, Green NR. Diagnosis of human ehrlichiosis with the indirect fluorescent antibody test: Kinetics and specificity. *J Infect Dis*. 1990;162(1):91–95.
178. Barton LL, Luisiri A, Dawson JE, Letson GW, Quan TJ. Simultaneous infection with an Ehrlichia and *Borrelia burgdorferi* in a child. *Ann N Y Acad Sci*. 1990;590:68–69.
179. Raad I, Singh V, Quan TJ. Concurrent positive serology for ehrlichiosis and Lyme disease. *J Infect Dis*. 1989;160(4):727–728.

180. Dumler JS, Brouqui P, Aronson J, Taylor JP, Walker DH. Identification of ehrlichia in human tissue. *N Eng J Med.* 325:1109–1110.
181. Brouqui P, Raoult D. In vitro antibiotic susceptibility of the newly recognized agent of ehrlichiosis in humans, *Ehrlichia chaffeensis*. *Antimicrobial Agents and Chemotherapy.* 1992;36:2799–2803.
182. Hoilien CA, Ristic M, Huxsoll DL, Rapmund G. *Rickettsia sennetsu* in human blood monocyte cultures: Similarities to the growth cycle of *Ehrlichia canis*. *Infect Immun.* 1982;35(1):314–319.
183. Tachibana N. Sennetsu fever: The disease, diagnosis, and treatment. In: Leive L, Bonzentree PS, Morello JA, Silver SD, Wu H. *Microbiology—1986*. Washington, DC: American Society for Microbiology; 1986: 205–208.
184. Ristic M. Pertinent characteristics of leukocytic rickettsiae of humans and animals. In: Leive L, Bonzentree PS, Morello JA, Silver SD, Wu H. *Microbiology—1986*. Washington, DC: American Society for Microbiology; 1986: 182–187.

# Chapter 12

## TROPICAL PARASITIC INFECTIONS

JAMES H. KEELING III, M.D.\*

---

### INTRODUCTION

### PROTOZOAL INFECTIONS

- Leishmaniasis
- South American Trypanosomiasis
- African Trypanosomiasis
- Amebiasis

### HELMINTHIC INFECTIONS

- Human Hookworm Disease
- Strongyloidiasis
- Filariasis
- Dracunculiasis
- Trichinosis
- Schistosomiasis

### SUMMARY

\*Colonel, Medical Corps, U.S. Army; Residency Program Director, Dermatology Service, Brooke Army Medical Center, Fort Sam Houston, Texas 78234-6263

## INTRODUCTION

A *parasite* is an organism that lives on or within another organism. The organism on which or within which it lives is referred to as the *host*. While a parasite–host relationship may be one of mutual benefit (mutualism) or one in which the host derives no benefit but is not injured by the relationship (commensalism), the term parasitism is used in this chapter to mean that the parasite is afforded physical protection or nourishment to the detriment of its human host.

The life cycles of parasites may be complex. In a *definitive* host, the parasite becomes sexually mature and undergoes reproduction. *Reservoir* hosts are those in which parasites that are pathogenic to other animals or to humans reside. An animal reservoir confers a survival benefit to the parasite, for it is often difficult to track and eliminate the organism from the larger pool of animals in which it is carried. When humans intrude into the wild and interrupt the zoonotic life cycle, they may be incidentally infected and thus become *incidental* (or *accidental*) hosts. In an *intermediate* host, the parasite exists in larval or asexual forms pending transmission to a definitive host.<sup>1</sup>

Often, the means by which a parasite is transmitted to the host involves an agent (eg, arthropod, mollusk), which is referred to as the *vector* of disease transmission. In a biological vector, the parasite undergoes development or multiplication prior to transmission. On the other hand, a mechanical vector carries or transmits the organism without any biological modification of its life cycle.<sup>1</sup>

Because they are deployed worldwide, U.S. armed forces are often in tropical locales where parasitic organisms produce diseases that may be truly foreign to the clinical experience of many military physicians. Although the historical record suggests that bacterial and fungal infections and immersion syndromes

produce the bulk of cutaneous disease, the record also shows that parasites can cause considerable morbidity in war.<sup>2</sup> Tropical parasitic diseases that manifest with distinctive cutaneous signs offer a unique opportunity for early diagnosis and treatment. To reduce morbidity and thus increase troop effectiveness and morale, medical officers must know the cutaneous signs, methods of diagnosis, epidemiology, and effective treatment of these diseases.

Furthermore, members of the local populace, in whom the incidence and prevalence of these diseases is much greater, are often treated at military medical treatment facilities. During peacetime humanitarian missions, this is expected; however, it also often occurs during wartime. During the Vietnam conflict, medical teams were sent to treat natives in nearby villages. The 18th Surgical Hospital (Mobile), located south of the border with North Vietnam at Quang Tri, Republic of Vietnam, had 20 to 30 beds added to its normal configuration to care for pediatric patients.<sup>3</sup> During Operation Desert Storm in Southwest Asia, physicians who were attached to hospitals that were deployed forward into Iraq, providing medical and surgical support to forces engaged in active combat, also provided medical and surgical care to civilians caught within the theater of operations. An understanding of the tropical parasitic diseases in the civilian populace, then, becomes important not only in delivering proper medical care but also in limiting the possibility of spread of disease from these civilians, who may also serve as disease reservoirs.<sup>4</sup>

Diseases common to the tropics are discussed in other chapters in this textbook. This chapter focuses on the characteristic cutaneous manifestations of protozoan and helminthic diseases that medical officers might expect to encounter during troop deployments.

## PROTOZOAL INFECTIONS

Parasitic protozoa that are infectious to humans are generally unicellular organisms that have nuclear structures separated from the cytoplasm by a membrane. Because these organisms can replicate in human tissue, single exposures can result in massive infections.<sup>1</sup> Those most likely to be associated with cutaneous manifestations are to be found in subphylum Mastigophora (in which flagella are

the characteristic means of locomotion) or in subphylum Sarcodina (in which pseudopodia [ie, creeping protoplasmic flow] are the basis of movement).<sup>1,5</sup>

### Leishmaniasis

While reporting on a case of Delhi boil in 1885, British Surgeon-Major D. D. Cunningham is cred-

ited with making the first scientific observation of leishmanial organisms. Subsequently, Borovsky and Wright, working independently, concluded that the parasite was probably protozoan. In 1903, two British Army medical officers, Colonel W. B. Leishman (of the Royal Army Medical College) and Colonel C. Donovan (of the Indian Medical Service, working at Madras, India) discovered that the parasite is the cause of visceral leishmaniasis; henceforth, the organism has been referred to as a Leishman-Donovan body in tissue.<sup>6</sup>

Although in 1913 the British Army reported only 53 cases of "oriental sore," the numbers increased during World War I to an estimated 10,000 in its Mesopotamia Force.<sup>7</sup> During World War II, U.S. forces experienced 1,000 to 1,500 cases of cutaneous leishmaniasis, most of which originated in the Persian Gulf Command between October 1943 and August 1945. Because all these soldiers were treated as outpatients, manpower was little affected. Fifty to 75 cases of visceral leishmaniasis were estimated to have occurred in the Mediterranean Theater of Operations and India.<sup>8</sup>

To standardize therapy, the treatment of leishmaniasis in U.S. military personnel has been done on protocol at Walter Reed Army Medical Center, Washington, D. C. Between 1957 and 1981, approximately 288 patients diagnosed as having leishmaniasis were treated—most having contracted the disease in Central or South America. (Because the leishmanial species from this region have the potential to cause mucocutaneous disease, treatment takes on added importance.) By 1994, the

## OK to put on the Web

**Fig. 12-1.** Intracellular amastigotes of cutaneous leishmaniasis. Photograph: Courtesy of Lieutenant Colonel Martha L. McCollough, Medical Corps, U.S. Army, San Antonio, Tex.

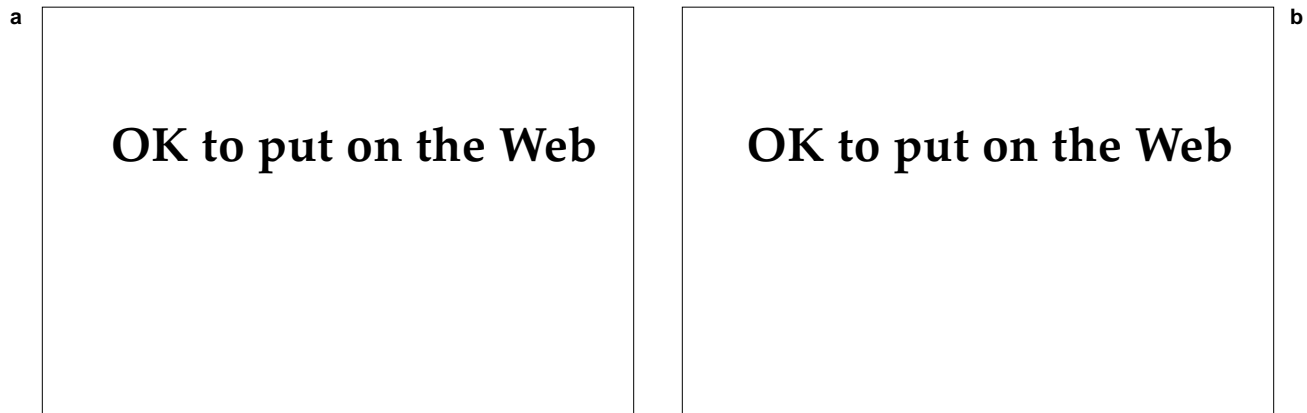
## OK to put on the Web

**Fig. 12-2.** Promastigotes of leishmaniasis obtained from an infected sandfly. The flagellum, large central nucleus, and kinetoplast are apparent.

total number of cases had increased to more than 440.<sup>9</sup> A number of patients (including several cases of systemic disease that were documented by bone marrow examination) were diagnosed following Operations Desert Shield and Desert Storm in 1990 and 1991.<sup>10</sup> Given the fact that the primary lesion of leishmaniasis from Southwest Asia tends to be of short duration and often is a self-limited disease, it is likely that a number of cases of cutaneous leishmaniasis have gone unreported or undiagnosed.

The life cycle of leishmaniasis begins in nature with a variety of animals (eg, dogs, sloths, rodents), as well as humans, serving as reservoirs for infection.<sup>11</sup> Located within reticuloendothelial cells of infected tissues, leishmania exist in an *amastigote* (nonflagellate) form, which is round or oval in shape and approximately 2 to 5  $\mu\text{m}$  in its greatest dimension (Figure 12-1). Feeding on a reservoir animal's infected tissues, female sandflies of the genera *Phlebotomus* or *Lutzomyia* ingest the parasitized cells. In the gut of the vector, the leishmania transform to the *promastigote* (or flagellate) form (Figure 12-2). The promastigote is a slender organism with a flagellum, undulating membrane, nucleus, and terminal kinetoplast; it can measure 28  $\mu\text{m}$  (including the flagellum) in length. After replicating, the leishmania promastigotes migrate to the sandfly's proboscis, from which they are regurgitated into the next host as the sandfly feeds (Figure 12-3).

Although the adult sandfly lives only a few weeks, it is able to transmit disease within 7 to 10 days after feeding on an infected reservoir host.<sup>11</sup> In some cases, the number of promastigotes is so great that they may physically obstruct the proboscis and



**Fig. 12-3.** (a) An adult sandfly, the vector of leishmaniasis. (b) The sandfly, seen in close-up. Photographs: Courtesy of Jorge Molina, M.D., Honduras, Central America.

prevent feeding.<sup>12</sup> Thus, the sandfly may make several attempts before successfully feeding. As a result, multiple primary inoculations, resulting in multiple primary lesions, can occur in a single human host; in other cases, single abortive feeding attempts on different persons may cause several individuals to become infected.

Once introduced into human skin, promastigotes activate complement, bind C3, and become internalized by means of complement receptors on mature macrophages.<sup>13,14</sup> Assuming the amastigote form, the leishmania replicate, causing the cell to rupture, which releases amastigotes that then infect other cells. Thus, infection (as defined by the presence of organisms) may be widespread, although the obvious manifestations of disease are limited.

Control of disease by eliminating the parasite is thought to be mediated by (a) a cellular oxidative burst or (b) lymphocyte-mediated cytotoxicity. When the cellular immune response is adequate, the parasite is eliminated and species-specific immunity results. Also, limited cross-immunity with other *Leishmania* species develops in some cases. Immunity, however, is not absolute, as reinfection with the same species of organism can occur.<sup>13</sup>

The taxonomy of the genus *Leishmania* has been complicated by the inclusion of complexes, subgenera, species, and subspecies identification based on a variety of clinical, biological, epidemiological, immunological, and biochemical criteria.<sup>15</sup> For a number of years, the standard procedure has been to classify organisms as members of complexes: *L mexicana* complex, *L braziliensis* complex, *L tropica* complex, or *L donovani* complex. A recently proposed change in the classification is that all mammalian leishmania that develop in the foregut or

midgut of the vector be placed into subgenus *Leishmania*, and those with hindgut development into subgenus *Viannia*. Because a consensus has yet to be developed, many authorities have adopted the simplified nomenclature used in Table 12-1.<sup>16,17</sup>

#### **Cutaneous Manifestations**

Clinically, it is convenient (although immunologically simplistic) to think of leishmaniasis in three forms: cutaneous, mucocutaneous, and visceral. Because of clinical differences, the disease is often classified as Old World (Africa, the Mediterranean littoral, the Middle East, India, Southwest Asia, and Asia) or New World (Central America and South America) leishmaniasis. Old World leishmaniasis tends to produce either cutaneous or visceral disease, while New World leishmaniasis may be cutaneous, mucocutaneous, or visceral.

Morphologically, the initial cutaneous lesions of both Old World and New World disease are similar (Figures 12-4, 12-5, and 12-6).<sup>13,18-23</sup> In the Old World, these lesions are called Baghdad sore, Aleppo boil, Delhi boil, or oriental sore. Synonyms for cutaneous New World disease include American leishmaniasis, South American leishmaniasis, *uta*, *pian bois*, and Chiclero's ulcer. Generally occurring on exposed areas of the body (ie, face, ears, arms, legs), single or multiple erythematous papules develop weeks to months after the bite of an infected sandfly. The papules enlarge ( $\geq 1-5$  cm) to form indurated nodules or plaques. Satellite lesions are not uncommon. These lesions may have overlying scale or they may ulcerate, leaving a central crater. The extensive differential diagnosis includes pyoderma, kerion, deep fungal infection, tuberculosis, atypical

**TABLE 12-1**

**NAMES, GEOGRAPHICAL DISTRIBUTION, AND DISEASE MANIFESTATION OF *LEISHMANIA* SPECIES THAT INFECT HUMANS**

Table 12-1 is not shown because the copyright permission granted to the Borden Institute, TMM, does not allow the Borden Institute to grant permission to other users and/or does not include usage in electronic media. The current user must apply to the publisher named in the figure legend for permission to use this illustration in any type of publication media.

\*rare manifestation

†taxa not recognized by all authorities

CL: cutaneous leishmaniasis

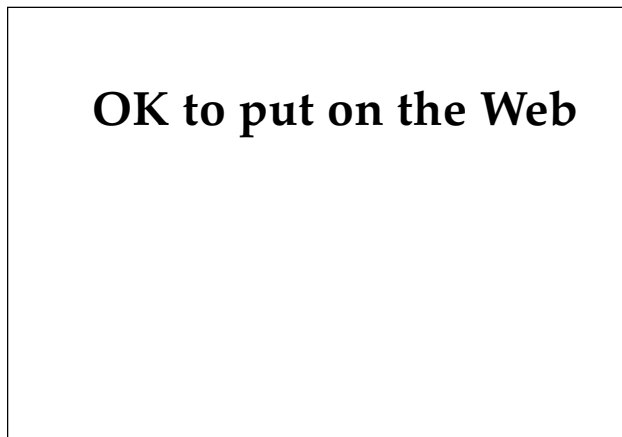
DCL: disseminated cutaneous leishmaniasis

MCL: mucocutaneous leishmaniasis

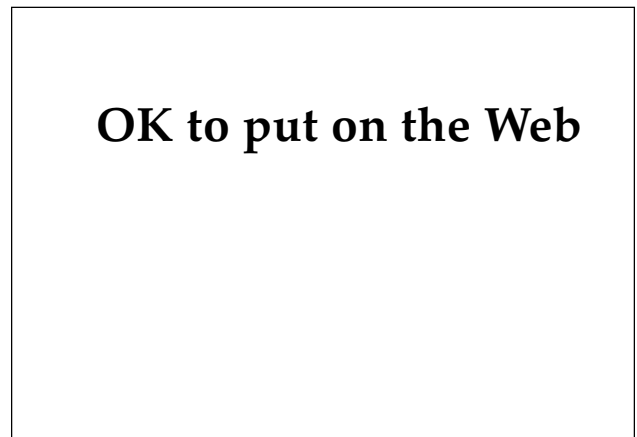
PKADL: post-kala-azar dermal leishmaniasis

VL: visceral leishmaniasis

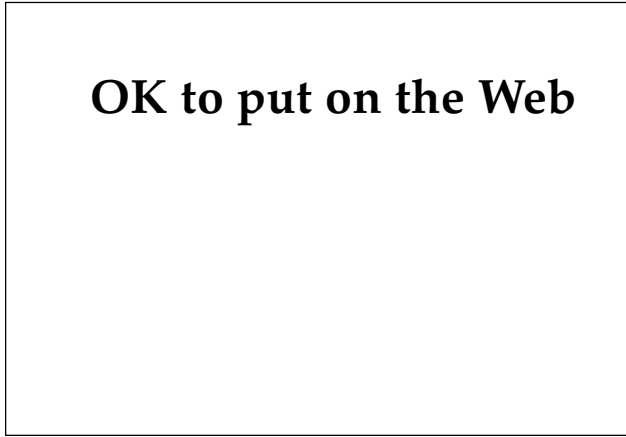
Reprinted with permission from Walton BC. Leishmaniasis: A worldwide problem. *Int J Dermatol*. 1989;28:307.



**Fig. 12-4.** An ulcerated nodule of cutaneous leishmaniasis in an active-duty soldier. The lesion appeared during Operation Desert Shield in Saudi Arabia. Clinical resolution occurred spontaneously after 6 to 7 months.



**Fig. 12-5.** An ulcerated nodule of leishmaniasis in a patient from Panama.



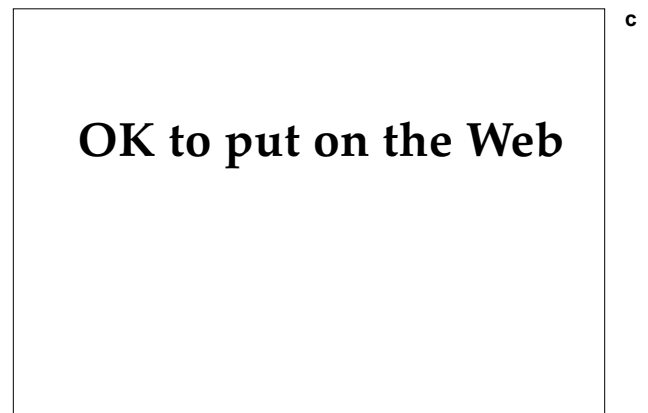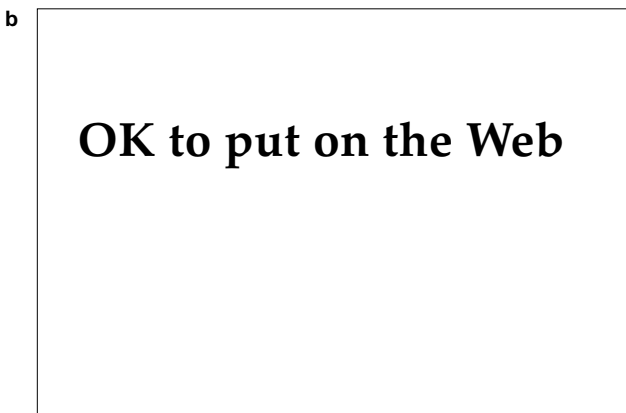
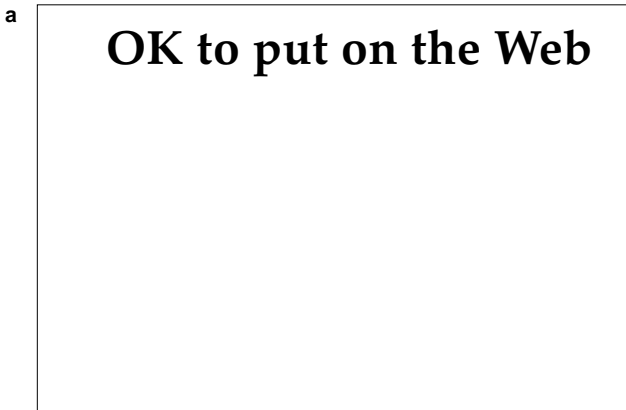
**Fig. 12-6.** A cutaneous ulcer of leishmaniasis. Photograph: Courtesy of Colonel Alfred K. Cheng, Medical Corps, U.S. Air Force (ret), San Antonio, Tex.

mycobacteria, sarcoidosis, foreign body reaction, squamous cell carcinoma, or granuloma faciale. Extension of disease may be manifest as subcutaneous nodules following the lymphatic drainage, which occurs in both Old World and New World disease (Figure 12-7).<sup>24</sup> Gradually the lesions begin to flatten and develop dermal fibrosis, leaving an irregular, sometimes disfiguring, scar. Disease due to *L tropica* or *L major* (Old World) generally resolves within a few months to a year. Leishmaniasis occurring in Central America or South America may produce cutaneous lesions that persist for much longer periods of time.<sup>21</sup>

A form of leishmaniasis associated with specific immunological unresponsiveness is disseminated anergic cutaneous leishmaniasis, often called diffuse cutaneous leishmaniasis.<sup>18,19</sup> In patients with this disease, hundreds of nonulcerating nodules and plaques develop and may become confluent. The facial involvement may become extensive and create the appearance of leonine facies. Macrophages within the lesions teem with amastigotes and the skin test reaction to leishmanial antigen is negative. Visceral involvement is thought not to occur.<sup>19</sup> The differential diagnosis includes lepromatous leprosy.

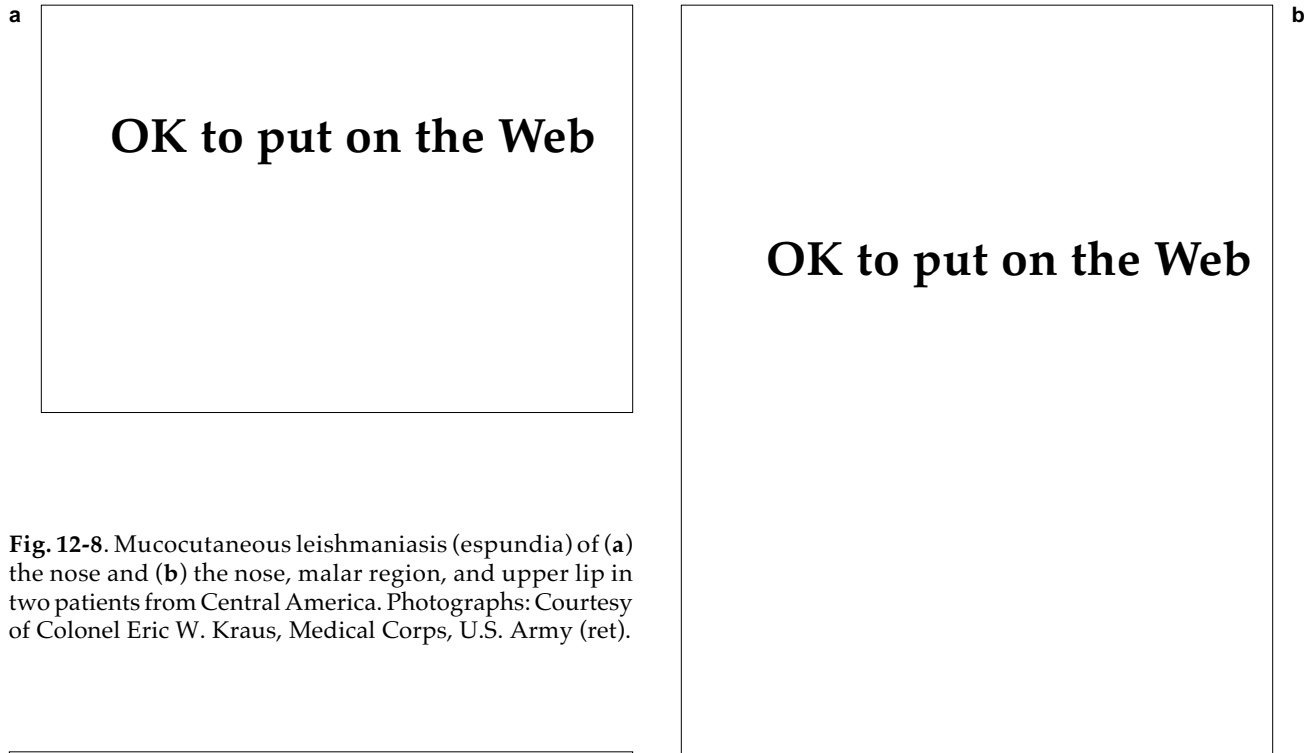
**Mucocutaneous Manifestations**

Seemingly unique to the spectrum of New World disease, espundia (mucocutaneous leishmaniasis) is caused by infection with *L braziliensis* or *L*

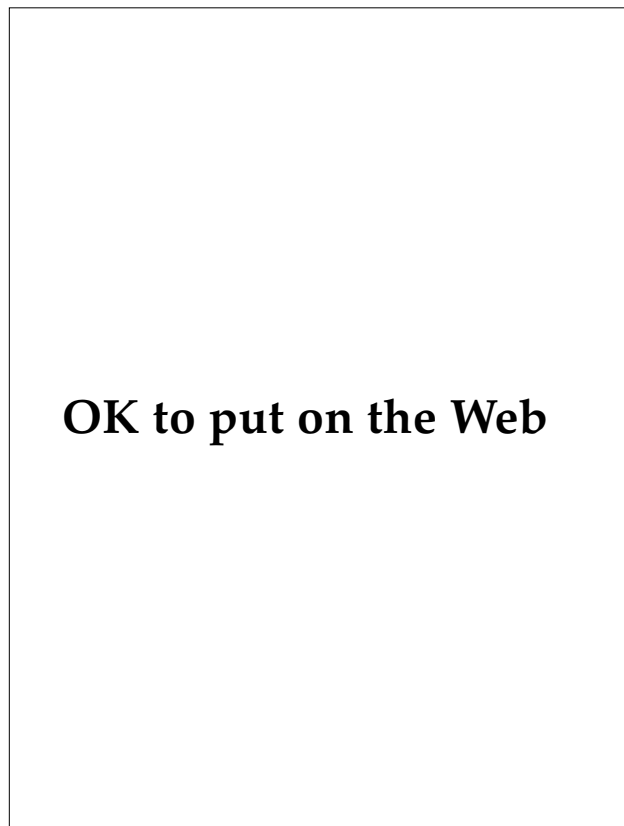


**Fig. 12-7.** (a) Plaque with satellite papules of *Leishmania panamensis* in a U.S. Army soldier on active duty in Panama, Central America. (b) The soldier's inner arm shows the array of papules and nodules occurring along lymphatic drainage that is known as sporotrichoid lymphatic involvement. (c) Close-up of the lesions along the pathway of lymphatic drainage.





**Fig. 12-8.** Mucocutaneous leishmaniasis (espundia) of (a) the nose and (b) the nose, malar region, and upper lip in two patients from Central America. Photographs: Courtesy of Colonel Eric W. Kraus, Medical Corps, U.S. Army (ret).



**Fig. 12-9.** Mucocutaneous leishmaniasis. A friable plaque (arrow) in the patient's posterior pharynx. Photograph: Courtesy of Colonel Alfred K. Cheng, Medical Corps, U.S. Air Force (ret), San Antonio, Tex.

*panamensis*.<sup>17</sup> Recurrent leishmaniasis involving the upper respiratory system may develop 3 to 10 years after the primary lesion—often at a distant site—has apparently healed.<sup>21</sup> Symptoms frequently begin with epistaxis or coryza, with subsequent extensive destruction of the nasal cartilage (Figure 12-8). The resulting overhanging nasal deformity coupled with infiltration is said to make the patient resemble a tapir.<sup>19</sup> Espundia's further progression to the palate, tongue, floor of the mouth, and pharynx may create an extensive midline facial defect (Figure 12-9). Untreated, inanition with aspiration pneumonia and death may occur (Figure 12-10). The differential diagnosis of espundia includes deep fungal infections, lethal midline granuloma, malignant tumors, rhinoscleroma, syphilis, tuberculosis, and leprosy.

#### **Visceral Manifestations**

Visceral leishmaniasis is caused by organisms of both the Old World and the New World (see Table 12-1). Viscerotropic species cause a systemic disease that may have fever, malaise, abdominal swelling, pain, anorexia, hepatosplenomegaly, and anemia. The earth-gray pigmentation of the face, hands, and feet gives this disease its common name, kala

## OK to put on the Web

**Fig. 12-10.** Mucocutaneous leishmaniasis. Autopsy specimen showing tracheal involvement. The patient died after aspirating a portion of the plaque. Photograph: Courtesy of Colonel Alfred K. Cheng, Medical Corps, U.S. Air Force (ret), San Antonio, Tex.

azar (ie, black sickness).<sup>25</sup> No pigmentary changes were noted in the cases of visceral disease that occurred among U.S. military personnel during World War II.<sup>26</sup> Either during the course of treatment or years after their apparent cure, an eruption of hypopigmented macules, butterfly erythema, and diffuse nodules develop in some patients in Kenya and India with visceral leishmaniasis.<sup>25,26</sup> The disorder is known as post-kala azar dermal leishmaniasis.

### Diagnosis

Diagnosis of leishmaniasis is generally accomplished by demonstrating the organism.<sup>22,23,27,28</sup> Methods of directly visualizing leishmania that are infecting tissue include the following:

- scraping of the primary lesion,
- a nonbloody slit smear of a nodule,

- needle aspiration at the elevated edge away from the scar, or
- biopsy and subsequent touch preparation.

All of these preparations are stained by Giemsa or Wright's stain and the investigator should look for the amastigote within the cell. Demonstrating organisms in tissue by this method is difficult, especially when numbers of parasites are low; thus, cultures of tissue specimens are often prepared. Results of cultures, however, are dependent on the numbers of organisms inoculated and the skill of the laboratory. The culture is usually grown on Novy-MacNeal medium, modified by Nicolle (ie, NNN medium), overlaid with Schneider's *Drosophila* medium and fetal bovine serum. Promastigotes are demonstrated in positive cultures. The Montenegro intradermal skin test is produced from promastigotes but is not commercially available in the United States.<sup>28</sup> This skin test is of limited usefulness in endemic areas because (a) a high percentage of the population may have been exposed to leishmania and (b) diffuse cutaneous disease tests negative. Serologic tests, in particular indirect fluorescent antibody tests and enzyme immunosorbent assays, have been developed but may be negative in 20% to 30% of cases.<sup>23,28</sup> Indirect immunofluorescent studies using monoclonal antibodies directed against leishmanial antigens are more sensitive than either Giemsa stains or culture and hold great promise in facilitating diagnosis.<sup>10,29</sup>

### Therapy

Comprehensive reviews of therapy are available.<sup>30,31</sup> Medical officers must keep in mind that strictly cutaneous Old World leishmaniasis is often self-healing, generally does not presage the development of kala azar, and thus may not require treatment. However, in addition to those patients having visceral disease, those whose cutaneous disease manifests as multiple lesions, facial lesions, or lesions occurring over a joint where motion might be limited by scar formation warrant consideration for therapy. Primary cutaneous lesions of New World leishmaniasis also show self-healing. However, because (a) cutaneous disease of New World leishmaniasis has a longer duration and (b) subsequent mucocutaneous disease is a possibility, patients with New World leishmaniasis are treated. *L. tropica*, *L. major*, *L. donovani*, *L. mexicana*, and *L. braziliensis* are treated with stibogluconate sodium (20 mg Sb [antimony, the active ingredient]/kg/d, administered intravenously or intramuscularly for

20–28 d) or meglumine antimonate (20 mg Sb/kg/d, for 20–28 d, route of administration not specified).<sup>32</sup> Adequate treatment of cutaneous disease due to *L braziliensis* may markedly diminish the risk of espundia.<sup>33</sup> Because pentavalent antimonials are not always effective and drug resistance has been documented, the quest for new therapies continues.<sup>34,35</sup> Investigational treatments include the use of amphotericin B, pentamidine isethionate, ketoconazole, recombinant human gamma interferon, and heat.<sup>22,32</sup>

### South American Trypanosomiasis

*Trypanosoma cruzi* causes a disease encountered in Central America and South America known as South American trypanosomiasis or Chagas' disease. Over a period of years, the disease may evolve from an acute stage, which includes cutaneous manifestations, through a clinically silent latent stage, to a chronic phase characterized by cardiac and gastrointestinal disease.

The life cycle of the parasite causing human disease typically begins with a wide variety of domestic (eg, dogs, cats, pigs) and wild (eg, rodents, marsupials) animals, which serve as reservoirs for infection.<sup>36–38</sup> The trypomastigote form circulates in the blood stream as a slender, spindle-shaped form, 15 to 20  $\mu\text{m}$  in length (in humans), having a nucleus, terminal kinetoplast, undulating membrane, and a long flagellum (Figure 12-11). While feeding on infected animals, true bugs (of the suborder Hemiptera) from the insect family Reduviidae (subfamily Triatomidae) ingest the trypomastigote. Dividing and transforming in the gut of the bug, the *T cruzi* appear in the hindgut as metacyclic trypomastigotes, which are infective to humans. Once infected, the bug remains so for life. Although many species of triatomid bugs exist, those that are adapted to living in human habitats serve as vectors of trypanosomiasis: *Rhodnius prolixus* in Central America, Colombia, and Venezuela (Figure 12-12); *Triatoma infestans* throughout much of South America; and *Panstrongylus megistus* in Brazil. Hiding within the cracks and crevices of mud and thatch homes during the day, the bug ventures out at night to feed on exposed skin (typically the face, hence the name "kissing bug") of sleeping humans. While feeding, the bug defecates, thus depositing the infective metacyclic trypomastigotes on the skin surface. Although the insect is undetected while feeding, a short time later the victim develops pruritus, which elicits a rubbing or scratching response, which then inoculates the organism from the fecal deposit into

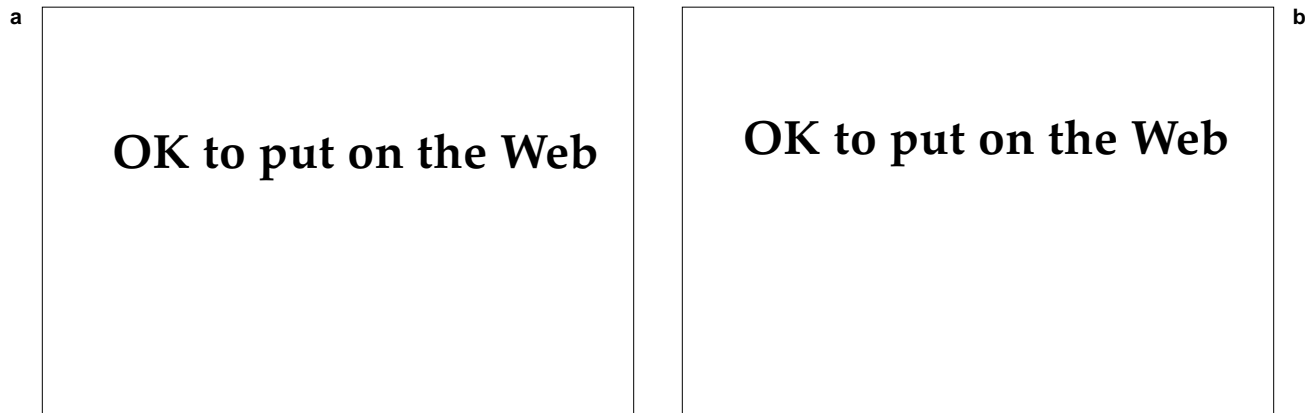
## OK to put on the Web

**Fig. 12-11.** A peripheral blood smear of *Trypanosoma cruzi*. The flagellum, undulating membrane, nucleus, and large terminal kinetoplast are obvious. The C-shape is characteristic. Photograph: Courtesy of Armed Forces Institute of Pathology. Negative 73-1150.

the victim's skin or mucous membrane. Invading tissue macrophages, the organisms transform to rounded, nonflagellate amastigote forms of approximately 3  $\mu\text{m}$  in diameter.

## OK to put on the Web

**Fig. 12-12.** A reduviid bug, the vector of South American trypanosomiasis. Photograph: Courtesy of Colonel Alfred K. Cheng, Medical Corps, U.S. Air Force (ret), San Antonio, Tex.



**Fig. 12-13.** (a) Amastigotes of *Trypanosoma cruzi* within a cardiac muscle fiber. (b) Inflammatory response elicited by the rupture of cardiac muscle fiber releasing trypanosomes. Photographs: Courtesy of Colonel Alfred K. Cheng, Medical Corps, U.S. Air Force (ret), San Antonio, Tex.

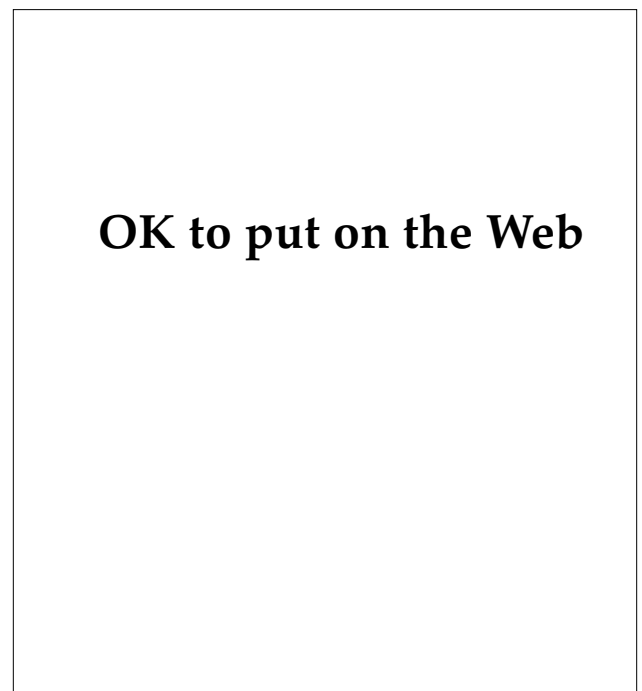Multiplying by binary fission, the *T cruzi* burst from the macrophages as trypomastigotes and disseminate widely to invade most human tissues including cardiac and skeletal muscle, parasympathetic ganglion cells, the central nervous system (CNS), and the reticuloendothelial system, where the cycle is repeated (Figure 12-13).<sup>39,40</sup> In addition to being vector-borne, the disease can also be transmitted transplacentally, by transfusion, transplantation, and in laboratory accidents.<sup>41</sup>

The circulating trypomastigotes produce a glycoprotein that may protect them from destruction by the alternate complement pathway.<sup>38,40</sup> Thus, parasites are relatively numerous initially and easily demonstrable on peripheral blood smear. With time, however, the human body produces neutralizing antibodies that permit complement-mediated destruction. Binding to fibronectin receptors on monocytes and macrophages, the *T cruzi* are internalized to the cytoplasm, where they are protected from the cellular oxidative burst as well as from the hostile extracellular milieu. This phase of immunologically diminished but, importantly, life-long parasitemia corresponds to latent and chronic phases of disease and creates a reservoir of disease. Although the parasite persists in the human body, an autoimmune response to the parasite may magnify the extent of parasite-induced disease—especially in the chronic stages.<sup>42</sup>

#### **Clinical Manifestations**

While infection may occur at any age, often only in children is clinical disease detected acutely.<sup>39,40,43-45</sup> Rupturing from infected macrophages about 5 days

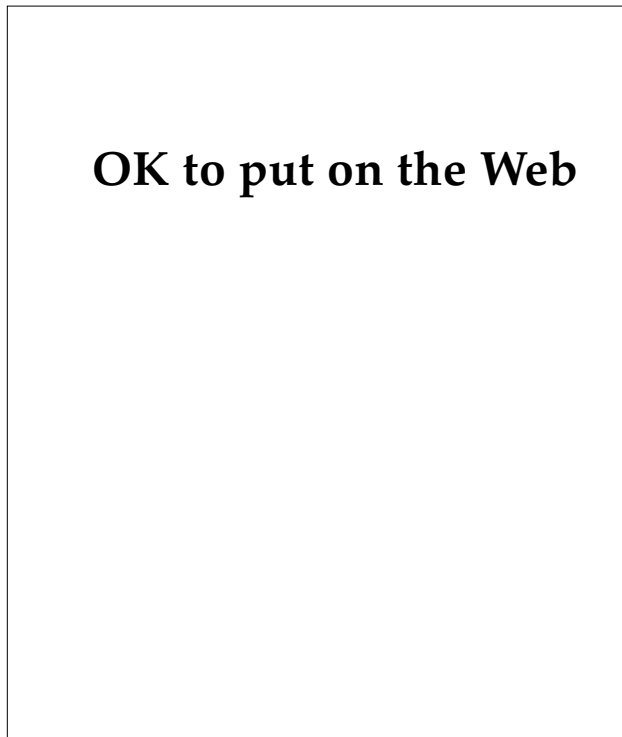
after infection, the *T cruzi* precipitate an inflammatory response at the site of inoculation. This produces an erythematous, edematous, indurated lesion, known as a *chagoma*, which is only minimally tender. A *chagoma* occurring on the eyelid and conjunctivae is known as Romana’s sign and is often associated with bipalpebral edema and en-



**Fig. 12-14.** A child manifesting Romana’s sign of South American trypanosomiasis. Photograph: Courtesy of Colonel Alfred K. Cheng, Medical Corps, U.S. Air Force (ret), San Antonio, Tex.

larged preauricular nodes (Figure 12-14). The chagoma lasts only a few days to a couple of weeks. However, the hematogenous dissemination and subsequent widespread tissue invasion may precipitate an acute systemic illness with fever to 104°F, vomiting, diarrhea, cough, hepatosplenomegaly, edema, myocarditis, seizures, and meningoencephalitis. Occasionally, a transient morbilliform, urticarial, or erythema multiforme-like eruption precedes the hepatosplenomegaly.<sup>39,40</sup> Ninety percent or more of patients survive the acute stage,<sup>40,44</sup> which subsides in 1 to 3 months.<sup>40</sup>

Patients then enter a latent phase of disease during which they are relatively asymptomatic, and parasitemia is difficult to detect on a peripheral blood smear. Estimates vary, but after years or decades, 10% to 20% of patients<sup>46</sup> or 10% to 30% of patients<sup>41</sup> develop chronic symptomatic disease. Myocardial heart disease, with fibrosis, conduction defects, cardiomegaly, failure, and an apical ventricular aneurysm, is characteristic (Figures 12-15 and 12-16).<sup>38,43-45,47</sup> Local denervation is believed to be important in the pathogenesis of cardiac disease.<sup>41</sup>



**Fig. 12-15.** Cardiomegaly of South American trypanosomiasis. Photograph: Courtesy of Colonel Alfred K. Cheng, Medical Corps, U.S. Air Force (ret), San Antonio, Tex.

## OK to put on the Web

**Fig. 12-16.** This markedly thinned cardiac ventricular wall is due to chronic disease with *Trypanosoma cruzi*. Photograph: Courtesy of Colonel Alfred K. Cheng, Medical Corps, U.S. Air Force (ret), San Antonio, Tex.

Destruction of the parasympathetic ganglion leads to dilation of portions of the gastrointestinal tract, typically the esophagus and colon, which is known as mega syndrome.<sup>38,40,44,48</sup> Dysphagia, aperistalsis, regurgitation, and constipation may result.

### Diagnosis and Treatment

In acute disease, diagnosis is established by finding trypomastigotes in the patient's blood. Complement fixation, indirect immunofluorescence, hemagglutination, and enzyme-linked immunosorbent assays (ELISAs) have been used for serologic diagnosis of chronic disease. However, because the tests lack specificity, it has been recommended that two different, positive assays be used to establish a diagnosis.<sup>41</sup> Organisms can be detected in about 50% of patients who have positive complement-fixation tests by allowing laboratory-raised reduviid bugs to feed on the individual and then identifying trypomastigotes in the bug—a technique known as xenodiagnosis.<sup>44</sup>

Nifurtimox (adult dose: 8–10 mg/kg/d, divided and administered orally 4 times daily for 120 days; the pediatric dosage is discussed elsewhere<sup>32</sup>) or benznidazole (5–7 mg/kg/d for 30–120 d, mode of administration not specified) are useful but toxic in the parasitemic phase of disease.<sup>32,38,41</sup> The amastigotes in tissue, however, are not eradicated by medication so the chronic disease persists despite treatment.<sup>38,41,44,47</sup> Therefore, control of the vector in the domestic setting is the key to preventing the disease.

## OK to put on the Web

**Fig. 12-17.** This smear of peripheral blood shows the trypomastigotes of *Trypanosoma (T) b rhodesiense*. The flagellum, undulating membrane, large nucleus, and small terminal kinetoplast are apparent. Photograph: Courtesy of Armed Forces Institute of Pathology. Negative 74-19698.

### African Trypanosomiasis

In sub-Saharan Africa, trypanosomes produce a disease known as African trypanosomiasis (sleeping sickness). Two morphologically similar organisms produce diseases with cutaneous, cardiac, and CNS manifestations that are ultimately fatal if not treated.<sup>46</sup> Geographical restrictions, rapidity of disease progression, and drug response are some features used to distinguish the two.<sup>49</sup>

Taxonomically, the organisms are placed in the genus *Trypanosoma* (subgenus *Trypanozoon*) and species *brucei*; *rhodesiense* is the subspecies in East Africa and *gambiense* in West Africa. The organisms are long and slender, measuring up to 30 × 3.5 μm, and each has a nucleus, kinetoplast, undulating membrane, and long flagellum (Figure 12-17). In East Africa, the reservoir is animal, while in West Africa, it is human.<sup>49</sup>

Hematophagous tsetse flies of the genus *Glossina* are the vectors of disease: *G morsitans* is the most important in East Africa (Figure 12-18) and *G palpalis* in West Africa.<sup>49</sup> *G morsitans* is found in savanna and woodland areas, while *G palpalis* is found in the thickets along rivers and lakes.<sup>49,50</sup> The flies have a painful bite, will follow moving objects, and will bite through thin clothing.<sup>49</sup> They are, however, susceptible to becoming desiccated; thus, brief exposures to light are potentially lethal.<sup>50</sup> Because the tsetse fly's distribution is widespread and the potential for resulting epidemics is great, one fourth of the African continent is effectively unavailable for

## OK to put on the Web

**Fig. 12-18.** A tsetse fly—the vector of African trypanosomiasis. This specimen is *Glossina morsitans*, the vector of East African (*rhodesiense*) disease. Photograph: Courtesy of Armed Forces Institute of Pathology. Negative 75-14469.

human habitation.<sup>51</sup> In an endemic area, however, less than 1% of the flies are infected; the number increases to perhaps 5% in epidemic areas.<sup>49</sup> Once infected, the fly remains so for life.

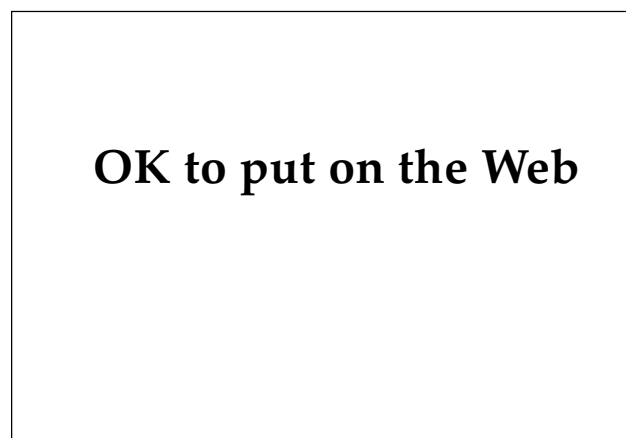In the production of human disease, the life cycle begins when the tsetse fly (*Glossina*) feeds on an infected reservoir animal.<sup>49,50</sup> The tsetse fly ingests trypomastigotes, which multiply by binary fission in the fly's midgut. Then moving to the fly's salivary gland, the trypomastigotes transform in stages to become infective metacyclic trypomastigotes. In those flies capable of transmitting disease, the time from ingestion to the development of infective trypanosomes is about 3 weeks. When the fly next feeds on human blood, it injects the trypanosomes into the human. Initially multiplying at the site of the bite and later in the victim's bloodstream and lymphatics, the organisms ultimately gain access, through the blood-brain barrier, to the CNS. These trypanosomes do not become internalized within the tissue cells, but do elicit an inflammatory response in many organs.<sup>37</sup> The organisms are difficult to identify in biopsy material.<sup>50</sup>

Trypanosomes shift their antigenic surface coat, with the result that effective immunological containment may not be achieved.<sup>49</sup> Because immunity is only type-specific, new antigenic strains of trypanosomes constantly appear in the infected host. There is an initial lymphatic and plasma cell response with a nonspecific elevation of immunoglobulin (Ig) M; later, though, a state of relative cellular and humoral immunosuppression develops.

### Clinical Manifestations

The signs and symptoms of the disease vary somewhat according to the area in which the disease was contracted.<sup>40,46,49,50,52</sup> Within 1 to 2 weeks after the bite, a dusky red nodule, which can reach 5 cm in size, develops and lasts approximately 2 weeks. This lesion, the primary chancre, may be painful and often is located on the lower extremities. The lesion is reported more often in nonindigenous persons, who have no partial immunity, and in disease caused by *T (T) b rhodesiense*.<sup>49,51,52</sup>

The appearance of fever marks the beginning of the parasitemic phase of the disease; it may occur within a week in East African disease or, in West African disease, in the immunologically naive.<sup>51,52</sup> Then the patient may experience intermittent fevers, headache, dizziness, joint pain, hepatosplenomegaly, lymphadenopathy, malaise, anorexia, irritability, personality change, and insomnia. Posterior cervical lymphadenopathy (ie, Winterbottom's sign) is thought to be characteristic of the disease caused by *T (T) b gambiense* (Figure 12-19).<sup>49,50</sup> About 10 days after the initial fever, a cutaneous eruption occurs in almost 50% of the cases.<sup>49</sup> The asymptomatic, circinate or oval, erythematous macules with clear centers may suggest an erythema multiforme-like eruption on the trunk.<sup>40,49,52</sup> Kerandel's sign, variously described as a delayed sensation to pain or as a sensation of hyperesthesia, may be frequent.<sup>37,46,49</sup> Pancarditis



**Fig. 12-19.** Enlarged posterior cervical nodes—Winterbottom's sign of West African (*gambiense*) trypanosomiasis. Photograph: Courtesy of Armed Forces Institute of Pathology. Negative 74-8337.

and arrhythmias may develop, particularly in patients with East African (*rhodesiense*) disease. Presumably because of partial immunity, months or years may elapse before infected individuals who are long-term inhabitants of endemic West African areas experience clinical symptoms.<sup>49,51</sup>

The patient entering a late or chronic phase of disease develops signs of meningoencephalitis. Somnolence, lassitude, indifference, seizures, and personality changes may develop and, with further deterioration, coma ensues. These CNS changes may be more likely to develop in patients with West African (*gambiense*) disease because of its more gradual progression.<sup>49</sup> East African (*rhodesiense*) disease may be more acute and fulminant, with patients dying of cardiac disease sometimes within a few months of contracting the infection.

### Diagnosis

Nonspecific abnormal laboratory findings include elevated erythrocyte sedimentation rate, markedly elevated IgM, moderately elevated IgG, cryoglobulinemia, anemia, thrombocytopenia, disseminated intravascular coagulation, and abnormal liver function tests.<sup>46,49</sup> Many of these are found more commonly in disease due to *T (T) b rhodesiense*.

Because of the greater degree of parasitemia, demonstration of *T (T) b rhodesiense* on thick and thin smears is easier than with *T (T) b gambiense*. Examination of aspirated fluid from a chancre or node, as well as bone marrow or cerebral spinal fluid, is useful in these situations. Increased leukocytes ( $> 5 / \text{mm}^3$ ) and protein ( $> 25 \text{ mg} / \text{dL}$ ), and/or increased IgM in the cerebral spinal fluid suggests a CNS invasion.<sup>49</sup> Serologic tests become positive 2 to 4 weeks after the onset of disease, which may be too late to be useful for diagnosing a patient with fulminant East African disease. Further, the antigenic variability of the trypanosomes makes standardizing immunofluorescence, hemagglutination, and ELISAs difficult.<sup>46</sup>

### Therapy

Suramin, which does not cross the blood-brain barrier, is very effective in destroying trypanosomes and effecting a cure when there is no CNS disease.<sup>34,50</sup> The adult dose is 100 to 200 mg administered intravenously (as a test dose), then 1 g administered intravenously on days 1, 3, 7, 14, and 21.<sup>32</sup> The pediatric dose is 200 mg/kg administered on days 1, 3, 7, 14, and 21.

Melarsoprol is effective in all stages of sleeping sickness, including CNS involvement; but, because of its toxicity (the drug can produce a fatal reactive encephalopathy), it is used only when the CNS is involved or when other drugs fail. The adult dose is 2.0 to 3.6 mg/kg/d, administered intravenously for 3 days; after 1 week, the dose is 3.5 to 4.5 mg/kg/d, for 3 days; 7 days later, 5.0 mg/kg/d is given for 3 days. The pediatric dosage is discussed elsewhere.<sup>32</sup>

### Amebiasis

Infection with the amoeba *Entamoeba histolytica* is known as amebiasis. The spectrum of clinical presentation includes an acute dysenteric form and a less symptomatic, nondysenteric, intestinal form; some people with amebiasis are asymptomatic cyst passers. From these presentations, a variety of mechanisms have been proposed to explain the development of cutaneous lesions. In 1986, it was estimated that 480,000,000 people (slightly > 10% of the global population) were infected, with the majority (> 80%) asymptomatic.<sup>53</sup> Amebiasis causes 40,000 to 75,000 or more deaths per year and may be the third-leading parasitic cause of death.<sup>53,54</sup> Significant numbers of U.S. military personnel were exposed to amebiasis during World War I, World War II, and the Korean conflict. During World War II, at least 1.2 million man-days of duty may have been lost to this disease. Unfortunately, no reliable statistics are available to reflect the numbers or types of extraintestinal amebiasis cases. Cutaneous amebic disease was rarely seen in the Vietnam conflict.<sup>55</sup>

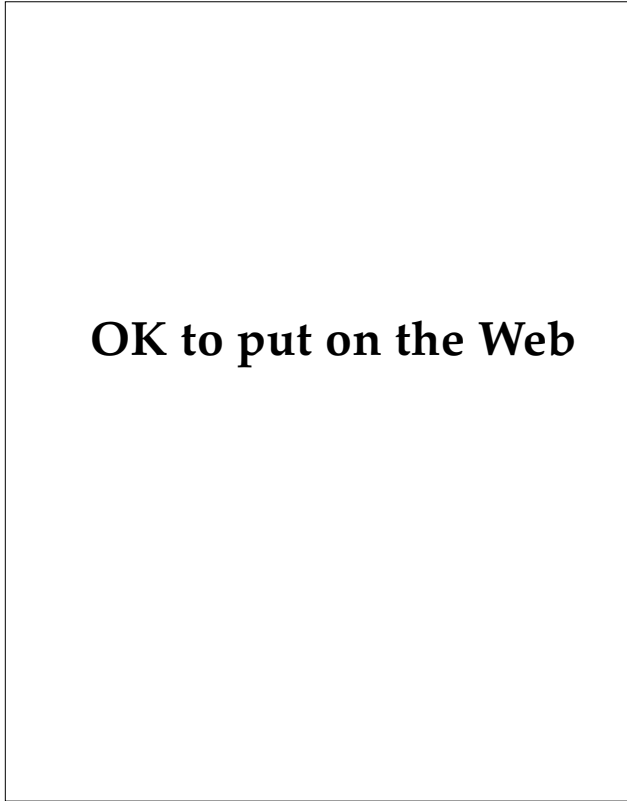
Although the organism has been identified in insects and other animals, humans are considered to be the reservoir of disease.<sup>53,56</sup> Infection is acquired when cysts from fecally contaminated sources (usually food or water) are ingested.<sup>40,53,56-58</sup> Cysts may survive for months in a warm, moist environment outside the host; further, they are resistant to chlorine concentrations that are usually used for water purification.<sup>56</sup> The spherical cysts (5–25 µm in diameter) have a thick wall that provides protection in the acidic gastric milieu. When they reach small intestine, excystation and division occur; each quadrinucleate cyst produces eight trophozoites that vary in size from 15 to 60 µm. Trophozoites are carried to the large intestine where various hosts or amebic factors (discussed below) determine whether tissue invasion or simple colonization of the bowel by trophozoites will occur. The cycle is established

when trophozoites divide and form quadrinucleate cysts that are then passed in the stool. In patients who are experiencing diarrhea, trophozoites may be passed prior to becoming encysted.

### Intestinal and Extraintestinal Manifestations

Symptomatic amebiasis is produced when the host's tissues are invaded. Bacterial flora in the gut, nutritional status, and cellular immune responses may be important host parameters; while amebic strains, adhesins, cytotoxins, and contact-dependent cytotoxicity are considered to be the parasitic determinants of tissue damage.<sup>58,59</sup>

Asymptomatic infections—detected only by the presence of cysts in screening examinations—account for most human infection. Acute disease may develop suddenly 1 to 3 weeks after the cysts are ingested. Abdominal cramps, fever, chills, headaches, tenesmus, and diarrheal stools with



OK to put on the Web

**Fig. 12-20.** Cutaneous amebiasis of the anterior portion of the external genitalia in a female child. Photograph: Courtesy of Jorge Molina, M.D., Honduras, Central America.



bloody mucus and fewer leukocytes than are characteristic of bacterial dysentery may develop. Nondysenteric intestinal disease may be characterized by intermittent constipation, watery or mushy stools, flatulence, abdominal cramps, fatigue, and weight loss. Extraintestinal disease, most often in the form of liver abscesses, can develop in patients who might not have manifested intestinal symptoms.<sup>56</sup>

### *Cutaneous Manifestation*

Cutaneous lesions of amebiasis seem to be extremely rare and are reported in literature as isolated cases.<sup>60-62</sup> A review of 5,000 South African cases found only two patients with cutaneous disease.<sup>63</sup> Proposed mechanisms of cutaneous involvement include direct extension of intestinal disease onto the skin, extension of liver abscess to the skin, direct inoculation during anal intercourse, and, in young children, trophozoites retained in direct contact with the skin under diapers.<sup>57,62</sup> Hematogenous and lymphatic spread is controversial. Patients with lesions, which are most commonly located in the anogenital region, present with painful ulcerations that may enlarge rapidly (Figure 12-20). The border may be red or violaceous, and the edges may be verrucous or undermined. The base can have granulation tissue and may have a purulent exudate. The differential diagnosis includes syphilis, granuloma inguinale, leishmania, deep fungal infections, tuberculosis, condyloma, inflammatory bowel disease, pyoderma gangrenosum, pemphigus vegetans, and carcinoma.

### *Diagnosis*

The diagnosis of cutaneous disease is established by finding trophozoites in scrapings or biopsy of the skin lesion. The presence of phagocytized erythrocytes or the use of special stains may be helpful in distinguishing trophozoites from histiocytes in tissue sections.<sup>57</sup> Thus, cutaneous amebiasis may be more amenable to direct diagnosis than intestinal or liver amebiasis, with their attendant difficulties of demonstrating the trophozoites or cysts. Indirect hemagglutination, immunofluorescence, and ELISAs are usually positive in patients with amebiasis, but these tests are variably sensitive in detecting asymptomatic carriers.<sup>64</sup>

### *Therapy*

A variety of drugs are available to treat amebiasis of intestinal and extraintestinal sites.<sup>32</sup> Cutaneous disease seems to respond well to metronidazole; but emetine, dihydroemetine, and hydroxyquinolone have also been reported successful.<sup>61,62</sup> Because metronidazole is well absorbed, iodoquinol or paromomycin, which achieve higher luminal concentrations, should be used to eradicate noninvasive amebae in the intestine.<sup>32,56</sup> The doses are, for metronidazole, 750 mg administered three times daily for 10 days; for iodoquinol, 650 mg administered three times daily for 20 days (not to exceed 2 g/d and not to exceed 20 d); and for paromomycin, 25 to 30 mg/kg/d, divided and administered in three doses for 7 days. The pediatric dosage is discussed elsewhere.<sup>32</sup>

## HELMINTHIC INFECTIONS

*Helminth* is derived from the Greek word *helmins*, meaning worm. For practical medical purposes, the helminths are categorized as annelids (ie, phylum Annelida, the segmented worms), nematodes (ie, phylum Nematoda, the roundworms), and platyhelminths (ie, phylum Platyhelminthes, the flatworms). The platyhelminths are further subdivided into trematodes (ie, flukes) and cestodes (ie, tapeworms) (Exhibit 12-1). While almost any worm infestation may elicit nonspecific cutaneous findings (eg, urticaria) or laboratory abnormalities (eg, eosinophilia), only the characteristic findings that would suggest skin penetration are emphasized. Thus, this discussion focuses on nematodes and trematodes; cestodes are not discussed.

Although sanitary and combat conditions amenable to the acquisition of helminthic infections existed in many of the theaters of operations in World War II, it was from the Pacific that infections were reported in significant numbers.<sup>4,65-67</sup> Prevalence surveys revealed that 10% to 40% of U.S. troops had human hookworm infection, perhaps in excess of 10,000 had filariasis, and more than 1,300 had schistosomiasis.<sup>65-67</sup> Strongyloidiasis was diagnosed in groups of U.S. military personnel who had been prisoners of war and who had worked on the Burma-Thailand Railroad during World War II.<sup>68</sup> Outbreaks of human hookworm disease were documented in the Vietnam conflict, and in one small study of 75 returning servicemen, the prevalence of human hook-

**EXHIBIT 12-1**

**HELMINTHS THAT PRODUCE CUTANEOUS DISEASE**

- 
- Nematodes (phylum Nematoda: Roundworms)
    - Hookworms
      - Human
      - Animal
      - Strongyloides stercoralis*
    - Filaria
    - Dracuncula
    - Trichinella
  - Platyhelminths (phylum Platyhelminthes: Flatworms)
    - Trematodes (flukes)
      - Schistosomes
    - Cestodes (tapeworms)

worm disease or strongyloidiasis or both ranged from 15% to 55%.<sup>56</sup> Although filariasis was endemic, few cases were ever documented among U.S. troops.<sup>55</sup> Finally, an outbreak of human hookworm disease involving over 200 soldiers who participated in military operations in Grenada has been reported.<sup>69</sup>

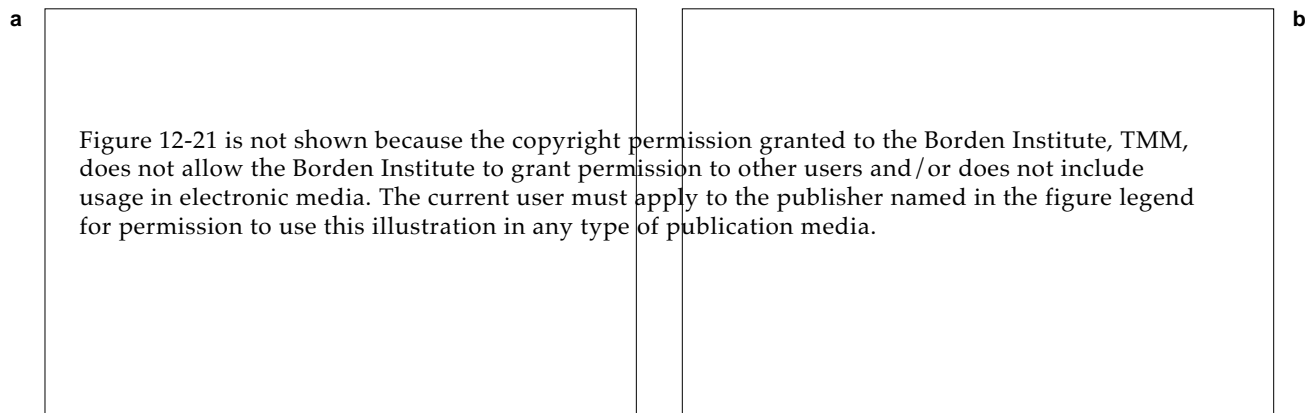
**Human Hookworm Disease**

Human hookworm disease is caused by the roundworms *Ancylostoma duodenale* and *Necator americanus*, both of which are found worldwide. The life cycle begins when female worms, residing in the host's small intestine, release eggs that are passed in the feces.<sup>70,71</sup> When the management of

human waste is poor and the proper conditions of shade, sandy soil, warm temperature, and relatively high humidity prevail, the eggs hatch in the soil. Larvae emerge, develop through a series of stages, and become infective filariform larvae. On contact with human skin (eg, bare feet), the larvae penetrate the skin, pass into the venous circulation, and are carried to the lung where they rupture into the alveoli. Then moving up the victim's respiratory tree to the pharynx, the larvae are swallowed and come to rest in the host's gut, where the larvae mature without invading tissue. Adult females tend to be larger than males and may be 9 to 13 mm in length; adult worms may live 6 years or longer. Hookworm eggs begin to appear in human feces within approximately 2 months after the skin was penetrated.<sup>71</sup>

**Cutaneous Manifestations**

Manifestations of human hookworm infection may occur (a) coincident with larval migration to other tissues or (b) as a result of chronic parasitic infection of the bowel. Cutaneous disease develops when penetration of the skin occurs and is frequently described as "ground itch." Most often, disease develops among people who go into contaminated areas without wearing shoes; however, contaminated soil may come in contact with the skin by passing through the vents or eyelets in boots or through holes in torn uniforms, or by being flung about by troops actively engaged in digging.<sup>55</sup> Experimental studies showed that a first exposure to the larvae of *N americanus* produces erythematous patches 24 hours later at the site of penetration (Figure 12-21).<sup>72</sup> By 48 hours after penetration,



**Fig. 12-21.** (a) Erythematous patches apparent 24 hours after larvae of *Necator americanus* have penetrated the skin of a volunteer. (b) Punctate, petechial papules that developed 48 hours after larvae of *Necator americanus* penetrated the skin of a volunteer. Photographs reprinted by permission of Cline BL. *Am. J. Trop. Med. Hyg.* 1984;33:390.

discrete, punctate, erythematous papules are frequently present. Pruritus is common. If rechallenged with larvae several weeks after the initial exposure, the host develops pruritic, erythematous, edematous, linear, threadlike tracts marking larval migration in the skin (Figure 12-22). This burrow is referred to as cutaneous larva migrans (also called creeping eruption), a finding also noted in other parasitic helminthic infections (Table 12-2). The tract progresses for approximately 1 week. With long intervals between recurrent exposure, the intensity of the cutaneous reaction wanes.<sup>73</sup>

### ***Pulmonary and Gastrointestinal Manifestations***

Pulmonary symptoms attributed to larval migration through the lung include cough and wheezing, and radiography may show associated pulmonary infiltrates. Gastrointestinal symptoms include abdominal pain, flatulence, nausea, vomiting, and diarrhea. Iron deficiency anemia is a characteristic finding, although it is dependent on the species, total worm burden, duration of infection, and nutri-

**OK to put on the Web**

**Fig. 12-22.** These threadlike, meandering burrows are caused by *Necator americanus*. Known as cutaneous larva migrans, this lesion is typical in patients who are immunologically sensitized to the organism. Photograph: Courtesy of Paul C. Beaver, PhD, Tulane University, New Orleans, La.

**TABLE 12-2**

### **PARASITES THAT PRODUCE A CUTANEOUS LARVA MIGRANS-LIKE ERUPTION**

Table 12-2 is not shown because the copyright permission granted to the Borden Institute, TMM, does not allow the Borden Institute to grant permission to other users and/or does not include usage in electronic media. The current user must apply to the publisher named in the figure legend for permission to use this illustration in any type of publication media.

tional status of the host. Eosinophilia may also be present.<sup>69,71,74</sup>

### Diagnosis and Treatment

Diagnosis of human hookworm disease is made by finding hookworm ova in stool specimens. The current recommended treatment regimen for adults and pediatric patients is 100 mg of mebendazole administered orally twice daily for 3 days. A single, 400-mg dose of albendazole is an alternative.<sup>32</sup>

### Animal Hookworm

Worldwide, *Ancylostoma braziliense*, the dog or cat hookworm, is the most common cause of cutaneous larva migrans (see Table 12-2 and Figure 12-23).<sup>75</sup> Eggs passed in the feces of infected dogs or cats hatch in the soil and develop into infective filariform larvae. After they penetrate human skin, these larvae lack the ability to invade further and complete their life cycle. Thus, they meander erratically through the epidermis producing raised, threadlike, serpiginous, pruritic, erythematous tracks that extend a few centimeters a day. Attempts to demonstrate the worm by biopsy are usually futile because the cutaneous change

develops after the larva's passage. Because the human is a "dead-end" host, the parasite usually dies. However, one study has shown that if untreated, 64% of patients continued to have lesions after 4 weeks, although the total number of lesions was markedly decreased.<sup>76</sup> Pulmonary and gastrointestinal symptoms do not develop because systemic invasion of and infection with these parasites do not occur.

The cutaneous lesions of dog or cat hookworm may be treated topically with 10% thiabendazole suspension four times daily for 7 days, or until 1 or 2 days after the last tracks have resolved, is effective.<sup>77,78</sup> Thiabendazole (50 mg/kg/d, divided and administered in two doses, maximum 3 g/d, for 2–5 d) may be used if oral treatment is elected. Toxicity may require dose reduction.<sup>32</sup>

### Strongyloidiasis

After penetrating the skin, *Strongyloides stercoralis* (commonly known as threadworm) takes a migratory pathway virtually identical to that of the human hookworm. Eggs generally hatch in the bowel mucosa, and thus the larval form rather than eggs are found most often in the feces. However, once the mature female worm (approximately 1 mm in

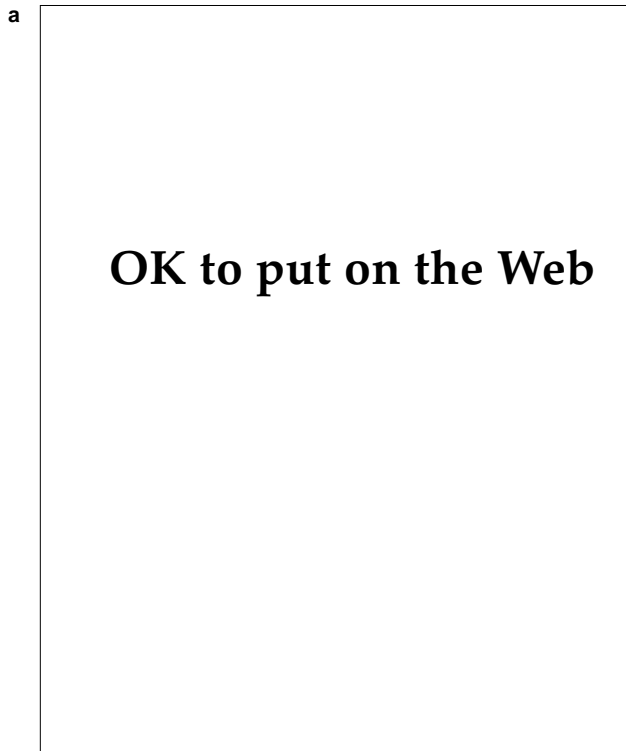
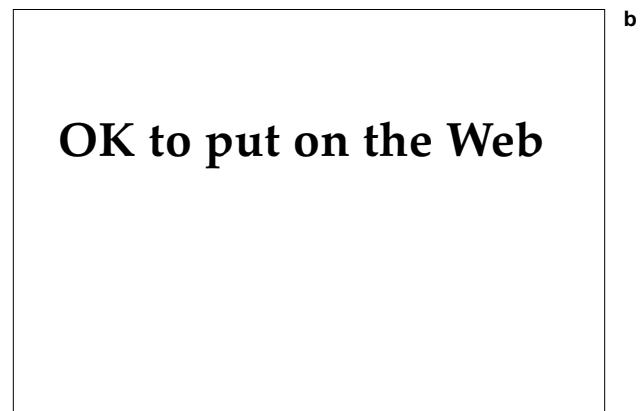


Fig. 12-23. (a) Thread-like serpiginous, meandering burrow of cutaneous larva migrans. (b) Multiple serpiginous burrows of cutaneous larva migrans of the back of a patient. Photograph b: Courtesy of Jorge Molina, M.D., Honduras, Central America.



size) starts producing eggs, propagation takes one of three forms<sup>79</sup>:

1. Passed in the feces, the larvae develop to an infectious stage, which finds another human host to penetrate.
2. Alternatively, under ideal climatic conditions, the larvae may develop into adults in the soil and thus propagate outside the host.
3. Finally, in the autoinfection cycle, the infectious larvae develop in the bowel of an infected host. Instead of passing in the feces, these infectious larvae penetrate the bowel mucosa or perianal skin and migrate back to the lung to resume the migratory cycle and perpetuate the infection in the same host.

Just as with human hookworm, the three phases of clinical manifestations of strongyloidiasis, which correspond to the migratory pathway, are the cutaneous, pulmonary, and gastrointestinal.<sup>71,79</sup>

#### *Cutaneous Manifestations*

Penetration of the skin and tissue migration are associated with parasitic secretion of a metalloprotease, which degrades the elastin and the dermal extracellular matrix.<sup>80</sup> Most often seen in the autoinfection cycle, the distinctive cutaneous eruption is that of a migratory linear or serpiginous, pruritic, erythematous, urticarial band (Figure 12-24), which may move as much as 10 cm or more per day. Because of its rapid

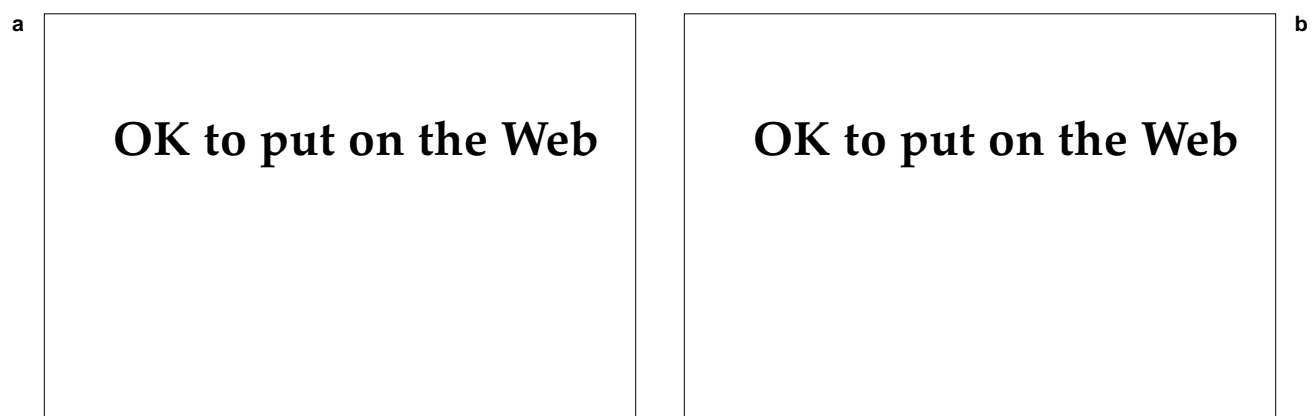
movement, this eruption is often referred to as larva currens.

#### *Pulmonary, Gastrointestinal, and Hematological Manifestations*

Pulmonary symptoms or findings may include cough, hemoptysis, shortness of breath, wheezing, and transient pulmonary infiltrates. Gastrointestinal symptoms include abdominal pain, vomiting, bloating, and diarrhea. Weight loss and eosinophilia are common findings. Of particular significance is the fact that up to 40 years later the infection may persist.<sup>68,81–85</sup> Persistent infection, when combined with suppression of the immune system, may result in an overwhelming, potentially fatal, infection associated with multiorgan larval invasion and bacteremia.<sup>86–88</sup> In these patients, the multiple linear burrows of strongyloides may have a hemorrhagic or petechial component.<sup>89</sup>

#### *Diagnosis and Treatment*

The cutaneous eruption is diagnostic of strongyloidiasis, and in its absence the diagnosis can be quite difficult. Finding larvae or, rarely, eggs in feces is a tedious and time-consuming task. Serologic tests by means of ELISA or indirect immunofluorescence may be helpful.<sup>90,91</sup> Treatment for both children and adults is with thiabendazole 50 mg/kg/d, divided and administered in two doses (maximum 3 g/d) for 2 days. Patients with disseminated strongyloidiasis may require a 5-day course of therapy; treatment of patients who are immunocompromised may require further modification.<sup>32</sup>



**Fig. 12-24.** (a) A serpiginous, urticarial track of *Strongyloides stercoralis*. (b) In the same patient, the eruption that was present on initial examination at 1130 hours was traced using a surgical marking pen. The unmarked portion shows how far the burrow had progressed in only 30 minutes (ie, by 1200 hours on the same day).

## Filariasis

Eight species of roundworm belonging to the family Filarioidea (hence the name filariasis) develop to adulthood in humans; of them, six are generally accepted as being pathogenic (Table 12-3).<sup>92</sup> The life cycles of the filariae are similar.<sup>92,93</sup> Microfilarial larvae in the blood of the human host are ingested when the insect vectors feed on infected humans. Within the vector, the microfilariae migrate to specific sites and develop from first-stage larvae into infective third-stage larvae. Then, when feeding, the vector transmits the infective larvae into a human, where the organism molts twice more to become an adult worm. The adult worm may be found in the lymphatic vessels, lymph nodes, or subcutaneous tissue.

The following observations have been made regarding the host–parasite interaction<sup>94</sup>:

- In endemic areas, a large percentage of the populace may have microfilaremia but little detectable disease.
- Individuals immigrating to areas of endemicity may experience symptoms due to infection with adult worms and yet not have demonstrable microfilaremia.
- Symptoms may vary markedly among those who develop overt infection.

It is the interplay of humoral and cellular immune responses that determines the manifestation of disease.<sup>95</sup> Most individuals in endemic areas seem to develop a humoral antifilarial IgE response. Effector immunological responses (eg, lymphocyte proliferative response, gamma interferon generation, or IgE and IgG production) to microfilariae seem to be specifically and actively suppressed in those patients without clinical disease. In endemic areas, the effector responses are enhanced in a small percentage of individuals, who develop the clinical manifestations of the disease. Tolerance to parasitic infection (ie, there is no overt clinical disease) may be prenatally determined by exposure to filarial antigens. The mechanisms that cause a shift from tolerance (with suppression of specific immune responses) to responsiveness (with expression of effector immune responses) are unknown. Individuals from nonendemic areas develop characteristic inflammatory responses typical of the diseases by virtue of intact effector immune responses when they move into endemic areas. Thus, the vast majority of these individuals are without detectable microfilaremia.<sup>66</sup>

TABLE 12-3

### FILARIAE OF MEDICAL SIGNIFICANCE

Organism	Vector
<i>Wuchereria bancrofti</i>	Mosquito
<i>Brugia malayi</i>	Mosquito
<i>Brugia timori</i>	Mosquito
<i>Loa loa</i>	Deerfly ( <i>Chrysops</i> )
<i>Onchocerca volvulus</i>	Blackfly ( <i>Simulium</i> )
<i>Mansonella streptocerca</i>	Midge ( <i>Culicoides</i> )

#### Bancroftian Filariasis

Bancroftian filariasis is due to filarial infection with *Wuchereria bancrofti*, which is found focally in tropical and subtropical regions throughout the world: sub-Saharan Africa, Asia, the South Pacific and western areas of the Pacific, the Caribbean region, the eastern coastal plains of South America, and portions of Central America.<sup>96–98</sup> The adult worms are found in the patient's lymphatic vessels and nodes and may produce microfilariae over a 2- to 4-year period. Female worms measure approximately 100 mm x 0.3 mm; males are about one half that size. Microfilariae generally are absent from the bloodstream during the day and are found in greatest numbers during the 4-hour period before and after midnight (ie, nocturnal periodicity)—corresponding to the feeding habits of the mosquito. In contrast is the diurnal periodicity seen in the South Pacific—a phenomenon that is an adaptation to the day-feeding habits of the local mosquitoes. The vectors of disease are mosquito species of the genera *Anopheles*, *Culex*, and *Aedes*. Marked variation exists with regard to efficiency of transmission: in Rangoon, Burma (now known as Yangon, Myanmar), 16,000 bites of infected mosquitoes produced but one overt case of Bancroftian filariasis; whereas in rural Tanzania, 200 bites per person per year maintained infection within the population.<sup>96</sup>

**Clinical Manifestations.** In individuals from nonendemic areas, manifestations of Bancroftian filariasis begin within 5 to 18 months of being bitten and are localized to the genitalia (42%), arms (25%), and legs (11%).<sup>96</sup> Genital disease includes edema of scrotal skin, funiculitis, epididymitis, orchitis, and hydrocele. A distinctive lymphangitis of the arms or legs develops in many patients and is characterized by a unique retrograde spread or extension.

Starting in a single node, erythematous patches of subcutaneous edema, or diffuse erythema and edema, develop and progress distally. Although the nodes and lymphangitis are tender, pain is not significant. Constitutional signs and symptoms may vary from no symptoms at all to headache, backache, fatigue, and, in some cases, fever, chills, and malaise.<sup>96,98,99</sup> The onset of genital and adenolymphangitis is often acute, lasts a few days, and is recurrent. Increased heat, physical activity, and fatigue seem to precipitate relapses.

The inflammatory histological response to the adult and, more importantly, dead or dying filariae may result in the clinical manifestations of filariasis.<sup>96</sup> Yet, in a small study that spanned 16 years after World War II, while the percentages of infected servicemen who experienced recurring attacks of disease increased, none developed elephantiasis or chronic disabling disease.<sup>100</sup> This favorable outcome was attributed to rapid evacuation of servicemen with acute filariasis. For it is repeated, acute attacks from repeated infection that are thought to

produce lymphatic scarring severe enough to obstruct the lymphatics, producing elephantiasis (Figure 12-25).

**Diagnosis.** Diagnosis of Bancroftian filariasis is made by associating signs and symptoms with a history of travel to endemic areas. Eosinophilia may be present in acute disease. Identification of microfilariae (among residents in endemic areas in whom this is typical) in peripheral blood smears is the best means to establish the diagnosis. Immunodiagnostic assays to detect infection are being actively pursued with deoxyribonucleic acid (DNA) probes showing great promise; ELISAs are available in some laboratories.<sup>95,96</sup>

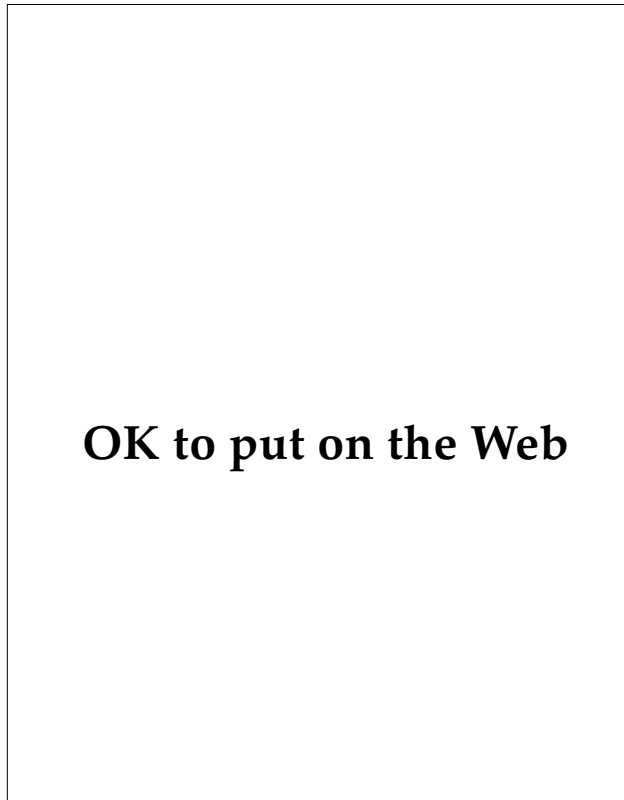
**Treatment.** Diethylcarbamazine, which has been the standard of treatment for years, kills microfilariae and is toxic to adult worms when administered in the following adult doses<sup>32,96</sup>:

- Day 1: 50 mg, administered orally after a meal
- Day 2: 50 mg, administered orally three times per day
- Day 3: 100 mg, administered orally three times per day
- Days 4 through 21: 6 mg/kg/d, administered orally in three doses

However, in a study of asymptomatic patients with microfilaremia, ivermectin in single doses seems to be effective in long-term suppression of microfilaremia.<sup>101,102</sup> Ivermectin's effect on the adult parasite is unknown. Nevertheless, eradicating the microfilariae is the key to stopping vector-borne transmission.

#### **Malayan Filariasis and Timorian Filariasis**

Malayan filariasis and Timorian filariasis are due to *Brugia malayi* and *Brugia timori*, respectively, and are more limited in their geographical distribution than is Bancroftian filariasis.<sup>96</sup> Both diseases are found in or near Indonesia; *B malayi* is found in Malaysia and the Philippines as well. Humans still serve as the primary reservoir hosts; however, animals may also serve as reservoirs for *B malayi*. In both diseases, axillary or inguinal lymphadenitis, lymphangitis, and fever are common. Lymphatic abscesses and resultant scarring are common. In areas where Malayan filariasis is endemic, elephantiasis is uncommon; when it does occur, it tends to involve the distal portions of the extremity. Lymphedema of the leg frequently progresses to elephantiasis in Timorian disease.



**Fig. 12-25.** This patient's unilateral elephantiasis is caused by filariasis. Photograph: Courtesy of Armed Forces Institute of Pathology. Negative 78873.

OK to put on the Web

**Fig. 12-26.** Microfilaria of *Loa loa*. Photograph: Courtesy of Armed Forces Institute of Pathology. Negative 75-6618.

### Loiasis

Loiasis is caused by infection with *Loa loa* and is found in the rain forests of central and West Africa.<sup>103</sup> The adult female worm measures 50 to 70 mm x 0.55 mm; the male is approximately one half the size. Both can be found in the subcutaneous tissue of the skin. In patients with microfilaremia, microfilariae are found in the bloodstream in highest numbers during the day, thus showing what is termed diurnal periodicity (Figure 12-26). Deerflies, large flies of the genus *Chrysops*, are the vectors of disease (Figure 12-27). The flies live under the rain forest canopy near streams and are attracted by the movement of people or vehicles below.

OK to put on the Web

**Fig. 12-27.** A deerfly of the genus *Chrysops*—the usual vector of *Loa loa*. Photograph: Courtesy of Armed Forces Institute of Pathology. Negative 72-4516.

**Clinical Manifestations.** A study of 20 individuals from nonendemic areas who visited an endemic area found that generalized or localized pruritus (75%); transient, nontender areas of angioedema (70%); and urticaria (55%) were the major signs and symptoms.<sup>104</sup> Ocular involvement, manifested as a worm migrating subconjunctivally, was noted in only one patient (Figure 12-28). Five of the 20 patients were asymptomatic and their disease was detected only by virtue of eosinophilia. Laboratory abnormalities include marked eosinophilia, elevated IgE, and hematuria.

The transient sites of angioedema, known as Calabar swellings, are thought to represent allergic reactions to antigenic substances that are produced by the migrating adult worm.<sup>103,104</sup> These swellings persist for hours to days and 1 to 150 days can elapse between recurrences. Of the 14 patients with Calabar swellings, 8 had more than six episodes in the 11-month (on average) interval between the onset of symptoms and treatment.<sup>104</sup>

**Diagnosis.** Definitive diagnosis is made by recovering a worm, either one migrating under the conjunctiva or one from a subcutaneous nodule. In natives of endemic areas, diagnosis may be made by identifying microfilariae in the blood. Otherwise, clinical symptoms and findings, laboratory findings, and response to treatment are the means of diagnosis.<sup>103,104</sup>

**Treatment.** Treatment is with diethylcarbamazine in the following adult doses<sup>32</sup>:

- Day 1: 50 mg administered orally after a meal
- Day 2: 50 mg administered orally three times per day

OK to put on the Web

**Fig. 12-28.** An adult *Loa loa* being removed from a patient's eye. Photograph: Courtesy of Armed Forces Institute of Pathology. Negative 75-1789-4.



- Day 3: 100 mg administered orally three times per day
- Days 4 through 21: 9 mg/kg/d administered orally in three doses

However, in patients with marked microfilaremia, corticosteroid treatment (or even plasmapheresis) may be necessary to prevent iatrogenic meningoencephalitis, which may occur even when very low initial doses (ie, 10 mg) are used.<sup>105</sup> The appearance of subcutaneous nodules containing the worm and hematuria may be associated with treatment, as well.<sup>105</sup>

### Onchocerciasis

Onchocerciasis develops in response to infection with *Onchocerca volvulus*. In 1985, it was estimated that 86 million people lived in endemic areas and of these, 17.8 million were infected.<sup>106</sup> More than 99% of infected individuals live in tropical Africa; the remainder are found in Yemen, Mexico, and countries in Central America and South America. Adult worms are often found encapsulated within fibrous nodules in the dermis and subcutaneous tissues near the bony prominences (Figure 12-29). Female worms, measuring 20 to 50 cm in length and 0.45 to 0.5 mm in width, may live up to 15 years, producing 1 million or more microfilariae per year. Microfilariae, which may live 6 months to 2 years, concentrate in the dermis, eyes, and regional lymph nodes (Figure 12-30).<sup>106,107</sup> In addition to the nodules formed in response to the adult worm, the disease manifestations are determined by the inflammatory response elicited by the migration or degenera-

OK to put on the Web

**Fig. 12-30.** A biopsy from a patient infected with *Onchocerca volvulus*. Numerous microfilariae (arrow) can be seen in the dermis. Photograph: Courtesy of Armed Forces Institute of Pathology. Negative 73-5681.

tion of microfilariae.<sup>108</sup> Furthermore, there are differences in the clinical presentations of the disease in different geographical locales.<sup>107</sup> Blackflies of the genus *Simulium* are the vectors of disease (Figure 12-31).<sup>108</sup> Because the flies favor habitats along rapidly moving streams or rivers, the disease tends to be focally distributed.

**Clinical Manifestations.** Dermatitis is one of the first signs of onchocerciasis.<sup>106-109</sup> In the typical African patient who is developing an immunological response to microfilariae, a symmetrical, pruritic, papular dermatitis of the lower trunk and extremities develops.<sup>107,109</sup> Chronic dermatitis secondary to the response to a heavy microfilarial load is associated with scaling, hypopigmentation (leop-

OK to put on the Web

**Fig. 12-29.** Coiled worms can be seen in this fibrous nodule of onchocerciasis. Photograph: Courtesy of Armed Forces Institute of Pathology. Negative 69-3639.

OK to put on the Web

**Fig. 12-31.** A specimen of *Simulium damnosum*, the blackfly vector of onchocerciasis in Africa. Photograph: Courtesy of Armed Forces Institute of Pathology. Negative 72-4519-E.

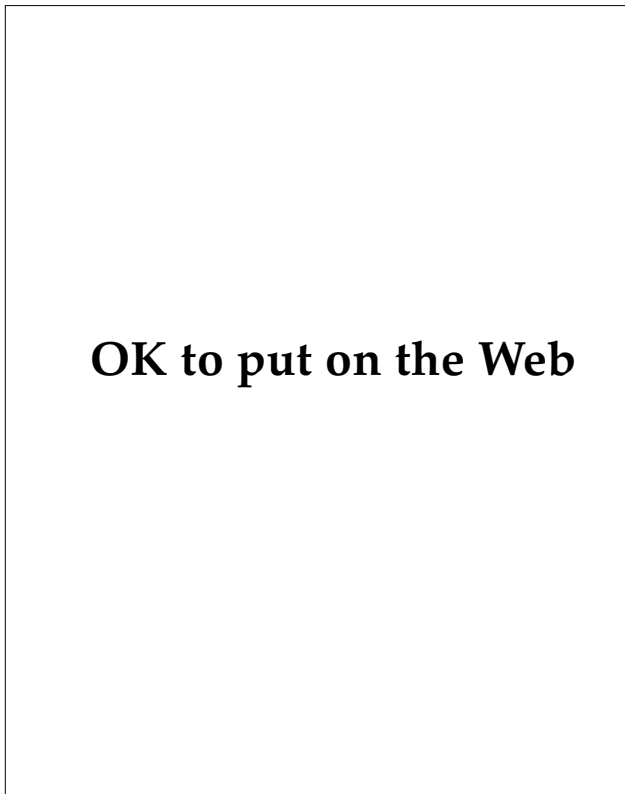
ard skin), edema, and lichenification (elephant skin), ultimately followed by the appearance of atrophy (lizard skin) (Figure 12-32).<sup>106,107,109</sup> In Yemen, infected patients who mount a brisk immune response (with concomitant marked decrease or absence of microfilaremia) develop *sowda*: edema, hyperpigmentation, a pruritic papular eruption, and adenopathy; the condition is generally confined to one anatomical quarter or one limb.<sup>109</sup> In travelers who immigrate to endemic areas, *sowda* is the disease manifestation that commonly develops.<sup>106</sup> Early in the course of onchocerciasis, the differential diagnosis includes contact dermatitis, scabies, and miliaria; later manifestations of chronic disease might suggest vitiligo, pinta, yaws, streptocerciasis, or leprosy.

Dermal and subcutaneous fibrotic nodules enclose adult worms and tend to be located over bony prominences in the skin.<sup>107</sup> In Africa, these are found around the pelvis and lower extremities, whereas in Guatemala and Mexico, the head and

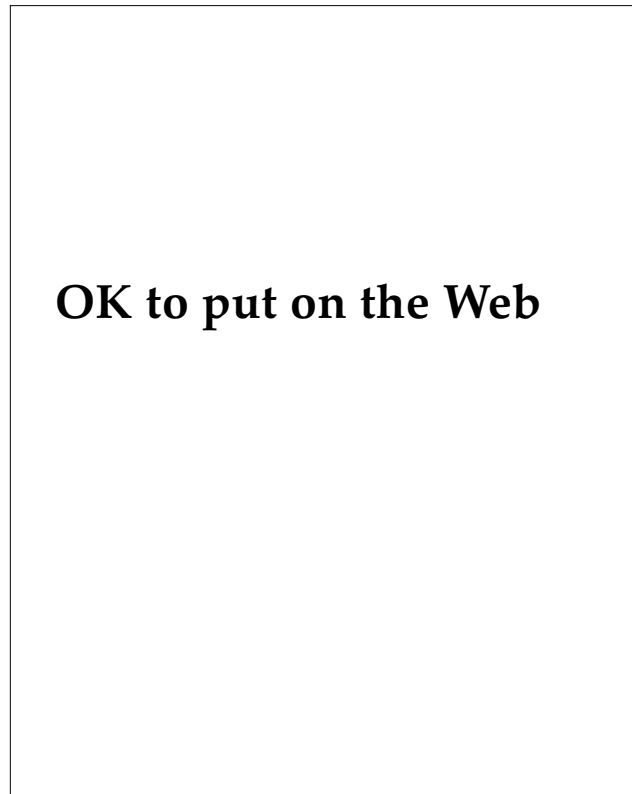
upper part of the body are the more common sites (Figure 12-33). Microfilariae may accumulate in nodes that drain the areas of dermatitis. In some African patients, the inflammation and subsequent fibrosis and atrophy may cause lymph nodes or portions of bowel to hang in pockets of skin—the “hanging groin” of onchocerciasis (Figure 12-34).<sup>106,107,110</sup>

In heavily infected endemic areas, up to 15% of the community may be blind as the result of the inflammatory reaction to onchocercal microfilariae in the eye.<sup>107</sup> Patients who are acutely ill with onchocerciasis may have corneal opacities, while individuals who are chronically heavily infected may develop sclerosing keratitis, uveitis, and chorioretinitis.

**Diagnosis.** The diagnosis is usually established by obtaining bloodless skin snips taken over bony prominences or at sites of clinical manifestations.<sup>107</sup> Several hours after the specimens have been placed in saline or culture media, microscopical examina-



**Fig. 12-32.** The depigmentation found in chronic onchocerciasis. Note also the onchocercal nodule at the patient’s left knee. Photograph: Courtesy of Armed Forces Institute of Pathology. Negative 72-17223.



**Fig. 12-33.** Onchocercal nodules on the scalp of a child from Central America. Photograph: Courtesy of Captain Kenneth F. Wagner, Medical Corps, U.S. Navy (ret), Bethesda, Md.

## OK to put on the Web

**Fig. 12-34.** These bilateral inguinal and femoral adenolymphoceles are the “hanging groins” of onchocerciasis. Photograph: Courtesy of Armed Forces Institute of Pathology. Negative 73-6655.

tion of the fluid will reveal microfilariae. Biopsy of a nodule will reveal an adult worm. Slitlamp examination of the eye may reveal microfilariae. Eosinophilia is a characteristic, nonspecific finding. Serologic testing is hampered by false-positive cross-reactions with other helminths; however, more specific tests are being developed.

**Treatment.** Ivermectin 150 µg/kg administered orally once every 6 to 12 months is the treatment of choice for onchocerciasis.<sup>32</sup> Ivermectin is a well-tolerated drug that is toxic to microfilariae. Because it has no effect on the adult worms, it is given at regular intervals to destroy or stop the release of microfilariae.<sup>32,106,107</sup> Ivermectin is not used to treat disease in children under 5 years of age, pregnant or lactating women, or patients who are otherwise ill. In the past, diethylcarbamazine was employed in the treatment, but such treatment was fraught with problems.<sup>107</sup> When given to acutely ill patients, it caused a flare of the cutaneous symptoms; in heavily infected individuals, it caused severe constitutional symptoms, including marked worsening of the eye lesion. Administering doses small enough to elicit a mild exacerbation of symptoms was the basis of a potentially dangerous, indirect method of diagnosis known as the Mazzotti test, which has fallen into disfavor.

### *Streptocerciasis*

The filarial disease streptocerciasis is caused by infection with *Mansonella streptocerca*. The disease is found in central and West Africa and is transmit-

ted by the midge *Culicoides grahmi*. Adult worms are found in the dermis of the patient’s upper trunk. The microfilariae are found in the dermis and lymph nodes but have not been found in the eye. Pruritus, hypopigmented macules, axillary or inguinal adenopathy, and occasionally a few papules comprise the cutaneous manifestations. Diethylcarbamazine kills both the adult worm and microfilariae and prompts an exacerbation of cutaneous symptoms analogous to a Mazzotti reaction.<sup>111</sup>

### *Dracunculiasis*

Dracunculiasis, also called Guinea worm or Medina worm, is caused by the nematode *Dracunculus medinensis* and is found focally in Africa, India, and Pakistan.<sup>112,113</sup> Of the 160 million people at risk, 10 to 15 million may be infected annually.<sup>113</sup> The cycle of human infection begins when the female worm discharges larvae into fresh-water sources. Copepods (microcrustaceans approximately 1–3 mm in length) of the genus *Cyclops* ingest the larvae, becoming the intermediate host. Copepods are found in bodies of standing (rather than flowing) water. Within this intermediate host, the larval parasite develops into an infective larva; humans become infected when they drink water containing the infected copepods. In the gastric milieu, the larva is freed from the copepod and proceeds to penetrate the human host’s small intestine to reach the peritoneum, where it matures. The worm (measuring 70–120 cm x 0.17 cm) migrates to the skin where, when the human host is in contact with water, it ruptures through the skin to release the larvae into fresh water. The cycle from ingestion of filariae to release of filariae takes approximately 8 to 12 months.

**Clinical Manifestations.** Signs and symptoms of dracunculiasis are generally associated with the presence of the adult worm in the subcutaneous tissue.<sup>112–114</sup> In general, the site of eruption is on the lower extremity and is signified by the presence of a painful, erythematous nodule up to 7 cm in diameter, a pruritic blister, or both. At about the same time, constitutional symptoms such as urticaria, nausea, vomiting, diarrhea, syncope, and fever may occur. Eosinophilia is common and may be marked. Worms that migrate to aberrant locations (other than to the skin of a lower extremity) die and form abscesses that may resolve with calcification.

**Diagnosis.** Diagnosis may be readily obvious if the worm is carefully examined as it emerges from the nodule or blister (Figure 12-35). Slowly extracting the worm by wrapping it around a small stick

## OK to put on the Web

**Fig. 12-35.** *Dracunculus medinensis* that has been removed from its resting site at the surface of the patient's skin. Photograph: Courtesy of Armed Forces Institute of Pathology. Negative 67-1563-3.

has been tried, but excision of the nodule may be a better removal technique because it is less likely to incite inflammation.<sup>112</sup>

**Treatment.** Treatment is with metronidazole (for adults: 250 mg administered three times daily for 10 days; the dosage for children is discussed elsewhere) or thiabendazole (adult and pediatric doses: 50 mg/kg/d, divided and administered in two doses for 3 d).<sup>32</sup>

Neither metronidazole, which is the drug of choice, nor thiabendazole kills either the worm or the larvae, but both drugs may be useful in reducing inflammation caused by the emerging worm.<sup>32,113</sup> Development of safe water supplies may be the best method of eradicating the disease. Until water supplies are safe, water suspected of being contaminated should be avoided, and infected individuals should stay physically removed from the water supply source.

### Trichinosis

Trichinosis develops when humans ingest inadequately cooked meat containing *Trichinella spiralis*.<sup>115-117</sup> Although traditionally pork is cited as the source of infection, any meat-eating animal may harbor infective larval cysts. *T spiralis* in pork is killed if the meat is fully cooked for 4 minutes at 135°F; however, 170°F is recommended to provide a margin for error. Refrigeration is another means for killing cysts.<sup>115</sup>

The acidity and enzymatic activity of the human digestive system disrupt the cyst and the larvae are

released. Attaching to the luminal wall, the larvae mature into adults, with the female measuring 3 to 4 mm in length x 60 µm in width and the male one half that size. Before the adults are expelled from the gut about 2 weeks later, they produce larvae that penetrate the gut and disseminate through the venous and lymphatic circulation. The larvae preferentially invade skeletal muscle and encyst, where they remain viable for years. The animal sources of human infection acquire the disease by feeding on the raw flesh of infected prey or carrion or on uncooked household meat scraps.

**Clinical Manifestations.** Signs and symptoms of infection develop 2 to 12 days following infection; the severity is influenced by the number of cysts ingested as well as the immunological response, which is determined by previous infection.<sup>116</sup> Most infections are asymptomatic. While adult worms inhabit the intestine, patients may experience diarrhea, constipation, abdominal pain, and anorexia or vomiting as a result of mucosal irritation.<sup>115-117</sup> The phase of muscle invasion is associated with myalgias, fever, and periorbital edema. Splinter hemorrhages, conjunctival hemorrhages, and maculopapular eruptions may also be found.<sup>116</sup> Severely infected patients may develop encephalitis, meningitis, myocarditis, bronchopneumonia, and nephritis.<sup>115,117</sup> Eosinophilia is a characteristic finding, although it may not occur during the first week of disease.

**Diagnosis.** The larvae may be found by incision biopsy of an infected muscle. However, serologic tests such as the bentonite flocculation test, the fluorescent antibody test, or the ELISA can detect the disease 2 to 3 weeks after the infection occurs.

**Treatment.** The disease is usually self-limited and requires no treatment. Corticosteroids have been used to reduce severe inflammation. Additionally, patients experiencing prolonged or severe illness, may be given mebendazole in the following adult dose: 200 to 400 mg three times daily for 3 days, then 400 to 500 mg three times daily for 10 days.<sup>32</sup>

### Schistosomiasis

The phylum Platyhelminthes contains the dorsoventrally flattened worms; of these parasites, blood flukes (schistosomes) belonging to the class Trematoda and genus *Schistosoma* are the most important producers of disease in humans. Schistosomiasis is the term generally reserved for disease produced in humans by the schistosomes *Schistosoma mansoni*, *S haematobium*, *S japonicum*, *S mekongi*, and *S intercalatum*.

Of the estimated 1 billion people worldwide at risk for schistosomiasis, 200 million living in 75 countries are thought to be infected.<sup>118</sup> *S mansoni* occurs throughout much of sub-Saharan Africa, portions of the Arabian peninsula, countries along the eastern coast of South America, and in the Caribbean. *S haematobium* is found in Africa and the Middle East, while *S japonicum* is restricted to China, Indonesia, and the Philippines.<sup>119,120</sup> Of these three, schistosomiasis produced by *S japonicum* is the most pathogenic, due to the greater number of eggs produced, and the most widespread. Two other species of limited geographical distribution also produce disease: *S mekongi* in Southeast Asia and *S intercalatum* in central Africa.<sup>120</sup>

During World War II, approximately 1,300 to 2,000 servicemen developed acute schistosomiasis in the Philippines.<sup>67,121</sup> Outbreaks of an acute systemic illness were reported from Vietnam; however, investigations suggested they were caused by schistosomes that typically do not parasitize humans.<sup>122</sup> Although no large-scale infections of schistosomiasis have been reported recently among U.S. military forces, outbreaks with high rates of infection among groups traveling in endemic areas emphasize the significant potential risk.<sup>123</sup>

The life cycle of the parasite begins with the production of eggs by an adult pair of flukes, which live in the venous plexus of the bladder or mesenteric plexus of the human host.<sup>118</sup> The species of schistosomes differ in their rate of egg production. The egg contains a *miracidium* (a larval form) that secretes enzymes that allow the egg to pass through the blood vessel and into the lumen of the bowel or bladder, from which it is then expelled. On reaching fresh standing or slowly moving water, and with correct conditions of light and temperature, the egg hatches, releasing the miracidium. First, the miracidium finds and penetrates one of the specific snails that serve as intermediate hosts; then each miracidium undergoes extensive asexual multiplication, with the result that a multitude of *cercariae* (final-stage larvae) are produced within the snail. With proper conditions of light, the cercariae, which have a head and a Y-shaped tail, are released into the water. Then, encountering humans, individual cercaria attach and release proteolytic enzymes that enable the cercaria to penetrate human skin. At the same time, the cercaria's tail is lost. Now known as a *schistosomulum*, it penetrates the dermis and passes to the lungs. From the lung, by mechanisms that are unclear, the schistosomulum passes to the host's liver, where it matures in the portal circulation to an adult schistosome. Adult worms then migrate to

specific venous plexuses, where they produce eggs that are either (a) excreted to repeat the cycle or (b) pass in the venous system to other organs.

Humans are thought to be the main reservoir host for *S mansoni* and *S haematobium*.<sup>121</sup> On the other hand, *S japonicum* has been shown to infect a wide variety of domestic animals (eg, dogs, cats, goats, pigs, horses, water buffalo, cattle) and rodents, which then serve as additional reservoirs.<sup>119,121</sup>

The host-parasite interaction in the production of disease is complex.<sup>119,124</sup> By acquiring host antigens, the adult worm may effectively disguise itself and not incite a host immunological response. Thus, an adult fluke (measuring 12–26 mm x 0.3–0.6 mm) may reside in vessels of the venous plexus for 3 to 7 years, on average.<sup>118</sup> However, penetration of the schistosomulum elicits a brisk cell-mediated cytotoxic response, in which IgE and eosinophils are important components. A reaction similar to that elicited by an immune complex formation is precipitated by worm migration, the initial reaction to egg production by mature female worms, or both. The granulomatous response to the eggs, which results in obstruction of vessels, is thought to be the major determinant of pathological manifestations of chronic disease. Acute schistosomiasis is a disease usually limited to travelers entering endemic areas and being exposed for the first time. In endemic areas, most of those infected are asymptomatic and major disease manifestations develop only in a small percentage of heavily infected individuals.<sup>119</sup>

**Clinical Manifestations.** When the cercariae contact the skin and begin their penetration, a transient pruritus or burning and erythematous macules or urticarial papules may develop.<sup>119,125,126</sup> Over the next 3 days, a punctate hemorrhagic component followed by crusting develops at the site. After several weeks, the eruption resolves, leaving postinflammatory hyperpigmentation. In humans, this cercarial dermatitis is known as schistosomal dermatitis, is less severe than that produced by nonhuman schistosomes, and may be more severe in individuals who have been sensitized by previous exposure.<sup>119</sup>

An acute syndrome that begins suddenly occurs in infected individuals and seems to be related to either migration of the worm or the initial release of eggs by the mature worm.<sup>119,121,125–127</sup> The acute syndrome, known as Katayama fever, occurs 2 to 6 weeks after penetration by cercariae and may last 1 to 2 months. Manifestations include spiking afternoon fevers, chills, bronchitis, pneumonitis, headache, lymphadenopathy, hepatosplenomegaly, joint

pain, diarrhea, urticaria, eosinophilia, leukocytosis, and an elevated erythrocyte sedimentation rate. Katayama fever is thought to be due to immune complex formation, but, interestingly, proteinuria and glomerulonephritis are not features of this stage of disease.<sup>124</sup>

A late hypersensitivity reaction characterized by generalized urticaria, pruritus, lichenified papules, or dermatographism occasionally develops (Figure 12-36). This may be due to a nonspecific reaction to egg deposition.<sup>126</sup>

Chronic schistosomiasis is due to a granulomatous response to egg deposition in target tissues. Localized in the venous plexus of the host's bladder, *S haematobium* releases its eggs, resulting in a characteristic urogenital syndrome in which hematuria, obstructive uropathy, and bladder cancer figure prominently. The other schistosomes that cause disease in humans are found in the venous plexus of the bowel: *S japonicum* in the superior mesenteric plexus and *S mansoni* in the inferior mesenteric plexus.<sup>119</sup> Egg granulomas in portal presinusoidal vessels result in hepatomegaly, splenomegaly, varices, ascites, and fibrosis (Symmers' clay pipestem); those in the mesenteric distribution produce protein-losing enteropathies, malabsorption anemias, hemorrhagic intestinal polyps, and fibrosis.

Aberrant or embolic lodgment of eggs may produce lesions in a variety of other tissues, including the kidney, lung, CNS, and, rarely, the skin.<sup>119</sup> When skin lesions occur, they are most commonly due to *S haematobium*; genital and perigenital sites are more frequent and periumbilical less frequent sites of involvement.<sup>119,125-132</sup> The lesions may be papules, macules, or, especially in the female genitalia, warty tumors. Cutaneous lesions may be asymptomatic, pruritic, or painful. Complications of disease may include ulcerations, fissures, multiple sinuses, fistulae, and fibrosis.

**Diagnosis.** It is systemic illness rather than cutaneous disease that leads the patient to seek treatment.<sup>125</sup> The diagnosis of Katayama fever is considered when patients who recently have been in an endemic area present with fever, headache, fatigue, diarrhea, or eosinophilia.<sup>123</sup> Chronic illness due to complications of egg granulomas is suspected more readily because patients are in endemic areas. Difficulties may arise, though, when such patients present in nonendemic areas to physicians who may be less familiar with the disease.

Finding ova in the feces or urine is the standard method of diagnosis: *S haematobium* is an oval egg

## OK to put on the Web

**Fig. 12-36.** This African patient developed these hyperpigmented nodules of cutaneous schistosomiasis on his abdomen as a manifestation of his infection with *Schistosoma mansoni*. Photograph: Courtesy of Armed Forces Institute of Pathology. Negative 78-3500-1.

with a terminal spine, while the spine of *S mansoni* is lateral, and that of *S japonicum* is small and rudimentary. In acute schistosomiasis, egg production may not be detectable. Biopsy of specific (ie, egg-induced) cutaneous lesions may well reveal granulomas. Reliable serologic diagnosis is currently limited to a few research laboratories; a sensitive ELISA seems to be the most promising.<sup>119</sup>

**Treatment.** Treatment of all human schistosomiasis is with praziquantel. One schedule calls for 40 mg/kg/d administered orally in two doses for 1 day, except for *S japonicum* and *S mekongi*, which are treated by administering 60 mg/kg/d in three doses for 1 day.<sup>32</sup>

Because of water-control measures, bodies of water in which snails, the fluke's intermediate host,

thrive are increasing. With population migration, then, schistosomiasis is actually spreading. In endemic areas, all fresh water should be considered contaminated. When using such water for bathing purposes, pretreatment by heating to 122°F for 5 minutes or by using chlorine or iodine in concentra-

tions similar to those used for treatment of drinking water should be used. Also, vigorous toweling or application of rubbing alcohol after potential exposure may prevent cercarial penetration.<sup>123</sup> Studies are ongoing to develop barrier substances that would limit skin penetration and subsequent infection.

## SUMMARY

Medical support of U.S. armed forces is critical to soldiers' health and effectiveness. The failure to provide timely diagnoses and effective treatment of cutaneous diseases may cause a serious degradation in the individual's physical condition and, therefore, effectiveness. Further, the psychological impediment that can develop in soldiers so afflicted should not be denigrated. Thus, the medical officer should never forget the maxim that common diseases are common. While this generally is construed to mean that bacterial and, perhaps, fungal diseases will cause the bulk of cutaneous disease, in the tropics we should not underestimate the morbidity that indigenous diseases can cause.

Tropical regions are host to a number of diseases with which physicians trained in the United States have little practical experience. With proper clothing, appropriate use of insect repellents, proper food handling, and good training in sanitation and hygiene, soldiers may be able to avoid some of these diseases. Nevertheless, the wary medical officer must remain alert to the possibility that these conditions may develop among the troops; the physi-

cian will certainly encounter them in the population native to the area. Medical personnel who live in these areas are excellent and important sources of information about local health risks. The Armed Forces Medical Intelligence Center at Fort Detrick, Frederick, Maryland, can provide information about regional risks. Coupled with that information, knowledge of the cutaneous manifestations that are often keys to the diagnosis should provide the medical officer the opportunity to diagnose accurately and to initiate effective treatment in a timely fashion.

Finally, medical officers should make every effort to consult regularly published periodicals for the latest treatment update, as treatments for these diseases are evolving. The doses listed in this chapter generally apply to adults. It is important to note that treatment of debilitated, frail patients; the elderly; children; and pregnant women may vary from the drugs and schedules listed in this chapter. The *Medical Letter on Drugs and Therapeutics* publishes a regular update of the drugs used for treatment of parasitic infection.

## REFERENCES

1. Strickland GT. Protozoal infections: General principles. In: Strickland GT, ed. *Hunter's Tropical Medicine*. 7th ed. Philadelphia, Pa: WB Saunders Company; 1991: 546–549.
2. Lapage G. Parasites and war. *Military Surgeon*. 1945;97:23–29.
3. Keeling WM. Former Commander, US Army 18th Surgical Hospital, Quang Tri, Vietnam, October 1970 through July 1971. Telephone conversation, November 1991.
4. Hayman JM. Filariasis. In: Havens WP, ed. *Infectious Diseases and General Medicine*. Vol 3. In: Havens WP, Anderson RS, eds. *Internal Medicine in World War II*. Washington, DC: Medical Department, US Army, Office of The Surgeon General; 1968: 123–144.
5. Beaver PC, Jung RC, Cupp EW. Morphology, biology, lifecycles, and classification of protozoa. In: *Clinical Parasitology*. 9th ed. Philadelphia, Pa: Lea & Febiger; 1984: 35–40.
6. Hart DT. Cutaneous and visceral leishmaniasis: A historical perspective. *Trans R Soc Trop Med Hyg*. 1985;79: 740–741.

7. MacPherson WG, Horrocks WH, Beveridge WWO, eds. Skin diseases. In: *Medical Services, Hygiene of the War*. Vol 1. In: *History of the Great War, Based on Official Documents*. London, England: His Majesty's Stationery Office; 1923: 68–113.
8. Most H. Leishmaniasis. In: Havens WP, ed. *Infectious Diseases and General Medicine*. Vol 3. In: Havens WP, Anderson RS, eds. *Internal Medicine in World War II*. Washington, DC: Medical Department, US Army, Office of The Surgeon General; 1968: 1–48.
9. Grögl M. Division of Experimental Therapeutics, Walter Reed Army Institute of Research, Washington, DC. Telephone conversations, September 1991, March 1994.
10. Magill AJ, Grögl M, Gesser RA, Sun W, Oster C. Visceral infection caused by *Leishmania tropica* in veterans of Operation Desert Storm. *N Engl J Med*. 1993;328:1383–1387.
11. Chulay, JD. Leishmaniasis: General principles. In: Strickland GT, ed. *Hunter's Tropical Medicine*. 7th ed. Philadelphia, Pa: WB Saunders Company; 1991: 638–642.
12. Beach R, Kiilu G, Leeuwenburg J. Modification of sand fly biting behavior by *Leishmania* leads to increased parasite transmission. *Am J Trop Med Hyg*. 1985;34:278–282.
13. Kubba R, Al-Gindan Y. Leishmaniasis. *Dermatologic Clinics*. 1989;7:331–351.
14. DaSilva RP, Hall BF, Joiner KA, Sacks DL. CR1, the C3b receptor mediates binding of infective *Leishmania major* metacyclic promastigotes to human macrophages. *J Immunol*. 1989;143:617–622.
15. Lainson R, Shaw JJ. Evolution, classification and geographical distribution. In: Peters W, Killick-Kendrick R, eds. *Biology and Epidemiology*. Vol 1. In: *The Leishmaniasis in Biology and Medicine*. Orlando, Fla: Academic Press; 1987: 1–120.
16. Grimaldi G Jr, Tesh RB, McMahon-Pratt D. A review of the geographic distribution and epidemiology of leishmaniasis in the New World. *Am J Trop Med Hyg*. 1989;41:687–725.
17. Walton BC. Leishmaniasis: A world-wide problem. *Int J Dermatol*. 1989;28:305–307.
18. Griffiths WAD. Old World cutaneous leishmaniasis. In: Peters W, Killick-Kendrick R, eds. *Clinical Aspects and Control*. Vol 2. In: *The Leishmaniasis in Biology and Medicine*. Orlando, Fla: Academic Press; 1987: 617–636.
19. Walton BC. American cutaneous and mucocutaneous leishmaniasis. In: Peters W, Killick-Kendrick R, eds. *Clinical Aspects and Control*. Vol 2. In: *The Leishmaniasis in Biology and Medicine*. Orlando, Fla: Academic Press; 1987: 637–663.
20. Kubba R, Al-Gindan Y, El-Hassan AM, Omer AHS. Clinical diagnosis of cutaneous leishmaniasis (oriental sore). *J Am Acad Dermatol*. 1987;16:1183–1189.
21. Kerdel-Vegas F. American leishmaniasis. *Int J Dermatol*. 1982;21:291–303.
22. Chulay JD. Cutaneous leishmaniasis of the Old World. In: Strickland GT, ed. *Hunter's Tropical Medicine*. 7th ed. Philadelphia, Pa: WB Saunders Company; 1991: 648–652.
23. Chulay, JD. Cutaneous leishmaniasis of the New World. In: Strickland GT, ed. *Hunter's Tropical Medicine*. 7th ed. Philadelphia, Pa: WB Saunders Company; 1991: 652–655.
24. Kubba R, El-Hassan AM, Al-Gindon Y, Omer AHS, Kutty MK, Saeed MBM. Dissemination in cutaneous leishmaniasis. Part 1. Subcutaneous nodules. *Int J Dermatol*. 1987;26:300–304.
25. Rees PH, Kager PA. Visceral leishmaniasis and post-kala azar dermal leishmaniasis. In: Peters W, Killick-Kendrick R, eds. *Clinical Aspects and Control*. Vol 2. In: *The Leishmaniasis in Biology and Medicine*. Orlando, Fla: Academic Press; 1987: 583–615.



26. Most H, Laviertes PH. Kala azar in American military personnel: Report of 30 cases. *Medicine*. 1947;26:221–284.
27. Oster CN, Chulay JD. Visceral leishmaniasis (kala azar). In: Strickland GT, ed. *Hunter's Tropical Medicine*. 7th ed. Philadelphia, Pa: WB Saunders Company; 1991: 642–648.
28. Kalter DC. Cutaneous and mucocutaneous leishmaniasis. *Progress in Dermatology*. 1989;23:1–11.
29. Anthony RL, Grögl M, Sacci JB, Ballou RW. Rapid detection of *Leishmania* amastigotes in fluid aspirates and biopsies of human tissues. *Am J Trop Med Hyg*. 1987; 37:271–276.
30. Bryceson A. Therapy in man. In: Peters W, Killick-Kendrick R, eds. *Clinical Aspects and Control*. Vol 2. In: *The Leishmaniasis in Biology and Medicine*. Orlando, Fla: Academic Press; 1987: 847–907.
31. Berman JD. Chemotherapy for leishmaniasis: Biochemical mechanisms, clinical efficacy, and future strategy. *Rev Inf Dis*. 1988;10:560–586.
32. Abramowicz M, ed. Drugs for parasitic infection. *Med Lett Drugs Ther*. 1993;35:111–122.
33. Netto EM, Marsden PD, Llanos-Cuentas EA, et al. Long-term follow-up of patients with *Leishmania (Viannia) braziliensis* infection treated with glucantime. *Trans Roy Soc Trop Med Hyg*. 1990;84:367–370.
34. Franke ED, Wignall FS, Cruz ME, et al. Efficacy and toxicity of sodium stibogluconate for mucosal leishmaniasis. *Ann Int Med*. 1990;113:934–940.
35. Grögl M, Thomason TN, Franke ED. Drug resistance in leishmaniasis: Its implication in systemic chemotherapy of cutaneous and mucocutaneous disease. *Am J Trop Med Hyg*. 1992;47:117–126.
36. Edgcomb JH, Johnson CM. American trypanosomiasis (Chagas' disease). In: Binford CH, Connor DH, eds. *Pathology of Tropical and Extraordinary Diseases*. Vol 1. Washington, DC: Armed Forces Institute of Pathology; 1976: 244–251.
37. Beaver PC, Jung RC, Cupp EW. The blood and tissue flagellates. In: *Clinical Parasitology*. 9th ed. Philadelphia, Pa: Lea & Febiger; 1984: 55–100.
38. Garcia-Zapata MTA, McGreevy PB, Marsden PD. American trypanosomiasis. In: Strickland GT, ed. *Hunter's Tropical Medicine*. 7th ed. Philadelphia, Pa: WB Saunders Company; 1991: 628–637.
39. Woody NC, Woody HB. American trypanosomiasis. Part 1. Clinical and epidemiologic background of Chagas' disease in the United States. *J Pediatr*. 1961;58:568–580.
40. Richman TB, Kerdel FA. Amebiasis and trypanosomiasis. *Dermatologic Clinics*. 1989;7:301–311.
41. Kirchhoff LV. American trypanosomiasis (Chagas' disease)—A tropical disease now in the United States. *N Engl J Med*. 1993;329:639–644.
42. Hudson L, Britten V. Immune response to South American trypanosomiasis and its relationship to Chagas' disease. *Br Med Bull*. 1985;41:175–180.
43. Laranja FS, Dias E, Nobrega G, Miranda A. Chagas' disease: A clinical, epidemiologic, and pathologic study. *Circulation*. 1956;14:1035–1060.
44. Marsden PD. South American trypanosomiasis (Chagas' disease). *Int Rev Trop Med*. 1971;4:97–121.
45. Amorim DS. Chagas' disease. *Prog Cardiol*. 1979;8:235–279.
46. Van Meirvenne N, Le Ray D. Diagnosis of African and American trypanosomiasis. *Br Med Bull*. 1985;41:156–161.

47. Hagar JN, Rahmtoola SH. Chagas' heart disease in the United States. *N Engl J Med*. 1991;325:763–768.
48. Earlam RJ. Gastrointestinal aspects of Chagas' disease. *Am J Dig Dis*. 1972;17:559–571.
49. Bales JD Jr. African trypanosomiasis. In: Strickland GT, ed. *Hunter's Tropical Medicine*. 7th ed. Philadelphia, Pa: WB Saunders Company; 1991: 617–628.
50. Connor JH, Neafie RC, Dooley JR. African trypanosomiasis. In: Binford CH, Connor DH, eds. *Pathology of Tropical and Extraordinary Diseases*. Vol 1. Washington, DC: Armed Forces Institute of Pathology; 1976: 252–257.
51. Foulkes JR. The six diseases of WHO: Human trypanosomiasis in Africa. *Br Med J*. 1981;283:1172–1174.
52. Duggan AJ, Hutchinson MP. Sleeping sickness in Europeans: A review of 109 cases. *J Trop Med Hyg*. 1966; 69:124–131.
53. Guerrant RL. Amebiasis: Introduction, current status, and research questions. *Rev Inf Dis*. 1986;8:218–227.
54. Walsh JA. Problems in recognition and diagnosis of amebiasis: Estimation of the global magnitude of morbidity and mortality. *Rev Inf Dis*. 1986;8:228–238.
55. Ognibene AJ, Wells RF, Barrett O Jr. Amebiasis and other parasitic diseases. In: Ognibene AJ, Barrett O Jr, eds. *General Medicine and Infectious Diseases*. Vol 2. In: Ognibene AJ, ed. *Internal Medicine in Vietnam*. Washington, DC: Medical Department, US Army, Office of The Surgeon General, and Center of Military History; 1982: 397–418.
56. Wolfe MS. Amebiasis. In: Strickland GT, ed. *Hunter's Tropical Medicine*. 7th ed. Philadelphia, Pa: WB Saunders Company; 1991: 550–565.
57. Connor DH, Neafie RC, Meyers WM. Amebiasis. In: Binford CH, Connor DH, eds. *Pathology of Tropical and Extraordinary Diseases*. Vol 1. Washington, DC: Armed Forces Institute of Pathology; 1976: 308–316.
58. Ravdin JI. Pathogenesis of disease caused by *Entamoeba histolytica*: Studies of adherence, secreted toxins, and contact-dependent cytolysis. *Rev Inf Dis*. 1986;8:247–260.
59. Salata RA, Ravdin JI. Review of the human immune mechanisms directed against *Entamoeba histolytica*. *Rev Inf Dis*. 1986;8:261–272.
60. El-Zawahry M, El Komy M. Amoebiasis cutis. *Int J Dermatol*. 1973;12:305–307.
61. Fujita WH, Barr RJ, Gottschalk HR. Cutaneous amebiasis. *Arch Dermatol*. 1981;117:309–310.
62. Rimsza ME, Berg RA. Cutaneous amebiasis. *Pediatrics*. 1983;71:595–598.
63. Adams EB, MacLeod IN. Invasive amebiasis. Part 1. Amebic dysentery and its complications. *Medicine*. 1977;56:315–323.
64. Healy GR. Immunologic tools in the diagnosis of amebiasis: Epidemiology in the United States. *Rev Inf Dis*. 1986;8:239–246.
65. Most H. Helminthiasis. In: Havens WP, ed. *Infectious Diseases and General Medicine*. Vol 3. In: Havens WP, Anderson RS, eds. *Internal Medicine in World War II*. Washington, DC: Medical Department, US Army, Office of The Surgeon General; 1968: 145–155.
66. Wartman WB. Filariasis in American armed forces in World War II. *Medicine*. 1947;26:333–394.
67. Bang PB, Billings FT. Schistosomiasis japonica. In: Havens WP, ed. *Infectious Diseases and General Medicine*. Vol 3. In: Havens WP, Anderson RS, eds. *Internal Medicine in World War II*. Washington, DC: Medical Department, US Army, Office of The Surgeon General; 1968: 91–121.

68. Pelletier LL Jr. Chronic strongyloidiasis in World War II Far East ex-prisoners of war. *Am J Trop Med Hyg.* 1984;33:55–61.
69. Kelley PW, Takafuji ET, Wiener H, et al. An outbreak of hookworm infection associated with military operations in Grenada. *Milit Med.* 1989;154:55–59.
70. Meyers WM, Neafie RC, Connor DH. Ancylostomiasis. In: Binford CH, Connor DH, eds. *Pathology of Tropical and Extraordinary Diseases*. Vol 2. Washington, DC: Armed Forces Institute of Pathology; 1976: 421–427.
71. Pearson RD, Guerrant RL. Intestinal nematodes that migrate through skin and lung. In: Strickland GT, ed. *Hunter's Tropical Medicine*. 7th ed. Philadelphia, Pa: WB Saunders Company; 1991: 700–711.
72. Cline BL, Little MD, Bartholomew RK, Halsey NA. Larvacidal activity of albendazole against *Necator americanus* in human volunteers. *Am J Trop Med Hyg.* 1984;33:387–394.
73. Beaver PC. Larva migrans. *Exp Parasitol.* 1956;5:587–621.
74. Rogers AM, Dammin GJ. Hookworm infection in American troops in Assam and Burma. *Am J Med Sci.* 1946;211:531–538.
75. Neafie RC, Meyers WM. Cutaneous larva migrans. In: Strickland GT, ed. *Hunter's Tropical Medicine*. 7th ed. Philadelphia, Pa: WB Saunders Company; 1991: 773–775.
76. Katz R, Zigler J, Blank H. The natural course of creeping eruption and treatment with thiabendazole. *Arch Dermatol.* 1965;91:420–424.
77. Davis CM, Israel RM. Treatment of creeping eruption with topical thiabendazole. *Arch Dermatol.* 1968;97: 325–326.
78. Edelgass JW, Douglass MC, Stiefler R, Tessler M. Cutaneous larva migrans in northern climates: A souvenir of your dream vacation. *J Am Acad Dermatol.* 1982;7:353–358.
79. Meyers WM, Connor DH, Neafie RC. Strongyloidiasis. In: Binford CH, Connor DH, eds. *Pathology of Tropical and Extraordinary Diseases*. Vol 2. Washington, DC: Armed Forces Institute of Pathology; 1976: 428–432.
80. McKerrow JH, Brindley P, Brown M, Gam AA, Staunton C, Neva FA. *Strongyloides stercoralis*: Identification of a protease that facilitates penetration of the skin by infective larvae. *Exp Parasitol.* 1990;70:134–143.
81. Gill GV, Bell DR. *Strongyloides stercoralis* infection in former Far East prisoners of war. *Br Med J.* 1979;2:572–574.
82. Grove DI. Strongyloidiasis in Allied ex-prisoners of war in South-east Asia. *Br Med J.* 1980;280:598–601.
83. Proctor EM, Isaac-Renton JL, Robertson WB, Black WA. Strongyloidiasis in Canadian Far East war veterans. *Can Med Assoc J.* 1985;133:876–878.
84. Pelletier LL Jr, Gabre-Kidan T. Chronic strongyloidiasis in Vietnam veterans. *Am J Med.* 1985;78:139–140.
85. Smith JD, Goette DK, Odom RB. Larva currens: Cutaneous strongyloidiasis. *Arch Dermatol.* 1976;112:1161–1163.
86. Scowden EB, Schaffner W, Stone WJ. Overwhelming strongyloidiasis: An unappreciated opportunistic infection. *Medicine.* 1978;57:527–544.
87. Hakim SZ, Genta RM. Fatal disseminated strongyloidiasis in a Vietnam war veteran. *Arch Pathol Lab Med.* 1986;110:809–812.
88. Cook GC. *Strongyloides stercoralis* hyperinfection syndrome: How often is it missed? *Quarterly Journal of Medicine.* 1987;64:625–629.

89. Von Kustner LC, Genta RM. Cutaneous manifestations of strongyloidosis. *Int J Dermatol.* 1973;12:305–307.
90. Neva FA, Gam AA, Burke J. Comparison of larval antigens in an enzyme-linked immunosorbent assay for strongyloidiasis in humans. *J Inf Dis.* 1981;144:427–432.
91. Genta RM, Weil GJ. Antibodies to *Strongyloides stercoralis* larval surface antigens in chronic strongyloidiasis. *Lab Invest.* 1982;47:87–90.
92. Buck AA. Filarial infections: General principles. In: Strickland GT, ed. *Hunter's Tropical Medicine.* 7th ed. Philadelphia, Pa: WB Saunders Company; 1991: 711–713.
93. Davis BR. Filariases. *Dermatologic Clinics.* 1989;7:313–321
94. Beaver PC. Filariasis without microfilaremia. *Am J Trop Med Hyg.* 1970;19:181–189.
95. Ottesen EA. Filariasis now. *Am J Trop Med Hyg.* 1989;41(Suppl 3):9–17.
96. Buck AA. Filariasis. In Strickland GT, ed. *Hunter's Tropical Medicine.* 7th ed. Philadelphia, Pa: WB Saunders Company; 1991: 713–727.
97. Beaver PC, Jung RP, Cupp EW. The filariae. In: *Clinical Parasitology.* 9th ed. Philadelphia, Pa: Lea & Febiger; 1984: 350–399.
98. Meyers WM, Neafie RC, Connor DH. Bancroftian and Malayan filariasis. In: Binford CH, Connor DH, eds. *Pathology of Tropical and Extraordinary Diseases.* Vol 2. Washington, DC: Armed Forces Institute of Pathology; 1976:340–355.
99. Weller PF, Arnow PM. Paroxysmal and inflammatory filariasis: Filarial fevers. *Arch Int Med.* 1984;143: 1523–1524.
100. Trent SC. Reevaluation of World War II veterans with filariasis acquired in the South Pacific. *Am J Trop Med.* 1963;12:877–887.
101. Ottesen EA, Vijayasekaran V, Kumaraswami V, et al. A controlled trial of ivermectin and diethylcarbamazine in lymphatic filariasis. *N Engl J Med.* 1990;322:1113–1117.
102. Weller PF, Liu L-X. Bancroftian filariasis and ivermectin. *N Engl J Med.* 1990;322:1153–1154.
103. Duke BOL. Loiasis. In: Strickland GT, ed. *Hunter's Tropical Medicine.* 7th ed. Philadelphia, Pa: WB Saunders Company; 1991: 727–729.
104. Nutman TB, Miller KD, Mulligan M, Ottesen EA. *Loa loa* infection in temporary residents of endemic regions: Recognition of hyperresponsive syndrome with characteristic clinical manifestations. *J Inf Dis.* 1986;154:10–18.
105. Carme B, Boulesteix J, Boutes H, Puruehnce MF. Five cases of encephalitis during treatment of loiasis with diethylcarbamazine. *Am J Trop Med Hyg.* 1991;44:684–690.
106. Duke BOL. Human onchocerciasis: An overview of the disease. *Acta Leidensia.* 1990;59(1–2):9–24.
107. Duke BOL, Taylor HR. Onchocerciasis. In: Strickland GT, ed. *Hunter's Tropical Medicine.* 7th ed. Philadelphia, Pa: WB Saunders Company; 1991: 729–744.
108. Gibson DW, Duke BOL, Connor DH. Onchocerciasis: A review of clinical, pathologic and chemotherapeutic aspects, and vector control program. In: Sun T, ed. *Progress in Clinical Parasitology.* Vol 1. New York, NY: Field & Wood Medical Publishers, Inc; 1988: 57–103.

109. Connor DH, Gibson DW, Neafie RC, Merighi B, Buck AA. Sowda–onchocerciasis in North Yemen: A clinico-pathologic study of 18 patients. *Am J Trop Med Hyg.* 1983;32:123–137.
110. Nelson GS. “Hanging groin” and hernia, complications of onchocerciasis. *Trans Roy Soc Trop Med Hyg.* 1958;52:272–275.
111. Meyers WM, Neafie RC. Streptocerciasis. In: Strickland GT, ed. *Hunter’s Tropical Medicine.* 7th ed. Philadelphia, Pa: WB Saunders Company; 1991: 746–748.
112. Neafie RC, Connor DH, Meyers WM. Dracunculiasis. In: Binford CH, Connor DH, eds. *Pathology of Tropical and Extraordinary Diseases.* Vol 2. Washington, DC: Armed Forces Institute of Pathology; 1976: 397–401.
113. Spencer HC. Dracunculiasis. In: Strickland GT, ed. *Hunter’s Tropical Medicine.* 7th ed. Philadelphia, Pa: WB Saunders Company; 1991: 750–756.
114. Beaver PC, Jung RC, Cupp EW. The spirurida: *Dracunculus* and others. In: *Clinical Parasitology.* 9th ed. Philadelphia, Pa: Lea & Febiger; 1984: 335–349.
115. Murrell KD. Trichinosis. In: Strickland GT, ed. *Hunter’s Tropical Medicine.* 7th ed. Philadelphia, Pa: WB Saunders Company; 1991: 756–761.
116. Chaudhry AZ, Longworth DL. Cutaneous manifestations of intestinal helminthic infections. *Dermatologic Clinics.* 1989;7:275–290.
117. Neafie RC, Connor DH. Trichinosis. In: Binford CH, Connor DH, eds. *Pathology of Tropical and Extraordinary Diseases.* Vol 2. Washington, DC: Armed Forces Institute of Pathology; 1976: 409–414.
118. Sturrock RF. Biology and ecology of human schistosomes. *Clin Trop Med Comm Dis.* 1987;2:249–266.
119. Strickland GT, Abdel-Wahab MF. Schistosomiasis. In: Strickland GT, ed. *Hunter’s Tropical Medicine.* 7th ed. Philadelphia, Pa: WB Saunders Company; 1991: 781–809.
120. Gilles HM. Schistosomiasis update. *Int J Dermatol.* 1988;27:400–401.
121. McCully RA, Barron CN, Cheever AW. Schistosomes (Bilharziasis). In: Binford CH, Connor DH, eds. *Pathology of Tropical and Extraordinary Diseases.* Vol 2. Washington, DC: Armed Forces Institute of Pathology; 1976: 482–508.
122. Allen AM, Taplin D, Legters LJ, Ferguson JA. Schistosomes in Vietnam. *Lancet.* 1974;1:1075–1076.
123. Centers for Disease Control. Acute schistosomiasis in US travelers returning from Africa. *MMWR.* 1990;39:141–142, 147–148.
124. Nash TE, Cheever AW, Ottesen EA, Cook JA. Schistosome infections in humans: Perspectives and recent findings. *Ann Int Med.* 1982;97:740–754.
125. Amer M. Cutaneous schistosomiasis. *Int J Dermatol.* 1982;21:44–46.
126. Gonzalez E. Schistosomiasis, cercarial dermatitis and marine dermatitis. *Dermatologic Clinics.* 1989;7:291–300.
127. Garcia-Palmieri MR, Marcial-Rojas RA. The protean manifestations of schistosomiasis mansoni: A clinicopathologic correlation. *Ann Int Med.* 1962;57:763–775.
128. Bittencourt AL, Pinho O, Lenzi HL, Costa IMC. Extragenital cutaneous lesions of schistosomiasis mansoni. *Am J Trop Med Hyg.* 1979;28:84–86.

129. Jacyk WK, Lawande RV, Tulpule SS. Unusual presentation of extragenital cutaneous schistosomiasis mansoni. *Br J Dermatol.* 1980;103:205–208.
130. Attili VR, Hira SK, Dube MK. Schistosomal genital granulomas: A report of 10 cases. *Br J Vener Dis.* 1983;59:269–272.
131. Obasi OE. Cutaneous schistosomiasis in Nigeria: An update. *Br J Dermatol.* 1986;114:597–602.
132. Milligan A, Burns DP. Ectopic cutaneous schistosomiasis and schistosomal ocular inflammatory disease. *Br J Dermatol.* 1988;119:793–798.

# Chapter 13

## BACTERIAL SKIN DISEASES

RICHARD H. GENTRY, M.D.\*

---

### INTRODUCTION

#### PYODERMAS

- Etiology
- Clinical Features
- Prognosis
- Treatment

#### PLAGUE

- Etiology
- Epidemiology
- Clinical Features
- Laboratory Findings
- Diagnosis
- Treatment

#### TULAREMIA

- Etiology
- Epidemiology
- Clinical Manifestations
- Diagnosis
- Treatment

#### DIPHTHERIA

- Etiology
- Epidemiology
- Clinical Manifestations
- Diagnosis
- Treatment
- Immunization

#### MENINGOCOCCAL INFECTIONS

- Etiology
- Epidemiology
- Clinical Manifestations
- Diagnosis
- Treatment
- Chemoprophylaxis of Carriers
- Vaccines

#### LYME DISEASE

- Epidemiology
- Clinical Manifestations
- Diagnosis
- Treatment

### SUMMARY

\*Colonel, Medical Corps, U.S. Army; Department of Dermatology, Fitzsimons Army Medical Center, Aurora, Colorado 80045-5001

## INTRODUCTION

Bacterial pyodermas are among the most common disabling skin conditions that occur in wartime. Secondary infections of various superficial wounds may lead to cellulitis, abscess formation, or lymphangitis. Cuts from coral in the Pacific Ocean during World War II<sup>1</sup> and fungal infections in Vietnam<sup>2</sup> were common precursors to pyodermas. Other bacterial diseases such as plague, meningococemia, and diphtheria can occur in epidemic

forms during wartime because of crowding and common exposures to insect vectors. These diseases have had major influences on military conflicts.<sup>3-5</sup>

Lyme disease is relatively newly recognized. It is not uncommon for present-day U.S. military troops to develop erythema chronicum migrans, the early skin manifestation of Lyme disease, after maneuvers in Germany.

## PYODERMAS

Pyodermas due to *Staphylococcus aureus* and *Streptococcus pyogenes* are common in army troops. There are several reasons for this: irregular bathing habits, poor access to facilities for personal hygiene, irritation of the skin by rough clothing and equipment, minor traumatic abrasions, scabies, insect bites, mingling with native populations, and crowded living conditions for large numbers of troops.

These infections have played a major part in combat ineffectiveness among troops. During World War I, bacterial infections (furuncles, abscesses, and cellulitis) and secondarily infected scabies were by far the two most common causes for hospital admission for skin disease among U.S. troops: as the primary diagnosis, they comprised almost two thirds of all hospital admissions of U.S. troops in the Great War.<sup>6</sup> During World War II, bacterial skin infections were the most common source of morbidity in a check of representative hospitals<sup>1</sup>:

- In a 3-week spot check of three American divisions in 1944, cutaneous bacterial infections were found to be responsible for 70% of lost man-days.
- In the Mediterranean theater, two chief groups, cellulitis and furunculosis, comprised most of the bacterial skin infections.
- In the Pacific theater, pyodermas were more common. For example, in the Philippines, excluding combat injuries, 70% to 80% of troops attending sick call complained of ecthyma. Impetigo was also common in the Pacific theater.

Although most of these lesions were likely due to *Staphylococcus aureus* or *Streptococcus pyogenes* or

both, some were culture-positive for *Corynebacterium diphtheriae*.<sup>1</sup>

During the Vietnam conflict, bacterial skin infections were second only to fungal infections in their frequency of occurrence and the disability they produced for U.S. troops. These were primarily ecthymatous ulcers due to *Streptococcus pyogenes* and were frequently referred to as "jungle sores." The importance of recognizing and treating these infections was documented in the U.S. Army Medical Department's official history, *Skin Diseases in Vietnam, 1965-72*:

With respect to pyoderma, the most important advance made during the Vietnam war was the recognition that these apparently trivial infections are a major military problem in the Tropics. Those who attempted to prevent and treat pyoderma found that simplistic solutions were of little avail and that lesions tended to grow in size and number despite the most strenuous efforts at control. Progress was made not only in recognizing the problem but also in better defining these infections both clinically and epidemiologically.<sup>2(pp89-90)</sup>

Pyodermas such as impetigo and ecthyma were more frequent and more severe in infantrymen than they were in support troops in Vietnam. This was explained by increased exposure to environmental stresses (eg, insect bites, cuts, and scratches) among infantrymen. Black soldiers had fewer pyodermas than white soldiers.<sup>2</sup>

### Etiology

For years, it has been dogma that most bacterial pyodermas were due to *Streptococcus pyogenes* occasionally complicated by *Staphylococcus aureus* infec-



tion. In a study of pyoderma in Vietnam,<sup>2</sup> 60 of 86 cases (70%) grew both *S aureus* and  $\beta$ -hemolytic streptococci. An additional 14% of cases cultured pure  $\beta$ -hemolytic streptococci, and another 10%, pure *S aureus*.<sup>2</sup> Within the past 10 years, most studies<sup>7-9</sup> of pyodermas show *S aureus* to be their primary cause.

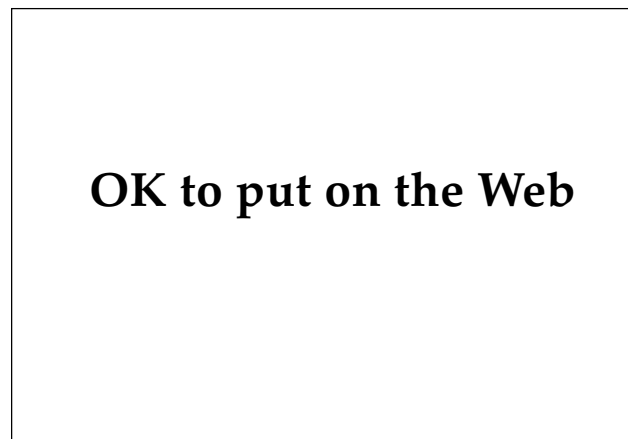It is not uncommon for tropical ulcers to contain several organisms of interest. A recent report on tropical ulcers in civilians found *S aureus* in only 2% and streptococci in only 15%. Coliform bacteria were found in 60%, fusobacteria in 35%, and bacteroides in 20%. All specimens grew a mixture of organisms.<sup>10</sup>

Folliculitis, furuncles, and carbuncles represent a continuum of severity of an infection centered about a hair follicle.<sup>11</sup> Although usually attributed to *S aureus*, one study<sup>12</sup> found this organism in only 24% of cutaneous abscesses. Another study<sup>13</sup> found *S aureus* in only 19% of vulvar furuncles; it suggested that although *S aureus* was usually believed to be the cause of furunculosis, it was not the only cause, especially if the lesion was around the genitals or the perianal region.

Erysipelas is almost always due to infection with  $\beta$ -hemolytic streptococci. Cellulitis is usually due to infection with  $\beta$ -hemolytic streptococci or *S aureus*.<sup>14</sup>

### Clinical Features

The characteristic sign of impetigo is superficial, stuck-on-appearing, honey-colored crusts (Figure 13-1). This is dried exudate from the underlying



**Fig. 13-1.** This thick yellow crust is typical of impetigo. Exudate from underlying denuded tissue dries, and patients present with this characteristic clinical sign.

## OK to put on the Web

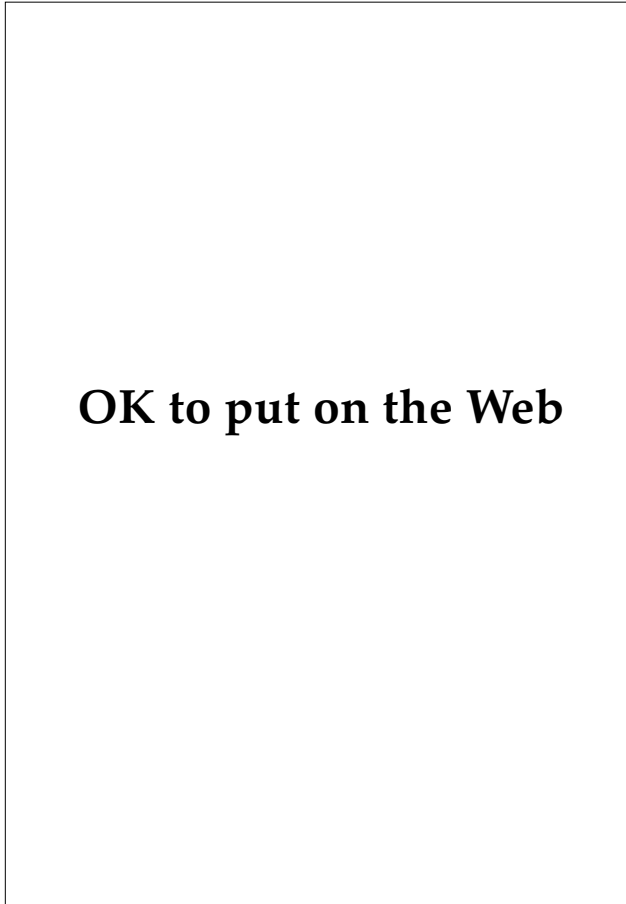
**Fig. 13-2.** In bullous impetigo, the vesicles and bullae quickly rupture and form a thin, dry, varnishlike veneer. Annular lesions are not uncommon. These were positive on culture for *Staphylococcus aureus*.

eroded tissue. While impetigo often occurs on the face, any break in the skin can become secondarily infected. In the field, exposed skin of the arms and legs will be involved frequently, as most insect bites, dermatophytoses, allergic contact dermatitides, and traumatic sores commonly become secondarily infected. Impetigo heals without scarring because it does not penetrate the epidermis.

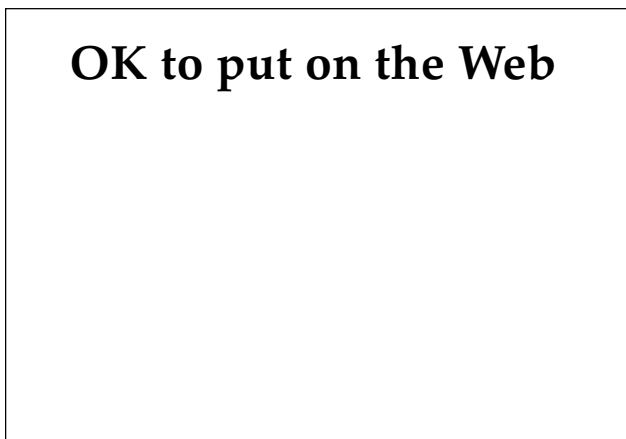
Bullous impetigo is usually due to pure *S aureus*, which manufactures a toxin, exfoliatin, that produces a subcorneal split in the epidermis.<sup>15</sup> Bullous impetigo is characterized by a flaccid blister that rapidly ruptures and makes the lesion appear varnished (Figure 13-2). Often a collarette of scale is also seen. Lesions tend to occur in the axillae or groin in adults (Figure 13-3).

Ecthyma presents as a punched-out ulceration, which may not be noted until a thick, overlying crust is removed (Figure 13-4). The condition is often tender or painful. Ecthyma was the most common pyoderma noted among U.S. troops in Vietnam<sup>2</sup> and was seen primarily on the hands, ankles, or lower extremities. There was often a zone of induration or erythema surrounding the ulcer, and multiple lesions were common. It heals with scarring because the epidermis is penetrated by the infection.

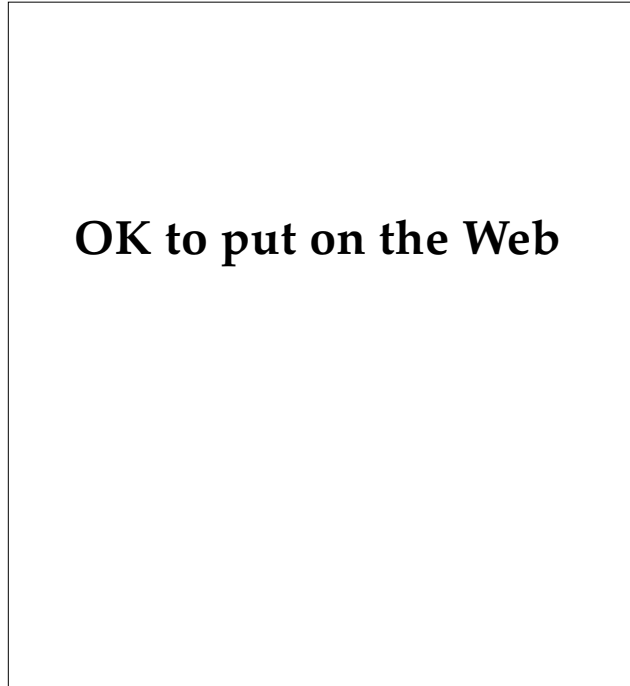
Furunculosis is an infection of the hair follicle that forms an inflammatory nodule with a pustular center (Figure 13-5).<sup>15</sup> Cellulitis is a more serious lesion that usually affects the lower extremities (Figure 13-6), face, or ear. It is red, painful or tender, and warm to the touch. If a palpable edge is present, the term *erysipelas* is used. Diagnosis is based on



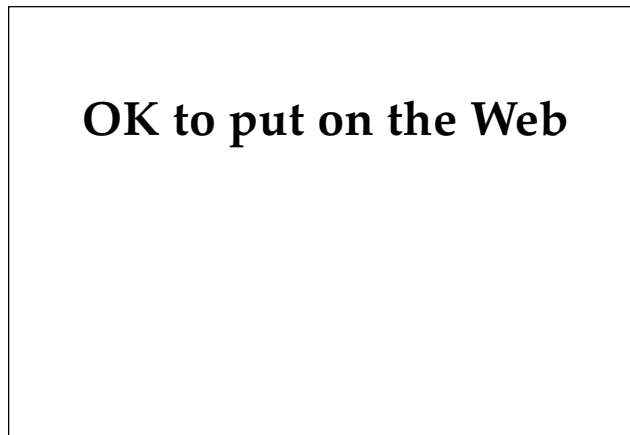
**Fig. 13-3.** A superficial pustule is noted anterior to the axilla. A Gram's stain of the contents revealed neutrophils and Gram-positive cocci in clusters. Culture was positive for *Staphylococcus aureus*. In the axillary vault, the pustules have ruptured, leaving collarettes of scale, which are characteristic of bullous impetigo.



**Fig. 13-5.** This erythematous papule with a pustular center is centered about a hair follicle. A furuncle is best treated with local heat and drainage.



**Fig. 13-4.** This punched-out ulceration above the ankle is typical of the "jungle sores" seen in Vietnam and the South Pacific during World War II. It had been present for several weeks without change. A culture was positive for  $\beta$ -hemolytic streptococci, group A. This lesion of ecthyma rapidly responded to appropriate antibiotics.



**Fig. 13-6.** This erythematous lesion above the ankle has been slowly worsening for several days. It is hot to touch. No raised, palpable edge is noted. In severe cases, such as this one, scaling is often seen over the surface. This location is classic for cellulitis.

physical examination. Both entities may be associated with rigors, fever, leukocytosis, and malaise.

### Prognosis

Under combat conditions, ecthyma can last for weeks unless properly treated. In Vietnam, it was not uncommon to find soldiers on light duty for a month or more due to these skin ulcerations. Frequently, a new crop of lesions appeared as the old lesions healed. Cellulitis, erysipelas, and lymphangitis are well-known complications of impetigo and ecthyma. Acute glomerulonephritis can also complicate skin infections caused by *Streptococcus pyogenes*, but this was uncommon in Vietnam.<sup>2</sup>

### Treatment

The treatment of choice for pyodermas is an antistaphylococcal penicillin such as dicloxacillin given in a dose of 250 mg orally four times daily for 10 days. The dose is often doubled the first 3 days in more severe infections. Erythromycin and clindamycin are suitable alternatives if the patient is allergic to penicillin. Cephalosporins or combinations of amoxicillin and clavulanate may also be used, but are much more expensive and seldom offer an advantage over antistaphylococcal penicillins.

Topical antibiotics are generally not helpful or necessary when appropriate oral antibiotics are

given. Mupirocin is an exception to this.<sup>16</sup> Applied thrice daily for 1 week, it will heal most simple pyodermas and may avoid the need for systemic antibiotics. Debridement of the lesions is helpful but soaking in hexachlorophene or other antibacterial soaks retards rather than enhances healing.

Treatment of pyoderma in a combat situation remains a problem. For most of these drugs to work, they must be given four times daily, which is impossible in combat. The combination of amoxicillin and clavulanate requires dosing thrice daily as does topical mupirocin, but in combat even this may be too much. Benzathine penicillin may be helpful as a single dose of 1.2 million units, administered intramuscularly. No further therapy for *Streptococcus pyogenes* would be required; however, this is poor coverage for *Staphylococcus aureus*.

Furuncles are best treated with local heat. When there is superficial fluctuance, they can be drained. Antibiotics are usually not required unless systemic symptoms are present.<sup>13</sup>

Cellulitis and erysipelas are more serious infections. Intravenous antibiotics are usually the best therapy. Penicillin is usually adequate for erysipelas, but coverage with an antistaphylococcal penicillin is indicated for cellulitis. If the patient is allergic to penicillin, intravenous vancomycin or erythromycin may be used. Elevation is important if a lower leg is involved.<sup>14</sup>

## PLAGUE

Plague is a zoonotic disease caused by the bacterium *Yersinia pestis*, which is usually transmitted to humans by rodents and their fleas but can also be transmitted via the respiratory route. When transmitted by a flea bite, the disease is characterized by an early sign known as a *bubo* (ie, a mass of lymph nodes in the groin, axilla, or neck that become matted together and drain purulent material). Three days after these buboes appear, the patients develop high fever and delirium. Black splotches develop due to hemorrhages into the skin. It is these black areas that gave this disease its common name: Black Death. Systemic and pneumonic forms of plague can also occur; these forms of the disease and their transmission, which are discussed later in this section, are far rarer than bubonic plague.

Plague is a disease of antiquity. During the second millennium BC, the Philistines were smitten with plague after capturing the Ark of the Covenant from the Israelites. During the 6th century AD, the

Justinian plague (ie, the first plague pandemic) was described in the area of Constantinople.<sup>3</sup> During the 14th century, 70% to 80% of those who contracted the disease died from it. During the year 1346, Europe and the lands around the Mediterranean had a population of approximately 100 million people. An outbreak of plague lasting from 1346 to 1352 and known as the Great Dying or the Great Pestilence (ie, the second pandemic) killed approximately one fourth of this population. Europe alone sustained a loss of approximately 20 million people.<sup>17</sup>

After the second great pandemic, plague recurred in Europe over the next few centuries. London's last experience with plague ended with the Great Fire of 1666.<sup>17</sup> The disease was subsequently seen in the armies of Frederick the Great, Catherine the Great, and Napoleon's troops in Egypt.<sup>3</sup>

The third pandemic began in China and rapidly spread to most of Asia during the period 1894 through 1920. In India alone, an estimated 12 mil-

lion people died. Several important epidemiological discoveries were made during this period<sup>3</sup>:

- During 1894, Kitasato and Yersin independently isolated and described the plague bacillus.
- From 1903 to 1905, Liston of the Indian Plague Commission demonstrated the association with rats and fleas. The vital concepts of rat and flea control emerged from this commission.
- Haffkine, working in Bombay during this same period, developed an effective plague vaccine.
- Territorial spread of this disease was reduced by the development of rat-proof ships, together with fumigation of premises and vessels.

During World War II, a killed plague vaccine was developed and administered to U.S. troops in endemic areas. Dichlorodiphenyltrichloroethane (DDT) was developed and introduced during the war, and plague control became synonymous with flea control. Plague was not a significant problem for U.S. troops during World War II. Following the war, plague control rapidly improved. The sulfonamides and, especially, streptomycin and tetracycline proved effective in the treatment of all clinical forms of the disease. Plague foci were found in both commensal and wild rodents via improved bacteriological and serologic techniques. These foci were reduced by new insecticides and rodenticides. Promising new vaccines were introduced.<sup>3</sup>

Plague has never been a significant problem to the U.S. military, thanks to an understanding of the epidemiology of the disease. Effective control measures have been rapidly incorporated into preventive medicine programs. Plague is endemic in Vietnam, and during the conflict in the 1960s and 1970s, more than 10,000 cases occurred per year in the Vietnamese population.<sup>18</sup> Still, there were relatively few cases of this disease in American servicemen.<sup>3</sup>

## Etiology

*Yersinia pestis* is a plump, Gram-negative, pleomorphic bacillus (0.8 × 1.5 μm; range 0.5–2.0 μm). A bipolar (ie, safety-pin) appearance is best demonstrated in smears of infected animal tissues stained by either the Giemsa or the Wayson method. Preparations stained with Gram's stain do not dependably render this classic appearance. It does not ferment lactose.<sup>19</sup>

Plague bacilli are aerobic and facultatively anaerobic. They are not fastidious and grow readily in most bacteriological culture mediums. Growth is satisfactory at 35°C to 37°C, but slow. Even at the optimum growth temperature of 28°C, about 48 hours are necessary before colonies are readily discernible on plain agar.<sup>19</sup>

The fluorescent antibody test is used for rapid identification of this bacterium. It tests for bacterial envelope fraction 1, which is produced most readily at 37°C but not at temperatures below 28°C. This test is best used on smears of animal tissues, aspirates of exudates from buboes or other tissues, sputum specimens, and cultures incubated at 37°C. Clinical specimens that were frozen or refrigerated after collection are suitable for immediate fluorescent antibody testing. Cross-reactions with *Y pseudotuberculosis* may occur, and occasional strains of *Y pestis* exhibit weak or no staining. A positive fluorescent antibody test supported by epidemiological and clinical evidence is good evidence for this diagnosis.<sup>19</sup>

## Epidemiology

The ecology of plague is complex. Infection occurs primarily in rodents and is usually spread to people and pets by the bite of an infected rodent flea. The oriental rat flea, *Xenopsylla cheopis*, has been considered the traditional vector in urban outbreaks; however, multiple species of fleas have been associated with plague.<sup>20</sup>

In the *X cheopis* flea, *Y pestis* infection leads to a blockage of the midgut by fibrinoid material and masses of these bacilli. The flea, in effect, cannot ingest a blood meal, and it makes repeated attempts to feed. Unable to pass the meal through the blockage, it regurgitates several thousand bacilli onto the bite site with each attempt. If infected *X cheopis* is maintained at temperatures over 27°C, this blockage will spontaneously clear. Plague epidemics have long been known to subside spontaneously when ambient temperatures remain above 27°C to 30°C, probably due to this phenomenon.<sup>20</sup> Epidemics of plague are distinctly seasonal: bubonic plague is a disease of the cooler months in hot climates and of the warmer months in cool climates.<sup>3</sup>

## Typical Mode of Transmission

The two most important reservoirs of plague bacillus throughout the world are two commensal rodents, *Rattus rattus* (the domestic rat) and *Rattus norvegicus* (the urban rat). Throughout history,

plague epidemics have occurred when huge numbers of susceptible rats died, which forced their infected fleas to seek other hosts. Rats are not the only host, however: more than 200 species of rodents are susceptible,<sup>20</sup> including prairie dogs, chipmunks, marmots, and deer mice. In the Rocky Mountain states, where plague is endemic, epizootics among rock squirrels are often the source of infection in humans. The infected fleas can seek out humans who are hunting, camping, or living in these areas.<sup>19</sup> The fleas can also be transported to humans through pets such as dogs and cats.

### Other Modes of Transmission

Pets can also acquire the disease via the ingestional route, by devouring the sick animals, which are easy prey. Although in dogs plague is usually a mild illness, it causes a higher than 50% mortality in cats.<sup>20</sup> Cats can transmit the disease to humans by bite or scratch<sup>21</sup> as well as via fleas. Cats have also been associated with the transmission of pneumonic plague.<sup>22</sup> Exposure to domestic cats was associated with 3% of plague in the United States during the 1970s, ranking third behind bites of infected fleas (82%) and direct exposure to wild animals (15%).<sup>23</sup>

Plague can also be rapidly spread through the air, and about 5% of bubonic plague patients will develop the potential for airborne transmission. Most severe epidemics have occurred in areas where the climate is relatively cool. *Y pestis* cannot survive in aerosol clouds at high temperature and humidity. Hence, primary plague pneumonia is rare in the tropics. Conversely, low humidity is also associated with rapid death of the plague bacillus in the air. Epidemics of primary plague pneumonia are favored by cool weather, moderate humidity, and close personal contact between individuals.<sup>3</sup>

The transportation of infected rodents and fleas from endemic areas may introduce the disease into new areas. The rat-proofing of ships has greatly reduced the risk of transporting infected rats and fleas to distant seaports. The technique of shipping by containers, however, may present a special hazard because the containers can harbor rats.<sup>3</sup>

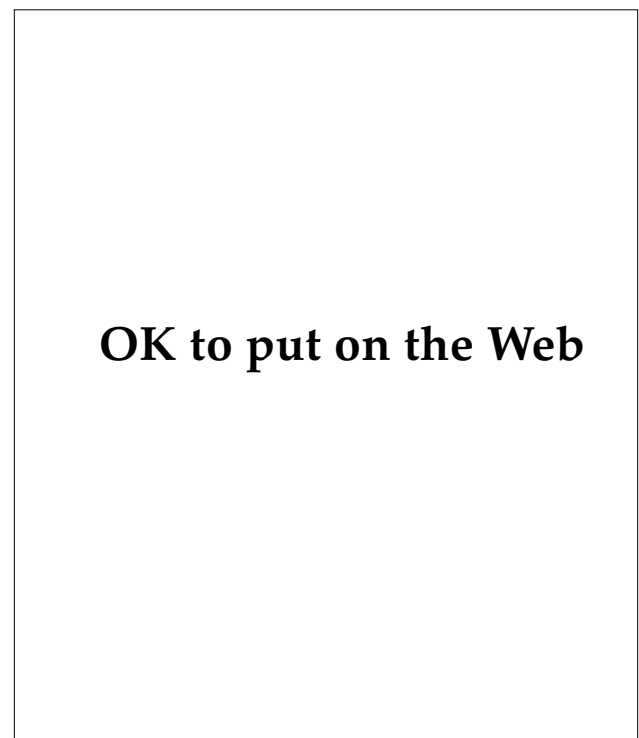### Clinical Features

Plague begins abruptly and, unless early therapy is initiated, can cause death in hours to a few days in 60% to 90% of cases. Only cholera and meningococemia can overwhelm a previously healthy body's defenses so rapidly.<sup>3</sup> Plague usually

occurs in three forms: bubonic, septicemic, and pneumonic. Complications such as meningitis and endophthalmitis can arise from hematogenous spread of *Y pestis*.

### Bubonic Plague

The bubonic form of plague is the most common. After the flea bite, the organisms proliferate in the lymph nodes. After an incubation period of 2 to 8 days, the typical patient has the sudden onset of chills, fever, weakness, and headache. At the same time or by the next day, the patient notices the bubo.<sup>18</sup> Intense pain usually heralds the onset of a bubo with the lesion itself becoming visible or palpable within 24 hours. Buboes may occur anywhere there are lymph nodes. Occasionally, intraabdominal buboes have presented as acute surgical abdomens, and operations for this have occurred on numerous occasions. The most common location, accounting for over half of all buboes, is in the groin. Involvement in this location is felt to be secondary to a flea bite on the leg. Buboes are also common in the axillae (Figure 13-7) and then the



**Fig. 13-7.** This painful, swollen axillary lymph node occurred in a prostrate, febrile patient with bubonic plague. Buboes most frequently occur in the groin, as flea bites are most common on the legs.

neck. Intense pain is characteristic of these buboes.<sup>3</sup>

The patient is typically prostrate and lethargic in uncomplicated bubonic plague. The temperature is in the range of 38.5°C to 40°C, with a pulse rate of 110 to 140 beats per minute and a low blood pressure of approximately 100/60. The liver and spleen are often palpable and tender.<sup>18</sup>

Early bubonic plague is typically not associated with skin lesions.<sup>24</sup> In Vietnam, about 25% of patients had papules, pustules, vesicles, or eschars near the bubo or in an anatomical area that drained to the bubo. Presumably, these were the sites of flea bites. White blood cells and plague bacilli were found on opening these lesions. Systemic disease may also lead to purpura and gangrene of the distal extremities.<sup>15</sup>

### **Septicemic Plague**

Plague also has a septicemic form in which buboes do not occur. In this small subset (about 10%) of patients, the mode of transmission is the same as in the bubonic form; however, blood stream invasion occurs prior to regional lymph node involvement. Older patients, who seem to be particularly susceptible to this aggressive form of plague, become acutely ill. In fact, there may be so many bacteria in the blood that they are readily seen on a blood smear. This is a grave prognostic sign.<sup>19</sup>

### **Pneumonic Plague**

One of the feared complications of bubonic plague is secondary pneumonia, which occurs by spread of the plague bacillus through the blood stream to the lungs. Intermittent bacteremia is common in plague. Single blood cultures taken at the time of admission of Vietnamese patients were positive in 27% of cases.<sup>18</sup> Plague pneumonia presents with cough, chest pain, hemoptysis, and purulent sputum loaded with bacilli. It is highly contagious with an incubation period of less than 3 days in new patients.<sup>19</sup> In fact, healthy patients have reportedly been exposed, become ill, and died on the same day. Pneumonic plague is invariably fatal when treatment is delayed more than 1 day after the onset of the illness.<sup>18</sup> Patients with plague may also present with pharyngitis.<sup>18</sup>

### **Laboratory Findings**

The white blood cell count is typically elevated in the range of 10,000 to 20,000/mm<sup>3</sup>. Severely ill

patients tend to have higher counts. Platelet counts are normal to low. Disseminated intravascular coagulation is common, with the laboratory abnormalities typical for this. Liver function tests are often elevated, as are renal function tests.<sup>18</sup>

### **Diagnosis**

Plague should be considered in all patients who present with buboes. It should also be seriously considered in febrile patients who have been exposed to rodents and fleas in endemic areas of the world. When a patient presents with a bubo, the best way to make the diagnosis is by needle aspiration. (It may be necessary to inject a small amount of saline to get an adequate specimen.) The specimen is sent for culture, but a small amount is air-dried and stained with Gram's and Wayson or Giemsa stains. The Gram's stain reveals pleomorphic, Gram-negative bacilli and coccobacilli. The typical safety-pin appearance is seen on either the Wayson or Giemsa stain. The fluorescent antibody test will give rapid confirmation.<sup>18</sup>

Blood, purulent sputum, and skin lesions (if present) should all be inoculated onto blood, MacConkey agar plates, and infusion broth. Appropriate stains should also be done on these specimens.<sup>18</sup>

For definitive identification, cultures can be mailed in double containers to the Centers for Disease Control and Prevention Plague Branch, P.O. Box 2087, Fort Collins, Colorado 80522 (telephone 303-221-6450). This laboratory can also perform acute and convalescent serologic testing to confirm the diagnosis.<sup>18</sup> The differential diagnosis should include tularemia, staphylococcal and streptococcal infections, lymphogranuloma venereum, and chancroid.<sup>19</sup>

### **Treatment**

Untreated, the case-fatality rate of bubonic plague is about 60%. In septicemic or pneumonic plague, it is probably 100%. The prognosis in pneumonic plague is poor if therapy is delayed more than 1 day after the onset of the symptoms. With early therapy, the fatality rate in bubonic plague should approach zero, but recently it was listed at 16%.<sup>19</sup>

All patients with bubonic plague should be isolated until 48 hours after specific therapy has been instituted because of the possibility of secondary plague pneumonia. Purulent discharges should be handled with rubber gloves. Face masks, including

eye protection, are indispensable in caring for patients with pulmonary plague. Nonspecific therapy includes management of shock, dehydration, high fever, and convulsions.<sup>19</sup>

Antibiotic therapy should be started promptly, without awaiting laboratory confirmation, after specimens have been obtained for diagnosis. The drug of choice, intramuscular streptomycin, was first demonstrated in 1948.<sup>25</sup> No drug investigated since then has proved more efficacious or less toxic. It is injected at a dose of 30 mg/kg/d in two<sup>18</sup> or four<sup>19</sup> equal portions for 10 days. Most patients improve rapidly and become afebrile within 3 days. The drug should be used cautiously in pregnant women. The risk of hearing loss and vestibular dysfunction is minimal, but this should be considered in patients with preexisting hearing loss and in the elderly. In such patients, the course could be reduced to 3 days following the disappearance of fever. Renal injury due to streptomycin is rare, but renal function should be monitored.<sup>18</sup> Gentamicin has also been reported to be effective and has the advantage that it can be given intravenously. Mobilization of intramuscular streptomycin may be compromised in hypotensive patients.<sup>24</sup>

Tetracycline is a satisfactory alternative, to be given orally in a daily dose of 2 to 4 g/d in four divided doses for 10 days. This drug is contraindicated in young children, pregnant women, and in patients with renal failure. Tetracycline has also been used to complete a 10-day course after 5 days of intramuscular streptomycin, to minimize the side effects of the latter.<sup>18</sup>

Chloramphenicol is especially good for the treatment of plague meningitis or endophthalmitis because of its excellent penetration in these areas. It is also good in patients with hypotension, in whom intramuscular injections would be poorly absorbed. The drug is given intravenously in the

above cases, but it can also be given orally. The intravenous loading dose is 25 mg/kg, followed by 60 mg/kg/d in four divided doses. After clinical improvement, the drug may be given orally to complete 10 days of therapy. The dose may be reduced to 30 mg/kg/d in four divided doses to lessen the effects of bone marrow suppression, which should be monitored.<sup>18</sup>

Co-trimoxazole, a combination of trimethoprim and sulfamethoxazole, has also been effective in the treatment of plague,<sup>26,27</sup> but it does not appear to be as effective as the aforementioned drugs.

In an asymptomatic person who has had close (ie, within 2 m or less) or face-to-face contact with a patient with pneumonic plague, prophylaxis should be considered. Oral tetracycline (30 mg/kg/d in divided doses every 6 h) is the best choice of drugs.<sup>18,28</sup> If the asymptomatic patient (*a*) cannot tolerate tetracycline, (*b*) is a child, or (*c*) is pregnant, then oral co-trimoxazole is recommended, although it is not optimal therapy for treating active disease. Reliable contacts who are not placed on drug prophylaxis can be instructed to take their temperature twice daily. They are to seek medical attention immediately if they develop fever or respiratory symptoms, including a sore throat, as this could be a manifestation of plaque pharyngitis.<sup>29</sup> In such cases, hospitalization, isolation, and more aggressive therapy are indicated. A 4-fold rise in titer of *Y pestis*-specific antibody when comparing acute and convalescent sera may establish whether actual infection has occurred.<sup>19</sup>

There is a vaccine available for those who might come in contact with plague. Two injections are given initially with an interval of 1 to 3 months between them. Thereafter, it must be given every 6 months.<sup>18</sup> This vaccine is given to members of the U.S. armed forces who are to deploy to regions where plague is endemic (eg, Southeast Asia).

## TULAREMIA

Tularemia (also called deer fly fever and rabbit fever) is a disease caused by the bacterium *Francisella tularensis*, which is usually transmitted to humans by exposure to rabbits and ticks (direct inoculation), but which can also be transmitted via infectious aerosol. Soldiers can be exposed to tularemia while on maneuvers in areas where the disease is prevalent. The typical ulceroglandular form of the disease is characterized by a cutaneous ulcer, regional lymphadenopathy, fever, and

constitutional symptoms; however, tularemia also takes typhoidal, oropharyngeal, and oculoglandular forms.

In 1911, McCoy described a plaguelike illness of rodents while studying plague among California ground squirrels.<sup>30</sup> Subsequently, he recovered the organism from rodents in Tulare County, California<sup>31</sup> (rabbits, now classified zoologically as members of the order Lagomorpha, were at that time classified with the Rodentia). In 1914, Wherry and

Lamb described the first bacteriologically confirmed case of tularemia in a human patient.<sup>32</sup>

### Etiology

*F tularensis* is a small, Gram-negative coccobacillus. It tends to be pleomorphic in culture. On most ordinary culture media, it grows poorly or not at all. It does grow well on glucose cysteine blood agar, thioglycolate broth, and in other media containing enough cysteine (specifically, sulfhydryl groups). Optimal growth occurs at 37°C under aerobic conditions, with small colonies occurring at 24 to 48 hours. The organism is identified on the basis of its growth requirements, morphology, fluorescent staining, and agglutinins with specific antisera.<sup>33</sup>

There are two types of *F tularensis*. Type A is distributed solely in North America and is virulent for humans and rabbits. It is also positive for citrulline ureidase, and it ferments glycerol. Type B is found in North America, Europe, and Asia. It causes a milder form of disease in humans and is avirulent for rabbits. It is negative for citrulline ureidase and does not ferment glycerol.<sup>34</sup>

### Epidemiology

*F tularensis* is distributed throughout the northern hemisphere between 30° and 71° north latitude. It has been recovered from numerous wild and domestic animals. Outbreaks are generally attributed to rabbits, hares, and muskrats. It has also been isolated from fish, amphibians, birds, ticks, deerflies, mud, and water.<sup>33</sup> Large outbreaks of gastroenteritis, which were traced to contaminated water, occurred in Europe during World War II.<sup>35</sup>


Humans most commonly acquire the disease via direct inoculation from a tick bite, or after exposure to the bite, body fluids, tissues, or pelt of an infected animal (eg, a rabbit). *F tularensis* has been reported able to penetrate intact skin but probably enters via small, open skin lesions—or, of course, via the bite. Most rabbit exposure cases have occurred in the winter, while most tick-bite cases occur in the spring or summer.<sup>33</sup>

Tularemia is an occupational hazard for rabbit hunters, butchers, cooks, those who process frozen rabbit meat and pelts, and laboratory technicians.<sup>34</sup> Laboratory workers can acquire the disease via two mechanisms: (1) direct inoculation and (2) aerosolization of *F tularensis* from cultured organisms.

### Clinical Manifestations

The incubation period is usually 3 to 5 days. A skin papule develops at the site of entry and within 2 to 4 days, an ulcer forms. The patient experiences an abrupt onset of fever, chills, headache, malaise, and fatigue. Painful regional lymphadenopathy follows, and buboes can occur. This is the typical ulceroglandular form of tularemia, which occurs in more than 75% of cases. In rabbit-associated cases, the ulcer is located on the patient's hand or fingers in more than 90% of cases (Figure 13-8). In tick-associated ulcers, the lesions tend to occur on the patient's lower extremities, perineum, or trunk. Multiple ulcers may occur in patients who came in contact with many infected animals.<sup>33</sup>

Of rabbit-associated cases of tularemia, 80% to 90% of patients have axillary or epitrochlear adenopathy; of tick-borne cases, 60% to 70% have inguinal or femoral adenopathy. Glandular tularemia occurs in 5% to 15% of cases and is characterized by lymphadenopathy without skin ulceration. In the typhoidal form (approximately 5% of cases), fever, weight loss, and prostration occur without lymphadenopathy. The protean manifestations of tularemia, including oropharyngeal and oculoglandular forms, and the often-negative history make diagnosis difficult.<sup>33</sup>



**OK to put on the Web**

**Fig. 13-8.** This ulceration on the hand is typical of tularemia in a rabbit hunter, one who skinned an infected rabbit and in so doing, infected his hand. He will subsequently develop distal nodes in his axilla that will likely suppurate. He will also develop profound malaise, chills, and fever. Cultures are typically negative, even if special media are used. Diagnosis is usually made on the basis of serologic testing.



Pleuropulmonary complications are not infrequent in tularemia. Pneumonia is seen in 30% to 80% of the typhoidal cases and in 10% to 15% of the ulceroglandular cases. It is characterized by non-productive cough, few findings on physical exam, and ill-defined infiltrates in one or more lobes on chest radiographs.<sup>33</sup>

A nonspecific skin eruption has been reported in about 20% of cases. In a few cases, erythema nodosum and, less commonly, erythema multiforme have been reported. Some patients develop hepatomegaly and elevated liver function test values. Transient renal failure, rhabdomyolysis, pericarditis, peritonitis, meningitis, and osteomyelitis rarely occur.<sup>33</sup>

### Diagnosis

Tularemia may be immediately suspected in the typical case of ulceroglandular tularemia with a characteristic skin lesion, lymphadenopathy, fever, and a history of exposure to rabbits or ticks. The diagnosis is much more difficult when other forms of the disease are seen and when the history is negative, as is frequently the case. *F tularensis* is seldom seen on Gram's stain of sputum, skin ulcerations, or node aspiration. Because the organism does not grow on most ordinary media, cultures are usually negative. Many laboratories are reluctant to grow this organism because infectious aerosols can be created.<sup>33</sup>

Most cases of tularemia are diagnosed serologically. A 4-fold rise in the tube agglutination or microagglutination titer is diagnostic of infection. A single convalescent titer of 1:160 or greater is diagnostic of past or current infection. Titers are usually negative in the first week of illness but are positive in 50% to 70% of cases after 2 weeks of illness. Maximum titers are reached in 4 to 8 weeks and may remain elevated at diagnostic levels for many years.<sup>33</sup>

### Treatment

Before the introduction of streptomycin therapy in 1947, the natural course of tularemia was a prolonged illness with most patients unable to work for the first month of illness; many could work only part time for 3 months after the disease began. Some illnesses lasted 14 to 15 months.<sup>35</sup> Untreated, the mortality of tularemia has been low, cited at 5% to 7%.<sup>36</sup> With antibiotics, mortality is about 2%.<sup>33</sup> If the patient has a serious underlying medical disorder or if treatment is delayed, mortality may rise to 6%.<sup>36</sup>

The drug of choice is streptomycin, administered intramuscularly in an adult dose of 0.5 g (15–20 mg/kg/d in divided doses) twice daily for 7 to 14 days.<sup>33</sup> In those with more severe infections (eg, pneumonic involvement or the typhoidal form), it may be wise to double the dose for the first 2 to 3 days.<sup>34</sup> Most patients' fevers decrease during the first 48 hours. Relapses are uncommon.<sup>35</sup>

Gentamicin is an acceptable alternative to streptomycin. The dose is 3 to 5 mg/kg/d in three divided doses every 8 hours, administered intramuscularly. (This dose may require adjustment depending on the patient's serum creatinine.) Gentamicin is a particularly useful drug when the diagnosis is unknown and additional Gram-negative coverage is desired.<sup>33</sup>

Tetracycline has also been used, but relapses are more common. A loading dose is given: 30 mg/kg, administered orally, followed by 30 mg/kg/d in divided doses for 14 days.<sup>33</sup> Tetracycline should not be given to pregnant or lactating women, young children, or patients with renal or hepatic insufficiency.

A live attenuated vaccine is available. It does not provide complete protection but does ameliorate the course of the disease. Candidates for receiving the vaccine include laboratory workers who are routinely exposed to *F tularensis* and persons whose vocations require repeated exposure to rabbits.<sup>33</sup> Soldiers are not routinely vaccinated against tularemia.

## DIPHTHERIA

Diphtheria, a disease of the pharyngeal mucous membranes, is caused by a toxin produced by the bacterium *Corynebacterium diphtheriae*. Locally, this toxin produces a tough pseudomembrane, which can cause death by asphyxiation. This same toxin can profoundly affect distal targets—especially the heart and nerves. In the United States, infection more commonly causes skin lesions than upper-

respiratory tract involvement.<sup>37</sup>

Early in the 1700s in New England, an epidemic of diphtheria killed 2.5% of the population, including one third of the children. Thereafter, epidemics occurred about every 25 years throughout the 18th and 19th centuries.<sup>4</sup>

In France in 1821, Bretonneau first described the unique clinical characteristics of diphtheria, nam-

ing it for the Greek word for leather, after its tough pseudomembrane. In 1883, Klebs described the bacillus in diphtheritic membranes. In Berlin in 1884, Loeffler first isolated the organism in pure culture. He then reproduced the disease in guinea pigs. He also demonstrated that healthy persons could carry the disease in an asymptomatic fashion. In 1888, Roux and Yersin demonstrated that bacteria-free filtrates of the organism could kill guinea pigs, thus demonstrating the production of a toxin. In 1890, Von Behring showed that antiserum against this toxin protected infected animals from death. Horses were found in 1894 to be the most efficient producers of antiserum.<sup>4</sup>

In 1913, Schick demonstrated that a person's susceptibility to diphtheria could be proven by injecting toxin into his skin. A positive reaction indicated the absence of protective antibodies. In 1923, Ramon found that the toxin could be rendered nontoxic by exposing it to formalin and heat, yet the nontoxic form could induce an antibody response. Between 1930 and 1945, most western countries introduced large-scale childhood immunization against diphtheria.<sup>4</sup>

About 5,700 cases of diphtheria occurred in the U.S. Army from 1942 to 1945. (In comparison, 150,000 cases of diphtheria, with nearly 14,000 deaths, had occurred in 41 states in 1920. And 30,000 cases of diphtheria, with 2,600 deaths, occurred in the entire United States in 1938.) The British Royal Army had recognized that cutaneous diphtheria was common in the desert sores of their troops in Palestine and Egypt during World War I, and this lesson was relearned later with the jungle ulcers of the Pacific and the China, India, and Burma theaters. There was no widespread immunization of U.S. troops during World War II because (a) the number of cases was relatively low and (b) reactions to the vaccine were feared. An important consideration in the decision not to immunize troops routinely was based on the knowledge that injection of diphtheria toxoid would be followed by moderate-to-severe reactions in an appreciable number of cases: 10% of those injected developed incapacitating febrile reactions.<sup>38</sup>

After World War II, during the occupation of Germany, the incidence of nasopharyngeal diphtheria increased tremendously among the civilian population living in bombed-out areas, often in association with overcrowding. As rules against fraternization with the civilian population were relaxed, diphtheria increased among the military population. During 1945, there were 2,240 cases of diphtheria, with 67 deaths, among U.S. troops

in Europe.<sup>38</sup> In April 1946, all susceptible military personnel under the age of 35 were required to be immunized before traveling to the European theater.<sup>39</sup>

## Etiology

*C diphtheriae* is an irregularly staining, pleomorphic, Gram-positive bacillus with clubbed ends. In Loeffler's medium (consisting of a heat-coagulated mixture of 75% serum and 25% broth), it initially outgrows other throat flora. The agar plates should be inspected for growth at 12 to 18 hours. Direct smears from clinical exudates do not demonstrate the characteristic metachromatic granules and "Chinese character" palisading morphology as well as smears that are taken from colonies grown on Loeffler's medium. Tellurite medium inhibits much of the normal throat flora and identifies *C diphtheriae* as gray-black colonies, subdivided into *gravis*, *intermedius*, and *mitis*, based on their hemolytic potential, fermentation reactions, and differing colonial morphology.<sup>4</sup>

*C diphtheriae* is not a very invasive organism, tending to remain in the superficial portion of the skin or mucous membranes. Its major virulence is due to the production of a potent exotoxin that inhibits protein synthesis in mammalian, but not bacterial, cells. The toxin affects all cells in the body but especially the heart, nerves, and kidney. This is an extremely potent toxin, in that one molecule causes cessation of protein synthesis in one cell within several hours. Exotoxin production is dependent on the presence of a lysogenic  $\beta$  phage, which may or may not be present in *C diphtheriae*. Antitoxin can neutralize the toxin before it reaches its target, but antitoxin is useless once the toxin is inside the cell.<sup>4</sup>

## Epidemiology

Humans are the only known reservoir of *C diphtheriae*. The organism can be spread by means of airborne droplets or from infected skin lesions. Most upper respiratory infections occur in the colder months in temperate climates and are associated with overcrowding. Convalescent or healthy carriers and those incubating the disease are most important in spreading the disease.<sup>40</sup>

In endemic conditions, *C diphtheriae* can be found in 3% to 5% of the population,<sup>4</sup> but in North America and Europe, the bacterium has recently become very rare. This is curious because in many parts of the United States, a large proportion of the popula-

tion is susceptible to the toxin. For example, among 183 urban adults in Minnesota, only 26% of men and 21% of women showed an overall protective level of antibody.<sup>41</sup> Despite this, the disease is quite rare in the United States at present.

Person-to-person spread from skin infections is more efficient than from the respiratory tract. Skin infections were once thought to occur primarily in the tropics, but several recent outbreaks have occurred in Europe and North America among alcoholics and poverty-stricken groups.<sup>4,37</sup>

### Clinical Manifestations

The incubation period for *C diphtheriae* is usually 2 to 4 days. Pharyngitis is the most common presentation of diphtheria and is characterized by abrupt onset, fever (usually < 103°F), mild pharyngeal injection, pharyngeal pain, a uniquely fetid breath, and the development of a membrane. This membrane may be on one or both tonsils, but it may also extend to involve the posterior pharynx, soft palate, larynx, and nasopharynx, which indicates more severe disease (Figure 13-9). Initially white, the membrane evolves into a dirty gray color with patches of necrosis. Cervical adenopathy and swelling may cause the patient to have a “bull-neck” appearance, with respiratory stridor. Involvement of the larynx, trachea, and bronchi may produce airway obstruction. This may require intubation and mechanical removal of the membrane, or the patient may rapidly become exhausted and die. Indeed, in the late 19th century, the most common

## OK to put on the Web

**Fig. 13-9.** This febrile patient with pharyngeal diphtheria has erythema, edema, and a gray membrane on the tonsils and posterior pharynx.

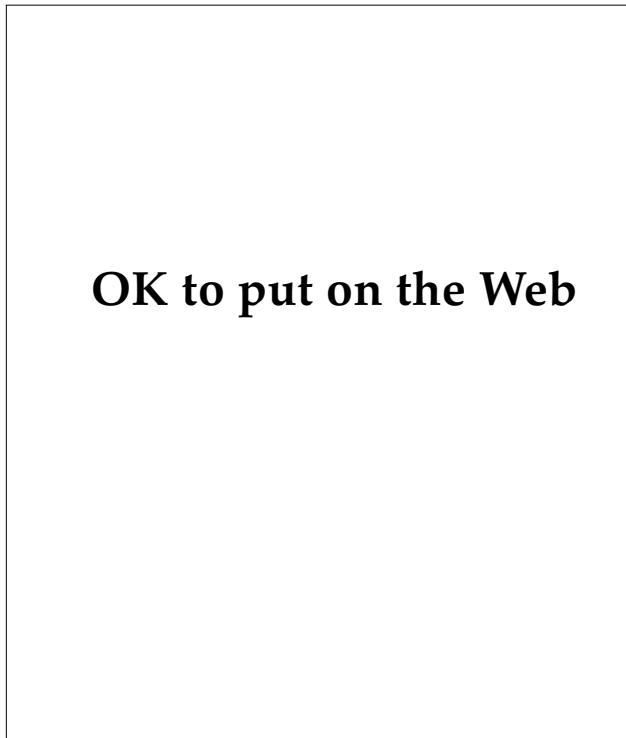
## OK to put on the Web

**Fig. 13-10.** Hemorrhagic pustules on the digits are often indicative of septicemia with *Candida albicans* or Gram-negative organisms. In this patient, *Corynebacterium diphtheriae* was the cause.

cause of death in children was suffocation. *Streptococcus pyogenes* is a common cause of secondary infection, which is usually manifested by a bright red pharynx and fever above 103°F.<sup>4,40</sup>

Cutaneous diphtheria occurs in patients of low socioeconomic status who have poor personal hygiene. Hemorrhagic pustules lead to ulcerations, which are frequently slow to heal (Figures 13-10 and 13-11). They are often infected with *Staphylococcus aureus* and *Streptococcus pyogenes* as well as *C diphtheriae*. Systemic toxicity is unusual, as is heart and nerve involvement.<sup>4</sup> Other sites for diphtheria infection include the ear, the conjunctiva, and the genitalia.<sup>40</sup>

Systemic complications of respiratory diphtheria are secondary to *C diphtheriae*'s production of toxin. The toxin may affect all tissues but is particularly toxic to the heart and nerves. Characteristically, myocarditis (*a*) is noticed when the respiratory disease is improving, usually 1 to 2 weeks after the onset of the disease and (*b*) is responsible for about half the mortality of diphtheria. Clinically significant cardiac abnormalities occur in about 20% of cases.<sup>40</sup> The onset of myocarditis may be acute or gradual. It is important to routinely monitor all diphtheria patients with electrocardiograms. The patient may appear clinically well, but the electrocardiogram may show significant abnormalities. Patients with electrocardiographic evidence of myocarditis have a mortality rate 3- to 4-fold higher than those with normal tracings. Patients with atrioventricular dissociation and left bundle branch block have a mortality of 60% to 90%; survivors may



**Fig. 13-11.** Diphtherial ulcerations characteristically have a purplish rolled border and involve the feet or legs.

have permanent conduction defects. The serum aspartate aminotransferase level closely parallels the intensity of the myocarditis and may be used to follow its course.<sup>4</sup>

Neurological abnormalities occur more commonly in those patients with severe disease. They usually occur late, often a month after the onset of the disease. Cranial nerves are usually affected first. Paralysis of the soft palate and posterior pharyngeal wall may lead to regurgitation of ingested fluids through the nose. Aspiration may also occur. Neurological involvement can affect the peripheral motor nerves, beginning proximally and advancing distally; it especially affects the dorsiflexors of the feet. Involvement varies from weakness to total paralysis.<sup>4</sup> Slow, but complete, recovery of neurological function is the norm.<sup>40</sup>

### Diagnosis

The diagnosis of diphtheria is based on cultural isolation and bacterial identification of the organism with laboratory proof of the toxicogenicity. The laboratory must be notified of the possibility of diphtheria so that the culture specimens may be

placed in appropriate media (ie, tellurite and Loeffler's). An immunofluorescence test can rapidly identify *C diphtheriae*, but it will not establish toxicogenicity. This determination requires either guinea pig inoculation or an agar gel-diffusion technique.<sup>40</sup>

The presence of the pharyngeal membrane, electrocardiographic abnormalities, and cranial nerve palsies all point to the diagnosis of diphtheria. Diagnosis is most difficult in mild cases.<sup>40</sup>

### Treatment

For nearly a century, the cornerstone of treatment has been diphtheria antitoxin. Diphtheria was the first disease in which treatment with specific antibody was shown to be of therapeutic value. Diphtheria antitoxin only neutralizes toxin before it enters the cell, so it is crucial to give it as soon as a presumptive diagnosis is made. Recommendations by the Committee on Infectious Disease by the American Academy of Pediatrics include the following:

- 20,000 to 40,000 units of diphtheria antitoxin for pharyngeal or laryngeal infection of 48 hours' duration,
- 40,000 to 60,000 units for nasopharyngeal disease, and
- 80,000 to 100,000 for extensive disease of 3 or more days' duration or brawny edema of the neck.

Intravenous administration is recommended to rapidly inactivate toxin. Before systemic doses are given, the patient must be tested for sensitivity with 1:10 antitoxin solution (for conjunctival testing) or 1:100 dilution (for intradermal testing). Antitoxin is probably of no value for cutaneous disease, but some authorities use 20,000 to 40,000 units of antitoxin because toxic sequelae have been reported.<sup>37,42</sup>

The diphtheria antitoxin is produced in horses and up to 10% of patients will show some allergy to horse protein. The patient must be questioned about sensitivity to horse protein prior to starting therapy. Epinephrine should be available for immediate administration. If an immediate reaction occurs, the patient should be desensitized with progressively increasing doses of diphtheria antitoxin.<sup>42</sup>

Antibacterial therapy serves three purposes:

1. It shuts down toxin production.
2. It treats the local infection and covers a

possible secondary infection with *Streptococcus pyogenes*.

3. It curtails the spread of the disease to other persons.

Untreated, 1% to 15% of persons recovering from diphtheria become carriers.<sup>40</sup>

The drug of choice in diphtheria for active infection is erythromycin, with an adult dose of 500 mg every 6 hours by mouth for 2 weeks. If the patient cannot swallow, erythromycin may be given intravenously as 30 mg/kg/d in three divided doses every 8 hours. Thrombophlebitis is common with intravenous usage.<sup>40</sup>

Penicillin is usually effective in active diphtheria but is not as effective in carriers as erythromycin. The adult dose of penicillin is 600,000 units (given in the procaine form) administered intramuscularly every 12 hours for 2 weeks. Clindamycin and rifampin have also been effective,<sup>37</sup> but generally only erythromycin and penicillin are recommended.<sup>40</sup>

The patient should be maintained in strict isolation during therapy and should have three consecutive negative cultures at 24-hour intervals at the conclusion of therapy to document eradication of the organism. This is to assess for the carrier state.<sup>4</sup>

Regarding cutaneous diphtheria, the patient should be placed in contact isolation until two cultures of skin lesions, taken at 24-hour intervals, are negative.<sup>42</sup>

The treatment of choice for the carrier state is 7 days of oral erythromycin.<sup>4</sup> However, in one study,<sup>43</sup> 21% of patients treated with erythromycin cultured positive for *C diphtheriae* 2 weeks after the conclu-

sion of therapy. An alternative for adults is 2,400,000 units of benzathine penicillin G, administered intramuscularly in one dose. Carriers should also be cultured for *C diphtheriae* 2 weeks after chemotherapy is concluded.<sup>40</sup>

Supportive care is also important. Airway and cardiac complications may occur early. The membrane can extend into the larynx or break off and occlude the airway, causing breathing difficulties or death by asphyxiation. Many experts recommend intubation or tracheostomy early, particularly if the membrane involves the larynx. This allows access so that the membrane can be mechanically removed. Cardiac monitoring is also important.<sup>4</sup>

### Immunization

Diphtheria is prevented by active immunization using toxoid (formalin-detoxified diphtherial toxin). Preschool immunization is undoubtedly effective, but this protection wanes with age. When toxicogenic diphtheria was common, reinforcement of immunization was also common owing to overcrowding and high carrier rates. In the United States, reinforcement no longer occurs, and large numbers of women and the elderly are now believed to be at risk. Hence, it is now recommended that adults be reimmunized every 10 years.<sup>41</sup> This is done usually with the highly purified tetanus-diphtheria toxoid for adults. Diphtheria immunization is the standard practice in the U.S. Army, and consequently, diphtheria should not be a problem for soldiers; however, diphtheria may well be a problem in local populations where overcrowding and poor hygiene are the rule.

## MENINGOCOCCAL INFECTIONS

Meningococcal infections usually begin with the growth of *Neisseria meningitidis* in the human oropharynx. Occasionally, this proliferation will give rise to systemic infection, usually meningitis and bacteremia (ie, meningococcemia).

In 1805, Vieusseaux described epidemic cerebrospinal fever (meningococcal meningitis) in Geneva. Weichselbaum isolated meningococcal organisms from cerebrospinal fluid in 1887. Healthy persons were noted to be carriers of the organism by Kiefer in 1896 and Albrecht and Ghon in 1901. In 1909, Dopter first recognized serotypes of meningococcus. This laid the basis for Flexner's serum therapy of infection in 1913. Sulfonamides were

found to be effective in 1937. Sulfonamides also eradicated the carrier state and were given as prophylaxis to prevent epidemics in areas of crowded living conditions. Subsequently, other antibiotics were found to be more effective in treating meningococcal infections, and mortality and morbidity declined further. In 1963, the resistance of *N meningitidis* to sulfonamide became a clinically significant problem. This has led to the development of safe and effective vaccines against serogroups A, C, Y, and W-135.<sup>44</sup>

Military records indicate that the U.S. Army has had significant outbreaks of meningococcal disease in the War of 1812, the Mexican War, the Civil War, World War I, and World War II.<sup>5</sup> Hospital admis-

sion rates have always been negligible except during periods of rapid mobilization of new personnel. During World War II, the Board for the Investigation and Control of Influenza and Other Epidemic Diseases in the Army issued an interim report, which contained this statement from its Commission on Meningococcal Meningitis:

[A] field laboratory was set up on September 28, 1942, [at Jefferson Barracks, Missouri]. The purpose of the study [was] to determine if possible the factors influencing the continued occurrence of meningitis at this station.... [The report emphasized] the three factors which aid the occurrence of meningococcal meningitis: crowded quarters, a high meningococcus carrier rate, and the continued addition of susceptibles (unseasoned recruits).<sup>45(p36)</sup>

Of 5,000 cases reported to the Commission on Meningococcal Meningitis during World War II, 67% of the soldiers had been in service less than 3 months and 93% in service less than 1 year.<sup>5</sup>

The incidence of this disease is low compared with that of other respiratory diseases. During World War I, meningococcal disease ranked only 76th as a cause of admission to a hospital; however, 40% of the cases were fatal and the disease ranked sixth as a cause of death.<sup>5</sup> Meningococcal disease is one of the few that can kill a healthy young adult in a matter of hours to a few days.

## Etiology

*N meningitidis* appears as a Gram-negative diplococcus with the adjacent sides flattened. It is oxidase positive and typically metabolizes both glucose and maltose. *N gonorrhoea*, in contrast, does not metabolize maltose.<sup>44</sup>

The organism is fastidious in terms of growth media and conditions. It is aerobic, grows best at temperatures of 35°C to 37°C with a 5% to 10% atmosphere of carbon dioxide, and requires enriched media such as chocolate agar.<sup>44</sup>

Meningococci are surrounded by a polysaccharide capsule and are divided into serogroups on the basis of differences in their capsular polysaccharides. Groups A, B, C, W, and Y cause the most serious disease.<sup>46</sup>

## Epidemiology

There is no known reservoir for meningococci other than humans. The bacteria are usually spread from person to person by respiratory droplets from the

nasopharynx of asymptomatic carriers. Usually this gives rise to immunity that is serospecific for the organism; serious infection will occasionally result.<sup>46</sup>

The carrier rate in the United States is estimated to be 5% to 10%. High carriage rates also consistently develop in military recruits whether or not actual disease has occurred. In this situation, the prevalence of meningococcal carriage has ranged from 40% to 80%. In household contacts of a case of meningococcal meningitis, 17% to 50% are found to carry the same strain as the index case.<sup>47</sup>

Major outbreaks of meningococcal disease have been documented at 7- to 10-year intervals in the United States during the 20th century, and large epidemics (in both the indigenous population and in the military) occurred during World War I, World War II, and the Korean and Vietnam conflicts. Significant outbreaks, usually of the group A serotype, are regularly reported in Africa and South America.<sup>48</sup>

Most epidemic disease in the United States was also caused by the group A serotype until the 1960s.<sup>48</sup> Then group B emerged and has remained the predominant serotype since: the B serotype currently causes more than 50% of the meningococcal meningitis in the United States.<sup>47</sup> Group C is the second-most-common serotype and is especially common in closed populations (eg, military training centers). Increasingly, Groups Y and W-135 are being reported in Western Europe and the United States. Group Y is also commonly associated with pneumonia.<sup>48</sup>

Most meningococcal disease in the United States occurs in two populations: infants and children under the age of 4, and military recruits, but sporadic disease may occur in any age group.<sup>48</sup> The highest frequency of cases is in the winter and early spring; the lowest in the summer.<sup>46</sup>

Several factors predispose to meningococcal disease:

- prior viral respiratory disease,
- complement defects in C5, C6, C7 and C8,<sup>49</sup>
- properdin deficiencies,<sup>50</sup> and
- immunoglobulin deficiencies.<sup>46</sup>

In addition,

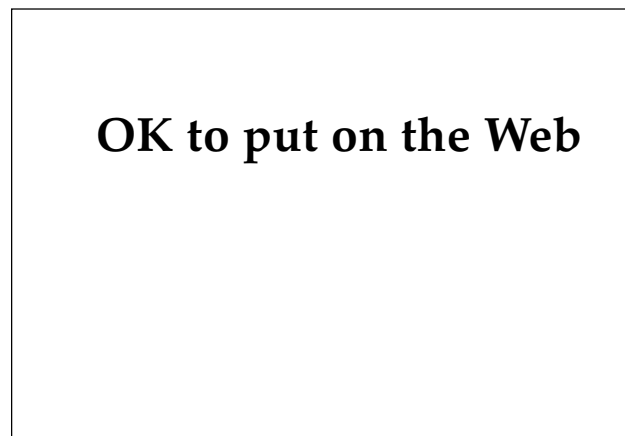- patients with a terminal complement deficiency frequently have recurrent disease in association with low mortality, a high incidence of group-Y disease, and initial infection during the teenage years<sup>49</sup>; and
- properdin deficiency predisposes to fatal disease.<sup>50</sup>

## Clinical Manifestations

The signs and symptoms of meningococcal disease can vary from bacteremia and transient fever to death within a matter of hours. Of patients with meningococcal disease, 90% to 95% present with either meningococemia or meningitis or both. The typical patient has nonspecific prodromal symptoms of headache, cough, and sore throat followed by the sudden development of spiking fever, chills, myalgias, and arthralgias.<sup>46</sup>

Although a transient maculopapular eruption associated with generalized myalgias has been described in meningococcal disease, the more typical eruption is petechial. It may remain sparse or progress to widespread purpura (Figure 13-12). The petechial eruption is manifested as 1- to 2-mm lesions on the trunk, lower extremities, and conjunctivae. They commonly occur on the skin where elastic from underwear or stockings applies pressure to the skin. Petechiae correlate with the extent of thrombocytopenia. Increasing numbers and enlarging lesions indicate progression of the bleeding complications due to disseminated intravascular coagulation.<sup>44</sup>

Postmortem studies<sup>44</sup> have found varying degrees of myocarditis in over 50% of patients who die of meningococcal disease. There may be clinical evidence of heart failure, which cardiac glycosides have successfully reversed.



**Fig. 13-12.** This patient, a young man with meningococemia, developed a stiff neck and fever several days before these purpuric macules developed. These lesions progress by coalescence into angulated, confluent, reticulated patches with central necrosis.

## Fulminant Meningococemia

Fulminant meningococemia, also known as the Waterhouse-Friderichsen syndrome, is meningococemia associated with shock and vasomotor collapse. The onset is abrupt, and profound prostration occurs within hours. Extensive ecchymoses are common. With the onset of shock, the blood pressure falls, mentation decreases, and coma may develop.<sup>46</sup> Global mortality for all meningococcal disease among civilians has remained constant at 10% to 19% for the past few decades, but the mortality for fulminant meningococemia is 40% to 57%.<sup>51</sup> Recovering patients may have extensive sloughing of skin or loss of digits due to gangrene.<sup>46</sup>

## Arthritis–Dermatitis Syndrome

The arthritis–dermatitis syndrome consists of fever, rash, and joint pain (or any combination) in a young, sexually active patient. This syndrome has primarily been caused by *Neisseria gonorrhoea*. However, a recent report of 62 such patients noted blood or synovial cultures, or both, positive for gonococci in 9 and meningococci in 5. This suggests that *N meningitidis* should be given more consideration in the differential diagnosis of arthritis–dermatitis syndrome in the future, although *N gonorrhoea* still predominates.<sup>52</sup>

## Meningitis

The other common form of meningococcal disease is meningitis. This occurs primarily in children aged 6 months to 10 years with symptoms of vomiting, fever, headache, and confusion or lethargy. Typically, the patient has signs of an upper respiratory infection followed by an illness that progresses over a few days. Onset may also be sudden and rapidly progressive. A presumptive diagnosis of meningococcal disease should be made whenever meningitis occurs in association with a petechial or purpuric eruption because this is rarely seen in other infections.<sup>46</sup>

Signs of meningeal irritation are common except in the very young or very old, but focal signs and seizures are less common than in infections due to *Haemophilus influenzae* or pneumococcus. The levels of consciousness are about the same in all three diseases.<sup>44</sup>

## Meningococcal Pneumonia

Meningococcal pneumonia has been recognized for decades. This type of infection usually has no

associated skin findings. It is most commonly caused by group Y. A study of U.S. Air Force recruits reported that a history of cough, chest pain, chills, and previous respiratory infection occurred in more than half of the cases. Rales and fever occurred in almost all patients, and pharyngitis occurred in over 80%. Forty-two percent of the patients had involvement of more than one lobe, and 29% had pleural involvement. Bacteremia is uncommon, so blood cultures are usually not helpful. Transtracheal cultures appear to be the best way of making the diagnosis in meningococcal pneumonia.<sup>53</sup>

### Diagnosis

The diagnosis of meningococcal disease is usually made from positive blood and cerebrospinal fluid cultures. About half of patients with meningococcal disease have positive blood cultures, and 58% to 94% of patients have positive cerebrospinal fluid cultures or positive Gram's stains for Gram-negative diplococci in the cerebrospinal fluid. Several cases of meningococemia with no evidence of meningitis have had positive cerebrospinal fluid cultures. The cerebrospinal fluid in meningococcal meningitis has elevated leukocytes (predominantly neutrophils), low glucose, and elevated protein.<sup>44</sup>

Counterimmunoelectrophoresis and latex agglutination assays may also be helpful, especially early in the course of the disease or when the patient has been treated with antibiotics before cultures were obtained.<sup>46</sup>

### Treatment

The current recommended treatment for meningococcal meningitis, meningococemia, and chronic meningococemia is penicillin G, administered intravenously at a dose ranging from 300,000 units per kg per day to 24 million units per day in divided doses. If the patient is allergic to penicillin, the second drug of choice is chloramphenicol, administered intravenously at a dose of 100 mg/kg/d up to 4 g/d in divided doses. A 7- to 10-day course of therapy is usually adequate.<sup>44</sup>

Penicillin-resistant *N meningitidis* has recently been reported in Europe.<sup>54</sup> These bacteria were sensitive to third-generation cephalosporins such as ceftriaxone and cefotaxime.

In every case of meningococcal disease, the potential for shock should be considered and

treated as necessary. The patient should be placed on respiratory isolation to minimize nosocomial spread.

### Chemoprophylaxis of Carriers

Household contacts of patients with meningococcal disease are 500- to 800-fold more likely to contract the infection than the general population. Military barracks, college dormitories, chronic-care hospitals, and nursery schools also have high-risk populations. These people should receive prophylactic therapy. Hospital personnel and medical staff are not recommended for prophylaxis unless they have had intimate contact with a patient (eg, mouth-to-mouth resuscitation).<sup>44</sup>

Initially, sulfadiazine was highly effective in eradicating the carrier state. However, the bacteria became resistant during the mid-1960s, and it is no longer used unless the meningococcus is known to be sensitive. The current choice for chemoprophylaxis in adults is rifampin, administered orally, 600 mg every 12 hours for four doses. The patient should be forewarned about red urine. Rifampin-resistant meningococci also occur.<sup>44</sup> Minocycline can also be used for prophylaxis but this drug has a high incidence of vertigo and staining of tooth enamel in young children. Recently, a single dose of ceftriaxone (250 mg, administered intramuscularly) was reported as effective in eradicating pharyngeal carriage of group A *N meningitidis*.<sup>55</sup> This could be particularly helpful if other serogroups are sensitive. It would also be especially useful in pregnant women. Ciprofloxacin (250 mg every 12 h for 2 d) has also been effective.<sup>56</sup>

### Vaccines

A quadrivalent vaccine that is effective against serotypes A, C, Y, and W-135 is licensed for use in the United States. It is recommended for high-risk patients with terminal complement defects and functional or anatomical asplenia. It is also recommended for travelers to high-risk areas, such as the meningitis belt in Africa.<sup>46</sup>

There is no effective vaccine for group B meningococcus, the predominant serotype in the United States. Group C is a poor immunogen for children under the age of 2 years—the age group usually affected by this serotype.<sup>44</sup>

Recruits into the U.S. Army are routinely given the quadrivalent vaccine.



## LYME DISEASE

Lyme disease (Lyme borelliosis) is a multisystem infection caused by the spirochete *Borrelia burgdorferi*, which is transmitted by ticks of the genus *Ixodes*. The characteristic skin lesion and earliest manifestation of this disease is erythema chronicum migrans (ECM, also known as erythema migrans). This may be followed by localized involvement of the nervous system, heart, or joints.<sup>57</sup> Some patients recover spontaneously without treatment,<sup>58</sup> but others will have disabling arthritis, neurological impairment, or cardiac conduction abnormalities.

Lyme disease is not only the most commonly reported tick-borne disease in the United States,<sup>58</sup> according to T. E. Woodward, former president of the Armed Forces Epidemiology Board, it is also

potentially of massive importance to both the military and the public in many areas of the continental United States. Many epidemiologists believe that, were it not for the advent of [acquired immunodeficiency syndrome], Lyme disease would now be the nation's primary infectious disease problem. Incidence of the disease is steadily rising in the United States, more commonly among males, and with widespread distribution.<sup>59(p269)</sup>

In Lyme, Connecticut, in 1975, a cluster of patients with presumed juvenile rheumatoid arthritis prompted an investigation by Steere<sup>60</sup> into a disorder now recognized as Lyme disease.<sup>57</sup> The rural setting of the case cluster and the identification of ECM as a feature of the disease suggested that it was passed by an arthropod vector. In 1982, Burgdorfer et al<sup>61</sup> reported the isolation of the causative spirochete, subsequently named *Borrelia burgdorferi*, from an *Ixodes scapularis* tick. In retrospect, it is clear that the borelliosis we now call Lyme disease had been seen and treated earlier<sup>57</sup>:

- In Sweden in 1909, Afzelius<sup>62</sup> described a patient with migrating annular skin lesions presumed to be caused by the tick *Ixodes reduvius*. He coined the term erythema chronicum migrans.
- In 1948, Lennhoff<sup>63</sup> described spirochetes in lesions of ECM. This received little attention.
- In 1951, Hollstrom<sup>64</sup> reported successful treatment of ECM with penicillin, and during the 1950s, ECM was widely treated in Europe with penicillin.

### Epidemiology

In this country, Lyme disease is most prevalent from April to October in the three geographical areas where the tick vector is endemic: in the Northeast, from Maryland to Massachusetts; in the Midwest, in Wisconsin and Minnesota; and in the West, in northern California and Oregon. Lyme disease was reported in 47 states during 1991.<sup>65</sup> Thousands of new cases are estimated to occur every summer in Europe, especially in Germany, Austria, France, Switzerland, and Sweden. In Russia, Lyme disease has been reported from the Baltic to the Pacific. The disease has also been found in Australia, China, and Japan.<sup>57</sup>

Ticks, particularly the genus *Ixodes*, are the major vectors for *Borrelia burgdorferi*. In the United States, *Ixodes scapularis* is the most common vector in the East and Midwest and *I pacificus* in the West; in Europe, the vector is *I ricinus*.<sup>58</sup>

The risk of contracting Lyme disease depends on both the density of the tick population and their degree of infection by *Borrelia*. In the eastern United States, as many as 60% of the *Ixodes scapularis* may be parasitized with *B burgdorferi*; in the West, only 1% to 2% of *I pacificus* are parasitized.<sup>58</sup>

All stages (larva, nymph, adult) of the *Ixodes* tick are capable of passing the disease, the nymphal being the most common. The nymph is so small that it is difficult to recognize (beware the freckle that moves!). The bite is painless and often unnoticed. The tick must remain attached for 1 to 3 days to pass the disease.<sup>58</sup>

Many organisms may serve as a reservoir for *B burgdorferi*, but the most common are the deer and white footed mice. *Ixodes* ticks feed on many species of song birds. Migration of birds infested with these ticks may be one means through which new endemic areas develop. The illness of Lyme disease is not known to occur in wild animals but is well known to occur in domestic animals, including dogs, horses, and cattle.<sup>66</sup>

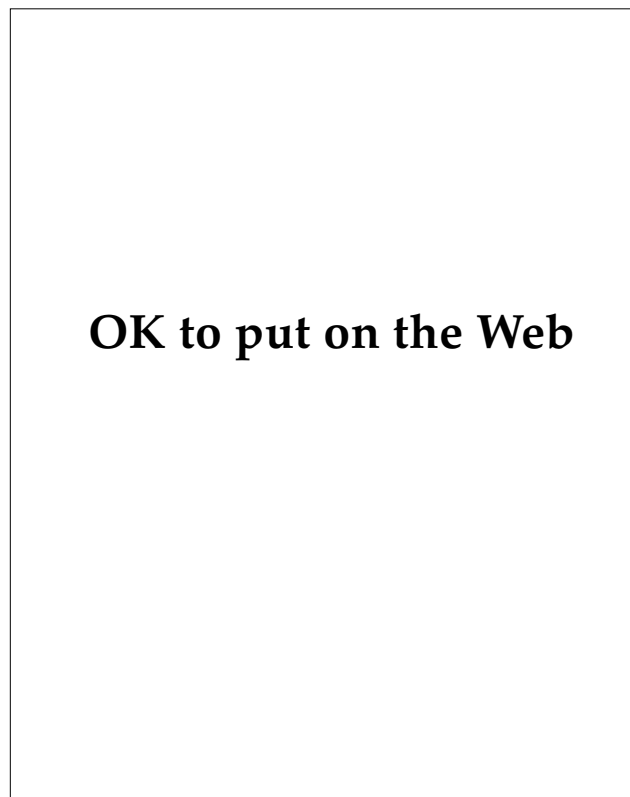
### Clinical Manifestations

Lyme disease has three major clinical stages: (1) localized ECM, (2) disseminated infection, and (3) persistent infection. These stages are arbitrary, and systemic progression from one stage to another is frequently not seen. In fact, a patient may present

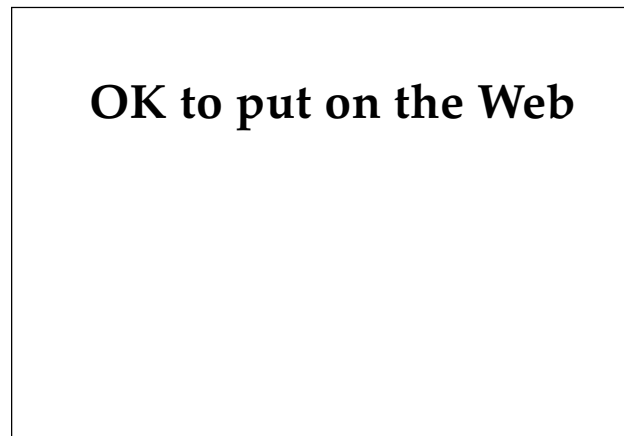
with manifestations of two stages or may present in the third stage without evidence of preceding findings. A revised classification also recognizes three stages of disease but groups them differently: (1) early infection, which encompasses stages 1 and 2; and (2) late infection, encompassing stage 3, which usually begins a year or more after the onset of the disease.<sup>57</sup>

**Early Infection: Stage 1 (Localized Erythema Chronicum Migrans)**

Stage 1 begins 3 to 30 days after the tick bite, which only about one third of patients recall. This stage is characterized by nonspecific constitutional symptoms: fever, chills, malaise, fatigue, arthralgias, and headache. The most prominent manifestation is ECM, which is present in 60% to 83% of adults,<sup>67</sup> but in fewer than 25% of children.<sup>58</sup> ECM typically begins at the site of the tick bite as an erythematous papule that enlarges to an annular configuration (Figure 13-13). The edge may be raised and indurated or flat.



**Fig. 13-13.** This early lesion of erythema chronicum migrans developed 2 weeks after a tick bite to the patient's leg. The site of the tick's attachment is clearly seen in the center of the peripheral erythema.



**Fig. 13-14.** As the annular erythematous border of the eruption of erythema chronicum migrans advances away from the central bite site, very large lesions may develop.

The central portion partially clears, often leaving an erythematous central punctum, but may remain red and indurated or, rarely, become necrotic. These signs suggest a differential diagnosis of brown recluse spider bite, cellulitis, or tularemia (Figure 13-14).<sup>67</sup>

The lesion is frequently found where ticks characteristically feed: the axilla, popliteal fossa, thigh, groin, buttocks, and underwear lines. ECM is usually asymptomatic. The average size of the lesion is 15 cm, but lesions up to 68 cm in diameter are sometimes seen. When left untreated, ECM fades in weeks to months. The average duration is 1 month. With appropriate antibiotic treatment, ECM usually resolves within days.<sup>67</sup>

The histological findings of ECM are relatively nonspecific. Hence, the presence of *B burgdorferi* must be shown on silver stain, labeled-antibody staining, or culture for confirmation of the disorder. Spirochetes are most commonly found in the dermis of the advancing edge of the lesions.<sup>67</sup>

**Early Infection: Stage 2 (Disseminated Infection)**

Within days to weeks of inoculation, the spirochete spreads to many parts of the body. One or more secondary skin lesions may occur and have been reported in 6% to 48% of cases. These secondary lesions tend to be smaller than the originals and to migrate less. However, multiple lesions may become confluent and produce polycyclic or geographical patterns. If untreated they tend to disappear within a month but can persist for more than a year. In patients who are receiving appropriate

therapy, the lesions usually resolve in a few days. The differential diagnosis includes erythema multiforme, erythema annulare centrifugum, secondary syphilis, erythema marginatum, and drug eruption.<sup>67</sup>

In Europe, approximately 1% of cases develop a borrelia lymphocytoma, a form of B-cell pseudolymphoma, also known as Spiegler-Fendt lymphoid hyperplasia. (The borrelia organism has been found on silver stain and also on tissue culture.) This lesion (described as a firm, red, red-brown, or red-purple nodule or plaque) has been known to occur at the time of ECM or as late as 10 months after the tick bite. In children, the lesion tends to develop on the ear's pinna. In adults, it is found on the nipple or areola. This lesion has not been described in the United States.<sup>67</sup>

**Musculoskeletal Manifestations.** Disseminated infection is associated with characteristic symptoms related to involvement of the musculoskeletal system. Musculoskeletal pain is generally migratory, lasting only hours or days at a given location. The patients often appear quite ill with debilitating malaise and fatigue. A mean of 6 months after the onset of the disease (range: 2 wk–2 y), approximately 60% of patients in the United States begin to have brief attacks of asymmetric oligoarthritis in the large joints, especially the knee.<sup>57</sup>

**Neurological Manifestations.** The earliest neurological manifestation is seventh cranial nerve palsy (Bell's palsy). This is seen in 5% of patients with early untreated disease. Gradual resolution over several weeks is generally seen, even in untreated patients. In the United States, approximately 15% of untreated patients develop a spectrum of neurological abnormalities, including lymphocytic meningitis, meningoencephalitis, cranial nerve palsies, peripheral neuritis, and radiculoneuritis.<sup>66</sup>

The most common manifestation of central nervous system Lyme disease is meningitis, which is characterized by fluctuating symptoms mimicking those of aseptic meningitis. Complaints include severe headache (typically occurring in short attacks lasting over hours), irritability, neck stiffness without frank meningism, photophobia, and nausea and vomiting. Examination of the cerebrospinal fluid shows a lymphocytic pleocytosis of a few to a few hundred cells, a normal glucose level, and mild protein elevation. These findings are indistinguishable from those found in aseptic meningitis.<sup>66</sup>

Syndromes involving the peripheral nervous system include peripheral neuritis; sensory radiculitis; sensorimotor radiculoneuritis; and brachial, lumbar, or sacral plexitis. Several neurological manifestations may occur simultaneously or in sequence.

The combination of radiculoneuritis and cerebrospinal fluid pleocytosis, known as Bannwarth's syndrome or tick-borne meningopolyneuritis, is particularly common in Europe and the countries of the former Soviet Union.<sup>66</sup>

**Myocardial Manifestations.** Fewer than 10% of untreated patients develop Lyme carditis, which appears, on average, 2 to 6 weeks after disease onset. Lyme carditis is generally seen in patients with minimal or no symptoms associated with the onset of the infection. Varying degrees of atrioventricular block occur, often changing from minute to minute or hour to hour. Even in untreated patients, these conduction abnormalities are usually brief. High-grade atrioventricular block frequently requires the insertion of a temporary pacemaker. Rarely, a permanent pacemaker may be required.<sup>66</sup>

### **Late Infection: Stage 3 (Persistent Infection)**

Episodes of arthritis, which is the characteristic sign of persistent infection, often become longer during the second and third years of illness. They last months rather than weeks, and chronic arthritis begins during this time. Only one or a few of the large joints are affected. Usually it is the knee.<sup>57</sup>

Acrodermatitis chronica atrophicans is a unique late complication of Lyme disease, which about 10% of patients in Europe develop. However, it has rarely been reported in the United States. Acrodermatitis chronica atrophicans occurs 6 months to 8 years after the initial infection and is more common in elderly patients. An initial, nonspecific, often bilaterally symmetrical, inflammatory state usually occurs on acral sites. Typically, this is an erythematous or violaceous discoloration in doughy or swollen skin with plaques or nodules. The lesions may wax and wane over weeks to years before atrophy occurs. In the atrophic stage, the skin resembles cigarette paper, with prominent blood vessels. There may be hypopigmentation or hyperpigmentation with scaling. The lesion may be associated with pain, pruritus, or paresthesias. Regional lymphadenopathy may be present. *B burgdorferi* may be demonstrated by special stains in these lesions. Early acrodermatitis chronica atrophicans does not resolve spontaneously but may respond to antibiotic therapy. Later lesions may not resolve even with antibiotics, but their progression can usually be halted.<sup>67</sup>

Other skin conditions rarely reported to be associated with *Borrelia* infection include benign lymphocytic infiltrate, morphea, lichen sclerosus et atrophicus, atrophoderma of Pasini and Pierini,

**TABLE 13-1**  
**RECOMMENDATIONS FOR TREATMENT OF ADULTS WITH LYME DISEASE**

Disease Stage	Recommended Treatment
Early infection, Stage 1	Doxycycline 100 mg PO b.i.d. for 10–21 d* Amoxicillin 500 mg PO t.i.d. for 10–21 d Tetracycline 250–500 mg PO q.i.d. for 10–21 d* Cefuroxime axetil 500 mg PO b.i.d. for 20 d Phenoxymethyl penicillin 250–500 mg PO q.i.d. for 10–21 d Erythromycin 250 mg PO q.i.d. for 14–21 d
Neurological manifestations	
Bell's Palsy or mild symptoms	Treat as above, but for at least 3 wk
Other neuropathies, meningitis, encephalitis	Ceftriaxone 2 g, IV, single daily dose for 14–21 d Penicillin G, 20 million U/d, IV, in divided doses for 14–21 d
Lyme carditis	
Mild disease (1st-degree heart block)	Doxycycline 100 mg PO b.i.d. for 14–21 d* Amoxicillin 500 mg PO t.i.d. for 14–21 d
More serious disease	Ceftriaxone 2 g IV single, daily dose for 14–21 d Penicillin G, 20 million U/d, IV, in divided doses for 14–21 d
Lyme arthritis	Doxycycline 100 mg PO b.i.d. for 30 d* Amoxicillin and probenecid, 500 mg of each PO q.i.d. for 30 d Penicillin G, 20 million U/d, IV, in divided doses for 14–21 d Ceftriaxone 2 g, IV, single daily dose for 14–21 d

\*Not recommended for use in pregnant women and children ≤ 8 years of age  
IV: intravenous; PO: by mouth; b.i.d.: twice daily; t.i.d.: three times daily; q.i.d.: four times daily; U: units  
Data sources: (1) Rahn DW, Malawista SE. Lyme disease: Recommendations for diagnosis and treatment. *Ann Int Med.* 1991;114:472–481. (2) Rahn DW, Malawista SE. Lyme disease. *West J Med.* 1991;154:706–714. (3) Nadelman RB, Luger SW, Frank E, et al. Comparison of cefuroxime axetil and doxycycline in the treatment of early Lyme disease. *Ann Int Med.* 1992;117:273–280. (4) Abele DC, Anders KH. The many faces and phases of borreliosis: Lyme disease. *J Am Acad Dermatol.* 1990;23:167–186; 401–410. (5) Rahn DW. Lyme disease: Clinical manifestations, diagnosis, and treatment. *Semin Arthritis Rheum.* 1991;20:201–218.

eosinophilic fasciitis, and progressive facial hemiatrophy. Only a minority of these lesions are believed to be caused by Lyme disease.<sup>67</sup>

In this third stage, the following neurological conditions have occurred: chronic encephalomyelitis, spastic paraparesis, ataxic gait, subtle mental disorders, chronic axonal polyradiculopathy, and dementia.<sup>57</sup>

**Diagnosis**

The diagnosis of Lyme disease is usually made by the observation of a typical ECM lesion and the history of its expanding character. In an endemic area, this is sufficient to treat the patient for Lyme disease. The history of a tick bite is helpful but present in only about one third of cases. More than one half the patients have other acute symptoms, especially fatigue, headache, fever, myalgias, arthralgias, and mildly stiff neck. Serologic tests

are often negative in early disease. Perhaps the best diagnostic test is a biopsy of the expanding edge of the lesion with a modified Steiner stain for organisms, but this is only positive in approximately half the cases.<sup>68</sup> Special cultures have made possible an isolation of 86% from 4-mm punch biopsies of the expanding edge of the lesions of erythema migrans.<sup>69</sup>

With chronic manifestations of Lyme disease, a serology test is much more likely to be helpful. These tests are not standardized and there may be significant variation between laboratories. Additionally, false positives from other conditions, such as syphilis, confuse the picture.<sup>70</sup> A significant percentage of patients in endemic areas may have positive serologic results with no evidence of Lyme disease.<sup>65</sup>

**Treatment**

Current recommended therapy<sup>71,72</sup> for early Lyme disease consists of

1. doxycycline, 100 mg, administered orally twice daily for 10 to 21 days, or
2. amoxicillin, 500 mg, administered orally thrice daily for 10 to 21 days (this is particularly useful when the patient is pregnant).

The duration of therapy depends on the rapidity of the clinical response.<sup>72</sup> Earlier regimens included tetracycline, 250 to 500 mg, administered orally four times daily for 10 to 21 days. Doxycycline is given only twice daily, is better absorbed and tolerated, and penetrates into the cerebrospinal fluid better than tetracycline. The major drawback with doxycycline is that it causes photosensitivity in many patients. It should also not be used in pregnant or lactating women or young children. Phenoxymethylpenicillin, 250 to 500 mg, administered orally four times daily for 10 to 21 days, has largely been supplanted by amoxicillin.<sup>71</sup>

For pregnant patients who are allergic to penicillin, and others who are allergic to or intolerant of

penicillins and tetracyclines, erythromycin remains a good alternative at a dose of 250 mg administered orally four times daily for 10 to 21 days. Erythromycin is less effective than doxycycline or amoxicillin. Cefuroxime axetil, 500 mg administered orally twice daily for 20 days, has been reported<sup>73</sup> to be effective in the treatment of early Lyme disease. Up to 15% of patients with early Lyme disease experience a Jarisch-Herxheimer reaction after the first or second dose of antibiotic therapy, particularly when penicillin or tetracycline is used.<sup>58</sup>

Late skin manifestations should be treated for 30 days. Other systemic late manifestations often require intravenous penicillin G or ceftriaxone. Ceftriaxone is particularly useful because it can be administered parenterally once a day.<sup>66,71</sup> The dose and duration of medications used for therapy are continually being refined. Lyme disease is a difficult one in which to define a cure from therapy, but Table 13-1 contains information that medical officers may find helpful.

## SUMMARY

Cutaneous bacterial infections have had a major impact on wars. Pyodermas (eg, furuncles, abscesses, impetigo, ecthyma), frequently caused by *Staphylococcus aureus* or *Streptococcus pyogenes*, are especially common in soldiers—probably due to poor hygiene in the field and the predisposition to superficial injuries to the skin. Pyodermas may be difficult to treat in deployed soldiers because local skin care and strict antistaphylococcal antibiotic administration can not be assured.

More lethal bacterial infections with cutaneous manifestations (eg, plague, tularemia, diphtheria, meningococcal infections) are fortunately much less common than are the pyodermas. Plague—the great scourge of the Middle Ages—is endemic in certain parts of the world today. (However, plague is a greater threat in its role as a biowarfare weapon.) Meningococcal meningitis was a curse of training bases in the past and still remains a threat today.

Meningococcal disease is one of the few that can kill a healthy young adult in a matter of hours to a few days. Medical officers should view with great seriousness a petechial rash in a recruit who also has a spiking fever, chills, and myalgia and arthralgias. Although penicillin remains the antibiotic of choice, the recent report of penicillin-resistant *Neisseria meningitidis* is worrisome.

Lyme disease, which is caused by a spirochete transmitted by a tick and is endemic to many parts of the continental United States, is becoming a public health problem of increasing importance. The occurrence of erythema chronicum migrans in a patient who goes on to develop protean symptoms involving the central nervous system, heart, and joints is highly suggestive of Lyme disease. In endemic areas, the presence of typical erythema chronicum migrans is sufficient to justify treatment with doxycycline or amoxicillin.

## REFERENCES

1. Pillsbury DM, Livingood CS. Dermatology. In: Havens WP Jr, ed. *Infectious Diseases and General Medicine*. In: Havens WP Jr, Anderson RS, eds. *Internal Medicine in World War II*. Vol 3. Washington, DC: Medical Department, US Army, Office of The Surgeon General; 1968: 607–613.
2. Allen AM. *Skin Diseases in Vietnam, 1965–72*. In: Ognibene AJ, ed. *Internal Medicine in Vietnam*. Vol 1. Washington, DC: Medical Department, US Army, Office of The Surgeon General, and Center of Military History; 1977: 87–102.

3. Cavanaugh DC, Cadigan FC, Williams JE, Marshall JD. Plague. In: Ognibene AJ, Barrett O Jr, eds. *General Medicine and Infectious Diseases*. In: Ognibene AJ, ed. *Internal Medicine in Vietnam*. Vol 2. Washington, DC: Medical Department, US Army, Office of The Surgeon General, and Center of Military History; 1983: 167–197.
4. MacGregor RR. *Corynebacterium diphtheriae*. In: Mandell GL, Douglas RG Jr, Bennett JE, eds. *Principles and Practice of Infectious Disease*. 3rd ed. New York, NY: Churchill Livingstone; 1990: 1574–1587.
5. Phair JJ. Meningococcal meningitis. In: Hoff EC. *Communicable Diseases Transmitted Chiefly Through Respiratory and Alimentary Tracts*. In: Coates JB Jr. *Preventive Medicine in World War II*. Vol 4. Washington, DC: Medical Department, US Army, Office of The Surgeon General; 1958: 191–209.
6. Tasker AN. Diseases of the skin. In: Siler JF, ed. *Communicable and Other Diseases*. In: *The Medical Department of the United States Army in the World War*. Vol 9. Washington, DC: Medical Department, US Army, Office of The Surgeon General; 1928: 551–557.
7. Gonzales A, Schachner LA, Cleary T, et al. Pyoderma in childhood. *Adv Dermatol*. 1989;4:127–141.
8. Coskey RJ, Coskey LA. Diagnosis and treatment of impetigo. *J Am Acad Dermatol*. 1987;17:62–63.
9. Barton LL, Friedman AD. Impetigo: A reassessment of etiology and therapy. *Pediatr Dermatol*. 1987;4:185–188.
10. Adriaans B, Hay R, Drasar B, Robinson D. The infectious aetiology of tropical ulcer—A study of anaerobic bacteria. *Br J Derm*. 1987;116:31–37.
11. Aly R. The pathogenic staphylococci. *Sem Derm*. 1990;9:292–299.
12. Meislin HW, Lerner SA, Graves MH, et al. Cutaneous abscesses: Anaerobic and aerobic bacteriology and outpatient management. *Ann Int Med*. 1977;87:145–149.
13. Dahl M. Strategies for the management of recurrent furunculosis. *South Med J*. 1987;80:352–356.
14. Schwartz M. Cellulitis and superficial infections. In: Mandell GL, Douglas RG Jr, Bennett JE, eds. *Principles and Practices of Infectious Disease*. 3rd ed. New York, NY: Churchill Livingstone; 1990: 796–807.
15. Feingold DS, Hirschmann JV, Leyden JJ. Bacterial infections of the skin. *J Am Acad Dermatol*. 1989;20:469–475.
16. Dobson RL. Antimicrobial therapy for cutaneous infections. *J Am Acad Dermatol*. 1990;22:871–873.
17. McEverdy C. The bubonic plague. *Scientific American*. 1988;258:118–123.
18. Butler T. *Yersinia* species (including plague). In: Mandell GL, Douglas RG Jr, Bennett JE, eds. *Principles and Practice of Infectious Disease*. 3rd ed. New York, NY: Churchill Livingstone; 1990: 1748–1756.
19. Poland JD. Plague. In: Hoeprich PD, Jordan MC, eds. *Infectious Disease*. 4th ed. Philadelphia, Pa: JB Lippincott; 1989: 1296–1306.
20. Ryan CP. Selected arthropod borne diseases—plague, Lyme disease, and babesiosis. *Vet Clin N Amer*. 1987;17:179–194.
21. Weniger BG, Warren AJ, Forseth U, et al. Human bubonic plague transmitted by a domestic cat scratch. *JAMA*. 1984;251:927–928.
22. Werner SB, Weidmer CE, Nelson BC, et al. Primary plague pneumonia contracted from a domestic cat at South Lake Tahoe, California. *JAMA*. 1984;251:929–931.
23. Kaufmann AF, Boyce JM, Martone WJ. Trends in human plague in the United States. *J Infect Dis*. 1980;141:522–524.

24. Welty TK, Grabman J, Kompare E, et al. Plague in Arizona: A spectrum including ecthyma gangrenosum due to plague and plague in pregnancy. *West J Med.* 1985;142:641–646.
25. Karamchandi PV, Rao KS. Streptomycin in human plague. *Lancet.* 1948;1:22.
26. Ai NV, Hanh ND, Dien PV, Le NV. Co-trimoxazole in bubonic plague. *Br Med J.* 1973;4:108–109.
27. Butler T, Levin J, Linh NN, et al. *Yersinia pestis* infection in Vietnam. Part 2. Quantitative blood cultures and detection of endotoxin in the cerebrospinal fluid of patients with meningitis. *J Infect Dis.* 1976;133:493–499.
28. Crook LD, Tempest B. Plague: A clinical review of 27 cases. *Arch Intern Med.* 1992;152:1253–1256.
29. Craven RB, Barnes AM. Plague and tularemia. *Inf Dis Clin North Am.* 1991;5:165–175.
30. McCoy GW. A plague-like disease in rodents. *Public Health Bull.* 1911;43:53–71.
31. McCoy GW, Chapin SW. Further observations on a plague-like disease of rodents with a preliminary note on the causative agent. *J Inf Diseases.* 1912;10:61–72.
32. Wherry WB, Lamb BH. Infection of man with *Bacterium tularensis*. *J Infect Dis.* 1914;1S:331–340.
33. Boyce JM. *Francisella tularensis* (tularemia). In: Mandell GL, Douglas RG Jr, Bennett JE, eds. *Principles and Practice of Infectious Disease*. 3rd ed. New York, NY: Churchill Livingstone; 1990: 1742–1746.
34. Hornick RB. Tularemia. In: Hoeprich PD, Jordan MC, eds. *Infectious Diseases*. 4th ed. Philadelphia, Pa: JB Lippincott; 1989: 1289–1295.
35. Evans EE, Gregory DW, Schaffner W, McGee ZA. Tularemia: A 30-year experience with 88 cases. *Medicine.* 1985;64:251–269.
36. Penn RL, Kinasewitz GT. Factors associated with a poor outcome in tularemia. *Arch Int Med.* 1987;147:265–268.
37. Harnisch JP, Tronca E, Nolan CM, Turck M, Holmes KK. Diphtheria among alcoholic urban adults: A decade of experience in Seattle. *Ann Int Med.* 1989;111:71–82.
38. McGuinness AC. Diphtheria. In: Hoff EC. *Communicable Diseases Transmitted Chiefly Through Respiratory and Alimentary Tracts*. In: Coates JB Jr. *Preventive Medicine in World War II*. Vol 4. Washington, DC: Medical Department, US Army, Office of The Surgeon General; 1958: 167–189.
39. Long AP. The Army immunization program. In: Hoff EC, ed. *Personal Health Measures and Immunization*. Vol 3. In: Coates JB Jr, ed. *Preventive Medicine in World War II*. Washington, DC: Medical Department, US Army, Office of The Surgeon General; 1955: 333.
40. Hoeprich PD. Diphtheria. In: Hoeprich PD, Jordan MC, eds. *Infectious Diseases*. 4th ed. Philadelphia, Pa: JB Lippincott; 1989: 318–326.
41. Karzon DT, Edwards KM. Diphtheria outbreaks in immunized populations. *New Engl J Med.* 1988;318:41–43.
42. American Academy of Pediatrics, Committee on Infectious Diseases. Diphtheria. In: *Report of the Committee on Infectious Diseases*. 22nd ed. Elk Grove, Ill: American Academy of Pediatrics. 1991: 191–195.
43. Miller LW, Bickham S, Jones WL, et al. Diphtheria carriers and the effect of erythromycin therapy. *Antimicrob Agents Chemother.* 1974;6:166–169.
44. Apicella MA. *Neisseria meningitidis*. In: Mandell GL, Douglas RF Jr, Bennett JE, eds. *Principles and Practice of Infectious Diseases*. 3rd ed. New York, NY: Churchill Livingstone; 1990: 1601–1613.

45. Blake FG, Bayne-Jones S. Commission on meningococcal meningitis. In: *Board for the Investigation and Control of Influenza and Other Epidemic Diseases in the Army. Interim Report. May 1942–1943.* In: Woodward TE. *The Armed Forces Epidemiological Board: Its First Fifty Years.* Washington, DC: Center of Excellence in Military Medical Research and Education, Office of The Surgeon General, Walter Reed Army Medical Center; 1990: 36.
46. Griffiss JM. Meningococcal infections. In: Wilson JD, Braunwald E, Isselbacher KJ, et al. *Harrison's Textbook of Medicine.* 12th ed. New York, NY: McGraw-Hill; 1991: 590–593.
47. Broome CV. The carrier state: *Neisseria meningitidis.* *J Antimicrob Chemother.* 1986;18(Suppl A):25–34.
48. Reinartz JA. *Neisseria meningitidis* infections. In: Stein J, ed. *Internal Medicine.* 3rd ed. Boston, Mass: Little, Brown and Co; 1990: 1468–1472.
49. Ross SC, Densen P. Complement deficiency states and infection: Epidemiology, pathogenesis and consequences of neisserial and other infections in an immune deficiency. *Medicine.* 1984;63:243–273.
50. Densen P, Weiler JM, Griffiss JM, Hoffman LG. Familial properdin deficiency and fatal meningococemia: Correction of the bactericidal defect by vaccination. *New Engl J Med.* 1987;316:922–926.
51. Giraud T, Dhainaut JF, Schremmer B, et al. Adult overwhelming meningococcal purpura: A study of 35 cases, 1977–1989. *Arch Intern Med.* 1991;151:310–316.
52. Rompalo AM, Hook EW III, Roberts PL, et al. The acute arthritis–dermatitis syndrome: The changing importance of *Neisseria gonorrhoeae* and *Neisseria meningitidis.* *Arch Intern Med.* 1987;147:281–283.
53. Koppes GM, Ellenbogen C, Gebhart RJ. Group Y meningococcal disease in United States Air Force recruits. *Am J Med.* 1977;62:661–666.
54. Levy J. Antibiotic resistance in Europe and the current use of antibiotics in severe pediatric infections. *Scand J Infect Dis.* 1990;(Suppl)73:23–29.
55. Schwartz B, Al-Ruwais A, A'Ashi J, et al. Comparative efficacy of ceftriaxone and rifampicin in eradicating pharyngeal carriage of group A *Neisseria meningitidis.* *Lancet.* 1988;1:1239–1242.
56. Renkonen O, Sivonen A, Visakorpi R. Effect of ciprofloxacin on carrier rate of *Neisseria meningitidis* in army recruits in Finland. *Antimicrob Agents Chemother.* 1987;31:962–963.
57. Steere AC. Lyme disease. *New Engl J Med.* 1989;321:586–596.
58. Abele DC, Anders KH. The many faces and phases of borreliosis: Lyme disease. *J Am Acad Dermatol.* 1990;23:167–186; 401–410.
59. Woodward TE. *The Armed Forces Epidemiological Board: Its First Fifty Years.* Washington, DC: Center of Excellence in Military Medical Research and Education, Office of The Surgeon General, Walter Reed Army Medical Center; 1990: 269.
60. Steere AC, Malawista SE, Snyderman DR, et al. Lyme arthritis: An epidemic of oligoarticular arthritis in children and adults in three Connecticut communities. *Arthritis Rheum.* 1977;20:7–17.
61. Burgdorfer W, Barbour AG, Hayes SF, et al. Lyme disease—a tick-borne spirochetosis? *Science.* 1982;216:1317–1319.
62. Afzelius A. Report to Verhandling der dermatologischen Gesellschaft zo Stockholm on December 16, 1909. *Arch Dermatol Syph.* 1910;101:405–406.
63. Lennhoff C. Spirochetes in aetiologically obscure diseases. *Acta Derm Venerol* (Stockh). 1948;28:295–324.



64. Hollstrom E. Successful treatment of erythema migrans Afzelius. *Acta Derm Venerol* (Stockh). 1951;31:235–243.
65. Centers for Disease Control and Prevention. Lyme disease—United States 1991–1992. *MMWR*. 1993;42:346–348.
66. Rahn DW. Lyme disease: Clinical manifestations, diagnosis, and treatment. *Semin Arthritis Rheum*. 1991;20:201–218.
67. Malane MS, Grant-Kels JM, Feder HM Jr, Luger SW. Diagnosis of Lyme disease based on dermatologic manifestations. *Ann Int Med*. 1991;114:490–498.
68. Barbour AG. The diagnosis of Lyme disease: Rewards and perils. *Ann Int Med*. 1989;110:501–502.
69. Berger BW, Johnson RC, Kodner C, Coleman L. Cultivation of *Borrelia burgdorferi* from erythema migrans lesions and perilesional skin. *J Clin Microbiol*. 1992;30:359–361.
70. Berg D, Abson KG, Prose NS. The laboratory diagnosis of Lyme disease. *Arch Dermatol*. 1991;127:866–870.
71. Rahn DW, Malawista SE. Lyme disease: Recommendations for diagnosis and treatment. *Ann Int Med*. 1991;114:472–481.
72. Rahn DW, Malawista SE. Lyme disease. *West J Med*. 1991;154:706–714.
73. Nadelman RB, Luger SW, Frank E, et al. Comparison of cefuroxime axetil and doxycycline in the treatment of early Lyme disease. *Ann Int Med*. 1992;117:273–280.

# Chapter 14

## LEPROSY

JAMES W. STEGER, M.D.\* AND TERRY L. BARRETT, M.D.†

---

### INTRODUCTION

#### HISTORY

- Leprosy in Antiquity
- Leprosy in Medieval and Renaissance Europe
- Modern Advances in the Study of Leprosy
- Leprosy in the U.S. Military

#### EPIDEMIOLOGY

#### MICROBIOLOGY

- Natural Reservoirs and Laboratory Transmission
- The Cell Wall
- Molecular Biology and Genetics

#### IMMUNOLOGY

- Humoral Immunity
- Cell-Mediated Immunity
- The Lepromin Test

#### LABORATORY DIAGNOSIS

- The Slit-Skin Examination Technique
- Bacterial Index
- Morphologic Index
- Cutaneous Nerve Biopsy
- Serologic Assays

#### CLINICAL AND HISTOLOGICAL DIAGNOSTIC CRITERIA

#### TREATMENT

- Paucibacillary Leprosy
- Multibacillary Leprosy
- The Most Potent Antileprosy Drugs
- Drug Resistance
- Microbial Persistence
- Promising New Drugs

#### COMPLICATIONS: THE REACTIONAL STATES

- Reversal Reaction
- Erythema Nodosum Leprosum
- Downgrading Reaction
- Lucio's Phenomenon

#### VACCINATION

#### LEPROSY AND ACQUIRED IMMUNODEFICIENCY SYNDROME

#### SUMMARY

\*Captain, Medical Corps, U.S. Navy; Head, Dermatology Clinic, Naval Hospital, San Diego, California 92134-5000

†Captain, Medical Corps, U.S. Navy; Pathology and Dermatopathology Consultant, Naval Hospital, San Diego, California 92134-5000

## INTRODUCTION

Leprosy (also called Hansen's disease) is an infectious disease caused by *Mycobacterium leprae* that affects principally the skin, the peripheral nervous system, and certain other organs. Depending on their immune status, patients with leprosy may present with a wide range of cutaneous and neurological signs and symptoms. These signs and symptoms have been grouped together to delineate leprosy into a spectrum of clinical forms or stages whose complications and therapies differ from one another. Thus, it is important at the outset to be aware of these clinical forms.

The simplest classification scheme is based on the relative immune status of the host. The form found in hosts with the highest immunity is known as *tuberculoid* leprosy; with the lowest immunity, *lepromatous* leprosy; and with intermediate immunity, *borderline* leprosy. Unfortunately, there are unstable transition forms between these groupings and very stable polar forms at the high and low ends of the immune state. Consequently, leprosy is now subdivided into seven stages of disease, arranged from lowest to highest immune status of the host:

- lepromatous lepromatous polar type (LLp),
- lepromatous lepromatous subpolar type (LLs),
- borderline lepromatous type (BL),
- borderline borderline type (BB),
- borderline tuberculoid type (BT),
- tuberculoid tuberculoid subpolar type (TTs), and
- tuberculoid tuberculoid polar type (TTp).

The polar forms never change to any other form, whereas all the remaining forms can change from

one form to the next. These transitional forms arise through fluctuations in the host's immune system. Transitions from a higher to a lower immune status are reactional states known as *downgrading* reactions, the converse as *reversal* reactions. Both types of reactional states complicate therapy. An infected patient whose clinical presentation (usually a hypopigmented patch) is not diagnostic is said to have *indeterminate* leprosy. In time, one of four such patients will develop lesions characteristic of one of the other forms of leprosy; the other three patients will clear spontaneously. Where no skin lesions are present but nerve damage has occurred, the disease is designated *primary neuritic* leprosy.

Although it was epidemic during the Middle Ages, today leprosy is acquired primarily by susceptible individuals and then only through prolonged contact (months to years) with infected individuals. In general, oriental and black people tend to be much more susceptible to the disease than white people.

Individuals infected with the lepromatous forms of the disease, whose immune status is low and who harbor enormous bacterial loads, particularly in their nasal mucosa, are the most dangerous sources of infection to susceptible troops. Therefore, military interest centers chiefly on the chance encounter with such patients in those countries where the prevalence of lepromatous leprosy is high, and on those troops from susceptible racial backgrounds. Because even mention of the word leprosy may elicit irrational and hysterical responses based on fear and ignorance, it behooves unit commanders and medical personnel to be well informed on the low infectiousness of the disease and to educate their troops accordingly.

## HISTORY

Perhaps because leprosy is of ancient origin and was feared and loathed, historical records abound that describe diseases that (a) are strikingly similar to the disease we know as leprosy, albeit by different names, and (b) diseases that may have been called leprosy then but clearly are not the disease we know today. The following brief account attempts to tease apart these sometimes intertwined historical trails. For example, from the time of Hammurabi (1958–1916 BC), the King of Babel on the

Euphrates, a disease was known that resembles what we call leprosy, and was recognized as being related to human association.<sup>1</sup> On the other hand, it seems clear that the disease called leprosy in the Bible could not have been the disease we call leprosy today.

Unless otherwise specified, the following general historical review of leprosy is translated from the German and adapted for this chapter (by JWS) from Klingmüller's comprehensive history of lep-

rosy,<sup>1</sup> which was published in 1930 and is difficult to obtain in the United States.

The review of leprosy in military history prior to the Vietnam conflict has been abridged and adapted from the official history of the U.S. Army Medical Department in World War II.<sup>2</sup> This unique source documents the military significance of and experience with leprosy through World War II.

## Leprosy in Antiquity

### Egypt

Egypt is generally agreed to be the land where the earliest history of leprosy can be found. In the Berlin Papyrus from the time of Rhamses II (1333 BC) is a letter concerning the treatment of leprosy, which concerns the time of Pharaoh Sapti 5th who, according to Brugsch, lived about 4266 BC. The German dermatologist, Iwan Bloch, a student of Unna, has determined that the character “aat” in the Ebers Papyrus was a designation for leprosy—on account of hyperaesthesia, hair loss, and sudden collapse of the nose. (However, his findings were contradicted by Richter.) Around 1700 BC, the Hyskos, a seminomadic tribe out of Asia Minor, invaded Egypt, resulting in a mixing of Egyptians and Asians. This may be important as it is believed that leprosy arose in Asia.<sup>1</sup>

The Exodus of the Jews from Egypt occurred around 1440 BC under Amenhotep II, or in the 16th century under Thothmes IV (according to Conder). At the time of the Exodus, according to the Egyptian historian Manetho (circa 300 BC), about 80,000 Jews were affected with leprosy. However, they lived in Goshen on the east side of the Nile, and did not mix with the Egyptians to any great extent—and later departed for Canaan. In the 6th to 5th centuries BC, the Persians ruled Egypt, resulting in a great mixing of populations. Around 250 BC, the Septuigent, a Greek translation of the Hebrew Bible, was started by Hebrew scholars. They translated the Hebrew word *Zaraath* as *Lepra*, which, according to the Greek physician Hippocrates, was the name given to a scaly skin condition. Hopes that the skulls and bones of Egyptian mummies might reveal earlier evidence of leprosy have not been fulfilled; the earliest pathological changes suggestive of leprosy date from the 2nd century BC.<sup>1</sup>

### In the Bible

ט[׳ר״ץ]x; , pronounced “tzah-rah-AHT,” and usually transliterated as *zaraath*, is the Hebrew word found in the *Tanakh* (the Hebrew Bible, ie, Old Testament) that has traditionally been translated as “leprosy” in many editions of the Bible. In the Torah, as described in Leviticus, the Third Book of Moses, ט[׳ר״ץ]x; is (a) diagnosed by the priests and (b) associated with periods of quarantine, both suggesting that its presence is due to the wrath of God. This may be the origin of the irrational horror of the disease and the ostracism of afflicted individuals.

The clinical characteristics of ט[׳ר״ץ]x; as revealed in the Scriptures of Leviticus 13 include the triad of (1) a white or shiny patch in the skin, (2) depression of the skin [*also translated as deeper than the skin—JWS*], and (3) whitening of the hair. However, the account seems not to have mentioned hyperpigmentation, alteration in cutaneous sensation, facial disfigurement, or loss of eyebrows; and no blindness, muscular palsies, or hideous mutilations.

Lastly, and most interestingly: if the condition involves the entire cutaneous surface, the individual is to be pronounced “clean” (ie, not infectious), and no longer to be excluded from the community:

If ט[׳ר״ץ]x; breaks out all over his skin and, so far as the priest can see, it covers all the skin of the infected person from head to foot, the priest is to examine him, and if the ט[׳ר״ץ]x; has covered his whole body, he shall pronounce that person clean.<sup>3</sup> [*Hebrew word ט[׳ר״ץ]x; not translated—JWS*]

Obviously, then, ט[׳ר״ץ]x; and leprosy cannot be equated. No leper with disease from head to toe would ever be clean according to Jewish law.

Interestingly, in the New Testament when Jesus encountered the man full of “leprosy” in the Gospel According to Luke, Chapter 5, and cleansed him of his leprosy, Jesus told him to go and show himself to the priest and make an offering for his cleansing, just as Moses had commanded regarding ט[׳ר״ץ]x; . [*Similarly, for the 10 lepers in the Gospel According to Luke, Chapter 17—JWS*] Consequently, it is obvious that the leprosy of the Bible is something quite different from Hansen’s disease. In fact, there is no known dermatologic disease that incorporates all its features. Modern interpreters consider the term to represent a variety of infections or skin inflammations. In Biblical context, it appears to be a sign of God’s displeasure.<sup>4</sup>

### Persia

Concerning Persia in the 6th century BC, Herodotus (484?–425? BC) writes in *The History*, Book 1, 138:

If a citizen has “leprae” or a white rash, he should not go into the city or into a group of people, but becomes a stranger, and is to be driven out of the land.<sup>1(p6)</sup>

It has not been shown that the conquests of Darius I (521–486 BC) and Xerxes I (486–465 BC) spread leprosy to the western parts of Asia minor, the Grecian Islands, or Greece proper, even though Xerxes’ troops and logistic supports numbered over 1 million individuals.<sup>1</sup>

### Greece

The contact of the Greeks with the eastern populaces through the Persian wars, and especially through the far-reaching (to India) campaigns of Alexander the Great (336–323 BC) and the subsequent campaigns of Diadochen (323–301 BC), surely have contributed to the spread of leprosy. The Greek writer Ktesias from Persica described in the 5th century BC that leprosy had “ruled” in Persia.<sup>1</sup>

The Phoenicians operated as agents between Asia and Europe in the spread of leprosy. In the 7th through the 6th centuries BC, they carried their trade from Asia to the French and English coasts.

In Greece up to the time of Hippocrates (460–377 BC), leprosy was essentially unknown. The term “leprae” was used to describe scaly rashes more on the order of psoriasis or eczema. It appears that Aristotle (384–322 BC), under the name Satyriasis, possibly described true leprosy (*de generat. animal* IV, 3).<sup>1</sup> The earliest description of a disease that is unmistakably leprosy was by Aretaeus, in Greece, about AD 150. He called the disease elephantiasis.<sup>5</sup> Plutarch (AD 46?–120?) (*Sympos* VIII, Qu IX) quoted the Greek physician Philon as stating that none of the ancient Greek physicians had given any information about elephantiasis. In Persian references and through Persian military campaigns, leprosy could have been transmitted from the peoples of Persia, Syria, or Phoenicia to Greece.<sup>1</sup>

The oldest Alexandrian physician (3rd century), Galen, brings us a detailed description of leprosy and notes the following symptoms (Galen, *introductio cap. XIII*)<sup>1</sup>:

- the superficial changes in the skin from inflammation and ulcers/abscess/boils as leprosy,
- the thickening of the joints and other parts of the body as elephantiasis,
- the changes on the face as “leontiasis,”
- the loss of hair as ophiasis and alopecia, and
- mutilations.

### The Roman Empire

It was during the time of Asklepiades, a contemporary of Pompey (106–48 BC), according to Plutarch (AD 46?–120?), (*Sympos*. VIII, 9), that leprosy first made its appearance in Italy. However, it appeared only rarely in the 1st century BC in Rome. But it was at this time that the nomenclature became clear: what one called lepra (Greek) in the Hippocratic sense was a scaly skin disease, and what one called elephantiasis (Greek) was true leprosy in today’s sense. In 95 BC Lucretius wrote of an “elephant disease” (*elephas morbus*) that raged on the banks of the Nile. The notion that this was leprosy is rendered more probable by a passage in Celsus concerning “elephantiasis.” Around the time of Christ, characteristic descriptions of leprosy are found. Aulus Cornelius Celsus, a contemporary of Tiberius (AD 14–37) wrote:

Totally unknown in Italy, but very frequent in a few other lands is the disease which the Greeks call elephantiasis. It is heard to be chronic. The whole body is so afflicted with it, that even the bones are afflicted. The surface of the body shows many spots and ulcers/abscesses which are closest to red in color, but progressively assume a black color. The skin is thick in many places, in other areas it is thin, in a few hard, in a few soft, and somewhat rough from scaling, thereby the body appearing emaciated, while, on the contrary, the face, the lower extremities and the feet are swollen. Where the disease has been present

for a long time, there is a disappearance of the fingers of the hands and the toes of the feet in the swelling, and a slight fever occurs all of which causes great sorrow.<sup>1(p8)</sup>

At a later time, Cajus Plinius Secundus (AD 23–39) in *Natural History* XXVI, 5 and XX, 14 writes: “We have already said that the elephantiasis had not arrived in Italy before the time of Pompey the Great.”<sup>1(p8)</sup> Caelius Aurelianus (*morb. chron* IV, cap 1), who lived in Rome, was a founder of the method school, a contemporary of Pliny the Elder, and the first to extensively deal with the treatment of lepra. Philumenus (circa AD 150) extensively described the treatment of elephantiasis: baths of albula and nepete; mineral springs in Macedonia, Thrace, Crete, and Anchialus; and steam baths followed by cold sulfur application or alum baths, all of which shorten the healing, “if the skin is as repulsive as that of a snake!”<sup>1(p8)</sup>

In the 2nd century the campaigns of the Roman emperors, especially towards Asia (eg, Trajan against the Parthians in AD 114–116, his campaign to the Tigris River and the Persian Gulf) resulted in the greater possibility of a spread of leprosy to Italy and Europe. And so it appears that in this time, courtesy of the Roman legions’ traveling, leprosy reached Spain, France, Germany, and especially Lombardy, and continued to spread throughout the Roman Empire.<sup>1</sup>

### India

A larger outbreak of leprosy appeared to have occurred in India. In the 14th and 15th centuries AD, the Rig Veda samhita used the term *kushtah* for a disease that was undoubtedly leprosy, a term that is still used today in India for the disease. In the interpretations of the text, there is the suggestion of references back to the 7th century AD. In the 4th century AD in the canonical texts, similar writings are found. In the Ayurveda (2000–500 BC), various treatments—including chaulmoogra oil—were suggested for the treatment of leproslike conditions. More recent investigations have found that *kushtah* was first described about 600 BC in the Susruth Samhita. Treatment at that time was also undertaken with chaulmoogra oil, a folk remedy that has had continued use up to the present day.<sup>5</sup>

### China

Leprosy has definitely been present in China for at least 2,000 years. The first reported incidence of leprosy in China was 1100 BC, and 200 to 300 years before Confucius (5th century BC), leprosy was thought to be a punishment for sins. In the last book of medical science of Su-wen, written toward the end of the Chon dynasty (1130–250 BC), the disease *lei-fon* is described as having (1) loss of sensation, (2) destruction of the nasal structures, and (3) discoloration, ulcers, or abscesses of the skin.<sup>6</sup>

Recently, an ancient book from the Ch’in dynasty (221–206 BC), the *Bamboo Book*, has been excavated from the tomb of magistrate Hsi in Yun Meng, Hupeh. In it, leprosy is well described:

Cha went to see Bing and said to Bing, "I think you have Leprosy (Li)." Bing replied, "At age three I was sick, my eyebrows were swollen and nobody knew what the sickness was. I was directed to see a doctor, Ting. The doctor said, you don't have eyebrows because they are rootless. Your nostril is destroyed; you cannot sneeze on irritation; your legs are halt because one of them burst, and your hands have no hair." He asked Bing to shout and the voice was hoarse. That is leprosy.<sup>6(p291)</sup>

This historically significant document, having been excavated and dated, represents original material rather than a redacted version from subsequent generations.<sup>6</sup>

Chang Chung-ching (AD 150–219), often referred to as the Hippocrates of China, wrote in his classic book, *Shang Han Lun (Essay on Typhoid)* that a person having leprosy has very little hair and eyebrows left, and his body is full of sores that have a fishy and stinking smell.<sup>6</sup>

In Chou-hau-hong, during the Chin Dynasty (AD 265–419), a disease with the name of lai-ping, whose manifestations included a loss of sensation and formication was described by Kwo-Hon (AD 281–361).<sup>1</sup> He described a second man whose leprosy was cured with pine cones. In another work, Kwo-Hon describes a military official named Tsui Yen who was suddenly afflicted with leprosy:

His eyes grew dim, he could not distinguish either objects or men. The eyebrows and hair fell off, the nasal bridge dropped and the skin was covered with sores.<sup>6(p294)</sup>

The man was later cured with saponin and rhubarb solution. Pine cones and saponin are still in the Chinese pharmacopoeia for leprosy and ulcers, respectively.<sup>6</sup>

Later in China, Pin-yüan-hou-lun (AD 589–617), detailed the signs of leprosy so clearly that no confusion with any other disease is possible: anesthesia, paresthesia, pains in the joints, insensibility to needle stick, anhidrosis, loss of fingers, cutaneous nodules, loss of the eyebrows, and roughness of the voice.<sup>1</sup>

Chaulmoogra oil, obtained from the seed of a coconut-shaped fruit of the *Hydnocarpus* tree, native to Cambodia, was probably imported into China in the Southern Sung period (1127–1278). Its value in the treatment of leprosy was well known, but required careful monitoring for side effects since it was poisonous to the blood and the eyes. One herbalist gives directions for the preparation of the oil as follows:

Take three cattles of the seeds, discard those that have turned yellow, remove the husks and grind into a fine powder. Pack in earthenware jar and seal up tightly. Put the jar into a pot of boiling water and seal the pot so that no steam can escape. Boil until the oil assumes a black and tar-like appearance. It is administered in the following way:

Chaulmoogra oil	1 ounce
Saphoro flavescens	3 ounces

Mix into a paste with wine and make into pills the size of a stercula seed. *Sig:* Take 50 pills with hot wine before meals.<sup>6(p301)</sup>

## Japan

Written about the year AD 702 in a place called Reino-gige, in the Commentary of Taiho-rei, the second-oldest Japanese law book, the following comments are found about leprosy:

There is loss of the eyebrows, destruction of the nasal structures, hoarseness, mutilation of the joints; one must not share a bed with such a diseased person, because the disease can be communicated to the next person.<sup>1(p4)</sup>

Leprosy was apparently endemic in Japan for 1,000 years. In AD 1554, the Portuguese Louis Almeida established a hospital in Funai, Japan, for syphilis and leprosy. The oldest leprosy colony, however, was apparently established in Nara, near Kyoto, perhaps going back to the time of Emperor Gwyo (AD 718–740), who, according to legend, washed 1,000 lepers with his royal hands, for chastening. The famous Chinese monk Chien Chen (688–763) became a medical missionary to Japan, and while in Nara, he became medical consultant to the Empress Komyo, whose own tragic life led her to take a major interest in the care of patients with leprosy. Chien Chen spent 10 years in Japan and wrote many medical books. He is worshiped as *Kanjin*, the ancestor of medicine.<sup>6</sup> In 740, the Empress Komyo herself provided for the nursing of leprosy patients at the time of the blossoming of Buddhism in Japan, by increasing the hospitals for lepers, which were founded by Prince Shotokautai (born 621). It was at this time that the Chinese medical book, *Byogenkoronsenkin-ho*, was carried to Japan, in which leprosy with its characteristic signs was described, which was thought to be due to unhealthy air and an insect that penetrated human flesh. That lepers may go blind was not mentioned. In 833, in *Reisikai*, a commentary on the law mentioned that leprosy was transmitted to men who were in the vicinity of the afflicted. This insight was apparently lost when the Buddhist priests taught that leprosy was a punishment for sins committed in a previous life. The lepers then suffered pitifully as beggars near the temples.<sup>1</sup>

## Leprosy in Medieval and Renaissance Europe

Because of the increase in the number of cases and the horror with which leprosy was regarded during the Middle Ages, it was not a diagnosis to be taken lightly. Nonetheless, it was not only physicians but also laymen who made the diagnosis. In general, diagnosis was conservative, tending to recognize only the most severely affected individuals.

As early as 757, Frankish law permitted divorce because of leprosy. In 1179, the Lateran Council decreed that lepers could not share church, cemetery, or even social life with the healthy. By 1220, it was a civil crime for a leper to live with a nonafflicted individual. The afflicted were officially cut off from the rest of Medieval society. In some parts of Europe they were considered

legally dead and the leper's heirs could inherit his property while he yet lived.<sup>7</sup>

Because leprosy had spread during the Crusades, the Order of Sacred Lazarus was founded in 1048 in Palestine, under Pope Damasius II. The head of the order was frequently afflicted with leprosy himself. By the 13th century, many branches had been established throughout the whole of Europe. Their monasteries were asylums for lepers, where they could remain until they died. Some 19,000 leprosaria were present in Europe by this time—a testimony to the rampant spread of leprosy during the Middle Ages.<sup>1</sup>

Theodoric of Cervia, who was both a bishop and a surgeon (1205–1298), drawing on the earlier medical writings of the Arabic physician Avicenna, described two types of leprosy: one that was self-limited and probably corresponds to tuberculoid leprosy; the other, to lepromatous leprosy. His description of the latter is unmistakable:

the face becomes puffy, the hairs of the eyebrows and eyelids thin out,... nodules are felt in the skin,... the voice wavers, tending to lower,... patients are pricked in the ankle bone and are unaware, they feel little, similarly on the leg.<sup>5(p301)</sup>

Whereas early in the Medieval period leprosy was less precisely recognized and was equated with heresy, as the diagnosis became more widely and reliably recognized, the social stigmata changed to that reflecting worldliness of the part of the victim: in particular, pride, avarice, gluttony, sexual promiscuity, and neglect of spiritual matters. This change in attitude is reflected in the literature of the period, for example, Dante's *Inferno* and Hartmann von Aue's famous middle-high-German poem "*Der Arme Heinrich*" (The Lamentable Henry).<sup>7</sup>

With time, there was some easing of the social situation for the patient during the Middle Ages. John of Gaddesden in the 14th century counseled that no man be judged a "leper" until his face had been destroyed by the disease. This advice was generally followed, since the diagnosis brought severe legal and religious sanctions. Indeed, seen as the outward figure of an unclean soul, leprosy evoked a special church ceremony in which the "leper" was enjoined to be "dead unto the world, but alive unto Christ."<sup>8(p347)</sup> Later, the Church decreed that leprosy was not grounds for divorce or dissolution of marriage, and the remarriage could not take place until the death of the infected person.<sup>8</sup>

However, within another century leprosy was clearly declining in England, while the population was greatly increasing. Only half of the available hospital spaces were still being used and many of the leprosaria began to be converted to other uses. Indeed, by the time of the Black Death (1347–1350), which killed one third of the population of Europe, many of the leprosaria were empty on the continent as well. In Scandinavia, where the population density was much less, leprosy persisted longer.<sup>8</sup>

Any doubts that the disease in the Middle Ages was leprosy have been dispelled by the paleopathologic stud-

ies of Møller-Christensen: he discovered, in Naestved, Denmark, the burial ground of a "lazar" hospital that existed between the years 1250 and 1550. He was able to demonstrate classical changes of lepromatous leprosy in many of the skulls and bones of 202 skeletons that were excavated at this Medieval leprosarium.<sup>5</sup> Characteristic was the destruction of the alveolar process of the maxilla, the loss of central incisors and canine teeth, erosion of the hard palate, and loss of the nasal bone.<sup>8</sup> Similar changes have been noted in skeletons from England and from Aachen, Germany.<sup>7</sup>

By the time of Fracastorius (1478–1553) during the Renaissance, leprosy had waned considerably. However, the rise of syphilis following the discovery of the New World led to the belief in the 16th century that leprosy and syphilis ("the French sickness") were the same disease. Using all the pertinent classical texts, original manuscripts, and the medical works of Pliny, Galen, and Avicenna, Fracastorius critically examined the language and descriptions of leprosy. He noted that the disease known as leprosy was described by the Greeks under the term "elephantiasis," and that the term "lepra" corresponded to milder, no-longer-recognizable conditions. He additionally distinguished the cutaneous nodules of leprosy from syphilis, and emphasized the slow progression of leprosy in contrast to syphilis. Whereas syphilis was considered a venereal disease, leprosy was recognized by Fracastorius to be contagious, transmitted by contact with lesions, by fomites, and by the breath of patients.<sup>9</sup>

Leprosy was first introduced in North America in the middle of the 16th century by immigrants from Europe. Later, slaves from Africa imported leprosy to America and Brazil.<sup>10</sup>

## Modern Advances in the Study of Leprosy

One of the greatest strides in the knowledge of leprosy came in 1874, when G. Armave Hansen first described the microorganisms present in nodular leprosy. In 1884, he defined the morphologic characteristics of *M leprae* using a methyl violet staining method, describing rodlike organisms, chains of coccoid forms, and the clumping of organisms that is now called *globi*. Paul Gerson Unna later confirmed this peculiar clumping.<sup>11</sup>

As early as 1884, Patrick Manson described a method of diagnosing leprosy. His suggestion was to squeeze the nodule and then pierce it. Exudate obtained was spread on cover slips or slides. It was dried, stained, and then examined microscopically for organisms. But the major breakthrough for microscopical examination was made by Wade in 1913, when he introduced the skin-slit procedure.

The enigmatic granularity of bacilli frequently seen with acid-fast staining was finally explained by Rees and Valentine in 1962, when they demonstrated by electron micrographs that the irregular acid-fast staining corresponded with degenerative changes in *M leprae*.<sup>11</sup>

The first major therapeutic breakthrough in leprosy came in the 1940s, when sulfones were shown to be

effective against the leprosy bacillus. In 1941, Dr. Guy Faget of Carville, Louisiana, began to use promin, and by 1943 began to report its beneficial effects.<sup>12</sup>

The first successful cultivation of *M leprae* occurred in 1960, when Dr. Charles Shepard of the Centers for Disease Control in Atlanta, Georgia, reported its propagation in the footpad of the mouse. Dr. Waldemar Kirchheimer of Carville, and Dr. Eleanor Storrs of the Gulf South Research Institute in New Iberia, Louisiana, demonstrated an animal model of leprosy in the nine-banded armadillo in 1968. These two advances have had a major impact in the basic understanding of leprosy and have led to a wide range of scientific studies on the nature of and the treatment of the disease.<sup>10</sup>

### Leprosy in the U.S. Military

The importance of leprosy as a military problem is limited by certain of its epidemiological characteristics. The most pertinent of these are (a) geographical distribution, (b) low prevalence rates even in areas in which the disease is considered to be highly endemic, and (c) relatively low attack rates in adult life.<sup>2</sup>

For practical purposes, leprosy may be considered a disease of the tropics and subtropics. Every country with high prevalence rates is situated within the tropics, and such tropical countries are inhabited mainly by backward people living in overcrowded huts under conditions favorable to the spread of the disease.

Every country with a very high leprosy rate (ie, 3 or more cases per 1,000 population) is situated in the tropics. In practically all, the climate is hot and damp. The tropical belts of Africa and India are considered to have the highest prevalence rates in the world.<sup>13</sup>

In contrast, prevalence rates are low (< 1 per 1,000 population) in most temperate regions of the world, and are virtually nonexistent in cold climates.<sup>13</sup> The attack rate is very low in adults. Acquisition of the disease normally requires prolonged respiratory contact with a person with untreated lepromatous leprosy. Nonetheless, more than 99% of the exposed population will fail to develop the disease.<sup>14</sup> For the remaining 1% who do, the incubation period averages 2 to 5 years.<sup>10</sup>

### Leprosy in the U.S. Army Before World War II

There are no records of leprosy occurring in the U.S. Army before the Spanish-American War. During the War of 1812, troops were engaged in New Orleans in the vicinity of an old endemic focus, but the number of men involved was small and the duration of the conflict short.<sup>2</sup>

The earliest records of leprosy in the armed services of the United States relate to cases among soldiers who served in the Spanish-American War, the Boxer Rebellion, or the Philippine Insurrection. Actually, the cases did not occur during the hostilities; they were reported at intervals over several subsequent decades, and the onset dates are not known with exactness. One or perhaps two of the cases may have originated as early as 1901. From

1921 to 1940, 32 veterans were admitted to the U.S. Marine Hospital (also called the National Leprosarium) at Carville, Louisiana. Of these, 28 had served in the army, three in the navy, and one in the marines. Thirty patients had had military service outside the United States in places known to be focuses of leprosy; 25 of the 30 had served in the Philippines. There is no record of foreign service for two of the patients; one was born in Louisiana and the other in Texas. Five were born outside the continental United States; 19 were born in parts of the United States where the disease rarely occurs. For 18 of the latter, the periods of service in endemic areas ranged from 9 months to 32 years. A large portion of the Spanish-American War veterans who had been admitted to the National Leprosarium were born in nonendemic areas; the average age on admission of the entire group of Spanish-American War veterans was 52. The dates at which the first signs of the disease are stated to have appeared ranged from 1901 to 1938, but, of 27 patients for whom dates are given, all except 4 are stated to have observed their first symptoms after 1910. A number of veterans who developed the disease had remained in the Philippines in military or civilian capacity for some years following termination of the Philippine Insurrection.<sup>2</sup>

From 1921 to 1940, 51 World War I veterans were admitted to the National Leprosarium. Of this population, 41 had served in the army, one in the Students Training Corps, eight in the navy, and one in the marines. Records show that 33 had no service outside the continental United States, 12 had served in France, two in Mexico, and one each in Hawaii, Panama, the Philippines, and Puerto Rico. Of the group of 51, 18 had been born outside the continental United States, and, of the remaining 33, 15 had been born in Louisiana, 10 in Texas, 5 in Florida, 2 in Mississippi, and 1 in Georgia. None had been born in the northern States. Age on admission to the National Leprosarium averaged 33.2 years (range: 22 to 43 y). In 35 patients (68.6%), the first signs of the disease were noticed during the years 1917 through 1923.<sup>2</sup>

### Preventive Measures During World War II

Because [a] knowledge was lacking about the mode of spread of the disease and [b] there were no effective vaccines or chemical prophylactics, there was not much that the U.S. Army's Preventive Medicine Service, Office of The Surgeon General, could do to protect troops and other military personnel against leprosy. Protection depended almost entirely on recognition of the disease when it occurred and avoidance of contact. At the same time, measures were invoked to counteract the fears, the military and public alarm, and the dangers of irrational behavior (eg, violence, hostility) that were aroused by age-old superstitions about the disease. The Preventive Medicine Service recognized that leprosy, because of its long latency and low incidence of adult infection, could not be a disease of military significance insofar as loss of manpower during World War II was concerned. It also recognized that the area of exposure was vastly extended



and that the number of possible contacts was increased when thousands of U.S. soldiers were deployed among populations where incidence of leprosy was high, particularly in the Pacific regions. The late consequences of acquisition of leprosy during the war by soldiers exposed in the course of their service were also matters of grave concern. A balanced program was adopted that was designed to stimulate awareness of the disease and at the same time to support reasonable precautionary measures.<sup>2</sup>

The prevention of contact of military personnel with leprosy persons within the service had been a long-standing practice, as specified by army regulations. Leprosy was a fixed basis for rejection of men coming up for induction through enlistment or draft. Despite provisions for rejection on account of leprosy, the records, examined later, showed that 15 men infected with leprosy before 1941 were inducted into the army during World War II. Of these, five were men who had been discharged from the National Leprosarium as "arrested cases." The other 10 men were from various parts of the United States and Hawaii and, at various periods after induction, were discovered to have leprosy. The other 10 men were from various parts of the United States and Hawaii and, at various periods after induction, were discovered to have leprosy. No secondary cases among military personnel are known to have arisen from these sources.<sup>2</sup>

Significant advances were made in the therapy of leprosy during World War II. For many years, the standard treatment had been administration of chaulmoogra oil or its esters, and, although there was controversy as to the results, there was nothing better at hand. In 1940, sulfanilamide was given to a group of patients at the National Leprosarium. However, "although secondary infections were cleared up, little or no improvement was noted in lepromatous lesions."<sup>2(p34)</sup>

Promin, one of the sulfone drugs (which differ from the sulfonamides in having two phenyl groups instead of one, and which have in common the diaminodiphenylsulfone radical), was released in soluble form for clinical study in 1938. In March 1941, the first group of leprosy patients at the National Leprosarium was placed on promin.<sup>2</sup>

At first [the drug] was given orally, and toxic symptoms were so severe that it had to be discontinued. Shortly afterward, a preparation for intravenous use was obtained and found to be well tolerated. Clinical improvement observed was slow but definite; as a rule, it did not become manifest until after 6 months of treatment. Lesions of the mucous membranes of the upper respiratory tract responded well, resulting in restoration of the voice and disappearance of nasal obstruction. Emergency tra-

cheotomies were much less frequently required. Nodules in the skin slowly flattened. Areas of infiltration gradually subsided. Leprous ulcers of the extremities gradually healed. Occasionally, regrowth of hair occurred in the eyebrows, beard, and on the arms and legs. There was little evidence of improvement in eye lesions. Skin and nasal smears remained positive in nearly all patients even after a year of treatment, but there was definite evidence of reduction after 2 years of treatment. Slow and gradual disappearance of bacilli was confirmed. Promin appeared to act by eliminating bacillary infection from the blood vessels and bloodstream, thereby preventing formation of new lesions and permitting natural resolution of lesions to take place.<sup>2(p34)</sup>

Promin was in part replaced in 1943 by disodium formaldehyde sulfoxylate diaminodiphenylsulfone, first prepared under the name of Diasone. It was given orally in doses as large as about 1 g daily. Other sulfones soon came into use, but the results with all of them were more or less equivalent to those obtained with Diasone. It is considered by many that beneficial effects of the sulfones on leprosy are attributable to diaminodiphenylsulfone (DADS).<sup>2</sup>

Records have been found of 69 cases of leprosy in individuals who served in the armed forces during World War II. In 15 of the 60 leprosy patients from the army, there is evidence that the disease had been present before enlistment or induction, and 5 of the 15 had been treated previously at the National Leprosarium. Of the other 45 patients, 7 had definite histories of exposure to leprosy in the family. The records of the remaining 38 patients were carefully examined in the search for the probable loci of exposure. All but six had been born in the areas in which the disease is endemic [eg, the Gulf coasts of Louisiana and Texas—JWS]. While this does not preclude the possibility of exposure during military service, it would seem more probable that the infection occurred at an earlier date. This is supported by the fact that the average age of these patients at time of stated onset was 27.2 years and also by the fact that there was no significant difference in average age at time of onset between those who had served in theaters in which the disease was endemic and those who had not.<sup>2</sup>

### *Leprosy During the Vietnam Conflict*

The only statistics on leprosy reported out of the Vietnam conflict dealt with indigenous Vietnamese patients seen at the 95th Evacuation Hospital Da Nang, I Corps, from July to October 1970. Fourteen cases, constituting 13% of the total (114) population presenting with skin diseases, were seen.<sup>15(p41)</sup>

## EPIDEMIOLOGY

The World Health Organization (WHO) currently estimates the prevalence of leprosy at 10 to 12 million cases, based on some 3.7 million registered cases, with 576,361 new cases detected in 1990 (Figure 14-1).<sup>13,16</sup>

The portal of entry for leprosy bacillus most probably is the respiratory tract, although there is evidence for transmission of leprosy through intact skin and via penetrating wounds such as thorns and

Fig 14-1 is not shown because the copyright permission granted to the Borden Institute, TMM, does not allow the Borden Institute to grant permission to other users and/or does not include usage in electronic media. The current user must apply to the publisher named in the figure legend for permission to use this illustration in any type of publication media.

**Fig. 14-1.** The world distribution of registered leprosy cases as of 1990. Data source: Noordeen SK. Leprosy control through multidrug therapy (MDT). *Bull WHO*. 1991;69:264.

arthropod bites.<sup>14</sup> It is widely accepted that the nose is the major portal of exit for bacilli. Multibacillary patients can shed several millions of bacilli per day in their nasal secretions.<sup>16</sup> Patients with untreated lepromatous leprosy have great numbers of bacilli in their nasal secretions. However, patients with borderline and tuberculoid disease have few to none. Chemotherapy rapidly renders the nasal discharge bacteriologically negative. Longitudinal studies have repeatedly confirmed that multibacillary patients constitute the major source of infection.

The decline in leprosy documented in some countries at a time of improvement in living conditions, but before the advent of modern control measures, suggests that mitigation of overcrowding and poverty, as well as improvements in nutrition and hygiene, have beneficial effects in preventing the disease.<sup>16</sup>

While humans are considered to be the major host for the leprosy bacillus, natural infections of

wild armadillos occur in Texas and Louisiana, and natural infections of chimpanzees and mangabey monkeys occur in the wild.<sup>16</sup> Anecdotal reports suggest that transmission of *M leprae* between armadillos and humans is possible.

Children, particularly infants and young children, seem to be much more susceptible to leprosy than adults in a given population. Where children are at risk because of leprosy in the family, up to 60% will develop disease after a 2- to 7-year incubation period. Thus, peak ages of incidence are ages 5 through 9 years.<sup>17</sup> In contrast, the incidence of conjugal leprosy in spouses is only about 5%.<sup>5</sup> Transplacental transmission has rarely been documented.<sup>17</sup> However, one series<sup>18</sup> of 91 children less than the age of 1 year in whom leprosy was diagnosed has been reported. In children, paucibacillary forms of leprosy tend to predominate, with most children expressing indeterminate and tuberculoid lesions.<sup>17</sup> However, in a recent series of 132 children from a nonendemic area of northern India, 59% had

borderline tuberculoid (BT) disease and 20.4% had borderline lepromatous (BL) disease. Only 3.8% had indeterminate leprosy.<sup>19</sup> Also noteworthy is the high frequency of nerve involvement in children (seen in two thirds of all cases) and the low frequency of reactional states.<sup>19</sup> Nonetheless, most people effectively resist infection even in highly endemic areas. It is now believed that only 0.5% of those infected with the leprosy bacillus actually develop an overt clinical case.<sup>14</sup>

The clinical profile of leprosy has changed considerably since the mid-1970s. Advanced lepromatous leprosy with leonine facies, ulcerating nodular lesions, and progressive ulcerative erythema

nodosum leprosum leading to amyloidosis, nephrotic syndrome, and death are less frequently observed. Such improvements are attributable to efficient leprosy control programs and improvements in chemotherapy.<sup>16</sup>

Pregnant women with incubating leprosy may develop overt signs of disease; most women worsen during pregnancy. Reversal reactions occur during puerperium, downgrading reactions during the third trimester. Erythema nodosum leprosum reactions are most likely in the third trimester and following parturition. Infants born of lepromatous mothers tend to be small for their gestational age.<sup>5</sup>

## MICROBIOLOGY

As seen in slit-skin smears, *M leprae* is a straight or slightly curved, rod-shaped organism with parallel sides and rounded ends. It measures 1 to 8  $\mu\text{m}$  in length and 0.3  $\mu\text{m}$  in diameter. *M leprae* is Gram-positive with the additional property of resisting decoloration of carbol-fuchsin with acid alcohol. It is primarily an intracellular organism commonly seen in clumps (*globi*), which may contain hundreds of bacilli. In clumps, they occur in parallel array and resemble bundles of cigars.

*M leprae* grows best at 27°C to 30°C (ie, in the cooler parts of the body). It divides every 12 to 15 days. The organism may be a natural soil saprophyte.

### Natural Reservoirs and Laboratory Transmission

Investigations into the basic biology, metabolism, and chemical structure of *M leprae* have been hindered by the inability to date to culture the organism in vitro. Additionally, it seems to multiply and produce disease in only a very limited number of animal species. The nine-banded armadillo is currently the only source of the large amounts of leprosy bacillus needed for research purposes and vaccine production. Inoculation into the footpads of immunologically normal mice remains the basic tool for assessing drug activity and resistance of *M leprae*. The use of immunodeficient rodents (ie, thymectomized, irradiated, bone marrow-reconstituted mice, nude mice, and neonatally thymec-tomized rats) is the most sensitive method available for monitoring the presence of viable *M leprae* in patients undergoing chemotherapy.<sup>16</sup>

Experimental transmission of infection to three

different species of monkey has been achieved within the last decade: lepromatous leprosy (LL) in mangabey monkeys, borderline lepromatous leprosy (BL) in African green monkeys, and borderline lepromatous-lepromatous leprosy (BL-LL) in rhesus monkeys.<sup>16</sup>

### The Cell Wall

The cell walls of all mycobacteria exhibit a similar complex structure of lipid-rich macromolecular structures. However, *M leprae* appears to differ from other mycobacteria in the composition of the peptide units and in the multiplicity of peptidoglycan layers that constitute the complete cell wall structure (Figure 14-2). The most notable of the cell wall-associated glycolipid molecules of *M leprae* is phenolic glycolipid I (PGL-1), which is species-specific and immunogenic during infection. Immunochemical and electron micrographic studies indicate that PGL-1 is associated with the outer surface of *M leprae* and may represent the "capsule" of the organism. This could function as a virulence factor, providing an important interface between parasite and host, critical for maintenance of the parasitic relationship. PGL-1 can accumulate in armadillo tissues in quantities equal to one half the total weight of the leprosy bacilli present. The "foam" seen in heavily infected macrophages—a characteristic of the lepromatous granuloma—is thought to contain PGL-1.<sup>14</sup>

### Molecular Biology and Genetics

The advent of monoclonal antibody techniques and T-cell cloning methods has permitted the iden-

Fig 14-2 is not shown because the copyright permission granted to the Borden Institute, TMM, does not allow the Borden Institute to grant permission to other users and/or does not include usage in electronic media. The current user must apply to the publisher named in the figure legend for permission to use this illustration in any type of publication media.

**Fig. 14-2.** *Mycobacterium leprae* has a complex cell wall composed of many layers. The outer layer contains the phenolic glycolipid PGL-1, which may be an important virulence factor. Adapted with permission from Gaylord H, Brennan PJ. Leprosy and the leprosy bacillus: Recent developments in characterization of antigens and immunology of the disease. *Annu Rev Microbiol.* 1987;41:645–675.

tification of a number of epitopes (as opposed to entire protein molecules) unique to *Mleprae*. The entire genome of *M leprae* has been cloned and

expressed in *E coli*; this development has opened a wide avenue for future research, despite the absence of in vitro culture techniques.<sup>16</sup>

## IMMUNOLOGY

### Humoral Immunity

Because of the intracellular, sequestered location of *M leprae*, it is doubtful that humoral immunity plays a significant role in resistance to the organ-

ism. However, humoral immunity is the source of the antigen–antibody complexes in the pathogenesis of erythema nodosum leprosum reactions. Lepromatous leprosy (LL) is generally associated with hypergammaglobulinemia and a high circu-

lating B lymphocyte count. Patients with borderline leprosy (BB) tend to have intermediate levels, and patients with tuberculoid leprosy (TT) have normal levels of B lymphocytes. There tends to be an inverse correlation between a patient's anti-*M leprae* antibody titer and the potency of the patient's cell-mediated immune response to the bacillus.<sup>14</sup>

PGL-1 was the first antigen specific to *M leprae* to be identified and to have its antigenic moiety chemically synthesized. Antibodies to PGL-1, primarily of the immunoglobulin (Ig) M subclass, have been detected in the sera of most multibacillary patients with leprosy, in titers proportional to the bacillary load. In some limited studies, high antibody titers have also been reported in some household contacts of multibacillary patients, as well as in other inhabitants of endemic areas, confirming that infection is more frequent than overt disease. However, false-negative results in patients with tuberculoid leprosy (TT) and their contacts limits the use of antibody titers for epidemiological purposes or for detection of subclinical infection.<sup>16</sup>

### Cell-Mediated Immunity

Experiments involving inoculations of *M leprae* into athymic (nu/nu) mice and rats have shown the importance of cell-mediated immunity in host resistance to leprosy.<sup>14</sup> The maximum number of T lymphocytes tends to be present in tuberculoid lesions, with a gradual decline across the spectrum such that very few are present in disseminated multibacillary lepromatous leprosy.<sup>20</sup>

At the lymphocyte level, the presence of T helper cells specific for antigens of the leprosy bacillus is a key characteristic of the tuberculoid end of the clinical spectrum of leprosy. T helper cells have been found to be as high as 95% of the lymphocytes in tuberculoid granulomas, whereas in lepromatous lesions T cytotoxic/suppressor cells can constitute up to 85% of the population.<sup>20</sup> More importantly, in tuberculoid lesions the cells are arranged in a distinct architecture within the lesion: T4 cells in the centers of the epithelioid granulomas and T8 suppressor cells in the margins.<sup>14</sup> T4 cell counts are often depressed and T8 cell counts increased in the peripheral bloodstream of many patients with lepromatous leprosy in proportion to their bacillary load.<sup>20</sup> These abnormal T cell counts slowly normalize with adequate chemotherapy.<sup>20</sup>

Additionally, in lepromatous disease, the macrophage fails to kill or inhibit *M leprae* and is unable to produce interleukin-1 (IL-1), the cytokine that

can amplify the production of IL-2 by T cells. Macrophages, activated by lymphokines (especially gamma interferon [IFN-g], which is released from sensitized helper T cells responding specifically to antigen), may play a major role in resistance to a wide variety of obligate and facultative intracellular pathogens. In an experimental model of leprosy of the lepromatous lepromatous (LL) type, it has recently been demonstrated that *M leprae*-engorged macrophages from the footpad lesions of infected nude mice (nu/nu) are refractory to IFN-g in vitro. Of interest, lipoarabinomannan (LAM), a carbohydrate-rich component of the *M leprae* cell wall, not only blocks the proliferation of T cells, but also induces a refractory response to IFN-g in human monocyte-derived macrophages. Thus, newly arriving macrophages may rapidly encounter local bacterial-wall products that effectively restrict their normal responsiveness and function.<sup>14</sup> Hence, they may then fail to produce IL-1, leading to nonreactive, nonproliferative T cells in that microenvironment.

### The Lepromin Test

The lepromin test is an indicator of the ability of the host to mount a cell-mediated immune response to *M leprae*. Lepromin is a heat-killed suspension of *M leprae* originally obtained from homogenized human tissue sources, but now prepared from armadillo tissue. WHO's Expert Committee on Leprosy has recommended standardizing the concentration at 40 million bacilli per milliliter.<sup>14</sup> The test itself is of no diagnostic value, but does establish the immune status of the individual and is thus of prognostic value. A positive reaction is typically biphasic:

- The early (24–48 h) Fernandez reaction is a delayed hypersensitivity reaction (probably to soluble protein antigens) and occurs in patients with tuberculoid leprosy, their contacts, and healthy individuals who are sensitized either to *M leprae* or to cross-reacting antigens from other mycobacteria.
- The late Mitsuda reaction, measured at 21 days, reflects the induction of acquired cell-mediated immunity, which is manifested by formation of an organized epithelioid cell granuloma. WHO has instituted the following system for grading the Mitsuda reaction<sup>20</sup>:
  - 0 No reaction (induration)
  - ± Induration or papules less than 3 mm

- 1+ Induration or papules 4 to 6 mm
- 2+ Papule 7 to 10 mm
- 3+ Nodule larger than 10 mm, or of any size that ulcerates

Positive reactions are seen in the vast majority of

contacts and unexposed individuals, as well as in patients with tuberculoid leprosy. Weakly positive reactions aid classification of borderline disease. Negative reactions are seen in lepromatous leprosy, despite years of chemotherapy.

## LABORATORY DIAGNOSIS

### The Slit-Skin Examination Technique

Bacteriological examination is very important and highly relevant to leprosy control. The slit-skin technique (in simple terms, a slit-scrape-smear method) is the WHO-preferred method for the detection of bacteria in patients suspected of harboring the leprosy bacillus<sup>11</sup>:

- Thoroughly clean the selected portion of skin to remove saprophytic acid-fast bacilli.
- Pinch the skin to remove blood and decrease hemorrhage.
- Using a sterile surgical blade, make a cut 5-mm long by 2-mm deep.
- Wipe away any oozing blood.
- Holding the blade at right angles to the slit, scrape the bottom and sides of the slit with the point of the blade to obtain sufficient material for a smear.
- Transfer the material to a clean, labeled, glass slide.
- Use pressure hemostasis to stop bleeding at the slit site.

It is essential that the Centers for Disease Control and Prevention's guidelines<sup>21</sup> for preventing the transmission of AIDS and hepatitis B infection be followed during the process of taking skin smears.

### Site Selection

In lepromatous leprosy, the skin and the mucous membranes of the nose and oral cavity are diffusely infiltrated with bacteria—even in areas that appear normal. In tuberculoid leprosy, organisms are sparse. In borderline leprosy, only the borderline lepromatous (BL) group may show bacilli in uninvolved sites. Thus, in lepromatous leprosy, it is a question of selecting a site with the highest density of bacteria, whereas in tuberculoid and borderline groups, one has to select from lesions only. The ear has traditionally been regarded

as the site of heaviest involvement. The chin, buttocks, and fingers are also sites of high bacillary counts. Recently, it has been noted that in long-treated cases, the bacilli are probably cleared from the fingers last.<sup>11</sup>

In general, smears should be taken from a minimum of three sites, including one ear lobe and two representative active skin lesions. In cases of paucibacillary patients with one lesion, two smears should be taken from the active border, diametrically opposite each other.<sup>16</sup> Sites previously shown to be positive in specific patients are recommended as sites for follow-up examination.

### Acid-Fast Preparations

The Ziehl-Neelsen acid-fast staining of slit-skin smears is the global standard, being inexpensive and requiring minimal facilities. Smears should be dried for 15 to 30 minutes and fixed. Fixation can be done by passing slides carefully through a flame. However, it is preferable to fix the smears in 40% formaldehyde for 15 minutes. Slides are then stained by the Ziehl-Neelsen method, a complex, regressive, staining method comprising three essential steps<sup>22</sup>:

1. Over-staining with basic fuchsin. This is achieved by using carbol-fuchsin containing phenol and applying heat, or keeping the staining solution on the slide for a period of time. Under field conditions the cold staining method is easier. The basic fuchsin is left on the slide for 30 minutes.
2. Decoloration (this is a regressive step) with either acidified alcohol or acid in water. All material except mycobacteria (in this case, *M leprae* or *M tuberculosis*) lose the red fuchsin stain. At this moment, leprosy bacilli in the preparation are stained red on a colorless background.
3. Counter-staining of the background with methylene blue.

## Bacterial Index

In the past in developing countries, the bacterial examination had largely been neglected. This practice was somewhat acceptable as long as therapy was based on one and only one drug, which was administered to patients no matter what form of the disease they had. However, now the differentiation of paucibacillary leprosy from multibacillary leprosy takes on added importance, as the two forms use different therapeutic regimens. The Ridley Logarithmic Scale,<sup>23</sup> proposed in 1958 as a bacterial index, has gained wide acceptance; WHO has recommended its uniform adoption worldwide to facilitate comparison of results.<sup>16</sup> Ridley's Logarithmic Scale is as follows:

- 6+ Many clumps of bacilli in an average field (> 1,000)
- 5+ 100–1,000 bacilli in an average field
- 4+ 10–100 bacilli in an average field
- 3+ 1–10 bacilli in an average field
- 2+ 1–10 bacilli in 10 fields
- 1+ 1–10 bacilli in 100 fields
- 0 No bacilli seen

Before a case is deemed negative, 200 fields are generally scanned. Otherwise, the bacterial index of the patient is averaged from all the bacterial indices of the individual sites.

The line between paucibacillary and multibacillary cases is a bacterial index of 2 or more at any site. Because of drug resistance and the need for multidrug therapy, the microscopical examination of smears for acid-fast bacilli is quite essential to detect relapse. Reading and interpretation of the bacterial index can be schematized as follows<sup>22</sup>:

- In patients with new, untreated leprosy:
  - 0 No leprosy or paucibacillary leprosy
  - 1 Bacteriologically proven paucibacillary leprosy
  - ≥2 Multibacillary leprosy
- In patients with old, previously treated leprosy:
  - 0 No leprosy, or treated paucibacillary or multibacillary leprosy
  - 1 Treated multibacillary leprosy
  - ≥2 Multibacillary leprosy, keeping in mind that adequate treatment diminishes the bacterial index by approximately 1 unit per year

Thus, these results should be interpreted taking into consideration the kind and duration of previ-

ous treatment. Notably, a significant increase of the bacterial index is the result of either irregular drug intake or development of drug resistance.

There is a widespread impression that multidrug therapy will hasten the attainment of smear negativity, but this is not substantiated by the available evidence. The rate of clearance of bacilli under multidrug therapy is approximately 0.6 to 1 Ridley Logarithmic Scale units per year. It must be appreciated that the bacterial index is a late marker for the antibacterial action of drugs in leprosy, even though it is of prime importance for the diagnosis of relapsed cases. Clinical improvement is accelerated by multidrug therapy and precedes the fall in the bacterial index.<sup>16</sup>

Bacilli in smears are seen only when the bacillary load is more than  $10^4$  organisms per gram of tissue. Negative results from a slit-skin examination do not exclude leprosy: organisms can be seen in biopsied specimens of skin, peripheral nerves, lymph nodes, and testes despite cutaneous negativity.<sup>11</sup>

The greatest importance of positive slit-skin examinations is probably in the diagnosis of indeterminate leprosy.

For treatment purposes, WHO has recently redefined multibacillary and paucibacillary disease. Paucibacillary disease is smear-negative, and multibacillary smear-positive.<sup>16</sup>

Both for patients currently under treatment and for patients previously treated, WHO has laid down certain guidelines for assessment. Both past and present bacterial indices should be considered. Patients are classified as paucibacillary or multibacillary on the basis of the highest bacterial index at any time during treatment.

The bacterial index is a direct measure of the bacillary load of an individual, and therefore of the seriousness and infectiousness of the patient's condition. Clearly, patients with a high bacterial index (ie, those with lepromatous leprosy) are more infectious. Prolonged skin-to-skin contact with such patients is a known mode of transmission of leprosy. Bacilli may also be continuously shed from nasal discharge into the environment. Thus, a high bacterial index from the nose may have great epidemiological significance. Maximum load is harbored in patients having a bacterial index of more than 3; a priority treatment for these patients is therefore logical. Bacterial load decides the severity and infectivity of the case.

A patient should be regarded noninfective if he or she has a bacterial index of 0, determined from multiple slit-skin smears repeated over 3 consecutive months.<sup>11</sup>

## Morphologic Index

Traditionally, the morphologic index was thought to give an indication of the proportion of viable bacilli in the patient. This viability was based previously on the percentage of bacteria with solid staining, as opposed to fragmented or granular staining. More sophisticated techniques such as electron microscopy, mouse-footpad inoculation, thymidine uptake studies, and so forth, have shown poor correlation between the morphologic index and true viability.<sup>11</sup> Additionally, there are problems with reproducibility and standardization, especially under field conditions. Therefore, WHO does not recommend its use in routine control programs.<sup>16</sup>

## Cutaneous Nerve Biopsy

A cutaneous nerve biopsy is frequently required to establish the diagnosis of primary neuritic leprosy (discussed later in this chapter). Patients with this form of leprosy have no cutaneous lesions other than localized anesthesia. Because standard skin biopsies and smears for acid-fast bacilli are usually nondiagnostic, cutaneous nerve biopsy may be the only method by which the condition can be diagnosed with certainty. The procedure for performing cutaneous nerve biopsy is as follows<sup>24</sup>:

1. Find a palpable nerve in the area of anesthesia and mark the skin overlying it with gentian violet.
2. Give local anesthesia.
3. Make a transverse incision 1 cm in length over the nerve.
4. Tease through the subcutaneous tissue gently with an artery forceps until the nerve is identified.
5. Remove a 1-cm piece of nerve with a scalpel.
6. Suture skin closed.
7. Process the specimen for routine histopathology and for acid-fast bacilli.

## Serologic Assays

Cases of subclinical infection can now be detected by serologic means including fluorescent leprosy absorption, radioimmunoassay for antibodies to cell-wall antigen, and enzyme-linked immunosorbent assay (ELISA) to detect antibodies against the phenolic glycolipid derived from the *M leprae* cell wall.<sup>10</sup> However, because only 0.5% of those infected with the leprosy bacillus are believed to actually develop overt clinical leprosy, it is difficult to interpret the meaning of a positive test, other than for epidemiological investigations.<sup>14</sup>

## CLINICAL AND HISTOLOGICAL DIAGNOSTIC CRITERIA

Clinically, leprosy demonstrates a wide spectrum of dermatologic lesions.<sup>25,26</sup> Untreated patients may present with any combination of the following:

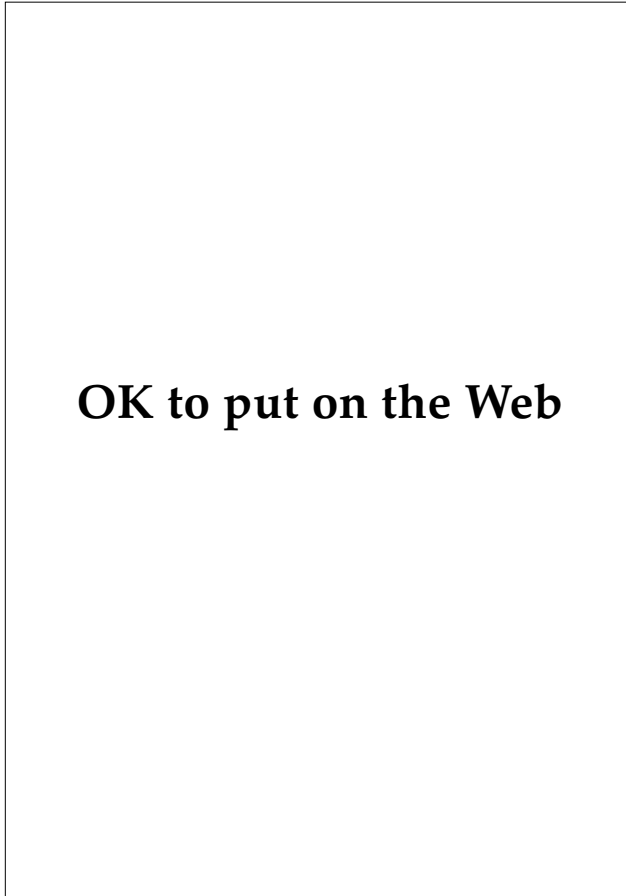
- a single, nondescript, hypopigmented macule;
- single or multiple, asymmetric, dry, scaly, or inflammatory plaques;
- symmetrical, widely disseminated, erythematous papules and nodules associated with coarse thickening and nodularity of the face (leonine facies);
- lagophthalmos (Figure 14-3);
- blindness;
- severe peripheral neurological disease;
- deformities of the nose and extremities; or
- diffuse infiltration and edema of the skin.

Secondary cutaneous infections, osteomyelitis, neurotropic ulcerations, and significant renal disease (amyloidosis or glomerulonephritis) may occur in

severely affected and untreated patients. Additionally, psychiatric abnormalities are not uncommon among patients with leprosy. A study of 81 patients conducted over a 4.5-year period at the Hansen's Disease Center in Carville, Louisiana, showed that more than 80% of the patients had a psychiatric disorder: 37 (46%) had a major affective disorder; 9 (11%) had an organic mental disorder; 9 (11%) had schizophrenia; and 9 (11%) had substance abuse.<sup>27</sup> The large number of patients with affective disorder and substance abuse may well be due to the emotional effect of the diagnosis on patients and their families in our society.

Histologically, established leprosy demonstrates a continuous spectrum of disease from a localized, self-healing, granulomatous disease with very few organisms to a widespread, progressive, anergic disease with massive numbers of bacilli.<sup>28</sup> *M leprae* tend to invade neuronal structures in the cooler areas of the body. Initially, only minor nerve infiltration may be demonstrated histologically. However, great variation is present from patient to patient.





To classify patients within this tremendous clinical and histological spectrum, several classification schemes have been proposed. The most popular, and the one endorsed by WHO, is the Ridley and Jopling Classification, with minor modifications (Table 14-1 and Figure 14-4). Histological classifications, by contrast, are much more expensive (and are thus impractical for use in third-world countries and in field situations) and they do not help further categorize patients except for those in the reactional states (which are discussed later in this chapter).<sup>28</sup> Exhibits 14-1 through 14-7 and Figures 14-5 through 14-12 are designed to aid in the diagnosis of leprosy in its various manifestations.

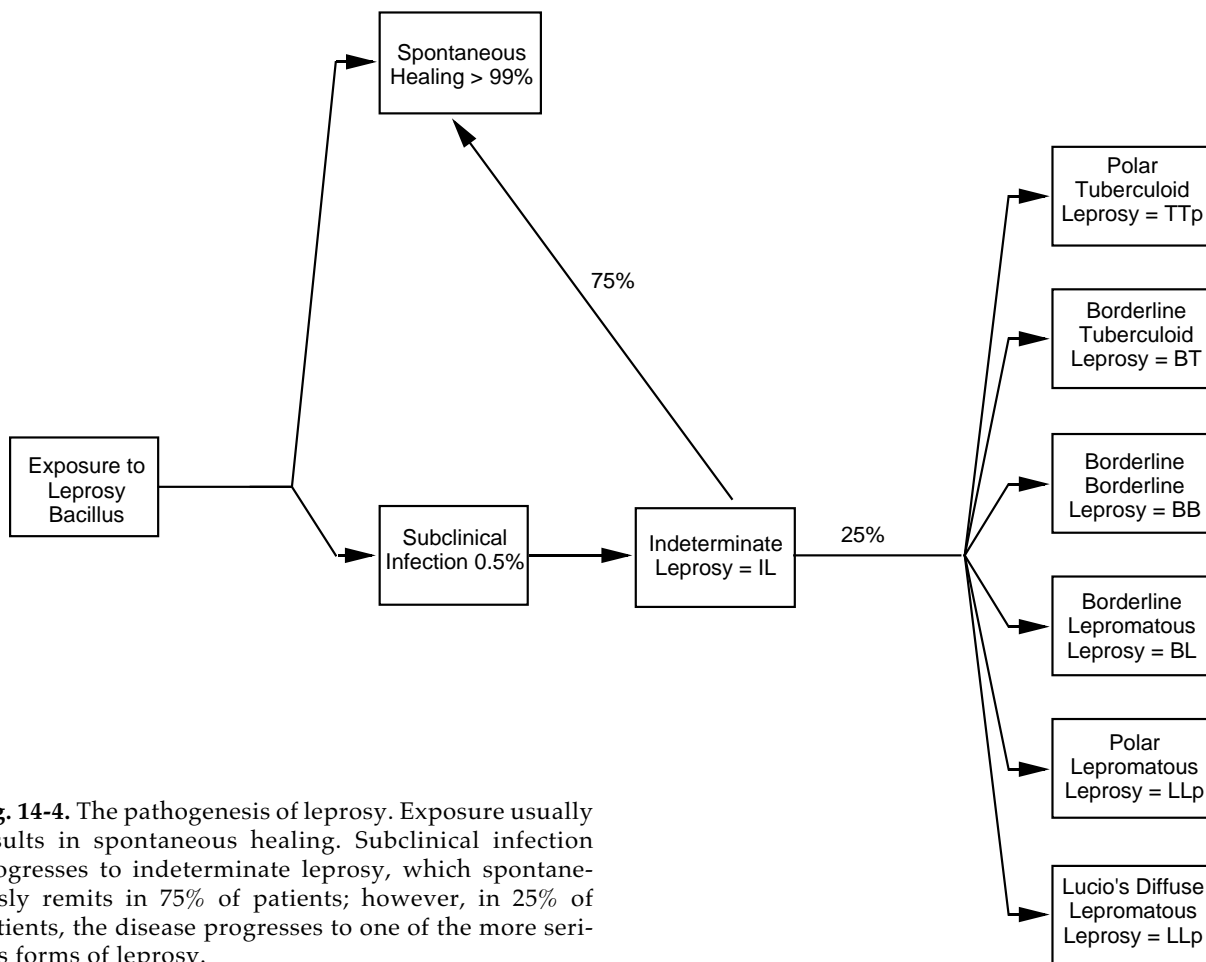
The polar forms—lepomatous leprosy (LLp) and tuberculoid leprosy (TTp)—tend to be stable clinically, whereas the borderline forms—borderline lepomatous (BL), borderline leprosy (BB), and borderline tuberculoid (BT)—tend to be unstable. The

←  
**Fig. 14-3.** This patient has advanced lepomatous leprosy with significant cutaneous and ocular disease. Note the severe lagophthalmos, which has led to an exposure keratitis, and the severe deformity of the fingers, which is a consequence of chronic trauma and secondary infection following anesthetic changes in the distal extremities.

**TABLE 14-1**  
**MODIFIED RIDLEY-JOPLING CLASSIFICATION FOR LEPROSY**

Stage of Disease	Characteristics of Lesions				
	Number	Size	Surface	Sensation*	Hair Growth
Polar lepomatous (LLp)	Very many	Small	Shiny	Not affected	Not affected
Subpolar lepomatous (LLs)	Very many	Small	Shiny	Not affected	Not affected
Borderline lepomatous (BL)	Many	Variable	Slightly shiny	Slightly diminished	Slightly diminished
Borderline borderline (BB)	Several	Variable	Dry	Slightly to moderately diminished	Moderately diminished
Borderline tuberculoid (BT)	Few or 1	Variable	Dry	Moderately to markedly diminished	Moderately diminished
Subpolar tuberculoid (TTs)	Usually 1	Variable	Very dry	Absent	Absent
Polar tuberculoid (TTp)	Usually 1	Variable	Very dry	Absent	Absent

\*Does not pertain to lesions on the face  
 †AFB: Acid-fast bacilli



**Fig. 14-4.** The pathogenesis of leprosy. Exposure usually results in spontaneous healing. Subclinical infection progresses to indeterminate leprosy, which spontaneously remits in 75% of patients; however, in 25% of patients, the disease progresses to one of the more serious forms of leprosy.

Contain AFB <sup>†</sup>	AFB Found in Nasal Secretions	Bacterial Index (Ridley)	Lepromin Test	Comment
Very many (plus globi)	Very many (plus globi)	5-6	Negative	Polar lepromatous leprosy
Very many (plus globi)	Very many (plus globi)	5-6	Negative	Downgraded to LL from BL due to lack of therapy
Many	Usually nil	4-5	Negative	Unstable immunity
Moderate	Nil	3-4	Negative	Unstable immunity
Nil or scanty	Nil	0-2	Weakly positive (+ or ++)	Unstable immunity
Nil	Nil	0-1	Strongly positive (+++)	Upgraded to TT from BT due to treatment or nutrition
Nil	Nil	0-1	Strongly positive (+++)	Polar tuberculoid leprosy

EXHIBIT 14-1

THE DIAGNOSIS OF LEPROMATOUS LEPROSY

OK to put on the Web

OK to put on the Web

**Fig. 14-5.** Lepromatous leprosy. This elderly man has innumerable erythematous infiltrated papules and plaques on his back. Notice the sparing of the spinal and immediate paraspinal areas. These zones are warmer and are consequently less hospitable to the growth and survival of *Mycobacterium leprae*.

**Fig. 14-6.** Lepromatous leprosy. This teenaged Peruvian girl has a more nodular form of lepromatous leprosy (compared with the patient shown in Fig. 14-5). Note the symmetry of the lesions and the diffuse infiltration of her nose.

**Clinical Features**

- The number of lesions is characteristically numerous to uncountable. They are bilaterally symmetric, widely distributed, hypopigmented (ie, dark-skinned) or erythematous, and may take any of these forms: macules, plaques, papules, and nodules (Figures 14-5 and 14-6).
- The margins of macules are hazy (ie, they merge imperceptibly into the surrounding skin).
- The lesions are smooth and shiny.
- The ears may be infiltrated (Figure 14-7.)
- The face may become exceedingly infiltrated with nodules, creating the leonine facies.
- The axillae, groin, perineum, and hairy scalp are almost invariably spared of lesions.
- Chronic edema of the lower extremities is common.
- Eyebrows are frequently lost, although body hair and scalp hair are generally retained.
- Lagophthalmos and corneal anesthesia leading to exposure keratitis are common with advanced disease.
- Sweating is often normal.
- Multiple nerve thickenings occur only in the late states of the disease: great auricular nerves in the neck, supraclavicular nerves, ulnar nerves (olecranon fossae), radial and medial nerves at the wrist, lateral popliteal nerves, sural nerves, and posterior tibial nerves.

## Exhibit 14-1 (continued)

**OK to put on the Web**

**Fig. 14-7.** Lepromatous leprosy. This elderly Peruvian man shows characteristic infiltration of the ears and ear lobes. Note the multiple nodules and papules on his face, many of which appear to be subcutaneous.

**Fig. 14-9.** Histology of lepromatous leprosy, oil emersion, Fite stain. Large numbers of acid-fast organisms are seen singly as well as in clusters (globi).

#### Clinical Features (continued)

- Nasal stuffiness, crusting, and discharge are characteristic. Discharge is striking for the large number of acid-fast bacilli.
- There may be systemic infiltration of liver, spleen, bone marrow, kidneys, and testes.

#### Histological Features

- The numerous, foamy macrophages in the dermis around blood vessels, nerves, and adnexa are characteristic. The entire dermis may not be involved (Figure 14-8).
- A well-preserved grenz zone is typical.
- The nerves are preserved and have an “onion peel” appearance.
- Acid-fast bacilli are numerous and are found in packets (ie, globi) within the macrophages (Figure 14-9). Older lesions show vacuolated cytoplasm within the macrophages due to lipid accumulation (ie, the lepra cells of Virchow).
- Bacterial Index (Ridley) = 5–6

**OK to put on the Web**

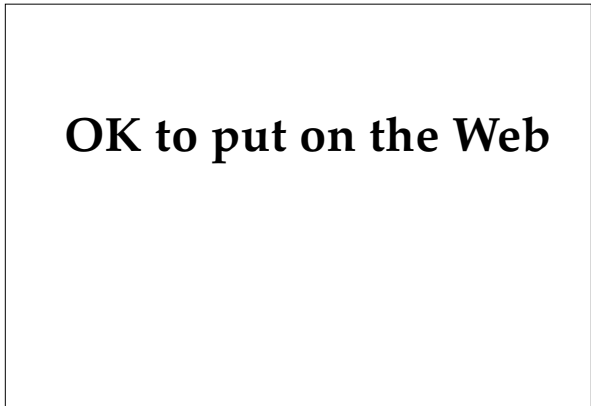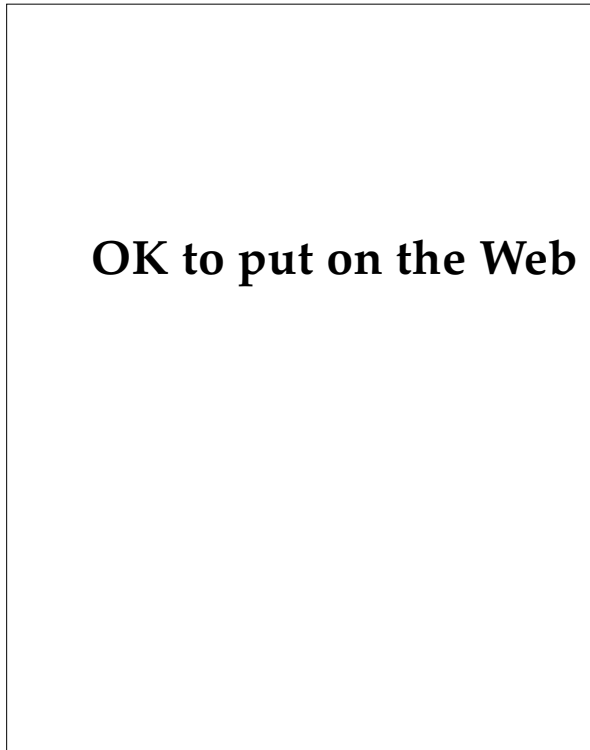
**Fig. 14-8.** Histology of lepromatous leprosy, low power. Foamy histiocytes loaded with *Mycobacterium leprae* bacilli are found diffusely infiltrating the dermis. Note the typical grenz zone beneath the epidermis and adjacent to the hair follicle.

**OK to put on the Web**

**EXHIBIT 14-2**

**THE DIAGNOSIS OF TUBERCULOID TUBERCULOID LEPROSY**

---



**Fig.14-11.** Tuberculoid leprosy, low power. Elongated, noncaseating granulomata coursing along the peripheral nerve twigs are characteristic.

← **Fig. 14-10.** Tuberculoid leprosy. A young Filipino man presented with this single, anesthetic, peripherally infiltrated plaque on his ankle. Note the central clearing and postinflammatory hypopigmentation.

**Clinical Features**

- One or a few hypopigmented or erythematous macules and plaques may be seen.
- The plaques are well defined, dry, scaly, and indurated (particularly at the periphery), and somewhat saucer shaped. The lesions may show central clearing or postinflammatory hyperpigmentation (Figure 14-10).
- Due to significant nerve involvement, impairment or complete loss of sweating and of sensation are common within the lesions.
- Alopecia may be partial or complete within the lesions.
- Thickening or tenderness or both in the nerves feeding or supplying the patch may be appreciated.

**Histological Features**

- Compact, often elongated, epithelioid granulomas surrounded by lymphocytes tend to be located just beneath the epidermis, and extend to the middermis or deep dermis (Figure 14-11).
- Infiltration and complete destruction of small cutaneous nerves is a constant feature (nerves may be unidentifiable). Histiocytes may be seen within the small nerves.
- The acid-fast bacilli are difficult to demonstrate by special stains, but can be seen with electron microscopy.
- Bacterial Index (Ridley) = 0-1

**EXHIBIT 14-3****THE DIAGNOSIS OF BORDERLINE BORDERLINE LEPROSY**

---

**Clinical Features**

- The lesions of borderline leprosy show morphology combining features of both tuberculoid and lepromatous leprosy.
- The number of lesions resembling tuberculoid morphology is almost equal to those resembling lepromatous leprosy.
- Lesions are bilateral but asymmetrical.
- Lesions are numerous but countable.
- Nerves may be thickened or tender or both.

**Histological Features**

- The granuloma is marked by the presence of epithelioid cells, absence of giant cells, and scanty lymphocytes scattered all over the lesion.
- A subepidermal zone relatively free of lesions is formed.
- The structure of the nerves is generally maintained, although they have been infiltrated by epithelioid cells.
- The acid-fast bacilli are easily demonstrable.
- Bacterial Index (Ridley) = 3–4

**EXHIBIT 14-4****THE DIAGNOSIS OF BORDERLINE LEPROMATOUS LEPROSY**

---

**Clinical Features**

- Lesions show morphology of both tuberculoid and lepromatous leprosy. However, the lesions resembling lepromatous morphology are much more numerous than those resembling tuberculoid.
- The lesions are bilateral and tend to be symmetrical.
- The lesions are numerous and may be uncountable.
- Nerves may show thickening or tenderness or both.

**Histological Features**

- The presence of granulomata consist of histiocytes, lymphocytes, and macrophages containing acid-fast bacilli. The granulomata are diffuse and located in the mid- and lower dermis.
- The structure of the nerves is maintained, although they are infiltrated by histiocytes. Their classic “onion-peel” appearance is the hallmark of the diagnosis.
- Acid-fast bacilli are easily identifiable.
- Bacterial Index (Ridley) = 4–5

#### EXHIBIT 14-5

#### THE DIAGNOSIS OF BORDERLINE TUBERCULOID LEPROSY

---

##### Clinical Features

Borderline tuberculoid leprosy may appear similar to tuberculoid leprosy, with the following exceptions:

- Satellite lesions are present.
- Lesions number fewer than 10.

##### Histological Features

- The well-developed granulomata are formed by epithelioid cells and plentiful lymphocytes. Giant cells are either absent or occasional. The granulomata are elongated due to their presence along the nerves.
- Dermal nerves are swollen with infiltrate, but are recognizable in the earlier stages. Later the nerves may be destroyed by the granulomatous reaction. Another common pattern is an intense epithelioid cell granulomatous infiltrate encroaching on the basal epithelium.
- Bacterial Index (Ridley) = 0-2

#### EXHIBIT 14-6

#### THE DIAGNOSIS OF INDETERMINATE LEPROSY

---

##### Clinical Features

- The number of lesions is usually one or a few.
- The lesions are hypopigmented, irregularly shaped macules in patients with dark skin, and may be erythematous in patients with lighter skin.
- The lesion margins are vague and ill-defined.
- Their surface is smooth and no infiltration is present.
- Sensations are equivocal.
- Nerves may or may not be thickened.

##### Histological Features

- There is a lymphocytic and histiocytic infiltrate around the adnexa, blood vessels, and nerve twigs of the upper dermis. The diagnosis requires clinical suspicion and is confirmed by the finding of acid-fast bacilli within the nerves.
- Bacterial Index (Ridley) = -/+

**EXHIBIT 14-7**

**THE DIAGNOSIS OF PRIMARY NEURITIC LEPROSY**

---



**OK to put on the Web**

**Fig. 14-12.** This patient has advanced neuritic leprosy. Note the interosseus muscle wasting in the hand caused by infiltration and destruction of the peripheral motor nerves.

**Clinical Features**

- There are no skin lesions—either present or past.
- Nerves are thickened or tender or both.
- The involvement of the nerves is asymmetrical.
- Sensations are lost in this order: temperature, touch, pain.
- Tendon reflexes normal or exaggerated.
- The muscles supplied by affected nerves atrophy (Figure 14-12). In the late stages, contractures and deformities may be present.

**Histological Features**

- A histological diagnosis of indeterminate leprosy is made when the nerve shows lymphocytic infiltration.
- A diagnosis of tuberculoid leprosy is made when the infiltrate contains epithelioid cells (with or without giant cells) and lymphocytes.
- A diagnosis of borderline leprosy is made when some foam cells are present in addition to the above.
- A diagnosis of lepromatous leprosy is made when macrophages are filled with acid-fast bacilli and a round cell infiltrate.
- A diagnosis of lepromatous neuritis is made when a mononuclear infiltrate is present, with fibrosis and hyalinization.



lepromatous leprosy group has been subdivided into polar lepromatous (LLp) and a subpolar lepromatous (LLs) forms. The subpolar lepromatous classification is used to differentiate those patients who were previously in an unstable borderline group and who “downgraded” into lepromatous disease through lack of treatment and waning immunity. The main reason for the subdivision is that the patients in the subpolar lepromatous leprosy group are capable of regaining their lost cell-mediated immunity during an “upgrading” (ie, reversal) reaction. Thus, although their conditions resemble polar lepromatous leprosy clinically, these patients are immunologically unstable, and, with chemotherapy, may become bacteriologically negative much sooner than with the polar lepromatous leprosy form. Similarly, the tuberculoid leprosy (TT) form of the disease has been divided into polar and subpolar (TTp and TTs), the subpolar form designating those patients who have developed tuberculoid leprosy on a secondary basis, an upgrading from their previous borderline form.<sup>5</sup>

Patients with lepromatous leprosy present with a large number of symmetrically distributed, cutaneous lesions, which may include macules, papules, infiltrated plaques, nodules (known as lepromas), or edematous, diffusely infiltrated skin. Lesions may vary from a few millimeters in size to several centimeters, be skin-colored, erythematous, or hypopigmented, and tend to localize in the cooler areas of the body. Infiltration of the earlobes is characteristic. Loss of hair may occur from the scalp, eyebrows, and eyelashes. The latter two are particularly characteristic. Nodular infiltration of the face, particularly around the orbits, may result in the grotesque leonine facies. Histological examination of lesions reveals granulomas composed of numerous foam cells stuffed with acid-fast bacilli.

In contrast, patients with tuberculoid leprosy typically present with one or a few asymmetric, erythematous or hypopigmented plaques, from a few centimeters to several decimeters in diameter. These tend to be thicker at the periphery than in the center, forming a platelike topography. Complete central clearing may occur. Dyspigmentation is common, particularly in people with darker skin color. Significant nerve involvement with anesthesia is the rule in this form, often corresponding to the nerve supplying the area of involved skin. Histologically, acid-fast bacilli are absent to very rare. The dermis may contain a few to numerous epithelioid granulomas with mantles of lymphocytes. Infiltration and destruction of small cutaneous

nerves is a prominent feature.

The clinical features of borderline leprosy are intermediate between lepromatous and tuberculoid. Lesions resembling those in lepromatous leprosy appear approximately equal in number to those resembling tuberculoid leprosy. Lesions are numerous but countable, bilateral, but not symmetric. Pathologically, nerves are infiltrated but not destroyed, and acid-fast bacilli are easily seen.

Borderline lepromatous leprosy is characterized by lesions resembling those found in both lepromatous and tuberculoid leprosy, but with the lepromatous lesions predominating. Similarly, borderline tuberculoid leprosy consists primarily of up to 10 asymmetric tuberculoid plaques surrounded by satellite nodules, resembling those seen in lepromatous leprosy. Both represent intermediate transitional forms—both clinically and histologically—between borderline and lepromatous or tuberculoid leprosy, respectively.

Indeterminate leprosy is recognized as a definite clinical entity, but there is no unanimity of opinion regarding its frequency, significance, and prognosis. Patients present with a single macule or a few asymmetrical macules, with alterations in color but with no change in the surface texture or consistency of the skin. The peripheral nerves are usually normal. Slit-skin smears are usually negative. To confirm the diagnosis, sensory impairment or histological evidence of acid-fast bacilli or infiltrate must be present selectively in a nerve bundle in the dermis. Thermal sensibility may be lost earlier than tactile sensibility.<sup>16</sup> Indeterminate leprosy has a variable course: in approximately 75% of patients, the disease remits spontaneously; the remainder progress to one of the established forms of the disease.<sup>14</sup>

Primary neuritic leprosy is increasingly being recognized as a clinical form of presentation. Most will be of the paucibacillary type. A lepromin test, the number of nerves affected, and nerve biopsy may all give some indication of the correct classification, but further research is needed to provide reliable clinical indicators for correct classification of patients with primary neuritic leprosy within the Ridley-Jopling system.<sup>16</sup>

Skin biopsies from anesthetic areas may fail to show histological changes suggestive of leprosy. Cutaneous nerve biopsy (a simple office procedure discussed above) can be performed for both histopathological examination and for acid-fast bacilli staining. This technique yields surprisingly good results.<sup>24</sup>

## TREATMENT

The treatment of leprosy varies considerably depending on the number of bacilli present and whether reactional states are present. WHO has recommended standard treatments for each type of leprosy (Figure 14-13).

### Paucibacillary Leprosy

The 1988 WHO recommendations for the standard treatment of paucibacillary leprosy are as follows<sup>16</sup>:

- Rifampin 600 mg (450 mg for patients who weigh < 35 kg), once per month for 6 months (10 mg/kg in children<sup>17</sup>).
- Dapsone 100 mg daily for 6 months (1–2 mg/kg in children<sup>17</sup>).

The administration of rifampin should be fully supervised; on the other hand, dapsone may be given unsupervised. Relapses, which need to be distinguished clinically from delayed reversal reactions by slit-skin smear or biopsy, should be retreated with a 6-month course of the multidrug regimen outlined below.

### Multibacillary Leprosy

The 1988 WHO recommendations for the standard treatment of multibacillary leprosy are as follows<sup>16</sup>:

- Rifampin 600 mg once per month, supervised (10 mg/kg in children<sup>17</sup>).
- Dapsone 100 mg daily, self-administered (1–2 mg/kg in children<sup>17</sup>).
- Clofazimine 300 mg once per month, supervised, and 50 mg daily, self-administered (1–2 mg/kg in children for both the monthly and daily doses<sup>17</sup>).

This treatment should be continued for at least 2 years, and, wherever possible, up to smear negativity. In multibacillary leprosy, rifampin should *never* be used alone or in combination with dapsone without a third bactericidal drug because of the high prevalence of dapsone resistance and the high risk of the development of rifampin resistance.

The addition of monthly supervised doses of ethionamide or prothionamide to this regimen is not recommended by WHO, as the triple-

drug therapy is deemed adequate. Where clofazimine pigmentation has been objectionable, clofazimine has been replaced by daily thioamide (either ethionamide or prothionamide). However, this substitution is not recommended by WHO unless absolutely necessary, because it is now clear that the recommended daily dose of 50 mg is well accepted by patients and has a marked influence on the frequency and severity of reactional states.<sup>16</sup> Ethionamide and prothionamide can have serious hepatotoxic side effects, particularly when administered with rifampin. Both have poor gastrointestinal tolerance as well.

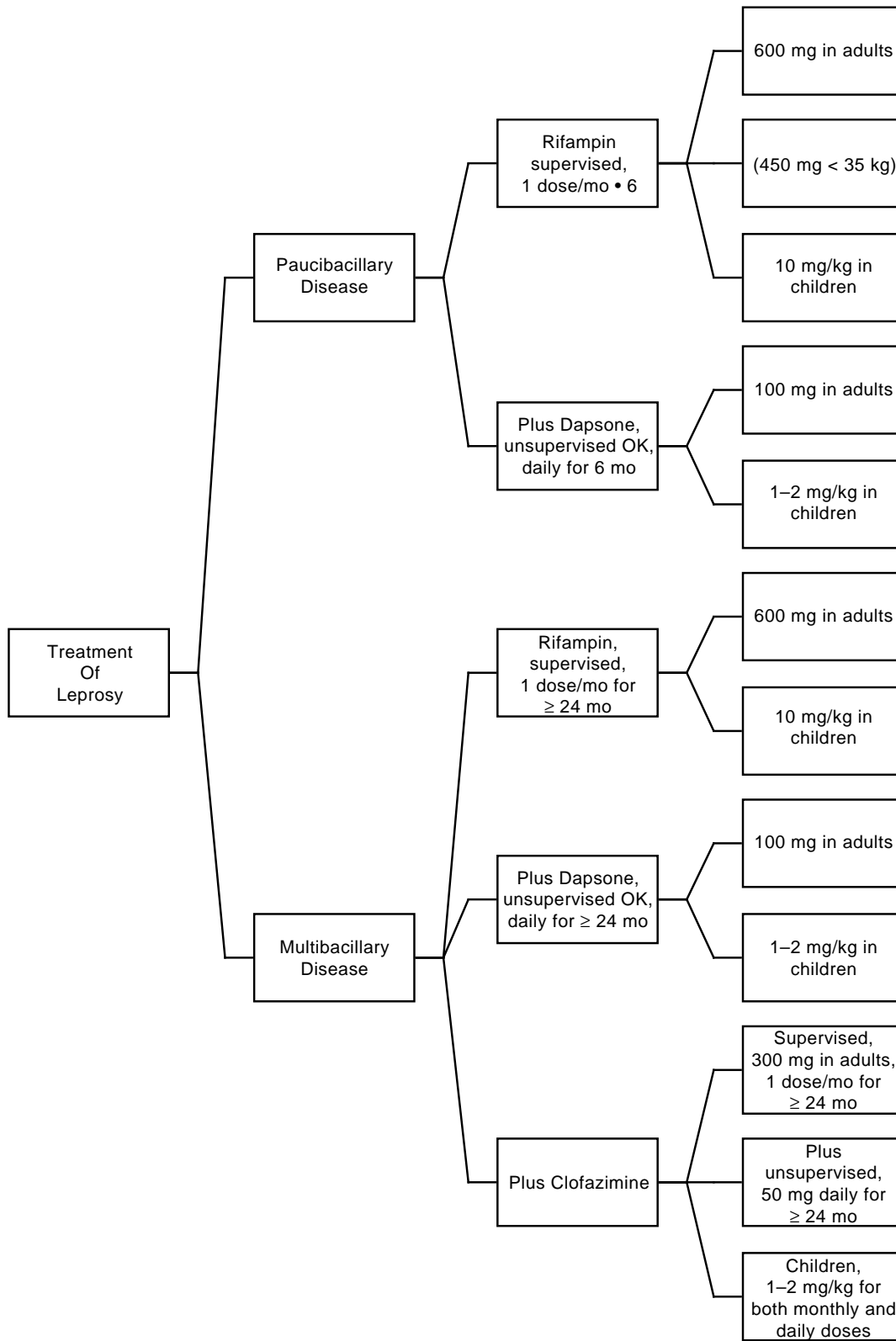
### The Most Potent Antileprosy Drugs

#### Rifampin

Rifampin is by far the most potent drug against *M leprae*. A single dose of 20 mg/kg was shown (by the proportional bactericidal test method) to kill about 99% of the viable leprosy bacilli in the mouse footpad, while single, 600-mg doses of the drug given to previously untreated multibacillary patients rendered the bacilli harvested from biopsies taken 4 days later noninfectious for mice, suggesting that such a dose had killed at least 99% of the viable *M leprae*.<sup>29</sup> Rifampin induces the metabolism of dapsone, but in the usual clinical setting this is of little importance.<sup>30</sup>

#### Dapsone

Dapsone is a sulfonamide analog of *p*-aminobenzoic acid (PABA) that inhibits *M leprae*'s de novo synthesis of folic acid. The drug is essentially bacteriostatic. It is metabolized in the liver and excreted, as metabolites, in the urine. It is well absorbed in the gastrointestinal tract and well tolerated. Dapsone's mean half-life is 28 hours in human plasma. The predominant side effect is hemolytic anemia (especially with glucose-6-phosphate dehydrogenase deficiency). Another side effect, the dapsone syndrome, is a rare clinical syndrome that usually develops within 6 weeks of the start of therapy and consists of exfoliative dermatitis, hepatosplenomegaly, fever, generalized lymphadenopathy, and hepatitis. Agranulocytosis is occasionally seen.<sup>30</sup>



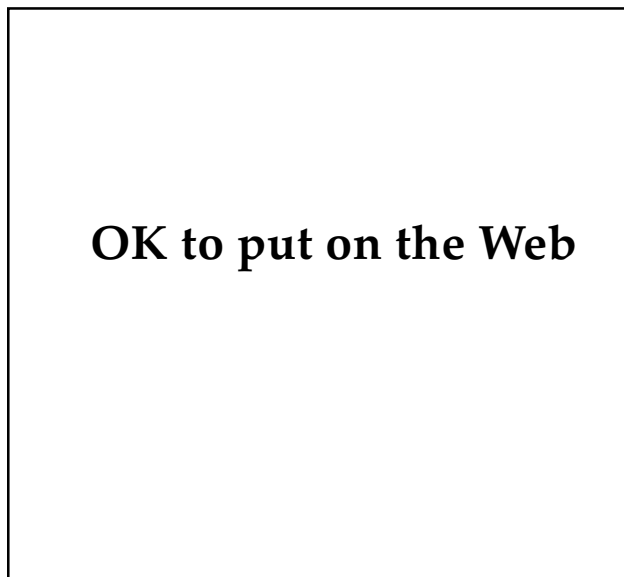
**Fig. 14-13.** World Health Organization guidelines for the treatment of uncomplicated leprosy. Data source: WHO Expert Committee on Leprosy. *World Health Organization Technical Report Series 768*. 6th report. Geneva, Switzerland: World Health Organization; 1988.

### Clofazimine

Clofazimine is the third-most-potent antileprosy drug, and has both antibacterial and anti-inflammatory effects. Its mechanism of action is not known. The drug has a complex pattern of distribution in the body, with high concentrations found in the reticuloendothelial system, the subcutaneous fat, and in the distal small bowel at the site of absorption. The half-life for elimination is estimated to be 3 months. The most dramatic side effect is dose-related skin pigmentation caused by drug accumulation (Figure 14-14). Gastrointestinal toxicity is caused by deposition of drug crystals in the distal small bowel and draining mesenteric lymph nodes.<sup>30</sup>

### Ethionamide and Prothionamide

Ethionamide and prothionamide are essentially identical in their effects and toxicities. Ethionamide is bactericidal in the mouse footpad system and has been used in leprosy treatment for more than 20 years. It is metabolized in the liver and excreted in the urine, with a mean half-life of 3 hours. A dose of 250 to 500 mg/d is used in adults. These drugs are hepatotoxic, but when used alone rarely present



**Fig. 14-14.** This patient with advanced lepromatous leprosy demonstrates significant dyspigmentation secondary to clofazimine accumulation within the lesions. Note the mild leonine facies, ear and nose deformities, and symmetry of the facial lesions.

a problem. When combined with rifampin, another hepatotoxic drug, the toxicities are additive. Because bacterial resistance may develop within a few years of treatment, combination therapy is mandatory.<sup>26</sup>

### Thalidomide

Thalidomide, a sedative-hypnotic widely used between 1957 and 1961, caused severe and characteristic fetal malformations (phocomelia) when taken by pregnant women between days 35 and 50 after the last normal menstrual period. In 1965, it was shown to be very effective in cases of erythema nodosum leprosum reactions and is now the drug of choice in men and nonfertile women. Thalidomide appears to inhibit de novo synthesis of IgM antibodies and to inhibit neutrophil chemotaxis. It has no antibacterial effect whatsoever. It is metabolized in the blood and excreted in the urine. Its half-life is 3.5 hours. Other than embryopathy, the only other significant side effect is a peripheral neuropathy.<sup>30</sup> Minor side effects, which are often transient, include dry mouth, rash, and constipation. Thalidomide is now supplied only through national governments that will indemnify the manufacturer (Chemie Grunenthal GmbH, Postfach 129, Zweifallerstrasse 24, 5190 Stolberg/Reinland, Federal Republic of Germany) against litigation<sup>31</sup> and is indicated only for Type 2 reactions (ie, erythema nodosum leprosum).<sup>32</sup>

### Drug Resistance

Extensive evidence shows that the emergence of secondary resistance of *M leprae* to dapsone is a worldwide phenomenon, occurring in as many as 40% of treated multibacillary patients in some areas. They are resistant to high or intermediate levels of the drug. During the 1980s, primary dapsone resistance was found in up to 70% of newly detected, previously untreated patients. Most primary resistant strains of *M leprae* have been shown to be resistant to low or intermediate levels of dapsone.<sup>16</sup>

From data collected during the 1980s, it has become clear that when rifampin is used alone, secondary resistance develops easily and rapidly in multibacillary patients with leprosy. No primary resistance is known at present.

Clofazimine resistance is unknown or unconfirmed.

Secondary resistance to ethionamide has been demonstrated in patients treated with ethionamide

alone. Resistant strains of *M leprae* have also shown cross-resistance to prothionamide, thiacetazone, and thiambutosine.

### Microbial Persistence

Viable, fully drug-susceptible *M leprae* that are able to survive for many years in patients with lepromatous leprosy, despite the presence of bactericidal concentration of an antileprosy drug, are termed *persisters*. They have been detected in about 10% of all biopsy specimens from patients with lepromatous leprosy who are receiving multidrug regimens containing rifampin—irrespective of the regimen or duration of treatment. It therefore seems likely that none of the existing drugs, used alone or in combination, greatly affects the occurrence of persisters.<sup>33</sup>

No clear relationship has yet been established between the existence of persisting organisms and the occurrence of relapses, and accumulating evidence from clinical trials is beginning to suggest that persisters may not pose a serious threat of relapse in patients who complete multidrug therapy, at least as far as early relapses are concerned. The rate of relapses following multidrug therapy in

paucibacillary cases is about 1%, for multibacillary cases about 0.2%.<sup>33</sup>

### Promising New Drugs

The quinolones pefloxacin and ofloxacin act by inhibiting DNA synthesis during bacterial replication, probably by interfering with DNA gyrase (topoisomerase) activity. Several rifampin derivatives, ansamycins, have shown antilepromatous activity up to 7-fold greater than rifampin. Like rifampin, however, they are very expensive.<sup>34</sup>

Minocycline has been shown to be much more bactericidal for *M leprae* than any other drug except rifampin. Its high lipid solubility may allow it to penetrate the outer capsule and cell wall. It apparently has additive effects when used in combination with dapsone and rifampin.<sup>34</sup>

Streptomycin is bactericidal and is synergistic with rifampin, even when given once per month.

Deoxyfructo-5-hydroxytryptamine (DF5-HT) has shown an ability to clear bacilli faster than dapsone, perhaps due to an immunostimulating effect.<sup>34</sup>

Investigational work is being done on clofazimine derivatives, including long-acting dapsone injections, macrolides, and pyrazinamide, among others.<sup>34</sup>

## COMPLICATIONS: THE REACTIONAL STATES

Were it not for its various reactional states, which represent alterations in host immunity, leprosy would be considered a rather straightforward bacterial disease with a “cookbook” approach to therapy. Fortunately, however, the reactional states that are the source of so much difficulty—for healthcare providers as well as for patients—have also stimulated significant research into leprosy and the immune system. Currently, there are four well-recognized reactional states: (1) reversal reaction, also called Type 1; (2) erythema nodosum leprosum, also called Type 2; (3) downgrading reaction; and (4) Lucio’s phenomenon (Figure 14-15). All reaction states are uncommon in children with leprosy. In a series of 132 cases of leprosy in children from northern India, 4 patients (3%) had reversal reactions, 2 (1.5%) had downgrading reactions, and only 1 (0.7%) had a Type 2, or erythema nodosum leprosum, reaction.<sup>19</sup>

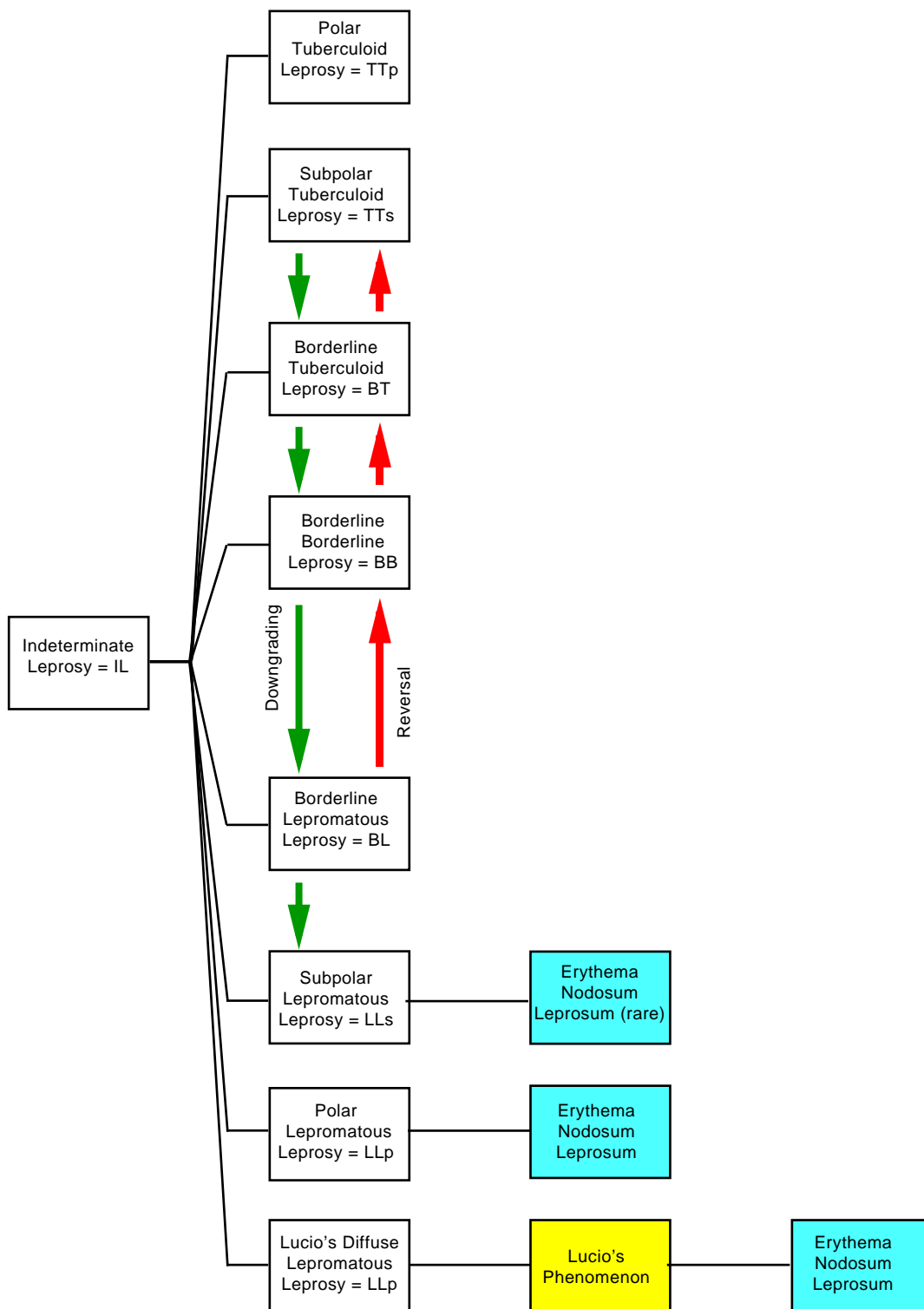
### Reversal Reaction

Reversal reactions, also called Type 1 reactions, occur in patients with unstable borderline disease

in the Ridley-Jopling classification scheme (ie, BT, BB, BL), who experience a rapid increase in specific cell-mediated immunity often brought on by either treatment or improved nutrition. This reaction is called a *reversal* because patients with borderline disease typically worsen slowly in the opposite direction (ie, toward the lepromatous end of the spectrum), but in this reaction, the patients are improving slightly (ie, the downward spiral of the natural course of the disease is reversing).

The reversal reaction is a Type IV hypersensitivity reaction, in which the host has an increased immune response against the antigens of *M leprae*. Thus, in terms of the killing and clearing of bacteria, this reaction is beneficial. However, the inflammation, particularly in nerve tissue, may be devastating. It is important to warn patients with borderline disease ahead of time about reversal reactions; otherwise, when the inflammation occurs, the patient may think the therapy is not working, lose confidence in the physician, and risk permanent disability from neglect.<sup>32</sup>

Most commonly, reversal reactions occur during the first 6 months of treatment, particularly in pa-



**Fig. 14-15.** The possible reactional states in leprosy: reversal reaction, also called Type 1 (red); erythema nodosum leprosum, also called Type 2 (blue); downgrading reaction (green); and Lucio's phenomenon (yellow). Note that erythema nodosum leprosum can occur via three pathways.

tients with borderline borderline (BB) and borderline tuberculoid (BT) leprosy. The normal progression in clinical classification in reversal reactions is

LLs → BL → BB → BT → TTs

The cardinal signs of a reversal reaction are the rapid development of erythema, warmth, and swelling in one or several preexisting clinical lesions (Figure 14-16). Nerve involvement, seen clinically as pain, swelling, and motor or sensory disturbances, is common and can constitute a medical emergency. Delay of treatment for even 2 days may result in severe adverse effects (eg, paralysis of the ulnar nerve, causing claw hand; of the lateral popliteal nerve, causing foot drop; and of the facial nerve, causing facial palsy). In the field or clinic, the following simple test of nerve function<sup>32</sup> can rapidly be carried out by checking

- the eyes for complete closure and normal blinking;
- the hand for loss of sensation, using nylon bristles or a ballpoint pen, and for loss of strength by abduction of the fifth finger and opposition of the thumb against firm pressure; and
- the foot for loss of sensation as above, and for loss of strength by dorsiflexion of the foot against firm pressure.

Systemic symptoms such as fever or malaise are unusual. Associated findings may include edema of the hands, feet, and face in any combination. Rarely, new lesions with tuberculoid characteristics may develop and cause confusion with a downgrading reaction. However, histology and lepromin testing are confirmatory.<sup>5</sup>

### Histological Findings

Histological findings show a shift of classification toward the tuberculoid end of the spectrum. Edema is present; the bacilli are reduced; and increased numbers of defensive cells such as lymphocytes, epithelioid cells, and giant cells are seen.

### Treatment

Systemic corticosteroids are very effective in reducing the edema and inflammation in reversal reactions and, thus, are most helpful in preventing nerve damage (Figure 14-17). Initial doses of prednisone, 40 to 80 mg/d for 5 to 7 days, may alleviate neuritis and edema. Tapering must be done slowly: the dose must not be reduced by more than 5 mg once or twice per week. Treatment with prednisone for 3 to 6 months is necessary in most cases and is definitely associated with decreased frequency and severity of disabilities and deformities as compared to shorter courses of prednisone.<sup>35</sup>

Thalidomide is not useful in the treatment of reversal reactions. Clofazimine's usefulness has not been clearly demonstrated for acute reversal reactions, in contrast to its usefulness in erythema nodosum leprosum, but clofazimine does play a role in chronic reversal reactions, where it may be steroid sparing. When used, clofazimine is begun at 100 mg three times daily for 6 weeks; then, if steroid sparing, reducing the dose to twice daily for several months, then daily for a few more months.<sup>35</sup>



OK to put on the Web

**Fig. 14-16.** Type 1 reversal reaction. This Filipino woman developed a rapid increase in erythema, warmth, and swelling in her preexisting lesions of borderline lepromatous leprosy.

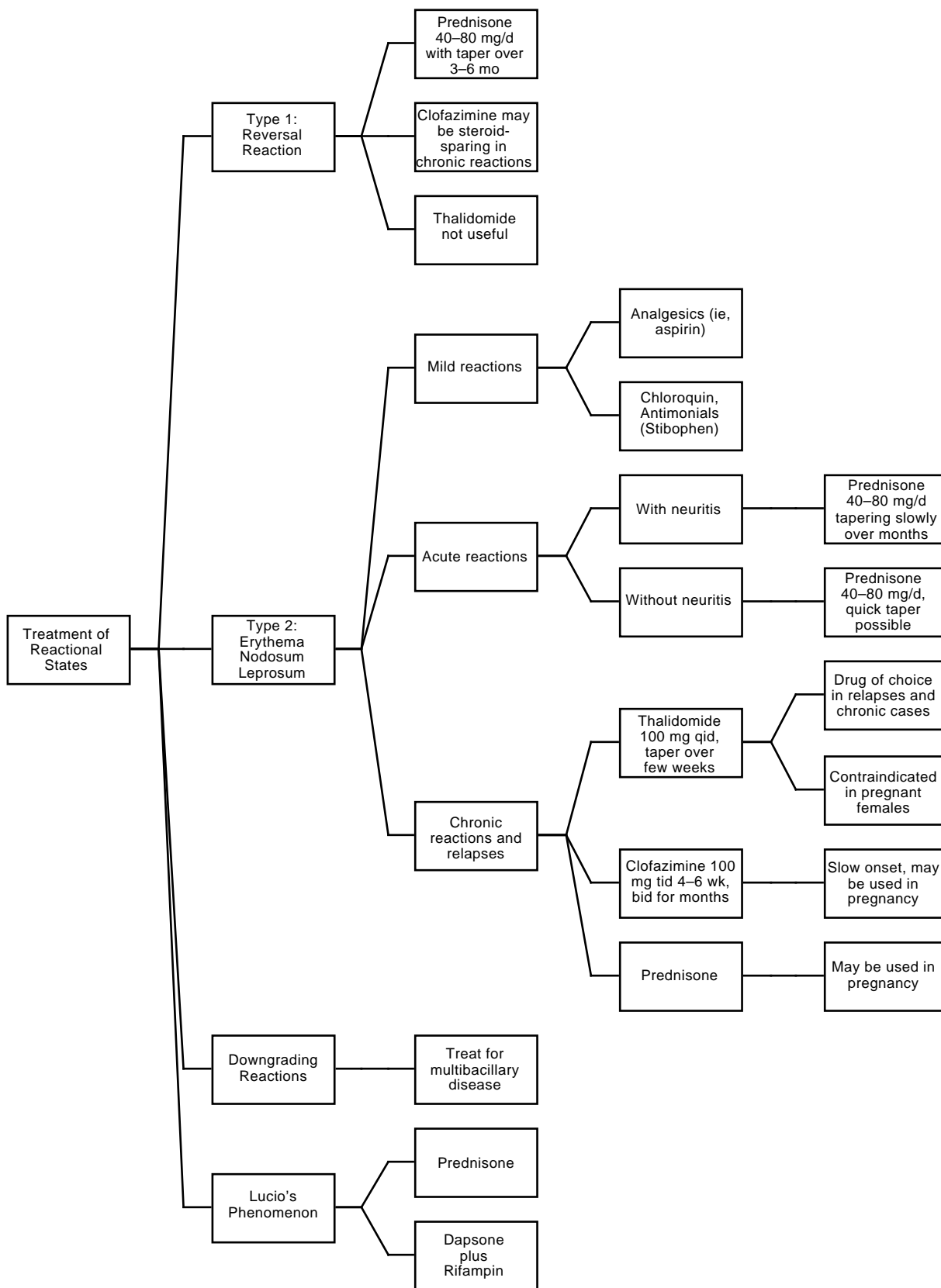


Fig. 14-17. Treatment algorithm for reactional states in leprosy .



## Erythema Nodosum Leprosum

Erythema nodosum leprosum, also called the Type 2 reaction, is named for its most prominent clinical finding: an eruption of tender, red nodules. It is an immune complex disease, a Type III hypersensitivity reaction, and occurs almost exclusively in patients with lepromatous leprosy (LLp and LLs), and only occasionally in patients with borderline leprosy (BL). Antigens of *M leprae* and antibodies form immune complexes with complement, which precipitate in the tissues of the skin, blood vessel walls, nerves, and other organs; these precipitates attract neutrophils, which further damage the tissues. Predisposing factors include infections (eg, malaria, filaria, bacterial infections), trauma, surgery, physical or psychological stress, immunizations or vaccinations, pregnancy, parturition, ingestion of potassium iodide, and antileprosy therapy (ie, dapsone, thiacetazone, rifampin).<sup>5</sup>

Clinically, the preexisting lesions of leprosy remain unchanged. However, new crops of brightly erythematous, painful nodules may come and go. Fever and malaise are common. The reaction tends to occur late in treatment, unlike reversal reactions, and often at a time when the skin lesions are quiescent and most of the bacteria are granular on the morphologic index. The skin lesions alone are also known as erythema nodosum leprosum. The lesions tend to be small, variably sized, slightly raised, tender nodules and plaques, which are brightly erythematous, warm, and blanchable. In contrast to classic erythema nodosum, the lesions of erythema nodosum leprosum last only 2 to 3 days, often resolving with hyperpigmented residua. They can be very numerous and widely disseminated. The scalp and the intertriginous areas tend to be spared. The lesions leave a blue stain when they regress. Associated features of Type 2 reactions include nerve pain, periosteal pain (especially in the tibia), myalgias or myositis or both, arthralgias or arthritis or both, rhinitis, epistaxis, acute iritis, dactylitis, lymphadenitis (especially the femoral chain), acute epididymo-orchitis, and proteinuria. Although nerve involvement occurs both in reversal and Type 2 reactions, it progresses much more slowly in the latter. If left untreated, however, it may still produce severe and extensive nerve damage. Edema of the hands and feet can be one of the major presenting features of erythema nodosum leprosum. If edema is present for more than a few days, stiffness and deformity of the fingers may result, hence treatment is imperative. Overall, erythema nodosum

leprosum tends to be a chronic, smoldering process that often lasts for years.

In the laboratory, circulating immune complexes can be detected. Additionally, tests for antinuclear antibody and rheumatoid factor may be positive.

### Histological Findings

Existing leprosy lesions show some edema. Erythema nodosum leprosum lesions show a leukocytoclastic vasculitis of both veins and arterioles; polymorphonuclear lymphocyte infiltrate; and scanty, fragmented bacilli.

### Treatment

Mild cases of erythema nodosum leprosum may hardly be noticed and often respond to minor symptomatic care with analgesics such as aspirin. Chloroquin and antimonials such as stibophen have also been used for mild cases, but are not indicated for neuritis or chronic reactions. Stibophen is given as a 5-mL intramuscular injection on alternate days for 3 doses. A second course may be given after a 2-week interval.<sup>32</sup>

Treatment for more extensive or severe Type 2 reactions requires systemic corticosteroids or thalidomide.<sup>35</sup> Acutely, prednisone in doses of 40 to 80 mg/d is begun. In the absence of neuritis, the dosage may be tapered moderately quickly once symptoms have been suppressed. Relapse is common and the dosage needs to be individualized. Where neuritis is present (or if nerve function has been lost within the preceding 6 mo), daily corticosteroids may be necessary for months. If the daily dose remains above 30 mg of prednisone, then switching to alternate-day steroids may be helpful. However, if nerve pain returns on the "off" day, then the physician must assume that nerve damage is occurring and reinstitute daily steroids. For acute, painful, hand edema, splinting of the hands in a position of function for a few days, as well as administering prednisone, are indicated. Subsequently, physical therapy may be started to prevent stiffness and loss of function. Thalidomide has rapid onset of action, often bringing relief within 24 hours. It is steroid sparing. Consequently, it is a drug worthy of serious consideration in severe erythema nodosum leprosum.<sup>31</sup>

For more chronic cases or for relapses, thalidomide is the drug of first choice (except in fertile women, due to its teratogenicity). The initial dose is 100 mg four times daily, which can be tapered

within a week to 100 to 200 mg/d. Further tapering to 50 to 100 mg/d may be possible. This dosage may need to be continued for 1 to 2 months, then discontinued. If erythema nodosum leprosum recurs, treat again with thalidomide.<sup>35</sup>

Alternatively, clofazimine can be beneficial, not only in suppressing the reaction, but also in its antibacterial and steroid-sparing effects. Unfortunately, its onset of action is delayed for 4 to 6 weeks. Clofazimine is given 100 mg three times daily for 4 to 6 weeks, then tapered to twice daily for several more months. Gastrointestinal intolerance may force a reduction in dose to 100 mg/d. The other major side effect of clofazimine is skin darkening.<sup>35</sup>

Some patients may require a combination of all three medications. In select circumstances such as in the case of nerve entrapment, surgical decompression may be indicated.<sup>35</sup>

In pregnancy, clofazimine and steroids may be used, as well as dapsone. However, thalidomide is absolutely contraindicated. Rifampin has also been associated with fetal anomalies (in animals only)<sup>35</sup>; hence its use should be avoided in pregnant women.

### Downgrading Reaction

Untreated patients are sometimes seen with a reaction that clinically appears similar to a reversal reaction, but who are, in fact, undergoing a downward shift in their immunity toward the lepromatous end of the spectrum. They are described as having a downgrading reaction. However, the diagnosis is difficult to make unless the patient is followed for a long period of time.

There is a shift in the Ridley and Jopling Classification system toward the lepromatous end of the spectrum, with an increase in bacilli and macrophages, and a decrease in lymphocytes, epithelioid, and giant cells.

The treatment for downgrading reactions is the same as that for multibacillary disease. Where drug-resistant organisms are suspected, additional measures (eg, the administration of additional and more toxic antibiotics) may be necessary.

### Lucio's Phenomenon

The fourth state, Lucio's phenomenon, is a rare type of acute, reactional leprosy. This state occurs only in patients with Lucio's leprosy, the rare, diffuse, nonnodular form of lepromatous leprosy that is seen in Mexico and Central America. Lucio's phenomenon is unique in that it occurs only in untreated patients. The reaction is characterized by crops of painful, tender, red macules that become purpuric, then necrotic, and finally ulcerative. The lesions eventually heal with atrophic, stellate scars. Patients are usually afebrile. The extremities are involved predominantly.

The lesions are essentially due to a necrotizing vasculitis that is caused by circulating immune complexes including mixed cryoglobulins.<sup>36</sup> Apparently, patients with Lucio's phenomenon have a deficient cell-mediated defense mechanism that permits unhindered multiplication of bacilli and production of circulating bacterial antigen. Production of antibodies by an active humoral immune system then results in vasculitis, infarction, and skin necrosis.

Histological findings include ischemic epidermal necrosis; necrotizing vasculitis of small blood vessels in the upper dermis; severe, focal, endothelial proliferation of middermal vessels; and large numbers of bacilli in the endothelial cells.<sup>5</sup>

Treatment with corticosteroids or dapsone combined with rifampin is beneficial. Thalidomide is of no value.<sup>5</sup> Many of these patients will develop the Type 2 reaction, erythema nodosum leprosum, once definitive antilepromatous therapy is begun.

## VACCINATION

Information on the value of Bacille bilié de Calmette-Guérin (BCG) vaccination against leprosy is available from five large field studies conducted by WHO<sup>16</sup>: the protective effect of BCG was generally high (80%) in Uganda, moderate (45%–55%) in Malawi and Papua New Guinea, and low (20%–30%) in Burma and India. In all these studies, the observed protective effect of BCG was primarily against paucibacillary leprosy. Currently, studies

are underway to assess the use of vaccines of killed *M leprae* combined with BCG versus BCG alone in 120,000 subjects in Malawi.<sup>16</sup>

The goal is to produce a genetically engineered, safe, potent leprosy vaccine consisting of highly immunogenic BCG that contains the appropriate genes of *M leprae*. This approach may allow those antigens associated with a protective immune response to be expressed.<sup>14</sup>

## LEPROSY AND ACQUIRED IMMUNODEFICIENCY SYNDROME

Because leprosy is associated with a defect in cell-mediated immunity, and because tuberculosis is now seen as a presenting sign of acquired immunodeficiency syndrome (AIDS), will leprosy also be seen as a presenting sign of AIDS, especially because AIDS suppresses cell-mediated immunity?

The only data on this question have been reported from rural Zambia. This study<sup>37</sup> included all patients with tuberculosis and leprosy at the Chikankata Salvation Army Hospital who were seen from October to December 1987. Of 27 patients with leprosy, 18 had new cases. Of those 18 new patients,

6 (33%) also had antibodies to human immunodeficiency virus (HIV), as detected by the Wellcozyme VK51 (ELISA) test. Positive results were confirmed on a second date and then reconfirmed using other serologic testing. Because the serologic prevalence of infection with HIV was significantly higher than that found in blood donors and surgical patients, and because the patients with leprosy tended to have more serious symptoms such as paralysis or neuritis, rather than a skin lesion, this study suggests that AIDS may predispose to leprosy. For comparison, 50% of the confirmed cases of tuberculosis showed evidence of HIV infection.

### SUMMARY

Leprosy is an infectious disease caused by the bacterium *Mycobacterium leprae*. The major source of infection is patients already infected with the most severe form of the disease, lepromatous leprosy, who shed millions of organisms per day in their nasal secretions. Acquisition of the disease requires prolonged contact with patients with lepromatous leprosy, and fewer than 1% of exposed individuals will ever develop the disease. Of those who do, 75% will heal spontaneously. Thus, only about 0.25% of exposed individuals ever develop clinical disease, and then many months or years after exposure.

The disease can take a wide variety of forms, depending on the immune status of the patient. Initially, no lesions or nondiagnostic hypopigmented macules are seen. This stage is known as indeterminate leprosy. Over time, 25% of these patients will progress to a more serious form of the disease. Those with poor immunity tend to develop the widely disseminated, symmetric, infiltrated papules and plaques of lepromatous leprosy, the skin lesions of which teem with acid-fast organisms. The involvement of the internal organs may be substantial in such patients. Patients with good immunity tend to develop one or a few asymmetric, indurated plaques, with a tendency for central clearing associated with significant nerve involvement. Other patients with moderate immunity develop an intermediate form—between lepromatous and tuberculoid leprosy—known as borderline leprosy. Patients whose disease leans more toward lepromatous leprosy than tuberculoid are said to have borderline lepromatous leprosy; whereas those

whose disease leans more toward the tuberculoid side are said to have borderline tuberculoid leprosy.

Diagnosis is made on the basis of clinical findings including characteristic skin lesions, nerve involvement with anesthesia or nerve enlargement, and demonstration of acid-fast organisms in biopsies, nasal secretions, or from slit-skin preparations.

Currently, for treatment purposes, paucibacillary disease is defined as being smear negative, whereas multibacillary disease is defined as being smear positive. WHO treatment guidelines for both paucibacillary and multibacillary disease should be followed exactly and continued for a minimum of 2 years and until the smear is negative. Deviating from the guidelines may lead to antibiotic-resistant organisms.

Reactional states are frequent in leprosy. They constitute fluctuations in the patient's immune status that may be deleterious to the patient's health and lead to life- and limb-threatening complications. There are four reactional states. Type 1 reactions, also called reversal reactions, occur early in treatment in patients with unstable borderline disease of the borderline tuberculoid (BT), borderline borderline (BB), or borderline lepromatous (BL) types. Here, because of improving immunity, inflammatory reactions develop in preexisting lesions and may result in nerve paralysis. Reversal reactions constitute a medical emergency. Prednisone continues to be the initial drug of choice. The Type 2 reaction, also called erythema nodosum leprosum, is a Type III immune-complex hypersensitivity reaction that occurs primarily in long-stand-

ing lepromatous leprosy of the lepromatous lepromatous polar or subpolar (LLp or LLs) forms, or, rarely, in borderline lepromatous (BL) disease. Systemic symptoms (eg, fever and malaise, neuritis, myalgias and arthralgias) accompany the bright-red crops of new, painful skin nodules. The third reactional state is called downgrading, in which the patient slips toward the lepromatous end of the spectrum. Downgrading reactions are difficult to diagnose, appear similar to reversal reactions, and are treated for ongoing or drug-resistant multibacillary disease. The fourth reactional state, Lucio's phenomenon, occurs only in patients who have the diffuse lepromatous leprosy known as Lucio's leprosy. The reaction, a necrotizing cutaneous

vasculitis, occurs only in untreated patients.

Medical officers need to understand that leprosy does not constitute a health threat to most troops. Prolonged, intimate contact with untreated individuals with lepromatous leprosy is necessary to transmit the disease, and more than 99% of all exposed individuals will resist infection. Such conditions are present in underdeveloped areas of the world, and may certainly be exacerbated by conditions of war (eg, famine, confinement, internment in concentration camps). Despite these well-established medical facts, the popular concept of leprosy—a horrible, disfiguring, infectious disease sent as a punishment from God—continues to terrify the uninformed.

## REFERENCES

1. Klingmüller V. Die lepra. In: Jadassohn J, ed. *Zehnter Band, Zweiter Teil, Handbuch der Haut- und Geschlechtskrankheiten*. Berlin: Verlag von Julius Springer; 1930.
2. Doull JA. Leprosy. In: Hoff EC, ed. *Communicable Diseases Transmitted Through Contact or by Unknown Means*. In: Coates JB Jr, ed. *Preventive Medicine in World War II*. Vol 5. Washington, DC: Medical Department, US Army, Office of The Surgeon General; 1960: 25–35.
3. Leviticus 13:12–13 (New International Version).
4. Unna PG. An exemplary instance of faulty scholarship. *Am J Dermatopathol*. 1983;5:569–574.
5. Jopling WH, McDougall AC. *Handbook of Leprosy*. 4th ed. Oxford, England: Heinemann Professional Publishing; 1988.
6. Skinsnes OK, Chang PH. Understanding leprosy in ancient China. *Int J Lep*. 1985;53:289–307.
7. Ell SR. Leprosy and social class in the Middle Ages. *Int J Lep*. 1986;54:300–305.
8. Ell SR. Plague and leprosy in the Middle Ages: A paradoxical cross-immunity? *Int J Lep*. 1987;55:345–350.
9. Ell SR. Three times, three places, three authors, and one perspective on leprosy in medieval and early modern Europe. *Int J Lep*. 1989;57:825–833.
10. Dayal R, Hashmi NA, Mathur PP, Prasad R. Leprosy in childhood. *Ind Ped*. 1990;27:170–180.
11. Sehgal VN, Joginder. Slit-skin smear in leprosy. *Int J Dermatol*. 1990;29:9–16.
12. Trautman JR. A brief history of Hansen's disease. *The Star*. 1990;50: 3–5, 15.
13. Noordeen SK. Leprosy control through multidrug therapy (MDT). *Bull WHO*. 1991;69:263–269.
14. Hastings RC, Gillis TP, Krahenbuhl JL, Franzblau SG. Leprosy. *Clin Microbiol Rev*. 1988;1:330–348.
15. Allen AM. *Skin diseases in Vietnam, 1965–72*. In: Ognibene AJ, ed. *Internal Medicine in Vietnam*. Vol 1. Washington, DC: Medical Department, US Army, Office of The Surgeon General, and Center of Military History; 1977.
16. WHO Expert Committee on Leprosy. *World Health Organization Technical Report Series 768*. 6th report. Geneva, Switzerland: World Health Organization; 1988.

17. Sehgal VN, Srivastava G. Leprosy in children. *Int J Dermatol*. 1987;26:557–566.
18. Brubaker ML, Meyers MW, Bourland J. Leprosy in children one year of age and under. *Int J Lep*. 1985;53:517–523.
19. Kaur I, Kaur S, Sharma VK, Kumar B. Childhood leprosy in northern India. *Ped Dermatol*. 1991;8:21–24.
20. Sehgal VN, Joginder, Sharma VK. Immunology of leprosy: A comprehensive survey. *Int J Dermatol*. 1989;28:574–584.
21. Centers for Disease Control. Update: Universal precautions for prevention of transmission of human immunodeficiency virus, hepatitis B virus, and other bloodborne pathogens in health-care settings. *MMWR*. 1988;37:377–382.
22. Pattyn SR. Minimal requirements for the laboratory diagnosis of leprosy in field conditions. *Acta Leprol*. 1983;1:33–40.
23. Ridley DS. Therapeutic trials in leprosy using serial biopsies. *Leprosy Review*. 1958;29:45–52.
24. Jacob M, Mathai R. Diagnostic efficacy of cutaneous nerve biopsy in primary neuritic leprosy. *Int J Lep*. 1988;56:56–60.
25. Sehgal VN. Clinical criteria for diagnosis of Hansen's disease. *The Star*. 1990;50:14–16.
26. Sehgal VN. Histopathology only supplements not supplants the clinical diagnosis of Hansen's disease. *The Star*. 1990;50:15–16.
27. Olivier HR. Psychiatric aspects of Hansen's disease (leprosy). *J Clin Psychiatry*. 1987;48:477–479.
28. Ridley DS. Histological classification and the immunological spectrum of leprosy. *Bull World Health Organization*. 1974;51:451–463.
29. Ellard GA. Chemotherapy of leprosy. *Br Med Bull*. 1988;44:775–790.
30. Hastings RC, Franzblau SG. Chemotherapy of leprosy. *Ann Rev Pharmacol Toxicol*. 1988;28:231–245.
31. Jakeman P, Smith WCS. Thalidomide in leprosy reactions. *Lancet*. 1994;343:432–433.
32. Sansarricq H. Technical problems related to multidrug therapy in leprosy control. *Acta Leprol*. 1989;7:59–62.
33. Baker RJ. The need for new drugs in the treatment and control of leprosy. *Int J Lep*. 1990;58:78–97.
34. Wheate HW. Management of leprosy. *Br Med Bull*. 1988;44:791–800.
35. Yoder LJ. Management of reactions in Hansen's disease. *The Star*. 1987;47:1–7.
36. Quismorio FP, Rea T, Chandor S, Levan N, Friou GJ. Lucio's phenomenon: An immune complex deposition syndrome in lepromatous leprosy. *Clin Immunol Immunopathol*. 1978;9:184–193.
37. Meeran K. Prevalence of HIV infection among patients with leprosy and tuberculosis in rural Zambia. *Br Med J*. 1989;298(6670):364–365.

# Chapter 15

## CUTANEOUS TUBERCULOSIS

JAMES W. STEGER, M.D.\* AND TERRY L. BARRETT, M.D.†

---

### INTRODUCTION

### HISTORY

- Tuberculosis in Antiquity
- Observations During the 4th Through 19th Centuries
- The Contributions of Robert Koch
- Tuberculosis in the Military

### EPIDEMIOLOGY

### BACTERIOLOGY

### HISTOPATHOLOGY

### CLASSIFICATION

- Primary Inoculation Tuberculosis
- Tuberculosis Verrucosa Cutis
- Miliary Tuberculosis of the Skin
- Scrofuloderma
- Tuberculosis Cutis Orificialis
- Lupus Vulgaris
- Other Rare Forms of Cutaneous Tuberculosis

### DIAGNOSIS

### TREATMENT

### PREVENTION

### TUBERCULOSIS AND ACQUIRED IMMUNODEFICIENCY SYNDROME

### TUBERCULOSIS CONTROL IN REFUGEE SETTLEMENTS

### THE TUBERCULIDS

- Erythema Induratum
- Papulonecrotic Tuberculid
- Lichen Scrofulosorum

### SUMMARY

\*Captain, Medical Corps, U.S. Navy; Head, Dermatology Clinic, Naval Hospital, San Diego, California 92134-5000

†Captain, Medical Corps, U.S. Navy; Pathology and Dermatopathology Consultant, Naval Hospital, San Diego, California 92134-5000

## INTRODUCTION

Just as systemic tuberculosis can be protean and diverse in its clinical manifestations, so tuberculosis of the skin is also highly variable in its clinical appearance, significance, and prognosis. Five factors that are important for the clinical presentation of cutaneous tuberculosis are (1) the pathogenicity of the organism, (2) its antibiotic resistance profile, (3) the portal of infection, (4) the immune status of the host, particularly the presence or absence of acquired immunodeficiency syndrome (AIDS) secondary to infection with human immunodeficiency virus (HIV), and (5) various local factors in the skin (eg, relative vascularity, trauma, lymphatic drainage, and proximity to lymph nodes).

The incidence of tuberculosis in the United States has been increasing since 1984 owing to the following factors:

- immigration of previously infected people from developing countries,<sup>1</sup>
- increasing homelessness and malnutrition,<sup>2</sup>
- worsening urban economic and social environments,<sup>3</sup>
- increased drug resistance,<sup>4</sup>
- the relaxation, reduction, or elimination of tuberculosis-control programs over the past two decades,<sup>3</sup>
- physicians who have not treated their patients in accordance with recommended treatment guidelines,<sup>5</sup>
- the increasing prevalence of AIDS.<sup>6</sup>

At present, the incidence of tuberculosis in the United States is approximately 10.5/100,000/y,<sup>7</sup> (up 15% since 1990), the largest group being 25 to 44 years of age—a group likely to have children in their households who are at risk of becoming infected.<sup>8</sup>

The worldwide incidence of tuberculosis in 1990 was estimated by the World Health Organization (WHO) to be 7.5 million cases, with the greatest number occurring in Southeast Asia and the western Pacific regions with 4.9 million cases, followed by India with 2.1 million, then China with 1.3 million, and Indonesia with 0.4 million.<sup>9</sup> This incidence is anticipated to climb by 58% to 11.9 million cases per year by the year 2005.<sup>9</sup> The rate of incidence of tuberculosis in the developing countries of the world is much greater: approximately 500/100,000/y.<sup>10</sup> These same factors that have led to the increases in the United States are operative worldwide. Of especially great alarm has been the progressive increase in numbers of strains of tuberculosis that are resistant to multiple antibiotics<sup>11,12</sup> as well as the rampant spread of such strains in AIDS-infected patients.<sup>6,12,13</sup>

Since 1984, the incidence of extrapulmonary tuberculosis has increased at an even faster rate than that of pulmonary tuberculosis<sup>14,15</sup> and is considered a diagnostic criterion in the case definition for AIDS.<sup>16</sup> Because immunocompromised individuals are at increased risk for extrapulmonary tuberculosis, dermatologists are renewing their historic role in the diagnosis of cutaneous lesions of tuberculosis.

From the military standpoint, the risk of tuberculosis exposure virtually worldwide has increased dramatically since the end of the Vietnam conflict. The continued rise toward a worldwide pandemic of tuberculosis, AIDS-associated tuberculosis, and drug-resistant tuberculosis portends a perilous future for troops who deploy to any underdeveloped country. Vigorous surveillance for tuberculosis, coupled with comprehensive drug treatment and aggressive public health programs will be essential to ensure that our military forces do not fall victim to this age-old malady.

## HISTORY

Unless otherwise noted, the general history of the study of tuberculosis up to the time of Robert Koch is quoted from Baldwin's "Tuberculosis: History and Etiology," a chapter in Osler, McCrac, and Funk's *Modern Medicine: Its Theory and Practice*, originally published in 1925.<sup>17</sup> The discussion of the contributions of Robert Koch is quoted from Neisser's "Chronic Infectious Diseases of the Skin,"

a chapter in Ziemssen's *Handbook of Diseases of the Skin*, originally published in German in 1885.<sup>18</sup>

Material relating to tuberculosis in the military in this chapter is quoted from Long's "Tuberculosis in the Army," published in 1963,<sup>19</sup> and Guiton and Barrett's "Tuberculosis," published in 1982,<sup>20</sup> both of which are chapters in official histories published by the U.S. Army Medical Department. The infor-

mation contained in these sources is essentially unavailable elsewhere.

### Tuberculosis In Antiquity

Pulmonary tuberculosis (also called consumption and phthisis) has existed from very remote times. It transcends all other maladies in the total number of its victims and the cost to society in civilized countries. Tuberculosis was a disease familiar to the most ancient civilizations, judging from the inscriptions on Babylonian tablets, which represent the earliest human records.<sup>17</sup> Pathological evidence of tuberculosis of the spine has been found in Neolithic burial sites in Heidelberg, Germany. Bone lesions have also been recognized in the mummified body of a priest of Ammon, exhumed from a tomb of the 21st Egyptian Dynasty, 1000 BC.<sup>21</sup>

Hippocrates (460–376 BC) first gave an intelligent description of phthisis, although empyema and *phyma* (abscess of the lung), were included. Otherwise, his portrayal of the symptoms of consumption was unsurpassed for many centuries. The Hippocratic school believed in the curability of phthisis in all stages and the benefits of a change of residence. Contagion was mentioned by Isocrates. Aristotle, a contemporary of Hippocrates, notes that it was a general belief among the Greeks of his day that phthisis was contagious. Celsus (30 BC) wrote of the disease in three forms: atrophy, cachexia, and ulceration. Aretaeus (AD 50) gave a very clear description of the disease and differentiated it from empyema. He believed in the efficacy of sea voyages and country air. Pliny lauded pine forests for their healing powers.<sup>17(p267)</sup>

Galen (AD 131–201) considered the disease an ulceration that should be treated by measures designed to dry the secretion. He therefore sent patients to the high land of Phrygia. In other details, the conceptions of the disease held by Galen were like those of Hippocrates; nor was any further light shed on the nature of consumption for 1,400 years, when anatomical study began.<sup>17(p267)</sup>

### Observations During the 4th Through 19th Centuries

[A clue to the prevalence of tuberculosis in different periods of European history is found in the accounts of the ceremony of the "touch" performed by French and English monarchs to cure the swollen glands that occurred in the necks of those suffering from scrofula. Ever since Clovis in the 5th century, the kings of France were believed to receive from God this healing power at the time of their anointment. Edward the Confessor had also claimed it for the English kings in the 11th century. The first act of Henry of Navarre, when he entered Paris as Henry IV in 1594, was to touch 600 scrofulous persons. The 17th century seemed to be the heyday for touching, as well as for deaths from pulmonary consumption. In England, the largest number of persons applying to be touched was recorded in 1684, when many of them were trampled to death in attempting to reach the hand of the king.<sup>21</sup>—JWS]

Sylvius (1614–1672) was the first to indicate the con-

nection between tuberculous nodules and phthisis. He regarded these nodules as enlarged lymph glands in the lung, analogous to scrofula, and on the scrofulous constitution depended the inheritance of phthisis. He gave a careful description of the symptoms and believed in contagion. Morton, (1689) whose celebrated book [on phthisis] was widely known among English physicians, brought the tubercle prominently to attention as the true cause of phthisis. He also believed in the hereditary predisposition to and contagious nature of tuberculosis. Morgagni (1682–1771) was uncertain that tubercles and glands were identical, and thought that phthisis could originate from other things; he regarded it as extremely infectious, and refrained from doing autopsies on consumptives.<sup>17(pp267–268)</sup>

The teachings of Benjamin Rush exerted a powerful influence on American medicine in Revolutionary times. In his *Thoughts upon the Causes and Cure of Pulmonary Consumption* (1783), he regarded tuberculosis as a disease of debility and considered tubercles to be the result of hypersecretion from the bronchial vessels. He believed in contagion at first, but doubted it later in his life. Stark described the miliary tubercles, and near the end of the 18th century, Reid (1785) and Baillie (1794) completed the description. Most noteworthy is the work of Gaspard Laurent Bayle (1810), who is justly named as the founder of correct teaching about tuberculosis. He studied miliary tubercles in all stages, and laid great stress on their varying degrees of opacity.<sup>17(p268)</sup>

René Laennec (1819), whose work soon followed Bayle's, summarized and simplified the knowledge thus far gained. He recognized the unity of all phthisis as tuberculosis, and scrofula as tuberculosis of lymph glands; his ideas in general as to causation and infection were distinctly modern, and his descriptions of the tubercle and its transformation toward ulceration are unsurpassed.<sup>3(p268)</sup>

During this period, America was represented but meagerly until 1834, when Samuel Morton, of Philadelphia, published the first pathological studies on consumption. He was a student of Laennec, and his conclusions as to the nature of tubercles were fairly accurate; they were ascribed to altered secretion and not to inflammation. Samuel Morton's work on *Pulmonary Consumption* found much favor in America, and included excellent therapeutic advice as to open-air life and exercise.<sup>17(p268)</sup>

English, American, and German physicians accepted the probability of infection under special conditions, but the strongest opinions were held by the Latin races [*Mediterranean peoples*—JWS], among whom the disease was said to be more virulent. The influence of Valsalva and Morgagni was certainly most potent in causing fear in Italy. The first recorded inoculations were by Kortum (1789), which, like some of those of his successors, were fortunately unsuccessful, since they were partly on humans including themselves. The strife over the question of the danger of inoculation of scrofula with vaccination led to these first attempts.<sup>17(p268)</sup>

Virchow (1847–1850) classified scrofula and tuberculosis entirely apart, restricting the latter term to the miliary form and considering it a form of lymphoma due



to an unknown diathesis; caseation was a nonspecific process. Hence, the idea of unity in tuberculous diseases received a serious rebuff despite the important discovery by Buhl (in 1857) that miliary tubercles were most often associated with preexisting caseous foci, from which he thought the specific poison originated. The microscopical studies brought out valuable data, but withal much confusion.<sup>17(p369)</sup>

Jean Antoine Villemin presented his important communication, *On the Cause and Nature of Tuberculosis and the Inoculation of the Same from Man to Rabbit*, in December 1865. His conclusions were positive: (1) Tuberculosis is a specific affection. (2) It has its origin in an inoculable agent. (3) The inoculation from man to rabbits is very successful. (4) Tuberculosis pertains, therefore, to the virulent diseases, and should be classed with variola, scarlatina, syphilis, or, better still, with glanders. Villemin covered a wide field in his inoculations, employing fragments of lung tubercle, sputum, blood, scrofulous gland, and perlsucht or bovine tubercle, with positive results in nearly all cases. His conclusions excited widespread discussion and experimentation. A new era in microbiology was founded about the same time by [Louis] Pasteur.<sup>17(p269)</sup>

The contest over the specificity of the giant cell, the importance of which was emphasized by Langhans (1868), was settled in the negative. Tubercles were studied in all the tissues hitherto unassociated with the conception of tuberculosis, as fungous joints, carious bones, and lupus, by Koster (1873) and Friedländer (1873). The development and spread of miliary tubercles were traced to venous infection by Weigert (1879–1892). The pathway of infection was already inferred by the many feeding and inhalation experiments, so that, with the rapidly developing investigation of bacteria caused by Pasteur's discoveries, search was being made for a specific living organism. E. Klebs (1877) was the first to observe actual transference of the virus by artificial culture on egg albumin through several generations before inoculation, but he did not recognize the bacillus; instead, he found a motile organism, *Monas tuberculosum*, which he presumed to be the contagium vivum. Aufrecht (1881) and Baumgarten (1882), working independent of Koch, described bacilli in the center of the tubercles, which, owing to lack of culture and staining methods, were not positively identified as the infective agents. The actual achievement was due to [the German physician] Robert Koch, whose demonstration [in 1882] of the causative relation of the tubercle bacillus to tuberculosis<sup>22</sup> was so complete that but little of importance has been added since.<sup>17(p269)</sup>

### The Contributions of Robert Koch

[Because Koch's contributions were so brilliant and of such great importance, albeit published in German, the following historical review of his work is reproduced verbatim from the account of his work written in 1885 by Professor Albert L. S. Neisser (1855–1916), the dermatologist from Breslau, Germany, now Poland. — JWS]

At the present time, tuberculosis, and with it scrofulosis, is the best-known chronic infectious disease of man, and the only one demonstrated with certainty.<sup>18(p275)</sup>

Villemin was the first to class tuberculosis as an inoculable infectious disease, but his doctrine failed to secure universal recognition. Further inoculation experiments were made by different savants in the most variable manner. The experimenters introduced the material into the animals from all possible points, so that the following result was rendered certain. If tuberculous material be transferred to an (appropriate) organism, there is developed in it, in a typical manner, a tuberculosis which sometimes remains more local, at other times spreads through the body generally. Only specific tuberculous material is capable of communicating this disease. Nontuberculous matters, or those deprived of their infectious quality, never produce tuberculosis. It was shown at the same time that the "predisposition" of some classes of animals was variable as regards the receptivity for the disease.<sup>18(p275)</sup>

Klebs described a form of micrococcus as peculiar to tuberculosis and cultivated it. In the same way, Schüller has reported experiments in cultivation and inoculations with its result. A landmark has been furnished also by the interesting experiments made by Deutschmann, who by leaving at rest inoculable tuberculous pus, separated it into a light wine-yellow serum inactive in inoculation, and a thick, tenacious sediment which produced tubercle. Recently, Damsch, in Ebstein's clinic, has been able to demonstrate tuberculosis of the urinary passages in the living, by successful inoculations into the anterior chamber of the eye of rabbits. Aufrecht alone has described microscopically specific bacteria in the tissues, without having been able to gain general recognitions of his results.<sup>18(p275)</sup>

But the credit of having finally elucidated the nature of tuberculosis belongs to Robert Koch, who furnished the incontrovertible proof that a specific bacillus is the cause of tuberculosis and of scrofulosis.<sup>18(p275)</sup>

The proof consisted, first, in the demonstration of a parasitic microorganism in tuberculous neoplasms. For this a new staining process had to be invented since alkaline solutions alone were appropriate. The method originally devised by Koch was very soon modified by Ehrlich, who found the alkalizing factor in aniline oil (or, according to Ziehl, in carbolic acid). His procedure is as follows: the sections are warmed, then stained in a mixture of a concentrated alcoholic-fuchsin or gentian-violet solution and an aqueous solution of anilin oil (carbolic acid solution) for several hours, or for a short time if heated. The sections are then freed from excess color by alcohol or water washing, then immersed in a solution of one part of officinal sulphuric (or nitric) acid with two or three parts of distilled water. The deep blue (or red) color gives place at once to a faint yellow, the stain being bleached in all parts of the tissue. The bacilli, however, retain the color and may now be recognized under comparatively low power. It is better to further stain the background with anilin brown or methylene

blue, because then the blue (or red) bacilli can be more easily distinguished. The preparations, after having been dehydrated in alcohol, are rendered transparent in oil of cloves and preserved in Canada balsam. The preparations are not always permanent, the color of the bacilli gradually fading, probably because the acid is not thoroughly washed out. The gentian preparations are certainly more constant in their color than the fuchsin preparations. The color keeps best when the specimens (dry preparations) are not enclosed in Canada balsam, but are directly examined in oil of cedar (with homogeneous immersion).<sup>18(pp275-276)</sup>

The bacteria rendered visible by this method have a rod shape, hence are bacilli. Their length corresponds about to one-fourth to one-half the diameter of a red blood corpuscle. Their breadth differs according to the method employed; Koch's original methylene blue results in exceedingly slender bacilli, while Ehrlich's and Baumgarten's method additionally colors the sheath enclosing the bacillus. Characteristic of the tubercle bacilli, in Koch's older method, is their rejection of the anilin brown staining after they have already taken the methylene blue. In Ehrlich's method, the tubercle bacilli retain the tint present in the anilin oil and are not decolorized by acid or subsequent methylene blue staining.<sup>18(p276)</sup>

Bacilli are aggregated in great numbers wherever the tuberculous process is of recent inception and in rapid progress—forming closely packed groups often arranged in intracellular bundles. There are also numerous free bacilli, especially at the border of large cheesy patches where they are present in large free swarms. After the pinnacle of the tubercular eruption has been passed, the bacilli become sparser and can be seen only as isolated, often faintly colored, probably dying or dead formations. If giant cells are present, the bacilli are most numerous within them. Here, too, those with bacilli are the more recent, those without them the older cells in which the bacilli originally present have died or have passed into a subsequent dormant state. Besides the ordinary bacillus forms, we find others with two to four oval spores which are placed at regular intervals along the bacillus [*producing the pathognomonic "beaded" appearance of this distinctive mycobacterium*—JWS].<sup>18(p276)</sup>

Subsequent examinations, wherever made, confirmed the correctness of Koch's statement as to the constant presence and the diagnostic value of these bacilli in tuberculous infections.

But even this did not satisfy Koch himself. He said:

It does not follow, however, from this coincidence of tuberculous affliction with bacilli that both phenomena stand in causal relation to each other, though no slight degree of probability for this assumption is furnished by the fact that the bacilli are found chiefly wherever the tuberculous process is in its inception or progress, disappearing where the disease comes to a standstill.<sup>4(p276)</sup>

...

In order to prove that tuberculosis is a parasitic disease caused by the immigration of the bacilli and is originally

due to their growth and increase, the bacilli must be isolated from the body and cultivated in pure fluids until they are freed from any possibly still adhering morbid product derived from the animal organism, and finally, by the introduction of the isolated bacilli into animals, the same morbid picture of tuberculosis must be produced which experience has shown us to result from inoculation with tuberculous matters of natural origin.<sup>18(p276-277)</sup>

This task Koch has performed in a brilliant and absolutely irrefutable manner.

The cultivations were made in sterilized, coagulated blood serum. They were distinguished by an exceedingly slow growth which proceeds only at a temperature of 37° to 38°C; they form minute compact scales which can be easily detached in toto and by appropriate examination are shown to consist only of the well known, extremely delicate bacilli. The cultivations yielded corresponding results, whether the matter was derived from animal or human tuberculosis; they were continued for months outside of the animal body, by successive transfer from serum to serum.<sup>18(p277)</sup>

But in every case inoculations of healthy animals with the cultivation yielded a positive and constantly uniform result—a typical inoculation tuberculosis of the animal.<sup>18(p277)</sup>

In guinea pigs, the inguinal glands swelled after 2 weeks. The inoculation sites on the abdomen changed into an ulcer, and the animals emaciated. After 32 to 35 days the animals were killed. They all exhibited intense tuberculosis of the spleen, liver, and lungs; the inguinal glands were greatly swollen and cheesy, the bronchial glands were only slightly swollen.<sup>18(p277)</sup>

In the same way rabbits, rats, cats, dogs, etc., were successfully inoculated. The experiments with rats and dogs are especially interesting because these animals have otherwise shown themselves uncommonly resistant toward inoculations of tuberculosis.<sup>18(p277)</sup>

The result of the experiments is independent of the point of inoculation: subcutaneous connective tissue, anterior chamber of the eye, abdominal cavity, direct introduction into the blood current, etc. It is necessary, owing to their exceeding slow growth, that the infectious matters be brought to a spot where, protected from external injury, the bacilli have the opportunity to increase and penetrate into the tissues, otherwise the bacilli are eliminated before they secure a habitat.<sup>18(p277)</sup>

Small shallow cutaneous incisions are no wounds appropriate to the invasion of bacteria. Similar conditions will be requisite to ensure the adherence of the bacilli which have reached the lungs. Probably, factors favorable to the retention of the bacilli, such as stagnating secretions, denudation of the mucosa of its protective epithelium, etc., will be of assistance in effecting the infection.<sup>18(p277)</sup>

Furthermore, it appeared that the rapidity of the course of inoculated tuberculosis, as well as its extent and spread over the several organs, is dependent upon the larger or smaller quantity of infectious matter introduced. The

picture of acute military tuberculosis occurred only when the body was at once overwhelmed, as it were, by a large quantity of infectious organisms. Otherwise, when but few bacilli are inoculated, the processes are of slow development or circumscribed locally (nodules on the iris, opacity of the cornea, affections of the lymphatic glands), which are very much later succeeded by general infection, unless the disease terminates altogether with the local process.<sup>18(p277)</sup>

[In 1882, only 2 years after the discovery of *Mycobacterium tuberculosis*, Robert Koch found the tubercle bacillus in the lesions of *lupus vulgaris*. This revelation gave rise to the concept of "localized tuberculosis of the skin." Sir Jonathan Hutchinson accepted the bacillary origin of *lupus*, in contrast to that of leprosy, and in a series of lectures in 1888, used the term "apple jelly nodule" to describe their peculiar transparency. Paul Gerson Unna later introduced the use of the diascop, which is particularly useful in the diagnosis of *lupus vulgaris*.<sup>23</sup>

In 1891, Koch recognized the reactivity of the skin to inoculation of virulent or killed tubercle bacilli when the host had had previous tuberculosis. In 1906, the Viennese pediatrician Clemens von Pirquet perceived that this reactivity to killed or heated bacilli after the development of a primary tuberculous complex was a tuberculosis specific allergy.<sup>24</sup> In 1907, Charles Mantoux introduced the Mantoux skin test, the standard method for determining previous exposure to tuberculosis. Since that time, the tuberculin skin test has been one of the most important methods of diagnosis of infection as well as for determining the cellular immune status (anergic, normal, hyperergic) of the host. —JSW]

## Tuberculosis in the Military

Tuberculosis has been a problem since antiquity and for centuries was a principal cause of death in men of military age. Records of hospital admissions and medical discharges from military service for tuberculosis have been maintained by the U.S. Army since the Civil War. During that conflict, there were 13,499 tuberculosis admissions and 5,286 deaths from the disease among white soldiers. The mean annual rate of discharge for tuberculosis was 8.6 per 1,000 in white troops and 3.1 per 1,000 in black troops. However, in neither the Civil War nor the Spanish-American War was the disease frequent enough to prompt any unusual comment in the analyses recording the medical aspects of military operations.<sup>20(p214)</sup>

## Tuberculosis in World War I

During World War I, men with tuberculosis were detected and excluded from military service almost entirely on the basis of the physical examination, as roentgenology was in its infancy and screening skin testing resources were not available. There were 22,812 disability separations because of tuberculosis during the war, or 5.52 per 1,000 strength per annum. The disease was the leading cause of disability separation, accounting for 11.1% of the total. Further, the full magnitude of the

problem did not become evident until several years after the war. Goldberg (1941) calculated that the approximate expenditure by the Veterans Administration for service-connected tuberculosis from the close of World War I through 1940 was \$1,186,000,000. The number of hospitalized tuberculosis beneficiaries peaked in 1922 at 44,591.<sup>20(p215)</sup>

## Tuberculosis in World War II

At the beginning of World War II, the Office of The Surgeon General recognized that drastic revision of the physical standards in the existing Mobilization Regulations was necessary because of technical developments in tuberculosis control. In April 1939, a chest X-ray examination was required before applicants could be commissioned. As early as 1940, routine screening chest X-ray examinations for all inductees were considered, but they were not made a mandatory part of all physical examinations at induction stations until 3 June 1941. While approximately 10 million men had chest X-ray examinations, about 1 million were inducted without them.<sup>20(p215)</sup>

The average incidence rate of tuberculosis for World War II from 7 December 1942 to 14 August 1945 was 1.2 per 1,000 per annum. Tuberculosis accounted for 1.9% of all discharges for disability from disease between 1942 and 1945, ranking 13th on the list. Among Americans who had been prisoners of war, the rates were higher. Prisoners from the European theater had an incidence five to seven times that of the U.S. Army in general. Statistics on those returned from the Pacific area were more difficult to obtain, but a special study of repatriated prisoners at West Coast debarkation hospitals, directed by The Surgeon General, showed that 2.7% of 3,742 individuals studied with chest X-ray examinations had evidence of active pulmonary tuberculosis.<sup>20(p215)</sup>

Extrapulmonic forms of tuberculosis were rare. A total number of 140 cases of cutaneous tuberculosis were reported by the U.S. Army between 1942 and 1945, or 0.01 case per 1,000 per year (ie, less than 1% of patients with systemic tuberculosis).<sup>19(p369)</sup>

The semiannual report of the senior consultant in tuberculosis in the European theater, dated 3 July 1945, called attention to an excessive and steadily rising prevalence of all forms of tuberculosis in nurses for the 3½ years of the war. The mean rate for the 3½ years was 3.8 times as high as the general tuberculosis admission rate for troops in the theater.... [I]n analyzing the responsible factors, [the report] called attention to the carelessness in technique that develops in times of strain and stressed the failure of medical officers to maintain proper measures, designed to prevent spread of the disease in hospitals.<sup>19(pp342-343)</sup>

In the final weeks of the war in Germany, Allied troops overran a large number of the notorious concentration camps in which the German government imprisoned political nonconformists, Jews, nationals of surrounding states, and others who had offended the Nazi Party. These camps included Auschwitz, Buchenwald,

Nordhausen, Dachau, Belsen, and many others. Thousands of dead were found in the camps at the time of their liberation, and many more thousands were sick and dying. Among the latter were hundreds of persons with advanced tuberculosis, who constituted an immediate problem for the evacuation hospitals of the advancing armies.<sup>19(p349)</sup>

A vivid description of conditions at the Dachau concentration camp, and the extent of tuberculosis in hospitalized inmates of that camp, has been given by Piatt.<sup>25</sup> He made a statistical analysis of 2,267 roentgenograms of the chest of patients removed from the concentration camp hospital and examined by X ray on admission to the receiving and evacuation section of the 127th Evacuation Hospital. In only 45.3% of the films was no abnormality discovered. Tuberculosis, pneumonia, and heart disease were the chief abnormalities. Six hundred twenty-six definite cases of tuberculosis, or 27.6% of the total number examined, were detected. In more than half of these, the disease was bilateral, and in four fifths of the cases, the process was either moderately or far advanced. In addition to definite tuberculosis, there were 94 patients (4.1% of the total) with pleural effusion, probably tuberculous in origin. There were five cases of miliary tuberculosis.<sup>19(p350)</sup>

Piatt, among others, expressed the view that the incidence of tuberculosis in Europe would increase appreciably in the years to come as a result of the return of numerous persons with undiagnosed active disease from concentration camps to their homes.<sup>19(p350)</sup>

### ***Tuberculosis in the Korean and Vietnam Conflicts***

While specific incidence rates are not available for the Korean conflict, tuberculosis continued to be a problem for the U.S. Army, as reflected by the approximately 600 admissions per year to Fitzsimons General Hospital during that period.<sup>20(p215)</sup>

Rightful concern was expressed about the exposure of American troops in Vietnam to a population with a high tuberculosis infection rate. The conflict in Vietnam placed an estimated 500,000 American military personnel annually in varying degrees of contact with a highly infected population. In 1968, a chest X-ray survey by Siegler, et al, of Vietnamese civilians showed that 31.7% [of the population] over the age of 15 had definite radiologic evidence of active pulmonary tuberculosis. Another study demonstrated that nearly 100 percent of the adult population was tuberculin skin test positive.<sup>20(p216)</sup>

Among U.S. troops, approximately 95% had had no previous exposure to tuberculosis and were tuberculin-negative on arrival in Vietnam. Data from the 20th Preventive Medicine Unit indicated that only 6.2% of 901 first-time personnel were tuberculin positive on entering the country, whereas 13.7% of 190 personnel who had served a previous tour in Vietnam were positive. In the first-tour group, breakdown by race showed that 3.2% of whites, 7.4% of blacks, 9.1% of Orientals, and 15.6% of Spanish-surnamed persons were tuberculin positive; a similar racial distribution was noted in the group with previous tours in Vietnam.<sup>20(p216)</sup>

The clinical course of tuberculosis was apparently no different in U.S. servicemen in Vietnam than it was in patients in the United States. Extrapulmonary forms and pleural effusion were uncommon.<sup>20(p218)</sup>

*[Currently, from a military perspective, the incidence of tuberculosis is highest in Africa, where estimates run 165 cases per 100,000 population. In Asia, the estimated incidence is 110 per 100,000. Because the population in Asia is much larger than Africa's, however, the total number of cases in Asia is thought to be 3.7 times greater. In the western Pacific, the highest rates occur in the Solomon Islands, the Philippines, and South Korea, and the lowest in Australia, New Zealand, and Japan. Some third-world countries may have incidences approaching 500 cases per 100,000 population.<sup>8</sup>—JWS]*

## **EPIDEMIOLOGY**

An estimated 1.7 billion people are infected with *Mycobacterium tuberculosis*: approximately one of three living persons.<sup>26</sup> In 1982, WHO estimated that of the 10 million new cases of tuberculosis that occur each year worldwide, 4 to 5 million are highly infectious, smear-positive cases, and approximately 3 million cases prove fatal.<sup>27</sup> In 1990, WHO estimated an incidence of 7.5 million cases of tuberculosis and 2.5 million deaths. HIV infection was considered responsible for 116,000 deaths (4.2%).<sup>9</sup> Case-fatality rates were estimated at 15% for those receiving treatment and 55% for those receiving no treatment.<sup>27</sup> For the decade 1990 through 1999, 30 million deaths (12.3 million in Southeast Asia, 6 million in sub-Saharan Africa) are anticipated from

tuberculosis, with approximately 10% expected to be associated with HIV.<sup>27</sup>

Although in most areas of the world the incidence of tuberculosis is anticipated to decline or remain stable, the incidence rates in Africa are anticipated to rise by some additional 10 cases per 100,000 population per year through 2005, primarily because of the HIV epidemic.<sup>9</sup>

In the United States, the large influx of immigrants from Southeast Asia and Haiti and the growing numbers of homeless—up to 50% of whom are infected with tuberculosis<sup>26</sup>—have posed a new threat to a previously well-administered tuberculosis-control program. More than 20% of the new cases in the United States occur among the foreign-

born,<sup>28</sup> virtually all of whom are from resource-poor countries with high rates of tuberculosis. For example, in 1988, not only did Asians and Pacific Islanders have the highest incidence of tuberculosis in the United States, with 49.6/100,000 (compared to 26.7/100,000 for blacks and 5.7/100,000 for whites), but in addition, 93.6% of those affected were foreign-born.<sup>29</sup> Selected incarcerated populations are at even greater risk for developing tuberculosis. For example, the incidence of tuberculosis in New York state prisons between 1980 and 1990 was 134/100,000—almost 14-fold higher than the national average.<sup>26</sup>

In the United States from 1963 through 1986, the incidence of pulmonary tuberculosis declined at an average annual rate of 5.0%; however, the incidence of extrapulmonic tuberculosis declined only 0.9% annually. Immigrants from developing areas, particularly from Africa, India, tropical America, and Southeast Asia, have been a major source of these extrapulmonary forms. In the United States in 1986, only 17.5% of all cases of tuberculosis were extrapulmonic, but of those, 71.2% of patients belonged to racial ethnic minorities or were foreign-born.<sup>30</sup> (Likewise, of patients with pulmonic tuberculosis, 63% belonged to racial ethnic minorities or were foreign-born.<sup>30</sup>)

As might have been expected, some of the most dreadful epidemics of tuberculosis have occurred in populations who had had little or no previous contact with the disease:

- Scrofula and pulmonary tuberculosis were extremely rare among native Pacific Islanders before contact with European immigrants; however, within a few decades, tuberculosis was the cause of 40% of all deaths in New Caledonia and Hawaii.
- The highest mortality rate on record (9,000/100,000) occurred among the Indians of the Qu'Appelle Valley Reservation in Western Canada.
- Tuberculosis was both fulminant and rampant in the Senegalese troops and Capetown men who were brought to France during World War I. Large numbers of these soldiers succumbed to what was then called "galloping consumption."<sup>21</sup>

Cutaneous tuberculosis is also found worldwide with higher frequency in the cooler latitudes. However, fewer than 1% of all cases of tuberculosis are expected to have cutaneous manifestations.<sup>19</sup> Nonetheless, with the sharp increases in AIDS, cutaneous

forms of tuberculosis such as miliary tuberculosis,<sup>31,32</sup> tuberculous abscesses,<sup>33</sup> and scrofuloderma<sup>34</sup> are beginning to be reported among AIDS patients. Infection with *M tuberculosis* can occur from contact with contaminated bodily fluids, secretions or discharges, or through direct contact with diseased skin. Modes of transmission for infection include (a) respiratory, (b) gastrointestinal (from unpasteurized milk from infected animals), (c) genitourinary (through sexual intercourse), and (d) inoculation through skin or mucous membranes (eg, the conjunctiva). Sources of infection include humans, cattle, swine, dogs and cats, monkeys, and laboratory bacteriological cultures. Exogenous iatrogenic inoculation has occurred in laboratory workers.<sup>35</sup>

Social and economic conditions are important factors in the incidence and prevalence of tuberculosis. Extreme youth, old age, poverty, overcrowding, and inadequate hygiene and nutrition increase the risk of infection, as does immunosuppression during the course of pregnancy, diabetes, sarcoidosis, leukemia, and lymphoma. Increased genetic susceptibility is associated with HLA-B<sub>W</sub>15 antigen. Treatment with cytostatic medications or systemic glucocorticosteroids can also increase the risk of acquisition or reactivation of pulmonary tuberculosis.

Wars usually bring into sharp focus the inadequacy of hereditary resistance and immunity when environmental stress, malnutrition, and hygienic conditions become too formidable. Tuberculosis mortality increased suddenly and dramatically in Paris during the siege by the Prussian Army in 1871. Similarly, it increased everywhere in Europe within a few months after two world wars began—even in countries that did not take a direct part in the conflict and where food was never scarce.<sup>21</sup>

Once tuberculosis is established in the host, spread to the skin may occur by contiguous extension of underlying lymph nodes or osseous lesions, from hematogenous or lymphatic dissemination, or through secondary exogenous inoculation.

An epidemiological analysis published in 1990<sup>36</sup> reviewed 400 cases of tuberculosis with skin manifestations seen in hospitals in Poland over the past 25 years. Of these, 268 (67%) had tuberculosis of the skin and 132 (33%) had tuberculids (which are discussed later in this chapter). The investigator noted that the prevalence of skin tuberculosis was 5.8-fold lower during the period 1983 through 1987 than it had been during the period 1963 through 1967. The frequency of the different forms of tuberculosis were as follows: lupus vulgaris (57.5%), scrofuloderma (35.4%), verrucous tuberculosis (4.5%), and

ulcerative tuberculosis (2.6%). The male-to-female ratio was 1:2.05. Women were more likely to have lupus vulgaris or scrofuloderma, while men more frequently had verrucous or ulcerative tuberculosis. The young more frequently had scrofuloderma and the elderly more frequently had lupus vulgaris.

In western Algeria, 45 cases of cutaneous tuberculosis were diagnosed from March 1981 through

December 1987. Both sexes were equally represented. The different forms of tuberculosis were seen in the following frequency: lupus vulgaris (28.8%), scrofuloderma (28.8%), specific adenitis (13.3%), verrucous tuberculosis (13.3%), tuberculous gumma (13.9%), and ulcerative tuberculosis (2.2%). The tuberculin skin test was positive in 86% of the cases.<sup>37</sup>

## BACTERIOLOGY

The bacterium *M tuberculosis* measures 2.5 to 3.5  $\mu\text{m}$  in length by 0.3 to 0.6  $\mu\text{m}$  in width. This slightly curved, sporeless, motile, obligate aerobic, Gram-positive bacterium is acid-, alkali-, and alcohol-fast. It has a high lipid content and a slow growth rate. Its peptidoglycan skeleton contains approximately 30 different antigenic substances, of which the most important is the tuberculo-protein, the active component of tuberculin, which is the agent used for intradermal testing for delayed hypersensitivity. Within the cell wall of *M tuberculosis* may lie all of the elements associated with tuberculosis, including the factors responsible for caseation and other features of hypersensitization, the antigens responsible for humoral immunity, the agents of toxicity, and, indeed, the very antigens implicated in protective immunity.<sup>38</sup>

There are two types of *M tuberculosis*—human

and bovine—but apparently no clinical difference between infections caused by either type. Bacille bilié de Calmette-Guérin (BCG) is an attenuated strain of the bovine form that is used for vaccination in many parts of the world. In a prospective series of 70 patients with cutaneous tuberculosis that was published in 1989,<sup>39</sup> researchers were able to culture *M tuberculosis* (using a concentration procedure from biopsy tissue homogenates inoculated on Lowenstein-Jensen medium) from 24 of 70 (34.03%) of their patients overall: from 4 of 30 (13.3%) patients with lupus vulgaris, 3 of 7 (42.85%) patients with verrucous tuberculosis, and 17 of 33 (51.05%) patients with scrofuloderma.

Tubercle bacilli grow in 3 to 4 weeks when cultured on Lowenstein-Jensen medium. In contrast, guinea pig inoculation requires 6 to 7 weeks for confirmation.

## HISTOPATHOLOGY

The histopathological inflammatory reactions to *M tuberculosis* can be organized along an immunopathological spectrum, as can be done with leprosy. A sequence from nonnecrotic epithelioid cell granulomas with no acid-fast bacilli (high-immune), through necrotic epithelioid granulomas with some acid-fast bacilli, to necrosis with abundant acid-fast bacilli (low-immune) can be arranged. Lupus vulgaris typifies the high-immune pole; tuberculosis cutis orificialis and acute miliary tuberculosis, the low-immune pole.

A similar immunopathological spectrum has been devised for cutaneous tuberculosis, extending from lupus vulgaris toward scrofuloderma through tuberculosis verrucosa cutis.<sup>40</sup>

In the classic case, the hallmark of the histopathological diagnosis of cutaneous tuberculosis is the presence of tuberculous or tuberculoid granulomata. However, the diagnosis may be missed if one searches solely for the classic tuberculoid gran-

ulomata.<sup>41</sup> Seven additional patterns of inflammation have been described<sup>42</sup>:

- Classic tuberculoid granulomas, which consist of typical granulomas with Langhans'-type giant cells. A peripheral cuff of inflammatory cells, predominantly lymphocytes, surrounds the giant cells. Caseation necrosis may or may not be present (Figure 15-1).
- Abscess formation, which consists of acute or chronic (or a mixture of both) inflammatory cells with variable degrees of necrosis. The amount of fibrosis varies during the healing phase. Giant cells are present in some cases only.
- Diffuse infiltration of histiocytes, in which the infiltrate is composed primarily of histiocytes; few other types of inflammatory cells are present. Only a few well-formed granulomas are seen. Necrosis is universal.

## OK to put on the Web

**Fig. 15-1.** Classic tuberculoid granuloma, seen on low-power magnification. Note foci of caseation necrosis and Langhans'-type giant cells.

- Panniculitis, which is unusual in that both septae and lobules are involved. The infiltrate may be an acute inflammation, a chronic inflammation, or both. Abscess formation may occur as well as necrosis. Phlebitis can be found rarely. One reported case<sup>42</sup> exhibited acid-fast bacilli in the vascular endothelium.
- Nonspecific chronic inflammation, which includes sheets or scattered clusters of chronic inflammatory cells consisting predominantly of lymphocytes and histiocytes. However, other cell types, including plasma cells and eosinophils, can be seen. Giant cells are absent in this pattern.
- Sarcoidal granulomas, which are classically described as "naked" granulomas, due to the absence of peripheral inflammatory cuffing of the granulomas by lymphocytes. The granulomas in this pattern consist primarily of Langhans'-type giant cells with little or no lymphocytic cuffing. Necrosis is minimal or absent. Lamellar calcifications identical to Schaumann bodies are sometimes present (Figure 15-2).
- Rheumatoid-like nodules, the hallmark of which is the presence in the dermis or subcu-

## OK to put on the Web

**Fig. 15-2.** Lupus vulgaris, seen on medium-power magnification. In this sarcoidal-type granuloma, the peripheral rim of lymphocytes, which is typical of lupus vulgaris, helps to differentiate it from sarcoidosis.

taneous tissue, or both, of central necrosis surrounded by palisading histiocytes. A mild, chronic, inflammatory infiltrate may be present, and giant cells are occasionally seen.

Several points must be emphasized when considering these patterns of inflammation: (1) The patterns do not correlate with either a specific mycobacterium or a specific clinical presentation. In fact, subsequent biopsies in the same patient may show a different pattern. (2) These patterns are not pure but represent a spectrum of changes; the patterns may be seen in any combination. (3) Patients with mycobacterial infections do not always present with tuberculoid granulomas, nor does the presence of tuberculoid granulomas necessarily indicate cutaneous tuberculosis. Infections (eg, syphilis) and noninfectious granulomas (eg, zirconium granuloma) may give identical histological patterns.

The sections that follow give the clinical presentations of diseases caused by *M tuberculosis*. The histological descriptions given are those most commonly encountered for each of the clinical entities; however, the general patterns given above must be kept in mind.

### CLASSIFICATION

Numerous attempts have been made to classify cutaneous tuberculosis based on clinical morphology, etiology, the immune status of the host, and so forth. Morphologic classification is unsatisfactory

because similarly appearing skin lesions can have multiple causes and can differ histologically. Classifications based on etiology or immune status are not helpful clinically. Confusion abounds

regarding chronic, reactivation, and reinfection tuberculosis; however, the complexities of cutaneous tuberculosis can be classified and the general pathogenesis described (Table 15-1 and Figure 15-3).

### Primary Inoculation Tuberculosis

Primary inoculation tuberculosis is also called tuberculous chancre, cutaneous primary complex, and tuberculosis primaria cutis.<sup>43</sup> This infection with the tubercle bacillus develops as a result of inoculation of *M tuberculosis* into the skin or mucosa of a nonimmune host. (Immunity can be conferred by previous infection or BCG immunization.) An initial negative reaction to purified protein derivative of tuberculin (PPD) reflects the host's absent immunity.

### Epidemiology

Inoculation tuberculosis accounts for only 5% of total primary tuberculosis; the majority of patients have (a) respiratory exposure with the subsequent formation of a Ghon complex or (b) gastrointestinal exposure.<sup>44</sup> Because *M tuberculosis*

cannot penetrate intact human skin, some sort of injury must be present for an infection to be established. Portals of entry often include such minor injuries as abrasions, puncture wounds, hangnails, and pyodermas. Overall, children are most frequently affected with primary inoculation tuberculosis, with the face and exposed extremities being sites of predilection. (The most famous example of inoculation tuberculosis, the "prosector's wart," albeit a secondary or reinfection tuberculosis, was frequently acquired by pathologists in years past from handling tuberculous lungs or other tissues without protective gloves at the autopsy table.) Tuberculous chancres have also followed *b'rit milah* (ritual circumcision), cardiopulmonary resuscitation, tattoos, inoculations and injections for immunization or therapy, ear piercing, venipuncture, misinoculation of laboratory animals, and sexual intercourse. Inoculation can also occur in the mucous membranes of the oral cavity after tooth extraction, in the tonsils from ingesting nonpasteurized milk, or in the ocular conjunctiva during ocular surgery.<sup>43,44</sup> Recently, primary inoculation tuberculosis has been reported following a needlestick injury from a patient with AIDS and undiagnosed tuberculosis.<sup>45</sup>

**TABLE 15-1**  
**CLASSIFICATION OF CUTANEOUS TUBERCULOSIS**

Stage	Source	Mode	Histology	Course	Disease	Immunity	Bacilli		
Primary	Exogenous	Inoculation	Nonspecific	Localized	Chancre	Developing	+++		
			TB specific	Localized	Primary TB complex	Good	+		
			TB specific	Localized	Lupus vulgaris	Moderate	++		
			TB specific	Progressive	TB fungosa serpiginosa	Poor	+++		
			TB specific	Generalized	Miliary TB	Poor	+++		
Secondary	Exogenous	Reinoculation	TB specific	Localized	TB verrucosa cutis	Good	+/-		
			TB specific	Progressive	TB cutis orificialis	Poor	+++		
			Endogenous	Contiguous	TB specific	Localized	Lupus vulgaris	Moderate	++
					TB specific	Localized	Scrofuloderma	Poor	+++
					TB specific	Localized	TB verrucosa cutis	Good	+/-
				Hematogenous	TB specific	Progressive	TB cutis orificialis	Poor	+++
	TB specific	Localized			Lupus vulgaris	Moderate	+++		
	TB specific	Localized			Gumma (subcutaneous abscess)	Moderate	++		
	Tuberculid	Endogenous	Hematogenous	TB specific	Localized	Ulcerative TB	Moderate	++	
				TB specific	Progressive	TB fungosa serpiginosa	Poor	+++	
				TB specific	Progressive	TB cutis orificialis	Poor	+++	
				TB specific	Generalized	Miliary TB	Poor	+++	
Variable				Localized	Erythema induratum	Moderate-to-good	-/+		
Variable				Scattered crops	Papulonecrotic tuberculid	Moderate-to-good	-/+		
			Variable	Generalized	Lichen scrofulosorum	Moderate-to-good	-/+		

+++ : numerous bacilli; ++ : some bacilli; +/- : bacilli rarely found; -/+ : unusual to find bacilli; +? : variable, depending on time course



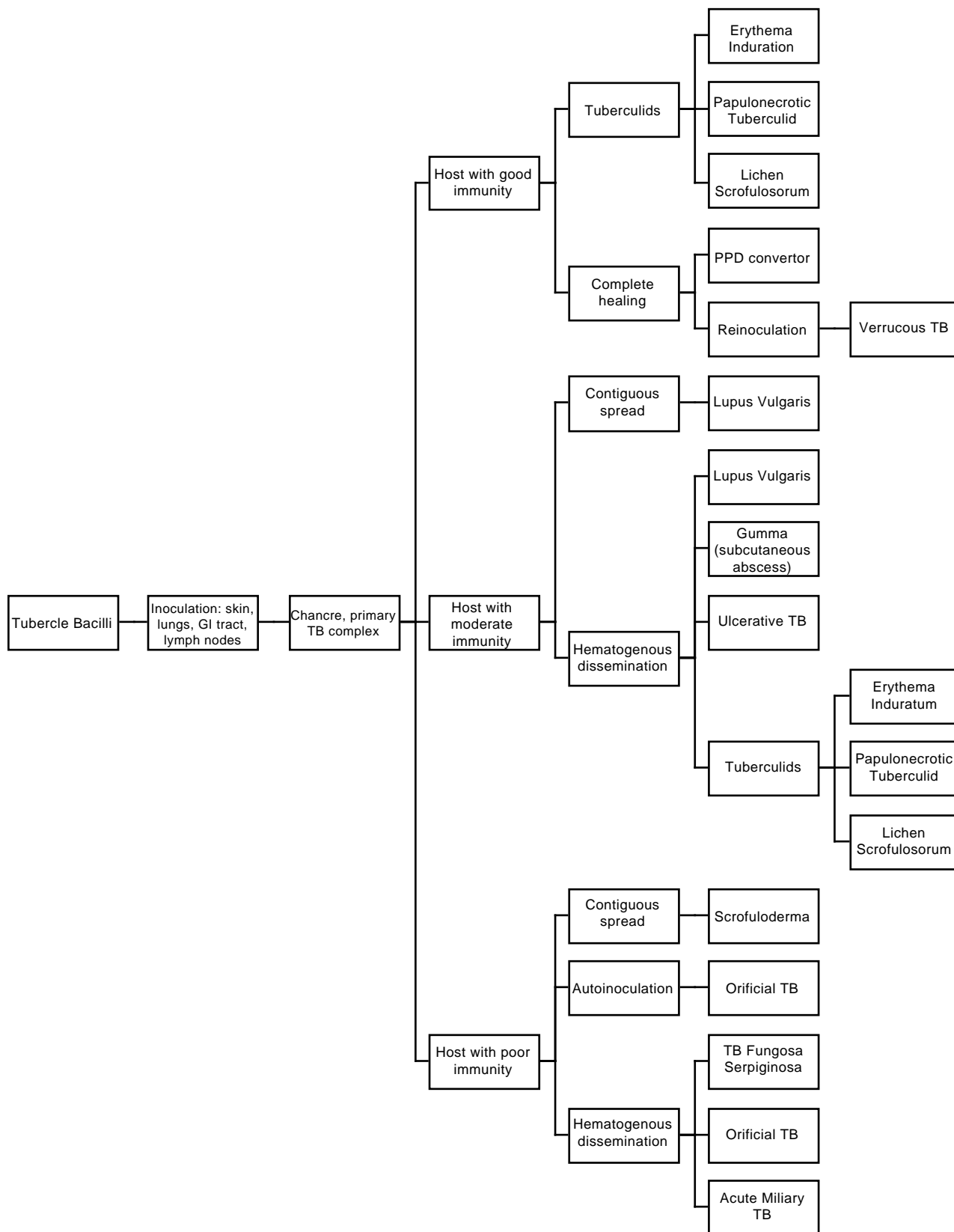


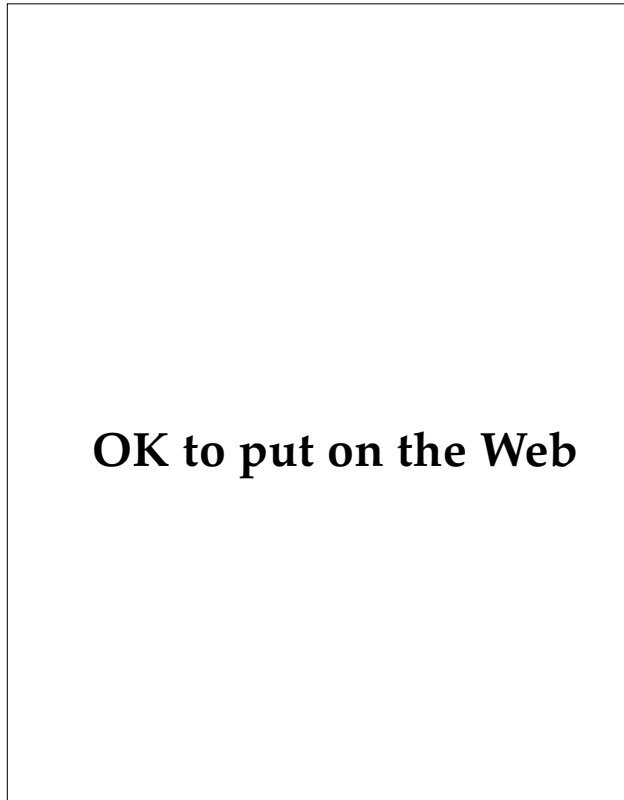
Fig. 15-3. General pathogenesis of cutaneous tuberculosis

### Clinical Features

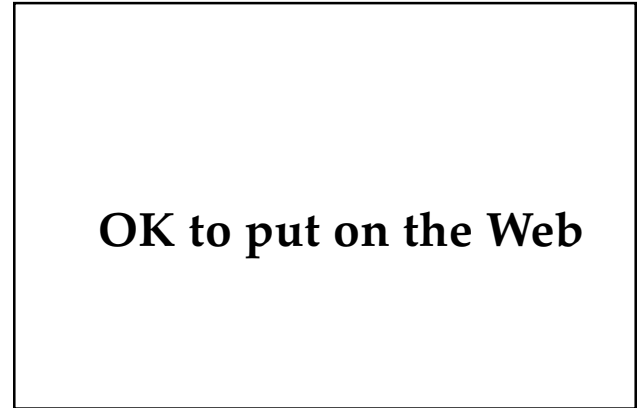
After an incubation period of 3 to 4 weeks following inoculation, a small inflammatory papule develops, which quickly breaks down into an indolent, firm, nontender, sharply delimited ulcer with no tendency for spontaneous healing for several weeks (Figures 15-4 and 15-5). After 3 to 8 weeks, tubercle bacilli reach the regional nodes, producing a painless lymphadenitis. This ulceroglandular complex is the prototype of primary inoculation tuberculosis, the skin analog to the primary pulmonary Ghon complex. The PPD usually becomes positive following the development of lymphadenopathy, although early treatment may prevent conversion.

### Laboratory and Histological Features

Tuberculin testing is negative early in the course of disease. Conversion will usually occur at the time that lymphadenopathy becomes apparent.



**Fig. 15-4.** A painless, well-circumscribed ulcer of primary inoculation tuberculosis is seen on the nose of a child.



**Fig. 15-5.** A well-circumscribed, indolent, nontender, clean ulcer (1.5 x 3.0 cm) of primary inoculation tuberculosis is seen on the right lateral thigh of a child.

The earliest histological sign of primary inoculation tuberculosis is that of an acute neutrophilic reaction with areas of necrosis, ulceration, and the presence of numerous tubercle bacilli. After 3 to 6 weeks, immunity usually develops and the infiltrate becomes granulomatous. Epithelioid cells, Langhans'-type giant cells, and a peripheral rim of lymphocytes are present. Caseation necrosis may develop with a subsequent decrease in the number of tubercle bacilli. Changes in the lymph nodes are similar.

### Course and Prognosis

After 1 to 3 months, the primary lesion usually heals with scarring. Rarely, the condition may last up to 1 year. In patients with poor immunity and large bacterial load, acute miliary tuberculosis can develop, with a fatal course. Usually, however, satisfactory host immunity with a high degree of tuberculin sensitivity result. Nonetheless, latent foci of infection can later reactivate locally or shed organisms hematogenously to distant sites. By these mechanisms, lupus vulgaris or even tuberculosis verrucosa cutis may develop as late sequelae of primary inoculation tuberculosis. Regional lymph nodes may liquefy, producing scrofuloderma. In as many as 10% of patients, erythema nodosum may develop as a nonspecific hypersensitivity reaction.

### Differential Diagnosis

The differential diagnosis of primary inoculation tuberculosis includes primary syphilis, tularemia, cat-scratch disease, sporotrichosis, and other

ulceroglandular infectious diseases. Dark-field microscopy can confirm syphilis. The clinical setting and culture of lesional tissue are most useful for distinguishing the other conditions.

### **Tuberculosis Verrucosa Cutis**

Tuberculosis verrucosa cutis, a verrucous (ie, wartlike) form of reinfection tuberculosis, is also called warty tuberculosis, prosector's wart, verruca necrogenica, tuberculosis cutis verruca, postprimary inoculation tuberculosis, and verrucous tuberculosis. The disease occurs when the skin of a previously infected or BCG-immunized (sensitized) host, who possesses a moderate or high degree of immunity, is subjected to exogenous reinfection with tubercle bacilli.

### **Epidemiology**

Reinoculation occurs at sites of minor abrasions or wounds. In the past, tuberculosis verrucosa cutis was an important occupational hazard for physicians, pathologists, medical students, laboratory attendants, and so forth, who were infected by tuberculous patients or by autopsy material. Veterinarians, farmers, and butchers are likewise susceptible to infection from tuberculous cattle. Autoinoculation from tuberculous sputum rarely occurs.

### **Clinical Features**

The initial lesion of tuberculosis verrucosa cutis is a painless, dusky red, firm papule or papulopustule that expands peripherally and is surrounded by an inflammatory halo that develops at the site of inoculation. It quickly develops a verrucous keratotic surface. By gradual, irregular, centrifugal expansion and growth, along with spontaneous central resolution, a polycyclic, serpiginous, or annular plaque with a warty, advancing border and central area of atrophy develops (Figure 15-6). Areas of softening, especially in the center, may be present. Pus and keratinous material may be expressed from the fissures in the warty areas. Lesions occur on areas exposed to trauma. Hands and fingers are most common sites in the West, but the lower extremities are affected most frequently in the East. The classic lesion is solitary, but multiple lesions also occur. Lymphadenopathy is characteristically absent. Lymph node enlargement, when present, may be the result of secondary infection. The lesions rarely ulcerate, and spontaneous invo-

## **OK to put on the Web**

**Fig. 15-6.** Tuberculosis verrucosa cutis on the dorsal surface of the left hand, demonstrating a large, warty-appearing plaque with central clearing

lution may occur over months to years.

Some of the documented unusual clinical presentations of tuberculosis verrucosa cutis are perianal ulcerations from gastrointestinal inoculation, sclerotic masses, fungating granulomas, disseminated tuberculosis with cutaneous and pulmonary involvement in an immunocompetent patient, and multifocal guttate tuberculosis verrucosa cutis.<sup>43</sup>

### **Laboratory and Histological Features**

Tuberculin testing usually shows a moderate-to-marked positive reaction.

Hyperkeratosis, hypergranulosis, acanthosis, and papillomatosis of the epidermis are present in tuberculosis verrucosa cutis. Abscesses form at the dermo-epidermal junction and in the superficial dermis. Variable numbers of tuberculoid granulomas with a modest amount of caseous necrosis and a few acid-fast bacilli are seen in the mid-dermis. With time, marked fibrosis occurs.

### **Course and Prognosis**

Lesions may evolve and last for years or even decades. Overall, the prognosis is good.

### **Differential Diagnosis**

The differential diagnosis of tuberculosis verrucosa cutis includes iododerma and bromoderma, chronic vegetative pyoderma, squamous cell carcinoma, verrucous carcinoma, North American blastomycosis, chromoblastomycosis, verrucous

atypical mycobacterial infection, verrucous lupus vulgaris, and tertiary syphilis. Consequently, biopsy, culture, and macroscopic and microscopical examination for aggregated colonies of organisms (ie, grains) in exudates, when present, help to distinguish among these entities.

### Miliary Tuberculosis of the Skin

Miliary tuberculosis of the skin, a rare form of acute or subacute cutaneous tuberculosis, is also called tuberculosis cutis miliaris disseminata, tuberculosis cutis miliaris acuta generalisata, and disseminated miliary tuberculosis of the skin. This disease occurs primarily in infants or children and is caused by hematogenous dissemination of *M tuberculosis* from an internal focus of disease, usually pulmonary or meningeal, often following infections that reduce the host immune response (eg, measles). Tuberculin sensitivity is usually absent and bacterial load very high.

In the United States during the period 1963 through 1986, of the 22,506 cases of tuberculosis reported, 289 cases (0.01%) were of miliary tuberculosis.<sup>30</sup> Several cases associated with AIDS have been reported.<sup>31,32,46</sup>

#### Clinical Features

Disseminated lesions occur on all parts of the body with predilection for trunk, thighs, buttocks, and genitalia. The mucous membranes of the mouth can also be affected. The primary lesions erupt as discrete, pinhead-sized, bluish red-to-brownish red macules or papules, often with a hint of purpura. They may be capped with minute vesicles, which soon burst and desiccate to form crusts. The lesions are often densely packed. Other forms of lesions may accompany the eruption, including macules, large pustular lesions, ulcerations, subcutaneous nodules, and purpuric lesions. All of these lesions are bacteria rich.

#### Laboratory and Histological Features

Tuberculin testing is almost always negative.

The characteristic features of miliary tuberculosis of the skin are (a) focal areas of necrosis and (b) abscess formation containing numerous tubercle bacilli. These may be surrounded by a zone of macrophages. Bacilli may also be found intravascularly. If and when immunity develops, lymphocytic cuffing of the vessels and tubercles can be seen.

### Course and Prognosis

The general prognosis of miliary tuberculosis of the skin is poor: it is usually a harbinger of death due to overwhelming infection. However, with aggressive therapy, a few survive. In patients whose internal manifestations do not prove fatal, spontaneous healing occurs with significant scarring as a sequela.

### Differential Diagnosis

The differential diagnosis includes Letterer-Siwe syndrome, pityriasis lichenoides acute et varioliformis, secondary syphilis, and drug reactions. The Venereal Disease Research Laboratory test (VDRL, with prozone check) and biopsy are definitive.

### Scrofuloderma

Scrofuloderma, a subacute form of tuberculosis that occurs in patients who have already evolved through a primary tuberculous complex, is also called tuberculosis colliquativa cutis and tuberculous gumma. The disease usually originates as a tuberculous process of the subcutaneous tissues leading to the formation of cold abscesses and then secondary breakdown of the overlying skin. The tuberculous foci are commonly in the lymph nodes, bones and joints, and epididymis.

### Epidemiology

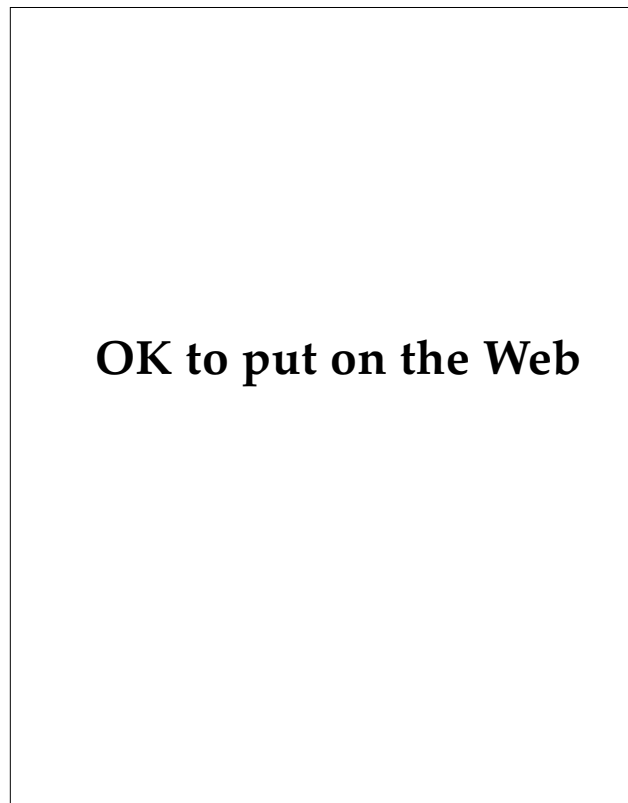
In earlier times, scrofuloderma was common in children—80% following an oral or tonsillar primary inoculation of bovine tuberculosis from infected milk.<sup>24</sup> The elderly are also susceptible, particularly when their immune defenses are compromised. True tuberculous lymphadenitis is becoming less common in children and is more often due to atypical mycobacteria: *M avium*, *M intracellulare*, or *M scrofulaceum*.<sup>43</sup> Scrofuloderma occurs rarely from the introduction of exogenous tubercle bacilli into the subcutis by trauma, or by injections into individuals with previous latent or manifest tuberculosis.

### Clinical Features

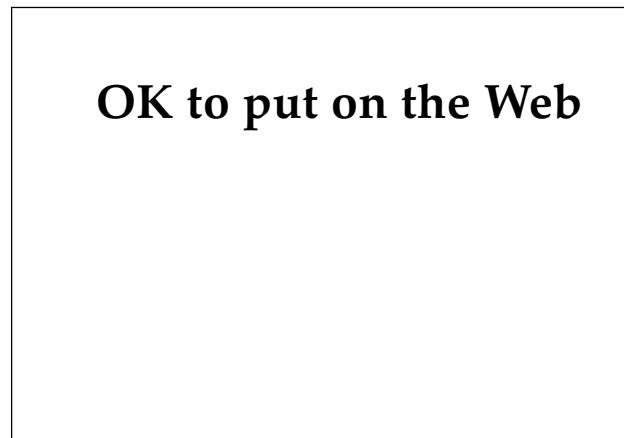
Patients with the initial lesion present with a firm, subcutaneous or deep cutaneous swelling or nodule, which is freely movable initially but soon firmly attaches to the skin and later ulcerates. The

ulcers tend to have bluish, undermined edges and soft, granulating floors. Watery, purulent, or caseous discharge may exude from the sinuses.

Cervical lymph nodes are infected most commonly on the side of the neck where the primary tuberculous complex was located (Figures 15-7 and 15-8). In the neck, the tonsillar, submandibular, preauricular, postauricular, occipital, and supraclavicular lymph nodes are usually implicated. The parasternal, axillary, inguinal (Figure 15-9), and epitrochlear nodes are potential sites, as well. In adults who have scrofuloderma, multiple lesions may form through hematogenous dissemination, especially on the trunk and pubic and buttock regions. Patients with lesions on the buttocks present with liquefying abscesses, fistulae, and purulent drainage resembling hidradenitis suppurativa.<sup>24</sup> Occasionally, discharging sinuses may occur over areas normally devoid of nodes. Over weeks to months the nodes enlarge, turn livid red, suppurate, then perforate with resultant ulceration and



**Fig. 15-7.** Scrofuloderma of the left cervical lymph nodes in a Central American adolescent male. Note the enlarged lymph nodes immediately inferior to the mandible and the multiple, perforating sinus tracts.



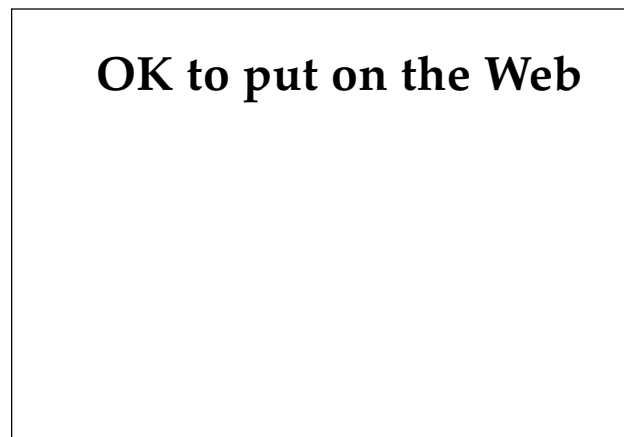**Fig. 15-8.** Scrofuloderma of long-standing duration in the neck. Note the boggy, edematous skin surrounding a number of perforating sinus tracts.

fistula formation. Over time, multiple fistulae form; severe, cordlike scarring bridges the ulcerations.

Spontaneous healing does occur, but it takes years before it is completed. Cordlike keloidal scars and localized recurrences are characteristic.

#### **Laboratory and Histopathological Features**

Tuberculin sensitivity is usually marked. Massive ulcers and abscesses form in the center of the lesion. Tuberculoid structures with marked caseation necrosis are present in the lower dermis and at the periphery of the ulcerations or abscesses. Epithelioid cells form the major component. A



**Fig. 15-9.** Scrofuloderma of the left inguinal lymph nodes showing subcutaneous swelling and purulent ulceration

large number of giant cells are present. Acid-fast bacilli are easily identified. As the lesion ages, caseation necrosis occurs and the number of organisms decreases. Occasionally, granuloma formation may not be apparent and the sections may only show a nonspecific, chronic, inflammatory infiltrate.

### *Course and Prognosis*

Scrofuloderma is usually associated with manifest tuberculosis elsewhere in the body, usually in the lungs and occasionally in the abdomen. Lupus vulgaris may occur at the site, in the vicinity, or in the scar of scrofuloderma. Malignant change in the form of an epithelioma can occur, and the very infrequent association of cutaneous tuberculosis with systemic amyloidosis was reported in a case of scrofuloderma.<sup>43</sup>

### *Differential Diagnosis*

The differential diagnosis includes tertiary syphilis, deep fungi (eg, sporotrichosis, actinomycosis, severe acne conglobata, hidradenitis suppurativa), and chronic granulomatous disease. Biopsy and culture are the definitive tests for the diagnosis.

### **Tuberculosis Cutis Orificialis**

Tuberculosis cutis orificialis is also called orificial tuberculosis and tuberculosis ulcerosa cutis et mucosae. Orificial tuberculosis is the tuberculosis of the mucous membranes and the skin of the orifices, resulting from autoinoculation of the tubercle bacilli in patients with advanced visceral tuberculosis. Its occurrence by lymphatic or hematogenous extension is rare.

### *Epidemiology*

Tuberculosis cutis orificialis affects men more often than women and is most prevalent in middle-aged or older individuals. The underlying disease is advanced pulmonary, intestinal, or genitourinary tuberculosis. At a traumatized site, bacilli that are shed from these foci become inoculated into the mucocutaneous areas of the orifices.

### *Clinical and Diagnostic Features*

Ulcerative lesions of tuberculosis cutis orificialis occur in the oral cavity and the perineal or perirectal areas. The tongue—particularly its tip and lateral margins—is the site most commonly affected in the

mouth. Other sites in the mouth are the soft and hard palate, lips, and in a tooth socket after extraction. In a patient with intestinal tuberculosis, the area on and around the anus is involved; with genitourinary tuberculosis, the vulva, glans, penis, and urinary meatus are involved. The lesion consists of a small, yellowish or reddish nodule that rapidly breaks down to form an exquisitely painful, shallow ulcer with bluish, undermined edges. The surrounding mucosa is swollen and the ulcer is covered by pseudomembranous material. Ulcers do not heal spontaneously and are signs of a poor prognosis.<sup>43</sup>

Cutaneous hypersensitivity to tuberculin in these patients is controversial; however, there is an absolute consensus that such patients ultimately develop anergy.

Histologically, in most cases, tuberculoid infiltrates with pronounced necrosis are found deep in the dermis. Acid-fast bacilli are easy to demonstrate. Ulceration and edema are the rule.

### **Lupus Vulgaris**

Lupus vulgaris, also called tuberculosis cutis luposa, is a reinfection tuberculosis of the skin occurring in previously sensitized individuals who have a high degree of tuberculin sensitivity. The disease may have protean and dramatic clinical presentations. Hypersensitivity to tuberculin is high, although immunity is low to moderate.

### *Epidemiology*

Lupus vulgaris is not only the most frequent type of cutaneous tuberculosis, it also has the greatest potential for disfigurement. Worldwide, approximately 50,000 new cases are diagnosed each year, and women tend to be affected twice as commonly as men.<sup>24</sup> Patients are usually tuberculin positive.

As many as two thirds of patients with lupus vulgaris are found to have visceral foci of tuberculosis. Of these, 40% have tuberculous adenitis or involvement of the mucous membranes, and 10% to 20% have pulmonary, bone, or joint tuberculosis.<sup>43</sup>

### *Pathogenesis*

Lupus vulgaris is a cutaneous form of postprimary tuberculosis. Because it may develop in the site of primary inoculation tuberculosis, in the scar of scrofuloderma, or after BCG immunization (particularly after multiple BCG vaccinations), it is likely that lupus vulgaris arises from a latent focus of

tuberculosis that is triggered into activity by later trauma or injury. Alternatively, the disease can arise from the perforation of tuberculous abscesses into the skin or from endogenous dermal inoculation of tubercle bacilli (via lymphatic or hematogenous metastasis) from a reactivated focus in an internal organ.

### Clinical Features

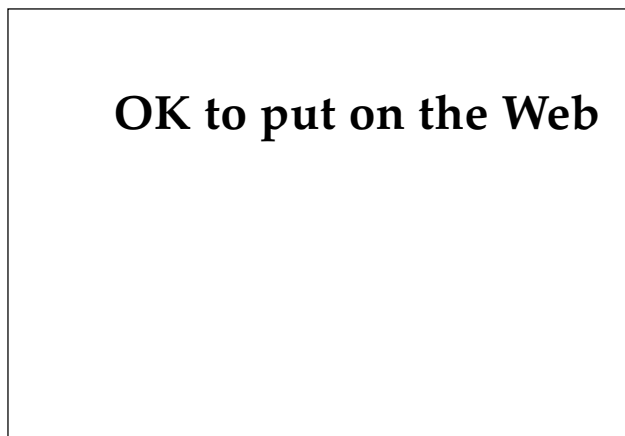
In western countries, lupus vulgaris is most common on the face, especially the nose and cheeks, followed by the ears, the extensor surfaces of the extremities, the buttocks, and the breasts. However, in India and many developing nations, the lower extremities, especially the buttocks, are the primary site of involvement. It is exceedingly rare for the mucous membranes to be involved.

The initial lesions are usually solitary. Occasionally, two or more foci can occur. Rarely, in the case of a preceding period of anergy, disseminated lesions may occur, resulting in lupus vulgaris postexanthematicus.

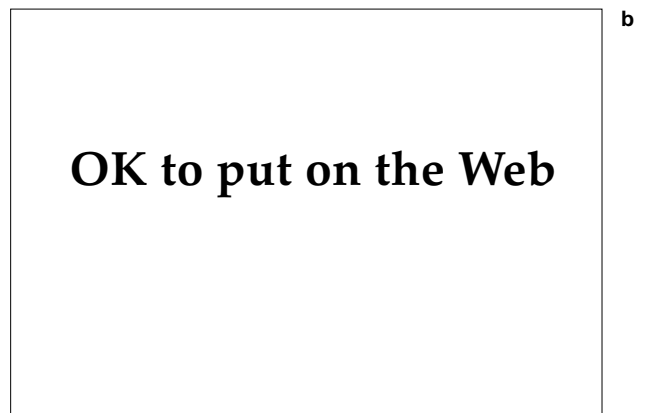
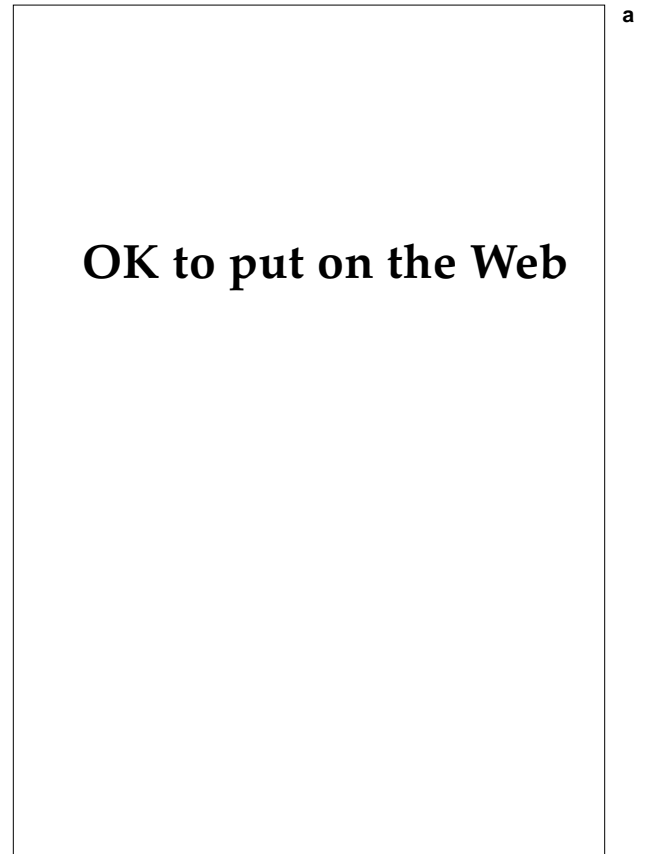Clinically, the earliest lesion appears as small, brownish red papules of soft gelatinous consistency, often resembling a small hemangioma. On diascopy, the characteristic translucent, apple jelly-colored lupoid infiltrates may be demonstrable (Figure 15-10), although they are rarely seen in the tropics because of the natural dark color of the skin of the indigenous populations. From these small granulomas, the various forms of lupus vulgaris develop over the course of years.

As the lesions enlarge, caseation necrosis pro-

ceeds, resulting in softening of the lesions. Probing with a blunt instrument at this stage may cause lesions to perforate. With time, the lesions become more infiltrated, elevated, and brown. They grow by peripheral extension and are accompanied by



**Fig. 15-10.** The lesions of lupus vulgaris on this patient's nose show the characteristic apple jelly-colored papules on diascopy.



**Fig. 15-11.** (a) An extensive plaque of lupus vulgaris can be seen on the patient's thigh. (b) A closer view of same patient shows an active border, relative central clearing, and new papules in previously cleared areas.

central atrophy or scarring (Figures 15-11 and 15-12). The reactivation of nodules within previously atrophic or scarred areas (ie, fresh papules may appear in old areas) is characteristic of the disease. A few sentinel lupus nodules may be present at the periphery on the normal skin. Lesions are usually asymptomatic.

Several clinical variants are seen:

- Lupus vulgaris exfoliatus is characterized by plaques with a psoriatic scale. Over time, serpiginous or polycyclic configurations may develop with central clearing and atrophy. Large plaques will have both (a) active scaly and (b) scarred and/or atrophic nonscaly areas.<sup>47</sup>
- Lupus vulgaris verrucosus results from a wartlike pseudoepitheliomatous hyperplasia of the epidermis.
- Lupus vulgaris ulcerosus forms when mas-

sive necrosis occurs within the tuberculous granulomas. This ulcerative variant may be accompanied by deep destruction of underlying tissues and cartilage.

- Lupus vegetans (also called lupus papillomatosus) is a vegetative form of lupus vulgaris that often occurs in regions of erosive or ulcerative disease.
- Lupus vulgaris postexanthematicus is a disseminated papular or nodular form that usually arises during a period of anergy or waning immunity (eg, following measles).
- Lupus vulgaris of the mucous membranes is a rare and special form of lupus vulgaris arising in the mucous membranes by direct extension of skin lupus to the buccal, nasal, or conjunctival mucosa. This form can be highly destructive and disfiguring.

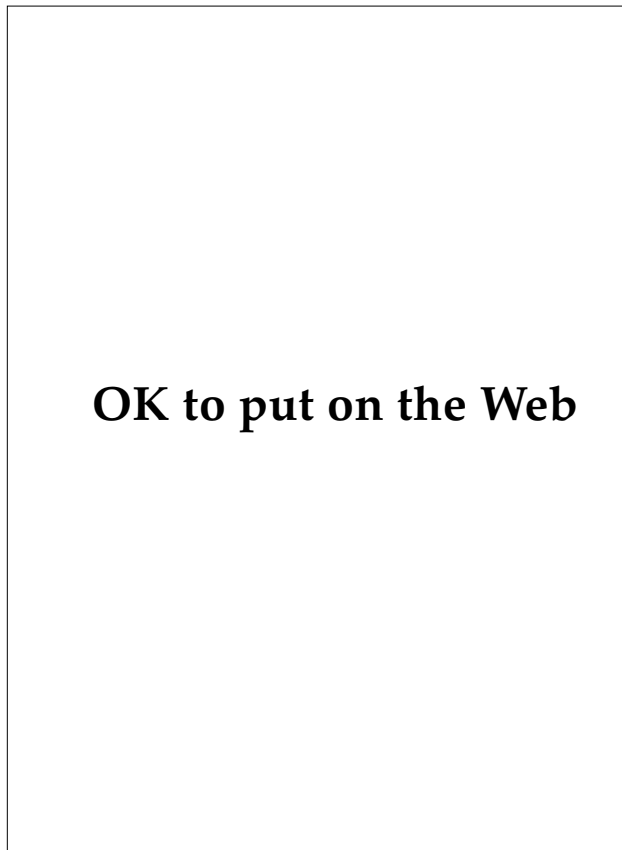
### Laboratory Features

Bacilli in lupus vulgaris are few and sparse. Inoculated guinea pigs usually succumb to disseminated tuberculosis at the anticipated time when inoculated with lesional tissue. Tuberculin testing is usually positive. The recent use of polymerase chain reaction (PCR) techniques to diagnose the presence of *M tuberculosis* deoxyribonucleic acid (DNA) in formalin-fixed, paraffin-embedded tissue within approximately 2 days promises to greatly facilitate the diagnosis of this and other forms of cutaneous tuberculosis.<sup>48</sup>

Diagnosis of the internal focus of tuberculosis may be aided by modern methods such as sonography, computerized tomography, and magnetic resonance imaging.

### Histological Features

The most prominent histological feature of lupus vulgaris is the presence of granulomas, usually in the upper dermis, composed of epithelioid cells, Langhans'-type giant cells, mononuclear cells, and a peripheral zone of lymphocytes. Epithelioid cells and lymphocytes predominate. Caseation necrosis is uncommon and minimal. Bacilli are difficult to find. Secondary epidermal changes (eg, atrophy, ulceration, acanthosis, or pseudoepitheliomatous hyperplasia) may be present. Occasionally, squamous cell carcinoma may be present. Foreign-body granulomas may develop. Occasionally, the necrosis and ulceration are accompanied by nonspecific inflammatory infiltrates, which may mask the tuberculous character of the disease.



**Fig. 15-12.** Lupus vulgaris on the neck and back. Scarring with severe hypopigmentation and an active, advancing margin, especially over the left scapula, can be seen.



### Course and Prognosis

Lupus vulgaris can be a very protean, destructive disease. In the absence of treatment, it may progress slowly over years or even decades. Because of its relatively slow progression, the disease is usually present for more than 5 years before a definitive diagnosis is made. Yet, the lesions remain essentially noncontagious (although the underlying organ tuberculosis may be quite contagious). Severe scarring and disfigurement of cosmetic areas may occur (eg, ectropion, distortion of the mouth, or destruction of the nose). Where scarring encompasses an entire lower extremity, distal elephantiasis can develop. The most critical areas where severe mutilation can result tend to be the face, hands, and feet.

Patients with pulmonary tuberculosis in combination with lupus vulgaris have a 4- to 10-fold higher mortality rate than patients with pulmonary tuberculosis alone.<sup>49</sup>

Long-standing lupus vulgaris can be complicated by the development of squamous cell carcinoma. Other tumors are exceedingly rare during the course of lupus vulgaris but can include basal cell carcinoma, sarcoma, and Hodgkin's disease.

Tuberculids such as lichen scrofulosorum and papulonecrotic tuberculid can be seen in conjunction with lupus vulgaris.

### Differential Diagnosis

Although the presence of apple jelly nodules is characteristic of lupus vulgaris, it is not pathognomonic. Other diseases with similar lupoid infiltrates that look like apple jelly nodules include lupoid leishmaniasis, sarcoidosis, lupoid rosacea, lupus erythematodes lupoide, pseudolymphoma of the skin, chronic granulomatous disease, and Spitz nevi. The real identification of a lupoid infiltrate as lupus vulgaris is done with a blunt probe, which easily breaks through the overlying epidermis into the nodule due to the caseous necrosis present in the lesions. Biopsy with special stains for organisms and culture are important diagnostic procedures to differentiate these other lupoid conditions.

### Other Rare Forms of Cutaneous Tuberculosis

#### Tuberculous Gumma

Tuberculous gumma (also called metastatic tuberculous abscess) is a rare form of tuberculosis that results from hematogenous spread from a primary

focus of infection during periods of bacilleemia and lowered resistance.<sup>50</sup> The disease usually occurs in malnourished children, and immunodeficient or immunosuppressed patients. The lesions are single or multiple, cold, subcutaneous nodules, which liquefy into nontender abscesses and perforate the skin, forming ulcers and sinus tracts. Tuberculin sensitivity is modest. Occasionally, the lesions mimic the lymphatic spread of sporotrichosis. With the spread of HIV infection, atypical forms of many infectious diseases are being seen, including tuberculosis. Several cases of isolated subcutaneous abscesses arising through hematogenous spread have been reported, two of which follow.

**Case 1.**—A 58-year-old, immunocompetent male presented with a 9-month history of several disseminated subcutaneous ulcerative nodules, fever, and weight loss associated with pulmonary tuberculosis. Large skin biopsies grew *M tuberculosis* in 6 to 8 days, whereas sputum samples and smaller biopsies grew out in 4 weeks. These lesions seemed to represent a type of hematogenous dissemination intermediate between classic cold abscesses (gumma) and acute miliary tuberculosis of the skin.<sup>51</sup>

Even in areas where tuberculosis is endemic, ulcerative forms are extremely rare and are often misdiagnosed because the physician has a low index of suspicion.

**Case 2.**—A 19-year-old Filipino male presented with (a) a 2-month history of persistent, dry cough; general malaise; and 7-kg weight loss, despite good appetite; and (b) a 5-month history of an enlarging, painful, purulent ulcer 4- x 8-cm in diameter, in the midlumbar area; and a nonfluctuant, 4-cm swelling involving the sternum. The ulcer was well demarcated, with a violaceous, slightly heaped-up border; an undermined edge; and a scant, light brown, cheesy, purulent discharge. Histological examination showed early granuloma formations. No organisms were identified. Roentgenograms of the chest showed bilateral, upper-lobe, nodular densities without definite hilar lymphadenopathy. A solitary lytic lesion was present in the sternum, consistent with osteomyelitis. Culture from bronchial washings and from tissue biopsy grew *M tuberculosis* in 2 and 6 weeks, respectively. PPD was strongly positive at 27-mm induration and 55-mm erythema (such hypersensitivity is consistent with the negative acid-fast stains since a higher degree of immunity is presumed). Triple drug therapy with isoniazid (isonicotinic acid hydrazide [INH]), rifampin, and ethambutol cleared the ulcer in 5 months. Therapy was continued for 1 year.<sup>52</sup>

Such ulcerated tuberculous gummas usually arise in adolescents, and are found on the extremities; occasionally on the trunk; and often in the presence of silent, deep foci of tuberculosis. These gummas

result from secondary breakdown of subcutaneous cold abscesses.

### *Tuberculosis Fungosa Serpiginosa*

*Tuberculosis fungosa serpiginosa* is a very rare, chronic form of skin tuberculosis that occurs in anergic, elderly individuals via endogenous or exogenous inoculation. Patients with this disease present with thick, papillomatous, vegetative, noncornified plaques (commonly in the axilla or on the backs of the hands) that resemble a chronic, vegetative pyoderma. The lesions are notable for fissures and fistulae with serous or purulent exudate. The lesions and exudates are bacillary rich. Tuberculin sensitivity is absent. With peripheral extension and central healing, annular and serpiginous lesions are formed.

### *Iatrogenic Immunization Tuberculosis*

Tuberculosis infection—ranging from primary inoculation complex to scrofuloderma, lupus vulgaris, or acute miliary tuberculosis—can also result from BCG immunization.<sup>50,53</sup> Since the BCG immunization organism is an attenuated *M tuberculosis bovis*, it can behave as a virulent opportunistic pathogen where immunity is depressed or lacking. With the worldwide increase in AIDS, the potential for such iatrogenic disease is growing.

### *Tuberculous Mastitis*

Patients with this rare form of tuberculosis involving the breast present with a nontender, cold abscess. Diagnosis depends on microbiologic and histological investigations.

## DIAGNOSIS

Diagnosis of cutaneous tuberculosis certainly requires (a) evidence of the tubercle bacilli either in the smear or in tissue sections or (b) its recovery in vitro (Exhibit 15-1). Various workers have tried but failed to demonstrate the bacilli in the histological sections of the usual variants of cutaneous tuberculosis using the routine acid-fast staining. Fluorescent staining with auramine or rhodamine is more effective; the results in lupus vulgaris, however, are still disappointing. Thus, the absolute diagnosis can be established only when the bacilli are isolated. Unfortunately, however, most investigators report a low incidence of positive culture growths in cutaneous tuberculosis.

The immunological diagnosis may be established in pulmonary tuberculosis by the tuberculin test, enzyme-linked immunosorbent assays for antibody to PPD and to *M tuberculosis* antigen 6, and specific tests using monoclonal-antibody and recombinant-DNA techniques. These latter two techniques might be employed in the diagnosis of cutaneous tuberculosis in the future.

One group of investigators,<sup>39</sup> utilizing the Mantoux test (ie, an intradermal injection of 0.1 mL of tuberculin [10 tuberculin units/0.1 mL]) in a prospective study of 70 patients with cutaneous tuberculosis (lupus vulgaris, verrucous tuberculosis, and scrofuloderma only), noted that all patients were moderately to highly reactive.

However, the most promising and exciting new technique for the rapid diagnosis of tuberculosis is the use of the PCR for the detection of *M tuberculo-*

*sis*-specific DNA fragments. This amplification technique yields millions of copies of tuberculosis-specific target nucleotide sequences. The particular

### EXHIBIT 15-1

#### CRITERIA FOR THE DIAGNOSIS OF CUTANEOUS TUBERCULOSIS

##### Absolute Criteria

- Culture
- Guinea pig inoculation
- Positive polymerase chain reaction to *Mycobacterium tuberculosis* complex

##### Relative Criteria

- Compatible history and skin examination
- Active, visceral tuberculosis
- Positive tuberculin-purified protein derivative reaction
- Positive enzyme-linked immunosorbent assay for antibody to purified protein derivative of tuberculin reaction or to *M tuberculosis* antigen 6
- Compatible histopathology
- Acid-fast bacilli in lesion
- Fluorescent staining of *M tuberculosis* organisms with auramine or rhodamine
- Response to specific tuberculosis therapy

assay having the greatest promise, due to its high sensitivity and specificity, is based on detection of a putative insertion sequence IS6110. This is usually present in 6 to 15 copies in most strains of *M tuberculosis*. Unlike other PCR-based assays, this method does not require hybridization of the PCR product to DNA probes, thus simplifying the test for routine clinical use. Other primer-probe sequences in use include ribosomal RNA, the DNA sequence mtp40, DNA encoding on a 38-kilodalton or 65-kilodalton protein, and MPB64.<sup>26</sup>

Because PCR reactions can be performed on formalin-fixed, paraffin-embedded sections, they hold

great promise for the diagnosis of extrapulmonary tuberculosis, especially of the cutaneous type. Not only has *M tuberculosis*-complex DNA been demonstrated in paraffin-embedded sections taken from proven cases of lupus vulgaris,<sup>54</sup> scrofuloderma,<sup>55</sup> and several other types of cutaneous tuberculosis,<sup>56</sup> but such probes have also been used to diagnose several tuberculid reactions as being truly tuberculous in origin,<sup>57</sup> allowing for a quicker diagnosis and treatment of the underlying systemic tuberculosis.<sup>58</sup> Turnaround time for the diagnosis takes only a few days, in contrast to the weeks required for culture and identification or inoculation.

## TREATMENT

As in tuberculosis of other organs, chemotherapy is the treatment of choice for cutaneous tuberculosis (Table 15-2). The only exception is the occasional use of cryosurgery or electrocautery for destroying small lupus nodules within scarred areas.<sup>43</sup>

Of great importance, especially in the Third World, has been the development of short-course, four-agent chemotherapy regimens for 6 months.<sup>59</sup> Treatment of smear-positive or culture-positive pulmonary or extrapulmonary tuberculosis is essentially identical. For the four-agent regimen, an initial combination of isoniazid, rifampin, pyrazinamide, and either ethambutol or streptomycin is given daily for 2 months. Subsequently, a 4-month course of isoniazid and rifampin is given. However, due to the increasing number of patients with single or multiple drug resistance, cure rates may drop as much as 20% to 25% for each drug the mutant bacilli are able to resist.<sup>10</sup> Resistance rates in New York City for one drug are as high as 33%, for two drugs, 26%. One study<sup>60</sup> found resistance to isoniazid to be 25%; rifampin, 20%; isoniazid-rifampin, 16%; and isoniazid-rifampin-streptomycin-ethambutol resistance, 13%. The virulence of this modern plague is accentuated in that the case-fatality rate exceeds 50% for patients with multidrug-resistant diseases, and approaches 90% for patients with HIV infection. The extent of the problem is illustrated by conditions in Manila, where as many as 80% of patients who present for treatment of tuberculosis are resistant to at least one, if not to several, drugs.<sup>10</sup>

Nosocomial outbreaks of multidrug-resistant organisms have been devastating. In a survey of outbreaks in hospitals and prisons in New York and Florida,<sup>61</sup> 96% of patients had underlying HIV infection. The case-fatality rate was 72% to 89%, with death

occurring in 4 to 19 weeks following diagnosis, despite aggressive multidrug therapy. Six of eight hospital staff who became infected with these resistant organisms were also positive for HIV; four have died.

Factors leading to multidrug resistance include monotherapy, erratic drug ingestion, omission of one or more of the prescribed chemotherapeutic agents, suboptimal dosage, poor drug absorption, insufficient number of active chemotherapeutic agents in a regimen, cavitary disease, and HIV infection.<sup>60,61,62</sup> In one study<sup>62</sup> of HIV-infected individuals, the median survival time for those with AIDS was 1.5 months versus 14.8 months for those without AIDS. Various social factors that contribute to these factors include homelessness, joblessness, intravenous drug addiction, alcoholism, and other forms of irresponsible behavior that place a low priority on taking multiple medications daily for prolonged periods.<sup>60</sup>

Recommendations for multidrug resistance change continually. As of September 1993, suggested approaches for treatment include the following<sup>62</sup>:

1. Patients in communities where the risk of single-drug resistance is greater than 2% should be placed on four-drug chemotherapy: isoniazid, rifampin, pyrazinamide, and ethambutol, until the results of drug sensitivity testing are available (2-5 wk, optimally).
2. In high-risk urban areas such as New York City, where many patients show resistance to two or more agents, at least five drugs are necessary.
3. For patients in high-risk areas with HIV infection or AIDS, six-drug chemotherapy, based on local patterns of resistance, may

**TABLE 15-2**  
**TUBERCULOSIS TREATMENT: DRUGS, DOSES, AND SIDE EFFECTS**

Table 15-2 is not shown because the copyright permission granted to the Borden Institute, TMM, does not allow the Borden Institute to grant permission to other users and/or does not include usage in electronic media. The current user must apply to the publisher named in the figure legend for permission to use this illustration in any type of publication media.

\*Not available in the United States  
 PO denotes administration via oral route; IM, intramuscular route; ? denotes not known  
 Sources: Adapted with permission from (1) Kastrup EK, Olin BR, Connell SI. *Drug Facts and Comparisons*. St. Louis, Mo: Facts & Comparisons; 1988: 1534. (2) Sehgal V, Wagh S. Cutaneous tuberculosis: Current concepts. *Int J Dermatol*. 1990;29:246. (3) Iseman MD. Treatment of multidrug-resistant tuberculosis. *N Engl J Med*. 1993;329:787.

be indicated until the results of antibiotic susceptibility testing are known.

4. Drug dosages and optimal timing of administration need to be determined for each patient to achieve maximal serum concentrations in the targeted ranges without serious side effects. In addition, care should be taken to assess proper absorption of antituberculosis agents in patients with AIDS, as they commonly malabsorb these drugs.

The optimal duration of therapy has not been determined. Generally, extrapulmonic tuberculosis is treated for the time being as pulmonic. However, with miliary tuberculosis or tuberculosis of the meninges or skeleton, longer courses are required.<sup>26</sup> Patients with pulmonary tuberculosis whose organisms are resistant to all or most of the first-line chemotherapeutic agents are treated with oral medications for 24 months following conversion of the sputum cultures from positive to nega-

tive. Of those who convert, as many as 20% may relapse after therapy is discontinued.<sup>62</sup>

Turning back the clock to the preantibiotic era in selective patients with cavitary pulmonic tuberculosis may be beneficial. Iatrogenic induction of pneumothorax or pneumoperitoneum, or surgical crushing of the phrenic nerve to collapse diseased lobes (because *M tuberculosis*, being an obligate aerobe, perishes in anaerobic environments), has been of some aid in difficult cases.<sup>10</sup> Similarly, where economically feasible, presurgical chemotherapy and hyperalimentation combined with pneumonectomy or lobectomy, reinforced with a muscular flap to secure the bronchial stump, has saved several severely afflicted patients. Experience with the latter for multidrug-resistant pulmonary tuberculosis at National Jewish Center in Denver, Colorado, has been most gratifying: 49 of 50 long-term survivors have consistently had negative sputum smears and tuberculosis cultures.<sup>62</sup>

## PREVENTION

The approach to the prevention of active tuberculosis varies from country to country. In developed countries such as the United States, where drug resistance is relatively low, two forms of isoniazid prophylaxis have been effective tools. First, in patients who meet the criteria for use, a 6- to 12-month course of isoniazid (300 mg/d in adults, 5-10 mg/kg/d in children) can reduce the development of active disease by 75%. Second, a multidrug prophylaxis with isoniazid, streptomycin, rifampin, and pyrazinamide for 8 weeks resulted in an 81.5% reduction in the incidence of bacteriologically proven tuberculosis—a prophylactic course as effective as 12 months of isoniazid alone.<sup>59</sup>

In developing countries, where tuberculosis morbidity and mortality are much greater, disease prevention is most desirable. BCG vaccination against tuberculosis, which is relatively safe, inexpensive, and easy to use in the field, has been used for many years. Large-scale epidemiological studies have been attempted, but the interpretation of their results has been hampered by the biological variability of available BCG vaccines, difficulties in case ascertainment and confirmation, and the necessity for long-term follow-up. Measured efficacy of current vaccines in preventing tuberculosis ranges from nil to 80%.<sup>28</sup> Vaccination apparently does not prevent infection but shows definite protection

against the development of miliary tuberculosis and meningitis, especially when given to infants and children.<sup>28</sup> Consequently, BCG immunization should be given as early in life as possible in areas of high prevalence. However, it does not seem to prevent reactivation of latent infections.

One of the probable reasons for the failure of BCG vaccination is that immunosuppressive factors present in mycobacterial polysaccharides depress cell-mediated immunity during active infection through (a) decreased expression of human lymphocyte antigens-D-group related (HLA-DR) determinants and (b) increased production of interleukin-1. The consequences of these immunosuppressive circuits are (a) depression of tuberculin-induced blastogenesis, (b) production of interleukin-2, and (c) generation of interleukin-2 receptors (ie, natural infection with *M tuberculosis* or with BCG may cause immunosuppression).<sup>63</sup>

Thus, worldwide control of tuberculosis appears improbable unless an effective vaccine is developed. One approach is to identify virulence factors and, through the use of transposon-mediated gene inactivation, produce mutants that lack these factors. Such a strategy can provide important information regarding the specific antigens that are important to the host for protection. Genetic deletion

or modification of these virulence factors provides insight into both the mechanisms of pathogenesis and the possibilities for the development of live attenuated vaccines. Alternatively, individual antigens identified as important for protection by

antibodies and T cells could be used to generate a vaccine. Current investigation centers on genetic engineering techniques to modify and optimize the antigenic determinants on the tubercle bacillus to avoid down-regulating the immune system.

## TUBERCULOSIS AND ACQUIRED IMMUNODEFICIENCY SYNDROME

The elimination of tuberculosis in countries where it is highly prevalent, particularly Africa, may be seriously impeded by patients with AIDS and persons infected with HIV. It is inevitable that the number of cases of tuberculosis will increase in those countries with large numbers of patients with AIDS. Indeed, as AIDS increases exponentially in Africa, tuberculosis continues to keep pace with it. Many of these patients will succumb rapidly to their disease, but not before they infect family members, friends, coworkers, and others with drug-resistant organisms. Infection with *M tuberculosis* tends to occur early in the course of AIDS, often preceding the diagnosis of AIDS by several months. This is in contrast to infections with an atypical opportunistic organism such as *M avium-intracellulare*, which tends to occur later when immuno-

suppression is more profound.<sup>64</sup>

Along with the increase in the number of patients who have both AIDS and tuberculosis, developing countries face serious epidemiological problems in the chemotherapy for tuberculosis. Why? Because poor countries tend to rely on intramuscular streptomycin as part of their drug regimens instead of the more expensive oral alternative, pyrazinamide. In primitive environments, keeping syringes sterile to prevent the transmission of AIDS presents a challenge to native public health services. Disposable syringes are not the answer due to their cost and the potential for reutilization.<sup>65</sup>

A different problem concerns BCG vaccination for tuberculosis or leprosy in children in countries with a high prevalence of AIDS: the BCG organism may become a pathogen in children infected with AIDS.<sup>65</sup>

## TUBERCULOSIS CONTROL IN REFUGEE CAMPS

Tuberculosis management in refugees and other displaced persons in temporary settlements poses a great challenge to the military or to other organizations that coordinate and provide care and resettlement. Although we might suspect that the incidence, morbidity, and mortality of tuberculosis might be worse in war zones, where malnutrition and physical and emotional stress may be at their worst, recent evidence from Thailand's experience with Kampuchean refugees and Pakistan's experience with Afghan refugees suggests that the incidence of tuberculosis in refugees is similar to that in their respective countries of origin.<sup>66</sup>

Initial attention to basic needs (nutritional rehabilitation, immunization, water supply, and sanitation) is paramount. This can be followed by treatment of the most infectious patients: those with active, smear-positive tuberculosis. Without treatment, 30% to 50% of these individuals will die of their disease, having first spread their bacilli to many others in the cramped refugee camps.<sup>66</sup>

Case-finding is one of the first tasks. Sputum samples should be checked on the spot for acid-fast

bacilli in any patient presenting with (a) a history of 3 weeks of cough or chest pain or (b) hematemesis or significant weight loss. Those whose sputum tests are negative for acid-fast bacilli should be rechecked on two consecutive mornings and observed if suspicion remains, but they should not be treated at this point. Treatment should be initiated for those whose sputum tests are positive for acid-fast bacilli, and additional cases should be sought among family members and close contacts. Among contacts, children are notorious for having sputum that tests negative; consequently, if they have symptoms and signs compatible with tuberculosis, they should be treated as well. Tuberculin sensitivity is a poor predictor of active tuberculosis in child contacts of known cases.

Basically, however, a rational choice for the patient with tubercle bacilli that are fully susceptible to drugs lies between these extremes:

- a 12-month course of isoniazid combined with thiacetazone (not available in the United States, due to the high frequency of side

effects seen especially among some Asians), preferably supplemented by streptomycin for the first 2 months, which is a very inexpensive regimen; and

- a 6-month course of isoniazid combined with rifampicin (supplemented with pyrazinamide, with or without streptomycin for the first 2 mo), which is an expensive regimen.

Whichever course is selected, patients being treated should be monitored to ensure compliance with the

treatment regimen, lest interruption of treatment lead to drug resistance. This may require retention of the individual in a medical patient-holding facility.

Chemoprophylaxis with isoniazid does not play any significant role for tuberculosis control in a temporary refugee settlement with a high incidence of disease. BCG immunization for infants and small children is still recommended to slow hematogenous spread of tubercle bacilli and the resultant miliary and meningeal tuberculosis.

## THE TUBERCULIDS

The term *tuberculid* denotes a symmetrical, generalized exanthem in the skin of a tuberculous patient due to an allergic or hypersensitivity reaction to the tubercle bacillus or one of its constituent parts.

In 1896, Jean Darier reported that patients with tuberculids have the following key findings<sup>67</sup>:

- a positive tuberculin skin test,
- tuberculous involvement of lymph nodes or internal viscera or both,
- absence of tubercle bacilli from skin biopsy and culture, and
- skin lesions that heal on remission of the tuberculous infection.

In the modern era, rapid resolution of the skin lesions invariably follows the institution of antituberculous antibiotic therapy.<sup>67</sup>

Tuberculids usually result from hematogenous spread of mycobacteria in an individual with a moderate or high degree of immunity (ie, the fluctuation in the immunological state of the patient determines the development and the features of the eruption). Histologically, the morphologic changes in the skin have a tuberculous character. Stasis, skin temperature, and the relative blood supply are responsible for the pattern of the disease.

Tuberculids have always been rare, even when tuberculosis was common. Today, they are so infrequent that some authorities question whether they ever existed. However, their appearance after the injection of tuberculin, after BCG prophylaxis, or during the chemotherapy of active tuberculosis remains the best evidence of their existence. Historically, tuberculids encompassed a host of conditions, including erythema induratum, papulonecrotic tuberculid, and lichen scro-

fulosorum.<sup>68</sup> Of 400 cases of tuberculosis with skin manifestations seen in hospitals in Poland during the period 1963 through 1987,<sup>36</sup> 268 (67%) had tuberculosis of the skin, 113 (28%) had pseudo-tuberculids, and only 19 patients (5%) had true tuberculids. Of the population with true tuberculids, 13 (68%) had erythema induratum and 6 (32%) had papulonecrotic tuberculid. No cases of lichen scrofulosorum were seen.<sup>36</sup>

### Erythema Induratum

Erythema induratum (also called Bazin's disease, tuberculom, tuberculosis cutis indurativa, nodose tuberculid) is a chronic condition associated with past or active tuberculosis. The disease is characterized by inflammatory cutaneous and subcutaneous nodules that have a tendency to ulceration and scarring. It typically occurs on the backs of women's legs and is believed to be an allergic or hypersensitivity reaction to the tubercle bacillus. Although in recent decades, many investigators have denied its tuberculous origin and have preferred the name nodular vasculitis, others have vigorously defended it.<sup>68</sup> Therefore, the term erythema induratum should be reserved for those cases in which components of tubercle bacilli are causative.

### Epidemiology

In earlier times when the morbidity of tuberculosis was greater, erythema induratum was frequently seen. Today, however, it is rarely diagnosed, its incidence paralleling the decline of tuberculosis seen in most industrialized countries. The disease tends to favor teenaged or middle-aged women, especially those with plump extremities and minor

peripheral circulatory disturbances such as cold feet, erythrocyanosis, or cutis marmorata.

### *Etiology and Pathogenesis*

The tuberculous cause of erythema induratum was generally accepted until the discovery of the tubercle bacillus and the development of Koch's three postulates for the diagnosis of tuberculosis: (1) isolation, (2) culture, and (3) the transfer of the bacillus. However, tubercle bacilli have only rarely been cultured out of the lesions of erythema induratum. Additionally, the degree of tuberculin sensitivity has been variable and the response to antituberculous therapy inconsistent. Nonetheless, researchers<sup>68</sup> argued strongly in 1989 for a connection between tuberculosis and erythema induratum, after studying a large series of patients who (a) had strong personal or family histories of tuberculosis, (b) were extremely tuberculin sensitive, and (c) had complete resolution of skin lesions after adequate antituberculosis therapy.

The pathogenic premises for erythema induratum and papulonecrotic tuberculid are the same: a tuberculous stimulus is initiated through either (a) hematogenous dissemination of a few tubercle bacilli or (b) dissemination of tubercle antigen into a cooled extremity with disturbed circulation. The ensuing hypersensitivity reaction, if immune-complex mediated, may be the cause of cases that show histological changes consistent with nodular vasculitis; if cell mediated, they may cause the cases that show the classic tuberculous histology. In support of the latter, researchers<sup>69</sup> reporting in 1990 found Leu-1<sup>+</sup>, Leu-3<sup>+</sup>, and HLA-DR<sup>+</sup> mononuclear cells (ie, helper T cells) within the lesions, in the absence of immunoglobulin or C3 deposition—thus suggesting a cell-mediated immune response to tuberculous antigen. Further, they noted one patient in whom satellite nodules of erythema induratum developed in the periphery of a PPD skin test, supporting the concept that the lesions of this tuberculid can indeed be produced by tuberculous antigen alone. Recently, the PCR has been applied to seven patients with erythema induratum. Five of seven patients were positive for *M tuberculosis* complex DNA, providing direct molecular confirmation for this long-debated association of tuberculosis and chronic nodular eruptions of the lower legs.<sup>56</sup>

### *Clinical Features*

The eruption of erythema induratum is usually

symmetric, and typically affects the calves of pubertal or adult women. Rarely are the pretibial areas affected. The lesions arise in small numbers as moderately tender, pea- to cherry-sized lesions, often platelike, firm, well circumscribed, and elastic. After some months, these lesions customarily regress, especially in the summer. Frequently, the larger lesions will turn livid red, liquefy centrally, ulcerate through the skin, and form ulcerations or fistulae. The ulcers tend to be ragged, irregular, and shallow. The oily or crusted ulceration can remain for months, but has little or no associated pain. An exhaustive search for a deep focus of tuberculosis is necessary, especially in countries where tuberculosis is prevalent.<sup>70</sup>

### *Laboratory Features*

Patients with erythema induratum are usually highly sensitive to PPD, with intradermal Mantoux test results strongly positive (ie, 20-mm induration/40-mm erythema, or +++) using the weaker 1:10,000 dilution (1 unit PPD). (Note: subcutaneous injection frequently will give a false-negative reaction, and initial skin testing with more concentrated preparations may result in ulceration.) Bacterial cultures are customarily negative.

### *Histopathology*

Often it is necessary to obtain many biopsies to obtain a definitive diagnosis because there are variations from biopsy to biopsy and within different areas of the same biopsy. In the earliest stages, a distinctive inflammation occurs in the vessel wall (usually a vein, but this disease can also involve the arterioles) with lymphocytic and plasma cell infiltration, and with thickening of the adventitia and media, sometimes with proliferation of the endothelium even to the point of occluding the lumen. A variable perivascular infiltrate is the rule at this stage. A septal panniculitis is present, which may overflow into the fat lobules. In many cases, the infiltrate is tuberculoid throughout<sup>71</sup>; in others, it is more banal. Fat necrosis and a foreign-body giant cell reaction may be present. A lobular granulomatous reaction in the damaged fatty tissue leads to *Wucher* (ie, proliferating) atrophy, wherein normal fat tissue disappears and is replaced by fibroblasts and macrophages.<sup>71,72</sup> Older lesions may progress to caseation and liquefaction. Later, fibrosis occurs. Caseation is always a late feature and may be seen at biopsy in only 50% of cases.<sup>73</sup>



### Course

Erythema induratum may wax and wane for many years, with worsening in the colder months. New nodules may form, while older nodules and ulcerations may show only a slight tendency to heal. Altogether, a good prognosis can be expected if no general disease is found. Careful investigations can reveal, in a large proportion of cases, active tuberculosis in an organ or the indication of past tuberculosis.

### Differential Diagnosis

It is important to distinguish erythema induratum from other conditions affecting the legs. Erythema nodosum predominantly affects the pretibial area and consists of tender, erythematous nodules that do not ulcerate. Other conditions to distinguish include subcutaneous lipogranulomatosis (Rothmann-Makai disease), which has a different histology (nodular vasculitis/cutaneous periarteritis nodosa) that can also be present with tuberculosis; the gummas of tertiary syphilis, which tend to be asymmetrically located; and nodular pernio, which has an even greater seasonal predilection, a more subacute course, and only occurs on the cold-exposed acral regions. In every case, histological examination is useful.

### Treatment

Combination four-agent antituberculous therapy given for 6 months is most important in treating erythema induratum, as one- or two-drug chemotherapy may frequently prove inadequate—especially with the increasing antibiotic resistance to INH and rifampin currently being seen.<sup>59,74</sup> Simple measures to prevent cold exposure to the legs, and general measures to improve the peripheral circulation are believed by some investigators<sup>24,75</sup> to be important. The indiscriminate use of corticosteroids for the treatment of nodular vasculitis, which mimics erythema induratum, may be harmful.

### Papulonecrotic Tuberculid

Papulonecrotic tuberculid (also called tuberculous cutis papulonecrotica) is clinically characterized as a recurrent, chronic, symmetric eruption of necrotizing skin papules that appear in crops. The lesions tend to heal with varioliform scarring, and occur in patients with active or past tuberculosis. The disease may be thought of as a reaction pattern

reflecting a normal protective immune response in a host with tuberculosis.

### Pathogenesis

As a rule, bacteria are difficult to demonstrate in the lesions of papulonecrotic tuberculid by acid-fast staining of tissue sections, culture, or guinea pig inoculation. But occasionally these investigations prove fruitful. A tuberculous etiology is not in question because

- a large number of cases have an associated deep focus of tuberculosis,
- tuberculin skin testing is almost always positive, and
- patients respond rapidly to antituberculous therapy.

However, rather than direct metastatic spread of infectious organisms (as is seen in miliary tuberculosis), some investigators<sup>76</sup> believe the mechanism of spread in papulonecrotic tuberculid is an Arthus reaction followed by a delayed hypersensitivity reaction to mycobacteria in the skin tissue; in other words, a focus of tuberculosis is believed to release mycobacteria into the circulation periodically, where they are opsonized by immunoglobulins and complement-forming circulating immune complexes. These complexes then lodge in the walls of slow-flowing capillaries in the skin. Phagocytosis of opsonized bacilli and the resultant destruction of neutrophils release proteolytic enzymes, which subsequently necrose and destroy the vessels. Presumably, the ensuing mononuclear cell response then destroys the bacilli. Other investigators<sup>77</sup> suggest that the primary insult is either (a) nonspecific or (b) a subacute lymphohistiocytic vasculitis with thrombosis and destruction of small dermal vessels, leading to an infarctive lesion with coagulative necrosis of the overlying dermal tissue.

Most recently, as in erythema induratum, PCR studies have detected *M tuberculosis* complex DNA in lesions of papulonecrotic tuberculid, suggesting the presence of at least partially intact bacilli within the skin.<sup>57,78</sup>

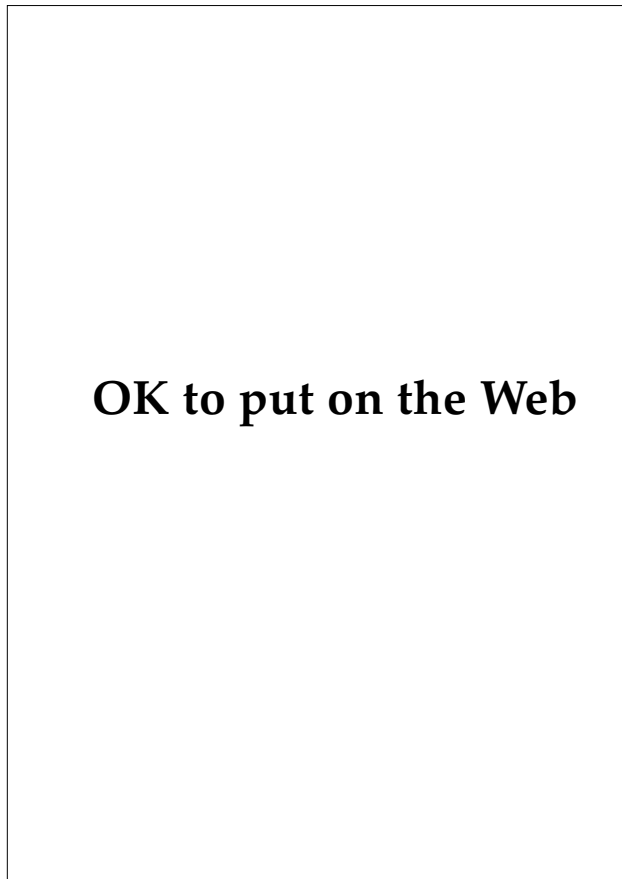
### Epidemiology

Girls and young women seem to be more susceptible than men to this particular condition. Papulonecrotic tuberculid is vanishingly rare in the industrialized world.<sup>79</sup> It occurred in 10 of 222 cases of tuberculosis in South Vietnam and only 9 times in

a 15-year period in the clinic at the Osaka University School of Medicine in Japan.<sup>67</sup> Rarely, it follows BCG vaccination.

### *Clinical Findings*

Typically, symmetrical, loosely disseminated, grouped eruptions of papulonecrotic lesions arise in crops, particularly on the extensor surfaces of the arms and legs, with predilection for the elbows, knees, backs of the hands, and dorsal surfaces of the feet (Figure 15-13), as well as on the lower trunk and buttock region. The genital region is usually spared. The eruption tends to worsen in the winter and fade in the summer months. The lesions begin as pinhead-to-pea-sized papules or small nodules and, over the course of approximately 2 weeks, may become pustular, vesicular, pemphigoid-like, hemorrhagic, and necrotic. After another 3 to 6 weeks, the lesions heal with varioliform scars. Rarely, crateriform



**Fig. 15-13.** Papulonecrotic tuberculid on the legs of an elderly woman with active pulmonary tuberculosis.

ulcerations occur. With recurrent crops, fresh papules and old scars frequently appear side by side. This results in a characteristic polymorphous clinical picture. The total number of lesions in any given patient is highly variable. Itching and burning sensations in the lesions may occasionally be present.

### *Laboratory and Histopathological Findings*

Patients often have an exceedingly heightened sensitivity to tuberculin, with positive intradermal reactions to PPD in dilutions of  $10^{-8}$  to  $10^{-9}$ .

A leukocytoclastic vasculitis is present early on. Later, wedge-shaped necrosis develops, representing a microinfarct. Epithelioid and giant cells are often seen at the periphery of the necrotic zone. However, well-formed granulomas are not identified. Blood vessel involvement is a key feature, being granulomatous, necrotizing (with fibrin present in the walls and lumen), and sometimes obliterative (ie, leading to thrombosis and complete occlusion of the vascular channels).

### *Course*

The disease may last for years or even decades with recurrent crops of ulcerations and consequent varioliform scarring.

### *Differential Diagnosis*

Differentiation from other papulonecrotic processes is necessary. Such entities may include leukocytoclastic vasculitis, pityriasis lichenoides et varioliformis acuta (Mucha-Habermann), lymphomatoid papulosis, acne necrotica, secondary syphilis (rarely), and prurigo simplex–neurotic excoriations. In all cases, biopsy and tuberculin skin testing are extremely helpful.

### *Treatment*

Definitive therapy for tuberculosis with four-drug therapy is indicated.<sup>59,74</sup> Occasionally, this is combined with systemic glucocorticosteroids in moderate doses in exceptionally extensive cases.

### **Lichen Scrofulosorum**

Lichen scrofulosorum (also called tuberculosis cutis lichenoides) is a very rare, but distinctive, lichenoid tuberculid. The disease, which was originally recognized by Ferdinand von Hebra in 1860,<sup>80</sup> occurs predominantly in children and adolescents

who have either primary complex of tuberculosis or a secondary organ tuberculosis.

### **Clinical Features**

In lichen scrofulosorum, the sites of predilection are the sides of the trunk. The exanthem is very discrete and consists of symmetrically arranged groups of tiny papules—often in elongated, oval arrangements parallel to the skin relaxation lines (lines of Langer). The primary lesion is a white, pale yellow-brown, pale red, or skin-colored follicular or perifollicular soft acuminate papule, which may carry a fine scale on its summit. Rarely, a small vesicle may be seen. Occasionally, the small, pointed, agminated papules are more polygonal and resemble lichen ruber acuminatus (a form of lichen planus). On diascopy, the distinct yellow-tone tuberculous character of the infiltrate is easy to miss due to its minimal size. In addition, because the eruption is asymptomatic, it may be overlooked.

### **Course**

After a few months, lichen scrofulosorum eruptions customarily resolve spontaneously without scarring. Recurrences are possible. If central vesicle or pustule formation progresses to an acneform or necrotic picture, then transformation to papulonecrotic tuberculid is assumed to have occurred.

### **Laboratory and Histopathological Features**

The Mantoux skin test for tuberculosis is almost uniformly positive. *M tuberculosis* can occasionally be cultured from the lesions.<sup>81</sup>

Typically in lichen scrofulosorum, tuberculoid granulomas with Langhans'-type giant cells are seen in the papillary dermis surrounding hair follicles and sweat ducts. Nonspecific inflammatory infiltrates may be mixed in with the tuberculous granulomas. Caseation necrosis is generally absent.

### **Differential Diagnosis**

The differential diagnosis includes lichen nitidus, lichen planus, keratosis pilaris, lichenoid secondary syphilis, lichenoid drug eruption, lichenoid sarcoidosis, follicular eczemas, and lichen scrobutus (scurvy). A rare possibility, lichenoid syphiliticus (a small papular, grouped follicular or lichenoid syphilid), occurs during the course of tertiary syphilis.

### **Prognosis**

In patients whose disease is due to tuberculin testing or BCG immunization, the prognosis is excellent. In other patients, the condition is associated with lymph node, osseous, pulmonary, or genitourinary tuberculosis. In patients with normal immunity and with chemotherapy, the prognosis is generally good.

### **Treatment**

The spontaneous resolution of the condition in most patients is no contraindication for treatment because lichen scrofulosorum is a harbinger of internal tuberculosis. Consequently, chemotherapy for the underlying systemic tuberculosis is indicated and usually clears the skin manifestations in a matter of weeks; in contrast, the internal disease may require 6 months or more of therapy.<sup>24,59,75</sup>

## **SUMMARY**

Tuberculosis is an infectious disease caused by the bacterium *Mycobacterium tuberculosis*. Estimated to be present in one third of all humans, tuberculosis is again increasing in incidence, particularly in sub-Saharan Africa, due, in part, to the AIDS epidemic. More alarming has been the progressive increase in multidrug-resistant strains, particularly among AIDS patients. Cases of extrapulmonic tuberculosis—and especially cutaneous tuberculosis—are again being seen in western Europe and in the United States as a result of the immigration of peoples from countries with high prevalence of tuberculosis. Although cutaneous lesions are

present in fewer than 1% of all tuberculosis patients, most cutaneous tuberculosis reflects more serious underlying systemic tuberculosis and can be seen in patients presenting with HIV infection. Therefore, prompt recognition of tuberculosis of the skin is important, as any delay in treatment may contribute to further spread of disease in the community.

Patients with cutaneous tuberculosis present with diverse forms ranging from single, smooth papules to disseminated, eruptive papules; verrucous or vegetative plaques; single or multiple ulcerations; or extensive sinus tracts. The form of the disease

depends on the virulence of the strain, the immune status of the host, the portal of entry, the mode of internal spread, and the adequacy of initial treatment. Acute miliary tuberculosis, particularly in patients who are highly immunosuppressed (eg, those with AIDS), is generally a harbinger of death due to overwhelming infection. Scrofuloderma and lupus vulgaris are much more common and are seen in patients who are less immunosuppressed. Tuberculosis verrucosa cutis is a highly localized form of cutaneous tuberculosis that is seen in patients who are immunocompetent.

The clinical diagnosis of cutaneous tuberculosis is suggested by the presence of apple jelly-colored dermal infiltrates. Definitive diagnosis requires that the organisms be (a) recovered and (b) identified by either bacterial culture or guinea pig inoculation, or by demonstration of the presence of *M tuberculosis* via PCR assays for specific DNA sequences. Compatible histopathology consisting of granulomatous infiltrates with caseation necrosis and the presence of acid-fast bacilli in tissue sections are both suggestive, but are by no means pathognomonic of tuberculosis.

Tuberculosis can be accompanied by a variety of hypersensitivity reactions to the bacillus or one of its constituent parts. These autosensitization reactions are commonly called tuberculids. Recent use of PCR assays for certain *M tuberculosis*-complex DNA segments have suggested that the tuberculid skin lesions contain sizable bacterial fragments of whole organisms.

The treatment of systemic tuberculosis has be-

come much more complicated during the 1990s. Administering four-agent chemotherapy for 6 months is standard initial therapy where the incidence of drug resistance is very low. However, with the rapid rise of multidrug-resistant strains—especially in the HIV-infected population—intensive and innovative chemotherapy protocols based on antibiotic sensitivities need to be custom tailored to each patient. The treatment of cutaneous tuberculosis in most cases is the same as for pulmonary tuberculosis, as lesions in the skin often represent hematogenously or lymphatically dispersed disease from internal foci of infection. Rarely will tuberculosis in the skin be confirmed as strictly a cutaneous disease.

Militarily, tuberculosis is a serious and growing health threat in most areas of the world, especially in Africa, Asia, and the Pacific. With the increased emphasis on peacekeeping forces, disaster relief, and so forth, military personnel are increasingly involved with refugees in distant, third-world areas where tuberculosis (and HIV) may have very high prevalence and incidence. Thus, the likelihood of exposure is greater. When coupled with the possibility that HIV-positive military personnel could be present, whose natural resistance to the organism may be significantly compromised, the stage is set for serious, highly infectious, life-threatening disease. Therefore, intensive tuberculosis screening, aggressive treatment, and comprehensive public-health measures are mandatory for protecting the health of military personnel who are deployed to these areas.

## REFERENCES

1. Blum RN, Polish LB, Tapy JM, Catlin BJ, Cohn DL. Results of screening for tuberculosis in foreign-born persons applying for adjustment of immigration status. *Chest*. Jun 1993;103(6):1670–1674.
2. Advisory Council for the Elimination of Tuberculosis. Prevention and control of tuberculosis among homeless persons. *MMWR*. Apr 17 1992;41(RR5):13–23.
3. Advisory Council for the Elimination of Tuberculosis. Prevention and control of tuberculosis in US communities with at-risk minority populations. *MMWR*. 17 Apr 1992;41(RR5):1–11.
4. Frieden TR, Sterling T, Pablos-Mendez A, Kilburn JO, Cauthen GM, Dooley SW. The emergence of drug-resistant tuberculosis in New York City. *N Engl J Med*. 1993;328(8):521–526.
5. Barnes PF, Barrows SA. Tuberculosis in the 1990s. *Ann Intern Med*. 1993;119(5):400–410.
6. Neville K, Bromberg A, Bromberg R, Bonk S, Nanna BA, Rom WN. The third epidemic—multidrug-resistant tuberculosis. *Chest*. 1994;105:45–48.
7. Centers for Disease Control. Tuberculosis morbidity—United States. *MMWR*. 17 Sep 1992;42(36):696–697, 703–704.

8. Jackson MM. Tuberculosis in infants, children, and adolescents: New dilemmas with an old disease. *Pediatr Nurs.* 1993;19(5):437–442.
9. Centers for Disease Control and Prevention. Estimates of future global tuberculosis morbidity and mortality. *MMWR.* 17 Dec 1993; 42(49):961–964.
10. Iseman MD. Dept of Medicine, Div of Infectious Disease, National Jewish Center for Immunology and Respiratory Medicine, Denver, Colo. Update on tuberculosis. Lecture delivered at Naval Medical Center, San Diego, Calif; 10 October 1990.
11. Iseman MD. Treatment of multidrug-resistant tuberculosis. *N Engl J Med.* 1993;329(11):784–791.
12. Edlin BR, Tokars JI, Grieco MH, et al. An outbreak of multidrug-resistant tuberculosis among hospitalized patients with the acquired immunodeficiency syndrome. *N Engl J Med.* 1992;326(23):1514–1521.
13. DeCock KM, Gnaore E, Adjorilo G, et al. Risk of tuberculosis in patients with HIV-II and HIV-III in Abidjan, Ivory Coast. *Br Med J.* 1991;302(6775):496–499.
14. Elder NC. Extrapulmonary tuberculosis. A review. *Arch Fam Med.* 1992;1:91–98.
15. Chen TM, Lee PY, Perng RP. Extrapulmonary tuberculosis: Experience at Veterans General Hospital–Taipei, 1985 to 1987. *J Formos Med Assoc.* 1991;90(12):1163–1170.
16. Slutsker, Castro KG, Ward JW, Dooley SW Jr. Epidemiology of extrapulmonary tuberculosis among persons with AIDS in the United States. *Clin Infect Dis.* 1993;16(4):513–518.
17. Baldwin ER. Tuberculosis: History and etiology. In: Osler W, McCrae T, Funk EH. *Modern Medicine: Its Theory and Practice.* Vol 1. Philadelphia, Pa: Lea & Febiger; 1925: 267–316.
18. Neisser A. Chronic infectious diseases of the skin. In: Ziemssen vH. *Handbook of Diseases of the Skin.* New York, NY: William Wood & Company; 1885; 271–360.
19. Long E. Tuberculosis in the army. In: Havens WP Jr, ed. *Infectious Diseases.* In: Havens WP Jr, Anderson RS, eds. *Internal Medicine in World War II.* Vol 3. Washington, DC: Medical Department, US Army, Office of The Surgeon General; 1963: 329–366.
20. Guiton CR, Barrett O Jr. Tuberculosis. In: Ognibene AJ, Barrett O Jr, eds. *General Medicine and Infectious Diseases.* In: Ognibene AJ, Barrett O Jr, eds. *Internal Medicine in Vietnam.* Vol 2. Washington, DC: Medical Department, US Army, Office of The Surgeon General, and Center of Military History; 1982: 214–218.
21. Dubos R., Dubos J. *The White Plague: Tuberculosis, Man and Society.* Boston: Little Brown and Company; 1952.
22. Koch R. Die Ätiologie der tuberculose. *Berliner Klinische Wochenschrift.* 1882;29:221–230.
23. Hollander A. Paul Gerson Unna of Hamburg (1850–1929). In: Herzberg JJ, Korting GW, eds. *On the History of German Dermatology.* Berlin, Germany: Grosse Verlag; 1987: 83–92.
24. Braun-Falco O, Plewig G, Wolff HH. *Dermatologie und Venerologie. Dritte neubearbeitete Auflage.* Berlin, Germany: Springer-Verlag; 1984.
25. Piatt AD. A radiographic chest survey of patients from the Dachau concentration camp. *Radiology.* 1946;47:234–238.
26. Barnes PF, Barrows SA. Tuberculosis in the 1990s. *Ann Intern Med.* 1993;119:400–410.
27. Joint IUAT/WHO Study Group. Tuberculosis Control. Geneva, Switzerland: World Health Organization; 1982. World Health Organization Technical Report Series 671.
28. Snider DE. Introduction. *Rev Infect Dis.* 1988;2(Suppl):S336–S338.

29. Gracey DR. Tuberculosis in the world today. *Mayo Clin Proc.* 1988;63:1251–1255.
30. Reider HL, Snider DE, Cauthen GM. Extrapulmonary tuberculosis in the United States. *Am Rev Respir Dis.* 1990;141:347–351.
31. Bickley LK. Acute miliary tuberculosis of the skin in AIDS. *J Am Acad Dermatol.* 1994;30:143–144.
32. Bassiri A, Chan NB, McLeod A, Rossi S, Phillips P. Disseminated cutaneous infection due to *Mycobacterium tuberculosis* in a person with AIDS. *Can Med Assoc J.* 1993 Feb 15;148(4):577–578.
33. Mellado B, Pedrol E, Casademont J, Grau JM. A tuberculous subcutaneous abscess as the form of presentation of the acquired immunodeficiency syndrome. (In Spanish.) *Rev Clin Esp.* 1993 Feb;192(2):95–96.
34. Berger TG. Department of Dermatology, University of California, San Francisco, Calif. Cutaneous manifestations of AIDS. Lecture delivered at Naval Medical Center, San Diego, Calif; 5 November 1993.
35. Sharma VK, Kumar B, Randotra BD, Kaur S. Cutaneous inoculation tuberculosis in laboratory personnel. *Int J Dermatol.* 1990;29:293–294.
36. Starzycki Z. Gruzlica skory w materiale chorych leczonych w klinice dermatologicznej am w Krakowie w Latach 1963–1987. I. Analiza epidemiologiczna. (In Polish.) Cutaneous tuberculosis treated at the dermatologic clinic, medical academy, in Cracow 1963–1987. Part 1. Epidemiological analysis. *Przeegl Dermatol.* 1990;77:34–39.
37. Bouali O, Ould-Amrouche N, Tchoua S. Apropos of 45 cases of cutaneous tuberculosis in Tlmcen (western Algeria). *Bull Soc Pathol Exot Fialiales.* 1989;82:341–350.
38. Brennan PJ. Structure of mycobacteria: Recent developments in defining cell wall carbohydrates and proteins. *Rev Infect Dis.* 1988;2(Suppl):S420–S428.
39. Sehgal VN, Jain MK, Srivastava G. Changing pattern of cutaneous tuberculosis: A prospective study. *Int J Dermatol.* 1989;28:231–236.
40. Sehgal VN, Srivastava G, Khurana VK. An appraisal of epidemiologic, clinical-bacteriologic, histopathologic, and immunologic parameters in cutaneous tuberculosis. *Int J Dermatol.* 1987;26:521–526.
41. Saxe N. Mycobacterial skin infections. *J Cutan Pathol.* 1985;12:300–312.
42. Santa Cruz DJ, Strayer DS. The histologic spectrum of the cutaneous mycobacterioses. *Human Pathol.* 1982;13(5):485–495.
43. Sehgal V, Wagh S. Cutaneous tuberculosis: Current concepts. *Int J Dermatol.* 1990;29:237–252.
44. Goette DK, Jacobson KW, Doty RD. Primary inoculation tuberculosis of the skin. *Arch Dermatol.* 1978;114:567–569.
45. Kramer F, Sasse SA, Simms JC, Leedom JM. Primary cutaneous tuberculosis after a needlestick injury from a patient with AIDS and undiagnosed tuberculosis. *Ann Int Med.* 1993;119:594–595.
46. Rohatgi PK, Palazzolo JV, Saini NB. Acute miliary tuberculosis of the skin in acquired immunodeficiency syndrome. *J Am Acad Dermatol.* 1992;26:356–359.
47. Prendiville J, Kaufman D, Esterly NB. Psoriasiform plaque on the buttock. *Arch Dermatol.* 1989;126:113–118.
48. Steidl M, Neubent U, Volkenant M, Chatelain R, Deglitz K. Lupus vulgaris confirmed by polymerase-chain reaction. *Br J Dermatol.* 1993;129:314–318.
49. Wolff K, Tappeiner G. Mycobacterial diseases: Tuberculosis and atypical mycobacterial infections. In: Fitzpatrick TB, Eisen AS, Wolff K, Freedberg IM, Austen KF, eds. *Dermatology in General Medicine.* New York: McGraw-Hill; 1987: 2161.

50. Kakakhel KU, Fritsch P. Cutaneous tuberculosis. *Int J Dermatol*. 1989;28:335–362.
51. Petit A, Maslo C, Herschkovitch D, Perrin P, Janier M, Civatte J. Multiple subcutaneous abscesses due to mycobacterium tuberculosis in an immunocompetent host. *Dermatologica*. 1989;179:207–210.
52. Lantos G, Fisher BK, Contreras M. Tuberculous ulcer of the skin. *J Am Acad Dermatol*. 1988;19:1067–1072.
53. Izumi AK, Matsunaga J. BCG vaccine-induced lupus vulgaris. *Arch Dermatol*. 1982;118:171–172.
54. Serfling U, Penneys NS, Leonardi CL. Identification of *Mycobacterium tuberculosis* DNA in a case of lupus vulgaris. *J Am Acad Dermatol*. 1993;28:318–322.
55. Taniguchi S, Chanoik M, Hamada T. Scrofuloderma: The DNA analysis of mycobacteria by the polymerase chain reaction. *Arch Dermatol*. 1993;129(12):1618–1619.
56. Penneys NS, Leonardi CL, Cook S, et al. Identification of *Mycobacterium tuberculosis* DNA in five different types of cutaneous lesions by the polymerase chain reaction. *Arch Dermatol*. 1993;129(12):1594–1598.
57. Deglitz K, Steidl M, Thomas P, Plewig G, Volkenant M. Aetiology of tuberculids. *Lancet*. 1993;341:239–240.
58. Deglitz K, Messer G, Schirren H, Classen V, Meurer M. Successful treatment of erythema induratum of Bazin following rapid detection of mycobacterial DNA by polymerase chain reaction. *Arch Dermatol*. 1993;129(12):1619–1620.
59. Grosset JH. Present status of chemotherapy for tuberculosis. *Rev Infect Dis*. 1989;2(Suppl):S347–S351.
60. Neville K, Bromberg A, Bromberg R, Bonk S, Hanna BA, Rom WN. The third epidemic—multidrug resistant tuberculosis. *Chest*. 1994;105:45–48.
61. Centers for Disease Control. Nosocomial transmissions of multidrug-resistant tuberculosis among HIV-infected persons—Florida and New York, 1988–1991. *MMWR*. 1991;40:585–591.
62. Iseman MD. Treatment of multidrug-resistant tuberculosis. *N Engl J Med*. 1993;329:784–791.
63. Ellner JJ, Wallis RS. Immunologic aspects of mycobacterial infections. *Rev Infect Dis*. 1989;2(Suppl):S455–S459.
64. Stack RJ, Bickley LK, Coppel IG. Miliary tuberculosis presenting as skin lesions in a patient with acquired immunodeficiency syndrome. *J Am Acad Dermatol*. 1990;23:1031–1035.
65. Styblo K. Overview and epidemiologic assessment of the current global tuberculosis situation with an emphasis on control in developing countries. *Rev Infect Dis*. 1989;2(Suppl):S339–S346.
66. Rieder HL, Snider DE, Toole MJ, et al. Tuberculosis control in refugee settlements. *Tubercle*. 1989;70:127–134.
67. Held JL, Kohn SR, Silvers DN, Grossman ME. Papulonecrotic tuberculid. *NY State J Med*. 1988;88:499–501.
68. Rademaker M, Lowe DG, Munro DD. Erythema induratum (Bazin's disease). *J Am Acad Dermatol*. 1989;21:740–745.
69. Kuramoto Y, Aiba S, Tagami E. Erythema induratum of Bazin as a type of tuberculid. *J Am Acad Dermatol*. 1990;22:612–616.
70. De Silva HJ, Goonetilleke AK, De Silva NR, Amarasekera LR, Jayawickrama US. Erythema induratum (of Bazin) in a patient with endometrial tuberculosis. *Postgrad Med J*. 1988;64:242–244.
71. Gans O, Steigleder G. *Histologie Der Hautkrankheiten, Erster Band*. Berlin: Springer-Verlag; 1955.
72. Pinkus H, Mehregan AH. *A Guide to Dermatohistopathology*. 2nd ed. New York, NY: Appleton-Century Crofts; 1976: 235.

73. Milligan A, Chen K, Graham-Brown RAC. Two tuberculides in one patient—a case report of papulonecrotic tuberculide and erythema induratum occurring together. *Clin Exp Dermatol*. 1990;15:21–23.
74. Hong Kong Chest Service/British Medical Research Council. Five-year follow-up of a controlled trial of five 6-month regimens of chemotherapy for pulmonary tuberculosis. *Am Rev Res Dis*. 1987;136:1339–1342.
75. Korting GW. *Dermatologie in Praxis und Klinik, Band II Spezielle Dermatologie*. Stuttgart, Germany: George Thieme Verlag; 1980.
76. Morrison JG, Fourie ED. The papulonecrotic tuberculide: From Arthus reaction to lupus vulgaris. *Br J Dermatol*. 1974;91:263–270.
77. Wilson-Jones E, Winkelmann RK. Papulonecrotic tuberculid: A neglected disease in western countries. *J Am Acad Dermatol*. 1986;14:815–826.
78. Victor T, Jordan HF, Van Niekerk DJ, Louw M, Jordan A, Van Helden PD. Papulonecrotic tuberculid. Identification of *Mycobacterium tuberculosis* DNA by polymerase chain reaction. *Am J Dermatopathol*. 1992;14:491–495.
79. Sloan JB, Medenica M. Papulonecrotic tuberculid in a 9-year-old American girl: Case report and review of the literature. *Ped Dermatol*. 1990;7:191–195.
80. von Hebra F. *Handbuch der speciellen Pathologie und Therapie, Dritte Band, Acute Exantheme und Hautkrankheiten*. Erlangen, Germany: Verlag von Ferdinand Enke; 1860: 311–314.
81. Rongioletti F, Clavarino M, Gortan C, Rebora A. Papules on the lower limbs of a woman with cervical lymphadenopathy. *Arch Dermatol*. 1988;124:1425–1426.



# Chapter 16

## ATYPICAL MYCOBACTERIAL DISEASES

JAMES H. KERR, M.D.\* AND TERRY L. BARRETT, M.D.†

---

### INTRODUCTION

### HISTORY

General History

Military History

### EPIDEMIOLOGY

Incidence

Sources of Organisms

Distribution

### CLASSIFICATION SYSTEMS

### HISTOPATHOLOGY

### MYCOBACTERIOLOGY

### ATYPICAL MYCOBACTERIAL INFECTIONS

*Mycobacterium marinum* Disease (Group I, Photochromogen)

*Mycobacterium kansasii* Disease (Group I, Photochromogen)

*Mycobacterium szulgai* Disease (Group I, Photochromogen/  
Scotochromogen)

*Mycobacterium scrofulaceum* Disease (Group II, Scotochromogen)

*Mycobacterium xenopi* Disease (Group II, Scotochromogen)

*Mycobacterium gordonae* Disease (Group II, Scotochromogen)

*Mycobacterium avium-intracellulare* Complex Disease (Group III,  
Nonchromogen)

*Mycobacterium ulcerans* Disease (Group III, Nonchromogen)

*Mycobacterium haemophilum* Disease (Group III, Nonchromogen)

*Mycobacterium malmöense* Disease (Group III, Nonchromogen)

*Mycobacterium fortuitum-chelonae* Complex Disease (Group IV, Rapid  
Growers)

*Mycobacterium smegmatis* Disease (Group IV, Rapid Growers)

### ATYPICAL MYCOBACTERIAL INFECTIONS AND ACQUIRED IMMUNODEFICIENCY SYNDROME

### SUMMARY

\*Captain, Medical Corps, U.S. Navy; Chairman, Dermatology Department, Naval Hospital, San Diego, California 92134-5000

†Captain, Medical Corps, U.S. Navy; Pathology and Dermatopathology Consultant, Naval Hospital, San Diego, California 92134-5000

## INTRODUCTION

The group of acid-fast mycobacteria that do not cause tuberculosis or leprosy are a diverse collection of more than 30 facultative pathogens and saprophytes; they have been called by many names since first being recognized almost 70 years ago. Due to the medical importance of tuberculosis at the turn of the 20th century, designation as nontuberculous mycobacteria was and still is a common classification for this group. However, this designation was not altogether accurate because the leprosy bacillus should have been included in such a group of nontuberculous mycobacteria; nonetheless its exclusion is understandable, as it was not a culturable organism. Pseudotubercle bacilli, unusual mycobacteria, chromogenic or nonpathogenic acid-fast bacilli, saprophytic mycobacteria, and mycobacteria other than tuberculosis (MOTT) were

some of the other terms used for this group of organisms. In 1954, Timpe and Runyon<sup>1</sup> called these organisms "atypical acid-fast bacteria" in their first attempt to classify them. In a 1959 refinement of this classification system, Runyon<sup>2</sup> referred to them as "anonymous mycobacteria." Thus, in reports about this group of organisms, any of these terms have been used to refer to what is now almost universally recognized as the atypical mycobacteria. This group includes both opportunistic pathogens as well as nonpathogenic, saprophytic, acid-fast mycobacteria; however, if the past is any indication of the future, some of the mycobacteria presently classified as nonpathogens will, under conducive host or environmental conditions, become facultative pathogens and be identified as such.

## HISTORY

### General History

The causative organism of leprosy was described in 1874 by Hansen,<sup>3</sup> from whose name the term Hansen's disease is derived; however, it was the identification of the tubercle bacillus as the cause of tuberculosis by Koch in 1882<sup>4</sup> that stole the mycobacterial disease spotlight for the next 50 years (Exhibit 16-1). A great effort was poured into research on epidemiology, diagnosis, and treatment of tuberculosis, then as now a significant worldwide medical menace. However, in many medical investigations of tuberculous disease, there began to emerge evidence for the existence of other "nontuberculous" mycobacterial infections. Probably the earliest hint of atypical mycobacterial infection was in 1897, with the description by Sir Albert Cook of slowly progressive ulcers of skin and underlying soft tissue in patients in Uganda.<sup>5</sup> More than 50 years later, in the Buruli District of Uganda, reports of multiple cases of *Mycobacterium ulcerans* infection would give it one of its eponyms, Buruli ulcer.

In the early 1900s, there were reports of rapidly growing, acid-fast organisms (as opposed to slow-growing tubercle bacilli) that were isolated from purulent sputum of patients with respiratory-tract disease.<sup>6</sup> Some clinicians called these organisms

pseudotubercle bacilli, but their attempts to culture them were unsuccessful. Then, in 1904, came the report of a chronic injection-site abscess caused by an acid-fast bacillus. This organism was cultured and grew rapidly, in less than 1 week, and probably was what is presently classified as the group of rapid-growing atypical mycobacteria of the *Mycobacterium fortuitum-chelonae* complex. In 1926, *Mycobacterium marinum* was described and named as the cause of disease, not in humans, but in salt-water fish in the Philadelphia aquarium.<sup>7</sup> Years later, this same organism under a new name, *Mycobacterium balnei*, would be rediscovered as a cause of a human skin disease associated with swimming pools.

During the 1930s, further evidence for the existence of a group of "atypical" mycobacteria began to accumulate. In 1931, the Ryan strain, probably *M fortuitum*, was isolated from a pleural empyema. The organism was used to prepare a skin-test reagent that was reactive in that patient, who had not reacted to the usual *M tuberculosis* tuberculin of that day. Clinical laboratories began to isolate yellowish, pigmented, acid-fast organisms that were completely unlike the nonpigmented cultures of *M tuberculosis* or *M bovis*. In addition, inoculation of

## EXHIBIT 16-1

## MILESTONES IN THE HISTORY OF MYCOBACTERIAL DISEASE

Date	Event
1874	Leprosy bacillus is described by Hansen
1882	Tubercle bacillus is identified by Koch
1926	<i>Mycobacterium marinum</i> is identified by Aronson in Philadelphia aquarium fish
1938	<i>M fortuitum</i> is isolated and named by da Costa Cruz
1943	<i>M avium-intracellulare</i> is recovered from silicotuberculosis
1948	<i>M ulcerans</i> is reported isolated from skin ulcers in Australia
1951	<i>M balnei</i> (now called <i>M marinum</i> ) is isolated from human skin lesions from swimming pool trauma
1953	<i>M kansasii</i> ("yellow bacillus") is isolated
1956	<i>M scrofulaceum</i> , so named because it resembled scrofula lymphadenitis in children
1959	Runyon Classification into Rapid Growers and Slow Growers (Groups I-IV) is established
1964	<i>M buruli</i> (now called <i>M ulcerans</i> ) is isolated in Buruli District of Uganda
1965	<i>M kansasii</i> is first reported as skin infection
1965	<i>M fortuitum</i> is reported to produce abscesses
1972	<i>M szulgai</i> is first isolated and described
1977	<i>M malmöense</i> is reported as new species
1978	<i>M haemophilum</i> is described and named
1984	First report of skin infection with <i>M gordonae</i>
1984	<i>M ulcerans</i> is discovered in koalas in Australia
1990	<i>M malmöense</i> skin infection is reported

the atypical organisms into guinea pigs produced only local, self-healing lesions instead of the usual generalized involvement following *M tuberculosis* inoculations of guinea pigs. The "Mx" (mycobacteria x) strain was isolated from sputum from a lung abscess, and the "IP" strain originated from a case of chronic pneumonitis. Some variants of the "IP" strain produced pigmented colonies when exposed to light—again, completely unlike *M tuberculosis* colonies. A review of the literature published in 1935 revealed more than a dozen instances in which slow-growing, pigmented strains of acid-fast bacilli were recovered from humans without associated disease.<sup>8</sup> Then in 1938, da Costa Cruz isolated, described, and named the rapid-growing, acid-fast bacillus *M fortuitum*.<sup>9</sup> In that same year, there were reports of several cases of superficial abscesses from which rapid-growing, pigmented, acid-fast bacilli were isolated. From 1939 on, reports by Hellerström of facial granulomas, which followed abrasions in a swimming pool, implicated *M tuberculosis* as the

cause of disease.<sup>6</sup> This was undoubtedly true in some of these cases, but in others the causative organism was probably *M marinum*. During the 1940s, manifestations of clinical disease were directly linked to atypical mycobacterial infections. In 1943, an acid-fast bacillus, later shown to be *M avium-intracellulare*, was recovered from a patient with silicotuberculosis. During that same year, a review of multiple pulmonary cases of normal or clinically nontuberculous patients revealed some positive *M tuberculosis* cultures and some "non-pathogenic" acid-fast bacilli. It was pointed out that "nonpathogenicity for animals did not preclude the ability to produce disease in the source patient."<sup>6(p109)</sup> In 1948, a new mycobacterial disease in humans was reported from the Bairnsdale district of Australia, with the first isolation and identification of *M ulcerans*.<sup>10</sup> Multiple reports of this infection in the same area gave it the eponym Bairnsdale ulcers. More than a decade later, what would eventually prove to be the same organism

was isolated from many patients in the Buruli District of Uganda with the disease they called Buruli ulcer.

In 1951, self-limited skin lesions thought to be tuberculous developed in approximately 80 Swedish patients, from whom was isolated acid-fast bacilli that grew at 31°C and produced yellow pigment only after exposure to bright light. These culture results made tuberculosis an impossibility, because *M tuberculosis* grows at 37°C and produces no pigment—with or without exposure to light. The same acid-fast organism was isolated from the walls of a swimming pool used in common by several infected patients. This apparently newly isolated species of mycobacterium was named *M balnei* (from the Latin, meaning “of the bath”). To remove all doubt that indeed a new mycobacterial disease had been discovered, Linell and Norden inoculated themselves with the organism and produced identical skin lesions from which the same mycobacteria were then isolated. Later in 1959, Bojalil showed that *M balnei* was the same species as *M marinum*, which had been isolated by Aronson in 1926 from fish in the Philadelphia aquarium. Thus, the earlier name took precedence and this organism officially became *M marinum*.<sup>11</sup> In 1953, two cases of mycobacterial disease were described that were caused by the “yellow bacillus,” later identified as *Mkansasii*.<sup>12</sup> Three years later, a nontuberculous, acid-fast organism that produced cervical lymphadenitis in children was named *M scrofulaceum*, because it so resembled tuberculous scrofula.<sup>13</sup> A preliminary report in 1954 on the known facts about nontuberculous pulmonary disease published the Timpe-Runyon classification system for these nontuberculous organisms, which were termed “atypical” acid-fast bacteria. This system was limited to grouping these organisms into Groups I through III, based on colony color and texture, and on virulence in mice and absence of virulence in guinea pigs. Timpe and Runyon warned against “discard of an acid-fast organism isolated from a patient with pulmonary disease because it fails to fit the cultural or virulence pattern of *M tuberculosis*.”<sup>1(p208)</sup>

Then in 1959 came Runyon’s landmark refined classification system of anonymous mycobacteria based on both colony pigmentation and growth rate.<sup>2</sup> This was a very detailed, in-depth report on the epidemiology, culture characteristics varying with temperature and light, animal pathogenicity, and drug resistance of more than 400 patient strains of atypical mycobacteria from 93 laboratories in 30 states. It provided incontrovertible evidence refuting the dogma that an acid-fast bacillus, unable to

produce disease in guinea pigs, was ipso facto a saprophyte and not a pathogen. For, only the year before, it had been suggested that “atypical variants” that produce lymphadenitis almost exclusively in children were actually “mutants of *M tuberculosis*” that had become predominant because of their higher drug resistance.<sup>14</sup>

Into the 1960s, widespread knowledge and acceptance of the identification of the various atypical mycobacteria were generally lacking. In a 1963 report of 12 orthopedic cases that grew out mycobacteria, the organisms were identified as “a mycobacterium, other than *M tuberculosis*, *M ulcerans*, *M balnei*, or *M leprae*.”<sup>15(p327)</sup> In other words, these infections were identified as *not* due to tuberculosis, Buruli ulcer, swimming-pool granuloma, or leprosy. The cultures in these cases grew at 22°C to 24°C, 30°C, and/or 37°C, with most colonies producing smooth, cream-colored (or, in a few cases, yellow or orange) growth. Unfortunately, the time required for colony growth was not recorded; however, the nonpigmented ones were probably rapid growers in the *M fortuitum* complex, and the orange colonies, which grew at all three temperatures, may have been *Mkansasii* from Group I photochromogens or *M szulgai*—a temperature-dependent photochromogen/scotochromogen not isolated until 1972. With all of the culture characteristics, excluding rate of growth, and without more modern metabolism, seroagglutination, and chromatography methods, it is impossible to classify these atypical mycobacterial infections precisely. Use of Runyon’s classification system, however crude it might appear by current standards, was and still is helpful in keying out general groups of organisms. Even though the yellow bacillus, *Mkansasii*, had been isolated from autopsy material more than 10 years previously, it was not until 1965 that the first skin infection caused by *Mkansasii* was reported.<sup>16</sup> Also in 1965, *M xenopi*, which has been commonly recovered from hospital hot-water storage tanks, was recognized first as a pulmonary pathogen. In that same year, subcutaneous abscesses due to *M fortuitum* were reviewed. Many reports of *M fortuitum* infections of skin, soft tissue, lung, and even the cornea were documented during this decade.<sup>17</sup>

The 1970s produced reports of pulmonary infections by *M simiae* and skin infections by two new atypical mycobacteria—*M szulgai* in 1972 and *M haemophilum* in 1978. In addition, work went forward on serotyping the various groups of atypical mycobacteria after more widespread use of differential culture techniques began to demonstrate the

more frequent occurrence of these acid-fast organisms in the production of disease. Additional biochemical tests were also developed to better differentiate the various species. Some species with differing names were found to be the same organism, while others were split into separate and distinct species. The acceptance of the atypical mycobacteria as separate and distinct species of mycobacteria became more widespread; the diagnosis of tuberculosis was restricted to slowly growing mycobacteria that (a) grew at 37°C, (b) did not produce yellow or orange colonies, (c) did give positive results for niacin and nitrate reduction, and (d) were virulent in guinea pigs.

In 1983, *M asiaticum*, which had been included among *M simiae* isolates from primates almost 20 years previously, was implicated as the cause of pulmonary disease; however, this particular newly identified organism did not, and has not been shown to, disseminate to the skin.<sup>18,19</sup> In 1984, *M gordonae*, a commonly encountered saprophyte in the laboratory, which has been referred to as the “tap-water bacillus” or *M aquae* in the past, was isolated as the cause of infection in the hand.<sup>13</sup> That same year, *M ulcerans*, thought only to infect humans, was isolated from koalas in Australia, thus stimulating speculation as to the epidemiology and transmissibility of this organism between humans and potential animal reservoirs.<sup>20</sup> Although *M malmöense* had been identified in 1977 in Malmö, Sweden, it had been associated solely with pulmonary disease and cervical adenitis until 1990, when it was isolated as the cause of skin nodules in a patient with chronic myeloid leukemia.<sup>21</sup> Prior to development of these skin nodules, this patient had developed a supraclavicular node that on biopsy was diagnosed as tuberculosis but was unresponsive to isoniazid, rifampicin, and pyrazinamide.

During the decade of the 1980s, increasing numbers of cases of atypical mycobacterial infections in immunocompromised patients, especially those with acquired immunodeficiency syndrome (AIDS), were being reported. Many of these infections occurred in organs that had not previously been reported as being involved with atypical mycobacterial infections. Thus, it had become apparent that clinicians and researchers should maintain a high index of suspicion for unusual presentations of the atypical organisms, especially in immunocompromised patients. Nevertheless, diagnosis is accomplished through better and more sophisticated diagnostic classification tests such as thin-layer chromatography, plasmid profiling, enzyme-linked immunosor-

bent assay (ELISA), high-pressure liquid chromatography, radiometric culture system, and species-specific deoxyribonucleic acid (DNA) probes.<sup>22-24</sup>

### Military History

There is no record of a single battle or military campaign whose outcome was determined by the presence of atypical mycobacterial infections. This is most likely due to their low overall clinical prevalence (< 2 / 100,000 in the United States) and to their lack of human-to-human or animal-to-human communicability.<sup>22</sup> Human infection occurs in an opportunistic fashion, with repeated or prolonged exposure of traumatized or compromised skin, soft tissue, or airway to adequate amounts of pathogenic, or in some cases, even saprophytic atypical mycobacteria. Water and soil appear to be their most common and most likely sources.<sup>22</sup> Therefore, on the battlefield or on the sea, wounded combatants may have a ready source of opportunistic infection if open wounds are allowed to come into repeated or prolonged contact with the environment. In 1918, chronic pustular skin lesions containing relatively rapidly growing, acid-fast bacilli were noted in a wounded English soldier who was being transported by ship. The ship was then sunk in the North Sea, which exposed his wounds directly to seawater.<sup>6</sup> The soldier's subsequent skin lesions were most likely caused by infection with organisms from the *M fortuitum-chelonae* complex or possibly *M marinum*.

Almost certainly there were some cases of atypical mycobacterial infections during World War II, because tropical areas are endemic for many of the atypical organisms and wounded soldiers and sailors were undoubtedly directly exposed—sometimes for prolonged periods—to soil, water, or lush vegetation. However, the seriousness of their wounds, or the occurrence of more virulent infections in these wounds, may have displaced concern over relatively benign-appearing skin lesions, a chronic cough, or indolent soft-tissue infections such as might have been seen with atypical mycobacterial infections. In fact, if the casualty did survive his other injuries, many of the skin, pulmonary, or soft-tissue lesions of atypical mycobacterial infections would have healed spontaneously, after several months or even years, despite the lack of standard wound care. Some of the atypical mycobacteria might well have responded to timely debridement, surgical excision, incision and drainage or, in the years following World War II, to the administration

of antituberculous drugs or antibiotics as they became available. Mortality from these organisms was apparently small or was attributed to other types of infections, because during the 1940s, atypical mycobacteria were only beginning to be suspected as agents of infection. Usually, pulmonary disease and soft-tissue and lymphatic involvement that produced acid-fast bacilli were attributed to tuberculosis and treated as such. These treatment failures were then considered to be unresponsive or resistant cases of tuberculosis, and, without the special culture techniques for demonstrating atypical mycobacteria, their involvement went undetected. It was not until after World War II, in 1948, that *M ulcerans* was isolated and identified as the acid-fast bacillus that directly causes progressive ulcerative skin lesions (ie, Bairnsdale ulcers).

With the beginning of the Korean conflict came the first reports of the isolation of *M balnei* (the same organism as *M marinum*, which had been described earlier in fish) as the cause of the disease (in several patients in Sweden) that would later become known as swimming-pool granuloma. Little more was known about atypical mycobacterial infections in humans, except for suspicions that they might be secondary pathogens in chronic pulmonary disease. Soon after the Korean conflict, Runyon's detailed study and classification system for these organisms was published in 1959.<sup>2</sup> Fortunately, soldiers kept their exposure to water to a minimum during the harsh Korean winter, thereby decreasing the chances that casualties with even minor battle wounds would be contaminated by organisms such as *M marinum* or *M kansasii*. Certainly there must have been some soft-tissue infections with the atypical mycobacteria secondary to contamination associated with shrapnel and bullet wounds; however, as in World War II, surgical debridement, excision, incision and drainage, or amputation would have been curative of many atypical mycobacterial infections. Being far from the tropics, Korea was not an endemic area for *M ulcerans*, the cause of Buruli ulcer. Pulmonary infections with *M kansasii* or *M avium-intracellulare*, found to be positive for acid-fast bacilli, would have been treated as tuberculosis, with some success using antituberculous drugs. Most likely, these infections were recognized as somewhat resistant strains of tuberculosis that, when cultured with the usual mycobacterial techniques, unlike *M tuberculosis*, produced strangely pigmented yellowish colonies. For, in this war, as in prior wars, knowledge

about atypical mycobacteria as possible pathogens was relatively uncommon throughout the medical community.

Although atypical mycobacterial infections per se are not mentioned in Lieutenant Colonel Alfred M. Allen's landmark volume on dermatology in the U.S. Army, *Skin Diseases in Vietnam, 1965–72*,<sup>25</sup> several reports of that era record infections with these organisms. In a report published in 1963,<sup>15</sup> 12 orthopedic cases were discussed, with atypical mycobacterial infections of tendon sheaths in one half of the patients and involvement of joints in the other half. Three of the tendon infections followed laceration or hydrocortisone injections, and three of the six joint infections followed repeated injections of hydrocortisone into the affected joint. The exact atypical mycobacteria species in these cases were not identified, but *M ulcerans* and *M marinum* were ruled out by bacteriological studies; thus, given the culture growth characteristics, the offending organisms were most likely *M fortuitum*, *M kansasii*, or *M szulgai*.

One report<sup>17</sup> recounted a *M fortuitum* infection following multiple gunshot wounds received by a 20-year-old army infantryman while in Vietnam in 1968. Interestingly, this organism was recovered from an abscess that developed proximally in the left thigh some 3 months after the initial wound and fracture of the left lower leg. Initial therapy with isoniazid and pyrazinamide for 2 months had shown no effect; therefore, extensive debridement, sequestrectomy of the involved bone, and split-thickness skin grafting finally produced sustained healing of the area after 4 more months. Another report<sup>26</sup> described *M fortuitum* infections in three severely wounded Vietnam veterans with deep soft-tissue abscesses; all eventually healed following extensive debridement, incision and drainage, and local wound care. These three cases were the only ones found among the large number of injured patients returning from Vietnam and treated at Valley Forge (Pennsylvania) General Hospital. The low number of cases may have been attributed to the aeromedical evacuation system that was used during the Vietnam conflict, which rapidly removed the accessible wounded from the battlefield, thus preventing continued contact of open wounds with water or soil contaminated with atypical mycobacteria. Rapid removal of patients with extensive open wounds to relatively sophisticated treatment facilities with good laboratory capabilities is essential in minimizing delays in diagnosis and effective treatment of atypical mycobacterial infections.

## EPIDEMIOLOGY

Atypical mycobacterial diseases are not communicable: human-to-human transmission has rarely, if ever, been known to occur. Instead, these diseases occur when an individual made susceptible by trauma, a deep wound, a surgical procedure—with or without compromise of the immune system—comes in sufficient contact with these saprophytic organisms. Atypical mycobacteria can be found almost worldwide in soil, water, vegetation, and indigenous animals. Therefore, the incidence of disease caused by these organisms is relatively low, even rare, unless the scales are tipped in their favor due to exposure of susceptible tissue to these organisms in their endemic locales.

Due to their similar clinical, etiologic, and antigenic characteristics, two groups of atypical mycobacteria are considered together as “complexes.” For example, *M intracellulare* and *M avium* produce almost identical human pathogenicity and are found together endemically. They differ in their ability to produce disease in animals and can be distinguished from one another by sophisticated laboratory techniques; however, their human clinical course, histology, and response to treatment are essentially identical. They are grouped together as the *M avium–intracellulare* complex. *M scrofulaceum* is sometimes included in the *M avium–intracellulare* complex because it also produces cervical adenitis—one of the clinical signs seen in both children and adults with *M avium–intracellulare* complex infection.

Although *M fortuitum* and *M chelonae* each contain several separate and identifiable subgroups, the human diseases that they produce have such similar clinical courses and culture characteristics that these organisms, too, are usually grouped together as the *M fortuitum–chelonae* complex.

Because atypical mycobacteria are ubiquitous, they were not readily associated with clinical disease. However, under circumstances that are precisely right for them and wrong for the host, these saprophytes take their place as true pathogens in the production of human disease.

### Incidence

The true incidence of atypical mycobacterial disease is difficult to ascertain: because they are not communicable diseases, they are not reportable in the United States. However, several laboratory surveys of pathogenic mycobacteria have been reported

(Table 16-1). One such survey, published in 1982 by the Centers for Disease Control in Atlanta, Georgia, suggests that 65.2% of the total mycobacterial pathogens isolated were *M tuberculosis* and 34.8% were atypical mycobacteria. Of the atypical mycobacterial isolates, about 60% were *M avium–intracellulare* complex; 20% *M fortuitum–chelonae* complex; 10% *M kansasii*; with *M scrofulaceum*, *M marinum*, *M xenopi*, *M szulgai*, and *M malmöense* comprising the remaining 10%.<sup>27</sup> In 1990, the overall prevalence of atypical mycobacterial infections was estimated at about 2/100,000 population in the United States, with over one half the cases due to *M avium–intracellulare* complex, and the largest population of patients being white males who are not infected with AIDS.<sup>22</sup> If *M avium–intracellulare* complex infections in AIDS patients were included, the percentage of infection in white males would be even higher. Even though the *M avium–intracellulare* complex is the most prevalent atypical mycobacterium in the United States and is also common in western Australia and Japan, it is rare in Europe: the predominant atypical organisms there are *M kansasii* and *M xenopi*.

### Sources of Organisms

Mycobacteria exist and probably multiply in a wide variety of natural sources such as soil, water,

**TABLE 16-1**  
**PATHOGENIC MYCOBACTERIA ISOLATES**  
**IN THE UNITED STATES (1980)**

Table 16-1 is not shown because the copyright permission granted to the Borden Institute, TMM, does not allow the Borden Institute to grant permission to other users and/or does not include usage in electronic media. The current user must apply to the publisher named in the figure legend for permission to use this illustration in any type of publication media.

Adapted with permission from Good RC, Snider, DE. From the Centers for Disease Control. Isolation of nontuberculous mycobacteria in the United States, 1980. *J Infect Dis.* 1982;146(6):830.

and wild and domestic animals and birds; therefore, it seems reasonable to believe that most human disease comes from the environment.<sup>6</sup> Even potable water supplies harbor some of these organisms: *M gordonae* (the tap-water bacillus) and *M xenopi* (isolated almost exclusively from water, especially from hospital hot-water systems, and called the hot-water bacillus).<sup>13,22</sup>

Although *M ulcerans* has recently been isolated in Australia from koalas, there have been no isolates from samplings of soil, water, or vegetation; however, Buruli (Uganda) and Bairnsdale (Australia) ulcers, both caused by *M ulcerans*, are known to be endemic in tropical or subtropical areas where wet, marshy terrain produces lush vegetation—usually without koalas in the environment.<sup>20</sup> *M marinum* is not only found in both fresh and salt water, it is also found in fresh- and salt-water fish. In addition, *M marinum* is found in swimming pools, aquariums, and mud and is capable of multiplying in soil.<sup>28</sup>

Although not isolated from soil or natural water supplies, *M kansasii* has been isolated many times from tap water and is found in wild and domestic animals such as cattle and pigs.<sup>22,29</sup> Organisms from the *M fortuitum-chelonae* complex have been isolated from soil, natural water supplies, tap water, house dust, distilled water, hemodialysis equipment, and even gentian violet skin-marking solutions.<sup>22,30</sup> *M scrofulaceum* organisms have been found in soil, water, raw milk, dairy products, and oysters.<sup>13</sup> Researchers in one report pooled together shucked oysters from several oyster beds. The oyster homogenate, inoculated on mycobacteria cultures, grew *M scrofulaceum*.<sup>31</sup>

The pulmonary route of infection is probably the most common for *M avium-intracellulare* complex. Interestingly enough, the highest numbers of these isolates are found aerosolized in air samples when compared to soil, dust, sediment, or even water samples (*M avium* and *M intracellulare* can remain viable for years in soil and water).<sup>13</sup> Even though the organisms are known to cause disease in birds, poultry, pigs, cattle, and monkeys, the disease has not been shown to be communicable from these animals to humans.

With the possible exception of pulmonary infections with *M xenopi*, human-to-human infections by atypical mycobacteria do not occur.<sup>32</sup>

### Distribution

Distribution of atypical mycobacteria appears to be worldwide; however, some organisms are found only in limited areas (eg, *M ulcerans* in Central Africa, Australia, New Guinea, Mexico, Central America, and South America). Some species are common in relatively similar geographical areas. For example, although *M avium-intracellulare* and *M fortuitum-chelonae* complexes are found almost worldwide, in the United States they are more common in the southeastern and Gulf-coast states, while *M kansasii* is more prevalent in the midwestern and central parts of the country.<sup>22,29</sup> A 1967 report,<sup>33</sup> which consolidated data from two previous reports<sup>34,35</sup> on the incidence of skin-test reactions to specific atypical mycobacterial antigens in healthy U.S. Navy recruits, gave the following results: in 257,476 recruits, *M avium-intracellulare* produced fewer than 30% reactors from northern, western, and far-western regions, and approximately 70% reactors from the southeastern United States. Similarly, in 31,479 recruits, *M scrofulaceum* produced about 30% to 50% reactors in most areas of the United States, while it produced more than 80% reactors in the southeastern United States.<sup>33</sup> Likewise, *M avium-intracellulare* complex infections are generally more common in rural areas, while *M kansasii* is most common atypical mycobacterium found in sputum specimens from urban areas.<sup>36</sup>

The relatively uncommon occurrence of *M malmöense* has been reported only rarely outside a relatively limited area that includes Sweden, Ireland, England, and Wales.<sup>13,21</sup> The occurrence of *M scrofulaceum* is worldwide, but generally in the more temperate climatic zones, while *M marinum* is found worldwide in association with either fresh or salt water.<sup>13,37</sup> Causing only rare cases of pulmonary disease, *M asiaticum* has been found in Queensland, Australia, and Los Angeles, California.<sup>19</sup>

## CLASSIFICATION SYSTEMS

Due to the variability in organ systems involved and in the clinical expression of disease in the atypical mycobacteria group, standardization of a logical, understandable classification system is difficult at best. However, some semblance of order has

developed since 1954, with the first attempt by Timpe and Runyon to group these organisms into meaningful categories. In that first attempt at classification, organisms were not named by their species but instead were placed in Groups I, II, or III



according to their colony color, texture, rate of growth, virulence in guinea pigs and mice, and how these characteristics compared with those of organisms from other microbiology laboratories from around the country.<sup>1</sup> Runyon's much more sophisticated system was proposed in 1959, when he placed more than 400 atypical strains in the following three slow-growing groups (ie, Groups I, II and III, which grew in 3–4 wk), based mainly on colony color and the effects of light and darkness; and in Group IV, based solely on how rapidly the colonies grew<sup>2</sup>:

- Group I: Photochromogens (color forms only with light),
- Group II: Scotochromogens (color forms even in darkness),
- Group III: Nonphotochromogens (weak to no color forms in both darkness and light), and
- Group IV: Rapid Growers (colonies grow within 48 h, with little to no color).

Additional features that were recorded included pretreatment drug resistance; strong colony catalase activity; growth at room temperature; lack of virulence in guinea pigs; and colony characteristics, including intense pigmentation, smooth surface, easy dispersion in liquid, and growth within 3 days. Several of the then-known species of atypical mycobacteria were then placed in one of these four simple groups according to their colony-growth characteristics; others (eg, *M ulcerans*) were not placed in the groups because their features overlapped.

Since then, many additional tests for species separation have been developed that can be used by specialty laboratories to determine (a) the exact species of atypical mycobacteria causing a specific disease and (b) its drug sensitivities. Using readily available media and incubating at the appropriate temperatures, a relatively accurate appraisal of suspected atypical mycobacteria can be made, using tables based on the original Runyon groups. The recently identified species have been inserted into their appropriate groups (Exhibit 16-2) for the reader's convenience. The most commonly isolated organisms are listed toward the top of each group; special or unique characteristics are noted in parentheses for some species; and, for the more uncommon pathogens, the most significant investigations are referenced. Although not included with the atypical mycobacteria because it was always the "typical" one, *M tuberculosis*, if it were listed, would go into Group III: its colonies are slow growing and produce no pigmentation. At present, *M leprae* is not culturable by routine methods and therefore is

## EXHIBIT 16-2

### RUNYON CLASSIFICATION OF ATYPICAL MYCOBACTERIA

#### Slow Growers (> 7 d)

##### Group I, Photochromogens

- M marinum*\*
- M kansasii*
- M szulgai* (at 25°C)<sup>1</sup>

##### Group II, Scotochromogens<sup>†</sup>

- M scrofulaceum* (cervical adenitis with ulcerations)
- M szulgai* (at 37°C)<sup>1</sup>
- M xenopi* (adenitis, sinus tracts)<sup>2</sup>
- M gordonae*<sup>3</sup>

##### Group III, Nonchromogens

- M avium-intracellulare*<sup>‡</sup>
- M ulcerans*
- M heamophilum* (seen in immunocompromised patients)<sup>2</sup>
- M malmöense*<sup>4</sup>

#### Rapid Growers (< 7 d)

##### Group IV, Buff colored

- M fortuitum-chelonae* complex (after surgery and trauma)\*
- M smegatis* (after cardiac bypass surgery)<sup>5</sup>

\*Most commonly seen

<sup>†</sup>All in this group are rare

<sup>‡</sup>Seen with increasing frequency with HIV infections  
The following are the most significant investigations for particular organisms:

1. Cross GM, Guill MA, Aton JK. Cutaneous *Mycobacterium szulgai* infection. *Arch Dermatol*. February 1985;121:247-249.
2. Woods GL, Washington JA II. Mycobacteria other than *Mycobacterium tuberculosis*: Review of microbiologic and clinical aspects. *Rev Infect Dis*. Mar-Apr 1987;9(2):275-294.
3. Shelley WB, Folkens AT. *Mycobacterium gordonae* infection of the hand. *Arch Dermatol*. 1984;120:1064-1065.
4. Gannon M, Otridge B, Hone R, Dervan P, O'Loughlin S. Cutaneous *Mycobacterium malmöense* infection in an immunocompromised patient. *Int J Dermatol*. March 1990;29(2):149-150.
5. Wallace RJ Jr, Musser JM, Hull SI, et al. Diversity and sources of rapidly growing mycobacteria associated with infections following cardiac surgery. *J Infect Dis*. 1989;159(4):708-716.

not placed in a classification group based on colony characteristics.

Some classification schematics differentiate organisms solely on their pigment production without reference to the rate of colony growth, while

others are based on characteristic clinical and radiographic findings and skin tests (eg, purified protein derivative of tuberculin [PPD]).<sup>36</sup> A recently suggested classification system for cutaneous mycobacteriosis, which includes mostly tuberculous infections, is based on the clinical *source* of the infection: whether exogenous, endogenous, or hematogenous.<sup>38</sup> A disadvantage of this particular system is that the atypical mycobacteria can fall into any of these three categories, and identification of the particular organism is not the goal of this system. A more recent, clinically useful classification system divides atypical mycobacterial infections into clinical disease groups based on the organ system involved—pulmonary, lymphatic, cutaneous, or disseminated.<sup>22</sup> In this classification system, common and unusual etiologic species in each group are then listed along with their growth rates, colony pigmentation characteristics, and references to the medical literature. One limitation of this system is that only the more common skin pathogens are

included; therefore, if a patient's disease is caused by a rare, atypical organism, it might not be considered in the clinical or laboratory differential.

One of the main objectives of organism classification is to expedite the initiation of effective therapy. In nonimmunocompromised patients who have atypical mycobacterial skin infections, time may be on the side of the patient. However, should the infection disseminate or spread to deeper structures—or, in immunocompromised patients, to soft tissue—time may be of the essence in preventing severe morbidity or even mortality. Additionally, the ability to rule in certain atypical mycobacterial infections and to rule out others by culture classification is significant in managing these patients with confidence and effectiveness. In most cases of mycobacterial infection, the histopathology alone will not be completely diagnostic; therefore, in cases with borderline or overlapping histopathological findings, the bacteriological classification of the involved organism may become vital.

## HISTOPATHOLOGY

As occurs in *M tuberculosis*, seven different patterns of reaction may be seen on histological examination of the atypical mycobacteria (see Chapter 15, Cutaneous Tuberculosis, for further discussion of these patterns):

1. classic tuberculoid granulomas,
2. abscess formation,
3. diffuse infiltrate of histiocytes,
4. panniculitis,
5. nonspecific chronic inflammation,
6. sarcoidal granulomas, and
7. rheumatoid-like nodules.

These patterns are not pure but represent a spectrum of changes. For example, well-formed granulomas are seen less commonly in atypical mycobacterial diseases than they are in *M tuberculosis* infections, and a classic tuberculoid pattern is not commonly seen. Therefore, instead of relying on a classic tuberculoid granuloma, the medical officer should be sufficiently familiar with the general patterns to suspect a mycobacterial infection in routine stained material, then obtain special acid-fast stains to identify the causative organism. In most atypical mycobacterial infections, acid-fast organisms are sparse (Fig-

ure 16-1). However, in early necrotic areas of Buruli ulcer and in immunocompromised patients, many organisms—sometimes even clumps—can be seen.

The features most commonly seen with each specific atypical mycobacterial infection are discussed later in this chapter.



**OK to put on the Web**

**Fig. 16-1.** Note the acid-fast bacillus in the center of this positive acid-fast stain of atypical mycobacteria.

## MYCOBACTERIOLOGY

In 1896, the genus name *Mycobacterium* was given to a group of bacteria that grew moldlike pellicles when cultured on liquid media.<sup>39</sup> This genus of bacteria was already large, and many additional species, including the atypical mycobacteria, have been added during the 20th century. All atypical mycobacteria are nonmotile, aerobic, nonencapsulated, nonsporulating, usually slender bacilli that have a waxy coating that resists acid-alcohol decolorizing once they are stained, thus their designation *acid fast*.

Useful acid-fast stains for these organisms include Ziehl-Neelsen and Kinyoun, a modified Ziehl-Neelsen stain that is milder and better suited to atypical mycobacteria. The Fite (Fite-Ferraco) stain, usually used in staining for *M leprae*, is useful as a screening acid-fast stain for all mycobacteria. The auramine-rhodamine stain using a fluorochrome technique is approximately 100-fold more sensitive than the Fite stain and is very useful for detecting sparse numbers of atypical mycobacteria; *M fortuitum-chelonae* organisms, however, do not take this fluorochrome stain well. The routine Gram's stain is usually positive, to some degree, for atypical mycobacteria. The organisms vary in size, ranging from 0.2 to 0.6  $\mu\text{m}$  in diameter and 1.0 to 4.0  $\mu\text{m}$  in length; however, there may be some variability even within the same species (eg, *M malmöense* can be coccoid to short to moderately long).<sup>13</sup>

Routine culture media, such as blood or chocolate agar, will support growth of many of the atypical mycobacteria including *M haemophilum*, which requires a source of hemoglobin or hemin; however, these media dry out within 5 to 7 days, making them suboptimal for all except the rapid-growing group. Lowenstein-Jensen medium, with contaminant-inhibiting antibiotics, is the preferable medium, with 2% ferric ammonium citrate added if *M haemophilum* is suspected. The hemin requirement of this organism can be met by using standard chocolate agar, 5% sheep-blood Columbia agar, or by using the more specialized Mueller-Hinton agar with Fildes supplement. The growth of mycobacteria, especially *M haemophilum*, is stimulated by the presence of 5% to 10% carbon dioxide during culture growth. A new biphasic culture system (Septi-Chek AFB [SCAFB], manufactured by Roche Diagnostic Systems, Nutley, New Jersey) is a specially designed bottle containing four selected media (7H11, Lowenstein-Jensen, chocolate agars, and 7H9

broth) for mycobacterial culture that requires only the addition of the homogenized specimen and then incubation at the appropriate temperature. A slow-release carbon dioxide process is built into the system. Culture results from early testing have given results as good as or better than those with regular Lowenstein-Jensen medium. When an inoculum is placed on any culture, the surface of the medium should be scratched to ensure good contact with the medium and optimum growth conditions. For the first 2 weeks, the inoculated surface should be kept almost horizontal to prevent the colonies from loosening from the medium, and the container cap should be kept loose to allow circulation of the carbon dioxide.

Tissue being prepared for culture can be minced in a sterile Petri dish with a sterile number 10 or number 15 scalpel blade. Also available is the handheld Sterile Disposable Tissue Grinder (number 3505, manufactured by Sage Products, Inc., Cary, Ill). This disposable plastic tissue grinder makes homogenization of tissue fast and simple. Great care must be taken to prevent contamination with environmental bacteria and ubiquitous saprophytic atypical mycobacteria, which, under proper conditions, can be opportunistic pathogens and, if grown out as a contaminant, could cloud the diagnostic picture.

Overgrowth of cultures by contaminants is a major problem in culturing of mycobacteria, because all are relatively slow growers compared to most bacteria. Even the rapid growers, which take only 3 to 7 days to grow, are slow compared to most other bacterial cultures (which, having no apparent colonies at 48 h, are called "no growth"). If any mycobacterial species are suspected, the laboratory should be advised to retain the special cultures for at least 8 weeks, as the usual laboratory procedure is to dispose of no-growth cultures after 48 to 72 hours. The laboratory procedures necessary to isolate and diagnose atypical mycobacteria can be described schematically (Figure 16-2).

Once suspected atypical mycobacterial colonies do grow, they should be checked for acid-fastness by using the Kinyoun or auramine-rhodamine staining technique. If the culture is acid-fast staining, the organism is most likely a mycobacterium; however, *Nocardia* (a genus of actinomycetes; see Chapter 18, Deep Fungal Skin Diseases) with its uneven acid-fast staining, could be present. All suspected

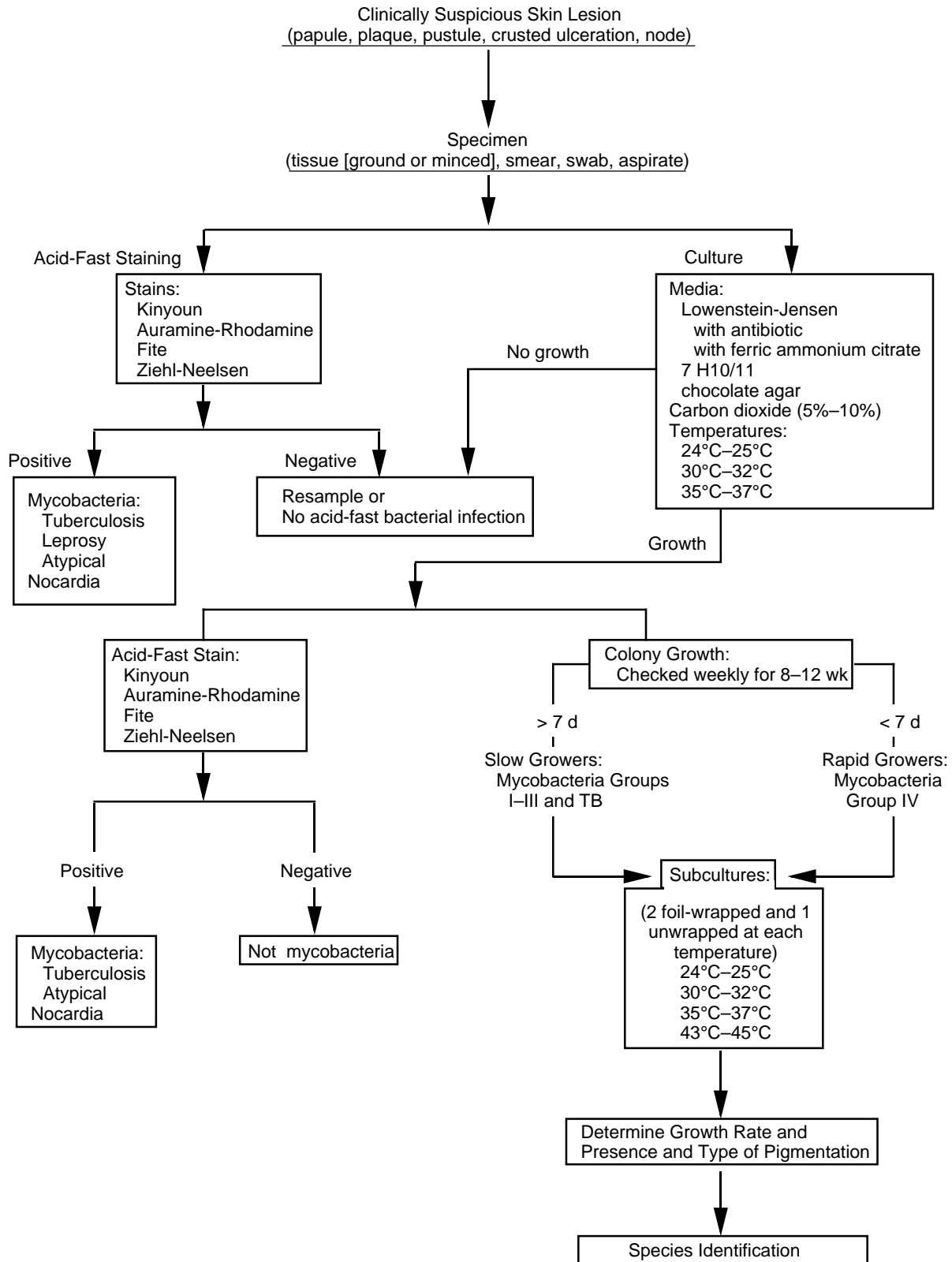


Fig. 16-2. Algorithm for the laboratory diagnosis and isolation of atypical mycobacteria.

**TABLE 16-2**  
**COLONY GROWTH AS A FUNCTION OF TEMPERATURE**

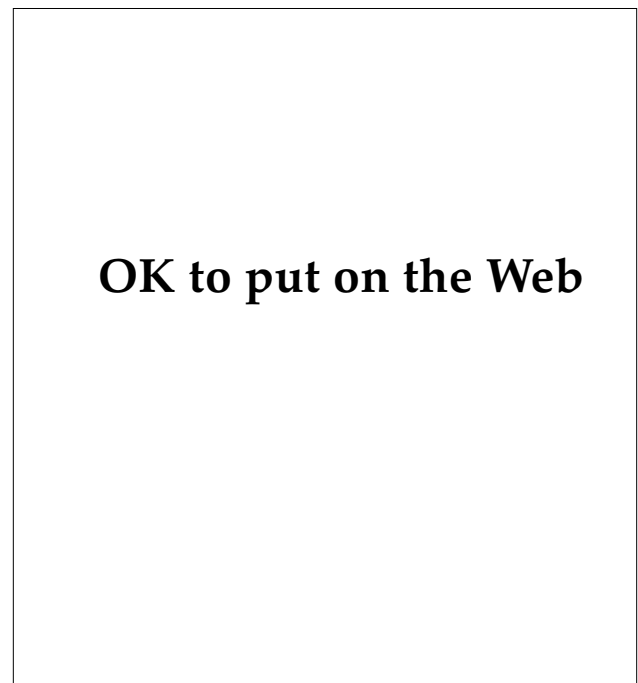
Atypical Mycobacteria	Temperature Range (in °C)			
	24–25	30–32	35–37	42–43
Group I				
<i>M marinum</i>	+	+(7–14)*	N	N
<i>M kansasii</i>	S	S	+(10–20)*	N
Group II				
<i>M szulgai</i>	S	S	+(12–25)*	N
<i>M scrofulaceum</i>	S	S	+( > 10)*	N
<i>M xenopi</i>	N	N	+	+(14–28)*
<i>M gordonae</i>	S	S	+(20–50)*	N
Group III				
<i>M avium-intracellulare</i>	±	+	+(10–21)*	±
<i>M haemophilum</i>	S	+(15–30)*	N	N
<i>M ulcerans</i>	N	+(28–60)*	S	N
<i>M malmöense</i>	S	S	+(15–60)*	N
Group IV				
<i>M fortuitum–chelonae</i> complex	+	+	+(3–5)*	N
<i>M smegmatis</i>	+	+	+	+(3–5)*

\* number of days necessary for growth at the optimum temperature

+: good growth; ±: growth may or may not occur; S: slow growth; N: no growth

mycobacterial cultures should be saved under refrigeration for sensitivity testing and positive biochemical identification procedures by a specialty laboratory, or by a referral laboratory such as the National Jewish Center, Denver, Colorado.

Temperature effects on atypical mycobacterial growth are crucial for both colony survival and for differentiation among the various species. (As discussed previously, the difference in temperature requirements and the production of colony pigmentation with and without exposure to light are the two characteristics that originally raised scientific awareness that atypical mycobacteria existed and were different from the tubercle bacillus.) With some species of atypical mycobacteria, colony growth to any degree hinges on the ambient temperature. The first objective in culturing is to obtain some colony growth; therefore, only a few parameters require attention. The properly inoculated Lowenstein-Jensen cultures are incubated at 25°C (usual room temperature), at 30°C, and at 37°C, with a 5% to 10% carbon dioxide atmosphere. If colonies appear between 3 to 7 days and are acid-fast on staining, then rapid-growing atypical mycobacteria are most likely present. If acid-fast colonies appear from 8 days to 8 weeks, then either a tuberculosis or a slow-growing atypical mycobacterium is most likely present. As mentioned above,



**Fig. 16-3.** These Lowenstein-Jensen cultures contain orange scotochromogen (*Mycobacterium gordonae*) colonies (left) and buff-colored, nonpigmented, rapid-grower (*Mycobacterium chelonae*) colonies (right). Cultures supplied by Deanne Harley, Supervisor, Microbiology Section, Laboratory Medicine Department, Naval Hospital, San Diego, California.

*Nocardia* can grow on Lowenstein-Jensen medium and is acid-fast; however, the staining is usually in an uneven pattern.

To further differentiate the organism, a saline or broth suspension from the initial culture is inoculated onto Lowenstein-Jensen medium cultures at 24°C, 32°C, 35°C, and 42°C (Table 16-2). For each temperature setting, two foil-wrapped and one unwrapped Lowenstein-Jensen cultures are used. After colony growth is noted in the unwrapped, light-exposed cultures, one of the foil-wrapped slants with growth is exposed to a strong light (eg, a 100-W light bulb at a distance that does not heat the

culture, approximately 50–60 cm). The other culture tube remains foil-wrapped and serves as a control for comparison. After 3 to 5 hours of exposure to light, the cultures are returned to their respective incubators and examined at 24, 48, and 72 hours for evidence of yellow or orange colonies (Figure 16-3) as compared to the covered control. With this information, using Table 16-2 and Exhibit 16-2, cutaneous atypical mycobacteria may be grossly classified to guide initial or continuing therapy. Positive cultures should always be saved under refrigeration for later use in definitive classification and drug sensitivity testing, if necessary.

### ATYPICAL MYCOBACTERIAL INFECTIONS

Because its first pathogenic representative was not identified until 1938, the recorded history of atypical mycobacterial infections is relatively short. In comparison with the other mycobacteria, leprosy and tuberculosis, they pose a much lower risk of serious disease. With little or no human-to-human contagion among the more than 30 species, infection usually is the result of an opportunistic encounter between patient and pathogen. These soil and water saprophytes will infect humans only under certain conducive conditions. In the operational military setting, traumatized skin is a portal of entry for *M marinum*, *M kansasii*, *M smegmatis*, and possibly *M ulcerans*. Penetrating wounds allow for deep inoculation of organisms such as *M gordonae* or *M fortuitum–chelonae* complex. Cardiac bypass surgery has been an avenue for infection by *M smegmatis*<sup>24</sup>; therefore, with cardiothoracic surgery of any type, whether in the military or civilian setting, it is prudent to be on guard for infection by this organism.

Atypical mycobacterial infections are slow in their progression and, occasionally, slow in regression. They can be widely destructive, as seen with deep infections with *M ulcerans* and *M scrofulaceum*. Having invaded tendons, joints, or even bone, *M kansasii*, *M szulgai*, or *M fortuitum–chelonae* complex organisms can be difficult to identify and even more difficult to eradicate. With the increasing frequency of organ transplantation and associated iatrogenic immunosuppression, the risk for opportunistic infection by several organisms such as *M haemophilum*, *M xenopi*, *M avium–intracellulare* complex, and even *M marinum* has correspondingly increased. Patients with AIDS are particularly susceptible to the *M avium–intracellulare* complex, which is found at autopsy in more than half of AIDS victims.<sup>40</sup>

As noted, mycobacterial infections have not played a pivotal role in military history. However, with the possibility that the military will be deployed anywhere in the world for brief or extended peacekeeping or combat missions, infections with these organisms should be kept in mind when military planners consider the biological threats in an operational arena. Otherwise, the failure to suspect, and thus to diagnose, infections by these organisms will lead to delayed diagnoses and treatment—with resultant increases in patient morbidity and even mortality.

#### ***Mycobacterium marinum* Disease (Group I, Photochromogen)**

The synonyms for *M marinum* include *M balnei*, *M platyopocilus* (recognized early as the cause of tuberculosis in Mexican platyfish), swimming-pool granuloma, fish-tank granuloma, fish-fancier's finger, aquarium granuloma, and oyster-shucker's palm.

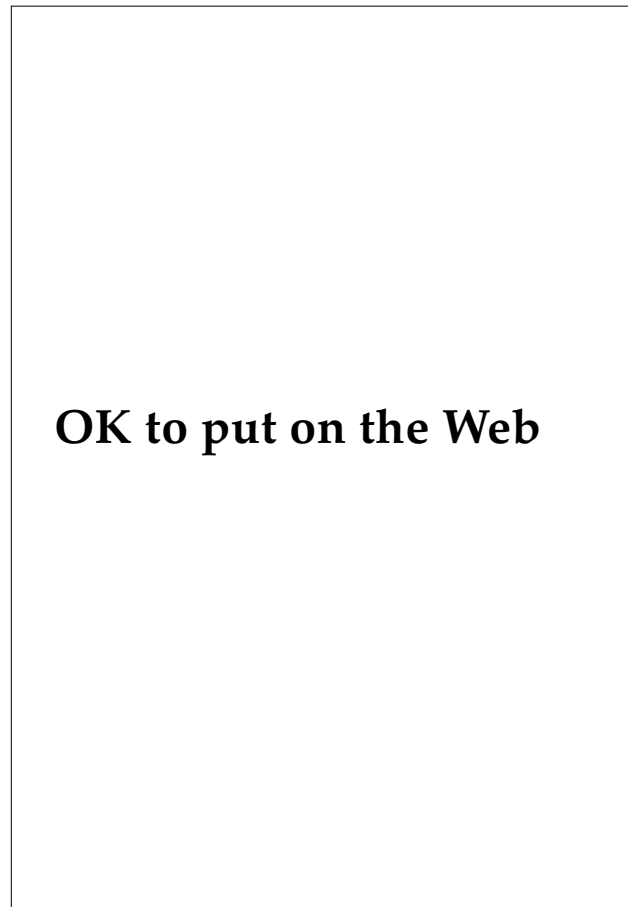
#### **Epidemiology**

Although first isolated from salt-water fish in the Philadelphia, Pennsylvania, aquarium in 1926, and named *M marinum* then, this mycobacterium was not identified as a human skin pathogen until 1951.<sup>7</sup> The overall incidence in the United States is only about 0.05/100,000<sup>41</sup>; however, it is the most common atypical mycobacterium to cause skin disease in the United States, with about 600 cases reported since 1951. The natural habitat is worldwide, in temperate fresh or salt water (eg, harbors, bays, rivers, brackish coastal waters, inadequately chlorinated pools, aquariums, and even the Dead Sea).

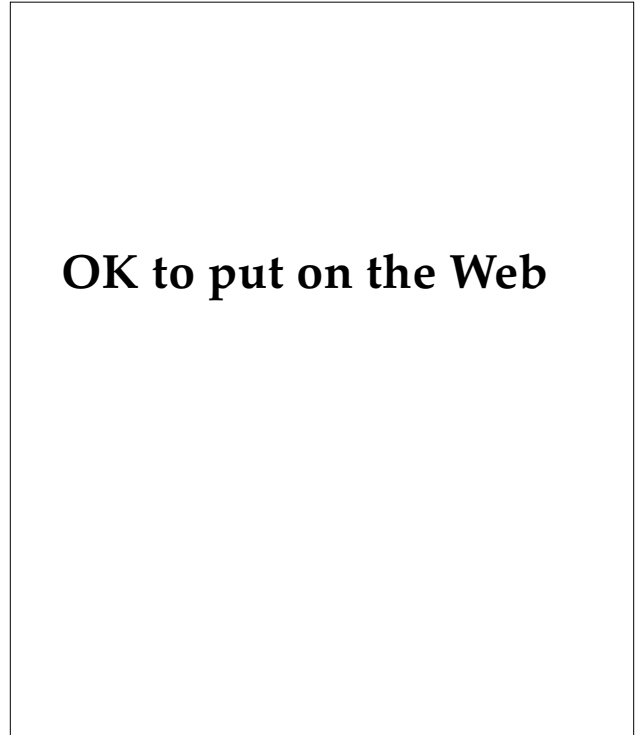
This organism has been readily cultured from masonry cracks and chinks in pools as well as from the mud in natural water sources. It is pathogenic for, and has been isolated from, marine animals, frogs, fishes, and even the water flea *Daphnia*. Humans acquire the infection through (a) traumatized skin lesions exposed to contaminated water or (b) wounds inflicted by, or in contact with, marine animals or their products (eg, fish bone). Occasionally, what seems to be epidemics of infection have occurred in patients using the same swimming pool; however, person-to-person transmission has not been reported and is assumed not to occur.<sup>7</sup>

### Diagnostic Features

A slightly tender, red, indurated area develops in the skin within a 1- to 6-week incubation period



**Fig. 16-4.** The early lesion of *Mycobacterium marinum* infection appears approximately 3 weeks after exposure to the organism in a water environment. Here, a brownish red papulonodule on the wrist is the first sign of infection.



**Fig. 16-5.** As an unrecognized, untreated infection with *Mycobacterium marinum* becomes chronic, over a several-week period, a verrucous plaque, like the one shown on this patient's knee, develops.

(usually about 3 wk) and then progresses to single or, occasionally, grouped multiple, brownish red papulonodules that slowly become violaceous (Figure 16-4). The skin lesions may eventually ulcerate to drain pus or they may form slightly verrucous papules or plaques resembling psoriasis (Figure 16-5). These papules are usually located, in decreasing order of occurrence, on the elbows (most common by far), knees, hands, or feet that have been traumatized during water-related work or leisure activities (Figure 16-6). Uncommonly in *M marinum* infection, underlying bursae, bone, or synovia may become involved. Systemic spread occurs in about 2% of infections, in immunocompromised or immunocompetent patients.<sup>7,42</sup> In about 25% of cases, tender, red, centrally spreading, secondary nodules can be seen along the course of the lymphatics of the involved extremity in a sporotrichoid pattern (Figure 16-7).<sup>7</sup>

**Differential Diagnosis.** The differential diagnosis for *M marinum* infection includes sporotrichosis, nocardiosis, blastomycosis, chromoblastomycosis, other mycobacterioses, cutaneous leishmaniasis, coccidioidomycosis, tularemia, foreign body granu-

## OK to put on the Web

**Fig. 16-6.** The feet may be affected if they are traumatized during water-related work or leisure activities. The enlarging plaque on this patient's foot is due to infection with *Mycobacterium marinum*. Photograph: Courtesy of Captain E. C. Oldfield, Medical Corps, US Navy, Naval Hospital, San Diego, Calif.

loma, posttraumatic hypertrophic scar, iodine and bromine granuloma, granuloma annulare, hypertrophic lichen planus, sarcoidosis, psoriasis, ecthyma, favus, syphilis, cutaneous tuberculosis, warts, and skin cancer.<sup>7,43</sup>

**Histopathology.** In only about 10% of cases does the histopathology reveal acid-fast bacilli, which are usually located within histiocytes. The granulomatous pattern is that of an epithelioid granuloma that usually does not exhibit caseation necrosis.

**Laboratory Features.** *M. marinum* is one of the faster slow-growing atypical mycobacteria, such

## OK to put on the Web

**Fig. 16-7.** As the infection ascends the lymphatics, multiple inflamed papulonodules develop proximal to the initial site. These lesions may ulcerate with time. The pattern shown here is referred to as "sporotrichoid" because it resembles the grouping of lesions seen in sporotrichosis.

that in 7 to 10 days, cultures grown in the dark produce nonpigmented colonies; these then become yellow-orange within 24 to 48 hours after exposure to the proper light (see Figure 16-3). In fact, in early classification schemata, *M. marinum* was occasionally classified as a rapid grower; however, a more restricted growth time (ie, < 7 d) now excludes this organism from the rapid growers. Culture media include Middlebrook 7H10 and 7H11, and Lowenstein-Jensen with antibiotic. Temperature control is a critical factor for growth of this organism since it typically grows best at 30°C to 32°C and not at the usual laboratory level of 37°C (see Table 16-2); however, this organism can show some eventual growth at 37°C.<sup>11,44</sup> If the culture conditions are optimum, *M. marinum* can be isolated by culture in about 70% of the involved cases with the earlier clinical lesions producing the greatest number of positive cultures.

### Course, Treatment, Prognosis, and Prevention

Single skin papules may heal spontaneously in 6 to 36 months; however, some infections have persisted for more than 45 years,<sup>45</sup> which makes initiation of therapy a reasonable approach. In the past, since this organism is resistant to some antituberculous drugs, local destruction of small areas of involvement was carried out by surgical excision, cryotherapy, curettage, or radiation. Fortunately, over the past 15 years, treatment with oral tetracycline (2 g/d) and, more recently, minocycline or doxycycline (200 mg/d) for 2 to 4 months has been quite effective in most cases.<sup>46</sup> Oral trimethoprim-sulfamethoxazole administered twice daily, or rifampin (600 mg) with ethambutol (15 mg/kg) administered daily for 3 months, or both, have also been successful therapy in resistant cases.<sup>22</sup> Rarely, cutaneous dissemination occurs in immunocompetent patients<sup>42,47</sup> and, on occasion, dissemination of infection may be associated with the administration of systemic corticosteroids.<sup>48</sup> Similarly, intralesional steroid injection may produce enlargement or exacerbation or both of the lesion (Figure 16-8). Dissemination or more severe and widespread cutaneous infection may occur in immunocompromised patients with *M. marinum*.<sup>48</sup>

Preventive measures include adequate chlorination of swimming pools, protection of traumatized skin from contaminated water, and reduction of skin trauma in those exposed to natural water sources or fish tanks. For example, in the Ches-



## OK to put on the Web

**Fig. 16-8.** Plaque of *Mycobacterium marinum* infection on the elbow. The original lesion began as a verrucous plaque resembling psoriasis and initially was injected with intralesional steroid by an unsuspecting civilian healthcare provider. Photograph: Courtesy of Commander S. J. Walker, Medical Corps, US Navy, Naval Hospital, San Diego, Calif.

peake Bay area, many commercial fishermen and watermen wear thick gloves while working with fish or crabs. If salt-water wounds occur, meticulous wound care, with thorough irrigation, should be performed. Severe or multiple wounds may benefit from a short prophylactic 3- to 5-day course of oral tetracycline or minocycline.<sup>49</sup> Infection with *M. marinum* frequently produces persistent positive cross-reactivity with tuberculin skin testing; this, however, is not a reliable diagnostic modality but should be kept in mind when PPD skin testing is done on patients who work in or around marine industries.<sup>7</sup>

### ***Mycobacterium kansasii* Disease (Group I, Photochromogen)**

#### ***Epidemiology***

*M. kansasii*, also known as the yellow bacillus of Buhler and Pollak, and as the orange bacillus, is worldwide in distribution but is especially prevalent in temperate-climate areas such as the midwestern and southwestern United States. This organism is commonly found in tap water and in both wild and domestic animals such as cattle and pigs. Pulmonary infections are most common and are probably caused by inhalation of aerosolized organisms; skin infections are much less common. Skin infection was reported in 1965,<sup>16</sup> with only nine additional cases reported as of 1987.<sup>12</sup> Cutaneous

involvement may occur in normal or previously traumatized skin, and is commonly seen in patients with immunodeficiency.

#### ***Diagnostic Features***

The infection incubation time of *M. kansasii* is from 15 days to several months. Clinical manifestations include red-to-violaceous indurated papules or plaques; pustular, ulcerated, crusted, or verrucous papules or nodules; cellulitis; abscesses; joint pain including arthritis, synovitis, and bursitis; cervical adenopathy; and a sporotrichoid adenopathy of an involved extremity (see Figure 16-6).

The clinical differential diagnosis includes pyogenic abscess, cellulitis, and sporotrichosis, as well as the other mycobacterioses. Exhibit 16-3 not only presents the variety of diseases that can have a sporotrichoid pattern of lymphatic spread but also directs the reader to the most noteworthy description of this clinical presentation.

***Histopathology.*** Histopathology can show acute and chronic inflammation alone, or tuberculoid or epithelioid granulomas with large, cross-barred, acid-fast bacilli in about 10% of all cases.<sup>50</sup>

***Laboratory Features.*** Cultures grow best on Lowenstein-Jensen medium at 37°C after 10 to 20 days (see Table 16-2), and produce yellow-orange pigment containing beta carotene crystals after exposure to bright light (see Figure 16-3). There are no reliable, routine, specific skin tests or serologic tests available.

#### ***Course, Treatment, Prognosis, and Prevention***

Pulmonary *M. kansasii* disease is apparently self-healing, as evidenced by research studies with prepared PPD-like material showing positive skin tests in about 50% of the healthy adult population of the United States.<sup>50</sup> In the few skin infections reported, untreated infections lasting up to 22 years have been seen.<sup>16</sup> For skin infection, successful therapy has included daily isoniazid (300 mg) plus rifampin (600 mg), with ethambutol (15 mg/kg for 18–24 mo), with streptomycin added (1 g/d for 2 wk, then twice weekly for 3 mo).<sup>22</sup> The addition of transfer factor to the treatment regimen has been helpful in successfully treating immunocompromised patients.<sup>51</sup> Oral therapy with minocycline (200 mg/d) has also been successful,<sup>52</sup> as has surgical excision of localized cervical adenitis.<sup>29</sup> There are no preventive measures known.

***Mycobacterium szulgai* Disease (Group I, Photochromogen/Scotochromogen)**

**Epidemiology**

*M szulgai*, first recognized in 1972, is a rare pathogen with fewer than 20 total cases reported—of which most have been chronic pulmonary disease in middle-aged men with fewer than 6 cases involving skin or soft tissue.<sup>13</sup> Apparently, this organism is distributed worldwide with no known natural reservoirs. The incidence of disease reported in 1983 in the United States was 0.01/100,000.<sup>41</sup>

**Diagnostic Features**

*M szulgai* has an array of manifestations. Red, tender nodules on the extremities, trunk, or neck may become fluctuant and drain spontaneously.<sup>53,54</sup> Some of these lesions have manifestations of underlying osteomyelitis or bursitis with or without accompanying pulmonary disease. Disease has been seen in immunocompromised and immunocompetent patients. The differential diagnosis includes all the causes for carbuncle, cellulitis, subcutaneous pyogenic abscess, olecranon bursitis, and tenosynovitis.

**Histopathology.** Histopathology is that of a histiocytic granuloma with multinuclear giant cells without caseation necrosis. The presence of acid-fast bacilli within the granuloma is variable.

**Laboratory Features.** Culture characteristics are both interesting and confusing: this organism is a photochromogen, with yellow-orange pigment production (see Figure 16-3) only after light exposure, when grown at 25°C; but it is also a scotochromogen, producing yellow pigment when grown in the dark at 37°C. Colonies appear at 2 to 4 weeks, with slower growth at the lower temperature.

**Course, Therapy, Prognosis, and Prevention**

Apparently *M szulgai* disease is progressive, especially in immunocompromised patients and, therefore, deserves treatment when it occurs. In a prednisone-immunosuppressed patient,<sup>53</sup> effective therapy was achieved with oral administration of isoniazid (300 mg/d), rifampin (600 mg/d), and ethambutol (1,200 mg/d for 24 mo); the prednisone was discontinued over a 3-week period at the beginning of this therapy. Since prolonged treatment of this organism is required, it must be distinguished from the usually more-responsive infections with *M tuberculosis* and other atypical mycobacteria.

**EXHIBIT 16-3**

**SKIN INFECTIONS WITH SPOROTRICHOID LYMPHATIC SPREAD**

- Sporotrichosis<sup>1</sup>
- Nocardiosis<sup>1</sup>
- Atypical mycobacteria
  - M marinum*<sup>2,3</sup>
  - M kansasii*<sup>2,4</sup>
  - M scrofulaceum*<sup>5,6</sup>
  - M chelonae*<sup>7</sup>
  - M avium-intracellulare*<sup>8</sup>
  - M gordonae*<sup>9,10</sup>
- Tuberculosis<sup>1</sup>
- Tularemia<sup>1</sup>
- Syphilis<sup>1</sup>
- Yaws<sup>1</sup>
- Scopulariopsis (blochi)<sup>1</sup>

The following are the most significant descriptions of the clinical presentations of these organisms:

1. Moschella SL. Diseases of the mononuclear phagocytic system (the so-called reticuloendothelial system). In: Moschella SL, Hurley HJ, eds. *Dermatology*. Vol 1, 2nd ed. Philadelphia, Pa: WB Saunders; 1985: 890–999.
2. Glickman FS. Sporotrichoid mycobacterial infections. *J Am Acad Dermatol*. 1983;8:703–707.
3. Raz I, Katz M, Aram H, Haas H. Sporotrichoid *Mycobacterium marinum* infection. *Int J Dermatol*. 1984;23(8):554–555.
4. Dore N, Collins J-P, Mankiewicz E. A sporotrichoid-like *Mycobacterium kansasii* infection of the skin treated with minocycline hydrochloride. *Br J Dermatol*. 1979;101:75–79.
5. Sowers WF. Swimming pool granuloma due to *Mycobacterium scrofulaceum*. *Arch Dermatol*. 1972;105:760–761.
6. Murray-Leisure KA, Egan N, Weitekamp MR. Skin lesions caused by *Mycobacterium scrofulaceum*. *Arch Dermatol*. 1987;123:369–370.
7. Murdoch ME, Leigh IM. Sporotrichoid spread of cutaneous *Mycobacterium chelonae* infection. *Clin Exper Dermatol*. 1989;14:309–312.
8. Wood C, Nickoloff BJ, Todes-Taylor NR. Pseudotumor resulting from atypical mycobacterial infection: A “histoid” variety of *Mycobacterium avium-intracellulare* complex infection. *Am J Clin Pathol*. 1985;83:524–527.
9. McIntyre P, Blacklock Z, McCormack JG. Cutaneous infection with *Mycobacterium gordonae*. *J Infect*. 1987;14:71–78.
10. Gengoux P, Portaels F, Lachapelle JM, Minnikin DE, Tennstedt D, Tamigneau P. Skin granulomas due to *Mycobacterium gordonae*. *Int J Dermatol*. April 1987;26(3):181–184.

There are no suggested preventive measures at present.

### ***Mycobacterium scrofulaceum* Disease (Group II, Scotochromogen)**

#### ***Epidemiology***

In 1956, *M scrofulaceum*, also called the Gause strain of mycobacteria, was named because of its scrofula-like involvement of the cervical lymph nodes in children. Most cases involving this organism still occur in the cervical nodes of children between 1 and 5 years of age, with rare occurrence in adults. Distribution is worldwide in soil, tap water, raw milk, dairy products, and other products of the environment such as oysters.<sup>13</sup> The route of infection has not been firmly established; however, oral, oropharyngeal, and hematogenous pathways are suspected circumstantially. The estimated overall incidence of all *M scrofulaceum* disease in the United States was 0.07/100,000 in 1987.<sup>41</sup> Due to similar antigenicity with *M avium-intracellulare*, *M scrofulaceum* is sometimes classified as part of a *M avium-intracellulare-scrofulaceum* (MAIS) complex. An additional organism that causes ulcerative skin lesions and shares some biochemical characteristics with both species is classified as *M avium-intracellulare-scrofulaceum* intermediate.<sup>55</sup>

#### ***Diagnostic Features***

Clinically, *M scrofulaceum* disease usually occurs in healthy-appearing children and, rarely, in adults as unilateral cervical adenopathy high in the neck, with minimal pain or tenderness.<sup>13</sup> Occasionally, the involved nodes may remain stationary for perhaps weeks to months<sup>13,56,57</sup> and then regress, leaving residual fibrosis and calcification. More commonly, the nodes progress to softening with eventual rupture and drainage. This organism also occasionally appears as scattered, multiple, subcutaneous abscesses and in a sporotrichoid pattern (see Figure 16-7).<sup>58</sup> Other manifestations of disease caused by this organism include pulmonary disease, disseminated disease, conjunctivitis, osteomyelitis, meningitis, and granulomatous hepatitis.

In adults, the differential diagnosis includes those entities that produce an expanding neck mass such as infectious adenitis, dermatopathic reactive lymphadenitis, lymphoproliferative malignancy, metastatic node, cat-scratch fever, mononucleosis, salivary gland infection or duct stone, subcutaneous or peritonsillar abscess, tuberculosis, or mumps.

In children, the differential includes the causes of cervical lymphadenitis such as cat-scratch fever, infectious adenitis, hematological malignancy, reactionary inflammatory nodes, deep abscess, or mononucleosis. The other skin lesions of *M scrofulaceum* resemble pyogenic abscesses or sporotrichosis (see Exhibit 16-3).

***Histopathology.*** The histopathological appearance is essentially the same as that of tuberculosis with varying degrees of caseation necrosis, granulomatous inflammation, and acid-fast bacilli.

***Laboratory Features.*** Culture on Lowenstein-Jensen medium produces buttery, smooth, yellow-orange colonies in 2 to 4 weeks with the best growth at 37°C and slow growth at 24°C, 32°C, and 35°C (see Figure 16-3). The colony pigmentation occurs even when grown in the dark (scotochromogen) and then continues to darken to a deeper orange with prolonged exposure to light. No reliable, diagnostic, skin-test procedure is presently available for routine testing; and PPD skin testing may be reactive or nonreactive.

#### ***Course, Treatment, Prognosis, and Prevention***

*M scrofulaceum* disease usually progresses; therefore, therapy is recommended. Surgical excision of the affected lymph node has been successful in patients who have limited cervical adenitis; however, incision and drainage alone may result in chronic draining sinuses and recurrence despite concomitant drug therapy.<sup>13</sup> Successful drug therapy has included oral rifampin (600 mg/d) plus isoniazid (300 mg/d) for 9 months despite in vitro resistance.<sup>58</sup> There are no effective preventive measures yet established.

### ***Mycobacterium xenopi* Disease (Group II, Scotochromogen)**

#### ***Epidemiology***

*M xenopi*, also called the hot-water bacillus and *M littorale*, was first isolated in 1957 and recognized as a pathogen in 1965. This organism has been found in both cold and hot water systems.<sup>6</sup> Remarkably, it has been recovered from hot water generators and storage tanks of several hospitals, where it was linked to pulmonary disease.<sup>13</sup> It has been recovered from bird droppings and, considering the fact that it has been isolated commonly from the coastal areas of England, Europe, and the United States, sea birds are considered possible reservoirs.<sup>6,13</sup> In the southeastern part of England, *M*

*xenopi* is reported<sup>22</sup> to be the most common atypical mycobacterium recovered in the laboratory since 1977. Interestingly, *M xenopi* is common among the atypical organisms isolated incidentally from tonsils. Although not yet isolated from water mains, the organism may enter hospital hot-water tanks in small numbers via the water system and multiply at its optimum growth temperature of 43°C to 45°C. Infection may then occur by aerosolization and absorption via the respiratory tract.<sup>22</sup> Not a common pathogen, its incidence in the United States is estimated as 0.01/100,000<sup>41</sup>; most occurrences appear as pulmonary disease in patients with preexisting lung disease or other debilitating systemic disease.<sup>13</sup>

### Diagnostic Features

Immunocompromised patients with *M xenopi* disease may have cutaneous involvement when they have underlying bone or soft tissue involvement such as epididymitis, osteomyelitis, lymphadenitis, arthritis, or sinus tract.<sup>13</sup> The rare occurrence of disseminated disease is usually found in AIDS patients. The differential diagnosis of skin manifestations includes all causes related to the underlying disease process, and pulmonary disease is clinically identical to infections with *M kansasii* and *M avium-intracellulare*.

**Histopathology.** Histopathology is nonspecific with collections of epithelioid macrophages, Langhans'-type giant cells, and acid-fast bacilli within caseating granulomas.<sup>13</sup>

**Laboratory Features.** In culture, this organism is a scotochromogen, producing yellow pigment in the absence of light (see Figure 16-3), and growing best at the relatively warm temperature of 42°C to 43°C after 3 to 4 weeks. This is the temperature of hot-water holding tanks where this organism has been isolated, giving rise to the name hot-water bacillus.

### Course, Treatment, Prognosis, and Prevention

Infection by *M xenopi* is opportunistic in immunocompromised patients and should be treated when it occurs. Response to therapy has been inconsistent; however, some success has been obtained with combinations of isoniazid, rifampin, ethambutol, and streptomycin with uniform susceptibility to cycloserine and ethionamide.<sup>13</sup> Preventive measures might include culturing hospital hot-water systems in facilities that serve immunocompromised patients, thus ensuring an uncon-

taminated hot-water source for drinking, bathing, hydrotherapy, and wound cleansing.

### *Mycobacterium gordonae* Disease (Group II, Scotochromogen)

#### Epidemiology

*M gordonae* is variously known as the water bacillus, the tap-water bacillus, the tap-water scotochromogen, and *M aquae*. Rare extrapulmonary postoperative infections have been reported since the early 1970s<sup>28,59</sup> but the first cutaneous infection was not reported until 1984,<sup>60</sup> and by 1987, only three cases had been reported.<sup>28,61</sup> This organism has been one of the most common contaminant saprophytes isolated in the laboratory (sometimes approaching 15% of all mycobacterial isolates) and has been found in water, mud, water supplies, swimming pools, and in soil where it has been shown to multiply.<sup>13,27,28</sup> Some wild animals may be reservoirs, since *M gordonae* strains have been recovered from the lymph nodes of wild armadillos in Louisiana.<sup>61</sup> An interesting case report from Belgium involved a patient who developed cutaneous infection with *M gordonae* several months after being bitten by a rat while collecting frogs in a pond. Although the animal bite may have been the source of infection, it may also merely have been the mode of organism inoculation from another environmental source such as water or soil.<sup>61</sup>

#### Diagnostic Features

Cutaneous *M gordonae* infection occurs as small tender, red-blue papulonodules 0.5 to 1.5 cm in diameter with mamillated or ulcerated surfaces and with or without proximal lymphangitic spread in a sporotrichoid pattern,<sup>61</sup> as was seen in the first reported skin infections by this organism (see Figure 16-7).<sup>60</sup> Occurring after inoculation from a penetrating wound, infection may produce spreading, diffuse inflammation, with the wound discharging serosanguineous material. The patient can have localized lymphadenitis but systemic signs of toxicity: fever, chills, malaise, nausea, and vomiting.<sup>28</sup> The clinical differential diagnosis includes sporotrichoid diseases (see Exhibit 16-3), other mycobacterioses (especially *M marinum* or *M kansasii*), pyogenic infection, sarcoidosis, and other infectious granulomas.

**Histopathology.** Histopathology reveals large histiocytes, multinucleated giant cells, acute and chronic inflammation, and a few of the acid-fast

bacilli sometimes described as “plump rods.” The inflammatory elements may be intermixed with areas of fibrosis.<sup>60</sup>

**Laboratory Features.** This organism produces yellow-orange colonies even when grown in the dark, thus it is a scotochromogen (see Figure 16-3). The optimum growth temperature is 37°C. The required time for colonies to grow varies from 4 to 8 weeks, with some colonies not seen for 24 weeks on Lowenstein-Jensen medium (see Table 16-2). Culture growth is reported to have been enhanced by decontamination with sodium hydroxide and by using modified Ogawa medium at pH 6 (versus the usual Lowenstein-Jensen medium at pH 7).<sup>61</sup> Both tine and Mantoux PPD skin testing with 10 tuberculin units have been reported positive at greater than 5 mm induration at 48 hours.<sup>28</sup>

#### **Course, Treatment, Prognosis, and Prevention**

Therapy has included oral rifampin (300 mg/d) alone for 6 months, or trimethoprim/sulfamethoxazole (320 mg/1600 mg) administered twice daily with ethambutol (800 mg/d), both given for 24 months, with cycloserine (250 mg/d) added during the first 9 months.<sup>28,61</sup> Antibiotic disc susceptibility testing may be useful in guiding therapy of resistant cases of this infection. In two reported cases,<sup>28,61</sup> all lesions cleared without recurrence within the treatment periods. In the initial report of skin infection by *M. gordonae*,<sup>60</sup> the investigator warns that this organism should not always be assumed to be a harmless contaminant if isolated from clinical specimens. At the present time, no specific preventive measures are recommended.

#### ***Mycobacterium avium-intracellulare* Complex Disease (Group III, Nonchromogen)**

##### **Epidemiology**

The *M. avium-intracellulare* complex is known by a variety of synonyms including Battey bacillus (specifically *M. intracellulare*) and *M. avium* complex (MAC). As its name suggests, *M. avium* was first known as a pathogen of chickens, and has been recognized as such since 1868. In 1943, the organism was recognized as a human pulmonary pathogen; however, in 1953, a separate but closely related organism without pathogenicity for chickens was isolated. Later in 1957, this organism was found to be pathogenic in several inpatients of the Battey State Tuberculosis Hospital in Rome, Georgia, and

was named the Battey bacillus.<sup>33</sup> This organism was later speciated as *M. intracellulare*, but it is so similar to *M. avium* that for human pathogenicity the two can be combined into one complex. With an incidence of about 3.2/100,000 population, approximately one third that of tuberculosis, *M. avium-intracellulare* complex became second only to *M. tuberculosis* in total numbers of mycobacterial isolates in the United States by 1980 (see Table 16-1).<sup>27</sup> In the United States, this organism is found most often in rural areas of the southeastern part of the country. This complex is of interest to dermatologists because of its rare involvement of skin and lymphatics and because of its rising incidence in AIDS patients.

*M. avium-intracellulare* complex has been found in soil, salt and fresh water, house dust, animal feed, dried plants, and bedding; however, the highest number of isolates are found in aerosol samples. This suggests a likely route for pulmonary infection. Although *M. avium-intracellulare* complex is a cause of disease in such animals as poultry, pigs, and monkeys, these are not thought to be sources of human infection.<sup>13</sup> This species of atypical mycobacteria is discussed in the AIDS section of this chapter.

##### **Diagnostic Features**

In otherwise healthy patients, *M. avium-intracellulare* complex may be isolated from sputum without being the cause of disease. Disease that is manifest is usually expressed as pulmonary infection in middle-aged white males with preexisting lung disease. In AIDS patients, the presence of *M. avium-intracellulare* is an ominous sign, especially if it is found in the urinary or pulmonary tract. Dissemination of disease is usually seen in patients who are immunocompromised secondary to systemic steroid therapy or AIDS. Primary skin lesions are very rare and their presence strongly suggests immune compromise in any affected patient. Clinical manifestations of skin involvement include red-bordered plaques or crusted ulcerations, which range from limited numbers of lesions to spreading, extensive lesions. With dissemination of disease, multiple granulomas, pustules, ulcerations, and generalized adenopathy have been reported.<sup>29</sup> Other dermatologic manifestations include cervical adenitis in children or adults, subcutaneous nodules, sporotrichoid spread (see Figure 16-7), panniculitis, fasciitis, and synovitis.<sup>62</sup> The differential diagnosis can include all reactive, malignant,

and infectious causes of the above underlying diseases, as well as any chronic granulomatous or sporotrichoid disease (see Exhibit 16-3).

**Histopathology.** Histopathologically, skin and lymph nodes show either caseating or noncaseating granulomas with acid-fast bacilli either within or outside of giant cells. In AIDS patients, foamy macrophages containing many intracellular acid-fast bacilli may be seen.

**Laboratory Features.** Culture on Lowenstein-Jensen medium produces nonpigmented colonies in the dark or light at 37°C within 2 to 3 weeks (see Table 16-2).

### **Course, Treatment, Prognosis, and Prevention**

In immunocompetent adult patients with localized disease, surgical debridement plus oral rifampin (600 mg/d); ethambutol (25 mg/kg/d for 2 mo, then decreased to 15 mg/kg/d); isoniazid (300 mg/d); and ethionamide or streptomycin (administered for several months beyond clearing) are usually recommended. An effective role for isoniazid has not been clearly established. In children with cervical adenitis, recommended treatment is local excision for primary involvement and limited recurrence.<sup>22</sup> Treatment of disseminated disease in immunocompromised patients is not yet specific; however, the above adult-disease regimens with the addition or substitution of amikacin and clofazimine may offer potential therapeutic advantages. Prevention lies in reducing or preventing the causes of immunosuppression in the involved patient. At present, the true impact of disseminated *M avium* complex disease on the survival of AIDS patients is not certain, but projections appear gloomy.<sup>22,40</sup>

### ***Mycobacterium ulcerans* Disease (Group III, Nonchromogen)**

#### **Epidemiology**

As previously discussed, the *M ulcerans* organism was formerly also known as *M buruli*<sup>6</sup>; the disease is likewise known by several synonyms: Buruli ulcer (in the Buruli District of Uganda), Kakerifu ulcer (in Zaire), Bairnsdale ulcer or Searls' ulcer (in Australia), and Kumusi ulcer (in New Guinea).

Although large cutaneous ulcers had been described in Uganda in 1897 and mycobacterial skin ulcers had been recognized in 1937 in Bairnsdale,

Australia, not until 1948 was *M ulcerans* first described in patients from Bairnsdale.<sup>5,20,63</sup> Later, in 1964, multiple cases of ulcerations, with isolation of an organism named *M buruli*, occurred in the Buruli District of Uganda.<sup>6</sup> Subsequently, this organism was shown to be *M ulcerans*. This infection occurs almost exclusively in tropical or subtropical climates in areas of lush vegetation or marshy terrain, with thousands of endemic cases in Uganda and Zaire and hundreds of cases in New Guinea and Australia, making it the largest cause of atypical mycobacterial skin disease worldwide. Although the disease is not endemic in the United States, military physicians should be aware that infection can be brought in from more tropical climates. Until 1984, when it was first isolated in koalas,<sup>20</sup> this organism had never been isolated outside the human body; and although it has been hypothesized<sup>63</sup> that *M ulcerans* resides in soil as a contaminant or on foliage as a commensal and is transmitted via injury from the environment, transmission from animals to humans has not been demonstrated.

#### **Diagnostic Features**

Almost all *M ulcerans* lesions occur on extremities. They probably begin as injuries or insect bites that do not heal but instead become indurated, with eventual necrosis and spreading ulceration. Otherwise, the skin lesion appears as a single, firm, sometimes itchy, papule that becomes more indurated and fluctuant over several weeks and then breaks



**OK to put on the Web**

**Fig. 16-9.** The ulceration of this patient's lower leg is due to *Mycobacterium ulcerans* infection. Note the characteristic undermined borders. The lesion is surprisingly asymptomatic.

down into a spreading, punched-out ulceration with classically undermined edges (Figure 16-9). Multiple ulcers do appear, but have been reported in only a few cases.<sup>64</sup> There is little pain or tenderness associated with the ulceration and the skin just beyond the involved border appears perfectly normal without physical signs, systemic symptoms, or lymphangitic involvement. The ulceration usually extends only down to muscle, with rare bony involvement (probably due to the organism's preference for cooler growing conditions not usually found in warm, viable muscle). It has been hypothesized<sup>63</sup> that infection usually occurs on an extremity where the subcutaneous tissue temperature is lower than core temperature, thus fostering growth of this organism. In addition, if the organism is inoculated into the skin during the hotter months, it may remain dormant in the skin until a prolonged cooling period occurs, then exacerbate with development of ulcerations. According to some experts,<sup>63,65</sup> this disease should be considered in any patient who presents with a relatively painless, chronic, progressive skin ulcer on an extremity in a tropical area where it is endemic. Indeed, in West Africa, where hundreds of cases have been seen, Buruli ulcer is a reliable clinical diagnosis.

Differential diagnosis should include infected insect bite, pyoderma gangrenosum, brown recluse spider bite, deep fungal infection, tuberculosis, suppurative panniculitis, or self-inflicted injury.

**Histopathology.** Histopathology shows coagulation necrosis, septate panniculitis, without caseation necrosis, but with granulation tissue and giant cells towards the periphery. Smears and biopsy material from the necrotic areas almost always reveal acid-fast bacilli; however, material at the edge of the ulceration will usually be negative for organisms and positive for plasma cells—some with strikingly polynuclear features. In early skin lesions, large, spherical clumps of many acid-fast organisms can be found extracellularly in the deeper parts of necrosed, coagulated tissue.<sup>10</sup> In recurrent or chronic disease, acid-fast organisms may be sparse or difficult to find. A toxin produced by the organism is suspected as the necrolytic factor that allows progression of this necrolytic process.<sup>66</sup>

**Laboratory Features.** Cultures on Lowenstein-Jensen medium produce nonpigmented colonies at 32°C to 33°C after 6 to 12 weeks, a relatively long incubation time (see Table 16-2). At culture temperatures of 25°C, and above 35°C, growth may be very slow or completely absent. Tuberculin skin tests are sometimes positive but not to a reliable degree.

## OK to put on the Web

**Fig. 16-10.** The large, spreading skin ulceration of this patient's lower shin is due to infection with *Mycobacterium ulcerans*. Almost all Buruli ulcers occur on the extremities and, if untreated, tend to progress slowly in size.

### Course, Treatment, Prognosis, and Prevention

If untreated, ulcerations tend to progress over months to years to involve large areas (Figure 16-10), sometimes involving an entire extremity, before healing with residual scarring, deformity, and lymphedema. Some rare cases have required amputation.<sup>67</sup> Small lesions respond to simple surgical curettage and heal by granulation.<sup>63</sup> In addition, heat application to 40°C to the involved area has been helpful in some cases.<sup>67</sup> The mainstay of therapy is surgical excision of the entire area with primary closure or skin grafting. Drug therapy consisting of dapsone and streptomycin with or without ethambutol for a few weeks beyond complete healing is not successful alone, but may be a helpful adjunct in more limited surgical treatment.<sup>13</sup> Other antituberculous drugs have not shown any consistent efficacy; however, some response has been seen with trimethoprim-sulfamethoxazole followed by rifampin and minocycline.<sup>62</sup>

Preventive measures are aimed at avoiding trauma or protecting traumatized extremities from environmental contact in endemic areas. Bacille bilié de Calmette-Guérin (BCG) vaccination may be somewhat protective for about 6 months.<sup>67</sup>

### *Mycobacterium haemophilum* Disease (Group III, Nonchromogen)

#### Epidemiology

Since its first description in 1978, most of the dozen reported clinical cases of infection with *Mycobacterium haemophilum* have been from Austra-

lia or Israel. Almost all of these cases occurred in patients with lymphoma or renal transplants, many of whom were lymphopenic.<sup>13,68</sup> Organism sources and natural reservoirs are unknown at present.

### Diagnostic Features

The skin lesions usually occur in multiple locations on the extremities and occasionally on the trunk, with red-to-violaceous papules that gradually enlarge to become tender, crusted, ulcerated nodules or abscesses and fistulas draining purulent material.<sup>13,39</sup> Rarely, patients may have bony involvement or, in children, cervical adenitis may be present.<sup>68</sup> The clinical differential includes pyogenic abscesses, other mycobacterioses, metastatic disease, osteomyelitis, and all the causes of cervical adenitis in children.

**Histopathology.** Histopathology reveals granulomatous panniculitis with a polymorphous infiltrate, occasional Langhans'-type giant cells, and usually no caseation necrosis. Straight, uniformly staining, acid-fast bacilli are frequently present singly or in small clusters, and often intracellularly.<sup>13</sup> Biopsy material tissue imprints frequently reveal acid-fast organisms.<sup>68</sup>

**Laboratory Features.** *M haemophilum*'s most unique feature is its requirement for hemoglobin or hemin for growth on culture media. This requirement can be fulfilled with the use of chocolate agar, 5% sheep-blood agar, Mueller-Hinton agar with Fildes supplement, or most commonly, Lowenstein-Jensen medium with 2% ferric ammonium citrate.<sup>13</sup> Nonpigmented colonies are produced in 2 to 4 weeks, with growth definitely stimulated by the addition of 10% carbon dioxide. The optimum growth temperature is not yet established but appears to be about 30°C, especially on subculture (see Table 16-2). Intermediate and second-strength tuberculin PPD skin testing have been negative in patients tested thus far.<sup>68</sup>

### Course, Treatment, Prognosis, and Prevention

It is possible that some patients may recover with improvement in their immune status; however, improvement has been seen after only a few weeks of isoniazid and rifampin.<sup>68</sup> Other reports record resistance to isoniazid.<sup>13</sup> Although not usually a cause of death, *M haemophilum* infection does produce considerable morbidity before healing spontaneously after months to years. Prognosis and

preventive measures have not been formulated.

### *Mycobacterium malmöense* Disease (Group III, Nonchromogen)

#### Epidemiology

Since the mycobacterium was first isolated in 1977 in Malmö, Sweden, only a few cases of *M malmöense* pulmonary or cervical-nodal infections in children had been reported until 1990, when the first case of cutaneous infection was reported from Ireland.<sup>21</sup> One earlier case report, in 1989, was that of an insulin-dependent diabetic who had a cold abscess of the hand, the infection in which may have been stimulated or possibly introduced when hydrocortisone was injected into a nodule that was assumed to be a ganglion cyst.<sup>69</sup> Most of the previous noncutaneous cases were reported from relatively small areas of Wales, England, and Sweden, and a rare case was reported from both Australia and the United States. Natural sources and possible reservoirs for this organism are not known.

#### Diagnostic Features

A patient with *M malmöense* disease presented with cervical adenitis; 6 months later, the patient developed tender, red, dermal nodules scattered on the extremities and trunk.<sup>21</sup> The differential diagnosis can include any condition manifesting as a tender dermal nodule or as cervical adenitis.

**Histopathology.** Histopathology has shown epithelioid granulomas, a few Langhans'-type giant cells, with caseation necrosis and variable numbers of acid-fast bacilli.<sup>21,69</sup>

**Laboratory Features.** Nonpigmented colonies grow in the dark or light in 2 to 12 weeks, with the shorter times required when pyruvate-containing media are used. Optimum temperatures for colony growth range from 24°C to 37°C, with growth usually in about 3 weeks at 37°C (see Table 16-2). Occasionally, cultures may require up to 12 weeks for growth. Acid-fast stains of colony material reveal coccoid, short, or moderately long acid-fast organisms.

#### Course, Treatment, Prognosis, and Prevention

The true course of this infection is not yet clear. Complete healing of skin lesions has occurred with cycloserine (750 mg/d) and ethambutol (1,200 mg/d) administered for 2 months. After 9 months,



medication was stopped, with the patient remaining free of disease for more than 5 years.<sup>21</sup> Preventive measures are not yet established.

### ***Mycobacterium fortuitum*–*chelonae* Complex Disease (Group IV, Rapid Growers)**

*M fortuitum* is also known as *M ranae*; *M minetti*; *M fortuitum* biovariant *fortuitum*; biovariant *peregrinum*; and third biovariant complex, containing at least three subgroups. *M chelonae* is also known as *M chelonei*, *M friedmannii*, *M abscessus*, *M runyonii*, and *M borstelense*; and as two subspecies: *M chelonae (abscessus)* and *M chelonae (chelonae)*.

#### **Epidemiology**

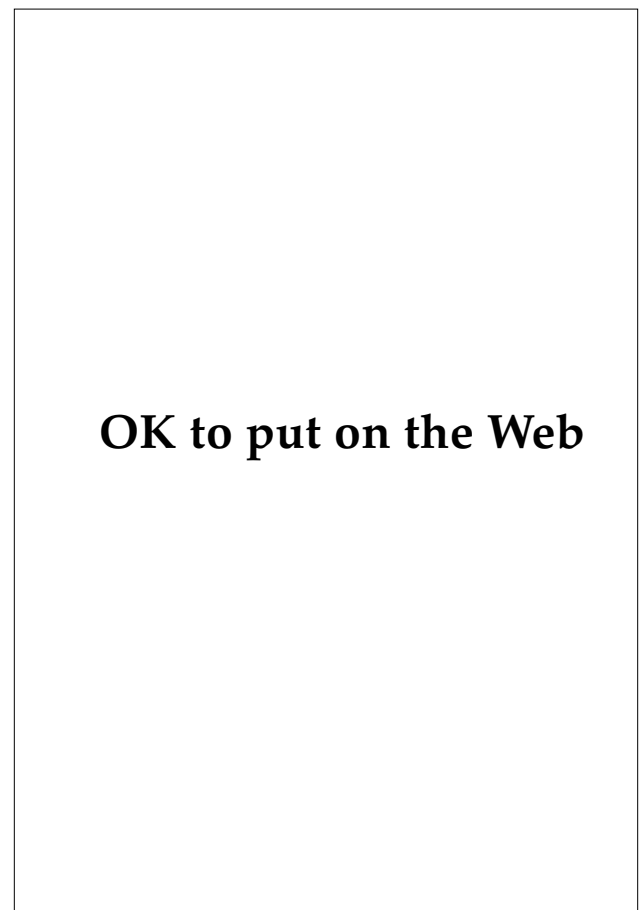First found as a pathogen in frogs in 1905 and named *M ranae* in 1923, *M fortuitum* was rediscovered as a human pathogen and named by da Costa Cruz in 1938.<sup>9</sup> *M chelonae* was isolated by Friedman in 1903 from the lung of a diseased sea turtle (*Chelona corticata*).<sup>30</sup> Although *M fortuitum* (with five subgroups) and *M chelonae* (with two subspecies) are separate species of the genus *Mycobacterium*, their very similar clinical manifestations and culture characteristics allow them to be grouped together for discussion of clinical skin disease. There are subtle differences between the two species in their noncutaneous disease incidence (more than 90% of the lung disease is due to *M chelonae*), in some drug susceptibilities, and in DNA homology.<sup>70</sup> These organisms are distributed worldwide in soil, water supplies, tap water, surgical basins, hemodialysis equipment, hydrotherapy pools, gentian violet solution, and even in laboratory distilled water containers.<sup>30</sup> Some disease has been seen in animals such as rodents and amphibians, but transmission to humans apparently does not occur. Overall incidence in the United States in 1980 was about 0.2/100,000.<sup>27</sup>

#### **Diagnostic Features**

Most *M fortuitum*–*chelonae* complex infections follow trauma or surgery (especially cardiovascular surgery, intravenous catheter placement, and injections) and manifest themselves, about 3 to 4 weeks after the initiating event, as tender, red, indurated areas or as an inflamed or cold abscess, any of which may break down and drain.<sup>29</sup> Occasionally, firm, red-brown, nontender, subcutaneous nodules arise at scattered sites in the skin as a result of dissemination from prior surgery or trauma

sites.<sup>17,71</sup> The infection sometimes does not arise until several months or even years after the causative surgical procedure. Rarely, infection may follow blunt trauma: in one case,<sup>72</sup> infection developed in the hip where, 2 months before, the patient had been kicked by a horse. These organisms may also cause solitary draining cervical lymphadenopathy (Figure 16-11), postoperative endocarditis, osteomyelitis, and chronic pulmonary disease. A sporotrichoid pattern of lymphangitic spread has been seen with *M chelonae* infection (see Figure 16-7).<sup>46</sup>

The differential diagnosis includes all causes of postoperative wound infections and injection ab-



**OK to put on the Web**

**Fig. 16-11.** The solitary draining cervical lymphadenitis was due to *Mycobacterium chelonae* infection in this patient. Other patients may exhibit sporotrichoid patterns of subcutaneous nodules due to lymphatic spread up an extremity, or widespread scattered papulonodules from hematogenous dissemination. Photograph: Courtesy of Captain E. C. Oldfield, Medical Corps, US Navy, Naval Hospital, San Diego, Calif.

sceses. In disseminated disease with bacterial embolization and scattered skin lesions with lymphatic involvement, the differential includes tuberculosis and all metastatic diseases including lymphoma. Sporotrichoid diseases should also be included in the differential (see Exhibit 16-3).

**Histopathology.** Histopathology shows polymorphonuclear cells with granulomatous inflammation, necrosis, giant cells, rare caseation, and, in about one third of the cases, acid-fast bacilli.<sup>13</sup> In addition, the *M fortuitum–chelonae* complex is the one type of mycobacteria that does not stain well with the auramine-rhodamine fluorochrome staining technique.

**Laboratory Features.** Cultures grow in 3 to 5 days on routine culture media and Lowenstein-Jensen medium at 24°C to 37°C without pigment production, in darkness or light (see Table 16-2). Old tuberculin skin testing may be weakly positive.

#### **Course, Treatment, Prognosis, and Prevention**

*M fortuitum–chelonae* complex infections tend to persist, with only a 10% to 20% remission rate for cutaneous infections, and a mortality rate of 10% to 20% with disseminated disease.<sup>30</sup> Fortunately, all localized diseases caused by *M fortuitum–chelonae* complex organisms appear to be responsive to surgical excision, with or without (depending upon the severity and extent of disease) systemic treatment with doxycycline, amikacin, and ciprofloxacin. Some infections that are secondary to wound contamination or injection may be prevented by (a) using only sterile surgical equipment, syringes, and needles and (b) adhering to strict aseptic technique during surgical procedures, especially those procedures involving deep body cavities or prolonged tissue exposure.

#### ***Mycobacterium smegmatis* Disease (Group IV, Rapid Growers)**

##### **Epidemiology**

*M smegmatis* was the second type of mycobacterium to be described following its discovery in syphilitic chancres and gummas in 1884. Later, it was found in chancres and in smegma (normal genital secretions) and was subsequently named *M smegmatis*.<sup>73</sup> This organism has been grown from soil and is known to occur in water and hospital dust.<sup>24</sup> This latter fact may account for the occurrence of some of the first isolations of this organism

from postoperative wound infections, mostly from cardiac bypass surgery, which occurred beginning in 1980. These cutaneous infections were first recognized and reported in 1988.<sup>73</sup> Remarkably, none of the organisms isolated from infections in these reported cases came from the male genital tract or from urine isolates. Distribution of *M smegmatis* is probably worldwide but thus far reports of disease have come only from the United States and Australia. This may be in part due to the failure of laboratories to consider this organism as a pathogen when it is isolated from patient specimens. Disease has been seen in cats as panniculitis (following injury) and in cattle as bovine mastitis.

##### **Diagnostic Features**

Almost always occurring after surgery, trauma, or invasive procedures, *M smegmatis* infections appear as either (a) cellulitis with redness, swelling, pain, tenderness, and heat or (b) draining, red, swollen areas around wounds, from trauma or surgical procedures including placement of intravenous catheters. The differential diagnosis includes any cause of posttraumatic or postoperative wound infection.

**Histopathology.** Histopathology is nonspecific, with the following findings: necrosis; presence of epithelioid cells; a mixed inflammatory infiltrate of giant cells, polymorphonuclear cells, and plasma cells; and variable short, coccoid-to-moderately long acid-fast bacilli.

**Laboratory Features.** Cultures grow best on Middlebrook 7H10 agar, with less growth on Lowenstein-Jensen medium, at 43°C to 45°C and always in less than 7 days. The colonies are buff-colored at 7 days but some develop yellow-orange color after 2 weeks' growth in the dark, with some intensification of the color on exposure to light. A notable characteristic is the ability of this organism to grow on special MacConkey agar without crystal violet. Isolates closely resemble *M fortuitum* in the laboratory because both mycobacteria are rapid growers and have similar-appearing colonies; however, *M smegmatis* is distinguished by a negative 3-day arylsulfatase test, a low semiquantitative catalase test, and colony growth at 45°C (see Table 16-2).<sup>73</sup>

##### **Course, Treatment, Prognosis, and Prevention**

Infections with this organism produce chronic draining wounds and abscesses; however, they are

reported to respond well to combinations of doxycycline, trimethoprim-sulfamethoxazole, ciprofloxacin, and amikacin.<sup>72</sup> Preventive measures

may be aimed at ensuring the adequacy of air filtration and the strict use of only sterile water and its containers in operating rooms.<sup>24</sup>

## ATYPICAL MYCOBACTERIAL INFECTIONS IN ACQUIRED IMMUNODEFICIENCY SYNDROME

Like other opportunistic infections, atypical mycobacterial infections have a much more severe and fulminant course in patients with AIDS than in immunocompetent patients. The most common atypical mycobacterial infection seen in AIDS patients is *M avium-intracellulare* complex disease.<sup>74,75</sup> This may be due to the depression of monocyte and T lymphocyte function in AIDS patients, an important host defense specifically against *M avium-intracellulare* complex and *M tuberculosis*, another increasingly frequent infection in patients with AIDS. In one series,<sup>40</sup> approximately 30% of AIDS patients harbored *M avium-intracellulare* complex while alive, and 52% at autopsy. The researchers also reported that the mere presence of *M avium-intracellulare* complex in urine or respiratory secretions is a sign that dissemination is impending: within 1 to 9 months. Once dissemination occurs, treatment has been unsatisfactory, with poor responses to the usually effective treatment regimens and progression of disease to a uniformly fatal outcome with a mean survival time of about 3 months.<sup>40</sup>

The new macrolides clarithromycin and azithromycin have shown promise in the treatment of disseminated *M avium-intracellulare* complex disease in patients with AIDS.<sup>76</sup> In the treatment of disseminated *M avium-intracellulare* complex disease, clinical trials with high-dose clarithromycin show 98% bacteriological cure initially but with a 25% failure rate by 6 months of treatment.<sup>77</sup> Azithromycin substantially reduced *M avium-intracellulare* complex bacteremia to 7% of the untreated level in 30 days of treatment of 21 patients.<sup>78</sup> In vitro studies<sup>79</sup> of the susceptibility of *M fortuitum-chelonae* to the macrolides clarithromycin, azithromycin, and roxithromycin suggest the clinical usefulness of these agents against atypical mycobacterial infections due to this organism. An

earlier report<sup>80</sup> describes a patient with AIDS who had 25 months free of *M avium-intracellulare* complex disease following multiple drug therapy with amikacin, clofazimine, rifampin, ethambutol, and ciprofloxacin. With this regimen, four other patients had favorable clinical and microbiologic responses for up to 1 year.<sup>80</sup>

Like they do in other immunosuppressed patients (ie, those who have had renal transplants; have been treated with corticosteroids; or who have autoimmune disease, leukemia, or lymphoma), atypical mycobacterial infections have more flagrant manifestations in AIDS patients, with the production of large lesions or extensive involvement. Individual skin lesions may reveal large numbers of acid-fast organisms on biopsy, or even on stained tissue smears of the skin lesion. If a tissue smear reveals acid-fast bacilli, specific mention should be made to suspect *M haemophilum*, a very rare cause of skin infection, and to include hemin- or ferric ammonium citrate-enriched media in culturing for this acid-fast organism.<sup>74</sup>

In addition, atypical mycobacteria that are currently classified as saprophytic may, in the future, become true opportunistic pathogens in the population of patients with AIDS. Vigilance should be exercised to rule out atypical mycobacterial infection if a patient with AIDS develops adenopathy or unusual fulminant skin lesions.

It is apparent that, should a patient manifest fulminant, widespread, or disseminated involvement from any atypical mycobacterial infection, especially *M avium-intracellulare* complex, the physician must suspect an immunocompromised status and pursue the diagnosis. In any patient, in fact, even the presence of an atypical mycobacterial infection should raise some suspicion of transient or early immunosuppression.

## SUMMARY

The varied and diverse group of cutaneous mycobacterial infections arise from a combination of the low innate pathogenicity of the organisms and opportune exposures of the hosts. The

virulence of the particular organism, individual host susceptibility, and the timing and degree of exposure all play crucial roles in the acquisition, progression, and duration of the specific

disease produced. Although they are classified together in the same genus of bacteria, the various atypical mycobacteria have widely varying clinical manifestations, culture characteristics, histologies, and responses to therapy. These very diversities, however, help to define the specific organism involved and the spectrum of disease produced in

immunocompetent and immunocompromised patients.

The incidence of these diseases in the military has been negligible in the past. Medical officers should be aware of them, however, especially as the population of immunocompromised individuals continues to increase.

## REFERENCES

1. Timpe A, Runyon EH. The relationship of "atypical" acid-fast bacteria to human disease. *J Lab Clin Med.* 1954;44:202–209.
2. Runyon EH. Anonymous mycobacteria in pulmonary disease. *Med Clin North Am.* 1959;43:273–290.
3. Hansen GA. Undversogelser angaaende spedalskhedens arsager. *Norsk Mag Laegevid.* 1874;4:1–88.
4. Koch R. Die Ätiologie der tuberculose. *Berliner Klinische Wochenschrift.* 1882;29:221–230.
5. Lunn HF, Connor DH, Wilks NE, et al. Buruli (mycobacterial) ulceration in Uganda (a new focus of Buruli ulcer in Madi District, Uganda). *E Afr Med J.* 1965;42:275. In: Woods GL, Washington JA II. Mycobacteria other than *Mycobacterium tuberculosis*: Review of microbiologic and clinical aspects. *Rev Infect Dis.* Mar-Apr 1987;9(2):285.
6. Wolinsky E. Nontuberculous mycobacteria and associated diseases. *Am Rev Respir Dis.* 1979;119:107–159.
7. Johnston JM, Izumi AK. Cutaneous *Mycobacterium marinum* infection ("swimming pool granuloma"). *Clin Dermatol.* 1987;5(3):68–75.
8. Pinner M. Atypical acid-fast microorganisms: Chromogenic acid-fast bacilli from human beings. *Am Rev Tuberc.* 1935;32:424. In: Wolinsky E. Nontuberculous mycobacteria and associated diseases. *Am Rev of Respir Dis.* 1979;119:108–109.
9. Hendrick SJ, Jorizzo JL, Newton RC. Giant *Mycobacterium fortuitum* abscess associated with systemic lupus erythematosus. *Arch Dermatol.* 1986;122:695–697.
10. Hayman J, McQueen A. The pathology of *Mycobacterium ulcerans* infection. *Pathology.* 1985;17:594–600.
11. Collins CH, Grange JM, Noble WC, Yates MD. *Mycobacterium marinum* infections in man. *J Hyg Camb.* 1985;94:135–149.
12. Hanke CW, Temofeew RK, Slama SL. *Mycobacterium kansasii* infection with multiple cutaneous lesions. *J Am Acad Dermatol.* May 1987;16(5, Part 2):1122–1128.
13. Woods GL, Washington JA II. Mycobacteria other than *Mycobacterium tuberculosis*: Review of microbiologic and clinical aspects. *Rev Infect Dis.* Mar-Apr 1987;9(2):275–294.
14. Curry FJ. Atypical acid-fast mycobacteria. *N Engl J Med.* 1965;272(8):415–417.
15. Kelly PJ, Weed LA, Lipscomb PR. Infection of tendon sheaths, bursae, joints, and soft tissue by acid-fast bacilli other than tubercle bacilli. *J Bone Joint Surg.* March 1963;45A(2):327–336.
16. Mayberry JD, Mullins JF, Stone OJ. Cutaneous infection due to *Mycobacterium kansasii*. *JAMA.* 1965;194(10):233–235.
17. Hand WL, Sanford JP. *Mycobacterium fortuitum*—a human pathogen. *Ann Intern Med.* 1970;73:971–977.

18. Wayne LG. The "atypical" mycobacteria: Recognition and disease association. *CRC Crit Rev Microbiol.* 1985;12(3):185–222.
19. Taylor LQ, Williams AJ, Santiago S. Pulmonary disease caused by *Mycobacterium asiaticum*. *Tubercle.* 1990;71:303–305.
20. Hayman J. Clinical features of *Mycobacterium ulcerans* infection. *Australas J Dermatol.* 1985;26:67–73.
21. Gannon M, Otridge B, Hone R, Dervan P, O'Loughlin S. Cutaneous *Mycobacterium malmöense* infection in an immunocompromised patient. *Int J Dermatol.* March 1990;29(2):149–150.
22. Wallace RJ Jr, O'Brien R, Glassroth J, Raleigh J, Dutt A. Diagnosis and treatment of disease caused by nontuberculous mycobacteria. *Am Rev Respir Dis.* 1990;142:940–953.
23. Ikawa H, Kaneda K, Goto K, et al. Rapid and precise diagnosis of atypical mycobacterial infection by chemotaxonomical and immunological methods. *Acta Leprol.* 1989;7(Suppl. 1):85–88.
24. Wallace RJ Jr, Musser JM, Hull SI, et al. Diversity and sources of rapidly growing mycobacteria associated with infections following cardiac surgery. *J Infect Dis.* 1989;159(4):708–716.
25. Allen, AM. *Skin Diseases in Vietnam, 1965–1972.* Vol 1. In: Ognibene AJ, ed. *Internal Medicine in Vietnam.* Washington, DC: US Army Medical Department, Office of The Surgeon General, and Center of Military History; 1977.
26. Herndon JH, Dantzker DR, LaNoue AM. *Mycobacterium fortuitum* infections involving extremities. *J Bone Joint Surg.* September 1972;54-A(6):1279–1282.
27. Good RC, Snider DE. Isolation of nontuberculous mycobacteria in the United States, 1980. *J Infect Dis.* From the Centers for Disease Control. 1982;146(6):829–833.
28. McIntyre P, Blacklock Z, McCormack JG. Cutaneous infection with *Mycobacterium gordonae*. *J Infect.* 1987;14:71–78.
29. Wolff K, Tappeiner G. Mycobacterial diseases: Tuberculosis and atypical mycobacterial infections. In: Fitzpatrick TB, Eisen AZ, Wolff K, Freedberg IM, Austen KF, eds. *Dermatology in General Medicine.* Vol 2, 3rd ed. New York: McGraw-Hill Book Company; 1987: 2152–2180.
30. Miller AC, Commens CA, Jaworski R, Packham D. The turtle's revenge: A case of soft-tissue *Mycobacterium chelonae* infection. *Med J Aust.* 1990;153:493–495.
31. Hosty TS, McCurmont CI. Isolation of acid-fast organisms from milk and oysters. *Health Lab Sci.* 1975;12(1):16–19.
32. Wheeler AP, Graham BS. Saturday conference: Atypical mycobacterial infections. *South Med J.* 1989;82(10): 1250–1258.
33. Smith DT. Diagnostic and prognostic significance of quantitative tuberculin tests. The influence of subclinical infections with atypical mycobacteria. *Ann Intern Med.* 1967;67(5):919–946.
34. Edwards LB. Current status of the tuberculin test. *Ann NY Acad Sci.* 1963;106:32–42.
35. Palmer CE, Edwards LB. Sensitivity to mycobacterial PPD antigens with some laboratory evidence of its significance. *Tuberkuloza.* 1966;18:193–200.
36. Margileth AM. Management of nontuberculous (atypical) mycobacterial infections in children and adolescents. *Pediatr Infect Dis.* 1985;4(2):119–121.
37. Lindberg MC, Thomas GG. Lymphadenitis due to atypical mycobacteria. *Ala Med.* 1989;59(5):19–21.
38. Beyt BE Jr, Ortbals DW, Santa Cruz DJ, Kobayashi GS, Eisen AZ, Medoff G. Mycobacteriosis: Analysis of 34 cases with a new classification of the disease. *Medicine.* 1981;60(2):95–109.

39. Savin JA, Wilkinson DS. Mycobacterial infections including tuberculosis. In: Rook A, Wilkinson DS, Ebling FJG, Champion RH, Burton JL, eds. *Textbook of Dermatology*. Vol 1, 4th ed. Boston, Mass: Blackwell Scientific Publications; 1986: 791–822.
40. Polsky B, Gold WM. The acquired immune deficiency syndrome. *Surg Annu*. 1986;18:279–295.
41. O'Brien RJ, Geiter LJ, Snider DE Jr. The epidemiology of nontuberculous mycobacterial diseases in the United States. Results from a national survey. *Am Rev Respir Dis*. 1987;135:1007–1014.
42. King AJ, Fairley JA, Rasmussen JE. Disseminated cutaneous *Mycobacterium marinum* infection. *Arch Dermatol*. March 1983;119:268–270.
43. Loria PR. Minocycline hydrochloride treatment for atypical acid-fast infection. *Arch Dermatol*. 1976;112:517–519.
44. Feldman RA. *Mycobacterium marinum*: A leisure time pathogen. *J Infect D*. 1974;129:618–621.
45. Walker HH, Shinn MF, Higakim OJ. Some characteristics of “swimming pool” disease in Hawaii. *Hawaii Med J*. 1962;21(5):403–409.
46. Glickman FS. Sporotrichoid mycobacterial infections. *J Am Acad Dermatol*. 1983;8:703–707.
47. Bruckner-Tuderman L, Blank AA. Unusual cutaneous dissemination of a tropical fish tank granuloma. *Cutis*. 1985;36(5):405–406, 408.
48. Enzenauer RJ, McKoy J, Vincent D, Gates R. Disseminated cutaneous and synovial *Mycobacterium marinum* infection in a patient with systemic lupus erythematosus. *South Med J*. 1990;83(4):471–474.
49. Hoyt RE, Bryant JE, Glessner SF, et al. *M. marinum* infections in a Chesapeake Bay community. *Va Med*. November 1989;467–470.
50. Negroni R. Cutaneous atypical mycobacterioses. In: *Proceedings of the 17th World Congress of Dermatology, Berlin, Germany*. In: Orfanos CE, Stadler R, Gollnick H. *Dermatology in Five Continents*. Berlin, Germany: Springer-Verlag; 1987: 1095–1100.
51. Hirsh FS, Saffold OE. *Mycobacterium kansasii* infection with dermatologic manifestations. *Arch Dermatol*. 1976;112:706–708.
52. Dore N, Collins J-P, Mankiewicz E. A sporotrichoid-like *Mycobacterium kansasii* infection of the skin treated with minocycline hydrochloride. *Br J Dermatol*. 1979;101:75–79.
53. Cross GM, Guill MA, Aton JK. Cutaneous *Mycobacterium szulgai* infection. *Arch Dermatol*. February 1985;121:247–249.
54. Cookson BD, Dunger D. *Mycobacterium szulgai*—A case of cutaneous infection? *Tubercule*. 1985;66:65–67.
55. Noel SB, Ray MC, Greer DL. Cutaneous infection with *Mycobacterium avium-intracellulare scrofulaceum* intermediate: A new pathogenic entity. *J Am Acad Dermatol*. 1988;19:492–495.
56. Moschella, SL. Diseases of the mononuclear phagocytic system (the so-called reticuloendothelial system). In: Moschella SL, Hurley HJ, eds. *Dermatology*. Vol 1, 2nd ed. Philadelphia, Pa: WB Saunders Company; 1985: 890–999.
57. Schaad UB, Votteler TP, McCracken GH, Nelson JD. Management of atypical mycobacterial lymphadenitis in childhood: A review based on 380 cases. *J Pediatr*. 1979;95:356–360.
58. Murray-Leisure KA, Egan N, Weitekamp MR. Skin lesions caused by *Mycobacterium scrofulaceum*. *Arch Dermatol*. 1987;123:369–370.

59. Gonzales EP, Crosby RM, Walker SH. *Mycobacterium aquae* infection in a hydrocephalic child (*Mycobacterium aquae* meningitis). *Pediatrics*. 1971;48:974–977.
60. Shelley WB, Folkens AT. *Mycobacterium gordonae* infection of the hand. *Arch Dermatol*. 1984;120:1064–1065.
61. Gengoux P, Portaels F, Lachapelle JM, Minnikin DE, Tennstedt D, Tamigneau P. Skin granulomas due to *Mycobacterium gordonae*. *Int J Dermatol*. April 1987;26(3):181–184.
62. Street ML, Umbert-Millet IJ, Roberts GD, Su DW-P. Nontuberculous mycobacterial infection of the skin. *J Am Acad Dermatol*. 1991;24(2) Part 1:208–215.
63. Hayman J. *Mycobacterium ulcerans* infection in Victoria: Celebration of a Golden Jubilee? *Australas J Dermatol*. 1987;28:99–105.
64. Igo JD, Murthy DP. *Mycobacterium ulcerans* infections in Papua New Guinea: Correlation of clinical, histological, and microbiological features. *Am J Trop Med Hyg*. 1988;38(2):391–392.
65. Van der Werf TS, Van der Graaf WTA. Buruli ulcer in West Africa. *Lancet*. December 8, 1990;1440.
66. Burchard GD, Bierther M. Buruli ulcer: Clinical pathological study of 23 patients in Lambaréné, Gabon. *Trop Med Parasitol*. 1986;37:1–8.
67. Meyers WM. Atypical mycobacterial skin infections. In: Strickland GT, ed. *Hunter's Tropical Medicine*. 7th ed. Philadelphia, Pa: WB Saunders; 1991: 495–500.
68. Davis BR, Brumbach J, Sanders WJ, Wolinsky, E. Skin lesions caused by *Mycobacterium haemophilum*. *Ann Intern Med*. 1982;97(5):723–724.
69. Elston RA. Missed diagnosis of mycobacterial infection. *Lancet*. May 20, 1989;1144.
70. Wallace RJ Jr. Recent clinical advances in knowledge of the nonleprous environmental mycobacteria responsible for cutaneous disease. *Arch Dermatol*. March 1987;123:337–339.
71. Fonseca E, Alzate C, Cañedo T, Contreras F. Nodular lesions in disseminated *Mycobacterium fortuitum* infection. *Arch Dermatol*. 1987;123:1603–1604.
72. Rappaport W, Dunington G, Norton L, Ladin D, Peterson E, Ballard J. The surgical management of atypical mycobacterial soft-tissue infections. *Surgery*. 1990;108:36–39.
73. Wallace RJ Jr, Nash DR, Tsukamura M, Blacklock ZM, Silcox VA. Human disease due to *Mycobacterium smegmatis*. *J Infect Dis*. 1988;158(1):52–59.
74. Rogers PL, Walker RE, Lane HC, et al. Disseminated *Mycobacterium haemophilum* infection in two patients with the acquired immunodeficiency syndrome. *Am J Med*. 1988;84(3, Part 2):640–642.
75. Snider DE, Hopewell PC, Mills J, Reichman LB. Mycobacterioses and the acquired immunodeficiency syndrome. *Am Rev Respir Dis*. 1987;136:492–496.
76. Kanatani MS, Guglielma BJ. The new macrolides—Azithromycin and clarithromycin. *West J Med*. 1994;160:31–37.
77. Dautzenberg B, Saint Marc T, Meyohas M, et al. Clarithromycin and other antimicrobial agents in the treatment of disseminated *Mycobacterium avium* infection in patients with acquired immunodeficiency syndrome. *Arch Intern Med*. 1993;153:368–372.
78. Young LS, Wivott L, Kolonosk P, Bolan R, Inderlies CB. Azithromycin for treatment of *Mycobacterium avium-intracellulare* complex infection in patients with AIDS. *Lancet*. 1991;338:1107–1109.

79. Brown BA, Wallace JR Jr, Orgi GO, et al. Activities of four macrolides, including clarithromycin, against *Mycobacterium fortuitum*, *Mycobacterium chelonae*, and *M chelonae*-like organisms. *Antimicrob Agents Chemother.* 1992;36:180-184.
80. Benson CA, Kessler HA, Pottage JC Jr, Trenholme GM. Successful treatment of acquired immunodeficiency syndrome-related *Mycobacterium avium* complex disease with a multiple drug regimen including amikacin. *Arch Intern Med.* 1991;151:582-585.

The authors acknowledge the technical advice of Deanne Harley in the preparation of the bacteriology section on atypical mycobacteria.



# Chapter 17

## SUPERFICIAL FUNGAL SKIN DISEASES

JAMES E. FITZPATRICK, M.D.\*

---

INTRODUCTION

MILITARY HISTORY AND EPIDEMIOLOGY

DERMATOPHYTOSIS

Clinical Features

Diagnosis

Treatment

CANDIDOSIS

Clinical Features

Diagnosis

Treatment

PITYROSPORUM INFECTIONS

Clinical Features

Diagnosis

Treatment

MISCELLANEOUS FUNGAL INFECTIONS

SUMMARY

\*Colonel, Medical Corps, U.S. Army; Chief, Dermatology Service, Fitzsimons Army Medical Center, Aurora, Colorado 80045-5001

## INTRODUCTION

In years past, *fungi* (including molds) were classified as a subdivision of the plant kingdom. Taxonomists have recently acknowledged that fungi lack important features of plants (eg, chlorophyll and differentiation into roots, stems, and leaves) and therefore merit inclusion in the new kingdom, Mycota. This large and diverse kingdom comprises more than 100,000 recognized species. Of this large group, only about 300 species have been identified as human pathogens; however, more than three fourths of these pathogens infect primarily the skin or subcutaneous tissues.

Fungi can be characterized as aerobic, heterophilic (ie, they require exogenous carbon sources), eukaryotic (ie, the nucleus is organized, with associated subcellular structures), achlorophyllous organisms that reproduce by sexual or asexual or both means. Their size and form are highly variable: they can be unicellular and microscopic (eg, yeast) or multicellular and large (eg, mushrooms). The cellular membranes of fungi contain ergosterol and zymosterol, in contrast to mammalian cellular membranes, which possess cholesterol as their primary sterol. This is an important distinction because many of the drugs used to treat fungi (eg, imidazoles and allylamines) primarily inhibit ergosterol synthesis, and thus minimally affect the human host.

Fungal infections can be divided into four broad groups: superficial, localized subcutaneous, systemic, and opportunistic. The superficial fungal infections, which are the subject of this chapter, include those that attack the epidermis, mucosa, nails, and hair. While *dermatophytes* are the most common cause of superficial infections of the skin and its appendages, many *nondermatophytes* can also produce superficial infections (Exhibit 17-1). By convention, dermatophytes are defined as fungi that can utilize keratin as a substrate for growth, while nondermatophytes use other substrates (eg,

### EXHIBIT 17-1

#### FUNGI CAUSING SUPERFICIAL CUTANEOUS INFECTIONS

##### Dermatophytes

*Epidermophyton floccosum*

*Microsporum* species

*Trichophyton* species

##### Nondermatophytes

*Candida* species

*Pityrosporum orbiculare* (*Malassezia furfur*)

*Exophiala werneckii*

*Piedraia hortae*

*Trichosporon beigellii*

*Hendersonula toruloidea*

*Scopulariopsis brevicaulis*

lipids).<sup>1</sup> This distinction is somewhat artificial, however, as the nutritional requirements have not been clearly established for all species.

Superficial fungal infections are most commonly acquired from other humans (the anthropophilic species) but may also be acquired from soil (the geophilic species) and animals (the zoophilic species). This point is important for medical officers to remember because soldiers in combat are more likely to be exposed to and become infected with fungi that inhabit the soil and infest wild animals.

Although most superficial fungal diseases are trivial, when they infect military personnel the morbidity associated with these infections and their potential effects on military campaigns cannot be overemphasized.<sup>1</sup>

## MILITARY HISTORY AND EPIDEMIOLOGY

Historically, superficial fungal infections have produced minimal disease in temperate climates such as seen in European theaters of combat. The most severe outbreaks are generally associated with tropical climates and exposure to new strains of fungi.

The medical report on skin diseases encountered

during World War I in the British Royal Army states that only 25 of 8,313 (0.3%) cases admitted to a single general hospital for skin diseases over an 8-mo period were for "ringworm."<sup>2</sup> This figure is surprisingly low and invites speculation that some cases might have been misdiagnosed as inflammatory skin conditions.

The U.S. Army Medical Department's official history of medicine during World War II<sup>3</sup> reported data for the continental United States as well as for different combat theaters. For example, only 6% of soldiers seen for skin disease at Fort Lee, Virginia, were seen for superficial fungal infections. As might be expected, the incidence of these infections was not strikingly different for the European theater of operations, but warmer climates were associated with higher attack rates. Of combat soldiers seen for skin disease in the Mediterranean theater, up to 22% had diseases that were attributable to dermatophytic infections. As expected, rear-echelon troops experienced a much lower rate of infection. In a study of the British Royal Army in Southeast Asia, investigators methodically examined the skin of both European and Southeast Asian troops stationed in the Far East. They noted that 34% of European soldiers had a tinea infection, while only 7% of the Southeast Asian troops had similar infections.<sup>4</sup> Besides the high attack rate, the European soldiers demonstrated widely disseminated or "florid" disease when compared to the types of dermatophytic infections normally seen in the United Kingdom.

The Vietnam conflict provides the best data on the impact of superficial fungal infections on military operations in a tropical climate. Skin diseases were the most common cause of outpatient visits during the war, accounting for 12.2% of visits, and superficial fungal infections were the most common skin disease. In one dermatology clinic, superficial fungal infections accounted for 12.3% of visits; the most common types were dermatophytosis, pityriasis versicolor, and candidosis.<sup>5</sup> The effect on combat troops in the forward areas was even more dramatic: of 142 soldiers in the Mekong Delta who

were studied as they came in for their noonday meals, 86 had "significant" dermatophytosis—an incidence of 65%.<sup>6</sup> Lieutenant Colonel Alfred M. Allen, in his seminal book on the skin diseases seen during the Vietnam conflict, states:

Superficial fungal infections were the most common and troublesome of all the dermatologic conditions that occurred among U.S. forces in Vietnam. Hardly anyone escaped some form of mycotic skin infection during his tour of duty in Vietnam, and a large majority of ground combat troops in wet, lowland areas developed extensive inflammatory lesions that led to high rates of disability.<sup>5(p59)</sup>

Although most superficial fungal infections merely produced discomfort and large numbers of outpatient visits, significant numbers of soldiers were hospitalized for dermatophytosis or its secondary complications. During a 1-year period, the 17th Field Hospital in Saigon reported 25 admissions related to dermatophytosis; this accounted for 7% of all admissions for skin conditions. Most cases were successfully managed in Vietnam; even so, dermatophytosis caused 127 soldiers to be medically evacuated to the continental United States from 1965 to 1970.<sup>5</sup>

Accurate figures regarding the current incidence of superficial cutaneous fungal infections in soldiers stationed in the Zone of Interior during peacetime are not available. They would be expected to parallel those of the civilian population when corrected for age, sex, and geographical location. In the best study done to date, investigators examined and cultured 152 healthy air force recruits in Texas and demonstrated that 12.5% were infected with dermatophytes. In general, the degree of infection was not as severe as that were seen in Vietnam.<sup>7</sup>

## DERMATOPHYTOSIS

Dermatophytic infections can be organized and studied either according to their etiology (Exhibit 17-2) or their clinical presentation (Table 17-1). Because the etiology is usually important only in epidemiological studies, this chapter is organized by clinical presentation. The field of dermatology has, unfortunately, used different Latin names to designate infections by the clinical appearance and site of involvement. The plethora of terms produced is confusing to patients and physicians alike, but the names are too ingrained in the medical literature to change.

### Clinical Features

The clinical presentation of dermatophyte infections depends on several factors including the site of infection, the species of fungus, and the host's response. Because dermatophytes utilize keratin for a substrate, they infect areas of the body with abundant keratin such as the stratum corneum of the skin, hair, and nails. With rare exceptions, dermatophytes are confined to tissue with keratin and will not invade living tissue. Some species have an affinity for the keratin of hair follicles (eg,

**EXHIBIT 17-2**

**IMPORTANT DERMATOPHYTOSIS-PRODUCING SPECIES**

**Genus *Epidermophyton***

*E floccosum*

**Genus *Microsporum***

*M audouinii*

*M canis*

*M ferrugineum*

*M gypseum*

*M nanum*

**Genus *Trichophyton***

*T concentricum*

*T mentagrophytes*

*T rubrum*

*T schoenleinii*

*T tonsurans*

*T verrucosum*

*Trichophyton tonsurans*), while other species have an affinity for the keratin of skin and nails (eg, *Trichophyton rubrum*). This explains the frequent limitation of infections to one site.

The host's response to infection is an important determinant of the clinical presentation. Patients with intense host responses to fungal infections produce inflammatory lesions that may be erythematous or even vesiculobullous, while hosts who have muted responses will produce scaly lesions with minimal scaling.

***Tinea Capitis***

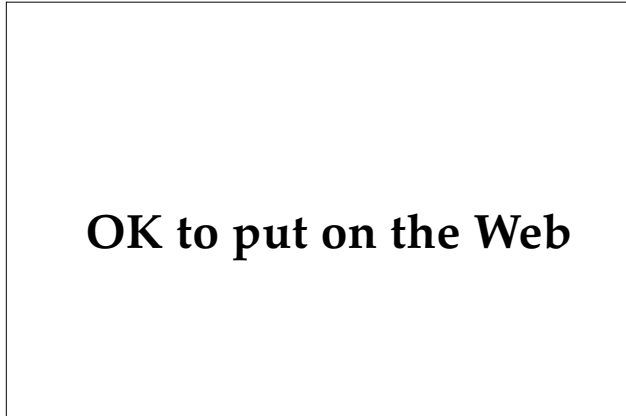
*Tinea capitis* is primarily a disease of children, with the peak incidence occurring between the ages of 2 and 9 years. In one large study done in Chicago, 95% of culture-proven patients were under 15 years of age.<sup>8</sup> However, no age group is exempt: patients as old as 64 years were included in this study. Recent evidence<sup>9</sup> suggests that an asymptomatic carrier state may be more common in adults than previously appreciated. *Tinea capitis* is an uncommon problem in servicemen even under wartime conditions, but military physicians frequently diagnose and treat this condition in dependent children.

The most common organisms producing *tinea capitis* vary in different geographical regions. In the United States, the most common organisms are the fungi *Trichophyton tonsurans* followed by *Microsporum canis*. Prior to World War II, *Microsporum audouinii* was the most common cause of *tinea capitis*, but this fungus has almost disappeared in the United States. (The author has seen only one case of *tinea capitis* produced by this organism during the last 15 y.) *Trichophyton tonsurans* and *Microsporum audouinii* are anthropophilic fungi that are transmitted directly or indirectly from person to person; *Microsporum canis* is a zoophilic organism that is often acquired from dogs or cats.

The clinical presentation of *tinea capitis* may broadly be divided into noninflammatory and inflammatory states; the latter is slightly more common. In the most common noninflammatory pattern, patients present with patchy, white scales that may resemble seborrheic dermatitis (Figure 17-1). As a rule, a diagnosis of "seborrheic dermatitis" in a prepubescent child is *tinea capitis* until proven otherwise. Close examination will often reveal the characteristic hairs broken just above the level of the skin. Occasional patients also may demonstrate dermatophytic infection of other cutaneous sites. In other patients, broken hairs may predominate, producing diffuse or patchy alopecia that may resemble alopecia areata. Occasional patients may present with "black-dot ringworm," in which areas of alopecia demonstrate numerous broken, black,

**TABLE 17-1**  
**CLINICAL PRESENTATIONS OF DERMATOPHYTOSES**

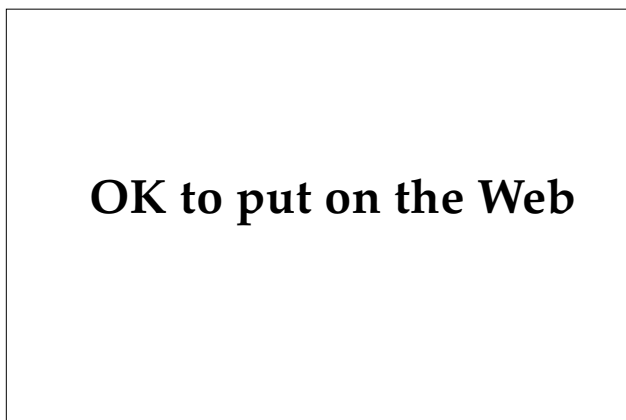Infection	Clinical Site
<i>Tinea capitis</i>	Scalp
<i>Tinea favosa</i>	Scalp
Kerion	Scalp, hair
Majocchi granuloma	Hair
<i>Tinea faciei</i>	Face
<i>Tinea barbae</i>	Beard
<i>Tinea corporis</i>	Glabrous skin
<i>Tinea cruris</i>	Groin
<i>Tinea manuum</i> (manus)	Hand
<i>Tinea pedis</i>	Feet
<i>Tinea unguium</i>	Nails



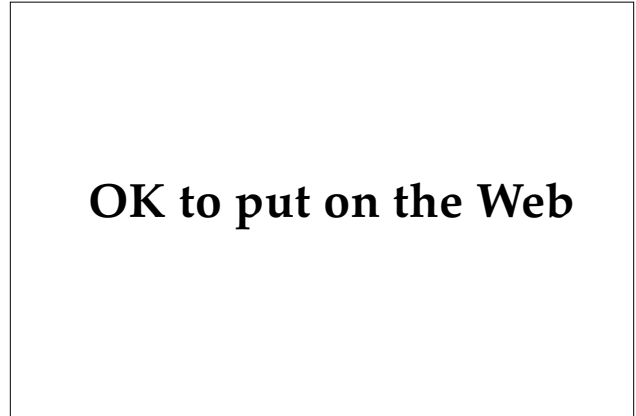
**Fig. 17-1.** A child presented with tinea capitis due to *Microsporum audouinii*, which manifested as diffuse scaling with occasional broken hairs. The child acquired the infection while the family was stationed in Turkey.

hair shafts that resemble comedones (Figure 17-2). In the United States, this pattern is almost pathognomonic of *Trichophyton tonsurans* infection, although in other geographical areas, *Trichophyton violaceum* also may produce a similar pattern.

Inflammatory tinea capitis is due to a heightened host cell-mediated immune response, virulent strains, or a combination of these two factors. Milder cases present as acute folliculitis with minimal induration of the surrounding tissues, while severe cases present as inflammatory, indurated plaques containing perifollicular abscesses (Figure 17-3). This last pattern is termed a *kerion*. Clinically, it may be confused with bacterial pyoderma, and it is



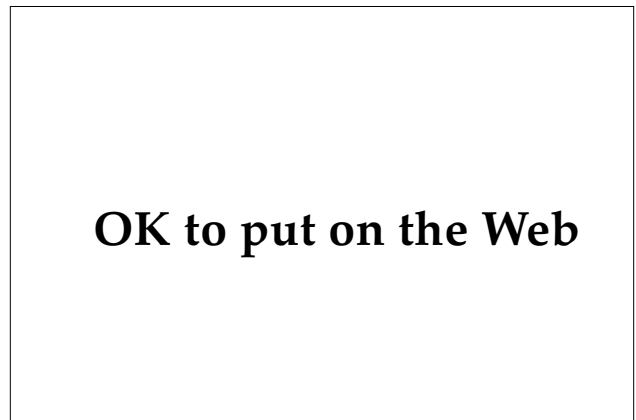**Fig. 17-2.** Alopecia and numerous broken hairs (black-dot ringworm) characteristic of infection with *Trichophyton tonsurans*.



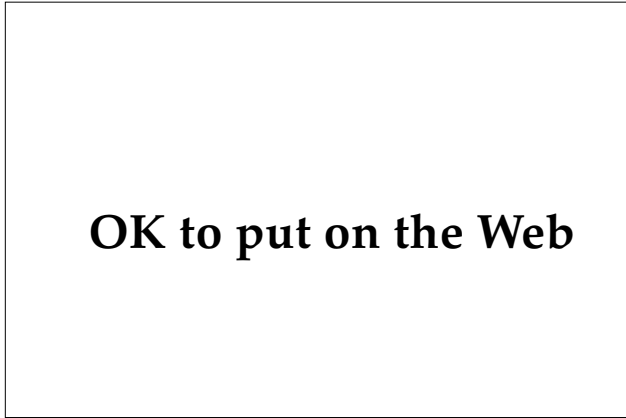
**Fig. 17-3.** Alopecia and scalp abscesses typical of kerion. Clinicians can easily confuse these with bacterial abscesses.

not unusual for patients to be initially treated with oral antibiotics directed against *Staphylococcus aureus*, as secondary impetigo is common (Figure 17-4). Lymphadenopathy, particularly of the posterior cervical triangle, is frequently present and may further suggest bacterial infection. While most patients do not demonstrate systemic symptoms, severe kerions may be associated with high fevers and malaise.

Tinea favosa (also called tinea favus) is a rare variant of tinea capitis produced by *T schoenleinii*. This variant is rare in North America, although small outbreaks have been reported in Quebec and Kentucky.<sup>10</sup> Clinically, tinea favosa is characterized



**Fig. 17-4.** Kerion with secondary bacterial infection on the scalp of this young patient. The thick crust and edema are characteristic.



**Fig. 17-5.** Deep, follicular pustules of tinea barbae. These lesions result from inflammation at the site of the organism : the follicular epithelium.

by an inflammatory alopecia demonstrating cup-shaped, honey-colored crusts called *scutula*, which are composed of masses of hyphae and serum.

Tinea capitis is a benign disease if quickly diagnosed and properly treated. Patients with noninflammatory forms and folliculitis will not demonstrate significant permanent hair loss. In patients with the kerion pattern of infection, however, approximately 50% will eventually recover normal hair density, approximately 25% will demonstrate focal hair loss that is cosmetically acceptable, and approximately 25% will demonstrate cosmetically significant permanent hair loss.

### **Tinea Barbae**

Tinea barbae is the term reserved for fungal infection of the bearded areas of the face and is thus limited to postpubertal males. Most patients with tinea barbae are from rural areas and acquire it from close contact with animals such as horses or cows. The most common organisms are zoophilic strains of *T mentagrophytes* or *T verrucosum*. In years past, it was called "barber's itch" because the disease was commonly acquired from infected hair-cutting instruments used in barber shops. Tinea barbae was not unusual during the Vietnam conflict, but it posed considerable diagnostic and management problems for physicians because it was frequently misdiagnosed as abscesses, granulomas, or allergic contact dermatitis. Attempts at treatment by surgical drainage resulted in excessive scarring.

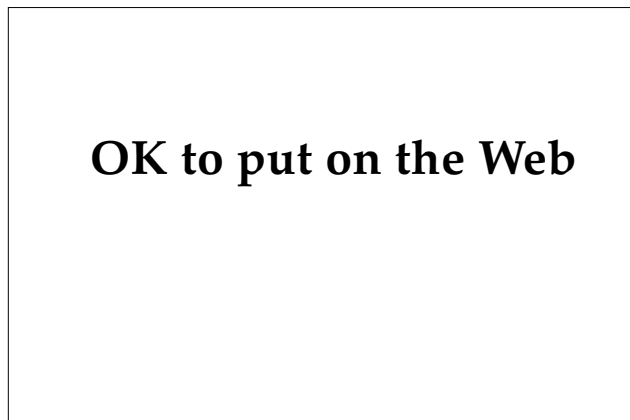Patients with tinea barbae present with severe, deep, pustular folliculitis of the beard area (Figure

17-5). It is typically unilateral. Large, indurated plaques resembling kerion may be present in the most severe cases. As is true with kerions, the inflammatory and pustular nature of this condition frequently suggests a bacterial etiology and early misdiagnoses are common.

### **Tinea Corporis**

Tinea corporis was a major problem for U.S. troops during the Vietnam conflict, particularly those assigned to combat units exposed to wet terrain. In the United States, the most common organism recovered is *T rubrum*; however, during the Vietnam conflict, the most common isolated species recovered from lesions of tinea corporis and tinea cruris was a zoophilic strain of *T mentagrophytes* that accounted for 73% of fungal infections in combat servicemen.<sup>11</sup> Epidemiological studies demonstrated that the most likely source was native rats. Interestingly, native Vietnamese troops and civilians were not recorded as having infections with this strain. The predominant organism identified from native Vietnamese was *T rubrum*. These data suggest that the American troops had not previously been exposed to this strain, and were thus immunologically susceptible to severe infections, while the native Vietnamese had developed immunity. This situation could recur in future conflicts.

In domestic anthropophilic infections, the sites of predilection are the neck, trunk, and buttocks, although any site may be involved. Most patients complain of pruritus although occasional patients are asymptomatic. The primary lesion is an annu-



**Fig. 17-6.** Primary lesion of tinea corporis demonstrating annular morphology and trailing scale.

## OK to put on the Web

**Fig. 17-7.** Extensive tinea corporis in an infantry soldier acquired at Fort Benning, Georgia.

lar, sharply circumscribed, erythematous ring with variable white scale that is most pronounced at the trailing edge of the expanding ring (Figure 17-6). The areas within the centers of the annular lesions demonstrate variable clearing with some lesions demonstrating residual scale, hypopigmentation, or hyperpigmentation. Less commonly, multiple consecutive rings produce a lesion that resembles a target. The numbers and sizes of the lesions are variable; some patients may demonstrate extensive involvement (Figure 17-7). Zoophilic strains acquired during combat in Vietnam showed a predilection for areas covered by wet clothing that could not be easily removed during combat, especially the buttocks and waist. Zoophilic strains tend to produce more-inflamed lesions and frequently show follicular involvement and secondary bacterial infections.

***Tinea Faciei.*** *Tinea faciei* is a regional variant of tinea corporis that involves the face but does not affect the beard. Clinically, the primary lesions are often circinate and well defined, as they are in other forms of tinea corporis, but ill-defined erythematous lesions with indistinct borders is a clinical variant

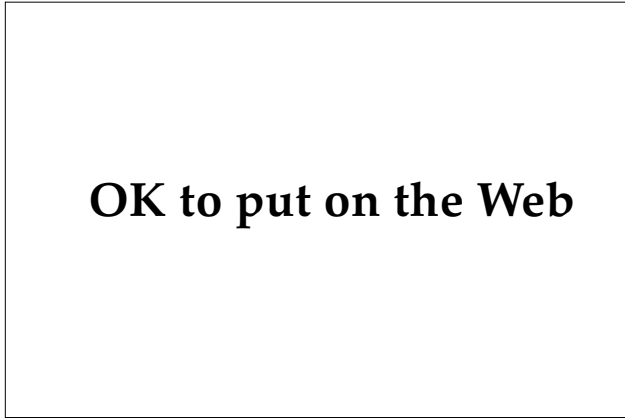
(*tinea incognito*) that seems to occur with great frequency.

***Majocchi Granuloma.*** Majocchi granuloma is a variant of tinea corporis that is clinically similar to kerion of the scalp. The most common organisms are *T rubrum* and *T mentagrophytes*. The most common location is the leg, followed by the arm. Clinically, patients present with boggy, indurated papules and plaques that may drain purulent material through the follicular orifices (Figure 17-8). More-typical annular lesions suggesting the correct diagnoses may or may not be present.<sup>12</sup> The patients may demonstrate systemic symptoms and fever suggesting a systemic infection. From a histological standpoint, the name is a misnomer because the primary histological process is that of follicular neutrophilic abscesses, although variable granulomatous inflammation is present in mature lesions.

***Tinea Imbricata.*** *Tinea imbricata* is a variant seen in the South Pacific and some regions of South America. The etiologic agent is *T concentricum*. This

## OK to put on the Web

**Fig. 17-8.** This patient's extensive Majocchi granuloma was acquired in the Panama Canal Zone. The patient had fever and malaise and required hospitalization for diagnosis and treatment.



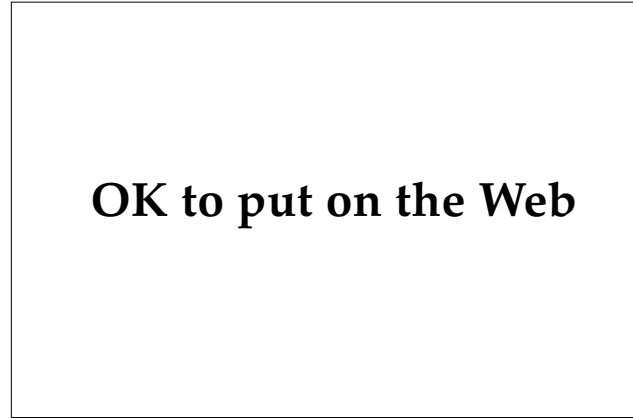**Fig. 17-9.** Chronic tinea cruris demonstrating characteristic annular border.

form of infection is generally restricted to native populations and it has not been a significant problem even when American soldiers have operated in endemic areas. Clinically, it is characterized by extensive concentric rings of scale that involve extensive areas of the body and produce a “geographical” pattern that resembles the relief scale of a map.

### **Tinea Cruris**

Tinea cruris (ie, jock itch) is almost exclusively limited to men, although women may, rarely, demonstrate a transient infection. This is probably the most common superficial fungal infection seen in young men. During the Vietnam conflict, it was the single most common dermatophytic infection: 33% of all U.S. combat troops developed tinea cruris.<sup>11</sup> In domestic infections, the most common causative organisms are *T rubrum*, *T mentagrophytes*, and *E floccosum*. *Epidermophyton floccosum* is highly infectious and has a high attack rate when men are housed together in military barracks, penal institutions, or dormitories, or on athletic teams. In a study of Colombian soldiers, investigators reported that *E floccosum* accounted for 82% and 78% of cases of tinea cruris in two separate groups of soldiers.<sup>13</sup> During the Vietnam conflict, the most common organisms were zoophilic strains of *T mentagrophytes*, followed by *E floccosum*.<sup>11</sup> In addition to heat and humidity, the wearing of tight briefs appears to be a predisposing factor in acquiring and maintaining tinea cruris.

Clinically, the disease may be unilateral or bilateral. Tinea cruris is often highly pruritic, and severe cases may produce pain (due to friction) on ambulation. The lesions typically start in a crural



**Fig. 17-10.** Scaly, noninflammatory tinea pedis with concentric rings radiating from interdigital space.

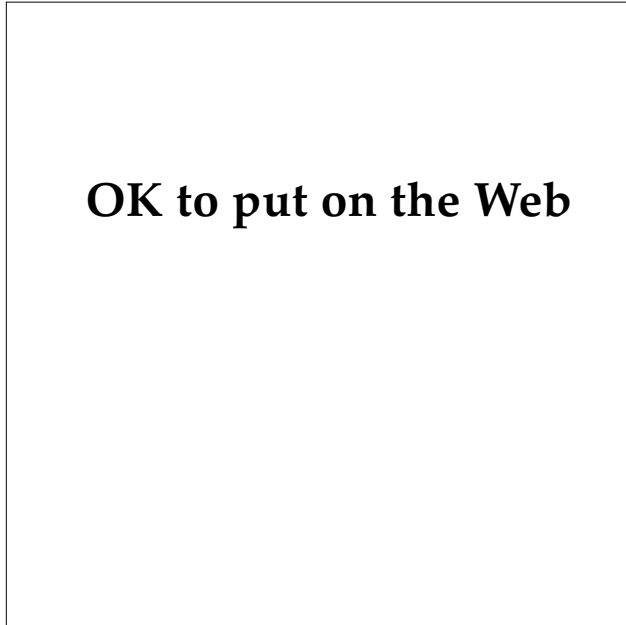
fold between the scrotum and upper thigh as an erythematous papule that demonstrates a typical, erythematous, annular configuration as it spreads to the upper thigh (Figure 17-9). More-severe lesions demonstrate vesicles, pustules, or crusting. Clinical involvement of the scrotum is uncommon.

### **Tinea Pedis**

Tinea pedis is the term applied to dermatophytic infections of the feet. In the United States, this is the most common form of superficial fungal infection. The most common organism in domestically acquired infections is *T rubrum*, followed by *T mentagrophytes* and *E floccosum*. During the Vietnam conflict, the most common organism was, again, a zoophilic strain of *T mentagrophytes*.<sup>6</sup>

Clinically, domestically acquired tinea pedis usually presents as either toe web infections or demonstrates diffuse involvement of the soles. Pruritus may at times be intense. The interdigital form is usually produced by an anthropophilic strain of *T mentagrophytes* var *interdigitale*, while diffuse involvement of the soles (ie, the “moccasin sandal” form) is more commonly produced by *T rubrum*. The typical, interdigital infection demonstrates scale between the toes on the plantar side, most typically seen around the fourth toe (Figure 17-10). Variable erythema or even vesicles may also be present. Secondary bacterial overgrowth is typically present in those lesions that demonstrate macerated, whitish, hyperkeratotic toe webs associated with a foul odor (Figure 17-11). Some authorities use the term *dermatophytosis simplex* for the former condition and *dermatophytosis complex* for the latter variant.<sup>14</sup> The



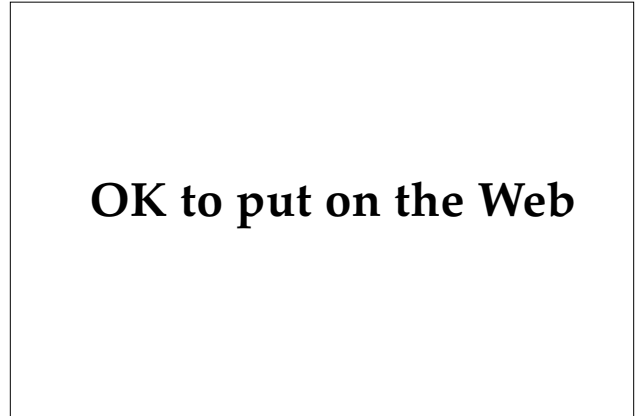


**Fig. 17-11.** Macerated, hyperkeratotic tinea pedis. Macerated tinea pedis may become severe enough to inhibit a soldier's combat effectiveness.

moccasin-sandal pattern is characterized by diffuse hyperkeratosis and scaling of the entire plantar surface. This variant is often asymptomatic and many patients assume that they have dry feet. In severe cases that extend to the instep or over the dorsal surface, inflammation or vesiculobullous lesions may occur (Figure 17-12). Bullous tinea pedis is most likely to occur on the instep of patients with a strong hypersensitivity to fungal antigens; however, any area of the foot may develop blisters. During the Vietnam conflict, in addition to toe web and plantar surface infection, severe infections of the dorsal surfaces of the feet and ankles were often present under the wet boots and made marching uncomfortable or impossible. Secondary bacterial pyoderma or cellulitis often complicated these infections.<sup>5</sup> Nail involvement is present in a high percentage of patients with diffuse hyperkeratosis, and less commonly in patients with interdigital infection.

#### *Tinea Manuum*

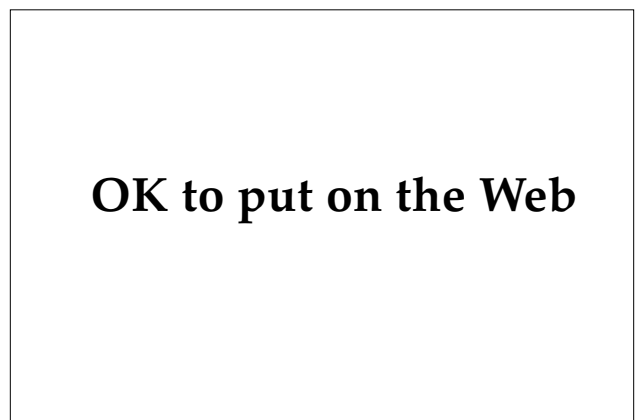Tinea manuum (also called tinea manus) is the term applied to dermatophytic infections of the hand. Tinea manuum is frequently associated with tinea pedis, but it is much less common. The most common organism is *T rubrum*, followed by *T*



**Fig. 17-12.** Severe, bullous tinea pedis of the instep initially diagnosed and treated as allergic contact dermatitis.

*mentagrophytes*. The effect of tinea manuum on military campaigns has been insignificant because of its low prevalence and minimal morbidity.

Tinea manuum commonly presents as diffuse scaling of the palms similar to the moccasin-sandal appearance of tinea pedis (Figure 17-13); variable erythema and vesicles may be present in patients with pronounced hypersensitivity. Most cases of tinea manuum are unilateral and are associated with bilateral infection of the feet, producing the "two-feet-one-hand" syndrome. This presentation is virtually diagnostic of dermatophytic infection. In cases difficult to differentiate from other inflammatory dermatoses, the presence of associated nail involvement may provide a valuable clinical clue.

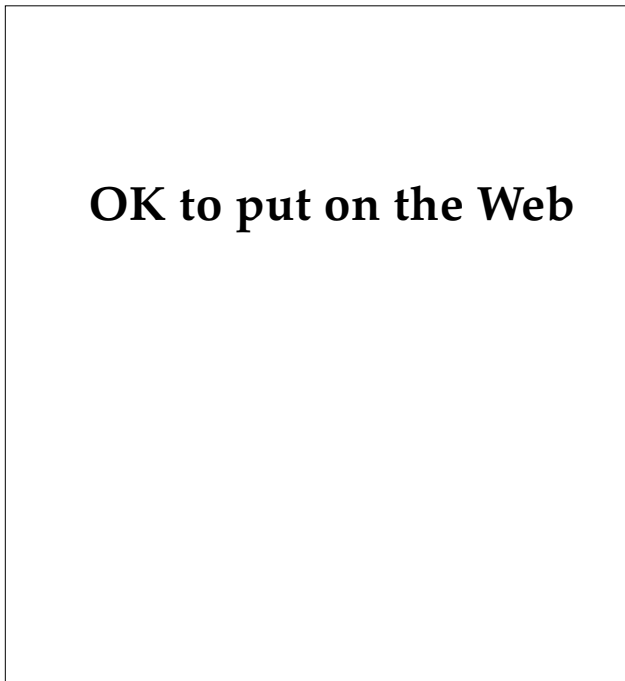


**Fig. 17-13.** Tinea manuum demonstrating diffuse hyperkeratosis of the left palm. The patient had similar "moccasin sandal" lesions of both feet.

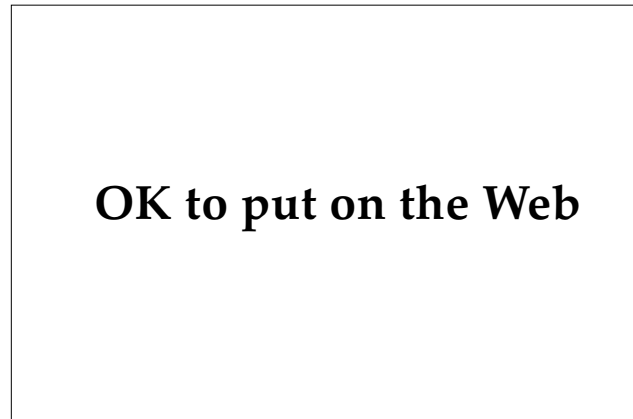
### Tinea Unguium

Tinea unguium is the most precise term for dermatophytic infections of the nail; the more commonly used term onychomycosis encompasses all fungal infections of the nail, including nondermatophytes. Onychomycosis is the most common cause of nail diseases presenting to physicians for treatment.<sup>15</sup> Dermatophytes are responsible for 27% to 66% of all cases of onychomycosis—depending on the survey.

As in tinea pedis, tinea unguium is most commonly caused by anthropophilic strains of *T rubrum* and *T mentagrophytes*, with the former accounting for approximately 80% of infections.<sup>15</sup> Most cases are associated with tinea pedis or tinea manuum and are believed to arise from local extension of these infections under the nail plate. Tinea unguium is not common in active-duty personnel but appears to be much more common in elderly persons. Infection of the toenails is more common than infection of the fingernails, reflecting the higher prevalence of tinea pedis. Usually the infected nail is asymptomatic, but occasionally the nails may become painful because of trauma or poorly fitting shoes.

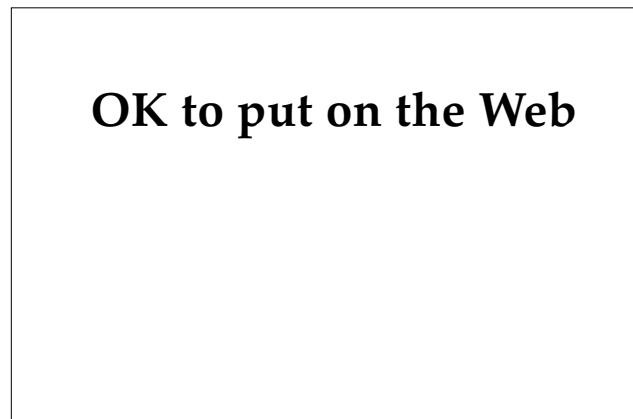

**Fig. 17-14.** Patients commonly present with tinea unguium demonstrating subungual hyperkeratosis.



**Fig. 17-15.** Tinea unguium demonstrating subungual hyperkeratosis and onycholysis. This is asymptomatic, as the surrounding skin is not affected.

Four clinical variants of tinea unguium have been defined: distal subungual hyperkeratosis, lateral onychomycosis, proximal onychomycosis, and leukonychia mycotica. Distal subungual hyperkeratosis is the most frequently encountered clinical presentation. One or more nails demonstrate subungual hyperkeratosis manifesting as a yellowish white or yellowish gray focal thickening of the nail that starts at the distal end and progresses proximally (Figure 17-14). Ultimately, the entire nail may be thickened and crumbly, or variable onycholysis may occur (Figure 17-15). Lateral onychomycosis is clinically similar except that it starts at the lateral edge of the nail. Proximal onychomycosis is a very uncommon variant that may be more common in patients with acquired



**Fig. 17-16.** White, opaque macular lesions of leukonychia mycotica.

immunodeficiency syndrome. Leukonychia mycotica is a somewhat uncommon variant in which the nail is invaded from its dorsal surface. Clinically, this manifests as white, opaque macules on the nail plate (Figure 17-16).<sup>15</sup>

### Diagnosis

The diagnosis of dermatophytic infections is usually easy but even the most astute clinician may miss atypical variants. Establishing the diagnosis hinges on the demonstration of the organism by microscopical examination of skin scrapings, culture, or biopsy material.

The following 10 clinical presentations are all suggestive of dermatophytosis and the appropriate investigative studies should be carried out:

1. children with "seborrheic dermatitis" (ie, scaly scalps),
2. children with hair loss,
3. children with pyodermas of the scalp,
4. any lesion that is scaly and annular,
5. any lesion that is red and annular,
6. any bullous lesion of the hands or feet,
7. unexplained follicular abscesses, especially of the legs,
8. dermatitis of the groin,
9. dermatitis or scale of the toe webs, and
10. "dry" feet or one "dry" hand.

It should be emphasized that these are only guidelines; atypical variants may be missed even if these principles are followed. Once a dermatophytic infection is suspected, the diagnostic test of choice is the direct microscopical examination of the suspected site: skin, hair, or nails. Skin specimens are best obtained by wetting the surface with an alcohol wipe or water and scraping the advancing edge of a lesion with a number 15 scalpel blade. Some dermatologists do not wet the skin; however, this method is inferior because the specimen does not adhere to the blade and the resulting sample is smaller and may be lost in transport. The specimen is then smeared on a glass slide and one or two drops of 10% to 20% potassium hydroxide is placed on the specimen. The slide is gently heated and examined under a microscope for the presence of hyphal elements. The hyphae of dermatophytes are linear, branched, demonstrate regular walls, and often demonstrate a subtle greenish hue (Figure 17-17). If dimethyl sulfoxide is included in the potassium hydroxide, then the heating step is not required. A number of other stains and methods are available

## OK to put on the Web

**Fig. 17-17.** This positive potassium hydroxide examination of glabrous skin demonstrates the characteristic branched hyphae of a dermatophyte. However, the species cannot be differentiated on the basis of potassium hydroxide preparations.

but potassium hydroxide examination remains the standard. In cases of suspected tinea capitis, the best results can be obtained when broken hairs can be plucked and examined using potassium hydroxide (Figure 17-18). Nails are inherently much more difficult to sample because the viable hyphae are often only at the proximal advancing edge. Initially, the proximal subungual debris should be scraped or the distal nail should be cut off for potassium hydroxide examination. If this examination is negative, the advancing edge can be sampled by carefully drilling a small hole with a large-bore

## OK to put on the Web

**Fig. 17-18.** This positive potassium hydroxide examination of infected hair demonstrates hyphae and arthrospores in a patient with tinea capitis due to *Trichophyton tonsurans* (original magnification 100X).

needle. Occasionally, other fungi, including *Candida albicans*, *Scopulariopsis brevicaulis*, *Hendersonula toruloidea*, *Aspergillus* species, *Alternaria tenuis*, *Cephalosporium* species, and *Scytalidium hyalinum* may produce onychomycosis.<sup>15</sup> These infections can be excluded only by culture.

In most studies, direct microscopical examination is much more sensitive than culture, but this depends on the experience of the examiner. In one study of 220 patients' dermatophytic infections, 97% were positive by direct potassium hydroxide examination and 48% were positive by culture. Positive cultures were obtained in only 2.7% of potassium hydroxide-negative specimens.<sup>16</sup> Similar results have been shown in several other studies.<sup>17,18</sup>

Cultural confirmation is often used by physicians who lack confidence in their direct microscopical examinations. Most dermatologists use cultures to exclude dermatophytic infections when the diagnosis is still suspected despite repeated negative potassium hydroxide examinations. Dermatophyte test medium is the most frequently used cultural medium. The sample is obtained in a fashion identical with that used for potassium hydroxide examinations and inoculated directly onto the culture medium. Dermatophytes usually grow within 7 days and turn the yellowish-orange medium a bright red color. If the medium turns red later than 1 week, then the color change was most likely caused by a contaminant. Dermatophyte test medium is not reliable for speciation, and if this is deemed necessary, the colony can be transferred to

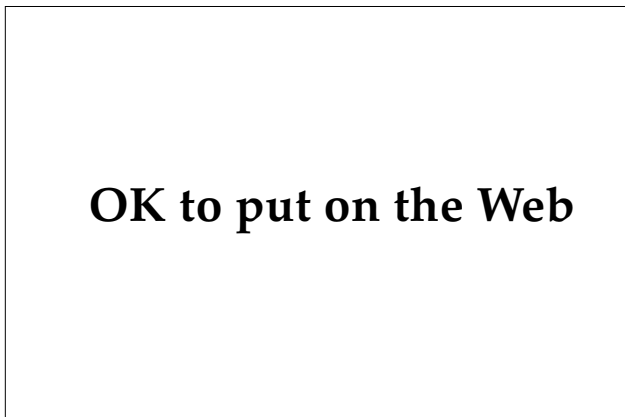Sabouraud's agar. Alternatives to dermatophyte test medium for initial isolation include Sabouraud's agar (Figure 17-19) or Sabouraud's agar with antibiotics (Mycosel, manufactured by Baltimore Biologica Co., Baltimore, Maryland.)

In cases of suspected tinea capitis, a Wood's lamp is useful in cases of fluorescent dermatophytes, which includes *M canis*, *M audouinii*, *M ferrugineum*, and *T schoenleinii*. The former three organisms will demonstrate a bluish-white fluorescence of infected hairs, while *T schoenleinii* will demonstrate a dull bluish-white fluorescence. A negative Wood's light examination does not exclude tinea capitis, however, because *T tonsurans*, the most common offender, does not fluoresce.

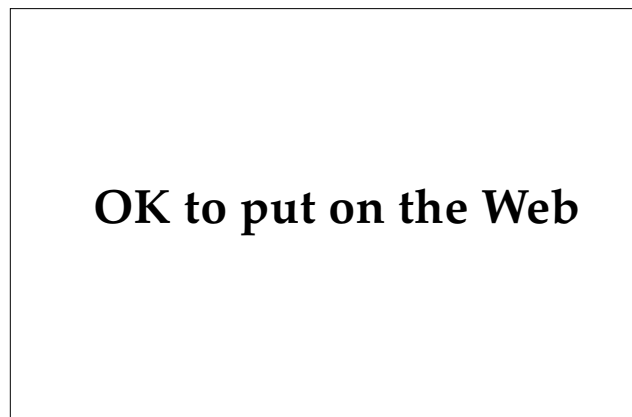In rare cases, a biopsy may be required to establish the diagnosis. This most commonly occurs in kerions or Majocchi granuloma, when the organisms may be difficult to demonstrate using less invasive techniques. The organisms are often difficult to visualize using standard hematoxylin-eosin stains; special stains such as periodic acid-Schiff with diastase or Gomori's methenamine silver stain are often required (Figures 17-20 through 17-22).

### Treatment

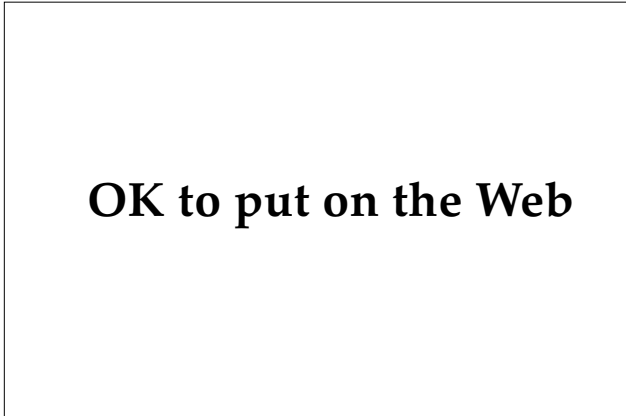
The options available for the treatment of dermatophytic infections are numerous and confusing (Exhibit 17-3). In many clinical situations, the optimal therapy has not been established, and military physicians rely on anecdotal information and local availability of antimycotic agents. Treatment most



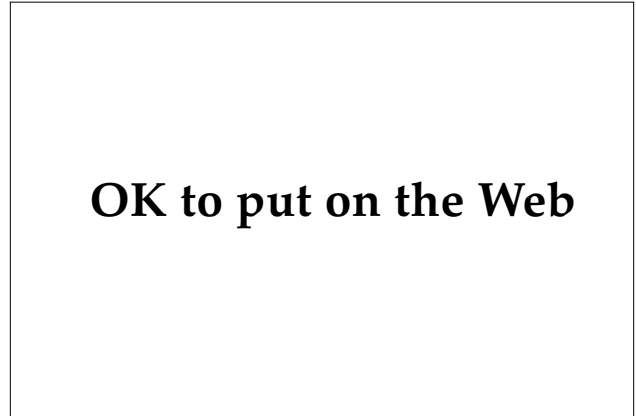
**Fig. 17-19.** Positive culture on Sabouraud's agar for *Epidermophyton floccosum*, a common cause of tinea cruris. Sabouraud's agar is the medium most commonly used for the culture and identification of dermatophytes.



**Fig. 17-20.** This specimen from a biopsy of tinea capitis demonstrates marked invasion and destruction of the hair shaft (hematoxylin-eosin stain, original magnification 200X).



**Fig. 17-21.** This specimen from a biopsy of tinea capitis demonstrates improved visualization of fungal elements with special stains (Gomori's methenamine silver stain, original magnification 100X).



**Fig. 17-22.** This specimen from a biopsy of tinea corporis demonstrates both horizontal and cross sections of hyphae (hematoxylin-eosin stain, original magnification 200X).

commonly involves the use of specific antifungal agents, although nonspecific measures are often used to augment the primary therapy (Figure 17-23).

The treatment of choice for tinea capitis and other infections that invade hair follicles (eg, tinea barbae or Majocchi granuloma) is oral griseofulvin. Griseofulvin is available in both microsize and ultramicrosize forms, with the latter being absorbed

from the gut approximately twice as efficiently. The dosages discussed in this chapter are for the ultramicrosize griseofulvin. If microsize griseofulvin is used, the listed dosage should be doubled. The optimal dosage of ultramicrosize griseofulvin for the treatment of tinea capitis in children has not been established. The accepted doses vary—depending on the authority cited—from 3.3 mg/kg to 5.0 mg/kg/d, given in a single daily dose. Adults should be treated with a total daily dose of 330 to 750 mg/d, depending on the severity of infection and tolerance to griseofulvin. Divided daily doses produce higher plasma levels and should be used if compliance is not a problem.<sup>19</sup> Treatment should continue for a minimum of 2 months, or 2 weeks past the last negative culture. Twice-weekly shampooing with 2% selenium sulfide is reported to be a useful adjunctive agent in the treatment of tinea capitis in children because it is sporicidal and may decrease the chances for spreading the infection to other individuals.<sup>20</sup> Ideally, other members of the family, especially children, should be examined as concurrent infection is not infrequent. Kerions require, in addition to antifungal therapy, intralesional triamcinolone acetonide at a strength of 5 to 10 mg/mL for limited lesions. Extensive lesions require the addition of oral prednisone at a dose of 1 to 2 mg/kg/d for 2 to 4 weeks.

The treatment of tinea corporis depends on the extent of involvement. Limited cases are best treated by twice-daily applications of a broad-spectrum antifungal cream (eg, one of the imidazoles, ciclopirox olamine, or naftifine). Inflamed and scaly areas should be treated for 2 weeks past the point of

**EXHIBIT 17-3**

**ANTIMYCOTIC DRUGS**

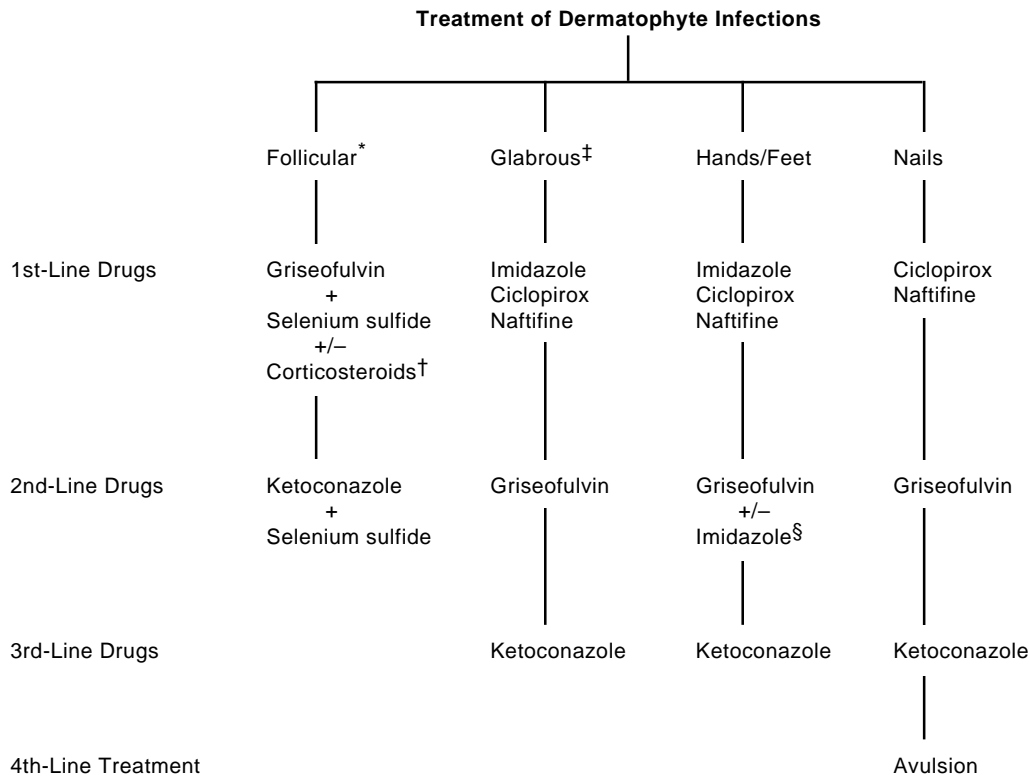
---

**Topical**

- Imidazoles
  - Clotrimazole
  - Econazole
  - Ketoconazole
  - Miconazole
  - Oxiconazole
  - Sulconazole
- Allylamines
  - Naftifine
- Hydroxypyridones
  - Ciclopirox olamine

**Oral**

- Griseofulvin
- Ketoconazole



\*Follicular denotes tinea capitis, follicular tinea barbae, or Majocchi granuloma

†Intralesional triamcinolone acetonide for limited lesions and oral prednisone for extensive lesions

‡Extensive cases should be treated with griseofulvin

§Griseofulvin plus topical imidazole for interdigital tinea pedis

Fig. 17-23. Algorithm for simplified, optimal treatment for dermatophyte infections.

resolution. Extensive or resistant cases should be treated with oral ultramicrosize griseofulvin (330–750 mg/d) for 4 weeks or 2 weeks past the point of total resolution. Griseofulvin-resistant cases should be treated with 200 mg of oral ketoconazole taken in a single morning dose. If the patient has not demonstrated a response at 1 month, the dose should be increased to 400 mg/d.<sup>21</sup>

The treatment of choice of tinea cruris is twice-daily applications of a broad-spectrum antimycotic agent (eg, an imidazole, ciclopirox olamine, or naftifine). Although good comparative irritancy studies of the various preparations have not been done, many of the topical preparations produce irritant reactions in this area, particularly in humid climates. In a study of 117 Colombian soldiers with tinea corporis and cruris, researchers report that sulconazole nitrate cream applied once daily was as effective as clotrimazole applied twice daily.<sup>13</sup> However, none of the sulconazole nitrate-treated pa-

tients experienced irritant reactions, while 15% of the clotrimazole-treated patients developed erosive irritant reactions. Until further, similar studies become available, sulconazole nitrate cream should be considered the topical imidazole of choice for tinea cruris in combat conditions, based on its ease of use and lack of irritancy. In resistant cases or in patients unable to tolerate topical antifungal drugs, oral ultramicrosize griseofulvin should be given in a dose of 330 to 750 mg/d for a minimum of 4 weeks, or 2 weeks past the point of total resolution. Topical haloprogin is no longer recommended for the treatment of tinea cruris because, when compared to the less-irritating imidazoles, its rate of irritation is high and its response rate is low.<sup>22</sup> Switching from briefs to boxer shorts is a helpful, nonspecific measure.

Tinea manuum and tinea pedis may initially be treated with topical, broad-spectrum, antimycotic agents. Infections of the toe web spaces sometimes

respond to topical antimycotic therapy alone within 4 to 6 weeks. At least one study has demonstrated that a synergistic effect can be achieved by combining a topical imidazole with oral griseofulvin.<sup>23</sup> Infections presenting as diffuse hyperkeratosis are associated with *T rubrum* infection and are notoriously more difficult to eradicate, often requiring 3 or more months of topical therapy; even then, the cure rate may be as low as 18%. Oral ultramicrosize griseofulvin in a dose of 330 to 750 mg/d for 3 months is probably the drug of choice in the diffuse plantar hyperkeratotic variant. The addition of a topical imidazole does not appear to produce higher cure rates. Oral ketoconazole in an oral dose of 200 to 400 mg/d should be reserved for cases of tinea manuum and pedis that are resistant to griseofulvin. Erosive or macerated interdigital tinea pedis often reflects dense colonization with resident bacteria or Gram-negative organisms. In these cases, the addition of a twice-daily application of 30% aluminum chloride or Castellani's paint (ie, carbol-fuchsin paint) may prove helpful.<sup>24</sup>

Tinea unguium remains the most resistant of dermatophytic infections, and many cases are essentially not curable using current therapies. In general, tinea unguium of the fingernails is more sensitive to therapy than toenails and should be treated more aggressively. Topical antifungal agents are rarely curative except in leukonychia mycetica

and in occasional cases affecting fingernails.

Although good studies are not available, topical ciclopirox olamine applied to the nails twice daily is recommended over the other topical antifungal agents because its penetration of keratin is excellent.<sup>25</sup> Pharmacokinetic studies have also shown that naftifine penetrates the nail plate, and cures have been reported in up to 42% of patients treated with twice-daily applications of naftifine gel.<sup>26</sup> Additional, long-term studies will be needed to confirm these results. The efficacy of topical antimycotic agents is improved if the infected keratin is removed by mechanical means such as filing, clipping, or paring. Oral griseofulvin is the treatment of choice when systemic antifungal therapy is used, although the long-term cure rates are low. In the author's experience, 12 months of 750 mg of oral ultramicrosize griseofulvin results in a 10% cure rate in toenails and a 60% cure rate in fingernails. While initial studies suggested that oral ketoconazole in a dose of 200 to 400 mg/d was highly effective against tinea unguium, a short-term cure rate of only 26% was found, with 40% of patients relapsing within 6 months.<sup>27</sup> Removal of infected nails by either surgical avulsion or urea ointment is time-consuming and often associated with recurrence of infection when the nail regrows. Avulsion is indicated when nails become symptomatic or impede the wearing of shoes.<sup>28</sup>

## CANDIDOSIS

In recent years, *candidosis* has been suggested as the preferred term to describe infections that occur as the result of mucocutaneous or systemic infection by *Candida* organisms, replacing the terms *candidiasis* and *moniliasis*. (However, *candidiasis* is ingrained in the medical literature and is still used by many authorities). Although other species may produce disease, particularly in immunocompromised individuals, *C albicans* is the most common pathogen (Exhibit 17-4). During the Vietnam conflict, *C albicans* accounted for most infections, although occasional isolates of *C tropicalis* were recovered.<sup>5</sup>

*Candida* organisms are usually harmless flora of the skin, mucous membranes, or gastrointestinal tract; under normal circumstances they do not produce clinical disease. *Candida* species may become opportunistic pathogens under a variety of circumstances including preexisting dermatitis, maceration, diabetes mellitus, antibiotic therapy, or immu-

nosuppression. Unlike the dermatophytes, *Candida* organisms do not utilize keratin as a substrate for growth but prefer areas with high concentrations of

### EXHIBIT 17-4

#### PATHOGENIC *CANDIDA* SPECIES

*Candida albicans*

*C tropicalis*

*C guilliermondii*\*

*C krusei*\*

*C pseudotropicalis*\*

*C stelloidea*\*

\*Rare pathogens

**EXHIBIT 17-5**

**CLINICAL MANIFESTATIONS OF CANDIDOSIS**

**Cutaneous Disease**

- Intertrigo
- Erosio interdigitalis blastomycetica
- Paronychia
- Onychomycosis
- Chronic mucocutaneous candidiasis

**Mucosal Disease**

- Thrush
- Perlèche
- Balanitis
- Vulvovaginitis

**Systemic Disease\***

\*Not discussed in this chapter

serum or glucose. This accounts for their predilection to invade living tissue and the relatively uncommon invasion of nails and hair. Although candidosis and candidiasis are terms that encompass all infections, numerous other terms are used to describe the diverse manifestations (Exhibit 17-5). Mucocutaneous candidosis is of interest to military medicine; systemic candidosis is not discussed in this chapter.

Candidosis was not listed as a significant problem in the military campaigns of World War I<sup>2</sup> or World War II,<sup>3</sup> but was a major problem during the Vietnam conflict.<sup>5</sup> It is difficult to imagine that candidosis was not a problem in tropical areas during the Pacific Campaign in World War II, and it is most likely that the disease was unreported or misdiagnosed. During the Vietnam conflict, candidosis of the skin and mucosa was estimated to be the third-most-common cause of skin disease.<sup>6</sup> In one survey, *C albicans* was isolated from 10% of soldiers in the Mekong Delta. These isolations were frequently associated with dermatophytic infections, suggesting that candidosis was often a secondary infection. As in the case of dermatophytosis, candidosis was more prevalent in combat troops than in support troops. An exception to this was support troops in extremely hot and humid environments (eg, cooks and boiler-room workers).<sup>5</sup>

The most common sites of infection were the toe web spaces and the groin.

**Clinical Features**

*Intertrigo*

The most common form of candidal infection experienced by military personnel is intertrigo (ie, infections of intertriginous areas). The most common intertriginous areas affected are the groin, followed by the toe web spaces, inframammary crease, and axillae. *Candida albicans* prefers high humidity and a damaged stratum corneum for growth. These two requirements are frequently fulfilled during military campaigns, particularly in tropical climates where clothes and boots are often soaked and the stratum corneum is damaged by other infections or friction.

Symptoms of candidal intertrigo include pruritus and burning. Candidosis is more likely to be painful than dermatophytosis, presumably due to invasion of viable tissue and a brisk host response. In the groin and axilla, patients with candidal intertrigo present with confluent, very erythematous lesions that demonstrate satellite lesions at the periphery (Figure 17-24). Small pustules are frequently present and central clearing—as seen in dermatophytic infections—is distinctly rare. Toe web infections demonstrate severe maceration associated with irregular plaques of white acanthosis. The surface of the denuded areas is fiery red and raw.

Erosio interdigitalis blastomycetica is a peculiar, erosive, hyperkeratotic form of candidal intertrigo

**OK to put on the Web**

**Fig. 17-24.** Candidosis of the groin demonstrating marked erythema, satellite lesions, and scrotal involvement; all features are suggestive of candidosis.



## OK to put on the Web

**Fig. 17-25.** Erosio interdigitalis blastomycetica demonstrating characteristic whitish hyperkeratosis. This patient also had diabetes mellitus, a common predisposing factor.

that affects the interdigital spaces, particularly between the third and fourth fingers (Figure 17-25). This clinical variant is seen in patients whose hands are immersed repeatedly in water. Experimental studies suggest that erosio interdigitalis blastomycetica is a synergistic infection of *C albicans* and one or more Gram-negative rods.<sup>29</sup>

### Paronychia and Onychomycosis

Candidal paronychia and onychomycosis are often present simultaneously. The role of *Candida* organisms in producing paronychia is controversial, as other fungi and bacteria may also be recovered. Paronychia is strongly associated with persons whose hands are repeatedly immersed in water (eg, cooks). The author personally developed paronychia while working as a bartender; the problem resolved spontaneously following a change in occupation. Clinically, candidal paronychia appear as erythematous, edematous lesions affecting the periungual tissues around one or more fingers. Occasionally, small amounts of purulent material may be expressed from beneath the proximal nail.

Candidal onychomycosis most commonly occurs in association with paronychia. It is generally re-

garded as a secondary process that occurs due to inflammation of the nail matrix. Clinically, it presents as nail dystrophy with horizontal or vertical furrows. Occasionally, *Candida* organisms may be recovered from the subungual spaces beneath onycholytic nails. It is unclear whether this represents infection or merely colonization of a moist habitat.

Chronic mucocutaneous candidosis is a rare, progressive form of infection that occurs in persons with inherited or sporadic defects in cell-mediated immunity. This is a heterogeneous disorder with anywhere from four to seven subtypes depending on the classification system used. Some cases may be associated with endocrinopathies or thymomas. In most cases, onset occurs during childhood, with cutaneous or mucosal infection that is resistant to normal therapies. Eventually, the lesions progress and produce diffuse oral thrush, perlèche, and involvement of virtually any cutaneous surface including nails, in which the entire thickness of the nail plate may be invaded and destroyed (Figure 17-26).

Except for chronic mucocutaneous candidosis, *Candida* organisms can affect glabrous skin only when occluded. This most commonly occurs in infants wearing occlusive diapers (Figure 17-27). While candidosis is only one of many causes of diaper dermatitis, a correct diagnosis is important because it affects treatment. The primary lesions are usually sharply demarcated areas of erythema that are confluent in folds that are associated with satellite erythematous papules or pustules. In adults, similar lesions may occur under dressings (Figure 17-28) and in immobilized hospital patients (Figure 17-29).

## OK to put on the Web

**Fig. 17-26.** Chronic mucocutaneous candidiasis demonstrating onychomycosis, paronychia, and marked hyperkeratosis.

## OK to put on the Web

**Fig. 17-27.** Marked diaper dermatitis secondary to candidosis. Note satellite lesions. Photograph: Courtesy of Bruce Kornfeld, MD, Fort Collins, Colo.

Candidal vaginitis is a very common infection; it is usually seen by gynecologists and will not be discussed here. However, extension of infection to the vulva (vulvovaginitis) may occur, particularly when the patient is pregnant, diabetic, immunocompromised, or taking antibiotics. The most com-

## OK to put on the Web

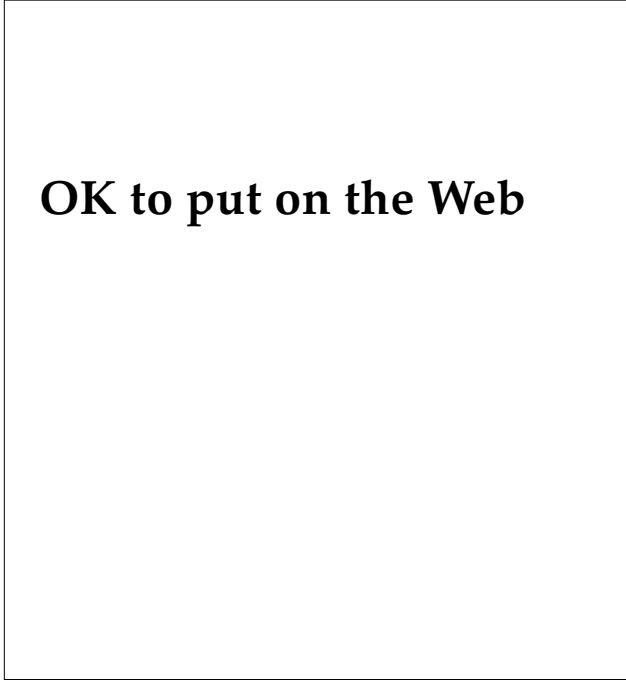
**Fig. 17-28.** Candidosis is limited to the occluded site beneath the tape. The local heat and moisture afforded by occlusion predispose to fungal infections.

## OK to put on the Web

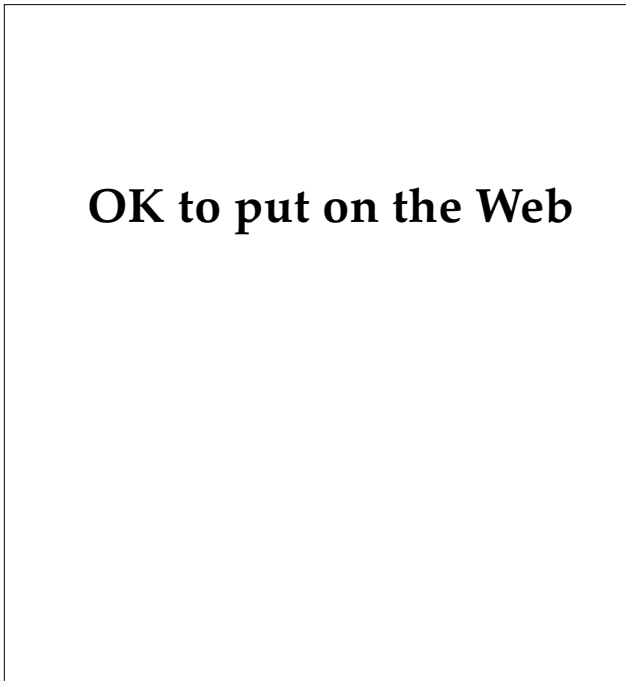
**Fig. 17-29.** Marked candidosis can be seen in this immobilized airborne soldier, who fractured both legs during a training jump.

mon symptoms are pruritus or burning. The findings include a vaginal discharge, erythema of the introitus and vulva, and characteristic satellite lesions on the vulva. Similar lesions may occur in men, particularly uncircumcised men, who may present with erythematous papules, diffuse erythema (Figure 17-30), or even superficial erosions (Figure 17-31).

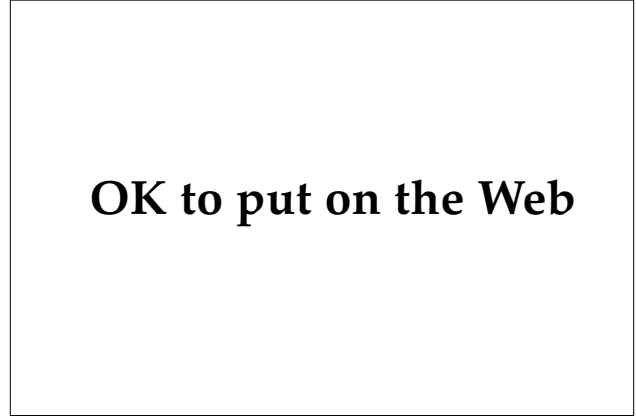Candidosis is the most common fungal infection of the oral mucosa.<sup>30</sup> The most common oral mucosal presentations are perlèche and thrush. Oral candidosis most commonly affects newborns, the elderly, and patients who have diabetes or are immunocompromised. The presence of oral candidosis in a young soldier should precipitate a search for diabetes mellitus and infection with the human immunodeficiency virus. Perlèche (ie, infection of the angles at the corners of the mouth) is usually but not invariably associated with thrush. Clinically, patients present with cracks or fissures at both corners of the mouth; these are associated with an adherent, white exudate (Figure 17-32). The hallmark of thrush is the presence of white patches anywhere within the oral mucosa. These areas are composed of white, creamy-to-almost-



**Fig. 17-30.** This patient with candidal balanitis presented with diffuse erythema and edema.



**Fig. 17-31.** A soldier stationed in Korea presented with candidal balanitis manifesting as superficial erosions. This patient had been incorrectly diagnosed with and treated for chancroid and genital herpes.



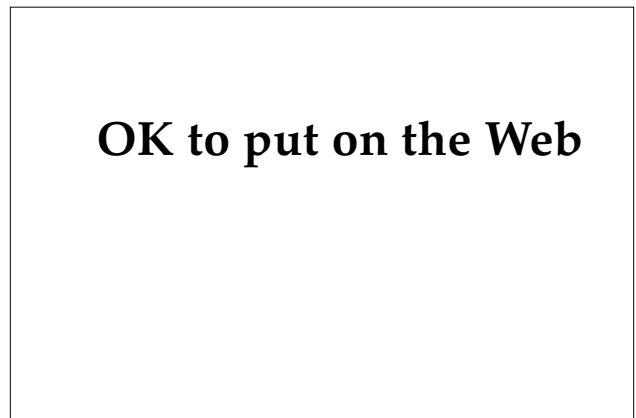
**Fig. 17-32.** This patient with perleche presented with bilateral fissures associated with white exudate.

cheesy exudates that are adherent but easily removed. The underlying mucosa is brightly erythematous. Involvement of the tongue results in intense erythema and loss of papillae.

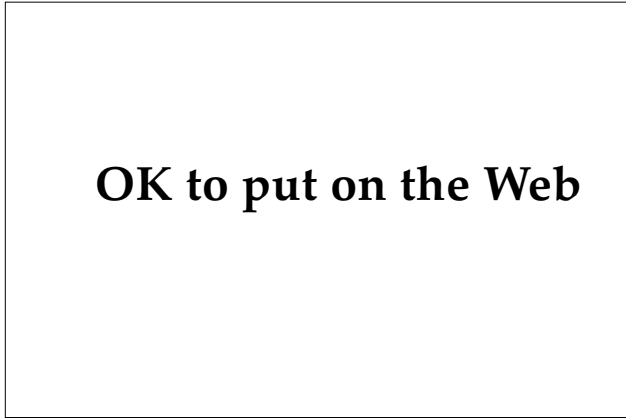#### **Diagnosis**

The diagnosis of candidosis is usually suspected based on the clinical presentation. In intertriginous areas or areas under occlusion, the presence of sharply demarcated erythema associated with small, brightly erythematous, satellite lesions is candidosis until proven otherwise. Similarly, leukoplakia of the oral mucosa that is easily removed with scraping is most likely candidosis.

The diagnosis is established by demonstrating the organism either microscopically or by culture.

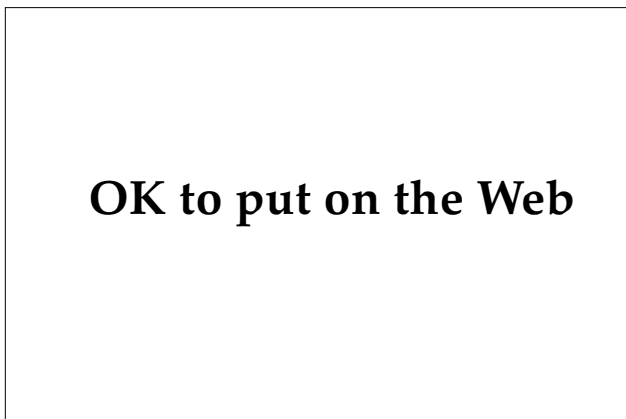


**Fig. 17-33.** Positive potassium hydroxide examination of thrush demonstrating pseudohyphae and yeast forms.



**Fig. 17-34.** Positive Gram's stain of a pustular lesion of candidosis demonstrating neutrophils and pseudohyphae.

Using potassium hydroxide examination on cutaneous surfaces, the yeast and pseudohyphae of candidosis are generally more difficult to find than dermatophytes: the viable pseudohyphae often penetrate deeper than the stratum corneum and samples are often too superficial. Scrapings of mucosal surfaces are more often positive (Figure 17-33). Gram's stain is particularly useful on pustular lesions that could be either bacterial or fungal because it will stain both bacteria and *Candida* organisms (Figure 17-34). Scrapings also may be cultured on either Sabouraud's or on a *Candida*-specific medium such as Nickerson's. On Sabouraud's medium, the colonies are white or cream-colored and produce a

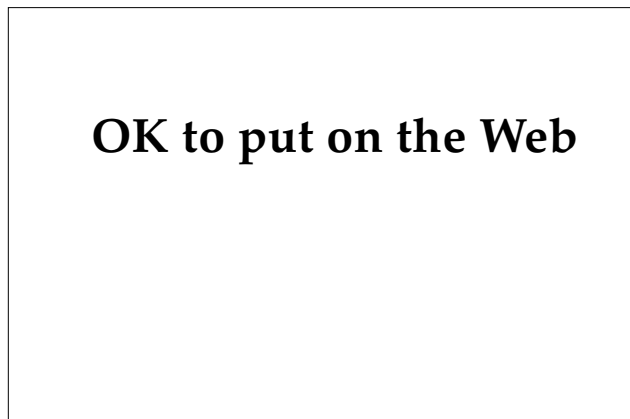


**Fig. 17-35.** Positive culture for *Candida albicans* on Sabouraud's agar demonstrating a typical white, yeasty colony. Definitive identification usually requires subculture on cornmeal agar.

yeastlike odor (Figure 17-35). On Nickerson's medium, the colonies produced are dark. Speciation of *C albicans* can be confirmed by the demonstration of chlamydo spores on cornmeal agar or the production of germ tubes in the presence of serum. On rare occasions, candidosis is not suspected and the diagnosis is made on biopsy specimens. Histologically, hyphal and yeastlike structures are seen in the stratum corneum and upper stratum spinosum. Neutrophils are more commonly associated with candidosis than dermatophytosis; this may manifest as subcorneal blisters or focal neutrophilic spongiosis (Figure 17-36).

### Treatment

Infection with *C albicans* responds to the antimycotic drugs typically used against dermatophytes—except tolnaftate and griseofulvin. Intertrigo, including erosio interdigitalis blastomycetica, is best treated by twice-daily applications of topical imidazoles, ciclopirox olamine, or naftifine. If the lesions are inflammatory or painful, sulconazole or nystatin are probably preferred due to their lack of irritancy. Nystatin, formerly the antifungal of choice for candidosis, has largely been replaced by the imidazoles due to the emergence of both primary and secondary resistant strains of *Candida* species.<sup>31</sup> Amphotericin B lotion or cream is also effective but is not recommended because of its cost. Nonspecific measures such as reducing moisture and maceration with a hair dryer and



**Fig. 17-36.** This specimen from a biopsy of cutaneous candidosis demonstrates neutrophilic spongiosis and pseudohyphae, which are clearly seen between two fragments of keratin (hematoxylin-eosin stain, original magnification 400X).

weight reduction are also helpful. Paradoxically, very painful inflammatory lesions can be relieved with water or Burrow's solution compresses three or four times per day.

Candidal paronychia and onychomycosis can usually be improved by simply having the patient discontinue wet work if feasible, or using cotton-lined gloves if water exposure is inevitable. Women also should be advised to discontinue the practice of pushing back the cuticle to allow it to reattach to the dorsum of the nail plate. A 3% to 4% solution of thymol in alcohol applied three times daily to the paronychial area is an extremely beneficial first-line therapy. Resistant cases can be treated with topical imidazoles, ciclopirox olamine, nystatin, or naftifine, applied twice daily. Therapy should be continued 2 weeks past the point of clinical resolution.

Thrush is best treated with nystatin oral suspen-

sion in a dose of 5 mL (500,000 units) held in the mouth for several minutes and then swallowed. This treatment is repeated four times daily for 7 to 10 days. An alternative approach is dissolving clotrimazole troches in the mouth five times daily for 2 weeks.<sup>32</sup> Gentian violet (0.5% to 1%) may be applied to affected areas two or three times daily in resistant cases, but is infrequently used because of the inevitable purplish discoloration. Perlèche readily responds to the twice-daily application of a topical imidazole, ciclopirox olamine, nystatin, or naftifine cream.

The first-line treatment of vulvovaginitis is one of the imidazole products made for use in this area including clotrimazole, miconazole, and butoconazole. These treatments have largely replaced nystatin, which is slightly less effective. Recurrent cases may respond to oral ketoconazole in a dose of 400 mg/d for 2 weeks for control.

## PITYROSPORUM INFECTIONS

Pityriasis versicolor is the correct term for superficial infections of the epidermis produced by the yeast *Pityrosporum orbiculare*. Many authorities continue to use the term tinea versicolor, although "tinea" is incorrect: it denotes infection with a dermatophyte that uses keratin for a substrate. *Pityrosporum* species require lipids for growth and thus are not dermatophytes. The taxonomy is also confusing in that *P orbiculare* is the taxonomic term most commonly used for the yeast phase of the fungus, while *Malassezia furfur* is the term sometimes used for the pathogenic hyphal phase. Some authorities do not make this distinction and one term or the other is used without explanation. However, *Malassezia furfur* is a confusing term and should not be used. From a taxonomic and mycological standpoint, *P orbiculare* is preferred.<sup>33</sup>

*Pityrosporum* species may also produce a characteristic folliculitis (formerly called *Malassezia folliculitis*). The organism responsible for pityrosporum folliculitis is probably *P orbiculare*, although good cultural studies are lacking. Some authorities have stated that *P ovale* is the etiologic agent; however, recent morphologic, physiological, and immunological studies suggest that this species is identical with *P orbiculare*.<sup>34</sup>

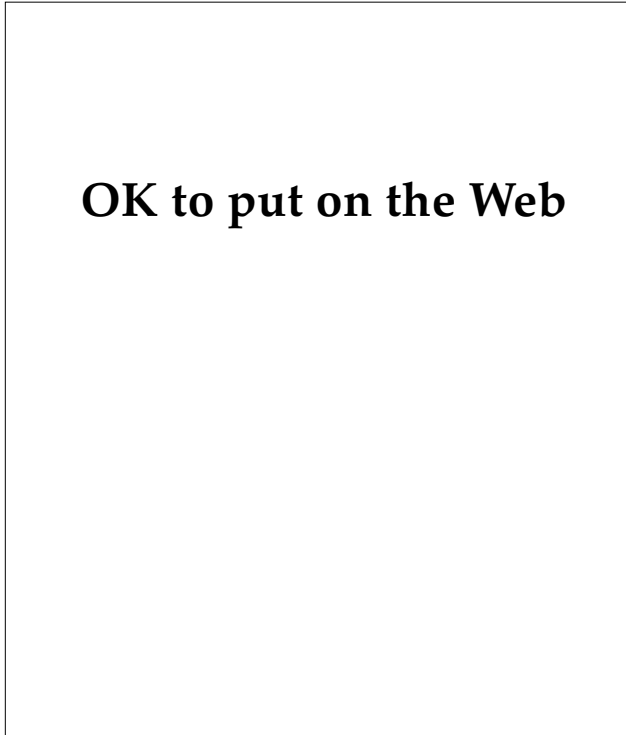
*Pityrosporum* organisms may occasionally produce systemic infections in the immunocompromised host, particularly when intravenous lipids are administered. This manifestation is beyond the scope of this chapter and will not be discussed.

### Clinical Features

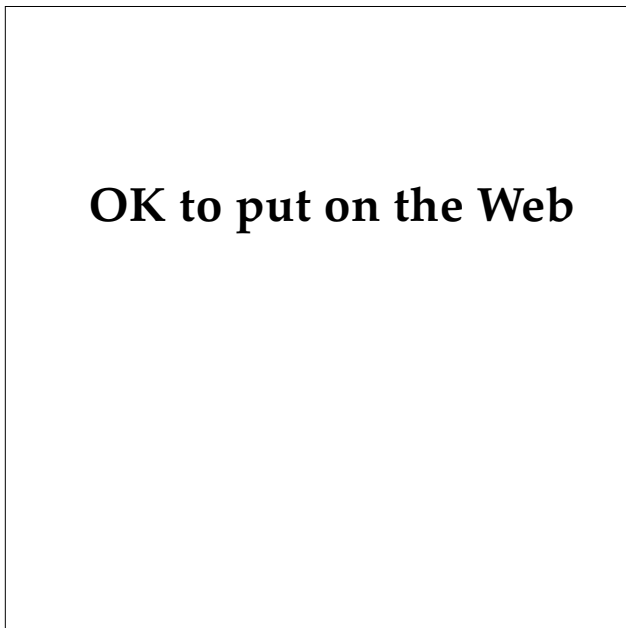
#### *Pityriasis Versicolor*

Pityriasis versicolor is a trivial cutaneous infection. It has had minimal impact on military campaigns and is infrequently discussed in the medical histories of previous wars. The importance of pityriasis versicolor on the military is related only to the cost of treatment and time lost from work. During World War II, a dermatology clinic in Camp Lee, Virginia, reported that pityriasis versicolor accounted for 2.4% of visits.<sup>3</sup> During the Vietnam conflict, it frequently caused outpatient visits, often because soldiers feared that it was a manifestation of a sexually transmitted disease. Pityriasis versicolor accounted for 2.7% of visits at one dermatology clinic, making it the tenth-most-common dermatologic complaint.<sup>5</sup>

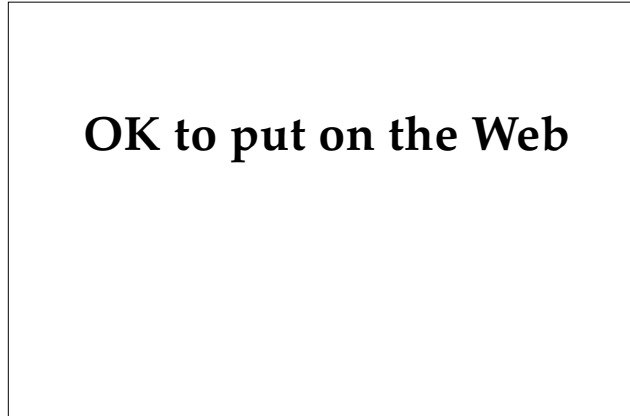
Pityriasis versicolor is more common in warm, humid climates, where it may affect up to 50% of individuals in some areas of the world.<sup>35</sup> The incidence is higher in persons such as cooks who work in hot, humid places (Figure 17-37). Many patients do not even regard it as a disease and it is frequently diagnosed during examination for other diseases. Pityriasis versicolor often affects multiple members of the same family, suggesting a genetic susceptibility to infection. It is possible that this familial clustering of infections may be due to more virulent strains, although this has not been investigated.



**Fig. 17-37.** This patient, a cook in the U.S. military, has extensive pityriasis versicolor involving almost his entire trunk.



**Fig. 17-38.** Characteristic fawn-colored macules of pityriasis versicolor are present on the abdomen of this young man.



**Fig. 17-39.** Hypopigmented lesions of pityriasis versicolor.

Pityriasis versicolor is usually asymptomatic, although occasional patients may complain of a burning sensation or mild pruritus. The primary lesions are usually tan or fawn-colored macules that may coalesce into large patches that almost replace the entire skin. Close inspection reveals a fine, branny scale that covers the entire macule or patch (Figure 17-38). Annular lesions are distinctly uncommon, although occasional lesions may be perifollicular. Inflammation is usually absent. The affected areas usually display a truncal distribution, although extension to acral areas may occur. Less commonly, the primary lesions are hypopigmented, which apparently is due to the yeast's production of biochemical products that interfere with melanin synthesis and packaging. This decrease in pigmentation is more noticeable when the patients attempt to develop a tan (Figure 17-39).

#### *Pityrosporum Folliculitis*

The prevalence of pityrosporum folliculitis infection in military combat personnel is unknown because only in recent years has this infection been defined and accepted as a valid disease process.<sup>36</sup> Given the benign nature of this disease, it is unlikely to have affected military campaigns.

Pityrosporum folliculitis most commonly affects young and middle-aged persons and has a predilection for women. Although most patients are healthy, this infection may be more common in immunocompromised hosts.

The lesions of pityrosporum folliculitis are intensely pruritic; this is often the primary reason that patients seek medical treatment. The pruritus may be aggravated by intense sweating or showers. The

## OK to put on the Web

**Fig. 17-40.** Extensive pityrosporum folliculitis of the back. The clinical picture can closely mimic acne vulgaris.

primary lesions are discrete, follicular papules and pustules, typically 2 to 4 mm in diameter, and most commonly located on the upper back, arms, and chest (Figure 17-40). Lesions occasionally develop on acral areas such as the face, arms, and legs. Variable erythema, excoriations, and wheal-and-flare reactions also may be present.

### *Other Pityrosporum Infections*

The role of *Pityrosporum* yeast in the pathogenesis of seborrheic dermatitis is controversial. The presence of high concentrations of yeast in lesions of seborrheic dermatitis, combined with a frequent response to topical imidazole treatment, support the notion of a potential role. However, the not-infrequent failure of imidazoles to improve seborrheic dermatitis and the presence of high concentrations of yeast in clinically normal patients who have no demonstrable seborrheic dermatitis both suggest that *Pityrosporum* organisms may play a secondary role. Further studies are needed to define the role of *Pityrosporum* in the pathogenesis of seborrheic dermatitis.

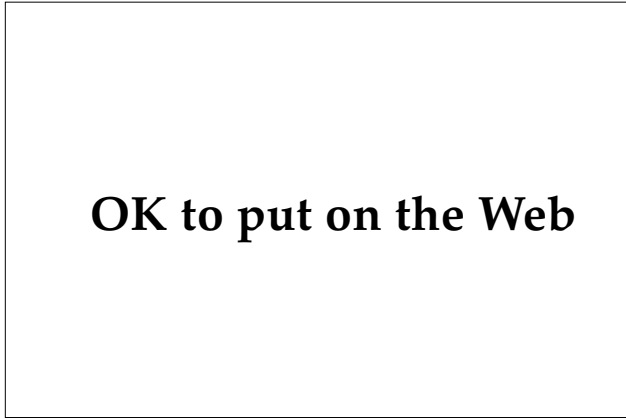
### Diagnosis

The diagnosis of pityriasis versicolor can usually be made based on the clinical presentation alone. The finding of asymptomatic, branny or whitish scales that are located primarily on the trunk is pityriasis versicolor until proven otherwise. Atypical cases may be diagnosed by microscopic examination of skin scrapings that are treated with potassium hydroxide; the examination is performed exactly like that for dermatophytic infections. Because the organism is located superficially in the stratum corneum, many physicians prefer to obtain specimens by touching lesions with clear cellophane tape. A drop or two of potassium hydroxide is placed on a slide and the tape is then placed sticky-side down over the potassium hydroxide. This technique is more rapid and less traumatic than the skin-scraping method. Alternatively, instead of potassium hydroxide, a 0.5% to 1% solution of toluidine blue may be used because the yeast preferentially take up this dye. The diagnosis is made by finding short, straight hyphae associated with clusters of round, budding yeast, often referred to as "spaghetti and meatballs" (Figure 17-41). In contrast to dermatophytic infections, the organisms are so abundant in pityriasis versicolor that a negative result obtained from a properly performed examination excludes this diagnosis.

Atypical lesions are sometimes biopsied. The biopsies demonstrate a somewhat normal epidermis with a mild, superficial, perivascular, lymphocytic dermatitis associated with mild hyperkeratosis

## OK to put on the Web

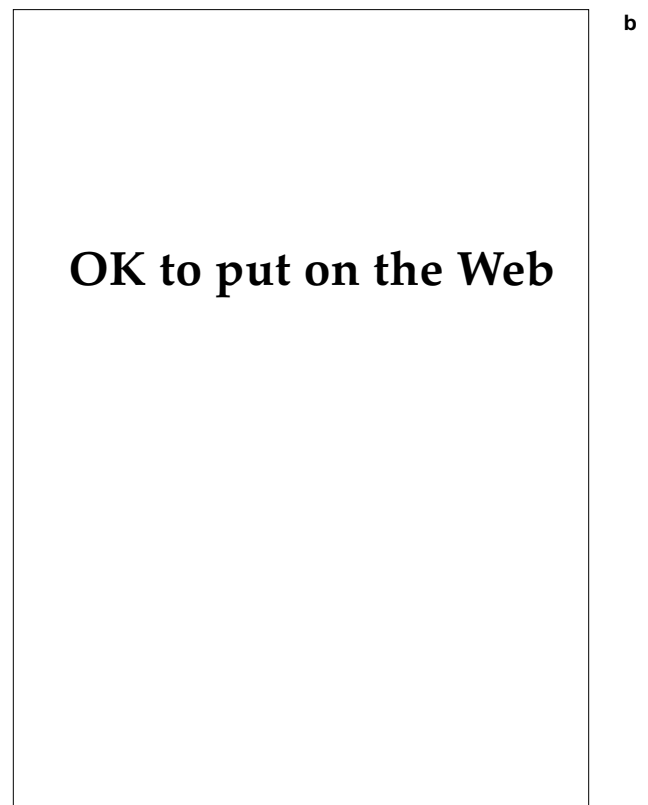
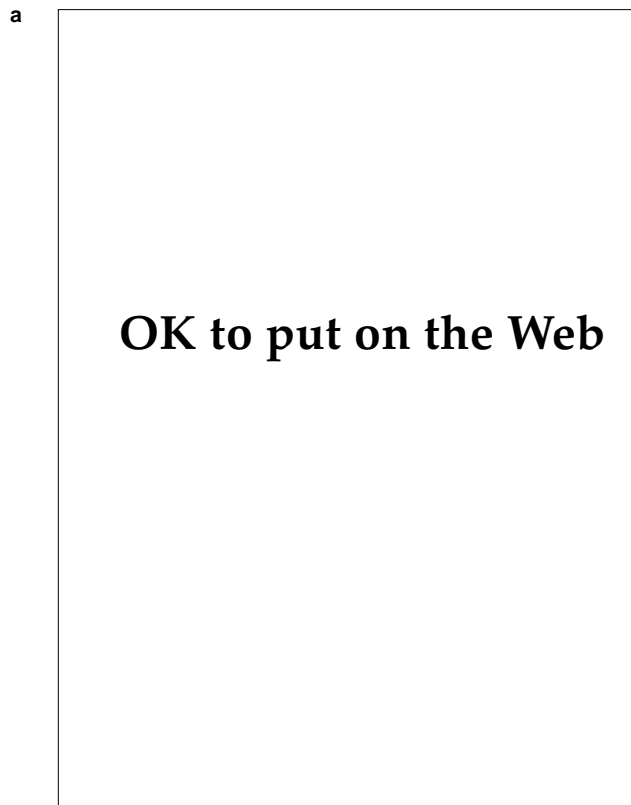
**Fig. 17-41.** This toluidine blue tape preparation demonstrates the yeast and short hyphae that are characteristic of pityriasis versicolor (original magnification 200X).



**Fig. 17-42.** This biopsy of pityriasis versicolor demonstrates the characteristic yeast and short hyphae (hematoxylin-eosin stain, original magnification 200X).

that may demonstrate a basket-weave (ie, slightly compact) appearance. The organisms are found in the stratum corneum and are often found in greater numbers near hair follicles (Figure 17-42). Occasionally, the organisms are difficult to visualize with hematoxylin-eosin stain, and special stains such as Gomori's methenamine silver or periodic acid-Schiff stain may be required to demonstrate them. Cultures are only required when a diagnosis of pityrosporum septicemia is suspected. Routine dermatologic media such as Sabouraud's or dermatophyte test medium do not support growth; the medical mycology technician must be informed that infection with *Pityrosporum* organisms is suspected so that a lipid source can be added to the medium.

*Pityrosporum* folliculitis is diagnosed based on the clinical presentation combined with a biopsy showing folliculitis and *Pityrosporum* yeast. The clinical features most suggestive of *pityrosporum* folliculitis are the characteristic distribution and associated pruritus. Microscopically, the organ-



**Fig. 17-43.** (a) This biopsy of *pityrosporum* folliculitis demonstrates acute folliculitis (hematoxylin-eosin stain, original magnification 100X). (b) The same tissue, stained with periodic acid-Schiff stain and digested with diastase (original magnification 200X), demonstrates budding yeast. The organisms are difficult to visualize with routine hematoxylin-eosin stains.



isms are always in the yeast phase and the short hyphae seen in pityriasis versicolor are absent. Special stains are frequently necessary to visualize the yeast, as they can be difficult to locate in the presence of severe inflammation (Figure 17-43).

### Treatment

Numerous treatments are reported to be effective for pityriasis versicolor; however, many topical therapies have a high rate of clinical relapse. Patients with focal or limited disease may be treated with topical antifungal agents (ie, an imidazole, ciclopirox olamine, naftifine, or tolnaftate) applied twice daily for 2 weeks. The cure rates achieved with these regimens are in the range of 80% to 90%.<sup>37</sup> However, these agents are relatively expensive and have a high relapse rate. Patients with extensive disease are most commonly treated with either selenium sulfide suspension applied daily for 10 to 30 minutes for 7 to 14 days or a zinc pyrithione shampoo applied daily for 5 minutes for 14 days. These regimens are inexpensive and have high cure rates; however, both regimens are associated with severe irritant reactions if the patient leaves the product on the skin for extended periods of time. As in the case of the topical imidazoles, relapses are common. Other effective topical agents include propylene glycol, sodium hyposulfite, sodium thiosulfate com-

bined with salicylic acid, salicylic acid preparations, and retinoic acid cream.

Oral ketoconazole is the most effective treatment of pityriasis versicolor. In addition to a high cure rate, it is associated with a much lower relapse rate. However, the development of idiosyncratic acute hepatitis reactions has prevented oral ketoconazole from replacing topical therapies as the first-line drug. Initial studies used 200 to 400 mg/d of oral ketoconazole for up to 4 weeks and reported high response rates. More-recent research has reported that a single, 400-mg dose cured 100% of patients, and that recurrences could be prevented by repeating this treatment on a monthly basis.<sup>38</sup> The author currently utilizes an intermediate dose of 200 mg/d for 7 days and does not use a prophylactic dose. Comparative studies are clearly needed to define the optimal dose.

The treatment options for pityrosporum folliculitis are almost the same as for pityriasis versicolor. Topical therapy with selenium sulfide lotion, 50% propylene glycol in water, and econazole cream have been reported equally efficacious when used for 3 to 4 weeks; however, if intermittent therapy was not continued, folliculitis frequently recurred.<sup>36</sup> Oral ketoconazole in a dose of 200 mg/d for 4 weeks is also effective, but the relapse rate approaches 100% and; therefore; it is not recommended for first-line therapy.<sup>39</sup>

## MISCELLANEOUS FUNGAL INFECTIONS

### *Tinea Nigra*

*Tinea nigra* is an uncommon superficial dermatomycosis produced by the dimorphic fungus *Exophiala werneckii* (formerly *Cladosporium werneckii*). *Exophiala werneckii* is a dematiaceous fungus that is commonly found in the soil and decaying vegetation. *Tinea nigra* is most commonly reported from subtropical and tropical climates, although occasional cases are acquired in the United States. This asymptomatic, rare infection is not important from a military standpoint. Other than the cosmetic appearance, it is only important in that it may be confused with acral lentiginous melanoma.<sup>40</sup>

Clinically, *tinea nigra* is characterized by asymptomatic gray, tan, brown, or black macular lesions on the palms or plantar surfaces, although, rarely, other sites are infected (Figure 17-44). The lesions are usually unilateral, although bilateral infection has been reported. Spontaneous resolution usually does not occur.<sup>41</sup>

The diagnosis is usually suspected based on clinical examination alone. The diagnosis can be confirmed by the demonstration of olivaceous, tortuous, septate hyphae associated with variable numbers of arthrospores on potassium hydroxide examinations of skin scrapings (Figure 17-45). The diagnosis also can be established by culturing skin scrapings on Sabouraud's medium at room temperature. Typical colonies are initially white or gray with a smooth surface but quickly turn olive or black with a downy edge. Occasionally, lesions are biopsied to rule out acral lentiginous melanoma. Histopathological examination reveals variable hyperkeratosis associated with hyphal elements that are located primarily in the upper stratum corneum. A superficial, perivascular, lymphocytic infiltrate is variably present.

Scraping the affected stratum corneum off with a surgical blade or abrasive cosmetic pad, followed by applying a topical imidazole or ciclopirox olamine, has been recommended as the treatment of

## OK to put on the Web

**Fig. 17-44.** A grayish-green macular lesion of tinea nigra can be seen on the palm of this 4-year-old child.

choice.<sup>41</sup> Other effective treatments include epidermal stripping, keratolytic agents, and thiabendazole. Oral griseofulvin does not appear to be an effective therapy.

### **Black Piedra**

Black piedra is a rare infection of terminal hairs produced by the dematiaceous fungus, *Piedraia hortae*. Black piedra is endemic in South America, although it has also been described in other tropical regions such as Africa and Asia. Familial infestations affecting multiple generations have been observed in endemic areas.<sup>42</sup> The disease is inconsequential in terms of its effect on military personnel.

The primary lesions are small, hard, ovoid, adherent, brown-to-black nodules that affect the scalp hairs. Black piedra produces broken hairs and does not spread to other terminal hairs; this is in contrast to the presentation of white piedra (discussed below).

The diagnosis can be suspected on the clinical presentation alone. The diagnosis can be firmly established by microscopical examination of the concretions, which demonstrate intertwined masses of brown hyphae surrounding an oval ascus that contains eight ascospores. Cultures on Sabouraud's agar demonstrate small, brown-to-black, adherent colonies.

The treatment of choice is removing infected hairs by either shaving or plucking. Recurrences are common in endemic areas.

### **White Piedra**

White piedra (also called trichosporosis) is an infection of the terminal hair shafts caused by

## OK to put on the Web

**Fig. 17-45.** This positive potassium hydroxide preparation of tinea nigra, taken from the palm depicted in Fig. 17-44, demonstrates the olivaceous, tortuous septate hyphae.

*Trichosporon beigeli* (formerly called *T cutaneum*). *Trichosporon beigeli* is a ubiquitous, yeastlike fungus that has been isolated from soil, air, stagnant water, and sewage. White piedra is endemic to tropical areas and formerly was thought to be uncommon in the United States. However, in a prospective study, researchers were able to isolate *T beigeli* in 40% of young men and 14% of young women in Houston, Texas.<sup>43</sup> These data suggest that white piedra is far more common than was formerly appreciated. Although cases have been reported in military personnel in San Antonio, Texas,<sup>44</sup> white piedra has not been reported to affect previous military campaigns.

Clinically, the primary lesions are typically white, although light-gray, red, brown, or greenish variants have also been observed. The concretions vary from distinct, ovoid nodules to coalescent concretions that totally coat the hair shaft. The nodules are softer and more easily removed than those seen in black piedra. The affected hairs are often straighter than the unaffected hairs. Cuticular invasion may occasionally produce broken hairs. The most commonly affected areas are the scalp, beard, moustache, and genital regions; less commonly affected areas are the eyelashes, eyebrows, and axillae. Rare manifestations of white piedra include onychomycosis and systemic dissemination in immunocompromised patients.

The diagnosis of white piedra may be suspected on the clinical appearance; however, trichomycosis caused by *Cornebacterium tenuis* may be clinically similar. A distinctive, dull-yellowish fluorescence is present under Wood's light examination; this may be a helpful diagnostic finding.<sup>39</sup> The

diagnosis can be confirmed by either a potassium hydroxide–glass-slide mount of an affected hair, which will demonstrate concretions composed of hyaline spores, or culture on Sabouraud’s dextrose agar at room temperature. Dermatophyte test medium and other media that contain cycloheximide should not be used

for isolation because cycloheximide will inhibit growth. The characteristic colonies are cream-colored, piled-up, and may demonstrate radial grooves.

The treatment of choice is shaving the affected hairs and applying a topical antifungal agent such as an imidazole or 10% glutaraldehyde.

## SUMMARY

Soldiers suffer from superficial cutaneous infections during both peace and war. During peacetime, the infections are mild and rarely produce significant morbidity; however, during wartime conditions, soldiers are exposed to more virulent strains of zoophilic and geophilic dermatophytes that are likely to induce an intense host response. When superficial fungal infections are combined with poor hygiene and hot, humid climates, combat units can be expected to suffer significant morbidity and loss of effective fighting strength—as was observed in the Asian theater during World War II and during the Vietnam conflict.

Medical officers, who may have to treat superfi-

cial fungal infections under field conditions, need to be familiar with the myriad of clinical manifestations. This is particularly important because adequate diagnostic equipment such as cultures, microscopes, and potassium hydroxide solution may not be readily accessible. Frequently, diagnosis and treatment must be initiated based on the clinical presentation.

The treatment options for the management of cutaneous fungal infections is becoming increasingly complex as new oral and topical antifungal agents are developed and released. Medical officers need to acquaint themselves not only with standard therapies but also with alternative therapies for resistant cases.

## REFERENCES

1. Matsumoto T, Ajello L. Current taxonomic concepts pertaining to the dermatophytes and related fungi. *Int J Dermatol*. 1987;26:491–499.
2. Macpherson WG, Horrocks WH, Beveridge WWO, eds. Skin diseases. In: *Medical Services: Hygiene of the War*. London, England: His Majesty’s Stationery Office; 1923: 68–72.
3. Pillsbury DM, Livingood CS. Dermatology. In: Havens WP Jr. *Infectious Diseases and General Medicine*. Vol 3. In: Anderson RS, ed. *Internal Medicine in World War II*. Washington, DC: US Government Printing Office; 1968: 568–607.
4. Sanderson PH, Sloper JC. Skin disease in the British Army in SE Asia. Part 2. Tinea corporis: Clinical and pathological aspects, with particular reference to the relationship between *T inderdigitale* and *T mentagrophytes*. *Br J Dermatol*. 1953;65:300–309.
5. Allen AM. Skin Diseases in Vietnam, 1965–72. In: Ognibene AJ, ed. *Internal Medicine in Vietnam*. Vol. 1. Washington, DC: Medical Department, US Army, Office of The Surgeon General, and Center of Military History; 1977.
6. Blank H, Taplin D, Zaias, N. Cutaneous *Trichophyton mentagrophytes* infections in Vietnam. *Arch Dermatol*. 1969;99:135–144.
7. Davis CM, Garcia KL, Riordon JP. Dermatophytes in military recruits. *Arch Dermatol*. 1972;105:558–560.
8. Bronson DM, Desai DR, Barsky S, Foley SM. An epidemic of infection with *Trichophyton tonsurans* revealed in a 20-year survey of fungal infections in Chicago. *J Am Acad Dermatol*. 1983;8:322–330.
9. Babel DE, Baughman SA. Evaluation of the adult carrier state in juvenile tinea capitis caused by *Trichophyton tonsurans*. *J Am Acad Dermatol*. 1989;21:1209–1212.

10. Joly J, Delage G, Auger P, Ricard P. Favus: Twenty cases of indigenous cases in the province of Quebec. *Arch Dermatol*. 1978;114:1647–1648.
11. Allen AM, Taplin D. Epidemic *Trichophyton mentagrophytes* infections in servicemen: Source of infection, role of environment, host factors, and susceptibility. *JAMA*. 1973;226:864–867.
12. Gentry R, Tribelhorn D, Fitzpatrick JE. Atypical dermatophytosis acquired in the tropics. *J Assoc Mil Dermatol*. 1988;14:17–18.
13. Tanenbaum L, Taplin D, Lavelle C, Akers WA, Rosenberg MJ, Carmargo G. Sulconazole nitrate cream 1 percent for treating tinea cruris and corporis. *Cutis*. 1989;44:344–347.
14. Leyden JJ, Kligman AM. Interdigital athlete's foot: The interaction of dermatophytes and resident bacteria. *Arch Dermatol*. 1978;114:1466–1472.
15. André J, Achten G. Onychomycosis. *Int J Dermatol*. 1987;26:481–490.
16. Lefler E, Haim S, Merzbach D. Evaluations of direct microscopic examination versus culture in the diagnosis of superficial fungal infections. *Mykosen*. 1981;24:102–106.
17. Loenenthal K. Seventy per cent ethyl alcohol as skin cleanser for fungus culture. *Arch Dermatol*. 1964;89:725–729.
18. Strauss JS, Kligman A. An experimental study of tinea pedis and onychomycosis of the foot. *Arch Dermatol*. 1957;76:70–79.
19. Lambert DR, Siegle RJ, Camisa C. Griseofulvin and ketoconazole in the treatment of dermatophyte infections. *Int J Dermatol*. 1989;28:300–304.
20. Allen HB, Honig PJ, Leyden JJ, McGinley KJ. Selenium sulfide: Adjunctive therapy for tinea capitis. *Pediatrics*. 1982;69:81–83.
21. Robertson MH, Rich P, Parker F, Hanifin JM. Ketoconazole in griseofulvin-resistant dermatophytosis. *J Am Acad Dermatol*. 1982;6:224–229.
122. VanDersarl JV, Sheppard RH. Clotrimazole vs haloprogin treatment of tinea cruris. *Arch Dermatol*. 1977;113:1233–1235.
23. Zaias N, Battistini F, Gomez-Urcuyo F, Rojas RF, Ricart R. Treatment of "tinea pedis" with griseofulvin and topical antifungal cream. *Cutis*. 1978;22:196–199.
24. Leyden JJ, Kligman AM. Aluminum chloride in the treatment of symptomatic athlete's foot. *Arch Dermatol*. 1975;111:1004–1010.
25. Qadripur SA, Horn G, Höhler T. Aur localwirksamkeit von ciclopiroxolamine bei nagelmykosen. *Arzneim Forsch*. 1981;31:1369–1372.
26. Klaschka F. Treatment of onychomycosis with naftifine gel. *Mykosen*. 1987;30(suppl 1):119–123.
27. Hersle K, Moberg H, Moberg S. Long-term ketoconazole treatment of chronic acral dermatophyte infections. *Int J Dermatol*. 1985;24:245–248.
28. South DA, Farber EM. Urea ointment in the nonsurgical avulsion of nail dystrophies—A reappraisal. *Cutis*. 1980;25:609–612.
29. Dreizen S. Oral candidiasis. *Amer J Med*. 1984;77(4D):28–33.

30. Rebora A, Marples RR, Kligman AM. Erosio interdigitalis blastomycetica. *Arch Dermatol*. 1973;108:66–68.
31. Macura AB. Fungal resistance to antimycotic drugs: A growing problem. *Int J Dermatol*. 1991;30:181–184.
32. Kirkpatrick CH, Alling DW. Treatment of chronic oral candidiasis with clotrimazole troches. *N Engl J Med*. 1978;299:1201–1203.
33. Fredriksson T, Faergemann J. Semantics—Tinea versus pityriasis versicolor and *Pityrosporum orbiculare* versus *Malassezia furfur*. Which is proper? *Int J Dermatol*. 1984;23:110–111.
34. Faergemann J, Fredriksson T. Experimental infections in rabbits and humans with *Pityrosporum orbiculare* and *P ovale*. *J Invest Dermatol*. 1981;77:314–318.
35. Pillsbury DM, Hurley HJ. *Dermatology*. Philadelphia, Pa: WB Saunders; 1975: 621.
36. Bäck O, Faergemann J, Hörnqvist R. *Pityrosporum* folliculitis: A common disease of the young and middle-aged. *J Am Acad Dermatol*. 1985;12:56–61.
37. Quiñones CA. Tinea versicolor: New topical treatments. *Cutis*. 1980;25:386–388.
38. Rausch LJ, Jacobs PH. Tinea versicolor: Treatment and prophylaxis with monthly administration of ketoconazole. *Cutis*. 1984;34:470–471.
39. Ford GP, Ive FA, Midgley G. *Pityrosporum* folliculitis and ketoconazole. *Br J Dermatol*. 1982;107:691–695.
40. Babel DE, Pelachyk JM, Hurley JP. Tinea nigra masquerading as acral lentiginous melanoma. *J Dermatol Surg Oncol*. 1986;12:502–504.
41. Sayegh-Carreño R, Abramovits-Ackerman W, Girén GP. Therapy of tinea nigra plantaris. *Int J Dermatol*. 1989;28:46–48.
42. Adam BA, Soo-Hoo TS, Chong KC. Black piedra in West Malaysia. *Aust J Dermatol*. 1977;18:45–47.
43. Kalter DC, Tschen JA, Cernoch PL, et al. Genital white piedra: Epidemiology, microbiology, and therapy. *J Am Acad Dermatol*. 1986;14:982–993.
44. Coquilla BH, Kraus EW. Trichosporosis (white piedra): Four cases in the United States. *J Assoc Mil Dermatol*. 1983;9:27–29.

# Chapter 18

## DEEP FUNGAL SKIN DISEASES

SCOTT A. NORTON, M.D., M.Sc., M.P.H.\*

---

### INTRODUCTION

#### SYSTEMIC MYCOSES

- Histoplasmosis and Histoplasmosis Duboisii
- Coccidioidomycosis
- Blastomycosis
- Paracoccidioidomycosis

#### SUBCUTANEOUS MYCOSES

- Sporotrichosis
- Chromoblastomycosis
- Mycetoma
- Lobomycosis
- Rhinosporidiosis

#### OPPORTUNISTIC MYCOSES AND MISCELLANEOUS INFECTIONS

- Cryptococcosis
- Entomophthoramycosis
- Actinomycosis
- Nocardiosis

### SUMMARY

\*Major, Medical Corps, U.S. Army; Assistant Chief, Dermatology Service, Tripler Army Medical Center, Honolulu, Hawaii 96859

## INTRODUCTION

Fungal infections of humans are divided somewhat arbitrarily into the *superficial* mycoses and the *deep* mycoses. The superficial mycoses, such as the dermatophyte infections, are generally confined to the surface of the skin and hair and are discussed in Chapter 17, Superficial Fungal Skin Diseases. The deep mycoses, discussed here, are fungal infections that regularly involve the dermis and subcutaneous tissues, and often other organ systems. Although deep fungal infections are seen most often in particular geographical locations, the diseases' natural distributions are not necessarily confined there (Exhibit 18-1). Even within an endemic focus, a disease (eg, rhinosporidiosis) may still be uncommon. Other diseases (eg, sporotrichosis) are probably ubiquitous but have hyperendemic foci. Still others (eg, coccidioidomycosis) are acquired only within their specific endemic areas. Our knowledge of the geographical distributions of mycoses depends to some extent on the abilities of local laboratories to detect the pathogens, and on local differences in disease-reporting requirements.

Deep fungal disease is usually acquired via either (a) inhalation of fungal spores or (b) direct inoculation of the fungus into the skin. Depending on the route of entry, some generalizations can be made on the resulting diseases. Inhalation of pathogenic spores may produce a primary pulmonary infection that resembles a transient, flulike illness. Patients usually recover uneventfully but secondary dissemination to skin is not uncommon. It is from the cutaneous lesions that the diagnosis of a systemic fungal infection is often made (Figure 18-1). Prompt recognition is important because untreated disseminated disease is often fatal. The other common route of acquisition is direct inoculation of the pathogenic fungus via minor, often unnoticed, skin trauma. Again, some generalizations can be made. Some fungi produce granulomatous or verrucous plaques that expand around the initial site of implantation; other fungi produce subcutaneous masses that can spread along lymphatic channels or cause chronic swelling and deformity.

Based on their route of entry, deep fungal diseases can be further divided into the *systemic* mycoses and the *subcutaneous* mycoses. Although this is an artificial classification, it reflects a clinically useful approach to the diagnosis of the deep mycoses. It is important to note that this scheme ignores true taxonomic relationships among the

fungi. Indeed, this scheme historically has embraced some bacterial diseases under the rubric of the deep mycoses because of the similarity of their clinical presentations. Because pharmacological therapy of these diseases corresponds more closely with taxonomy than with the clinical syndromes, it is important to recognize the discordance between the clinical and phylogenetic classification systems in medical mycology.

In the wild, the pathogenic fungi usually dwell in the soil or on plants as saprophytes. They are inconspicuous, usually microscopical, and are often undetected in their natural state. Humans are not essential for the life cycle of any deep fungal

### EXHIBIT 18-1

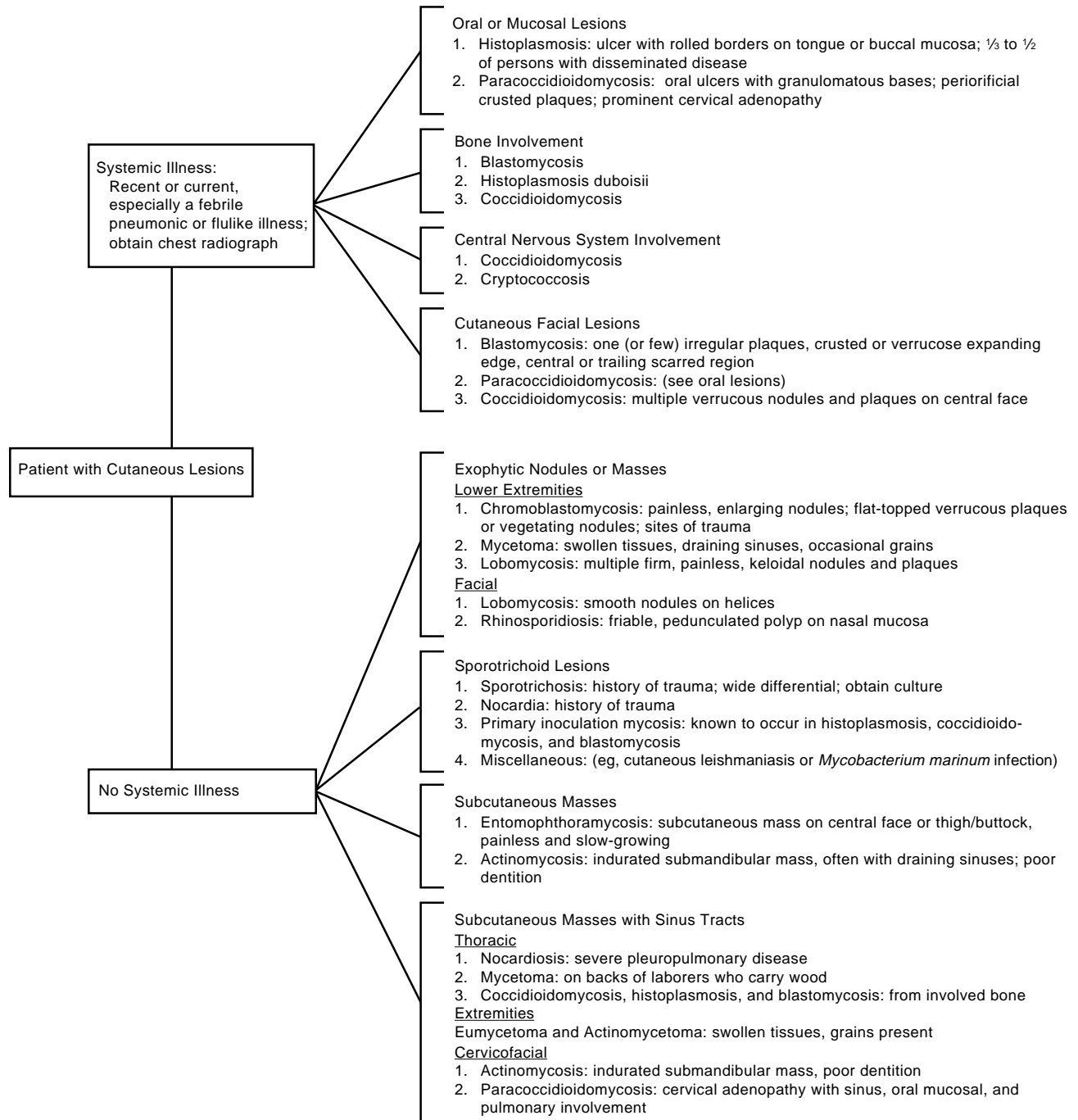
#### PRINCIPAL GEOGRAPHICAL LOCATIONS OF DEEP FUNGAL DISEASES

##### Systemic Mycoses

- Histoplasmosis
  - Mississippi and Ohio River valleys
  - Panama
  - Northern South America
- Histoplasmosis duboisii
  - Tropical Africa
- Coccidioidomycosis
  - Southwestern United States
  - Northwestern Mexico
- Blastomycosis
  - South-central United States
  - Great Lakes region
- Paracoccidioidomycosis
  - South America, especially Brazil

##### Subcutaneous Mycoses

- Sporotrichosis
  - Oklahoma
  - Mexico, Brazil, Japan, South Africa
- Chromoblastomycosis
  - Pantropical
- Mycetoma
  - Mexico, India, northeast Africa
- Lobomycosis
  - Amazon River basin
- Rhinosporidiosis
  - India, Sri Lanka



**Fig. 18-1.** Algorithm for the clinical diagnosis of deep fungal diseases. The clinical presentation of cutaneous lesions and any systemic symptoms can be used to suggest a diagnosis. Deep fungal infections that are typically systemic (eg, histoplasmosis) may occur in a sporotrichoid fashion following an inoculation injury. Conversely, infections that are usually confined to the skin and subcutaneous tissues (eg, sporotrichosis) occasionally occur as serious systemic illnesses. Seemingly isolated cutaneous lesions may be the presenting sign of an otherwise subclinical systemic infection, particularly in blastomycosis. The diagnosis of any suspected deep fungal infection must be confirmed by identification of the pathogen by direct examination of tissue specimen, biopsy, culture, or serologic assay. In patients with disseminated histoplasmosis, cryptococcosis, or sporotrichosis, the physician must consider an underlying immunosuppressive condition (eg, infection with human immunodeficiency virus, chemotherapy, malignancy).



pathogen and become infected only incidentally. Once inside a host, the fungus can undergo a dramatic morphologic transformation to cause the conditions described in this chapter.

Several of the systemic mycoses with epidemic potential have been implicated in occupationally

related outbreaks. To date, however, the deep mycoses have not significantly influenced military operations. Nevertheless, outbreaks typically occur in environmentally disturbed areas and therefore armies on the move will continue to encounter some risk from these diseases.

## SYSTEMIC MYCOSES

There are four systemic mycoses: histoplasmosis (including histoplasmosis duboisii), coccidioidomycosis, blastomycosis, and paracoccidioidomycosis. Each disease has a distinctive ecological and geographical distribution (see Exhibit 18-1). Infections begin when persons inhale fungal spores into their lungs. There, the spores convert to their thermophilic, pathogenic, yeastlike phase, which causes a primary pulmonary infection. Initial infections are often asymptomatic or may cause a transient, flulike illness. Unrecognized or subclinical infections are very common in endemic areas. Sometimes a severe lung disease develops or the infection may spread to other organs, with a frequent predilection for skin. Indeed, for many years, several systemic mycoses were known only from their cutaneous manifestations.

### Histoplasmosis and Histoplasmosis Duboisii

Histoplasmosis is also called Darling's disease, spelunker's disease, cave disease, Ohio Valley disease, and cytomycosis. Histoplasmosis duboisii is also called African histoplasmosis.

Histoplasmosis is probably the most common systemic mycosis in the world. In the United States alone, perhaps 30 to 40 million persons are infected.<sup>1</sup> Most infections are clinically inapparent; however, because of its prevalence, the disease has the greatest morbidity of any systemic mycosis. Infection is acquired by inhaling the spores of *Histoplasma capsulatum* and is established most importantly in the lungs. Cutaneous manifestations arise uncommonly from disseminated infection. *Histoplasma duboisii* is the pathogen in central Africa.

*Histoplasma capsulatum* is a thermally dimorphic fungus that assumes its mycelial phase in nature and in culture at room temperature. In tissue and in warmer cultures, the yeast form predominates. Yeast, 2 to 4  $\mu\text{m}$  in diameter, are phagocytized but not killed by host macrophages. The apparent capsule seen on histological sections is an artifact and the epithet, *capsulatum*, a misnomer. The fungus has a sexual (ie, perfect) state, an ascomycete,

*Emmonsiiella capsulata* (synonym *Ajellomyces capsulatus*). *Histoplasma duboisii* (syn *H capsulatum* variety *duboisii*) has larger yeast, about 7 to 15  $\mu\text{m}$ .<sup>2</sup>

### History

In December 1905, Samuel Taylor Darling, an American pathologist working for Colonel William Gorgas at Ancon (later Gorgas) Hospital in the Panama Canal Zone, first encountered histoplasmosis. While performing an autopsy on a canal laborer from Martinique, he noted intracellular organisms in many tissues. Darling named the organism *Histoplasma capsulata* [*sic*] because of its location within histiocytes (*Histo-*), its resemblance to plasmodia (*-plasma*), and its encapsulated appearance (*capsulata*).<sup>3</sup> He later masculinized the specific epithet, *capsulatum*, to achieve nomenclatural agreement. Two additional autopsies with similar findings convinced Darling that he had found a new form of visceral leishmaniasis.<sup>4</sup>

Mortality rates among canal workers were extraordinary. Most deaths were caused by pneumonia and the mosquito-borne diseases, yellow fever and malaria.<sup>5</sup> The morbidity of undiagnosed histoplasmosis among the canal workers remains undetermined. Nearly 50 years passed before the next case of histoplasmosis in Panama was reported,<sup>6</sup> although the disease is now known to be common there.<sup>7</sup>

After reviewing Darling's original slides, a Brazilian pathologist, Henrique da Rocha-Lima, determined that *Histoplasma* was more akin to yeasts than to protozoa.<sup>8</sup> Its fungal nature was confirmed by culturing organisms that were recovered from the blood of an infant dying of an unexplained febrile illness.<sup>9</sup> Until a benign form of the infection was recognized during the 1940s, histoplasmosis was considered a uniformly fatal, primarily tropical, disease. During the early 1950s, *H capsulatum* was detected in calcified pulmonary nodules resected from healthy soldiers at Fitzsimons Army Hospital in Colorado.<sup>10</sup> The true geographical range, prevalence, and usual benignity of histoplasmosis

were further clarified by skin testing large groups with histoplasmin and by recovering *H capsulatum* from the soil.

Several outbreaks of acute pulmonary histoplasmosis have occurred in military units training in tropical areas but cutaneous manifestations have not been reported. While training in Panama, 27 of 47 U.S. soldiers (57%), who had cleaned out and then slept in an abandoned bunker, contracted acute pulmonary histoplasmosis. The bunker, inhabited by a colony of bats, had several inches of mixed soil and bat guano (ie, excrement) on the floor. The soldiers' sweeping of the floor had aerosolized the spores of *Histoplasma*, which permitted their inhalation. The severity of the soldiers' illnesses corresponded roughly to the duration of exposure to the aerosolized dust.<sup>11</sup>

During 1977, 8 soldiers in a 35-man engineering unit who were returning from training exercises in Panama suddenly developed fevers. Initial evaluations were unrevealing, leading to a presumptive diagnosis of an arboviral disease, but histoplasmosis was confirmed by complement fixation. The exposure probably occurred while the soldiers cleaned an abandoned Spanish fort that was inhabited by bats.<sup>12</sup>

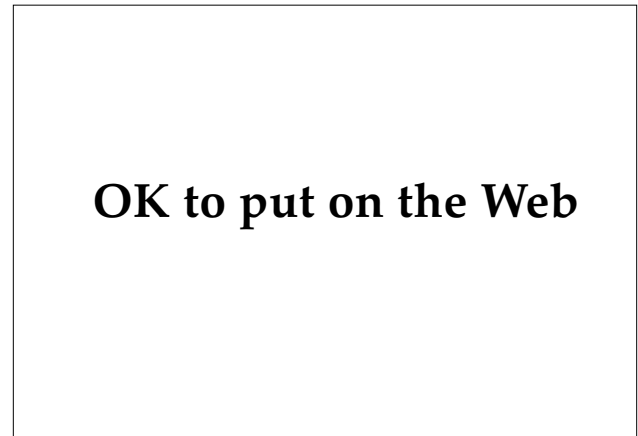French and Dutch soldiers serving in colonial French Guiana and Surinam (now Suriname), respectively, occasionally contracted histoplasmosis. Symptomatic illnesses were usually first diagnosed as acute pulmonary tuberculosis. Exposures presumably occurred in bunkers and old huts where bat guano had accumulated.<sup>13,14</sup>

At Chanute Air Force Base, Illinois, there was an outbreak of acute pulmonary histoplasmosis in 10 persons, most of whom had not lived previously in endemic areas. *Histoplasma* had colonized soil in the gardens and orchards around their housing development.<sup>15</sup>

### *Distribution and Epidemiology*

Histoplasmosis occurs worldwide but is hyperendemic along the Mississippi and Ohio River valleys (Figure 18-2). Histoplasmin skin tests and chest radiographs showing calcified granulomata suggest nearly universal infection in residents of these areas. Additional foci occur in Panama and northern South America, Australia, Indonesia, India, South Africa, the Mediterranean, and western Europe.<sup>14</sup> Histoplasmosis *duboisii* occurs in tropical Africa.

The organism is a saprophyte found in soil laden with excreta of bats or birds. Therefore, habitats with guano accumulations, for example, caves and



**Fig. 18-2.** Histoplasmosis is hyperendemic in this North American region. The distribution corresponds roughly to the areas drained by the Mississippi and Ohio rivers.

chicken coops, are consistent sources of infection. Occupations and recreations (eg, chicken farming, spelunking, pigeon breeding) that expose people to these niches predispose for infection. In tropical areas, bats are the usual reservoir of histoplasmosis. They, unlike birds, naturally become ill with infection. The microenvironment in their caves is suitable for the growth of *Histoplasma*, whereas the surrounding environment apparently is not.<sup>16</sup> In temperate regions, outbreaks have occurred in residential areas where excrement from starlings, grackles, blackbirds, pigeons, or other birds accumulates beneath roosting sites.

### *Clinical Manifestations*

Histoplasmosis is acquired when a person inhales spores into the lungs, where the spores convert to their yeast forms. In heavily endemic areas, perhaps 95% of the population has been infected, albeit usually with asymptomatic disease or a self-limited, mild, flulike illness. The erythema nodosum and erythema multiforme that sometimes accompany acute disease are probably hypersensitivity reactions.<sup>17</sup> Acute pulmonary infections typically produce inactive, calcified, pulmonary granulomas and transient immunity to further bouts of histoplasmosis. Persons with underlying lung disorders are susceptible to chronic cavitary histoplasmosis. Its clinical and radiographic features resemble pulmonary tuberculosis and may be fatal if untreated.<sup>1</sup>

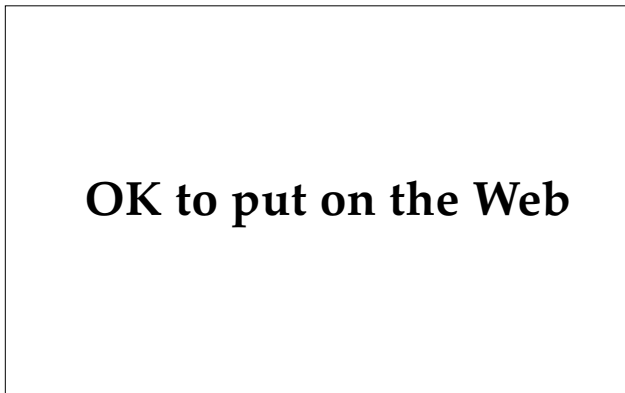Hematogenously disseminated histoplasmosis occurs in 1 of 2,000 to 5,000 acute infections and has

a predilection for immunocompromised, elderly, or very young persons.<sup>18</sup> The organisms enter reticuloendothelial organs, such as liver, spleen, lymph nodes, and bone marrow. Infants, in particular, can have a fulminant illness with fungemia characterized by fever, hepatosplenomegaly, and pancytopenia. Their peripheral smears may reveal yeast cells. In adults, disseminated disease has a more protracted course, often localizing in the bone marrow. Subsequent involvement of the meninges, endocardium, or adrenal glands is insidious but potentially lethal.<sup>18</sup> Disseminated histoplasmosis in a person infected with the human immunodeficiency virus (HIV) meets the Centers for Disease Control and Prevention's (CDC's) definition of acquired immunodeficiency syndrome (AIDS).<sup>19</sup>

Oropharyngeal lesions are the most common dermatologic sign, found in one third to one half of disseminated cases (see Figure 18-1). When present, they are often the only clinical manifestation of the disease. Oral papules or nodules typically erode, forming ulcers with prominent rolled borders (Figure 18-3). In order of their frequency, the affected sites are the tongue, buccal mucosa, larynx, lip, and gingiva.<sup>1</sup>

Skin lesions, none distinctive, occur in only 5% of patients with disseminated disease (Figure 18-4). Reported lesions include papules, plaques, ulcers, abscesses and furuncles, panniculitis, purpura, eczema, and erythroderma.<sup>17</sup>

African histoplasmosis differs from classic American histoplasmosis because its pulmonary symptoms are less severe, whereas bony and skin lesions are more common. The most common cutaneous lesions are hypopigmented, dome-shaped papules surrounded by hyperpigmented halos, giving them



**Fig. 18-3.** This man has disseminated histoplasmosis. Note the shallow ulcer on his oral mucosa.

## OK to put on the Web

**Fig. 18-4.** Granulomatous plaque of cutaneous histoplasmosis. Cutaneous lesions of disseminated histoplasmosis have varied, nondistinctive morphologies but they can be diagnostic on either culture or histopathology. Photograph: Courtesy of William E. Dismukes, MD, Birmingham, Ala.

a targetlike appearance. These heal with scarring. Subcutaneous abscesses and draining sinuses arising from lymph nodes or underlying osteomyelitic foci are less common but still characteristic of the disease.<sup>20,21</sup>

Rare cases of primary inoculation cutaneous histoplasmosis have followed laboratory accidents or environmental inoculation.<sup>22</sup> A noduloulcerative lesion arises at the implantation site, followed by lymphangitis and a chain of lymphocutaneous nodules. Except for its spontaneous resolution, the clinical features resemble lymphocutaneous sporotrichosis.

### Diagnosis

*H capsulatum* can be found within parasitized macrophages of involved organs (Figure 18-5). Similarly sized, intracellular parasites also occur in granuloma inguinale, rhinoscleroma, and leishmaniasis. Each may also affect mucocutaneous regions, but only *H capsulatum* picks up fungal stains. Direct examination of Giemsa- or Wright-stained smears of sputum, pus, skin or ulcer scrapings (Tzanck preparation), Buffy-coat smears, or other materials may reveal *Histoplasma*.<sup>17,23,24</sup> Culture has the highest yield with material aspirated from bone marrow but is often positive when performed on skin, blood, and other tissues.<sup>18</sup> Skin testing with histoplasmin is useful mainly as an epidemiological tool, and is often falsely negative in persons with cutaneous or otherwise dissemi-

## OK to put on the Web

**Fig. 18-5.** This photomicrograph shows infection of the skin. The yeast forms have been consumed by host macrophages. The unstained rim around the organisms gives the illusion of a capsule, although a true capsule does not exist (hematoxylin-eosin stain, original magnification 430X). Photograph: Courtesy of Colonel James E. Fitzpatrick, Medical Corps, US Army, Aurora, Colo.

nated disease. Investigational radioimmunoassays that detect *Histoplasma* polysaccharide antigen in the urine are rapid and sensitive.<sup>25</sup> Serologic tests are not the subject of this chapter but are reviewed in detail elsewhere.<sup>18</sup>

### Treatment

Except in cases of primary inoculation histoplasmosis, cutaneous lesions signify disseminated disease. Accordingly, these patients require aggressive treatment. For severe disease, intravenous amphotericin B should be administered at 25 to 35 mg/d for a total of 2 g over approximately 6 weeks. Immunocompetent patients with mild infections that do not involve the central nervous system may receive the fungistatic agent, ketoconazole, on an outpatient regimen of 400 mg daily, administered orally. Mild, acute, pulmonary infections resolve spontaneously and require no therapy.<sup>18,26,27</sup>

### Military Implications

Cutaneous histoplasmosis is unlikely to interfere with military operations. Outbreaks of acute pulmonary disease will continue to occur whenever immunologically naive soldiers enter endemic areas. Caution should be exercised on entering caves and sheltered areas such as old bunkers, especially in the tropics. Care not to disturb dusty soil laden

with bat or bird excrement may help prevent outbreaks of histoplasmosis.<sup>24</sup>

### Coccidioidomycosis

Coccidioidomycosis has a well-recognized ecological and geographical distribution: it is endemic in certain arid and semiarid regions throughout the Americas, especially in the southwestern United States. Coccidioidomycosis is acquired by inhaling the arthrospores of *Coccidioides immitis* or, rarely, by percutaneous inoculation of the spores. Primary pulmonary infections are usually inapparent or produce a transient, flulike illness. Disseminated disease is uncommon but, when present, frequently has cutaneous lesions. Coccidioidomycosis is also called San Joaquin Valley Fever, Posada's disease, valley fever, coccidioidal granuloma, and desert fever.

*C immitis* is a dimorphic fungus that exists in nature as a soil saprophyte. The mycelia produce spores (or arthroconidia) that are easily wind-blown and are infectious when inhaled. In tissue, the organisms develop into specialized, thick-walled structures called spherules. Mature spherules are large, (10–) 30 to 60 (–80)  $\mu\text{m}$  in diameter, with internal septae separating numerous endospores. When a spherule ruptures, endospores discharge into surrounding tissue. External budding, as seen in other systemic mycoses, does not occur.<sup>2</sup>

### History

Coccidioidomycosis was first described in 1892 in an Argentinean cavalryman stationed in the Gran Chaco of northern Argentina. An unexplained sore developed on his cheek and was unresponsive to treatment. The lesion grew more warty so he was transferred to the University Hospital Clinics in Buenos Aires. There, a 21-year-old intern, Alejandro Posadas, evaluated the patient and discovered the characteristic spherules of coccidioidomycosis, describing them as protozoa.<sup>28</sup> A few years later, the organism was isolated from several patients in California with widespread, destructive skin lesions. It was named *Coccidioides* for its superficial resemblance to the avian parasite, *Coccidia*. The epithet, *immitis*, meaning "not mild," reflects the early impression that coccidioidomycosis was nearly always fatal.

Further investigations in the San Joaquin Valley in the 1930s determined that the flulike condition known locally as valley fever was, in fact, benign primary pulmonary coccidioidomycosis.<sup>29</sup> When the U.S. Army Air Corps elected to train aviators there, concerns were raised over bringing nonexposed

individuals into a highly endemic area. Despite the efforts of the military physicians who served as coccidioidomycosis control officers at each airfield, the disease caused significant interruptions in training. Coccidioidomycosis particularly hampered preparations for the World War II North Africa campaign conducted at the U.S. Army's Desert Training Center (west of Twenty-Nine Palms, California, near the Arizona border) and several sites in southern California and Arizona. Prisoner-of-war camps housing Japanese, German, and Italian soldiers in Florence, Arizona, and San Luis Obispo, California, also experienced outbreaks. The foundation of the modern understanding of coccidioidomycosis emerged from the effects of this disease on the U.S. military during World War II and the medical departments' epidemiological and preventive medicine responses.<sup>30</sup>

Military installations in Arizona and California continue to experience high rates of lost man-days due to pulmonary coccidioidomycosis.<sup>31</sup> Active military bases that have reported disease or serologic evidence of infection include Twenty-Nine Palms Marine Corps Base, Lemoore Naval Air Station, Edwards Air Force Base, and Fort Irwin, all in California; Chandler Air Force Base, Davis–Monthan Air Force Base, Luke Air Force Base, and Williams Air Force Base, all in Arizona; and Fort Bliss, Texas.<sup>32–34</sup> In addition, personnel from the Norwegian, Belgian, and German military have acquired coccidioidomycosis during training exercises in the American Southwest.<sup>35–37</sup>

### Epidemiology

Approximately 100,000 new cases of coccidioidomycosis occur in the United States each year, most during periods when dry, dusty winds carry the spores aloft. Occupational and recreational activities that expose persons to dusty soils are risk factors for coccidioidomycosis. Agricultural workers, military units, outdoor construction workers, and archeological teams repeatedly have been involved in point (ie, localized, single-occasion) outbreaks.<sup>38,39</sup> California's workmen's compensation laws recognize coccidioidomycosis as an occupational illness.

Risk factors for systemic disease include race, gender, and, possibly, pregnancy.<sup>38,40</sup> The propensity for severe disease is greater in nonwhites than in whites. This disparity is severalfold greater for Mexicans and Native Americans and considerably more so for blacks and Filipinos.<sup>31</sup> The reasons for this are not well understood. Socioeconomic factors (eg, occupational exposures and nutritional status)

do not entirely account for the differences. In general, the disease is more often self-limited in females than in males. In contrast, the hormonal milieu and mild immunosuppression associated with pregnancy may permit vigorous growth of the fungus. Infants, the elderly, and persons with blood types B or AB also may be at increased risk for severe disease.<sup>31</sup>

### Distribution

*C immitis* is tolerant of a wide range of environmental conditions but competes poorly with other microorganisms in fertile soils. Therefore, *C immitis* is most abundant in soils too dry and dusty for more fastidious fungi. Also, once lands are under cultivation, other soil fungi displace *C immitis*. In North America, coccidioidomycosis occurs primarily in the Lower Sonoran life zone, which is characterized by semiarid conditions; hot summers; mild winters; and alkaline, sandy soils (Figure 18-6). Plants typically found in this habitat include creosote, yucca,

## OK to put on the Web

**Fig. 18-6.** *Coccidioides immitis* occurs naturally in the dusty soils of the Lower Sonoran life zone. Ocotillo (the long, wiry-branched shrub) and several types of cacti (saguaro, cholla, and prickly pear) typify this ecosystem, seen here in the Saguaro National Monument near Tucson, Ariz.

## OK to put on the Web

**Fig. 18-7.** The geographical distribution of coccidioidomycosis. Infection with *Coccidioides immitis* is not known to have occurred naturally outside the Americas.

mesquite, ocotillo, and several types of cacti (saguaro, cholla, prickly pear). Hyperendemic foci are scattered throughout central California's San Joaquin Valley, the southwestern United States, and northwestern Mexico (Figure 18-7). The disease also occurs infrequently in several locations in Central and South America. The disease is not transmissible between humans and there are no reliable reports of coccidioidomycosis acquired outside the Americas. Mammals other than humans are susceptible to infection.<sup>31,38</sup>

### Clinical Manifestations

Coccidioidomycosis follows inhalation of dust laden with spores of *C immitis*. After an incubation period of 1 to 4 weeks, a primary pulmonary infection develops. Perhaps 60% of newly acquired cases are asymptomatic.<sup>40</sup> The others experience symptoms ranging from a flulike syndrome with mild fevers to severe pneumonitis with cough, fever, chest pain, dyspnea, chills, and night sweats. Typically, symptomatic illnesses completely resolve.

Several nonspecific cutaneous findings are associated with early coccidioidomycosis. A transient

morbilliform or scarlatiniform erythema may accompany the early symptoms in children, adolescents, and 10% of adults. Several weeks later, a syndrome (Valley Fever), more common in women and white people, develops.<sup>29</sup> It affects approximately 25% of infected white women and 10% of infected white men.<sup>38</sup> Erythema nodosum or, less commonly, erythema multiforme may occur, indicating the host's strong immunological response and decreased risk for disseminated disease. Nonmigratory arthralgias (eg, desert rheumatism) occur in one third of patients.<sup>38</sup>

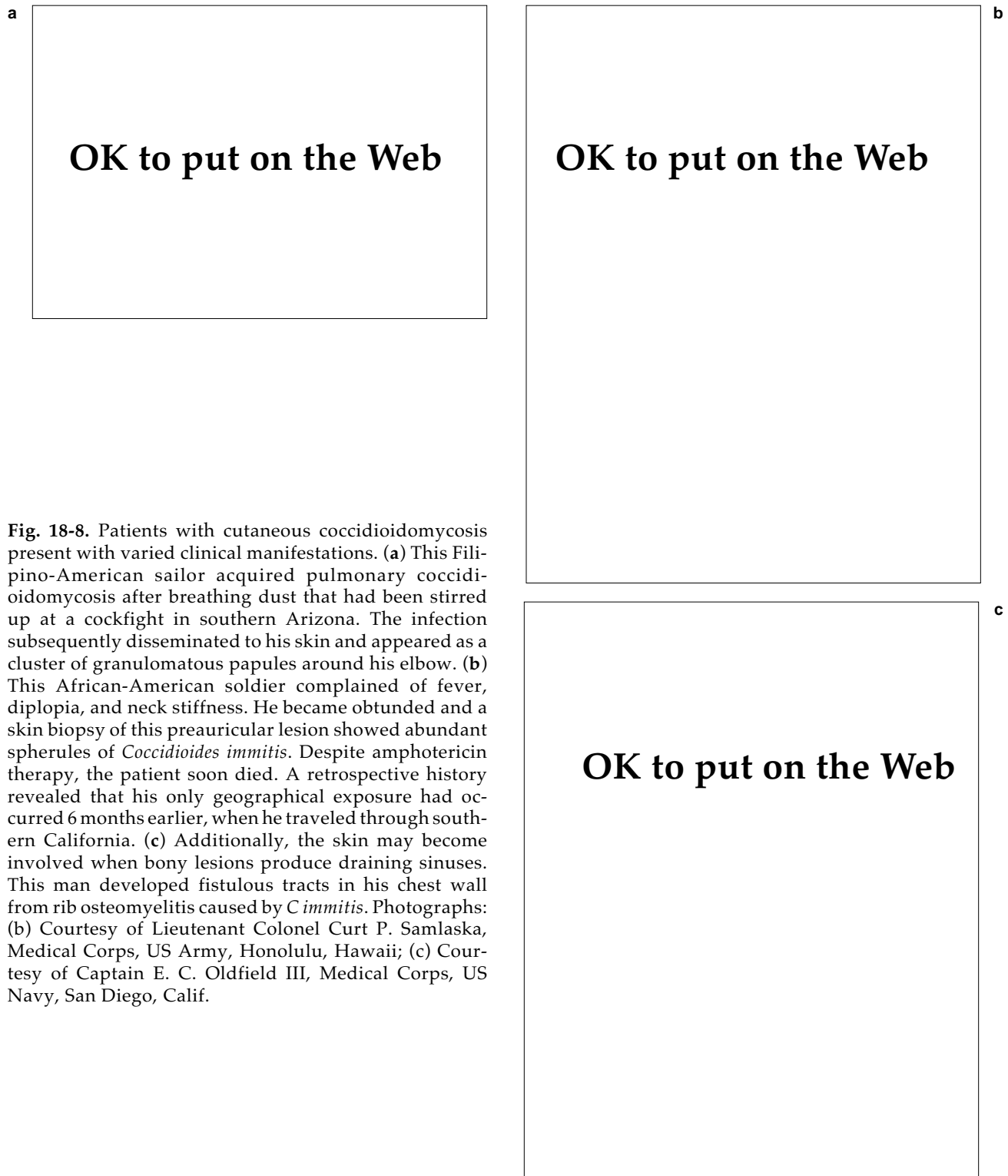
Extrathoracic disease occurs in fewer than 1% of infections, more commonly in the ethnic groups noted above. Target organs for disseminated infection include skin and subcutaneous tissues, bones, and the meninges.<sup>40</sup> Fatalities, approximately 60 per year in the United States,<sup>31</sup> are usually the result of severe involvement of the lungs or central nervous system.

Skin lesions with recoverable coccidioidomycosis organisms occur in 15% to 20% of patients with disseminated disease (Figure 18-8). Papules typically evolve into verrucous nodules or plaques. Plaques frequently occur in the center of the face, particularly along the nasolabial folds (see Figure 18-1). Other lesions have considerable variability, such as subcutaneous cold abscesses or sinuses that arise from involved bones.<sup>41</sup>

Primary inoculation coccidioidomycosis has occurred several times after accidental inoculation during a laboratory or postmortem procedure. Barbed wire and splinter injuries have also led to infections.<sup>42</sup> In immunologically naive patients, ulceration at the site of trauma is typically followed by transient lymphangitis and regional lymphadenitis. One case subsequently disseminated, causing coccidioidal meningitis.<sup>42</sup> Another kind of rare eruption occurs in patients with pulmonary coccidioidomycosis who develop localized skin lesions at sites of trauma unassociated with inoculation.<sup>43</sup>

### Diagnosis

The diagnosis of coccidioidomycosis is established quickly by finding spherules in touch preparations of skin lesions or in sputum smears. The spherule's large size, doubly refractile walls, and numerous endospores are pathognomonic. Material taken from a cutaneous pustule, abscess, or ulcer should be cleared with potassium hydroxide and examined by direct microscopy. Lactophenol cotton blue or Papanicolaou stain may give superior results.<sup>44</sup> In histological sections, spherules are

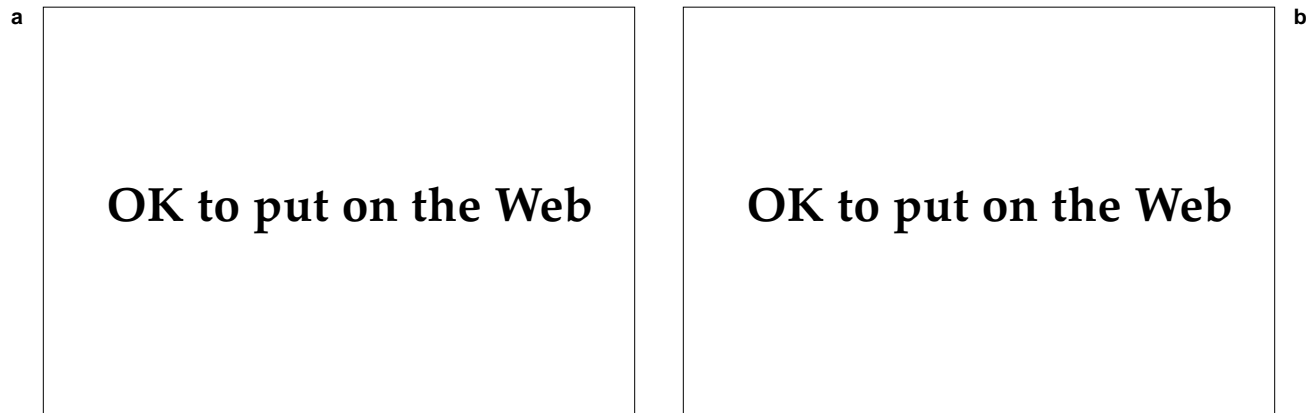


**Fig. 18-8.** Patients with cutaneous coccidioidomycosis present with varied clinical manifestations. (a) This Filipino-American sailor acquired pulmonary coccidioidomycosis after breathing dust that had been stirred up at a cockfight in southern Arizona. The infection subsequently disseminated to his skin and appeared as a cluster of granulomatous papules around his elbow. (b) This African-American soldier complained of fever, diplopia, and neck stiffness. He became obtunded and a skin biopsy of this preauricular lesion showed abundant spherules of *Coccidioides immitis*. Despite amphotericin therapy, the patient soon died. A retrospective history revealed that his only geographical exposure had occurred 6 months earlier, when he traveled through southern California. (c) Additionally, the skin may become involved when bony lesions produce draining sinuses. This man developed fistulous tracts in his chest wall from rib osteomyelitis caused by *C immitis*. Photographs: (b) Courtesy of Lieutenant Colonel Curt P. Samlaska, Medical Corps, US Army, Honolulu, Hawaii; (c) Courtesy of Captain E. C. Oldfield III, Medical Corps, US Navy, San Diego, Calif.

apparent with hematoxylin-eosin stain but are enhanced by fungal stains (Figure 18-9).

The intradermal skin test is a useful diagnostic and prognostic tool. Spherulin, derived from the

pathogenic tissue phase of *C immitis*, is perhaps more sensitive to the arthrospore-derived coccidioidin, which was used previously.<sup>38,45</sup> Skin tests turn positive within 3 weeks after onset of pulmo-



**Fig. 18-9.** These photomicrographs show cutaneous coccidioidomycosis. (a) Exuberant granulomatous skin lesions are characterized histologically by pseudoepitheliomatous hyperplasia of the epidermis. Dermal and intradermal abscess may contain spherules (original magnification 40X). (b) A high-powered view shows many endospores within a spherule (hematoxylin-eosin stain, original magnification 430X).

nary symptoms. A positive test confirms infection in previous nonreactors and, presumably, in persons who have never before lived in endemic areas. False positives may indicate previous infection with histoplasmosis, blastomycosis, or paracoccidioidomycosis. False negatives may indicate the host's poor immunological response to infection and signal susceptibility for disseminated disease.<sup>38</sup> Furthermore, persons with persistent negative skin tests during therapy are at increased risk for relapse if therapy is discontinued.

In endemic areas, the most common cause of erythema nodosum in white patients is coccidioidomycosis. It signifies a vigorous immunological response. If skin testing is conducted on these individuals, a dilute strength (1:1000 or 1:10,000) of spherulin should be used to prevent an intense reaction such as local necrosis or erythema multiforme.<sup>41</sup>

Patients with symptomatic primary pulmonary coccidioidomycosis often have chest radiographs showing infiltrates, hilar adenopathy, or pleural effusions. Mild peripheral eosinophilia is frequently present and may reach 80%.

Serologic assays are valuable adjuncts in the diagnosis and management of coccidioidomycosis. Tests that detect immunoglobulin (Ig) M antibodies (eg, tube precipitin, latex particle agglutination, or concentrated immunodiffusion) help confirm acute coccidioidomycosis, whereas complement fixation is more valuable in cases of long-standing or disseminated disease, including cutaneous coccidioidomycosis. A high (> 1:16) or rising complement fixation-titer suggests either dissemination of dis-

ease or failure of therapy.<sup>40,41,45</sup> Many medical centers refrain from routine coccidioidal cultures because the mycelia have easily dispersed, highly infectious spores. Hundreds of medical personnel have been infected under seemingly innocuous laboratory conditions.<sup>31</sup> Therefore, if tissue is sent for culture, laboratory personnel must be advised to use appropriate precautions.

#### **Treatment**

Most cases of exclusively pulmonary coccidioidomycosis are both unrecognized and untreated. On the other hand, most persons with cutaneous coccidioidomycosis require aggressive therapy for disseminated disease. After determination of the extent of disease, usually by bone scan, gallium scan, and lumbar puncture, a regimen of amphotericin B should be started. Surgical debridement of subcutaneous abscesses and underlying bone infections should be considered.<sup>40</sup> Ketoconazole, fluconazole, and itraconazole are under evaluation for use either in place of, or as a complement to, amphotericin.<sup>46</sup> As azoles, they are fungistatic and probably should not be used alone to treat disease in immunocompromised patients. Members of ethnic groups prone to disseminated disease should be evaluated with extra concern.

#### **Prevention**

Most attempts to prevent coccidioidomycosis are impractical because the infectious particles are borne by wind-blown dust. Dust-control measures in-



clude watering down or oiling airstrips, planting lawns or vegetation, encouraging cultivation, and restricting activities downwind of disturbed sites.<sup>32,47</sup> Archaeologists working in the Southwest have tried wearing masks and wetting the ground in their work areas to lessen the dusty conditions. Susceptible persons from nonendemic areas should preferably avoid dusty activities, such as road grading.<sup>48</sup> Efforts to develop an effective vaccine continue.

### Blastomycosis

Blastomycosis, caused by *Blastomyces dermatitidis*, is principally a pulmonary infection that involves the skin after rare dissemination. Even more rarely, skin lesions follow percutaneous inoculation of the pathogen. Synonyms include North American blastomycosis, Gilchrist's disease, Chicago disease, Namekagon fever, and blastomycetic dermatitis.

A thermally dimorphic fungus, *B dermatitidis* exists in a mycelial phase in nature and in culture at 25°C. A pathogenic yeast phase grows at body temperature. Yeast cells are spherical, approximately 8 to 15 (–30) µm in diameter, and possess a thick, doubly refractile cell wall. Yeast reproduce by forming single buds attached to the parent cell by a broad base. The sexual stage is *Ajellomyces dermatitidis*.

### History

Blastomycosis was identified in 1894 by Thomas Caspar Gilchrist, a dermatologist at The Johns Hopkins Hospital, Baltimore, Maryland, and later president of the American Dermatologic Association. His 1894 report was titled "Protozoan Dermatitis,"<sup>49</sup> despite his recognition that the organism was a hitherto-unknown fungus.<sup>50</sup> The epithet, *dermatitidis*, reflects Gilchrist's appreciation for the organism's affinity for skin. Before self-limited forms of blastomycosis were recognized, the disease was believed nearly always fatal.<sup>51</sup>

### Epidemiology

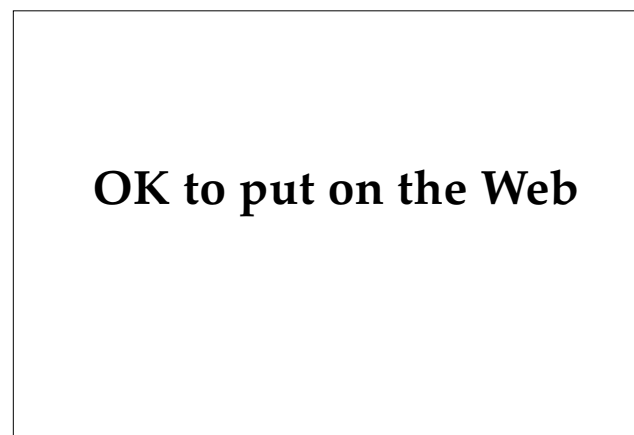The epidemiology of blastomycosis is poorly defined because clusters of human disease rarely occur. Moreover, it was 1984 before *B dermatitidis* was recovered from a location where human disease had occurred: half of the approximately 100 members of a Wisconsin school group that visited a beaver lodge acquired blastomycosis.<sup>52</sup> The organism was found in the moist, excrement-laden soil surrounding the lodge. Apparently, a microfocus

of damp or swampy, nitrogen-rich soil with an acid pH and high organic matter content provides a suitable habitat for the fungus.<sup>53</sup> Persons whose occupational or recreational activities (eg, forestry, hunting, camping) expose them to this ecological niche are at risk for infection. Even so, the disease is unlikely to be contracted more than once in any particular location. One third of foresters in northern Wisconsin and Minnesota have serologic evidence of prior infection.<sup>54</sup>

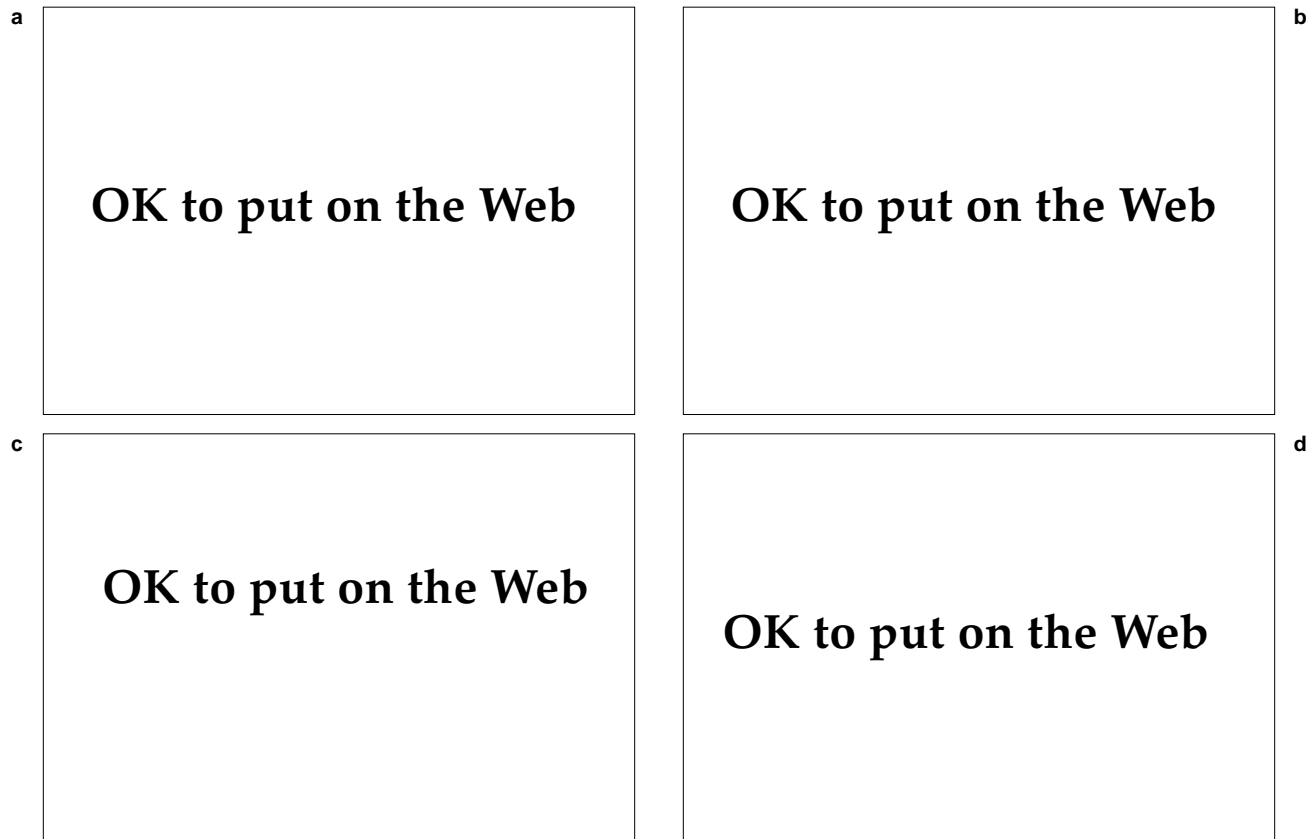
Sporadic disease affects mostly men, reflecting occupational exposures, but epidemic disease affects the sexes equally.<sup>51</sup> Although the disease is not considered contagious, women have acquired endometrial blastomycosis after sexual contact with partners who had genitourinary disease.<sup>55</sup> In North America, other mammals, most notably dogs, naturally acquire blastomycosis. The geographical range of canine blastomycosis parallels that of human disease,<sup>56</sup> except in Africa where canine disease has not been diagnosed.<sup>57</sup>

### Distribution

Blastomycosis is principally a North American disease, endemic in the southeastern United States (particularly Kentucky, Mississippi, and Arkansas), the Great Lakes region, and the drainage basins of the Mississippi and St. Lawrence rivers (Figure 18-10). Many cases of autochthonous infection have occurred in Zimbabwe and South Africa.<sup>57</sup> Fewer cases are reported from other parts of Africa, South



**Fig. 18-10.** The North American region where blastomycosis is endemic. Like histoplasmosis, its distribution follows the parts of the Mississippi and Ohio River valleys. Note that the range of blastomycosis extends into the upper Midwest and along the St. Lawrence River.



**Fig. 18-11.** These individuals have cutaneous blastomycosis. The mid-face (a, b, and c) and distal extremities (d) are typical locations for cutaneous disease. The appearance of these lesions is quite suggestive of blastomycosis: typical granulomatous plaques with expanding, verrucous borders surmounted by fine, dark puncta.

America, and Asia. Indigenous disease in Europe and the Far East is unknown.

### *Clinical Manifestations*

There are three clinical forms of disease: primary pulmonary blastomycosis, systemic blastomycosis, and primary cutaneous inoculation blastomycosis (see Figure 18-1). The first form is the most common.

**Primary Pulmonary Blastomycosis.** Primary pulmonary blastomycosis starts with the inhalation of spores. The usual incubation period is 40 to 50 days<sup>53</sup> but may range from 21 to 106 days.<sup>52</sup> Most infections are asymptomatic but patients can present with mild pneumonia; both conditions usually resolve without sequelae. Erythema nodosum may accompany a syndrome of fever, chest pain, and productive cough. Symptomatic conditions also include a fulminant presentation and a chronic, progressive, pulmonary disorder, with or without dissemination.

**Systemic Blastomycosis.** Hematogenous spread from the lungs produces systemic blastomycosis. The skin is the most commonly affected extrathoracic organ, involved in perhaps 50% of disseminated cases. Bones, the genitourinary system (particularly the prostate), and the central nervous system also are involved frequently.<sup>58</sup> In addition, there is a less aggressive form of systemic blastomycosis in which infection spreads exclusively to skin.<sup>59</sup> About 40% of patients with disseminated blastomycosis have inactive pulmonary disease.<sup>27</sup>

Skin lesions are usually few or solitary and are located on exposed skin, often the face (Figure 18-11). They begin as inflammatory nodules that subsequently break down to form expanding granulomatous ulcers and plaques. Borders are raised and have an annular, arcuate, or serpiginous pattern. Lesions often expand asymmetrically with an exuberant, verrucous, active edge. When the crusted edges are removed, a granulomatous base studded with minute pustules is revealed. Central healing may leave a depigmented, atrophic scar. Oral and

mucocutaneous ulcers also can occur. Bone infections sometimes produce fistulae extending to the skin.<sup>51</sup>

The differential diagnosis of cutaneous blastomycosis includes other deep fungal infections, tuberculosis verrucosa cutis, halodermias, pyoderma gangrenosum, and squamous cell carcinoma.<sup>50</sup>

**Primary Cutaneous Inoculation Blastomycosis.**

Several cases of primary cutaneous inoculation blastomycosis have followed autopsy or laboratory accidents<sup>60</sup> or dog bites.<sup>61</sup> A chancriform syndrome, with regional lymphadenopathy and a chain of subcutaneous nodules, generally resolves on its own within several months.<sup>60</sup>

**Diagnosis**

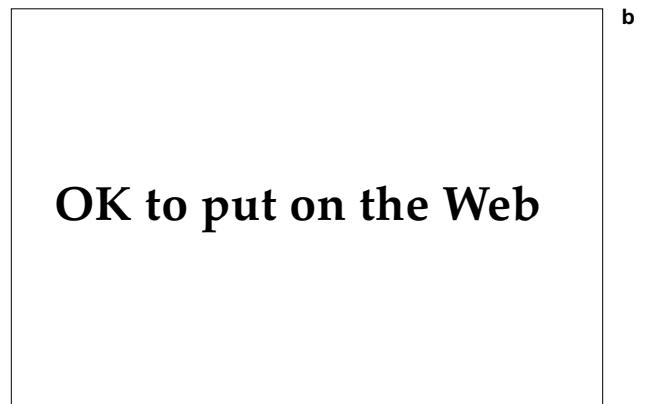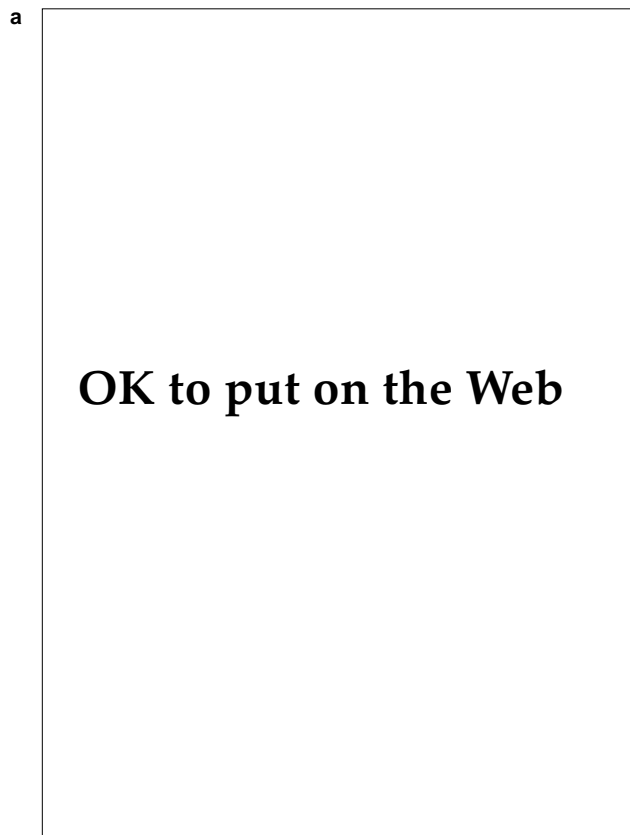Direct examination of a smear of pus or sputum is a simple, quick way to diagnose blastomycosis. Smears are positive in more than half the cases. After the crust has been lifted off an active border, swabbed material from a micropustule should be smeared on a glass slide. A bit of necrotic tissue crushed between two slides is also suitable. After debris is cleared with potassium hydroxide, micro-

scopical examination will show yeast with doubly refractile walls (accentuated by lowering the condenser) and distinctive, single, broad-based buds.

Biopsied skin specimens prepared with fungal stains show pseudoepitheliomatous hyperplasia, microabscesses, giant cells, and the characteristic organisms (Figure 18-12).<sup>51</sup> The organism may be cultured, on Sabouraud's agar at 25°C to 30°C, from pus, skin scrapings, or biopsy specimens.<sup>2,51</sup> Blastomycin skin tests are insensitive, lose reactivity over time, and are often falsely positive in patients with histoplasmosis.<sup>54</sup> Investigational enzyme immunoassay and in vitro lymphocyte stimulation assays show greater reliability than the two more widely available serologic tests, immunodiffusion and complement fixation.<sup>52-54</sup>

**Treatment**

Because most cases of acute pulmonary blastomycosis probably resolve spontaneously, whether all persons should receive treatment remains unresolved.<sup>58,62</sup> If untreated, pulmonary blastomycosis can reactivate years later. In general, patients with active lung disease or with cutaneous involvement



**Fig. 18-12.** These photomicrographs show the histology of cutaneous blastomycosis. (a) The granulomatous plaques are characterized histologically by pseudoepitheliomatous hyperplasia of the epidermis (hematoxylin-eosin stain, original magnification 25X). There are dermal and intraepidermal abscesses that, when passed through the epidermis, appear as the superficial dark puncta seen clinically. (b) The typical broad-based budding of blastomycosis can be seen in the high-power view (Gomori's methenamine-silver stain, original magnification 430X).

should receive therapy.<sup>63</sup> An outpatient regimen of ketoconazole (400 mg daily for at least 6 mo) is generally effective.<sup>26,53</sup> If the disease worsens, the dose should be increased to 600 to 800 mg daily. Because ketoconazole is distributed poorly in the central nervous system and is not excreted by the kidneys, it is not recommended for treating meningeal or genitourinary blastomycosis.<sup>27</sup> Intravenous amphotericin B (2-g regimen over 6 wk) is recommended for immunocompromised patients or those with fulminant, refractory, or meningeal disease. The triazole antifungal agent, itraconazole, has shown promise in preliminary investigations.<sup>63</sup>

### Military Implications

Few clusters of human blastomycosis have occurred,<sup>52,62</sup> suggesting that the disease has little epidemic potential. Military exercises may expose soldiers to the habitats of *B dermatitidis* but the appearance of skin disease, other than in solitary cases, is unlikely. Because dogs are more susceptible to infection than are humans, close cooperation with veterinary staff may be required.<sup>56</sup>

### Paracoccidioidomycosis

Paracoccidioidomycosis (also called South American blastomycosis, Brazilian blastomycosis, Lutz-Splendore-Almeida's disease, and paracoccidioidal granuloma) is a chronic, progressive, potentially fatal, systemic mycosis. It is principally a pulmonary infection but may secondarily involve skin and mucosal surfaces. The causative organism is *Paracoccidioides brasiliensis*. The disease occurs only in South and Central America, where in many areas it is the most prevalent and serious systemic fungal disorder. Paracoccidioidomycosis occurs sporadically and therefore poses little risk to military units.

*P brasiliensis* is a thermally dimorphic fungus whose pathogenic yeast forms have a diameter of 6 to 40  $\mu\text{m}$ . In tissue, a spherical yeast cell surrounded by narrow-based progeny cells gives the distinctive appearance of a ship's pilot wheel or, if fewer buds are present, a Mickey Mouse head.

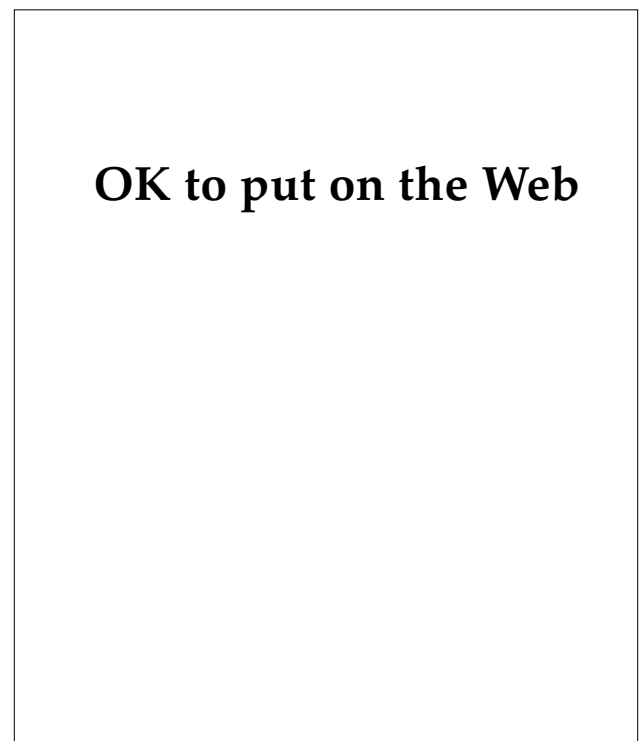### History

A mummified woman who died circa AD 290, excavated from northern Chile, was found to have paracoccidioidal pulmonary infection.<sup>64</sup> The first patients described in modern times presented with oral lesions and were reported in 1908 by Adolpho Lutz, director of the São Paulo Bacteriological Insti-

tute. Lutz demonstrated the dimorphism and pathogenicity of the fungus, yet its distinction from *Blastomyces* and *Coccidioides* remained in dispute. In the late 1920s, Almeida convincingly differentiated the organisms and provided the name *Paracoccidioides brasiliensis*.<sup>65</sup> Paracoccidioidomycosis is not known to have hampered military operations.

### Epidemiology and Distribution

Paracoccidioidomycosis is restricted to the Americas, occurring as far north as Mexico (Figure 18-13). Brazil, in particular the São Paulo region, has the highest incidence of disease.<sup>66</sup> The disease occurs primarily in forested tropical and subtropical regions, although the ecological niche of the fungus remains unknown.<sup>67</sup> Young and middle-aged men who work outdoors are at greatest risk for infection. Women are rarely affected, probably due to the suppressive effects of active estrogens on mycelial-to-yeast transformation.<sup>68</sup> The theory that cleaning one's teeth with contaminated twigs causes gingival inoculation remains unproven.

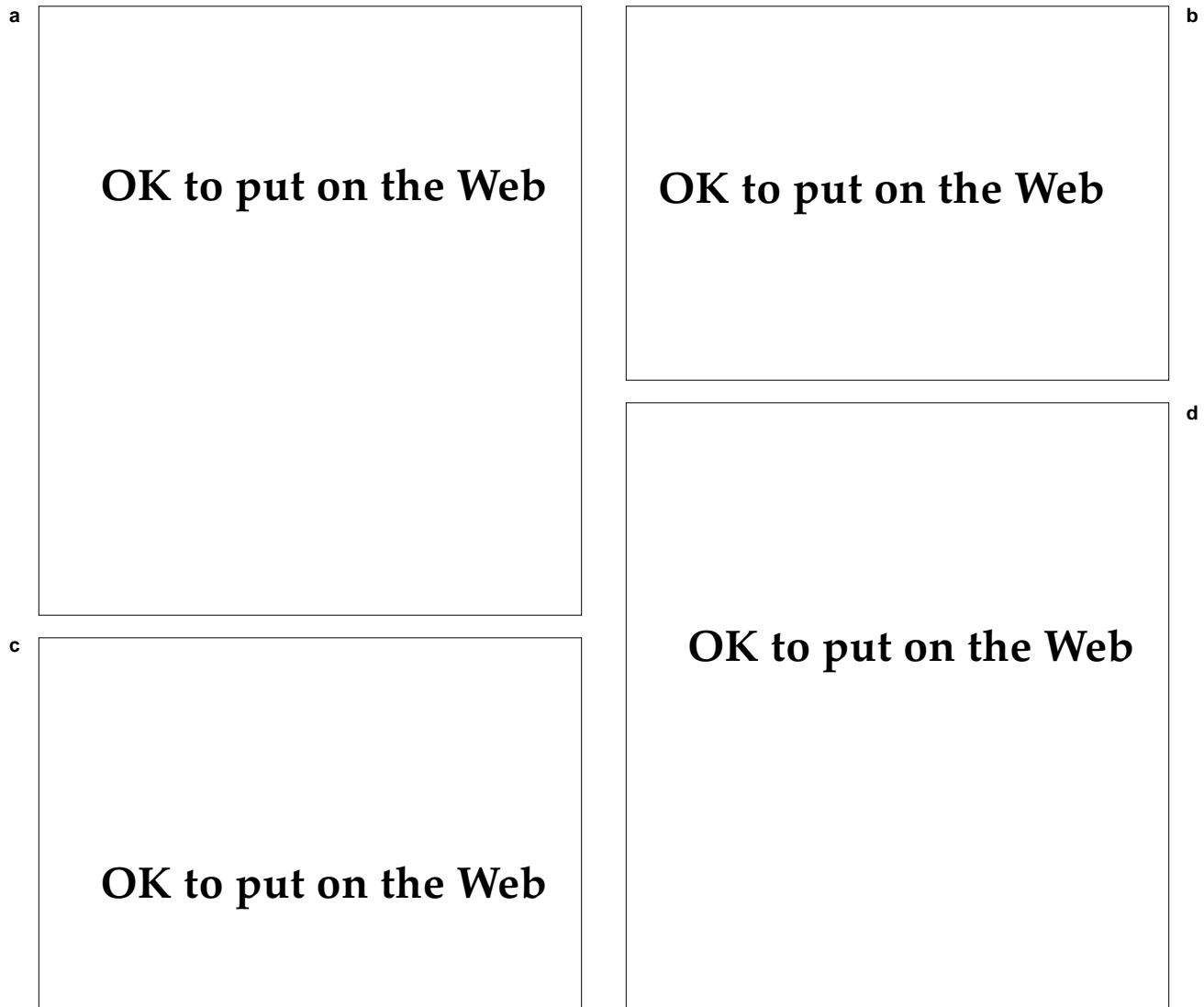

**Fig. 18-13.** This map shows the geographical distribution of paracoccidioidomycosis. The disease is most prevalent in coastal regions of Brazil but can occur throughout South America and Central America.

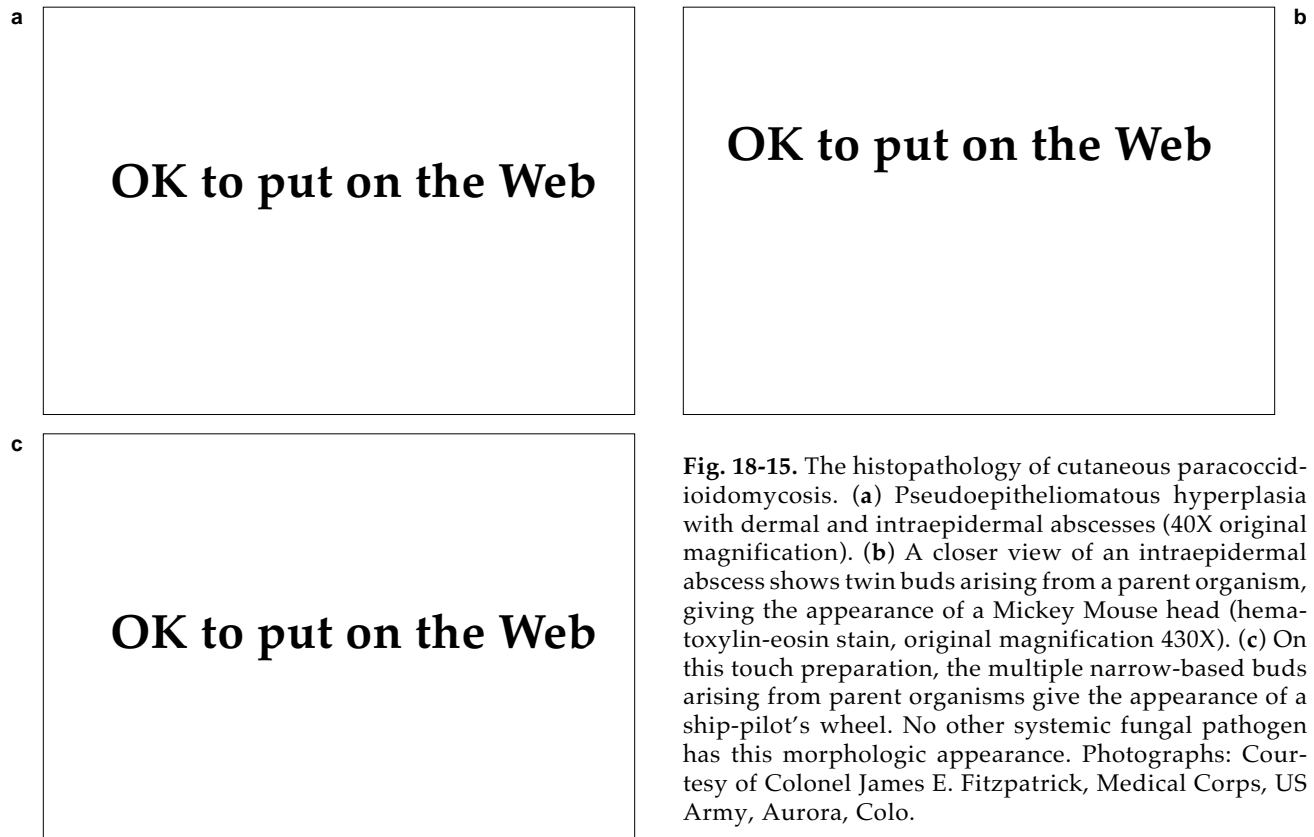
### Clinical Manifestations

The clinical manifestations and natural history of paracoccidioidomycosis are poorly understood. Presumably infectious organisms are inhaled, causing a primary lung infection that is characterized by productive cough, dyspnea, fever, and weight loss.<sup>69</sup> Asymptomatic pulmonary infections, similar to those of histoplasmosis, occur infrequently<sup>70</sup> but

may recrudesce after years of dormancy.<sup>71</sup> One half of infected individuals develop oral lesions, often accompanied by nasal and pharyngeal ulcers (see Figure 18-1). Mucosal ulcers have granulomatous, often exuberant, bases. The patient may complain of dysphagia or hoarseness. Periorificial, crusted, granulomatous plaques may encroach onto and destroy facial structures (Figure 18-14). Affected gingivae may lose teeth. Involvement of lymphoid



**Fig. 18-14.** Cutaneous lesions of paracoccidioidomycosis typically appear in or around the mouth. These patients have (a) periorificial granulomatous plaques and (b) granulomatous infiltration of the tongue and (c) labial mucosa. (d) Cervical adenopathy resembling tuberculous adenopathy commonly occurs in paracoccidioidomycosis. The lymph nodes may suppurate and form draining sinuses. Photographs: Courtesy of Professor Angela Restrepo-M., Medellin, Colombia.



**Fig. 18-15.** The histopathology of cutaneous paracoccidioidomycosis. (a) Pseudoepitheliomatous hyperplasia with dermal and intraepidermal abscesses (40X original magnification). (b) A closer view of an intraepidermal abscess shows twin buds arising from a parent organism, giving the appearance of a Mickey Mouse head (hematoxylin-eosin stain, original magnification 430X). (c) On this touch preparation, the multiple narrow-based buds arising from parent organisms give the appearance of a ship-pilot's wheel. No other systemic fungal pathogen has this morphologic appearance. Photographs: Courtesy of Colonel James E. Fitzpatrick, Medical Corps, US Army, Aurora, Colo.

tissues is especially common in children. Cervical lymph nodes draining oral lesions may be painful and massive. Invasion of mesenteric lymphoid tissue may cause bowel obstruction and symptoms of an acute abdominal emergency.<sup>71</sup>

Cutaneous lesions do not resolve spontaneously. Untreated paracoccidioidomycosis is often fatal, due mainly to extensive pulmonary fibrosis or adrenal gland invasion. Dormant infections may be reactivated after a 30-year latency.<sup>72</sup>

The differential diagnosis includes mucocutaneous leishmaniasis, fixed cutaneous sporotrichosis, histoplasmosis, lymphoma, and scrofula. Coexisting tuberculosis has been noted often. *Blastomyces blastomycosis* more commonly affects skin instead of mucosa, often heals centrally with atrophic scars, and lacks both gingival involvement and regional lymphadenopathy.

### Diagnosis

Evaluation for paracoccidioidomycosis is warranted in patients from endemic regions who have

respiratory symptoms and oral lesions. The diagnosis is confirmed by culture or by finding characteristic, multiply budding yeast in tissue (Figure 18-15). Skin biopsies show areas of pseudoepitheliomatous hyperplasia and microabscesses containing the organisms. A potassium hydroxide preparation of lesional scrapings, sputum or lung-lavage fluid, or pus from draining sinuses may reveal the organisms. The thinner cell wall, increased number of buds, and narrow bud stalks distinguish *P brasiliensis* from *B dermatitidis*.

Cultures grow slowly but are diagnostic. Several immunological assays, in particular immunodiffusion, are potentially valuable diagnostic adjuncts and are being evaluated in endemic areas.<sup>73,74</sup> Paracoccidioidin skin tests are unreliable.<sup>67,72</sup>

### Treatment

Paracoccidioidomycosis must be treated because it rarely resolves on its own. Therapy with itraconazole for 6 months or more generally is effective for both pulmonary and cutaneous disease.<sup>75,76</sup>

## SUBCUTANEOUS MYCOSES

The subcutaneous mycoses comprise sporotrichosis, chromoblastomycosis, mycetoma, lobomycosis, and rhinosporidiosis. They are united by their similar onset after percutaneous inoculation of the pathogen—usually a soil or plant saprophyte. The resulting disease is usually confined to the skin and subcutaneous tissues, and rarely invades deeper or disseminates. The subcutaneous mycoses are most common in tropical or warm temperate regions (see Exhibit 18-1).

### Sporotrichosis

Sporotrichosis has a nearly worldwide distribution and is perhaps the deep mycosis that military dermatologists most frequently encounter. Sporotrichosis nearly always results from traumatic implantation of the pathogen *Sporothrix schenckii* into the skin. Infection is generally limited to cutaneous and subcutaneous tissues.

*S. schenckii*, a thermally dimorphic fungus, is the sole member of its genus. It is a common saprophyte, associated with live and decaying vegetation, plant products, and soils. It infects humans and other mammals but simply colonizes the host plants. In nature and in cooler cultures, the mycelial phase predominates. In infected tissues and in culture at 37°C, *S. schenckii* assumes its yeast phase.

Sporotrichosis poses risks to individuals worldwide but has little epidemic potential. There are no reports of sporotrichosis hampering military operations.

### History

Sporotrichosis was first described in 1898 by Benjamin Robinson Schenck, then a second-year medical student at The Johns Hopkins University, Baltimore, Maryland.<sup>77,78</sup> Most cases of sporotrichosis are solitary, although clusters of infection have occurred. The largest outbreak was among South African gold miners in the 1940s. Nearly 3,000 Bantu mine workers developed lymphocutaneous sporotrichosis after wounding themselves on the *Sporothrix*-laden timbers that were used to shore the mine tunnels.<sup>79</sup> Such outbreaks can be controlled by discontinuing the use of local timber or treating the wood with antifungals.

### Epidemiology and Distribution

Sporotrichosis results from minor, often unnoticed, traumatic implantation of the organism into the skin. Occupations typically at risk for sporotrichosis are those exposed to injuries from plant materials, such as florists, plant nursery and forestry workers, and farmers. Rosebushes, hay, and sphagnum moss have been implicated repeatedly as sources of infection.<sup>80</sup> Hands and fingers are typically involved, except in regions where bare-foot farmers get foot infections. Transmission to humans from animals, particularly cats, may cause sporotrichosis even without a clear history of an animal bite or scratch.<sup>81</sup> No clear gender or racial predilections have been identified. Sporotrichosis is not transmitted from person to person.

*Sporothrix* and sporotrichosis occur in tropical and warm, humid, temperate regions worldwide. Mexico, Brazil, Japan, and Oklahoma have especially high incidences of disease.<sup>80,82,83</sup>

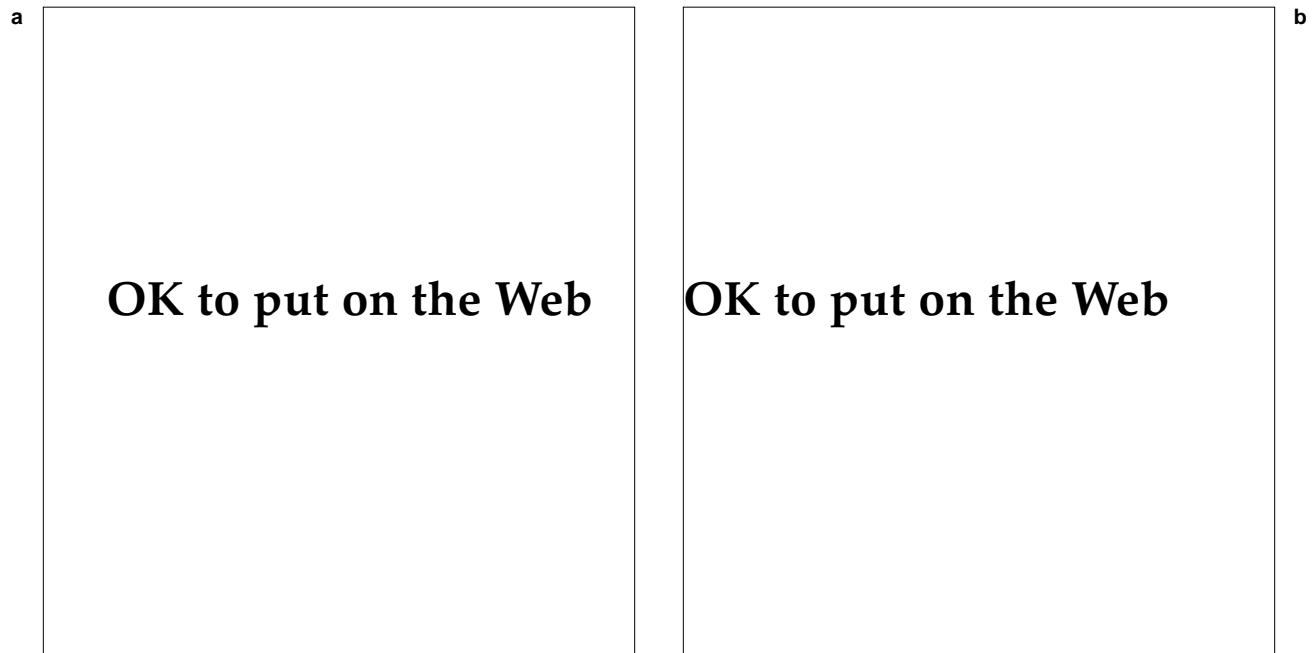
### Clinical Manifestations

Sporotrichosis has several clinical forms but rarely causes systemic disease. Classically, inoculation occurs on a distal extremity, and, after an incubation period of several weeks, a violaceous, firm, granulomatous papule or plaque develops. The initial site often remains painless, although it may suppurate, ulcerate, or become verrucous.

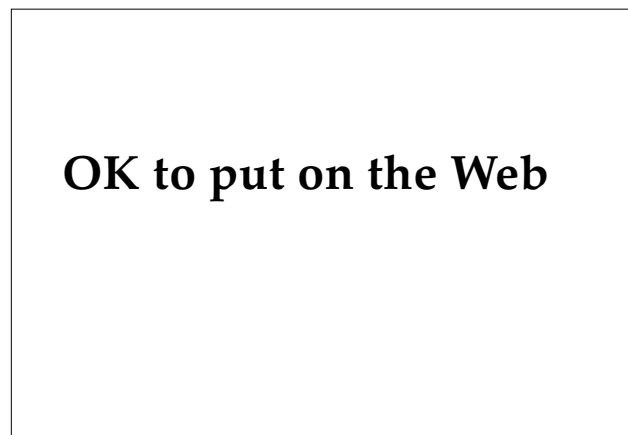Lymphocutaneous sporotrichosis constitutes approximately 75% of cases (Figure 18-16). An ascending chain of painless, subcutaneous nodules develops along lymphatic drainage, causing lymphangitis and regional lymphadenopathy (see Figure 18-1). The nodules may form cold abscesses and ulcerate. Untreated infections have an indolent course and rarely disseminate.

Fixed cutaneous sporotrichosis (approximately 20% of cases) also follows trauma but lacks lymphatic involvement (Figure 18-17). Persistent granulomatous papules or plaques develop at the site of implantation. In particular, children with facial lesions typically present this way. Fixed cutaneous sporotrichosis may resolve spontaneously.

The differential diagnosis for lymphocutaneous sporotrichosis includes other deep fungal infections, atypical mycobacteriosis (eg, from *Mycobacterium marinum*), cutaneous leishmaniasis, tularemia,



**Fig. 18-16.** Lymphocutaneous sporotrichosis arises after traumatic inoculation of *Sporothrix schenckii*. (a) A veterinary assistant developed dermal nodules on the dorsa of her hands after being scratched by an infected cat. Culture of Sabouraud’s medium confirmed the diagnosis 1 week later, and she was successfully treated with a potassium iodide preparation. (b) As *Sporothrix* infection spreads along subcutaneous lymph nodes, the characteristic sporotrichoid appearance develops.



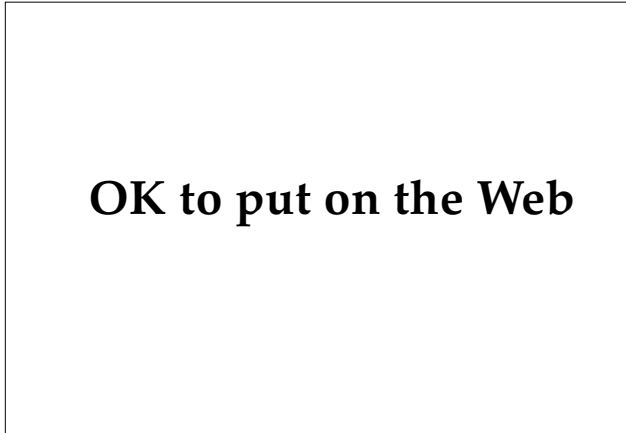
**Fig. 18-17.** This young girl developed fixed cutaneous sporotrichosis on her face after suffering a cat scratch on her left malar region. Photograph: Courtesy of Colonel M. J. Schleve, Medical Corps, US Army, Aurora, Colo.

cat-scratch disease, anthrax, pyodermas, botryomycosis, and *Nocardia brasiliensis* infection. When evaluating fixed cutaneous sporotrichosis, pyodermas, syphilis, other deep fungal infections, cutaneous tuberculosis, and sarcoidosis should be considered.<sup>80</sup>

Extracutaneous sporotrichosis arising from a primary cutaneous infection is rare. The typical patient with systemic sporotrichosis is immunosuppressed by chronic alcoholism, hematological malignancies, diabetes mellitus, or chronic corticosteroid therapy.<sup>84</sup> Extracutaneous infection commonly involves joints, causing monoarticular or oligoarticular arthritis that often eludes diagnosis for some time.<sup>82</sup> Several patients with chronic *Sporothrix* meningitis had concomitant primary cutaneous lesions. Meningeal disease is uncommon but usually fatal if untreated.<sup>82,84</sup>

Pulmonary sporotrichosis follows inhalation of spores and may range from an inapparent to a tuberculosis-like illness. In some regions, skin tests show a high prevalence of infection, suggesting that asymptomatic pulmonary infection is more common than is ordinarily suspected. Rare hematog-





**Fig. 18-18.** Immunocompromised patients may develop disseminated sporotrichosis. This soldier, debilitated from alcohol abuse, presented with the fever, weight loss, and skin nodules. This picture shows ulceration of dermal and subcutaneous nodules. *Sporothrix schenckii* was cultured from several skin sites. His sporotrichosis may have started as a primary pulmonary infection.

enous dissemination may produce skin lesions (Figure 18-18) or involve joints, tendons, bones, or the brain.<sup>80</sup>

### Diagnosis

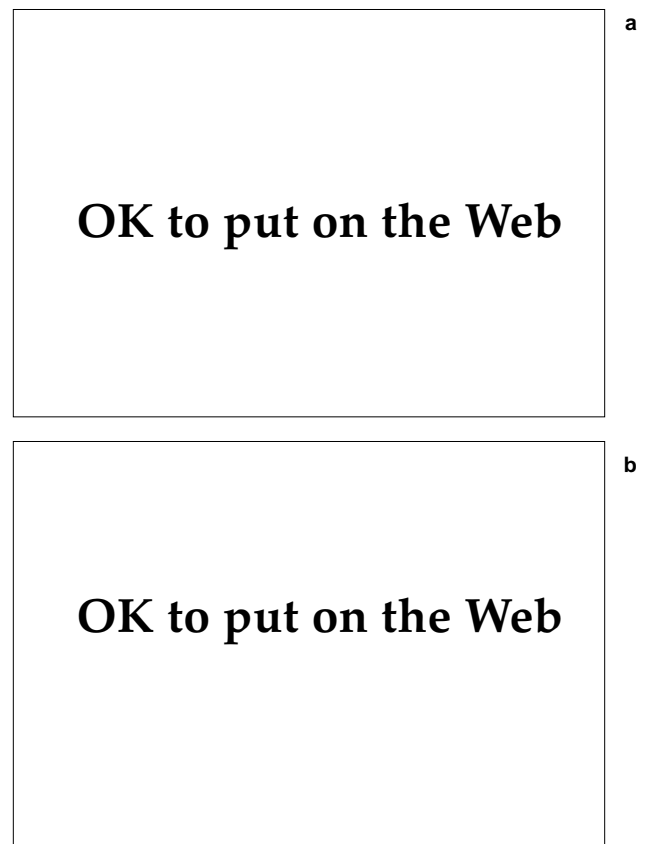
The clinical picture of an extremity with a painless ulcer and ascending lymphocutaneous nodules is characteristic of sporotrichosis. The diagnosis is strongly supported by (a) the history of onset after plant-related trauma and (b) the lack of response to presumptive antibacterial therapy. Confirmation requires identification of the organism by culture or microscopy. On histological sections, the organisms appear round to oval and are approximately 4 to 6  $\mu\text{m}$  in diameter (Figure 18-19). Larger, cigar-shaped bodies, 8  $\mu\text{m}$  in length, and asteroid bodies, although characteristic of sporotrichosis, occur infrequently. Rarely, the fungus can be identified on microscopical examination of smears of pus from a lesion, stained with periodic acid–Schiff or Gram’s stain. Histological confirmation is often difficult because the organisms are scarce and small.<sup>59</sup>

On the other hand, *Sporothrix* grows rapidly on Sabouraud’s agar. Material for culture can be obtained from ulcer scrapings, an aspirated subcutaneous nodule, or macerated biopsy material. After 3 to 7 days at 25°C to 30°C, smooth, moist, cream-colored colonies develop. As aerial hyphae develop, the colonies typically become brown and velvety.

Delayed-hypersensitivity skin tests with sporotrichin are often positive in inhabitants of endemic areas, ranging from 10% in Louisiana and Arizona to more than 90% in parts of Japan. Direct immunofluorescence and serologic tests have varying degrees of sensitivity, specificity, rapidity, and availability.<sup>80,84</sup>

### Treatment

Most cases of purely cutaneous disease may be treated simply and inexpensively with supersaturated potassium iodide (SSKI). SSKI (5 drops in juice) is consumed three times daily, increasing the amount by 1 drop per dose per day until a dose of 40 drops three times daily is achieved.<sup>85</sup> Administration is continued until 4 weeks after clinical resolution. SSKI’s mechanism of action is uncertain. The untoward side effects of iodides include an acneform



**Fig. 18-19.** (a) Typical skin lesions of sporotrichosis show pseudoepitheliomatous hyperplasia and intraepidermal abscesses (hematoxylin-eosin stain; original magnification 25X). (b) A closer view shows the characteristic oval-shaped budding yeast (periodic acid–Schiff stain; original magnification 430X).

eruption, brassy taste, gastrointestinal distress, hypothyroidism, parotid swelling, and increased salivation and lacrimation.<sup>86</sup> Local heat therapy is a useful adjunct because *Sporothrix* is intolerant of temperatures above 38.5°C. Applications of hot (42°C), moist compresses for 30 minutes twice daily will enable the heat to reach subcutaneous infections.<sup>80</sup>

Currently, intravenous amphotericin B is the drug of choice for extracutaneous infections and for refractory, widespread, or debilitating cutaneous disease. Because amphotericin is nephrotoxic and requires intravenous administration, other antifungal agents are being evaluated. Itraconazole, but not ketoconazole, is effective at a daily dosage of 100 to 200 mg, administered orally for 3 to 5 months.<sup>82,87</sup>

### Chromoblastomycosis

Chromoblastomycosis designates a group of chronic cutaneous and subcutaneous mycoses caused by several species of dematiaceous fungi. Common pantropically in rural areas, the disease is also called chromomycosis, verrucous dermatitis, Pedroso's disease, Fonseca's disease, and Lane and Pedroso's mycosis.

Chromoblastomycosis occurs sporadically and lacks epidemic potential. In tropical areas, shoes and leg coverings protect individuals from the minor penetrating trauma that inoculates the pathogens.

Several species of dematiaceous (darkly pigmented) fungi cause most cases of chromoblastomycosis. These include *Fonsecaea pedrosoi* (the major pathogen), *Fonsecaea compacta*, *Phialophora verrucosa*, *Cladosporium carrionii*, and *Rhinocladiella aquaspersa*.<sup>88</sup> Each species has more than one morphologic strain, compounding the nomenclatural disarray. The related genera produce similar, dark brown, sclerotic bodies in tissue and form pigmented colonies on culture. Because these fungi reproduce by internal septation rather than by budding, some<sup>89</sup> have argued that -blasto- should be deleted from the name of the disease.

### History

Early in the 20th century, several workers described patients with chromoblastomycosis and isolated the pathogens.<sup>89</sup> Controversy persists over priority of description, name of the disease, and nomenclature of the causative fungi.<sup>89,90</sup> There are no reports of chromoblastomycosis having hampered military operations.

### Epidemiology and Distribution

Although found worldwide, chromoblastomycosis occurs mainly in the humid tropics and subtropics. The causative fungi are saprophytes and are recoverable from soil, rotting wood, and other plant debris. Their spores enter the skin via minor penetrating trauma. Barefooted rural farmers, therefore, have the greatest occupational risk.<sup>91</sup> The disease occurs overwhelmingly in men aged 25 through 50, except in Japan where men and women are affected equally.<sup>92</sup> *Fonsecaea pedrosoi* is the major pathogen, although regional variations exist.

### Clinical Manifestations

Chromoblastomycosis starts as painless, skin-colored papules typically on the lower legs or the lateral aspects of the feet (see Figure 18-1). Enlarging lesions develop into nodules or plaques. Their surfaces can be verrucous, papillomatous, scaly, sclerotic, or a combination of these. Flat, rough-surfaced plaques often heal with central atrophy, scarring, or keloid formation (Figure 18-20). Elsewhere, satellite lesions or peripheral expansion along serpiginous borders may develop.<sup>91,93</sup>

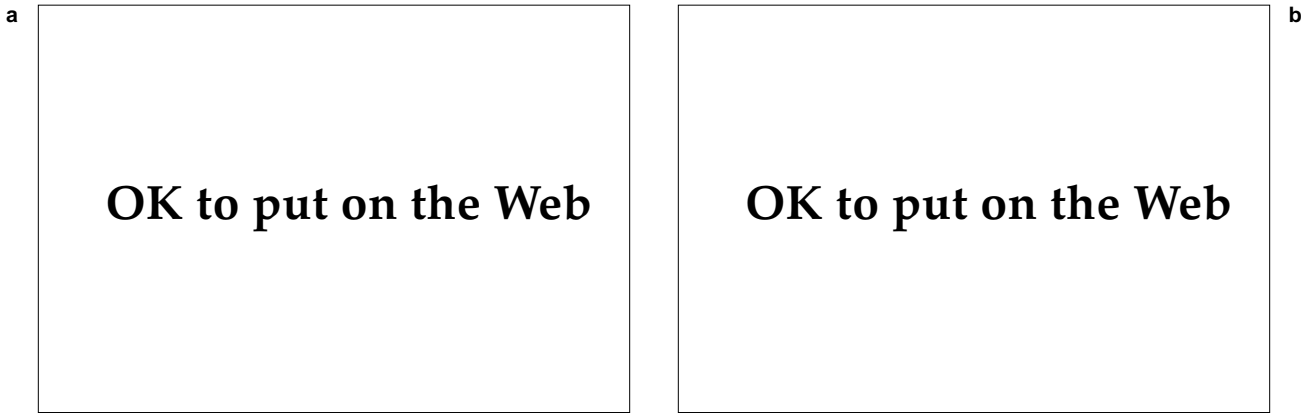
After many years, some lesions evolve into cauliflower-like lobulated vegetations (Figure 18-21). Frequently, secondary bacterial infections cause fibrosis of superficial lymphatics and subsequent lymphedema or elephantiasis. The fungi do not invade underlying muscle and bone.

Morbidity in chromoblastomycosis arises from the disfigurement or disability of an affected part, secondary infections, or, rarely, a supervening squamous cell carcinoma. Rare hematogenous spread may lead to cerebral chromoblastomycosis even if cutaneous lesions are absent.<sup>93</sup>

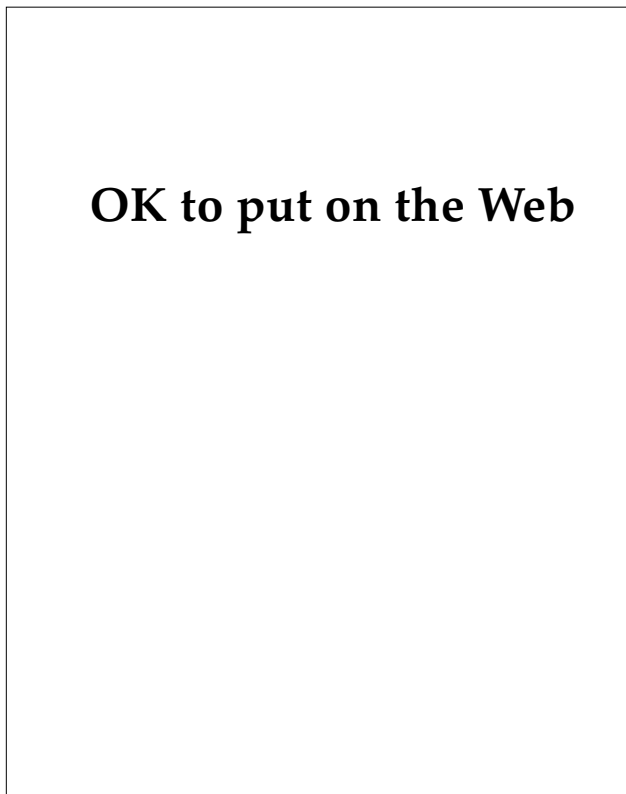
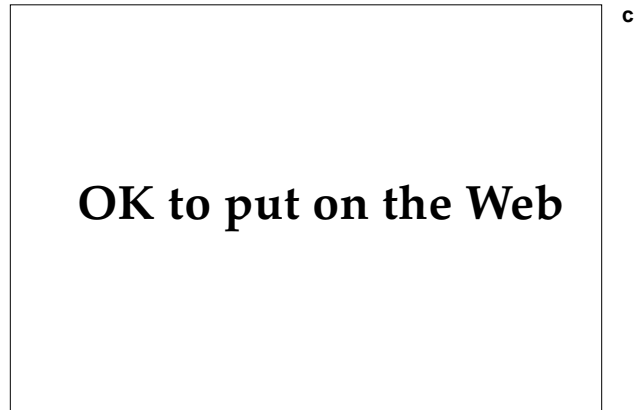The differential diagnosis includes other deep fungal infections (such as blastomycosis, sporotrichosis, and mycetoma), tuberculosis verrucosa cutis, cutaneous leishmaniasis, and treponemal diseases (eg, yaws and tertiary syphilis).

### Diagnosis

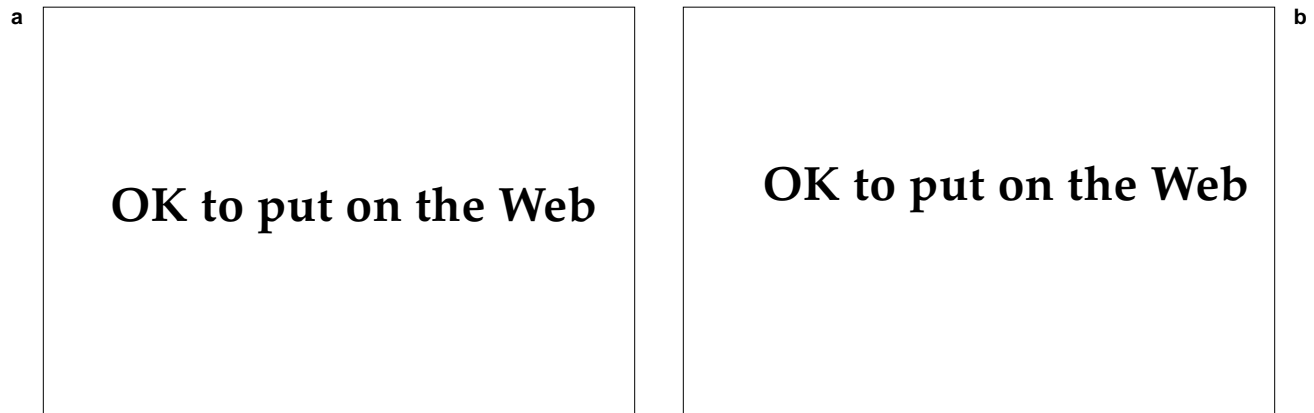
Diagnosis of chromoblastomycosis requires both detection of sclerotic bodies from lesional material and a fungal culture. Sclerotic bodies (ie, "copper pennies" or Medlar bodies) are 6- to 12- $\mu$ m, dark-walled, polyhedral structures (Figure 18-22). Internal cross-walls (ie, septae), produced by intracellular reproduction, give the cells a muriform appearance.<sup>89</sup> They are often seen in potassium



**Fig. 18-20.** Chromoblastomycosis most commonly appears as granulomatous plaques with serpiginous borders. These photographs (**a** and **b**) show the proximal pretibial surface of a woman from Yap, Federated States of Micronesia. She presumably acquired the infection by kneeling on contaminated wooden planks in her traditional home. (**b**) The scattered dark puncta are found in both blastomycosis and chromoblastomycosis, but the lesion's location on a surface exposed to minor trauma and the tropical setting make the clinical diagnosis straightforward. Chromoblastomycosis can remain indolent for decades. (**c**) This man acquired his infection 50 years earlier during World War II when he was stationed on Manus Island, north of New Guinea. A log fell on his upper back while he was working on a construction project.



**Fig. 18-21.** Chromoblastomycosis can also progress into a vegetative form, as seen in this disfiguring vegetative chromoblastomycosis of the leg.



**Fig. 18-22.** (a) A potassium hydroxide preparation of the dark puncta seen in Fig. 18-20 b revealed the diagnostic copper-colored sclerotic bodies of chromoblastomycosis. (b) More sclerotic bodies are seen in tissue with a photomicrograph of her skin biopsy (hematoxylin-eosin stain; original magnification 430X). The culture grew *Fonsecaea pedrosoi*.

hydroxide preparations of exudate or surface scrapings. Punctate black dots found on the surface of exuberant lesions are often composed of transepidermally eliminated sclerotic bodies. Skin biopsies show pseudoepitheliomatous hyperplasia, multinucleated giant cells, microabscesses, and sclerotic bodies. Sclerotic bodies, easily seen with hematoxylin-eosin staining, appear singly or in clusters, and are most numerous in vegetative growths.<sup>94</sup> Material grown on Sabouraud's agar forms gray-green or black colonies. Species identification is based on sporulation patterns.

### Treatment

Treatment regimens for chromoblastomycosis have been disappointing. Physical measures include wide surgical excision, Mohs' surgery, carbon dioxide laser, radiation, local heat, and cryotherapy. Curettage and electrodesiccation may promote lymphatic spread and should be avoided. Chemotherapeutic approaches include potassium iodide, intralesional amphotericin, ketoconazole, itraconazole, thiabendazole, and 5-fluorocytosine.<sup>91,95</sup> Small, early lesions may be excised successfully. More extensive disease requires long-term treatment with itraconazole alone or with a regimen combining 5-fluorocytosine and amphotericin.<sup>96,97</sup> Limbs disabled or deformed from refractory infections may require amputation.

### Mycetoma

Mycetoma is also called maduramycosis, Madura foot, eumycetoma, eumycotic mycetoma, actinomy-

cetoma, and actinomycotic mycetoma. The word mycetoma means "fungal tumor" but most cases are caused by bacteria. Perhaps 20 different pathogens cause mycetoma, the main ones being *Pseudallescheria* (syn *Allescheria*, *Petriellidium*, *Monosporium*, *Scedosporium*) *boydii* in the United States, *Nocardia brasiliensis* in Mexico, and *Madurella mycetomatis* in India and Africa (Table 18-1). The organisms are saprophytes, recoverable from soil and plant debris. Ecological conditions influence their distribution and medical importance so that, for example, in Central and South America the overwhelming majority of cases are due to *Nocardia brasiliensis*, a less important pathogen elsewhere.<sup>98</sup>

Mycetoma is a chronic, progressive infection of skin and subcutaneous tissues and is found mostly in the tropics. Infection follows traumatic implantation of pathogenic true fungi (eumycetoma) or filamentous bacteria (actinomycetoma). The two forms are similar clinically. Mycetomas frequently affect the lower extremities and may invade deeper structures. Infection is characterized by swollen tissues and destructive sinuses from which drains pus containing characteristic granules.

In hyperendemic tropical regions, soldiers should protect themselves from minor trauma by wearing footgear and uniforms. Activities during which implantation could occur, such as carrying locally obtained wood on bare shoulders or backs, should be avoided.

### History

Royal Army physicians stationed in the Madura region of India first described mycetomas in the

**TABLE 18-1**  
**MAJOR PATHOGENS IN MYCETOMA: THEIR DISTRIBUTION AND GRANULE COLOR**

Pathogen	Location						
	Eur	USA	Mex	SAm	Waf	Eaf	Ind
Eumycetoma (Ascomycetes and deuteromycetes)							
<i>Pseudallescheria boydii</i>	Y-W	Y-W					
<i>Madurella grisea</i>				B			
<i>Madurella mycetomatis</i>					B	B	B
<i>Leptosphaeria senegalensis</i>					B		B
Actinomycetoma (Actinomycetes and streptomycetes)							
<i>Streptomyces somaliensis</i>						Y	Y
<i>Streptomyces (Acremonium) pelletieri</i>					R	R	
<i>Actinomadura (Nocardia) madurae</i>							W
<i>Nocardia brasiliensis</i>			C-W	C-W			C-W

Eur: Europe, USA: United States; Mex: Mexico; SAm: South America; Waf: West Africa; Eaf: East Africa; Ind: India; Y: yellow; W: white; B: black; R: red; Y-W: yellow-to-white; C: colorless; C-W: colorless-to-white

Data sources: (1) Magaña M. Mycetoma. *Int J Dermatol.* 1984;4:221–236. (2) Gumaa SA, Mahgoub ES, El Sid MA. Mycetoma of the head and neck. *Am J Trop Med Hyg.* 1986;35:594–600. (3) Develoux M, Audoin J, Tregueur J, Vetter JM, Warter A, Cenac A. Mycetoma in the Republic of Niger: Clinical features and epidemiology. *Am J Trop Med Hyg.* 1988;38: 86–90. (4) McGinnis MR, Fader RC. Mycetoma: A contemporary concept. *Infect Dis Clin North Am.* 1988;2:939–954. (5) Zaias N, Taplin D, Rebell G. Mycetoma. *Arch Dermatol.* 1969;99:215–225.

local population in the 1840s. Vandyke Carter, surgeon in the British India Army in Bombay, recognized the fungal etiology and coined the name “mycetoma.”<sup>99</sup> Military health reports from India did not include mycetoma as a significant problem for British forces there.

**Epidemiology and Distribution**

Although it is a cosmopolitan disorder, mycetoma is important only in the tropics and subtropics. Adult males engaged in outdoor work are at greatest risk. The site of infection corresponds to the body parts exposed to trauma: barefoot laborers have foot and leg infections, whereas persons who carry contaminated wood and other plant products on their heads, upper backs, and shoulders develop mycetomas there. The infections are not contagious.

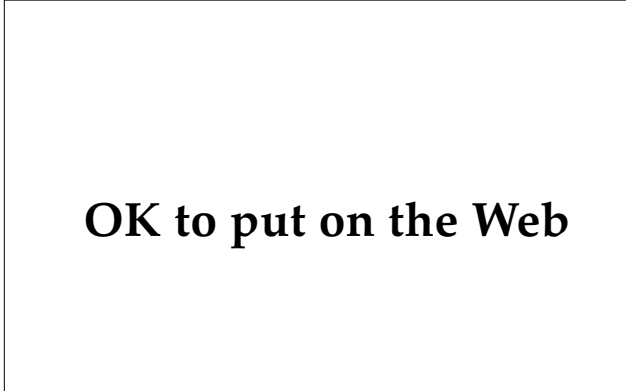
Infections occur more often in moist regions, although some organisms, notably *Nocardia brasiliensis* and *Streptomyces pelletieri*, are common in dry areas. Incidence is highest in Mexico, India, and parts of Africa (Sudan, Somalia, Senegal).<sup>98,100,101</sup>

**Clinical Manifestations**

Mycetoma is characterized by the clinical triad of

swollen tissues, draining sinuses, and extrusion of grains.<sup>102</sup> Mycetomas principally occur on the foot, ankle, leg, hand, and upper trunk, although any exposed area is susceptible (see Figure 18-1). After the pathogen is implanted, there is a several-month incubation period. Early lesions are painless, indurated, subcutaneous nodules that grow slowly, coalescing into large plaques or tumors (Figure 18-23). These subsequently form necrotic abscesses and draining sinuses. Grains, usually 0.5 to 2.0 mm in diameter, which are actually colonies of organisms, can be recovered in the seropurulent drainage. Invasion into subcutaneous tissues causes more swelling and induration, often destroying fascia and muscle, and producing chronically draining fistulae. Further extension occurs by direct invasion along fascial planes or by coalescence of abscesses and sinus tracts. Bone involvement leads to periostitis, chronic osteomyelitis, and osteolysis. Mycetomas do not self-heal. Infections progress relentlessly, ultimately leading to deformity and disability. Encroachment into the central nervous system has been reported, although mortality is generally low.<sup>98,100,103–105</sup>

The differential diagnosis for mycetoma includes other deep fungal infections, tuberculous and bacterial osteomyelitis, actinomycosis, botryomycosis,



**Fig. 18-23.** The swollen tissues and draining sinuses of a mycetoma are apparent in this photograph. The feet and lower legs are the most common sites for mycetomas because those sites suffer the most minor trauma, especially in individuals who go barefoot.

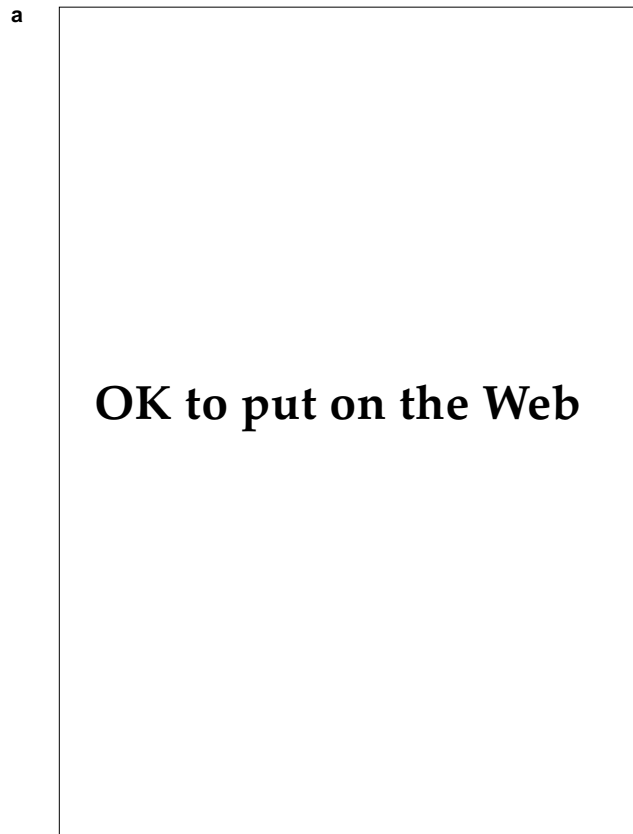
Kaposi's sarcoma, tertiary syphilis, yaws, leprosy, and cutaneous leishmaniasis.<sup>106</sup>

**Laboratory Diagnosis**

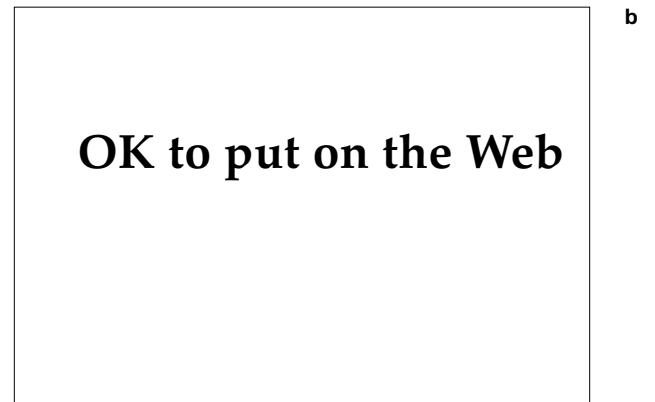
It is essential to determine whether a fungus or

an actinomycete causes a mycetoma so that appropriate therapy can be started. Preliminary identification can be made from clinical assessment, the patient's travel history, and, most importantly, examination of the grains (see Table 18-1). Grains, particularly dark ones, are often visible to the naked eye but may be found by diluting purulent exudate with sterile saline. Grains should be examined grossly for color and texture and microscopically for hyphae or filaments. Black grains (Figure 18-24) are produced exclusively by eumycetomas. Pale (colorless, white, or yellow) granules are produced by most actinomycetes but only by one eumycete, *Pseudallescheria boydii*. Red granules are formed by *Streptomyces pelletieri*. A hard, brittle texture characterizes *Madurella* species' grains. Extensive details on mycetoma grains can be found elsewhere.<sup>98,106</sup>

Crushed granules should be examined with Gram's stain and potassium hydroxide preparations. Eumycotic grains will reveal Gram-negative septate hyphae. Actinomycotic grains have Gram-negative centers with Gram-positive, fine, radiating fringes. Also, preparations with potassium hydroxide or lactophenol cotton blue demonstrate the delicate (1 μm thick), branching filaments of



**Fig. 18-24.** Histopathology of eumycetoma. (a) This skin biopsy of a eumycetoma shows fibrosis, deep abscess, and two dark granules (hematoxylin-eosin stain, original magnification 10X). (b) A closer view of the same biopsy tissue (hematoxylin-eosin stain, original magnification 40X).



actinomycetes and the larger (4-5  $\mu\text{m}$ ) septate hyphae of eumycetes.<sup>103,107</sup>

Skin biopsies show dermal inflammation and microabscesses surrounded by a polymorphous infiltrate. The grains of botryomycosis and actinomycosis resemble those of mycetoma. Often the organism can be identified by histopathological examination alone. True fungi are enhanced with periodic acid-Schiff or Gomori's methenamine-silver stains, whereas *Nocardia* is partly acid-fast.

Culture of the pathogen permits a determination of drug sensitivities. Grains should be either washed in sterile saline to remove contaminants or obtained from deep sites.<sup>103</sup> They should be minced into a suspension for plating onto an appropriate agar (eg, Sabouraud's with and without antibiotics). Growth requirements for the various organisms are discussed elsewhere.<sup>107,108</sup>

Serologic tests and immunoassays are under investigation but are not widely available. Radiographs of affected parts will help assess extent of bony destruction.<sup>105</sup>

### Treatment

Therapy for mycetoma depends on the organism, the site of the infection, and the degree of invasion. The prognosis for actinomycetoma is better than for eumycetoma but therapies for both are often disappointing. Actinomycetoma may be treated with long-term combinations of oral antibiotics, such as streptomycin with either dapsone or co-trimoxazole. Eumycetomas are resistant to amphotericin and griseofulvin but on occasion respond to imidazoles. Small, solitary nodules can be excised but that must be followed by chemotherapy to prevent relapses. Larger nodules can be debrided and abscesses drained. Advanced disease should receive combined surgical and chemotherapeutic measures. Limbs with refractory, destructive disease may require amputation, although stump recurrences are common.<sup>98,103,105</sup>

### Lobomycosis

Lobomycosis is a chronic, cutaneous mycosis of the New World tropics. It typically appears as multiple, smooth, firm nodules of skin only, sparing mucosa and viscera. The disease is also called Jorge Lobo's disease and keloidal blastomycosis.

Jorge Lobo first described the cutaneous lesions of lobomycosis in 1931 in a patient from the Amazon basin.<sup>109</sup> The fungus is recoverable only from cutaneous lesions. It has neither been isolated from

nature nor grown satisfactorily in culture. Taxonomists have never been sure of the proper affinities of this fungus, and in the early literature, it was included at times in several genera, such as *Paracoccidioides*, *Blastomyces*, *Glenospora*, *Glenospora*, and *Lobomyces*. Until its taxonomic affinities are better determined, the organism, *Loboa lobo*, is best regarded as the sole member of its genus.<sup>110</sup>

Lobomycosis is rare even in endemic areas and poses little risk to military units. Individuals may become infected in the dense lowland forests of Central and South America, but, owing to the lengthy incubation period, clinical manifestations will be inapparent for months. No military activities are known to have been hampered by this disease. Several Atlantic bottle-nosed dolphins on duty with the U.S. Navy have been afflicted with lobomycosis.

### Distribution and Epidemiology

Lobomycosis occurs only in South and Central America, where it is, nevertheless, rare (Figure 18-25). It occurs mostly in densely forested humid areas,



OK to put on the Web

**Fig. 18-25.** The distribution of human lobomycosis, which occurs principally in the Amazon River basin. Dolphin lobomycosis is found more northward, along the Caribbean coast of South America and the coast of southern Florida.

such as the Amazon basin of Brazil, and less often in contiguous countries from French Guiana to Costa Rica. Farmers, miners, workers on rubber plantations, and Brazil's Cayabi Indians are most frequently affected.<sup>111,112</sup> Presumably, the fungus enters the skin by minor trauma or via arthropod bites.<sup>112</sup> Another enigma is that lobomycosis naturally occurs in dolphins found along the coasts of Florida (Atlantic bottle-nosed dolphin, *Tursiops truncatus*) and an estuary in Suriname (Guyana River dolphin, *Sotalia guianensis*).<sup>109</sup>

### Clinical Manifestations

The incubation period of lobomycosis is probably months to years. Skin lesions begin as multiple, painless, firm, violaceous nodules that coalesce into variably sized keloidal plaques (Figure 18-26). Although their surfaces are usually smooth and shiny, they may instead show epidermal atrophy or warty changes. Lobomycosis principally involves the face and ears, distal extremities, and buttocks (see Figure 18-1). This distribution and the relative sparing of the back support the idea that the disease is acquired initially by minor trauma and spread subsequently by autoinoculation. Lesions also may spread locally by direct extension or via the superficial lymphatics. Sequelae include ulcers, fistulae, and, rarely, squamous cell carcinoma.<sup>111</sup>

Helical lesions must be distinguished from lepromatous leprosy, sarcoidosis, cutaneous

leishmaniasis, and true keloids. Verrucous plaques of the legs may resemble other deep mycoses, such as chromoblastomycosis.<sup>112</sup>

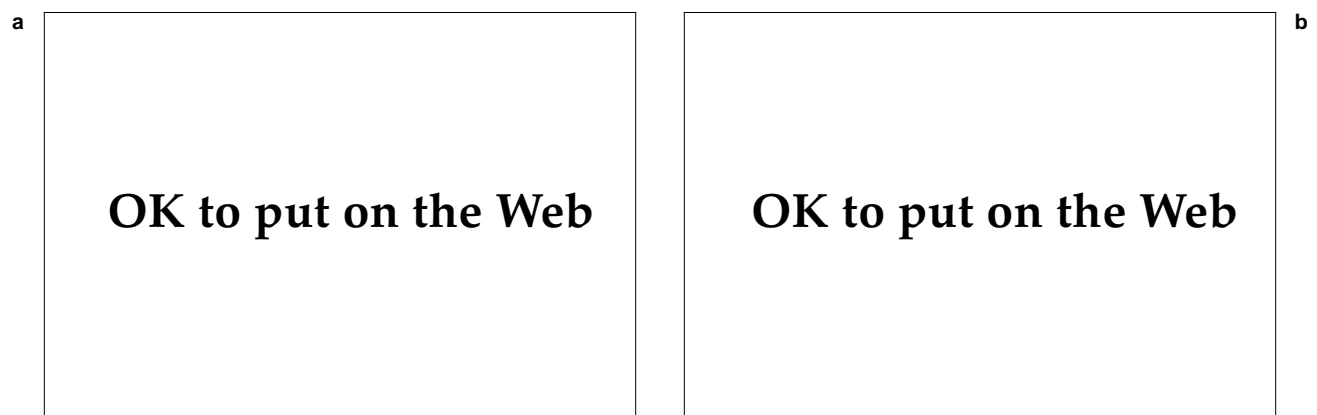
The disease is chronic and spreads slowly, though the patient remains generally well. Morbidity is a consequence of disability or disfigurement.

### Diagnosis

The diagnosis of lobomycosis must be confirmed histopathologically.<sup>110</sup> The dermis is nearly replaced by an infiltrate of macrophages and multinucleate giant cells. Abundant fungal spores, averaging 8 to 10  $\mu\text{m}$  in diameter, appear within and freely between the giant cells. The organisms stain poorly with hematoxylin-eosin, producing a characteristic sievelike pattern (Figure 18-27).<sup>59</sup> Fungal stains, such as periodic acid-Schiff, reveal chains of thick-walled organisms with tubular interconnections. Single buds are seen occasionally. Skin tests, serologic tests, and attempts to culture the pathogen are not useful in the evaluation of lobomycosis.

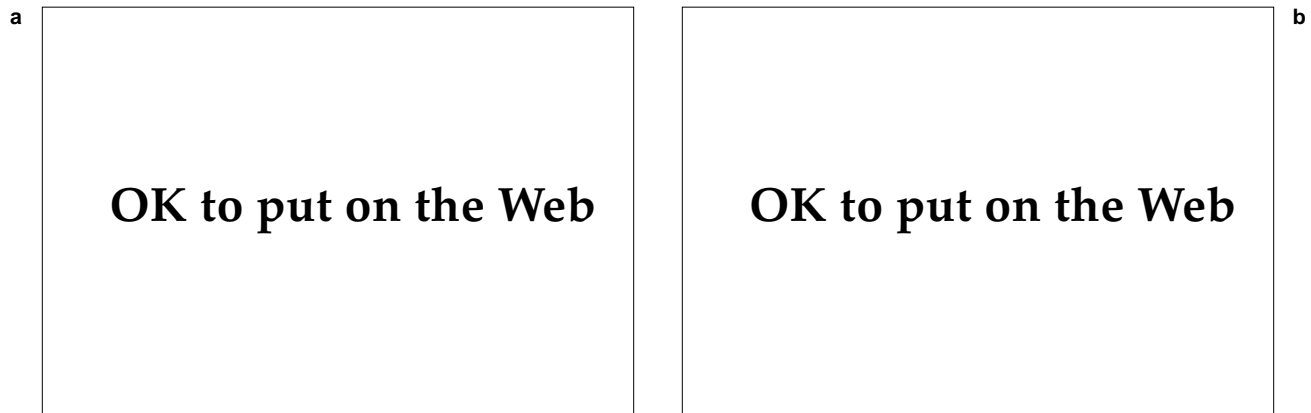
### Treatment

Lobomycosis does not resolve spontaneously nor is there any satisfactory treatment. Medical intervention, even with amphotericin and ketoconazole, has been uniformly unsuccessful. Small lesions may be excised but recurrences are common.<sup>112</sup>



**Fig. 18-26.** (a) Human and (b) dolphin lobomycosis. The smooth, whitish, warty excrescences of lobomycosis are similar in both species. This Atlantic bottle-nosed dolphin was captured in an estuary in central Florida. For over a decade, the dolphin has been an active member of the US Naval Command Control Ocean Surveillance Center research facility, formerly at Kaneohe Marine Corps Air Station, Hawaii. The lesions are unresponsive to imidazole therapy but they do not seem to hamper the dolphin's life or performance of its duty. Photograph (a): Courtesy of Professor Angela Restrepo-M., Medellin, Colombia.





**Fig. 18-27.** The characteristic histology of *Loboa lobo* infection in a human. (a) The low-power view shows dermal fibrosis and a sievelike pattern created by numerous organisms. (b) Chains of *L lobo* are seen on closer view (hematoxylin-eosin stain, original magnification 430X).

### Rhinosporidiosis

Rhinosporidiosis is a chronic, painless, mucosal infection caused by *Rhinosporidium seeberi*. Typically, an intranasal papule evolves into a hyperplastic polyp. Lesions may obstruct the nares and impair breathing, cause nasal bleeding, or, if the oral mucosa is involved, compromise speech and digestion.

In infected tissues, *R seeberi* appear as abundant spores and sporangia. Immature spores (7–10  $\mu\text{m}$ ) enlarge and undergo repeated mitotic divisions, forming thick-walled sporangia (100–350  $\mu\text{m}$ ).<sup>113–115</sup>

Solitary cases of rhinosporidiosis may occur after individuals are exposed to fresh water in India and adjacent countries. No cases were reported among U.S. soldiers in Vietnam. The disease lacks epidemic potential.

### History

Rhinosporidiosis was first described in 1896 in Argentina, where few cases have been reported since. Guillermo Seeber, a medical student in Buenos Aires, described a 19-year-old farm worker whose breathing was impaired by a nasal mass. The pathogen was considered a coccidia-like protozoan, but in 1923, Ashworth determined it was a fungus and established the current name.<sup>116</sup>

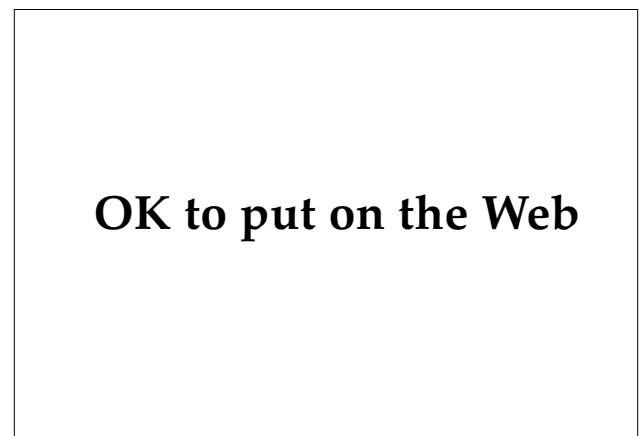### Epidemiology and Distribution

Nearly 90% of cases of rhinosporidiosis are from India and Sri Lanka. The disease has been reported worldwide except in parts of Europe and Oceania.

Details of transmission remain largely speculative, but infection seems to follow exposure to contaminated water. Paddy cultivators and persons who bathe in waters frequented by large farm animals are at increased risk. Young men are most often affected, but this may reflect occupational exposure. The disease also occurs in horses, mules, cattle, goats, dogs, and birds.<sup>116,117</sup>

### Clinical Manifestations

In 70% of cases, patients with rhinosporidiosis present with a friable, usually pedunculated, polyp



**Fig. 18-28.** Although most patients with rhinosporidiosis present with nasal lesions, other mucosal sites such as the conjunctiva may also be affected. The glistening, red, pedunculated lesion may have the appearance of a pyogenic granuloma. Photograph: Courtesy of Colonel William D. James, Medical Corps, US Army, Washington, DC.

emerging from the nasal mucosa (see Figure 18-1). The surface of lesions appears vascular and has sharply defined white dots corresponding to visible sporangia. Usually only one nostril is involved, though both may be. Mucosal sites involved less frequently include the palpebral conjunctiva (Figure 18-28), oropharynx and nasopharynx, external ear canal, and genitalia. Visceral dissemination has been reported several times.<sup>113,114,116-118</sup>

### Diagnosis

Histopathological demonstration of the charac-

teristic thick-walled, giant sporangia is diagnostic. The organisms are abundant and appear in various sizes and stages of development.<sup>118</sup> Recently, *R seeberi* has been cultivated successfully in vitro in a human epithelial cell culture.<sup>119</sup> The technique is not suitable for routine diagnostic work.

### Treatment

Medical management is inadequate. Excision of the polyps is necessary, although recurrences are common.<sup>117</sup>

## OPPORTUNISTIC MYCOSES AND MISCELLANEOUS INFECTIONS

In addition to the systemic and subcutaneous mycoses, deep fungal skin diseases also include the opportunistic mycoses and miscellaneous infections. Cryptococcosis was formerly an uncommon opportunistic infection, but it is seen frequently now in HIV-infected persons. Entomophthoramyiasis is a rare, tropical fungal infection of deep subcutaneous tissues of immunocompetent hosts. Actinomycosis and nocardiosis are traditionally placed with the deep fungal infections although they are caused by related, true bacteria.

### Cryptococcosis

Cryptococcosis, also called Busse-Buschke's disease, torulosis, and European blastomycosis, is an opportunistic infection that has its most severe effects on the central nervous system. Cutaneous cryptococcosis occurs in approximately 15% of patients with disseminated disease.

The disease is caused by *Cryptococcus neoformans*, the only basidiomycete known to cause deep fungal infections. The organism has a perfect state (*Filobasidiella neoformans*) but lacks thermal dimorphism. The pathogenic form is a unicellular, round-to-oval, thin-walled yeast that reproduces by budding. In tissue, *C neoformans* often acquires a thick, mucoid, polysaccharide capsule, assuming a size of 4 to 12  $\mu\text{m}$ . Differences in capsular antigenicity produce four serotypes (A, B, C, and D), of which types A and D are most common in the United States.<sup>120,121</sup> Capsular features influence virulence, although the patient's immune status determines the course of the disease. Two varieties, *C neoformans* var *neoformans* and *C neoformans* var *gattii*, but rarely other cryptococcal species, cause disease.<sup>120</sup>

### Epidemiology and Distribution

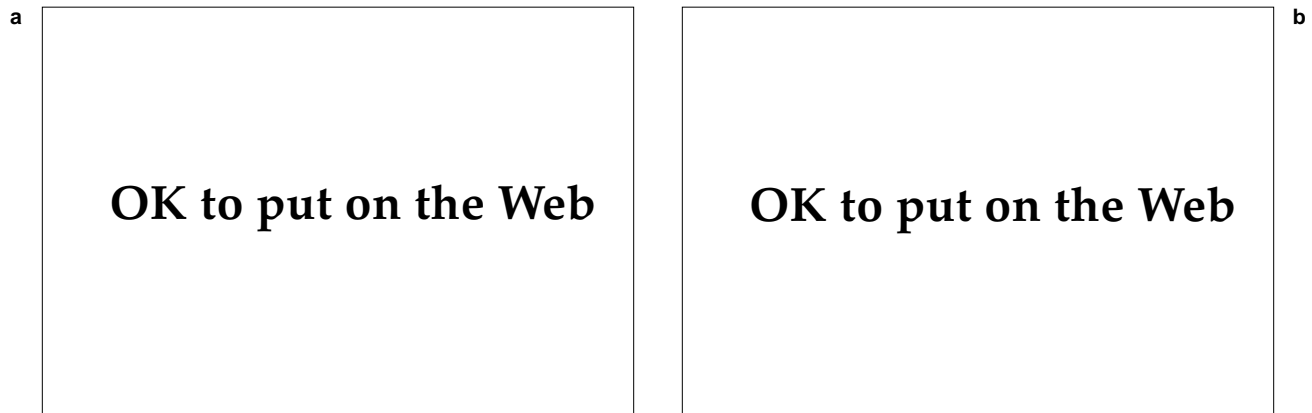
Cryptococcosis, a cosmopolitan disease, is reported most frequently from temperate regions. *C neoformans* is ecologically associated with birds, especially pigeons, because it thrives in their excreta. The organism passes harmlessly through the bird's gut. Pigeon fanciers often have antibodies, indicating frequent exposure, but do not have an increased rate of infection. *C neoformans* is easily recovered from pigeon excrement but is rapidly cleared from soil by *Acanthamoeba* organisms.

In Australia, *Cryptococcus neoformans* var *gattii* is closely associated with *Eucalyptus camaldulensis*, one of the few trees on which koalas feed. Koalas pass the yeast fecally (in the same ecological role served by pigeons elsewhere) but also contract cryptococcosis occasionally.<sup>122</sup> Serious infections caused by *Cryptococcus neoformans* var *gattii* have been found not only in immunocompromised but also in immunocompetent patients.<sup>123</sup>

Persons at increased risk for infection are those with impaired cell-mediated immunity from, for example, chronic corticosteroid therapy, lupus erythematosus, sarcoidosis, or iatrogenic immunosuppression associated with organ transplantation.<sup>121</sup> Cryptococcal infection in an HIV-infected person meets the CDC definition for AIDS. Indeed, the unexpected diagnosis of cutaneous cryptococcosis requires prompt evaluation for other involved organs and for underlying immunodeficiency.

### Clinical Manifestations

The primary infection in cryptococcosis is pulmonary, but involvement of the central nervous



**Fig. 18-29.** Disseminated cryptococcal infection usually occurs in immunocompromised individuals. (a) Most lesions of cutaneous cryptococcosis are not distinctive. (b) However, in an individual infected with the human immunodeficiency virus, the lesions may resemble those seen in patients with molluscum contagiosum. Photograph (b): Courtesy of Colonel Richard Gentry, Medical Corps, US Army, Aurora, Colo.

system is the most common and serious complication. Cutaneous manifestations appear in approximately 15% of persons with disseminated disease, occasionally before the start of life-threatening meningeal involvement (see Figure 18-1).<sup>124</sup> The clinical diagnosis of cutaneous cryptococcosis is difficult because the manifestations are diverse and nonspecific (Figure 18-29). Most often, painless papules arise on the head or neck and then evolve into nodules, pustules, abscesses, grouped vesicles, purpura, vasculitis, plaques, or ulcers.<sup>125-127</sup> Two uncommon but well-described cutaneous presentations are cryptococcal cellulitis in prednisone-treated patients who have had renal transplants<sup>125,128</sup> and molluscum-like facial papules in patients with AIDS.<sup>124</sup> More rarely, the lesions resemble pyoderma gangrenosum or Kaposi's sarcoma. Primary inoculation cryptococcosis is extremely rare<sup>129-131</sup> and it is best to consider a cutaneous lesion evidence of disseminated cryptococcosis until proven otherwise.<sup>126</sup>

### Diagnosis

The clinical diagnosis may be difficult but the histological diagnosis is not. Two patterns—gelatinous and granulomatous—are seen in biopsy specimens. The gelatinous pattern demonstrates many organisms with minimal host response. The thick, mucopolysaccharide capsules do not stain with hematoxylin-eosin, producing a sievelike appearance (Figure 18-30). The granulomatous pattern has fewer organisms, which measure 2 to 4  $\mu\text{m}$  in size, with inconspicuous capsules. In this type, the host response is vigorous and organisms are seen

within macrophages and giant cells.<sup>59</sup> Mucopolysaccharide capsules are enhanced with Meyer mucicarmine stain but the organisms within are better seen with periodic acid–Schiff stain. Gram's stain, India ink, and Tzanck preparations on aspirated or biopsied material also may reveal the organisms.<sup>125</sup> Culture of skin, sputum, and cerebrospinal fluid should be set up on Sabouraud's agar.<sup>121</sup>

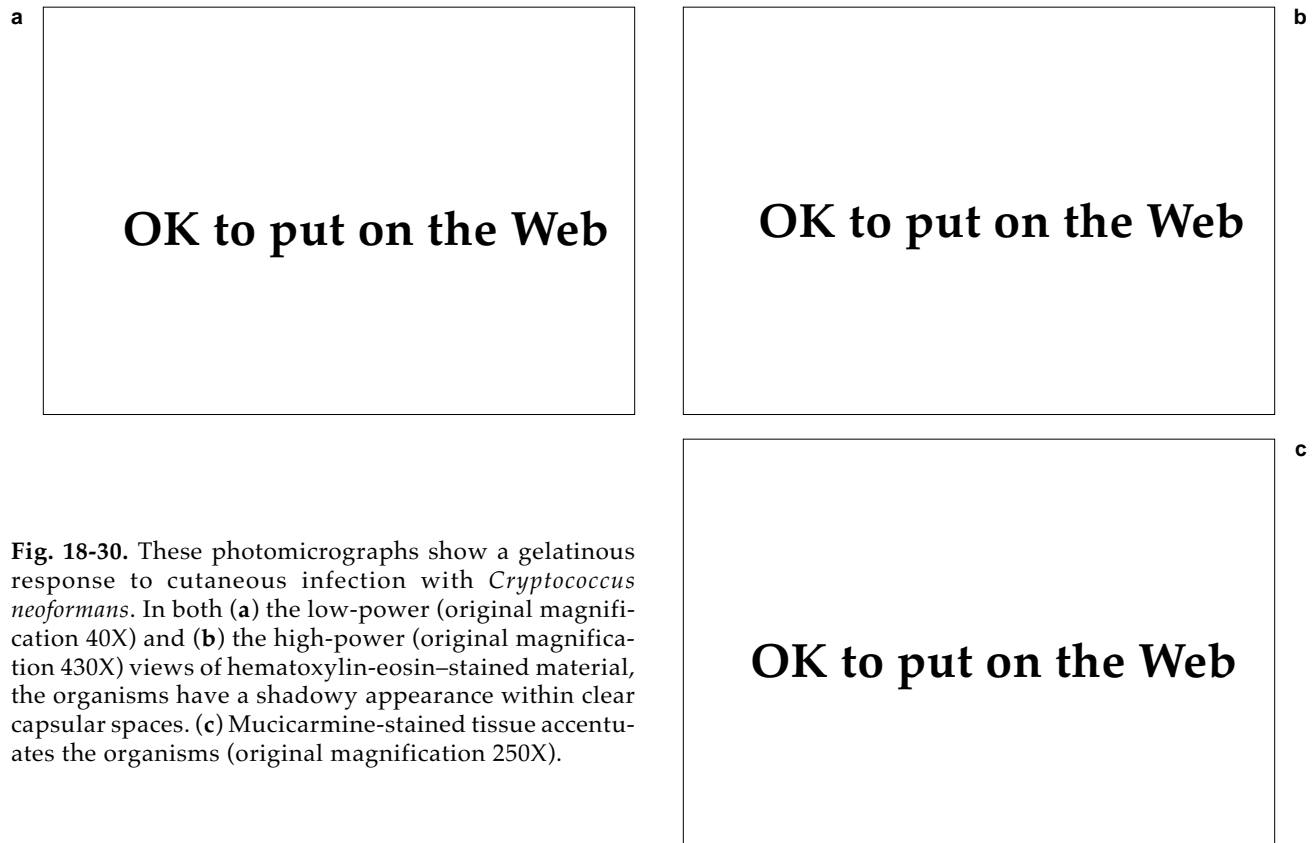
Cryptococcal infections of the meninges are traditionally diagnosed by examining a cerebrospinal fluid–India ink preparation, which has only 50% sensitivity. Latex agglutination tests for cryptococcal antigens are more sensitive. Serologic tests may demonstrate antibodies.

### Treatment

Disseminated cryptococcosis is usually fatal if untreated. Combination therapy with flucytosine and amphotericin is the treatment of choice for cryptococcal meningitis.<sup>121,132</sup> Fluconazole is proving increasingly valuable in managing cryptococcosis in patients with AIDS.

### Entomophthoramycosis

Entomophthoramycosis (also called entomophthoromycosis, subcutaneous zygomycosis or phycomycosis, rhinophycomycosis, and rhin-entomophthoromycosis) comprises two rare infections, conidiobolomycosis and basidiobolomycosis, that are caused by the related zygomycetes *Conidiobolus coronatus* and *Basidiobolus ranarum*, respectively. Both diseases occur mainly in forested



**Fig. 18-30.** These photomicrographs show a gelatinous response to cutaneous infection with *Cryptococcus neoformans*. In both (a) the low-power (original magnification 40X) and (b) the high-power (original magnification 430X) views of hematoxylin-eosin-stained material, the organisms have a shadowy appearance within clear capsular spaces. (c) Mucicarmine-stained tissue accentuates the organisms (original magnification 250X).

tropical regions even though the causative fungi are ubiquitous. *Conidiobolus coronatus* naturally occurs both as a plant saprophyte and as a pathogen of several arthropods. *Basidiobolus ranarum* is frequently recovered from the digestive tracts of reptiles and amphibians.<sup>133</sup> Their portal of entry and incubation period in humans is unknown. Neither organism is opportunistic. Some generalizations regarding each infection can be made (see Figure 18-1).

Conidiobolomycosis is usually confined to subcutaneous tissues of and surrounding the nose. The disease usually occurs in adult males, starting as a swelling of the inferior nasal turbinates with subsequent bilateral invasion of perinasal structures (such as the sinuses and upper lip). The resulting masses are firm, mobile, nontender, and profoundly disfiguring but rarely lethal.<sup>133-135</sup> The patient generally remains otherwise healthy, a feature that clinically distinguishes this condition from rhinocerebral mucormycosis. Basidiobolomycosis occurs as large, indurated, subcutaneous masses on the proximal extremities, buttocks, or trunk of healthy children. Biopsy specimens of both organisms show broad hyphae with infrequent septae and no vascular

invasion. The hyphae are surrounded by eosinophilic debris (the Splendore-Hoeppli phenomenon).

Treatment consists of oral potassium iodide.<sup>135</sup> Amphotericin alone is ineffective but ketoconazole has shown some promise.<sup>136</sup>

### Actinomycosis

Infections caused by actinomycetes (also called ray fungi) are traditionally placed with fungal disorders despite their proper position among true bacterial diseases. Synonyms include lumpy jaw, leptothricosis, and streptothricosis. The source of infection is the normal oral flora harboring *Actinomyces israelii*. Several clinical forms of actinomycosis are recognized: cervicofacial (the most common), thoracic, and abdominal. Another form, pelvic, was linked with endometritis associated with intrauterine devices.<sup>137</sup>

Years ago, actinomycosis was commonly diagnosed but it is rare in the United States now because of improved oral hygiene.<sup>137</sup> During World War II, there were approximately 230 cases of actinomycosis in U.S. troops. Of these, four died of complications of their infections.<sup>138</sup>

## OK to put on the Web

**Fig. 18-31.** This Fijian soldier developed cervicofacial actinomycosis after repeated dental procedures on an abscessed tooth. On palpation, the mass was woody and adherent to the mandible. Exploratory surgery showed five yellow-green sulfur granules, each approximately 2 mm in diameter.

*Actinomyces israelii* is the most common cause of human actinomycosis. Several congeners and members of related genera (*Arachnia*, *Bifidobacterium*) have also been implicated. They are anaerobic, Gram-positive, filamentous bacteria that grow best under anaerobic conditions. *Actinomyces bovis* causes actinomycosis of cattle, commonly presenting as woody tongue disease.<sup>139</sup>

The clinical forms of actinomycosis are characterized by chronic suppuration. Predisposing factors to cervicofacial infection include accidental trauma to the area, dental extraction, caries, or other evidence of poor oral hygiene. Patients with cervicofacial actinomycosis typically present with a painless, indurated mass growing insidiously along the jawline (Figure 18-31). The masses consist of deep nodules that coalesce and form sinuses draining to the exterior (see Figure 18-1). The discharge often contains minute, yellow spherules (1–5 mm in diameter) called sulfur granules. They contain no sulfur but are colonies of organisms that form dense

aggregates of mycelia.<sup>140</sup> The swellings are characteristically woody in their firmness. Mandibular periostitis and osteomyelitis may ensue. Abdominal and thoracic infections follow aspiration or ingestion of oral material. Their cutaneous manifestations also appear as sinuses draining to the exterior.<sup>137,139,140</sup>

The diagnosis is confirmed by detecting organisms by culture, biopsy, or tissue examination. Gram's stain of a crushed granule shows thin (approximately 1  $\mu$ m), Gram-positive filaments radiating and intertwining along the periphery.<sup>139</sup> Biopsy specimens stained with hematoxylin-eosin show that the centers of grains are basophilic and the fringes are eosinophilic (Figure 18-32). *Actinomyces* may be distinguished from *Nocardia* by their lack of acid-fastness and by specific fluorescent antibody stains. Culture has special requirements so prior consultation with a laboratory officer is necessary.<sup>140</sup>

## OK to put on the Web

## OK to put on the Web

**Fig. 18-32.** Histology of actinomycotic granule. (a) Basophilic center and eosinophilic periphery (hematoxylin-eosin stain, original magnification 100X). (b) Radiating fringe of filamentous organisms from the same tissue (hematoxylin-eosin stain, original magnification 250X).

Cervicofacial infection requires long-term antibiotic therapy, usually 6 months or more, often coupled with surgical debridement of indurated masses. Penicillin is the drug of choice and should be given parenterally during the initial weeks of therapy.<sup>140</sup>

### Nocardiosis

Several forms of nocardiosis involve the skin. The most common and serious form mostly affects debilitated hosts and is caused by *Nocardia asteroides*. It usually causes a pleuropulmonary disease resembling tuberculosis. Secondary involvement of the skin is due to hematogenous spread or the formation of thoracic sinuses. Its most serious complication is metastatic cerebral infection.<sup>141</sup> Primary cutaneous nocardiosis is caused by *Nocardia brasiliensis*, the organism also responsible for most New World actinomycetomas. This form typically

follows plant-associated percutaneous injuries to the hands, followed by a chain of nodules ascending along lymphatic channels (see Figure 18-1). By history and examination, primary cutaneous nocardiosis may be clinically indistinguishable from lymphocutaneous sporotrichosis.<sup>142</sup> Diagnosis requires identification of the organism because there are no pathognomonic clinical features.<sup>143</sup> *Nocardia* grows slowly on a wide range of culture media. Gram's stain of purulent material shows Gram-positive filaments that also are partially acid-fast. Granules, as seen in nocardial actinomycetoma, are absent. Initial therapy should be with cotrimoxazole or other sulfa derivatives. Because long-term treatment is necessary, antibiotic sensitivity studies should be conducted. Other unrelated agents, such as minocycline and amikacin, are often effective.<sup>141,142</sup> Incision and drainage or excision of lymphocutaneous abscesses also may be indicated.<sup>143</sup>

### SUMMARY

Deep fungal infections can involve a number of organ systems, and patients can present with a broad range of clinical signs and symptoms. Often, it is the cutaneous aspects of an illness that allow clinicians to make a diagnosis, whether by physical examination, biopsy, or culture.

Many pathogenic fungi have distinctive environmental or geographical predilections. Consequently, the diseases they cause also have environmental or geographical distributions. Our knowledge of coccidioidomycosis, for example, comes largely from the problems the disease posed during World War II exercises in Arizona

and California. Military physicians continue to see patients with systemic coccidioidomycosis acquired during duty in the southwestern United States.

Several of the deep mycoses are uncommon or unreported in the U.S. armed forces or, for that matter, in personnel of any military. The endemic foci of several diseases are in areas where armies have rarely deployed. As the missions of the U.S. military evolve and as populations migrate, however, it behooves medical officers to know the epidemiology and clinical manifestations of even the uncommon deep mycoses.

### REFERENCES

1. Goodwin RQ, Des Prez, RM. Histoplasmosis. *Am Rev Respir Dis.* 1978;117:929–956.
2. Moser SA, Lyon FL, Greer DL. Systemic mycoses. In: Wentworth BB, ed. *Diagnostic Procedures for Mycotic and Parasitic Infections.* 2nd ed. Washington, DC: American Public Health Association; 1988: 173–238.
3. Darling ST. A protozoön general infection producing pseudotubercles in the lungs and focal necrosis in the liver, spleen, and lymph nodes. *JAMA.* 1906;46:1283–1285.
4. Darling ST. Histoplasmosis: A fatal infectious disease resembling kala-azar found among natives of tropical America. *Arch Intern Med.* 1908;2:107–123.
5. Ziperman HH. A medical history of the Panama Canal. *Surg Gynecol Obst.* 1973;137:104–114.
6. Zimmerman LE. A missing link in the history of histoplasmosis in Panama. *US Armed Forces Med J.* 1954;5:1569–1573.

7. Young RV, Cleve EA, Vicente-Mastellari A. Acute pulmonary histoplasmosis on the isthmus of Panama. *Arch Intern Med.* 1957;100:430–435.
8. Schwarz J, Baum GL. The history of histoplasmosis, 1906 to 1956. *N Engl J Med.* 1957;256:253–258.
9. Sell SH. Appreciation of histoplasmosis: The Vanderbilt story. *South Med J.* 1989;82:238–242.
10. Puckett TF. Pulmonary histoplasmosis: A study of twenty-two cases with identification of *H capsulatum* in resected lesions. *Am Rev Tuberc.* 1953;67:453–476.
11. Larrabee WF, Ajello L, Kaufman L. An epidemic of histoplasmosis on the isthmus of Panama. *Am J Trop Med Hyg.* 1978;27:281–285.
12. Burke DS, Churchill FE, Gaydos JC, Kaufman L. Epidemic histoplasmosis in patients with undifferentiated fever. *Milit Med.* 1982;147:466–467.
13. Silverie C, Duchassin M. Enquête sur l'incidence en Guyane Française de l'histoplasmose en milieu militaire au moyen de tests cutanés a l'histoplasmose. *Bull Soc Pathol Exot.* 1966;59:199–207.
14. Gans JC, Karbaat J. Histoplasmosis in Dutch servicemen returning from Surinam. *Trop Geogr Med.* 1967;19:177–186.
15. Byrd RB, Leavey R, Trunk G. The Chanute histoplasmosis epidemic: New variations of urban histoplasmosis. *Chest.* 1975;68:791–795.
16. Hasenclever HF, Shacklette MH, Young RV, Gelderman GA. The natural occurrence of *Histoplasma capsulatum* in a cave. Part 1. Epidemiologic aspects. *Am J Epidemiol.* 1967;86:238–245.
17. Dijkstra JWE. Histoplasmosis. *Dermatol Clin.* 1989;7:251–258.
18. Wheat LJ. Diagnosis and management of histoplasmosis. *Eur J Clin Microbiol Infect Dis.* 1989;8:480–490.
19. Centers for Disease Control. Revision of the CDC surveillance case definition for acquired immunodeficiency syndrome. *MMWR.* 1987;36:1–15S.
20. Lucas AO. Cutaneous manifestations of African histoplasmosis. *Br J Dermatol.* 1970;82:435–447.
21. Williams AO, Lawson EA, Lucas AO. African histoplasmosis due to *Histoplasma duboisii*. *Arch Pathol.* 1971;92:306–318.
22. Giessel M, Rau JM. Primary cutaneous histoplasmosis: A new presentation. *Cutis.* 1980;25:152–154.
23. Leshner JL Jr, Kight FJ. Tzanck preparation as a diagnostic aid in disseminated histoplasmosis. *J Am Acad Dermatol.* 1986;15:534–535.
24. Benenson AS, ed. Histoplasmosis. In: *Control of Communicable Disease in Man.* 15th ed., Washington, DC: American Public Health Association; 1990: 216–219.
25. Wheat LJ, Kohler RB, Tewari RP. Diagnosis of disseminated histoplasmosis by detection of *Histoplasma capsulatum* antigen in serum and urine specimens. *N Engl J Med.* 1986;314:83–88.
26. National Institute of Allergy and Infectious Diseases Mycoses Study Group. Treatment of blastomycosis and histoplasmosis with ketoconazole: Results of a prospective randomized clinical trial. *Ann Intern Med.* 1985; 103:861–872.
27. Saag MS, Dismukes WE. Treatment of histoplasmosis and blastomycosis. *Chest.* 1988;93:848–851.
28. Posada[s] A. Un nuevo caso de micosis fungoides con psorospermias [A new case of mycosis fungoides with spores]. In Spanish. *Anales Circulo Med Argent.* 1892;15:585–597.

29. Smith CE. Epidemiology of acute coccidioidomycosis with erythema nodosum: ("San Joaquin" or "Valley Fever"). *Am J Public Health*. 1940;30:600–611.
30. Egeberg RO. Coccidioidomycosis. In: Havens WP Jr, ed. *Infectious Diseases and General Medicine*. Vol 3. In: Havens WP Jr, Anderson RS, eds. *Internal Medicine in World War II*. Washington, DC: Medical Department, US Army, Office of The Surgeon General; 1968: 49–89.
31. Pappagianis D. Epidemiology of coccidioidomycosis. *Curr Top Med Mycol*. 1988;2:199–238.
32. Drips W Jr, Smith CE. Epidemiology of coccidioidomycosis: A contemporary military experience. *JAMA*. 1964;90:1010–1012.
33. Hooper R, Curley R, Poppell G, Husted S, Schillaci R. Coccidioidomycosis among military personnel in southern California. *Milit Med*. 1980;145:620–623.
34. Roberts PL, Lisciandro RC. A community epidemic of coccidioidomycosis. *Am Rev Respir Dis*. 1967;96: 766–772.
35. Williot J. Un infiltrat pulmonaire coccidioidomycosique [A pulmonary infiltrate from coccidioidomycosis]. In French. *Acta Tuberc Pneumol Belg*. 1965;2:139–146.
36. Sturde HC. Coccidioidomykose bei soldaten der Bundeswehr [Coccidioidomycosis in soldiers of the federal armed forces]. In German. *Z Hautkr*. 1983;58:1601–1615.
37. Sturde HC. Skin test reactivity and residua of coccidioidal pulmonary infections in German airmen. In: Einstein HE, Canizaro A, eds. *Coccidioidomycosis: Proceedings of the 4th International Conference on Coccidioidomycosis*. Washington, DC: National Foundation for Infectious Diseases; 1985: 43–46.
38. Drutz DJ, Catanzaro A. Coccidioidomycosis. *Am Rev Respir Dis*. 1978;117:559–585, 727–771.
39. Johnson WM. Occupational factors in coccidioidomycosis. *J Occup Med*. 1981;23:367–374.
40. Ampel NM, Wieden MA, Galgani JN. Coccidioidomycosis: Clinical update. *Rev Infect Dis*. 1989;11:897–911.
41. Hobbs ER. Coccidioidomycosis. *Dermatol Clin*. 1989;7:227–239.
42. Winn WA. Primary cutaneous coccidioidomycosis. *Arch Dermatol*. 1965;92:221–228.
43. Pappagianis D. The phenomenon of locus minoris resistentiae in coccidioidomycosis. In: Einstein HE, Canizaro A, eds. *Coccidioidomycosis: Proceedings of the 4th International Conference on Coccidioidomycosis*. Washington, DC: National Foundation for Infectious Diseases; 1985: 319–329.
44. Warlick MA, Quan SF, Sobonya RE. Rapid diagnosis of pulmonary coccidioidomycosis: Cytologic *v* potassium hydroxide preparations. *Arch Intern Med*. 1983;143:723–725.
45. Pappagianis D, Zimmer BL. Serology of coccidioidomycosis. *Clin Microbiol Rev*. 1990;3:247–268.
46. Tucker RM, Denning DW, Arathoon, EG, Rinaldi MG, Stevens DA. Itraconazole therapy for nonmeningeal coccidioidomycosis: Clinical and laboratory observations. *J Am Acad Dermatol*. 1990;23:593–601.
47. Smith CE, Beard RR, Rosenberger HG, Whiting EG. Effect of season and dust controls on coccidioidomycosis. *JAMA*. 1946;132:833–838.
48. Benenson AS. Coccidioidomycosis. In: *Control of Communicable Disease in Man*. 15th ed. Washington, DC: American Public Health Association; 1990: 98–100.
49. Gilchrist TC. Protozoan dermatitis. *J Cutan Genitourin Dis*. 1894;12:496.



50. Harvey AM. Two mycoses first described at Johns Hopkins. *Johns Hopkins Med J*. 1973;135:114–123.
51. Steck WD. Blastomycosis. *Dermatol Clin*. 1989;7:241–250.
52. Klein BS, Vergeront JM, Weeks RJ, et al. Isolation of *Blastomyces dermatitidis* in soil associated with a large outbreak of blastomycosis in Wisconsin. *N Engl J Med*. 1986;314:529–534.
53. Dismukes WE. Blastomycosis: Leave it to beaver. *N Engl J Med*. 1986;314:575–576.
54. Vaaler AK, Bradsher RW, Davies SF. Evidence of subclinical blastomycosis in forestry workers in northern Minnesota and northern Wisconsin. *Am J Med*. 1990;89:470–476.
55. Craig MW, Davey WN, Green RA. Conjugal blastomycosis. *Am Rev Respir Dis*. 1970;102:86–90.
56. Furculow ML, Chick EW, Busey JF, Menges RW. Prevalence and incidence studies of human and canine blastomycosis: Cases in the United States, 1885–1968. *Am Rev Respir Dis*. 1970;102:60–67.
57. Carman WF, Freaux JA, Crewe-Brown HH, Culligan GA, Young CN. Blastomycosis in Africa: A review of known cases diagnosed between 1951 and 1987. *Mycopathologia*. 1989;107:25–32.
58. Davies SF, Sarosi GA. Blastomycosis. *Eur J Clin Microbiol Infect Dis*. 1989;8:474–479.
59. Lever WF, Schaumburg-Lever G. Fungal diseases. In: *Histopathology of the Skin*. 7th ed. Philadelphia, Pa: Lippincott; 1990: 364–393.
60. Larsh HW, Schwarz J. Accidental inoculation blastomycosis. *Cutis*. 1977;19: 334–337.
61. Gnann JW Jr, Bressler GS, Bodet CA III, Avent CK. Human blastomycosis after a dog bite. *Ann Intern Med*. 1983;98:48–49.
62. Cockerill FR, Roberts GD, Rosenblatt JE, Utz JP, Utz DC. Epidemic of pulmonary blastomycosis (Namekagon fever) in Wisconsin canoeists. *Chest*. 1984;86:688–692.
63. Chapman SW. *Blastomyces dermatitidis*. In: Mandel GL, Douglas RG Jr, Bennett JE. *Principles and Practice of Infectious Diseases*. 3rd ed. New York, NY: Churchill Livingstone; 1990: 1999–2008.
64. Allison MJ, Gerszten E, Shadomy HJ, Munizaga J, Gonzalez M. Paracoccidioidomycosis in a northern Chilean mummy. *Bull NY Acad Med*. 1979;55:670–683.
65. Ajello L. Paracoccidioidomycosis: A historical review. In: *Paracoccidioidomycosis: Proceedings of the First Pan American Symposium*. Pan American Health Organization Scientific Publication 254. Washington, DC: Pan American Health Organization; 1972: 3–10.
66. Mackinnon JE. On the importance of South American blastomycosis. *Mycopathologia*. 1970;41:187–193.
67. Restrepo A. The ecology of *Paracoccidioides brasiliensis*: A puzzle still unsolved. *Sabouraudia*. 1985;25:323–334.
68. Restrepo A, Salazar ME, Cano LE, Stover EP, Feldman D, Stevens DA. Estrogens inhibit mycelium-to-yeast transformation in the fungus *Paracoccidioides brasiliensis*: Implications for resistance of females to paracoccidioidomycosis. *Infect Immun*. 1984;46:346–353.
69. Restrepo A, Robledo M, Gutiérrez F, Sanclemente M, Castañeda E, Calle G. Paracoccidioidomycosis (South American blastomycosis). *Am J Trop Med Hyg*. 1970;19:68–76.
70. Franco M, Montenegro MR, Mendes RP, Marques SA, Dillon NL, Mota NM. Paracoccidioidomycosis: A recently proposed classification of its clinical forms. *Rev Soc Bras Med Trop*. 1987;20:129–132.

71. Angul-Ortega A. Calcifications in paracoccidioidomycosis: Are they the morphological manifestations of subclinical infections? In: *Paracoccidioidomycosis: Proceedings of the First Pan American Symposium*. Pan American Health Organization scientific publication 254. Washington, DC: Pan American Health Organization; 1972: 129–133.
72. Sugar AM. Paracoccidioidomycosis. *Infect Dis Clin North Am*. 1988;2:913–923.
73. Cano LE, Restrepo A. Predictive value of serologic tests in the diagnosis and follow-up of patients with paracoccidioidomycosis. *Rev Inst Med Trop São Paulo*. 1987;29:276–283.
74. Ferreira-da-Cruz M, Wanke B, Galvão-Castro B. Prevalence of paracoccidioidomycosis in hospitalized adults in Rio de Janeiro (RJ), Brazil. *Mycopathologia*. 1987;97:61–64.
75. Naranjo MS, Trujill M, Munera MI, Restrepo P, Gomez I, Restrepo A. Treatment of paracoccidioidomycosis with itraconazole. *J Med Vet Mycol*. 1990;28:67–76.
76. Restrepo A. Paracoccidioidomycosis. In: Jacobs PH, Nall L, eds. *Antifungal Drug Therapy: A Complete Guide for the Practitioner*. New York, NY: Marcel Dekker; 1990: 181–206.
77. Schenck BR. On refractory subcutaneous abscesses caused by a fungus possibly related to the *Sporotricha*. *Johns Hopkins Hosp Bull*. 1898;93:286–290.
78. Harvey AM. Two mycoses first described at Johns Hopkins. *Johns Hopkins Med J*. 1974;135:114–123.
79. Helm MAF, Berman C. The clinical, therapeutic and epidemiologic features of the sporotrichosis infection on the mines. In: *Sporotrichosis Infection in Mines of the Witwaterstrand: A Symposium*. Transvaal South Africa Chamber of Mines: Transvaal Mine Medical Officer's Association; 1947: 59–67.
80. Belknap BS. Sporotrichosis. *Dermatol Clin*. 1989;7:193–202.
81. Dunstan RW, Langham RF, Reimann KA, Wakenell PS. Feline sporotrichosis: A report of five cases with transmission to humans. *J Am Acad Dermatol*. 1986;15:37–45.
82. Winn RE. Sporotrichosis. *Infect Dis Clin North Am*. 1988;2:899–911.
83. Conti Diaz IA. Epidemiology of sporotrichosis in Latin America. *Mycopathologia*. 1989;108:113–116.
84. Scott EN, Kaufman L, Brown AC, Muchmore HG. Serologic studies in the diagnosis and management of meningitis due to *Sporothrix schenckii*. *N Engl J Med*. 1987;317:935–940.
85. Leshner JL Jr, Smith JG Jr. Antifungal agents in dermatology. *J Am Acad Dermatol*. 1987;17:383–394.
86. Haynes RC Jr, Murad F. Thyroid and antithyroid drugs. In: Goodman AG, Goodman LS, Gilman A, eds. *The Pharmacologic Basis of Therapeutics*. 6th ed. New York, NY: Macmillan; 1980: 1397–1419.
87. Restrepo A, Robledo J, Gómez I, Tabares AM, Gutiérrez R. Itraconazole therapy in lymphangitic and cutaneous sporotrichosis. *Arch Dermatol*. 1986;122:413–417.
88. Rippon JW. Chromoblastomycosis and related dermal infections caused by dematiaceous fungi. In: *Mycology: The Pathogenic Fungi and the Pathogenic Ascomycetes*. 2nd ed. Philadelphia, Pa: WB Saunders; 1982: 249–276.
89. McGinnis MR. Infections caused by black fungi. *Arch Dermatol*. 1987;123:1300–1302.
90. Castro RM, Castro LGM. On the priority of description of chromomycosis. *Mykosen*. 1987;30:397–403.
91. Milam CP, Fenske NA. Chromoblastomycosis. *Dermatol Clin*. 1989;7:219–225.

92. Fukushima R. Chromomycosis in Japan. *Int J Dermatol*. 1983;22:221–229.
93. Vollum DI. Chromomycosis: A review. *Br J Dermatol*. 1977;96:454–458.
94. Zaias N, Rebell G. A simple and accurate diagnostic method in chromoblastomycosis. *Arch Dermatol*. 1973;108:545–546.
95. Fader RC, McGinnis MR. Infections caused by dematiaceous fungi: Chromoblastomycosis and phaeohyphomycosis. *Infect Dis Clin North Am*. 1988;2:925–938.
96. Tuffanelli L, Milburn PB. Treatment of chromoblastomycosis. *J Am Acad Dermatol*. 1990;23:728–732.
97. Benenson AS. Chromoblastomycosis. In: *Control of Communicable Disease in Man*. 15th ed., Washington, DC: American Public Health Association; 1990: 94–95.
98. Magaña M. Mycetoma. *Int J Dermatol*. 1984;4:221–236.
99. Chalmers AJ, Archibald RG. A Sudanese maduramycosis. *Ann Trop Med*. 1917;10:169–214.
100. Gumaa SA, Mahgoub ES, El Sid MA. Mycetoma of the head and neck. *Am J Trop Med Hyg*. 1986;35:594–600.
101. Develoux M, Audoin J, Tregueur J, Vetter JM, Warter A, Cenac A. Mycetoma in the Republic of Niger: Clinical features and epidemiology. *Am J Trop Med Hyg*. 1988;38: 86–90.
102. Vanbreuseghem R. The early diagnosis of mycetoma. *Dermatol Int*. 1967;6:123–140.
103. Palestine RF, Rogers RS III. Diagnosis and treatment of mycetoma. *J Am Acad Dermatol*. 1982;6:107–111.
104. McGinnis MR, Fader RC. Mycetoma: A contemporary concept. *Infect Dis Clin North Am*. 1988;2:939–954.
105. Magaña M, Magaña-García M. Mycetoma. *Dermatol Clin*. 1989;7:203–217.
106. Mariat F, Destombes P, Segretain G. The mycetomas: Clinical features, pathology, etiology and epidemiology. *Contrib Microbiol Immunol*. 1977;4:1–39.
107. Barnetson RStC, Milne LJR. Mycetoma. *Br J Dermatol*. 1978;99:227–231.
108. Zaias N, Taplin D, Rebell G. Mycetoma. *Arch Dermatol*. 1969;99:215–225.
109. Caldwell DK, Caldwell MC, Woodard JC, et al. Lobomycosis as a disease of the Atlantic bottle-nosed dolphin (*Tursiops truncatus* Montagu, 1821). *Am J Trop Med Hyg*. 1975;24:105–114.
110. Rippon JW. Lobomycosis. In: *Mycology: The Pathogenic Fungi and the Pathogenic Ascomycetes*. 2nd ed. Philadelphia, Pa: WB Saunders; 1982: 315–324.
111. Baruzzi RG, Rodrigues DA, Michalany NS, Salomão R. Squamous-cell carcinoma and lobomycosis (Jorge Lobo's disease). *Int J Dermatol*. 1989;28:183–185.
112. Fuchs J, Mibradt R, Pecher SA. Lobomycosis (keloidal blastomycosis): Case reports and overview. *Cutis*. 1990;46:227–234.
113. Binford CH, Dooley JR. Rhinosporidiosis. In: Binford CH, Connor DH, eds. *Pathology of Tropical and Extraordinary Diseases: An Atlas*. Vol 2. Washington, DC: Armed Forces Institute of Pathology; 1976: 597–599.
114. Lasser A, Smith HW. Rhinosporidiosis. *Arch Otolaryngol*. 1976;102:308–310.

115. Easley JR, Meuten DJ, Levy MG. Nasal rhinosporidiosis in the dog. *Vet Pathol.* 1986;23:50–56.
116. Karunaratne WAE. Rhinosporidiosis in man. London, England: Athlone Press; 1964.
117. Samaddar RR, Sen MK. Rhinosporidiosis in Bankura. *Indian J Pathol Microbiol.* 1990;33:129–136.
118. Thianprasit M, Thagerngpol K. Rhinosporidiosis. *Curr Top Med Mycol.* 1989;3:64–85.
119. Levy MG, Meuten DJ, Breitschwerdt EB. Cultivation of *Rhinosporidium seeberi* in vitro: Interaction with epithelial cells. *Science.* 1986;234:474–476.
120. Pincus DH, Salkin IF. Human infections caused by yeastlike fungi. In: Wentworth BB, ed. *Diagnostic Procedures for Mycotic and Parasitic Infections.* 2nd ed. Washington, DC: American Public Health Association; 1988: 239–269.
121. Diamond RD. *Cryptococcus neoformans*. In: Mandel GL, Douglas RG Jr, Bennett JE. *Principles and Practice of Infectious Diseases.* 3rd ed. New York, NY: Churchill Livingstone; 1990: 1980–1989.
122. Ellis DH, Pfeiffer TJ. Ecology, life cycle, and infectious propagule of *Cryptococcus neoformans*. *Lancet.* 1991; 336:923–925.
123. Levitz SM. The ecology of *Cryptococcus neoformans* and the epidemiology of cryptococcosis. *Rev Infect Dis.* 1991;13:1163–1169.
124. Rico MJ, Pennys NS. Cutaneous cryptococcosis resembling molluscum contagiosum in a patient with AIDS. *Arch Dermatol.* 1985;121:901–902.
125. Hall JC, Brewer JH, Crouch TT, Watson KR. Cryptococcal cellulitis with multiple sites of involvement. *J Am Acad Dermatol.* 1987;17:329–332.
126. Barfield L, Iacobelli D, Hashimoto K. Secondary cutaneous cryptococcosis: Case report and review of 22 cases. *J Cutan Pathol.* 1988;15:385–392.
127. Hernandez AD. Cutaneous cryptococcosis. *Dermatol Clin.* 1989;7:269–274.
128. Carlson KC, Mehlmauer M, Evans S, Chandrasoma P. Cryptococcal cellulitis in renal transplant recipients. *J Am Acad Dermatol.* 1987;17:469–472.
129. Baes H, Van Cutsem J. Primary cutaneous cryptococcosis. *Dermatologica* 1985;171:357–361.
130. Glaser JB, Garden A. Inoculation of cryptococcosis without transmission of the acquired immunodeficiency syndrome. *N Engl J Med.* 1985;313:266.
131. Sussman EJ, McMahan F, Wright D, Friedman HM. Cutaneous cryptococcosis without evidence of systemic involvement. *J Am Acad Dermatol.* 1984;11:371–374.
132. Sugar AM, Stern AM, Dupont B. Overview: Treatment of cryptococcal meningitis. *Rev Infect Dis.* 1990;12(Suppl):S338–348.
133. Rippon JW. Entomophthoromycosis. In: *Mycology: The Pathogenic Fungi and the Pathogenic Ascomycetes.* 2nd ed. Philadelphia, Pa: WB Saunders; 1982: 303–314.
134. Segura JJ, Gonzalez K, Berrocal J, Marin G. Rhinoentomophthoromycosis: Report of the first two cases observed in Costa Rica (Central America), and review of the literature. *Am J Trop Med Hyg.* 1981;30:1078–1084.
135. Herstoff JK, Bogaars H, McDonald CJ. Rhinophycomycosis entomophthorae. *Arch Dermatol.* 1978; 114:1674–1678.

136. Towersey L, Wanke B, Estrella RR, Londero AT, Mendonça AMN, Neves RG. *Conidiobolus coronatus* infection treated with ketoconazole. *Arch Dermatol*. 1988;124:1392–1396.
137. Bennhoff DF. Actinomycosis: Diagnostic and therapeutic considerations and a review of 32 cases. *Laryngoscope*. 1984;94:1198–1217.
138. Smith DT. Actinomycosis. In: Hoff ED, ed. *Communicable Disease Transmitted Through Contact or by Unknown Means*. Vol 5. In: Coates JB Jr, ed. *Preventive Medicine in World War II*. Washington, DC: Medical Department, US Army, Office of The Surgeon General; 1960: 1–2.
139. Rippon JW. Nocardiosis. In: *Mycology: The Pathogenic Fungi and the Pathogenic Ascomycetes*. 2nd ed. Philadelphia, Pa: WB Saunders; 1982: 51–67.
140. Lerner PI. The lumpy jaw: Cervicofacial actinomycosis. *Infect Dis Clin North Am*. 1988;2:203–220.
141. Lerner PI. *Nocardia* species. In: Mandel GL, Douglas RG Jr, Bennett JE. *Principles and Practice of Infectious Diseases*. 3rd ed. New York, NY: Churchill Livingstone; 1990: 1926–1932.
142. Schwartz JG, McGough DA, Thorner RE, Fetchick RJ, Tio FO, Rinaldi MG. Primary lymphocutaneous *Nocardia brasiliensis* infection: Three case reports and a review of the literature. *Diagn Microbiol Infect Dis*. 1988;10:113–120.
143. Smego RA Jr, Gallis HA. The clinical spectrum of *Nocardia brasiliensis* infection in the United States. *Rev Infect Dis*. 1984;6:164–180.

# Chapter 19

## SEXUALLY TRANSMITTED DISEASES

PAUL M. BENSON, M.D.\*

---

### INTRODUCTION

### MILITARY IMPACT OF SEXUALLY TRANSMITTED DISEASES

### SYPHILIS

- Magnitude of the Problem
- Clinical Manifestations
- Laboratory Diagnosis
- Treatment

### GONORRHEA

- Clinical Manifestations
- Laboratory Diagnosis
- Treatment

### CHANCROID

- Clinical Manifestations
- Laboratory Diagnosis
- Treatment

### GRANULOMA INGUINALE

- Clinical Manifestations
- Complications
- Laboratory Diagnosis
- Treatment

### LYMPHOGRANULOMA VENEREUM

- Clinical Manifestations
- Laboratory Diagnosis
- Treatment

### GENITAL HERPES INFECTION

- Clinical Manifestations
- Laboratory Diagnosis
- Treatment

### GENITAL WARTS

- Clinical Manifestations
- Clinical Diagnosis
- Treatment

### MOLLUSCUM CONTAGIOSUM

- Clinical Manifestations
- Complications
- Diagnosis
- Treatment

### SUMMARY

\*Lieutenant Colonel, Medical Corps, U.S. Army; Dermatology Service, Walter Reed Army Medical Center, Washington, D.C. 20307-5001

## INTRODUCTION

Field medical officers are likely to encounter sexually transmitted diseases (STDs)—a diverse group of infections caused by bacterial, chlamydial, and viral pathogens—in an active-duty population of men and women. Worldwide, STDs account for millions of patient visits to health clinics and serious perinatal complications, and expose sexual partners to the risk of infection with the human immunodeficiency virus (HIV). STDs share several common characteristics<sup>1</sup>:

- they are infectious,
- they spread predominately by sexual activity,
- the usual presentation is in the anogenital area, and
- infection does not confer lifelong immunity.

Genital ulcer disease is a subset of STD in which patients present with ulcers on the genitalia or perineum. This subset includes syphilis, chancroid, granuloma inguinale, lymphogranuloma venereum, and genital herpes. In the United States, genital herpes is the most common cause of genital ulcer disease, accounting for 60% to 70% of ulcer disease in patients attending an STD clinic. In 1991, there were more than 250,000 visits to healthcare providers for genital herpes. Syphilis, the second-most-common cause of genital ulcer disease, was responsible for 10% to 20% of visits to STD clinics. In 1991, approximately 43,000 cases of primary and secondary syphilis were reported. Fewer than 10% of STD visits were for chancroid, with the remaining visits due to infection with lymphogranuloma venereum, granuloma inguinale, and miscellaneous conditions.<sup>2</sup>

Elsewhere in the world, chancroid accounts for more than half of all cases of genital ulcer disease, and the disease is closely linked to prostitution and drug abuse. Syphilis accounts for 10% to 20% of cases; genital herpes for fewer than 10%; and lymphogranuloma venereum, granuloma inguinale, and others account for the remainder.<sup>2</sup>

The evaluation of genital ulcer disease is difficult even for experienced clinicians, and the limited diagnostic tests and laboratory support in dispensaries and field medical units make accurate diagnosis even more difficult. However, important

clinical clues can enable medical officers to be more certain of their diagnoses (Table 19-1 and Figure 19-1).

Many of the bacterial and viral pathogens involved in STDs are able—by mechanisms that remain to be elucidated—to successfully evade the host's (ie, the individual human's) immune system. This may lead to chronic, progressive disease, as in lymphogranuloma venereum or tertiary syphilis; recurrent episodes of disease, as in genital herpes; or asymptomatic carrier states, as in gonorrhea and chancroid. Additionally, persistence of infection may be due to many factors, including antibiotic resistance, ineffective or inappropriate treatment, an immunologically impaired host, or lack of available treatment.

*Risk factors* and *risk behavior* have replaced the term *risk groups* to describe an activity or behavior that has a significant association with the acquisition of STD (Exhibit 19-1). The worldwide spread of infection with HIV has focused much attention on these behaviors because unprotected sexual intercourse, multiple sexual partners, prostitution, and intravenous drug abuse significantly increase the risk of transmission of the HIV virus.<sup>1</sup> It is the responsibility of healthcare providers to do more than simply treat STDs. Not only individual soldiers but also the chain of command must be educated and reeducated on risk factors and behaviors and, when necessary, must make attempts to modify them.

International travel permits rapid mobility of large groups of individuals, with the result that diseases previously thought to be local or regional phenomena suddenly appear in areas far removed from the source. Likewise, microorganisms carry their antibiotic susceptibility profiles with them; as a result, an antibiotic-resistant strain of diseases such as gonorrhea or chancroid from the Philippines or the Middle East may appear abruptly. Clearly, a thorough history, careful contact tracing, laboratory confirmation of antibiotic sensitivities, and follow-up cultures are essential to ensure that appropriate therapy is provided and that the disease is eradicated.

This chapter does not address acquired immunodeficiency syndrome (AIDS) and HIV infection as STDs per se for the following reasons:

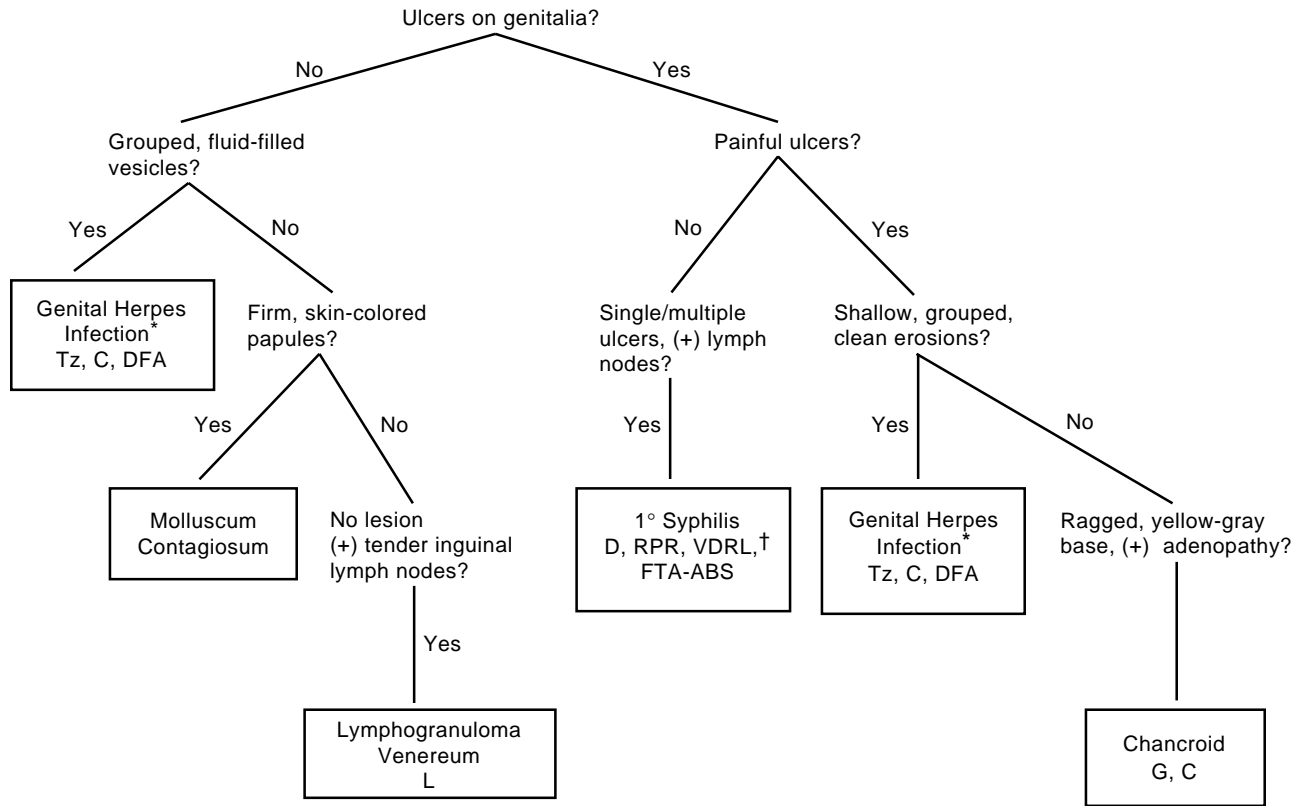
**TABLE 19-1**  
**RELATIVE FREQUENCY OF CLINICAL FEATURES OF GENITAL ULCER DISEASE**

Table 19-1 is not shown because the copyright permission granted to the Borden Institute, TMM, does not allow the Borden Institute to grant permission to other users and/or does not include usage in electronic media. The current user must apply to the publisher named in the figure legend for permission to use this illustration in any type of publication media.

1+: 0%–25%; 2+: 25%–50%; 3+: 50%–75%; 4+: 75%–100%; 1°: primary; 2°: recurrent.

Reprinted with permission from Jessamine PC, Ronald AR. Chancroid and the role of genital ulcer disease in the spread of human retroviruses. *Medical Clinics of North America*. Philadelphia, Pa: WB Saunders; 1990;74(6):1423.





\*patients with genital herpes infection can present both with and without ulcers  
 †RPR and VDRL may be negative in early syphilis  
 (+): positive  
 C: culture  
 D: dark-field microscopy  
 DFA: direct fluorescent antibody  
 FTA-ABS: fluorescent treponemal antibody absorption  
 G: Gram's stain  
 L: serology for lymphogranuloma venereum  
 RPR: rapid plasma reagin test  
 Tz: Tzanck prepreparation  
 VDRL: Venereal Disease Research Laboratory test

Fig. 19-1. A field algorithm for diagnosing genital ulcer disease.

**EXHIBIT 19-1****RISK FACTORS AND RISK BEHAVIORS FOR SEXUALLY ACQUIRED DISEASES**

Exhibit 19-1 is not shown because the copyright permission granted to the Borden Institute, TMM, does not allow the Borden Institute to grant permission to other users and/or does not include usage in electronic media. The current user must apply to the publisher named in the figure legend for permission to use this illustration in any type of publication media.

Reprinted with permission from Eichmann AR. Sexually transmitted diseases. In: Fitzpatrick TB, Eisen AZ, Wolff K, Freedberg IM, Austen KF, eds. *Dermatology in General Medicine*. 4th ed, Vol 2. New York, NY: McGraw-Hill; 1993: 2701.

- HIV-positive military personnel are not deployed;
- there are no recognizable cutaneous signs and symptoms of early HIV infections;
- the cutaneous manifestations of AIDS are usually late signs (this chapter focuses on acute, treatable STDs that have signs and symptoms that allow the medical officer to make a definite or probable diagnosis); and
- because HIV infection and AIDS are complicating and exacerbating factors in other STDs and also in other cutaneous diseases (eg, tuberculosis and leprosy), they are discussed briefly in this and other chapters throughout the book.

**MILITARY IMPACT OF SEXUALLY TRANSMITTED DISEASES**

Among U.S. Army personnel during World War I, STDs accounted for 6,804,818 lost duty days and the discharge from active duty of more than 10,000 men.<sup>3</sup> As a cause of disability and absence from duty, STDs ranked second only to influenza in this conflict. During World War II, the different theaters varied widely in the impact of STDs on military personnel. Worldwide, between the years 1941 and 1945, the incidence of STDs in U.S. Army personnel was about 43 cases per 1,000 individuals.<sup>4</sup> The impact of these figures can be appreciated in a report issued early in World War II that addresses the critical problem of sulfonamide-resistant gonorrhea among U.S. military personnel during the early period of the war:

Circular Letter No. 86, Office of The Surgeon General, 18 August 1942, ... designated eight named general hospitals as fever therapy centers....

These eight hospitals soon proved to be insufficient to care for the mounting load of patients with

sulphonamide-resistant gonorrhea. The average rate of cure with the sulphonamides was falling below 75 percent, owing to the development of sulphonamide-resistant strains of the gonococcus and to the substantial number of chronic cases that probably represented relapse after inadequate self-administered treatment. Every station and general hospital had a mounting backlog of patients with chronic gonorrhea for whom the only prospect of cure and return to duty at that time lay in treatment with fever [therapy].<sup>4(p412)</sup>

During the years 1946 to 1950, the incidence of STDs doubled to more than 82 cases per 1,000 service personnel. During the years 1951 to 1955 of the Korean conflict, the case rate more than doubled again to 184/1,000.<sup>3</sup>

During the Vietnam conflict, STDs were the number one medical diagnosis in the theater, and approximately 90% of this caseload was caused by gonorrhea. The overall incidence of STDs exceeded 260/1,000/y during the period 1963 to 1972. De-

spite the high prevalence of STDs, however, fewer than 1% of individuals required admission to the hospital for therapy.<sup>3</sup>

Much has changed since World War I, when patients with STDs were admitted to hospitals and treated with painful and often dangerous medications. Treatment now is rational and safe, state-of-the-art medical facilities can be transported quickly

to the front, and hospitalization with prolonged convalescence is almost never necessary. Nonetheless, the inability of the military's extensive public health procedures to curb the enormous incidence of STDs among its personnel, especially in wartime, means that military physicians need to attain and maintain clinical competence in the diagnosis and treatment of STDs.

## SYPHILIS

Syphilis is a venereal disease that is caused by the bacterial spirochete *Treponema pallidum* and is transmitted by direct contact, usually sexual intercourse. Among the STDs, syphilis has occupied a unique place in medical literature and lore since the late 15th century. Various theories attempt to explain the origins of syphilis and reasons for the rapid spread and increased severity of the disease among European populations, who knew the disease as the "Great Pox." The Columbian theory proposes that, on returning to Europe in 1493, Columbus's crew brought syphilis with them, having acquired it from natives in the West Indies. However, there are inconsistencies in this theory: syphilis has not been described in early Native Americans, and ancient Chinese writings are known that describe an illness similar to late cutaneous syphilis. Others postulate that syphilis was endemic to European populations during the time of Columbus. At that time, Europe was embroiled in long, protracted wars and syphilis, already present at a low background level, may have become epidemic as a result of the movement of troops and the migration of civilian populations.<sup>5,6</sup>

A newer idea, known as the environmental or unitarian theory, proposes that syphilis, yaws, pinta, and nonvenereal endemic syphilis (ie, bejel) are all variants of the same disease and that they arose from a single ancestral saprophytic treponeme (Figure 19-2). According to this theory, the various expressions of spirochetal disease reflect the influence of temperature, environment, and other factors on pathogenicity and clinical manifestations.<sup>7,8</sup> The relatively benign African diseases yaws and bejel may have been transformed in the susceptible population of Europe into a highly virulent disease with high mortality rates.<sup>9,10</sup>

The venereal nature of the transmission of syphilis was not recognized until the 18th century, and confusion reigned whether gonorrhea and syphilis represented different manifestations of the same disease or were two different diseases. To resolve the issue, in 1767, John Hunter inoculated himself

with urethral exudate from a patient with gonococcal urethritis. In fact, the patient had both syphilis and gonorrhea. Hunter developed both a chancre and urethritis, and he erroneously concluded that the two diseases were disparate manifestations of the same infection.<sup>11</sup> Not until 1838 was the separate nature of gonorrhea and syphilis established.

A dramatic increase in the incidence of primary, secondary, and congenital syphilis in the United States has prompted a resurgence of interest in this ancient disease. The populations most at risk—urban, heterosexual, black and Hispanic men and women with limited access to medical care—are the

Fig 19-2 is not shown because the copyright permission granted to the Borden Institute, TMM, does not allow the Borden Institute to grant permission to other users and/or does not include usage in electronic media. The current user must apply to the publisher named in the figure legend for permission to use this illustration in any type of publication media.

**Fig. 19-2.** Syphilis, yaws, pinta, and nonvenereal syphilis may all have evolved from one ancestral saprophytic spirochete. This photomicrograph of *Treponema pallidum*, the spirochete that causes syphilis, shows the characteristic helical coils. These thin, highly motile microorganisms must be viewed through a dark-field microscope, which uses light reflected off the specimen. Photograph: Reprinted with permission from Smith JL. *Spirochetes in Late Seronegative Syphilis, Penicillin Notwithstanding*. Springfield, Ill: Charles C Thomas; 1969: 317.

same groups experiencing a dramatic increase in the rates of HIV infection as a result of intravenous drug use and sex-for-drugs prostitution.<sup>12</sup> In addition, syphilis in individuals who are infected with HIV may behave in a biologically different manner resulting in serologic aberrations,<sup>13</sup> an increased risk of symptomatic neurosyphilis,<sup>14</sup> and failures with traditional antibiotic regimens.<sup>15</sup>

Syphilis, the “great imitator,” will continue to present clinicians and public health officials with major diagnostic and therapeutic challenges in this decade. The medical officer in a field unit or on board a ship may find himself or herself with a lack of resources and trained personnel to accurately diagnose syphilis in any stage of the disease. Dark-field microscopy, the principal means of diagnosing primary syphilis, is usually unavailable. A new test utilizing direct immunofluorescent staining of dried ulcer exudate (discussed later in this chapter) may allow more accurate and timely diagnosis. The cutaneous and mucosal lesions of secondary and tertiary stages of syphilis may be confused with numerous similar skin eruptions. Pitfalls in the interpretation of serologic tests cause a small but significant number of false-positive and false-negative test results. The legal requirement to report syphilis and the potential embarrassment of contact tracing may lead to less-than-honest answers by patients regarding their sexual exposure and sexual behavior.

A rational approach to the clinical and laboratory diagnosis of primary and secondary syphilis will be presented, geared to the resources available to the field medical officer. Late, or tertiary, syphilis will be discussed briefly; congenital syphilis and syphilis during pregnancy will not; interested readers can find several excellent discussions<sup>16,17</sup> of these subjects. Lastly, the impact of HIV infection on the current syphilis epidemic will be discussed as it relates to changes in diagnosis and treatment.

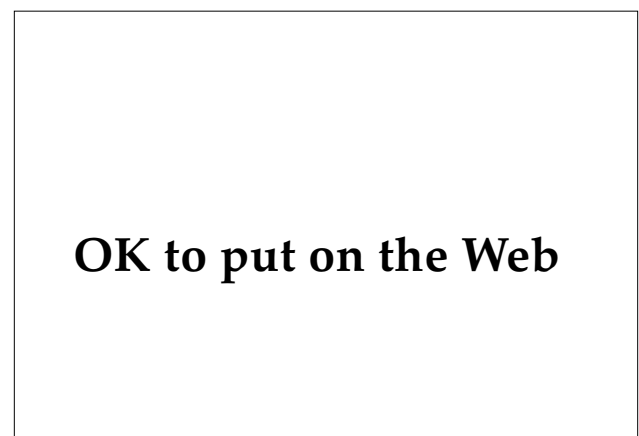### Magnitude of the Problem

In 1990, the Centers for Disease Control (CDC), Atlanta, Georgia, reported that between the years 1981 to 1989 the incidence of primary and secondary syphilis increased an alarming 34% in the United States.<sup>12</sup> This represents the highest incidence of syphilis in the general population since 1949. In 1993, there were 26,279 projected cases of primary and secondary syphilis (10.6/100,000) reported to the STD Surveillance Department of the CDC. In reviewing the data among various population groups, several striking trends are apparent<sup>12</sup>:

- Among white men, the incidence of syphilis actually decreased by 69% during this period, to 3.2/100,000.
- However, among heterosexual black men and women, the incidence of syphilis approached 122/100,000. This is almost a 50-fold difference between black and white populations.
- Incidence rates for Hispanic men and women were intermediate between the rates for whites and blacks.
- The increase in syphilis is most acute for women, regardless of their racial or ethnic background.
- The male-to-female ratio has declined to just below 2:1.

This shift of disease—from homosexual men in the 1970s to heterosexual black men and women in the 1980s—foreshadows a potential public health catastrophe with regard to human HIV infection. Several reports from Africa<sup>18,19</sup> demonstrate that genital ulcer disease, including syphilis, facilitates the sexual transmission of HIV infection. This suggests that segments of the population in the United States, especially urban blacks, may be at great risk of suffering the rapid spread of HIV disease that has been seen among heterosexuals in Africa.

As a result of changes in sexual practices between 1981 and 1989, the largest decrease in syphilis rates occurred among white homosexual and bisexual men (Figure 19-3). However, among black



**Fig. 19-3.** Anal chancre in a man who is also infected with the human immunodeficiency virus. Primary lesions of syphilis are usually asymptomatic and are frequently overlooked by the patient. Such a lesion might mimic a perirectal abscess.

heterosexuals, especially black women, the enormous increase in rates of syphilis and gonorrhea can be traced to the use of illegal drugs—in particular, crack cocaine.<sup>12</sup>

There has also been a resurgence in cases of congenital syphilis that parallels the increase in syphilis among women. During 1989, for example, 1,747 cases of congenital syphilis were reported to the CDC. The majority (1,017 cases) were reported from New York City.<sup>20</sup>

### Clinical Manifestations

Syphilis is not a highly contagious STD. About 30% of individuals exposed to an infected partner will develop syphilis, based on a study<sup>21</sup> that determined the efficacy of antibiotics to abort syphilis infections in individuals exposed to known contacts. Another study<sup>22</sup> demonstrated that about one half of the contacts of individuals with early syphilis developed infection. Transfusion-associated syphilis has been virtually eliminated in the United States as a result of serologic screening of all blood prior to transfusion. However, in developing countries where screening of donated blood is inconsistent, transfusion-associated syphilis still occurs. The practice in the United States of using refrigerated stored components is also advantageous, as *T pallidum* is killed by storage at 4°C.<sup>11</sup>

Syphilis is almost exclusively sexually transmitted and direct contact with skin or mucous membranes, from an infected to an uninfected person, is required for transmission. The organism will pass through mucous membranes and abraded skin. However, it is quite sensitive to a variety of physical and chemical agents and is inactivated by heat, cold, drying, and soap and water.<sup>23</sup> The site of inoculation is usually on the genitalia, although the lips may be involved through kissing, and other areas of the skin may be infected through abrasions. Healthcare workers can be infected if they fail to use gloves when examining lesions or handling infectious exudates or specimens.<sup>9</sup>

Following exposure, *T pallidum* incubates for a variable period ranging from 10 to 90 days (average 21 d). The length of the incubation period is inversely proportional to the size of the inoculum (eg, the larger the inoculum, the shorter incubation period).<sup>24</sup> In the primary stage of syphilis, a chancre develops at the site of inoculation. If untreated, the chancre spontaneously resolves within 3 to 6 weeks. In 60% to 90% of patients, secondary syphilis develops, typically 4 to 10 weeks following the development of primary syphilis. A chancre is still present

in 18% to 34% of patients who present with secondary syphilis.<sup>11</sup> Almost 25% of patients with secondary syphilis do not recall a primary lesion: lesions are often on the cervix or vaginal wall in women, or in the anal canal in women and homosexual men.<sup>23</sup>

With resolution of the secondary stage, the patient enters the latent phase, where there are no clinical signs or symptoms of the disease. For treatment purposes, the U.S. Public Health Service defines *early* latent syphilis as syphilis of less than 1 year's duration after the primary lesion, and *late* latent syphilis as syphilis of longer than 1 year's duration after the onset of the chancre.<sup>25</sup>

After a period ranging from 2 to more than 40 years, clinical signs of late, or tertiary, syphilis may develop in about one third of untreated patients.<sup>11</sup> Tertiary syphilis is now rare in this country because of widespread serologic testing and the availability of antibiotics. However, infection with HIV appears to alter the biological behavior of the spirochete and its responsiveness to therapy.<sup>26</sup> Persistence of spirochetes has been reported<sup>27</sup> in the cerebrospinal fluid of patients who (a) are infected with HIV and (b) have been treated with the doses of penicillin recommended for early syphilis. The treatment guidelines for managing all stages of syphilis in the HIV-infected population will undoubtedly change.

### Primary Syphilis

The primary lesion of syphilis is the chancre, which develops 10 days to 3 months (average 3 wk) after exposure to the spirochete. The classic chancre begins as a painless, firm, rubbery, elevated papule that progresses to develop a central ulceration (Figure 19-4). The base of the ulcer is clean and smooth with a thin, serous exudate present. In men, the chancre is found on the inner aspect of the foreskin, near the frenulum, in the coronal sulcus, and occasionally on the glans or penile shaft. In women, the primary lesion may go unnoticed. It occurs on the cervix, vaginal wall, vulva, and periurethral and perianal areas. Although they are classically described as nontender, occasional chancres are painful owing to secondary infection with bacteria.<sup>28</sup>

Atypical lesions commonly occur. Multiple chancres may be found in up to 25% of patients.<sup>29</sup> In the perianal area, the primary lesion may resemble an anal fissure. Extragenital chancres may be found on the oral mucosa, lips, tonsils, and pharynx of homosexual men or individuals who practice orogenital sex. Anal and rectal chancres also occur and may be asymptomatic, may present as an acute proctitis, or

## OK to put on the Web

**Fig. 19-4.** This painless, clean-based ulcer with rolled borders is typical of primary syphilis.

may be misdiagnosed as a carcinoma. Intraurethral chancres may produce signs and symptoms of urethritis. Lesions in other areas such as fingers are rare (Figure 19-5).<sup>10</sup>

Inguinal lymphadenopathy usually develops within a few days of the appearance of the chancre, if it is located on the external genitalia. Lymphadenopathy may be unilateral or bilateral. The lymph nodes are firm, discrete, and painless unless the chancre is secondarily infected. With extra-genital infection, the lymphadenopathy is more commonly unilateral.<sup>10</sup>

If no treatment is sought or if the chancre is inconspicuous, it heals uneventfully in 3 to 6 weeks.

### Secondary Syphilis

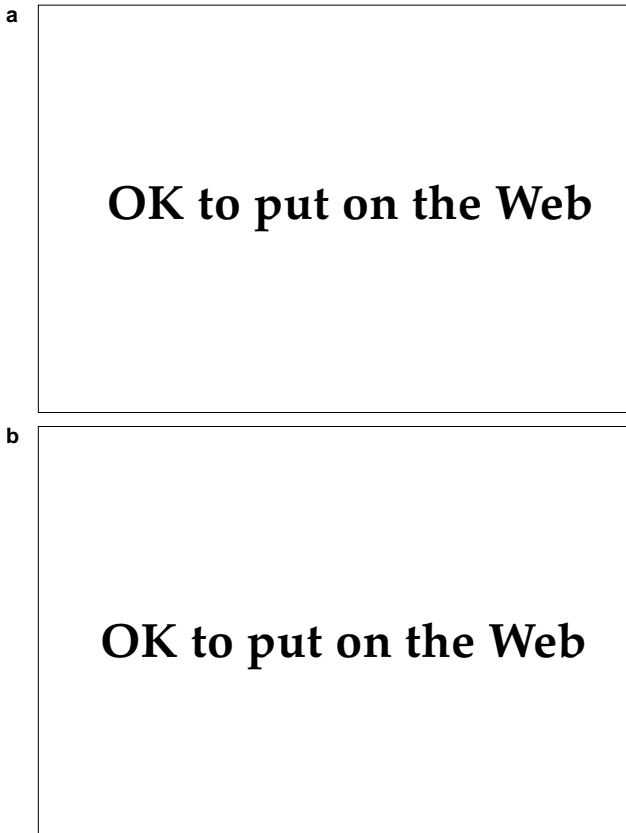
Secondary syphilis develops in 60% to 90% of untreated patients from 4 to 10 weeks after the initial appearance of the chancre. As noted previously, up to one third of patients may still have a chancre present at the time of onset of lesions of secondary disease.<sup>11,30</sup> The characteristic rash, present in 75% to 100% of patients, is typically found on the trunk, extremities, palms, and soles. Condylomata lata lesions are found on mucous membranes and other moist areas such as the inframammary and axillary areas. The cutaneous lesions are polymorphous, and numerous colorful terms have been used to describe the clinical findings. Lesions may be macular, papular, papulosquamous, follicular, annular, pustular, or nodular—the most common presentations are variants of papular lesions. Vesiculobullous lesions do not occur in adults but are frequently seen in congenital

syphilis. Pruritus is usually absent but has been reported in a minority of patients; the presence or absence of pruritus is not a reliable clinical sign in the evaluation of possible syphilitic exanthems.<sup>28</sup>

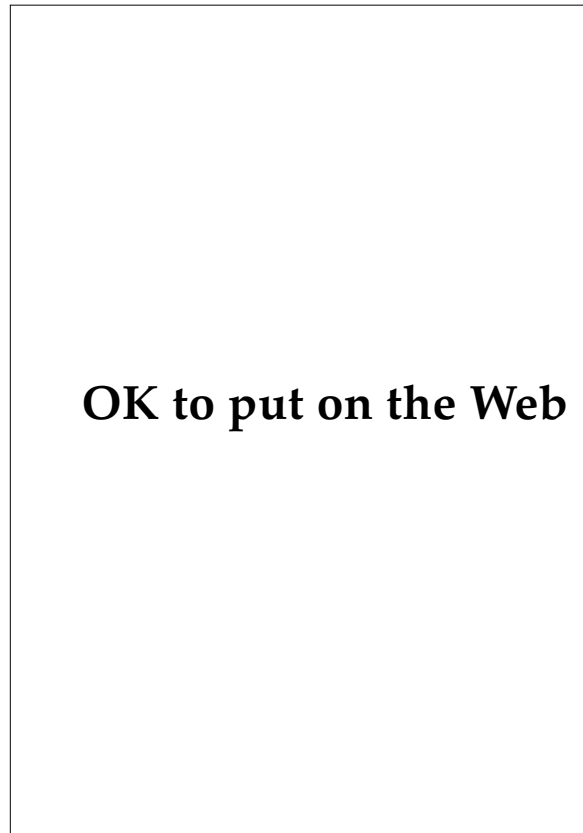
Papular lesions are dull red-to-ham colored but may only appear as elevated areas of hyperpigmentation in dark-skinned patients. Macules and papules are often found together as symmetrically distributed, discrete lesions with a predilection for the palms and soles (Figure 19-6). Various investigators have emphasized the “uniqueness” of palmar and plantar lesions. However, dermatologists are well aware that drug eruptions, viral illnesses, and rickettsial infections (ie, Rocky Mountain spotted fever) may also be important causes of lesions in these areas. Scaling overlying the lesions may be (a) minimal to absent, (b) suggestive of psoriasis, or (c) very thickened and keratotic (ie, lues corneae). Central clearing of papular lesions results in annular lesions (also called annular syphilid) that are commonly seen on the face of dark-skinned individuals. Split papules are common, especially at the corners of the mouth and nostrils in dark-skinned individuals.<sup>31</sup> Less-common secondary lesions include pustules; acneform lesions; follicular or miliary syphilid consisting of small, discrete follicular papules; corymbose (ie, bombshell) syphilid with a large central papule surrounded by smaller lesions (Figure 19-7); and a highly destructive, necrotic, ulcerative form known as lues maligna, which is associated with fever and malaise (Figure 19-8).<sup>28</sup>

## OK to put on the Web

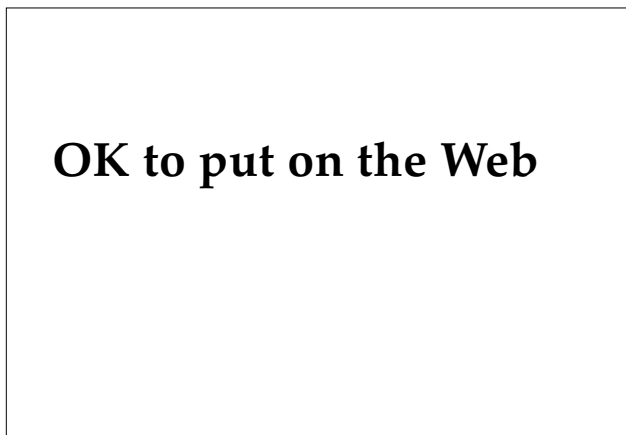**Fig. 19-5.** Syphilitic chancre on a patient's index finger. This chronic, ulcerative lesion mimics many other infectious and inflammatory processes such as tuberculosis, deep fungal infections, or malignancy.



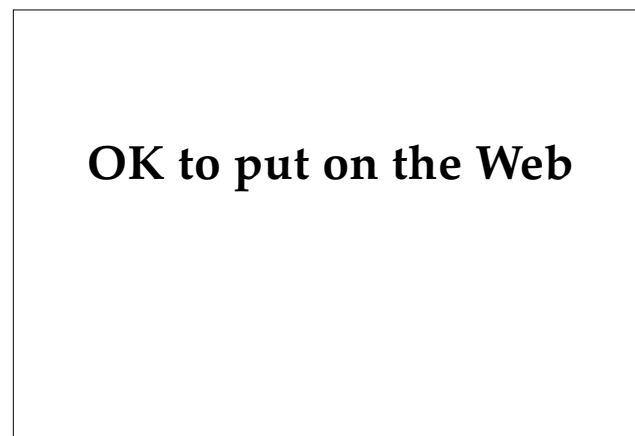**Fig. 19-6.** Papulosquamous lesions of secondary syphilis on (a) the hands and (b) the feet, which are frequently involved in secondary syphilis. The lesions are asymptomatic, pink-to-red papules with slight overlying scale. These eruptions are frequently overlooked by the patient or misdiagnosed as viral exanthems or drug eruptions. Photograph: Courtesy of C. Kalter, MD, Bethesda, Md.



**Fig. 19-8.** Lues maligna showing destructive papulo-necrotic lesions of the face and scalp. This rare, destructive form of secondary syphilis is associated with severe constitutional symptoms and ulcerative lesions. Photograph: Courtesy of Walter Reed Army Medical Center Dermatology Service slide file, Washington, DC.



**Fig. 19-7.** Rupial lesions are uncommon manifestations of secondary syphilis. They are elevated, often with thick, overlying scale-crust. Photograph: Courtesy of C. Kalter, MD, Bethesda, Md.



**Fig. 19-9.** These grayish white, smooth papules of condylomata lata of the glans penis resemble genital warts. When lesions like this are seen, healthcare personnel should look elsewhere on the patient's body for telltale signs of secondary syphilis. Photograph: Courtesy of C. Kalter, MD, Bethesda, Md.

Lesions in the mucous membranes are common and are known as (a) condylomata lata when found in moist intertriginous areas (eg, groin and perianal area) and (b) mucous patches when located in the mouth or on the lips. The lesions are asymptomatic, white-to-grayish, flat-topped papules or plaques, with a mucoid exudate on the surface (Figure 19-9). The lesions may become large, malodorous vegetations. The moist environment in which they develop permits large numbers of spirochetes to survive, and the lesions are highly infectious.<sup>28</sup>

Other reported cutaneous findings include a “moth-eaten,” patchy alopecia, or a diffuse hair loss; hyperpigmentation and hypopigmentation, often as a result of previous inflammation; and syphilitic paronychia.<sup>28</sup>

Constitutional signs and symptoms are variable, although generalized, asymptomatic, nontender lymphadenopathy is present in virtually every patient with secondary syphilis. Signs and symptoms vary from mild to severe and include low-grade fever, headache, myalgias, sore throat, and loss of appetite. Anemia, elevated sedimentation rate, and lymphocytosis may be found on routine blood tests. Almost any organ may be involved during the second stage of syphilis, and clinical and laboratory findings referable to this involvement should be sought. Major organ involvement includes the following<sup>31</sup>:

- syphilitic hepatitis (elevated alkaline phosphatase, rarely jaundice);
- renal involvement (proteinuria, nephrotic syndrome, glomerulonephritis);
- ocular disease (anterior uveitis, photophobia, lacrimation, and rarely chorioretinitis);
- syphilitic myocarditis with electrocardiographic abnormalities; and
- central nervous system involvement, which, although uncommon, may include cranial nerve palsies, acute meningitis, transverse myelitis, neural deafness, or thrombosis of spinal arteries.

Recently, patients with HIV infection have been reported to develop lesions of secondary syphilis in the absence of confirmatory serologic tests (eg, the Venereal Disease Research Laboratory [VDRL] test and the fluorescent treponemal antibody absorption [FTA-ABS] test).<sup>13</sup> Therefore, in any patient with clinical signs or symptoms that may be those of syphilis, laboratory tests—and even skin biopsy—should be done early and routinely.

If secondary syphilis is not treated, the lesions spontaneously resolve in 1 to 3 months, with secondary relapses occurring in as many as 25% of patients,<sup>32</sup> usually during the first year after infection. After resolution of the secondary lesions, the patient enters either the early or the late latent disease phase. This division has important medical implications, as patients with early latent disease (a) may have relapses of secondary lesions during this time and (b) are potentially infectious to their sexual partners. Individuals in the late latent phase are generally not infectious.<sup>11</sup>

### Tertiary Syphilis

Tertiary syphilis is now a rare disease in the United States. About 70% of patients with untreated syphilis will remain asymptomatic; the remainder will progress to tertiary disease and may present with late benign gummata (16%), cardiovascular syphilis (9.6%), neurosyphilis (6.5%), or involvement of bone or virtually any other organ.<sup>28</sup>

Gummata (ie, superficial or deep, destructive granulomatous lesions that involve skin, subcutaneous tissues, or bone) tend to occur on the extremities, especially at the sites of trauma and in the head and neck. The lesions, which are asymptomatic, begin as nodules or subcutaneous masses that often ulcerate and coalesce to form large irregular plaques with annular borders. The skin may be secondarily involved by direct extension from underlying bony gummata. The lesions heal slowly with atrophy and pigmentary changes. Differential diagnosis includes malignancy, tuberculosis, leprosy, cutaneous lymphomas, and deep mycoses, among others.<sup>11,28</sup>

The clinical presentation of syphilitic involvement of the central nervous system has changed recently, for unknown reasons. General paresis and tabes dorsalis are much less common than in previous times and seizure disorders and neuro-ophthalmic findings are more often encountered.<sup>28</sup> A discussion of neurosyphilis is beyond the scope of this chapter; however, recent experiences with late syphilis in patients infected with HIV suggest that current treatment regimens are inadequate to prevent this complication in this population. Two groups of investigators<sup>26,33</sup> have reported development of symptomatic neurosyphilis in patients infected with HIV despite treatment with recommended doses of benzathine penicillin.



## Laboratory Diagnosis

### Culture

Culture of treponemes is both unavailable and impractical for the rapid diagnosis of syphilis. However, the recent confirmation that *T pallidum* can successfully be propagated in vitro will undoubtedly increase knowledge of both the molecular biology and the spirochete–host interaction that leads to infection.

*T pallidum*, a spirochete, the causative organism of syphilis, is a motile, flexible, rod-shaped bacterium with 8 to 14 helical coils that gives the treponeme its characteristic shape. The genus *Treponema* (from the Greek words *trepo* and *nema* meaning “turning thread”) contains the spirochetes that cause syphilis, yaws, pinta, and nonvenereal syphilis; the species are indistinguishable both morphologically and serologically. Differentiation of the pathogenic spirochetes is based solely on their mode of infection, the severity of the infection, and the infectivity for laboratory animals. As a result, the nomenclature has been changed to reflect the close relatedness of the treponemes<sup>9</sup>:

- *Treponema pallidum* (which causes syphilis) is now called *T pallidum* (subspecies *pallidum*);
- *Treponema pertenuis* (which causes yaws) is now called *T pallidum* (*pertenuis*); and
- the *Treponema pallidum* variant that causes endemic syphilis is now called *T pallidum* (*endemicum*).

In the laboratory, *T pallidum* is usually maintained in rabbit testes. Until recently, the spirochete had never been cultured outside a human or animal host. Using special tissue culture techniques, the organism has been shown to multiply through several generations in rabbit epithelial cells. Treponemes were found to attach and replicate on the surface of tissue culture cells—tissue culture appears to be essential for successful in vitro cultivation. However, although virulence has been maintained in culture, it has not been possible to pass the organisms serially.<sup>9,34</sup>

### Dark-Field Microscopy

*T pallidum* is too narrow to be seen well by ordinary light microscopy, and dark background illumination (ie, dark-field microscopy) is necessary to visualize the organism (see Figure 19-2). Dark-field microscopy is the principal means of diagnosing

primary syphilis, as serologic tests are often negative when patients are first seen.<sup>10</sup> Except from the moist condylomata lata, organisms are difficult to obtain from lesions of secondary syphilis. Nonpathogenic treponemes are found in the mouth and along the gingival margins in normal individuals. Therefore, dark-field microscopy is unreliable for diagnosis of primary or secondary lesions occurring in the oropharynx.

Dark-field microscopy requires a dark-field condenser, trained personnel, and knowledge of the technical difficulties in preparing a specimen and interpreting the findings. Pitfalls often encountered include (a) the age or condition of the lesion, (b) inadequate or improper collection of specimens, (c) recent use of topical or oral antibiotics by the patient, and (d) failure to distinguish artifacts and nonpathogenic treponemes from *T pallidum*.

For those interested in the technique and materials required for dark-field microscopy, the CDC has an excellent publication available free of charge.<sup>35</sup>

### Direct Fluorescence Microscopy

A fluorescein-tagged monoclonal antibody that is specific for *T pallidum* has been developed and can be used to detect the presence of the organism on dried exudate from lesions. A smear of lesional material is applied to a glass microscope slide, air-dried, fixed in acetone, and sent to the laboratory. The slide can be sent by mail to a reference laboratory if the test cannot be done locally. If specimens are to be mailed, the smears should be air-dried only and not fixed.<sup>36</sup> Initial results of the fluorescein-tagged monoclonal antibody indicate that it is both sensitive and specific.<sup>10,37</sup>

Lesional material may also be collected in heparinized, microhematocrit capillary tubes, then sealed and stored at 4°C to 8°C until slides are to be prepared. Capillary tubes may be mailed to a reference laboratory without refrigeration.<sup>36</sup>

### Serologic Tests

Serologic testing, despite its limitations and pitfalls, remains the workhorse for the laboratory diagnosis of syphilis. Unfortunately, these tests are neither inexpensive nor rapid, and delays of days to a week or more may cause treatment to be delayed in a potentially infectious individual. Two types of serologic tests for syphilis are currently in use or are being evaluated for use: the nontreponemal tests, which are discussed below, and treponemal tests. Treponemal tests employ spirochetal antigen and

are reliable indicators of syphilitic infection, present or past. However, they do cross-react with other treponemes and therefore are not entirely specific.<sup>9</sup> It is incumbent on the medical officer to appreciate the sensitivity and specificity of the test that is being ordered, and to consider false-negative and false-positive results, prior infection (serofast), possible reinfection or relapse, and treatment failures in the evaluation of the patient (Exhibit 19-2).

**Nontreponemal Tests.** The word *nontreponemal* means that the test antigen is derived from a source other than a spirochete. This test antigen is cardiolipin-lecithin-cholesterol (reagin), which is a beef-heart extract. Reagin is a phospholipid also found in human tissue and is present in minor amounts in spirochetal membranes.<sup>36</sup> Nontreponemal tests currently available include the

standard VDRL microscopical flocculation test and various modifications including the rapid plasma reagin (RPR) 18-mm-circle card test; automated reagin test (ART); unheated serum reagin (USR); and toluidine red unheated serum test (TRUST), which is an investigational test.

All nontreponemal tests measure antilipid immunoglobulin (Ig) G and IgM antibodies. The test antigen is mixed with the patient's serum on a card, rotated for a specified number of minutes, and then read. The tests are reported as either reactive or nonreactive; the VDRL and USR tests are also reported as weakly reactive (Table 19-2).<sup>36</sup>

In general, quantitative tests indicating tube dilutions (ie, 1:32) are more useful in evaluation of serologic status and response to treatment. Active disease will show a rising titer, adequately treated disease will show a drop in titer, and serofast patients will have no change in titer on serial testing.<sup>28</sup>

The nontreponemal tests usually become positive within 10 to 14 days after the chancre has appeared, but up to 4 weeks may be required in some individuals.<sup>10</sup> In primary syphilis, the titers may be negative, low, or occasionally 1:32 or higher. They are usually high (> 1:32) in secondary syphilis.<sup>28</sup> Sera from about 30% of patients with cardiovascular syphilis or with neurosyphilis are nonreactive with the VDRL test.<sup>38</sup> In a small number of patients with secondary syphilis, a false-negative or weakly reactive test (ie, the prozone phenomenon) may occur in the presence of high antibody titers. Most laboratories perform dilutions on specimens to distinguish false-negative results from this phenomenon.<sup>17</sup>

Biological false-positive reactions occur in 1% to 2% of the population and increase to more than 10% of intravenous drug abusers. Most titers are usually 1:8 or less; however, low titers may also be seen in the later stages of syphilis. All reactive nontreponemal tests must be confirmed with a treponemal test.<sup>36</sup>

**Treponemal Tests.** Patients with reactive nontreponemal tests must have the reactivity confirmed with one of the four currently available treponemal antibody tests: (1) fluorescent treponemal antibody absorption (FTA-ABS); (2) fluorescent treponemal antibody absorption double-staining (FTA-ABS DS), a recent modification using a fluorochrome-labeled counterstain; (3) hemagglutination treponemal test for syphilis (HATTS); and (4) microhemagglutination assay for antibodies to *T pallidum* (MHA-TP).

The FTA-ABS is still the most widely used test and is an indirect immunofluorescent technique

#### EXHIBIT 19-2

#### DIAGNOSTIC TESTS FOR SYPHILIS

Exhibit 19-2 is not shown because the copyright permission granted to the Borden Institute, TMM, does not allow the Borden Institute to grant permission to other users and/or does not include usage in electronic media. The current user must apply to the publisher named in the figure legend for permission to use this illustration in any type of publication media.

**TABLE 19-2**  
**SENSITIVITY OF SEROLOGIC TESTS IN UNTREATED SYPHILIS**

Table 19-2 is not shown because the copyright permission granted to the Borden Institute, TMM, does not allow the Borden Institute to grant permission to other users and/or does not include usage in electronic media. The current user must apply to the publisher named in the figure legend for permission to use this illustration in any type of publication media.

VDRL: Venereal Disease Research Laboratory

FTA-ABS: fluorescent treponemal antibody absorption

MHA-TP: microhemagglutination assay for antibodies to *Treponema pallidum*

Adapted with permission from Jaffe HW, Musher DM. In: Holmes IL, Mårdh P-A, Sparling PF, et al, eds. *Sexually Transmitted Diseases*. New York: McGraw-Hill; 1990: 935.

that utilizes a fluorescein-labeled antihuman antibody to detect host antibodies against *T pallidum*. A *sorbent*, which removes antibodies to nonpathogenic Reiter treponemes (hence the word “absorption”), is first utilized.<sup>36</sup>

The other two tests, the HATTS and MHA-TP, do not require a fluorescent microscope and can be performed more quickly. However, they are less sensitive in primary syphilis and cross-reactions may occur.<sup>36</sup>

The treponemal tests become reactive earlier in primary syphilis than the nontreponemal tests. Still, approximately 20% of patients who present with primary syphilis will be nonreactive on the FTA-ABS test. Therefore, the FTA-ABS test should be performed and may provide important information in suspect cases where the RPR test is negative. The treponemal tests remain positive throughout an individual’s life. However, the CDC reports<sup>25</sup> that 15% to 25% of patients who are treated during the primary stage may revert to being seronegative on the treponemal tests after 2 to 3 years. The false-positive rate in the general population is about 1% (Exhibit 19-3).<sup>11</sup>

The FTA-ABS test has several drawbacks: it requires special equipment and trained personnel, is time-consuming to perform and technicians find the repetitive reading of tests tiresome, and is somewhat expensive. It should be used principally as a confirmatory test.<sup>39</sup>

### Treatment

Penicillin, the treatment of choice for all patients in any stage of syphilis today, is a considerable

improvement over the treatment used during the Civil War by Assistant Surgeon E. A. Tompkins, Fourth Cavalry, Fort Yamhill, on 1 April 1863:

The patient contracted syphilis ... a short time before I arrived at this post. He was relieved by the use of iodide of potassium in syrup of sarsaparilla. Small doses of corrosive sublimate were given and lunar caustic was applied to the chancres. A continuance of this treatment for three weeks enabled him to return to duty, although not entirely well.<sup>40(p893)</sup>

*T pallidum* has remained sensitive to penicillin since the drug was first used for the treatment of syphilis in 1943. However, because of the organism’s long dividing time, prolonged, moderately low levels are required for complete killing of the organisms present.<sup>11</sup> The current treatment guidelines for adults recommended by the CDC are presented below. Controversy exists regarding therapy of patients with HIV infection, and they may require alternative regimens. Consultation with an infectious disease specialist is advised, as numerous investigational protocols are currently underway. The treatment of syphilis in pregnant women and children is not discussed in this chapter.

### Primary, Secondary, and Early Latent Syphilis

The recommended regimen for treatment of primary, secondary, and early latent syphilis<sup>25</sup> is benzathine penicillin G 2.4 million units, administered intramuscularly, in one dose. There are two alternative regimens for nonpregnant, penicillin-allergic patients:

**EXHIBIT 19-3**

**FALSE-POSITIVE REACTIONS TO NONTREPONEMAL AND TREPONEMAL TESTS FOR SYPHILIS**

---

Exhibit 19-3 is not shown because the copyright permission granted to the Borden Institute, TMM, does not allow the Borden Institute to grant permission to other users and/or does not include usage in electronic media. The current user must apply to the publisher named in the figure legend for permission to use this illustration in any type of publication media.

---

Adapted from (1) Hutchinson CM, Hook EW. Syphilis in adults. *Med Clin N Am.* 1990;74(6):1405. (2) Rhodes AR, Luger AFH. Syphilis and other treponematoses. In: Fitzpatrick TB, Eisen AZ, Wolff K, Freedberg IM, Austen KF, eds. *Dermatology in General Medicine*. 3rd ed. New York, NY: McGraw-Hill; 1987: 2424, 2426.

1. doxycycline 100 mg, administered orally twice daily for 2 weeks, or
2. tetracycline 500 mg, administered orally four times daily for 2 weeks.

There is less clinical experience with doxycycline than with tetracycline, but compliance may be better with doxycycline.

Similarly, two options are available for treating patients who are unable to tolerate tetracycline or doxycycline<sup>25</sup>:

1. the patient should have skin-testing for penicillin allergy and be desensitized, if necessary; or
2. erythromycin 500 mg should be administered orally four times daily for 2 weeks.

Erythromycin is less effective than other recommended regimens. Single-dose ceftriaxone is *not effective* for treating syphilis.<sup>25</sup> Optimal dose and duration have not been established for ceftriaxone.

**Persons Exposed to Syphilis.** Persons who have

been exposed to syphilis within the preceding 90 days should have clinical and serologic examinations, and the patient should be treated presumptively even if seronegative. Evidence of other STDs should be sought in every individual.<sup>25</sup>

**Follow-Up.** Following treatment, the CDC recommends that patients be reexamined clinically and serologically at 3 and again at 6 months. Treatment failures can occur with any regimen. The CDC currently recommends that patients who are infected with HIV, and who are also being treated for syphilis, should have more frequent serologic testing at 1, 2, 3, 6, 9, and 12 months.<sup>25</sup>

#### ***Latent Syphilis of Unknown Duration, Late Latent Syphilis, and Tertiary Syphilis***

Patients with late latent or symptomatic tertiary syphilis need more extensive evaluation that is beyond the scope of this discussion. For therapeutic guidelines, see the CDC guidelines for dosage and routes of administration of penicillin or alternative regimens.<sup>25</sup>

## **GONORRHEA**

Gonorrhea, caused by the Gram-negative diplococcus bacterium *Neisseria gonorrhoeae*, is the most commonly reported communicable disease in the United States. In 1993, there were 419,711 projected cases (169/100,000) reported to the CDC,<sup>41</sup> although many more cases go unreported. Important shifts in the epidemiology, populations at risk, and antibiotic susceptibility of the organism have resulted in significant and rapid changes in treatment guidelines and strategies for public health intervention. The military has figured prominently in epidemiological studies of gonorrhea because of the large numbers of young, sexually active individuals who can be followed prospectively for long periods of time.

Gonorrhea is transmitted almost exclusively by sexual contact and is common in both developed and developing countries. Globally, almost 200 million cases are reported annually, evidence of the enormity of the problem and the necessity for improved public health measures for control. Early and accurate diagnosis of gonococcal infection followed by an effective treatment that ensures a high level of patient compliance are crucial to any successful control program.<sup>42</sup>

The spectrum of disease caused by *N gonorrhoeae* includes<sup>42</sup>:

- genital infection including acute anterior urethritis in men, acute endocervicitis in women, and asymptomatic urethral infections;
- rectal infection;
- pharyngeal infection;
- local complications including acute salpingitis (pelvic inflammatory disease) and Bartholin's gland abscess in women; and epididymitis, prostatitis, and other perineal complications in men;
- disseminated gonococcal infection, including the arthritis-dermatitis syndrome and meningitis; and
- infections in infants and children, frequently a sign of sexual abuse (although gonorrhea can be acquired during birth).

### **Clinical Manifestations**

#### ***Acute Anterior Urethritis in Men***

Epidemiological studies have revealed that following a single exposure to an infected woman, about 20% of exposed men will become infected.<sup>43</sup> The incubation period for acute gonococcal urethritis averages 2 to 5 days following exposure, with a range of 1 to 14 days.

Approximately 85% of infected men will develop an acute urethritis syndrome consisting of pain, dysuria, and a urethral discharge (Figure 19-10).<sup>44</sup> The discharge is initially scant and mucoid to mucopurulent, but within 24 hours becomes frankly purulent and profuse.<sup>45</sup> The urethral discharge has been reported to be purulent in 75% of cases, white or cloudy in 20%, and clear to mucoid in the remaining 5%.<sup>46</sup> Recent voiding will temporarily eliminate a discharge in more than one half of patients and will reduce it to cloudy or white in another one third.<sup>46</sup>

Signs and symptoms of untreated gonococcal urethritis in men peak within 2 weeks, with spontaneous resolution occurring in more than 95% of patients within 6 months.<sup>45</sup>

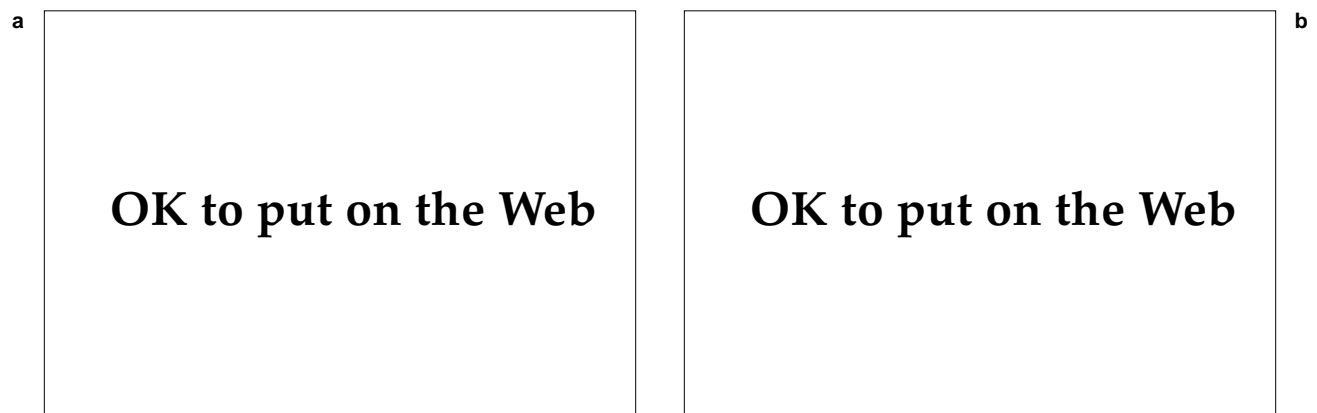
#### ***Asymptomatic Infections in Men***

Of infected men, 15% will have only mild symptomatic urethritis, and a minority (1%–2%) will be asymptomatic.<sup>28,47</sup> The actual figures cited in the literature vary due to the types of populations studied and how carefully the individuals were questioned and examined regarding the presence of symptoms. The existence of the asymptomatic man was considered but was not verified until 1974, when researchers demonstrated that male carriers of the organism could be identified.<sup>48</sup> Two groups of U.S. Army personnel were surveyed to assess the incidence of asymptomatic urethral carriage of gonococci. From a group of 2,628 asymptomatic men who had sexual intercourse either in Vietnam or in the Fort Lewis, Washington, area, the investigators recovered gonococci from the urethras of 59 (2.2%

of the total), of whom 40 (68%) were asymptomatic. Additionally, 28 asymptomatic men were followed without treatment for periods ranging from 7 to 165 days and were found to be culture positive for gonococci until the time of treatment, indicating that asymptomatic infections in men may be chronic.<sup>48</sup>

#### ***Acute Endocervicitis in Women***

The cervix is the most common site of infection in women, although the urethral canal, periurethral glands, or Bartholin's gland may be primarily or secondarily involved. Within about 10 days following a single exposure to an infected partner, about one half of women will become infected with *N gonorrhoeae*, and most become infected after multiple exposures.<sup>49</sup> Symptoms include purulent cervical discharge, dysuria, lower abdominal discomfort, menstrual irregularities, and uterine bleeding that varies from minimal to severe. Although 60% to 70% of women will have these nonspecific symptoms, only 10% to 20% of infected women will have an obvious purulent cervical discharge or a purulent vaginal discharge that clearly originates from the cervix. Women may remain asymptomatic and infectious for many months before a spontaneous cure occurs.<sup>50</sup> Female prostitutes constitute an important reservoir of the disease. The reported prevalence of gonorrhea in this group varies from one study to another—from 5.2% to 11.2%—with the higher rates seen in developing countries.<sup>51</sup> In a 1991 study of 757 female prostitutes in Madrid, Spain, 89 were infected with *N gonorrhoeae*. Of these, 48 (54%) were asymptomatic.<sup>51</sup>



**Fig. 19-10.** (a) This thick, purulent, urethral discharge is typical of primary gonorrhea. (b) In nongonococcal urethritis, in contrast, the discharge is clear and mucoid. Photograph: Courtesy of C. Kalter, MD, Bethesda, Md.

### Rectal Infection

The rectal mucosa may be the primary site of infection in 40% of homosexual men and in 5% of women. Of women with gonococcal infections of the cervix, one third to one half will also have infection of the rectum, which is mainly due to contamination of the anus by infected cervical secretions but may also result from anal intercourse.<sup>42</sup> In most women, rectal infection is asymptomatic. However, as a result of receptive anal intercourse, a syndrome of acute proctitis occurs in homosexual men with pain, tenesmus, purulent rectal discharge, and constipation. Physical examination reveals perianal erythema and discharge. Anoscopy shows inflammatory mucosal changes consisting of a purulent exudate, erythema, friability, and bleeding.<sup>45</sup>

### Pharyngeal Infection

Infection of the pharynx most commonly occurs as a result of orogenital intercourse, although occasional cases develop as a result of autoinoculation from infections at other sites. More than 90% of pharyngeal infections are asymptomatic. In the remaining 10%, however, an acute pharyngitis or tonsillitis develops associated with cervical lymphadenopathy and fever. The significance of pharyngeal infection is uncertain and epidemiological studies have shown that without treatment, spontaneous cure occurs in 100% of affected individuals within 3 months.<sup>45</sup> The prevalence of pharyngeal infection is highest among homosexual men.<sup>42</sup> Transmission of pharyngeal infection to sexual partners appears to be rare.

### Complicated Infections

Local complications of gonococcal disease include acute salpingitis (ie, pelvic inflammatory disease) and Bartholin's gland abscess in women and epididymitis, penile lymphangitis, prostatitis, seminal vesiculitis and urethral strictures in men.<sup>42</sup>

Of women with gonococcal infection of the cervix, approximately 15% will develop acute pelvic inflammatory disease with pelvic and abdominal pain, cervical discharge, dyspareunia, abnormal bleeding, and constitutional signs and symptoms including fever, leukocytosis, and elevated sedimentation rate.<sup>49</sup> In the United States, about one half the cases of pelvic inflammatory disease are caused by *N gonorrhoeae*, with chlamydia and other non-STD organisms responsible for the remaining cases. Long-term complications of pelvic inflam-

matory disease include sterility and the risk of ectopic tubal pregnancy.

Bartholin's gland abscess is also common, and patients present with enlargement of the gland and tenderness. Gonococci may be isolated from the Bartholin's glands in a significant number of women who have no symptoms of bartholinitis.<sup>45</sup>

In men, infection of the urethra may uncommonly progress to involve the epididymis, prostate, testicle, preputial glands (Tyson's glands), bulbourethral glands (Cowper's glands), the median raphe of the penis, and the glans penis.<sup>10</sup> Epididymitis is uncommon, probably because (a) gonococci have difficulty traversing a long urethra and vas deferens and (b) men often seek early treatment for symptomatic urethritis.<sup>50</sup> Infection is usually unilateral, with patients complaining of a painful and swollen testicle. Physical examination reveals scrotal erythema and an enlarged and tender epididymis; the testicle is usually normal. A secondary hydrocele is frequently found.

Gonococcal prostatitis and seminal vesiculitis are rare complications. Signs and symptoms include urinary urgency, vague pelvic discomfort, hematuria, fever, and painful erections. Infection of the median raphe of the penis is also rare; patients present with a small papule from which pus may be expressed (Figure 19-11).<sup>10</sup> As a result of early and effective treatment, urethral strictures are now an uncommon complication in the United States. However, in parts of the world with inadequate medical facilities, urethral strictures and fistula formation are frequent.<sup>42</sup>

### Disseminated Gonococcal Infection

Disseminated gonococcal infection occurs with 6-fold greater frequency in women than men. There is a definite relationship to menstruation: the disease occurs within 1 week of the onset of menses in more than half the cases. Disseminated gonococcal infection is also more common in women during the third trimester of pregnancy and in homosexual men. This complication occurs in 1 in 300 to 1 in 600 patients with genital gonorrhea.<sup>47</sup>

Patients present with the dermatitis-arthritis syndrome, which consists of fever, chills, acute arthritis, tenosynovitis, and tender, erythematous pustules located on the distal extremities. Any joint may be involved but most frequently the wrist, metacarpophalangeal, ankle, or knee joints are affected. Frank pyogenic arthritis may cause joint destruction if not recognized and promptly treated.<sup>45</sup> The characteristic skin lesions usually number fewer

## OK to put on the Web

**Fig. 19-11.** Uncommonly, patients with gonococcal infection may present with a painful abscess of the median raphe of the penis. Gram's stain of the expressed pus would show typical intracellular gonococci. Photograph: Courtesy of the Walter Reed Army Medical Center Dermatology Service slide file, Washington, DC.

than 12 and are concentrated on the extremities, around the joints. They are typically tender vesiculopustules on an erythematous base, which may become hemorrhagic (Figure 19-12).<sup>44</sup>

### *Infections in Infants and Children*

Gonococcal infections in infants and children are the result of sexual abuse, with the exception of gonococcal conjunctivitis (ophthalmia neonatorum), which is acquired from an infected birth canal. This subject is not discussed in this chapter; readers are referred to excellent reviews<sup>52,53</sup> in the literature.

### **Laboratory Diagnosis**

The present approach to the evaluation of a patient with suspected gonococcal infection consists of (a) obtaining Gram-stained smears of exudate, (b) culture on gonococcal media, and (c) determination of antibiotic susceptibility (Table 19-3). Newer methods, such as monoclonal or polyclonal anti-

body tests to detect gonococcal antigens in cultures or exudate, gonococcal complement fixation tests, and gonococcal deoxyribonucleic acid (DNA) hybridization probes, are available to diagnose the infection rapidly. Whenever possible, culture and sensitivity testing should be obtained.

### *Gram's Stain*

Staining the genital secretions with Gram's stain is the most widely accepted procedure for the immediate diagnosis of gonococcal infection. In men with urethral symptoms, the test is both highly specific and highly sensitive; approximately 90% to 98% of culture-positive men with a purulent discharge have a positive smear. On urethral smears from men, the Gram's stain is considered positive when Gram-negative diplococci of typical morphology are found within or closely associated with neutrophils. It is equivocal if only extracellular organisms or atypical, intracellular, Gram-negative diplococci are seen. Nonpathogenic *Neisseria* organisms are usually not cell-associated (Figure 19-13).<sup>9</sup>

In women, Gram-stained smears from the endocervix are relatively insensitive (30% to 60%)<sup>50</sup> and interpretation is difficult and time-consuming. However, the test may permit rapid diagnosis and treatment in the presence of pelvic inflammatory disease, acute endocervicitis with a purulent discharge, or a history of exposure to gonorrhea.<sup>50</sup> It is important to avoid mistaking morphologically similar saprophytes of the normal flora for *N gonorrhoeae*,

## OK to put on the Web

**Fig. 19-12.** This hemorrhagic pustule, when seen in a sexually active individual in association with acute arthritis and tenosynovitis, should elicit a high degree of suspicion of disseminated gonorrhea. The patients, usually women, may have mild preceding symptoms and are usually unaware that they have gonorrhea prior to the onset of their illness.



TABLE 19-3

SENSITIVITY OF GRAM'S STAIN AND CULTURE IN DIAGNOSING GONORRHEA

---

Table 19-3 is not shown because the copyright permission granted to the Borden Institute, TMM, does not allow the Borden Institute to grant permission to other users and/or does not include usage in electronic media. The current user must apply to the publisher named in the figure legend for permission to use this illustration in any type of publication media.

---

\*These specimens are often contaminated with local flora  
Reprinted with permission from Judson FN. Gonorrhea. *Med Clin N Am.* 1990;74(6):1358.

and only those smears that contain several polymorphonucleocytes with multiple, intracellular, Gram-negative diplococci with typical morphology should be considered positive.<sup>9</sup>

Gram-stained smears of pharyngeal and rectal exudate are not helpful and the diagnosis rests principally with a culture.

**Culture**

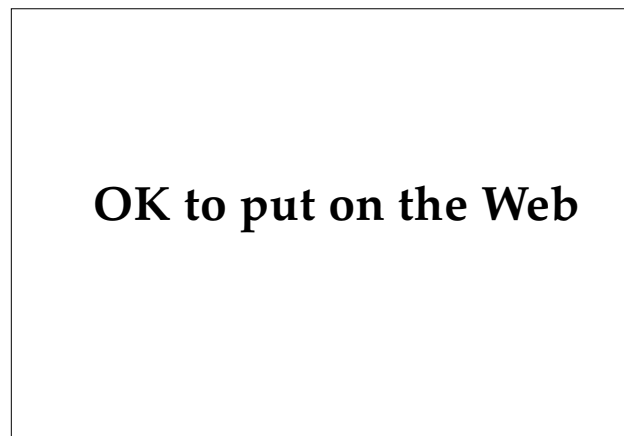In men, culture of exudates adds little (2%) to the yield and considerable cost but is often employed when the Gram-stained specimen is negative for *N gonorrhoeae*. However, the CDC currently recommends that all cases of gonorrhea be diagnosed or confirmed or both by culture.<sup>25</sup> The susceptibility of *N gonorrhoeae* to antibiotics changes over time in a locality, and routine culture facilitates antimicrobial susceptibility testing.

In women, cultures obtained from multiple sites provide better yields and a greater chance for isolating the organism than does a single endocervical culture. Ideally, specimens for culture should be obtained from the endocervix, urethra, rectum, and pharynx.<sup>42</sup>

Blood cultures are often positive both early in the course of disseminated disease and when taken from synovial fluid of patients with acute purulent

gonococcal arthritis. In disseminated gonococcal infection, culture of skin lesions is usually negative, although Gram's staining and fluorescent-antibody testing of smears from pustules often demonstrates organisms. Culture requires viable organisms, whereas stains and fluorescent antibody testing do not.<sup>44,54</sup>

Immediately after the specimen is collected, it should be plated on an enriched, selective medium



**Fig. 19-13.** Gram-negative intracellular diplococci are the hallmark of gonococcal infection. Photograph: Courtesy of M. Mulvaney, MD, Albany, NY.

and incubated in an atmosphere containing 5% carbon dioxide (eg, a candle-extinction jar) at 37°C.<sup>55</sup>

### Treatment

Treatment guidelines for the management of gonococcal infections have changed dramatically during the last decade. Several factors, including resistance to penicillin, coinfection with gonococci and chlamydia, and the anatomical site of infection, are responsible for the shift in therapeutic approaches.

Resistance to penicillin was first noted in the 1950s, with increasing doses required to cure infection.<sup>56</sup> Penicillinase-producing *N gonorrhoeae* (PPNG) were first reported from Southeast Asia and West Africa during the mid-1970s. Infected military personnel returning from Southeast Asia introduced PPNG to the United States.<sup>49</sup> Resistance is conferred by plasmid-mediated transfer of the genes responsible for production of  $\beta$ -lactamase.<sup>57</sup> During the next several years, only isolated outbreaks associated with prostitution in urban areas were reported.<sup>58</sup> Since 1980, however, the incidence of PPNG has risen significantly, and infection with PPNG is now firmly established in the United States.<sup>58</sup> Additionally, plasmid-mediated, high-level resistance to tetracycline was first reported in the mid-1980s, resulting in outbreaks of tetracycline-resistant strains of *N gonorrhoeae* (TRNG).<sup>59</sup>

There is a high incidence of coinfection with gonococci and chlamydia. Experimental data have demonstrated that simultaneous infection with *N gonorrhoeae* and chlamydia results in a 100-fold increase in the replication of chlamydia in cervical epithelium, and current recommendations encourage the use of single or multiple agents that are effective against both organisms.<sup>60</sup>

The anatomical site of infection has a significant bearing on the choice and efficacy of antibiotics. When caused by susceptible strains of *N gonorrhoeae*, uncomplicated gonococcal infections of the urethra and cervix will respond to single-dose therapy. On the other hand, not all cases of gonococcal pharyngitis or proctitis in a homosexual man will respond to single-agent therapy regimens. Patients whose symptoms persist after treatment should be recultured for *N gonorrhoeae*, and the gonococci should be tested for antibiotic susceptibility. Invasive gonococcal disease (eg, pelvic inflammatory disease, disseminated gonococcal infection) usually requires multiple-dose parenteral therapy.<sup>61</sup>

Other factors to consider in the selection of appropriate antibiotic regimens for gonococcal dis-

ease include safety of the drug, incidence of adverse reactions, patient compliance, ease of administration, and cost (Exhibit 19-4).

### Uncomplicated Gonococcal Infections

In 1993, the CDC recommended the following regimen for treating uncomplicated gonococcal infections<sup>25</sup>:

- ceftriaxone 125 mg, administered intramuscularly in a single dose, or
- cefixime 400 mg, administered orally in a single dose, or
- ciprofloxacin 500 mg, administered orally in a single dose, or
- ofloxacin 400 mg, administered orally in a single dose;

#### EXHIBIT 19-4

#### ANTIBIOTIC SELECTION CRITERIA FOR GONORRHEA

---

Exhibit 19-4 is not shown because the copyright permission granted to the Borden Institute, TMM, does not allow the Borden Institute to grant permission to other users and/or does not include usage in electronic media. The current user must apply to the publisher named in the figure legend for permission to use this illustration in any type of publication media.

---

Adapted with permission from Moran JS, Zeligman JM. Therapy for gonococcal infections: Options in 1989. *Rev Infect Dis.* 1990;12(Suppl 6):S633.

- plus a regimen that is effective against possible coinfection with *Chlamydia trachomatis*, such as doxycycline 100 mg, administered orally twice daily for 7 days.

In clinical trials, these recommended regimens cured more than 95% of anal and genital infections; any of the regimens may be used for uncomplicated anal and genital infection. Published studies indicate that ceftriaxone 125 mg and ciprofloxacin 500 mg can cure more than 90% of pharyngeal infections. If pharyngeal infection is a concern, one of these two regimens should be used.<sup>25</sup>

No ceftriaxone-resistant strains of *Neisseria gonorrhoeae* have been reported. The drawbacks of ceftriaxone are (1) it is expensive, (2) it is currently unavailable in vials smaller than 250 mg, and (3) it must be administered by injection. Some healthcare providers believe that the discomfort of the injection may be reduced by using 1% lidocaine as a diluent. Ceftriaxone also may abort incubating syphilis, a concern when gonorrhea treatment is not accompanied by a 7-day course of doxycycline or erythromycin for the presumptive treatment of chlamydia.<sup>25</sup>

Cefixime has an antimicrobial spectrum similar to that of ceftriaxone. Cefixime appears to be effective against pharyngeal gonococcal infection, but few patients with pharyngeal infection have been included in studies. No gonococcal strains resistant to cefixime have been reported. The advantage of cefixime is that it can be administered orally. Whether the 400-mg dose can cure incubating syphilis is not yet known.<sup>25</sup>

Ciprofloxacin, at a dose of 500 mg, provides sustained bactericidal levels in the blood. Ciprofloxacin can be administered orally and is less expensive than ceftriaxone. No resistance has been reported in the United States, but strains with decreased susceptibility to some quinolones are becoming common in Asia. Quinolones are contraindicated for pregnant or nursing women and for persons younger than 17 years of age, on the basis of information from studies with animals. Quinolones are not active against *Treponema pallidum*.<sup>25</sup>

Many other antimicrobials are active against *Neisseria gonorrhoeae*. These guidelines are not intended to be a comprehensive list of all effective treatment regimens.

**Follow-Up.** Patients with uncomplicated gonorrhea who are treated with any of the regimens in these guidelines need not return for a test of cure.

Patients whose symptoms persist after treatment should be evaluated by culture for *N gonorrhoeae*, and any gonococci isolated should be tested for antimicrobial susceptibility. Persistent urethritis, cervicitis, or proctitis also can be caused by *Chlamydia trachomatis* and other organisms.

**Management of Sexual Partners.** Patients should be instructed to refer their sexual partners for evaluation and treatment. Sexual partners of *symptomatic* patients who have gonorrhea should be evaluated and treated for both *Neisseria gonorrhoeae* and *Chlamydia trachomatis* infections if their last sexual contact with the patient was within 30 days of onset of the patient's symptoms. If the index patient is asymptomatic, sexual partners whose last sexual contact with the patient was within 60 days of diagnosis should be evaluated and treated.

### Disseminated Gonococcal Infection

The 1993 CDC recommendations also specify the following treatment for patients with disseminated gonococcal infection<sup>25</sup>:

- Recommended initial regimen:
  - ceftriaxone 1 g, administered intramuscularly or intravenously every 24 hours.
- Alternative initial regimens:
  - cefotaxime 1 g, administered intravenously every 8 hours, or
  - ceftizoxime 1 g, administered intravenously every 8 hours, or,
  - for persons allergic to  $\beta$ -lactam drugs, spectinomycin 2 g, administered intramuscularly every 12 hours.

All regimens should be continued for 24 to 48 hours after improvement begins; then therapy can be switched to one of the following regimens to complete one full week of antimicrobial therapy<sup>25</sup>:

- cefixime 400 mg, administered orally twice daily, or
- ciprofloxacin 500 mg, administered orally twice daily.

Ciprofloxacin is contraindicated for children, adolescents younger than 17 years of age, and pregnant and lactating women.

Hospitalization is recommended for initial therapy, especially for patients who cannot be relied on to comply with treatment, for those whose

diagnosis is uncertain, and for those who have purulent synovial effusions or other complications. Patients should be examined for clinical evidence of endocarditis and meningitis. Patients treated for disseminated gonococcal infection should be treated presumptively for concurrent *Chlamydia trachomatis* infection.<sup>25</sup>

### Pregnant Women

Pregnant women should not be treated with quinolones or tetracyclines. They should be treated with a recommended or alternative cephalosporin, following the regimen for disseminated gonococcal infection, above.<sup>25</sup>

## CHANCROID

Chancroid is an STD caused by the Gram-negative coccobacillus *Haemophilus ducreyi*. Worldwide, chancroid is a more important cause of genital ulcers than syphilis, and there is a clear association between chancroid, poverty, and poor hygiene. This association is reflected in the incidence of the disease, which is highest in underdeveloped tropical and subtropical countries.

Chancroid was well known during the Civil War, as Surgeon J. G. Bradt of the 26th Massachusetts Volunteers, New Orleans, Louisiana, reported on 1 January 1863:

Of the various forms of venereal disease, chancre of the non-indurated variety is the most common. It is accompanied in a majority of cases with bubo. The sores yield readily to cauterization with acid nitrate of mercury and applications of black wash, the bowels meanwhile being regulated and the patient kept on a low diet.<sup>40(p892)</sup>

There is ample epidemiological evidence that the incidence of chancroid increases dramatically during wartime.<sup>10</sup> Among U.S. troops in the Korean conflict, chancroid was 14- to 21-fold more common than gonorrhea.<sup>62</sup> A study conducted in 1969 found that among troops in Vietnam, chancroid was second only to gonorrhea in the total reported cases of venereal disease (Figure 19-14).<sup>63</sup>

Chancroid is more common in uncircumcised men, and the disease is more often reported in men, as well. However, women may have inapparent or mildly symptomatic infections for which they do not seek medical care. In addition, female prostitutes constitute an important reservoir of infection.<sup>64</sup> Of prostitutes who were implicated as sources of chancroid infection, only 10% had genital ulcers, and 4% were either transient or persistent asymptomatic genital carriers.<sup>10</sup>

Recent epidemiological studies have noted an association between the presence of genital ulcer disease and a significant risk of acquiring HIV infection. In both men and women who are exposed

to partners who are infected with HIV-1, those who develop genital ulcer disease are at increased risk of HIV-1 seroconversion.<sup>18</sup> In developing countries, from 10% to 30% of patients presenting with STDs may have genital ulcer disease, of which chancroid is the most commonly reported.<sup>65</sup> In a study of female prostitutes in Nairobi with genital ulcer disease, HIV-1 could be isolated from the ulcer exudate in 11% of these patients.<sup>66</sup> In another study of 19 men presenting with confirmed chancroid, HIV-1 could be isolated by viral culture from the ulcers of two of seven HIV-1-positive patients.<sup>67</sup> Polymerase chain reaction confirmed the presence of the virus in genital exudate in six of the same seven men. The fact that it was possible to culture virus from these chancroidal ulcers suggests that a concentration of virus sufficient to result in transmission from such lesions is possible.<sup>67</sup> Not surprisingly, uncircumcised men are at greater risk of acquiring both chancroid and HIV-1 infection.<sup>68</sup>

## OK to put on the Web

**Fig. 19-14.** A painful, ragged, necrotic, undermined ulcer of chancroid in the coronal sulcus of the penis. The yellowish pseudomembrane is characteristic of chancroid, but can be confused with herpes simplex or other secondarily infected penile ulcerations.

## Clinical Manifestations

Following an incubation period that varies from 2 to 35 days (average 7 d), a small papule develops at the site of initial infection.<sup>69</sup> This rapidly becomes pustular and then ulcerates as a result of thrombotic occlusion of the underlying dermal vessels. The ulcer enlarges, rapidly forming a crater with ragged, undermined borders surrounded by a thin rim of erythema. The ulcer floor is covered by a grayish membrane; removal of this membrane reveals a glistening base of granulation tissue. Unlike the chancre of primary syphilis, the chancroidal ulcer is painful and the border is not indurated. Auto-inoculation of surrounding areas results in multiple ulcers in various stages of evolution, which is a more common finding than a solitary lesion (Figure 19-15). Ulcers may range from a few millimeters to more than 2 cm in diameter. There are no constitutional symptoms.<sup>10</sup>

In men, the foreskin is the region most commonly affected, with lesions found less frequently on the glans or penile shaft. In women, the labia majora, introitus, vagina, and perianal areas are involved. Homosexual men may present with chancroidal lesions in the perianal area, as well. Extragenital lesions are rare, and disseminated infection with *H ducreyi* has not been reported.<sup>10</sup>

In about 50% of cases, unilateral, occasionally bilateral, tender, inguinal lymphadenitis (ie, a bubo) develops and is characteristic of chancroid. The overlying skin may vary from erythematous to a dusky violaceous color. If untreated, buboes

progress to form soft, fluctuant abscesses that often rupture spontaneously, leaving large, nonhealing, serpiginous ulcers.<sup>70</sup> Aspiration of fluctuant buboes before they rupture will promptly relieve discomfort and prevent this complication (Figure 19-16). There is no permanent immunity following chancroid infection.

There are several clinical variants of the chancroidal ulcer:

- Patients with transient chancroid present with a small, evanescent ulcer that remains for less than 1 week. Rapid healing is followed by painful inguinal lymphadenitis that must be differentiated from lymphogranuloma venereum.
- Patients with follicular chancroid present with small, follicular ulcerations in the perineum, which resemble bacterial folliculitis.<sup>71</sup>
- Patients with phagedenic chancroid present with large, rapidly spreading, necrotic ulcerations, which may result in extensive destruction or formation of a urethral fistula. Superinfection with anaerobic bacteria such as *Treponema vincentii*, *Fusobacterium nucleatum*, and *Leptotrichia buccalis* are responsible for the massive ulceration.<sup>10</sup>
- Other uncommonly reported clinical variants include dwarf chancroid, papular chancroid, and giant chancroid.<sup>71</sup>

## Laboratory Diagnosis

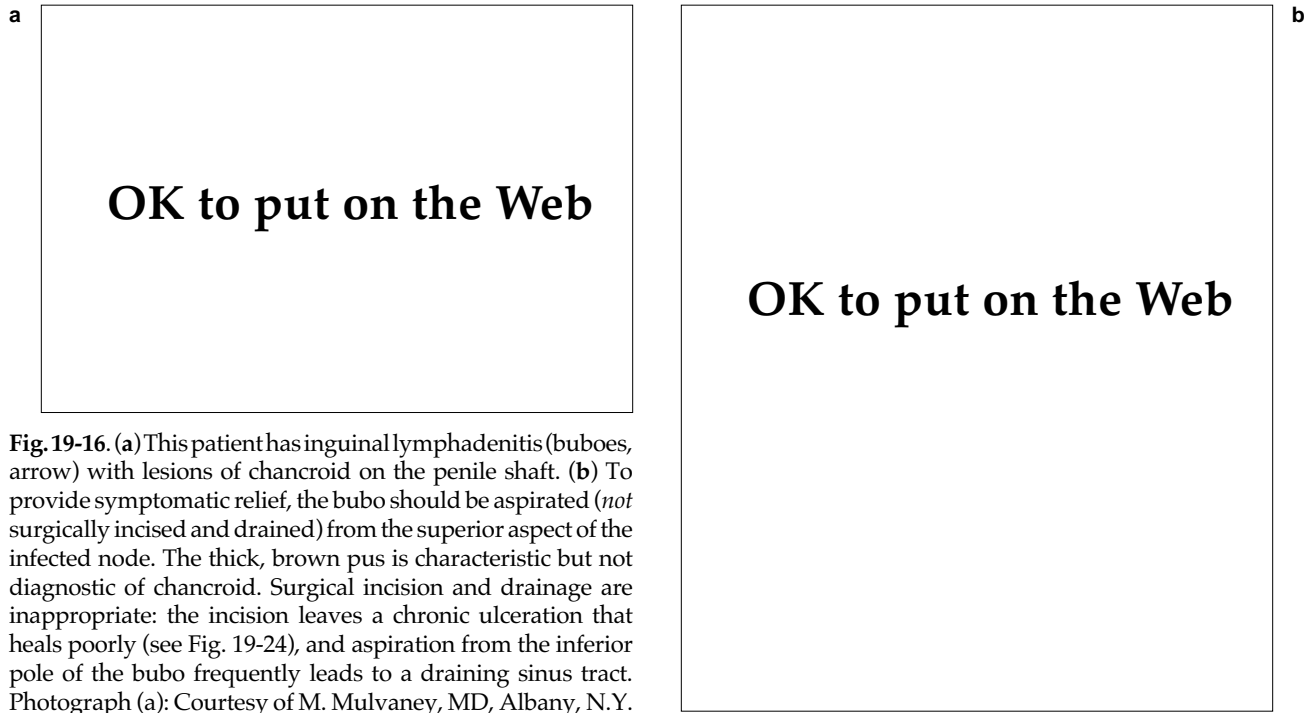
### Gram's Stain

A Gram-stained smear of a specimen taken from a penile ulcer or bubo aspirate may allow a preliminary diagnosis of chancroid in approximately half the patients. To properly obtain a specimen, the ulcer should first be cleaned with physiological saline and then dried. The specimen is obtained with a cotton-tipped applicator from the undermined edge of the ulcer, and then carefully rolled across a glass microscope slide in one direction only (this is important, as it will preserve the morphologic appearance of the organism). The Gram-negative coccobacilli are found in small clusters or parallel chains of organisms described as "school-of-fish" or "railroad-track" patterns (Figure 19-17). Routine light microscopy lacks both sensitivity and specificity because Gram-negative coccobacilli that are morphologically similar to *Haemophilus ducreyi* are present. As a result, Gram-stained smears from



OK to put on the Web

**Fig. 19-15.** Multiple, small, vulvar erosions of chancroid can easily be confused with lesions of genital herpes infection. Smears and culture are required to distinguish the two. Compare with the lesions shown in in Fig. 19-26.



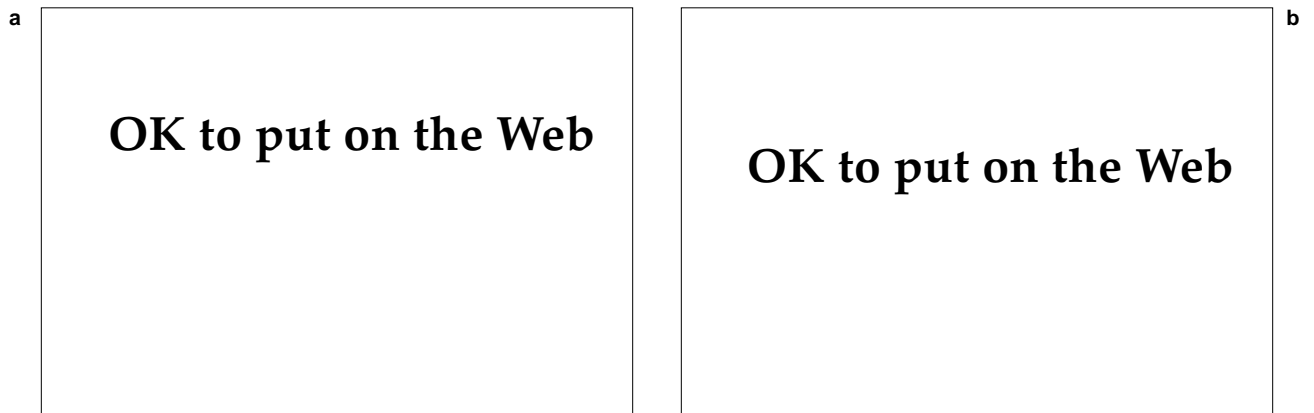
**Fig. 19-16.** (a) This patient has inguinal lymphadenitis (buboes, arrow) with lesions of chancroid on the penile shaft. (b) To provide symptomatic relief, the bubo should be aspirated (*not* surgically incised and drained) from the superior aspect of the infected node. The thick, brown pus is characteristic but not diagnostic of chancroid. Surgical incision and drainage are inappropriate: the incision leaves a chronic ulceration that heals poorly (see Fig. 19-24), and aspiration from the inferior pole of the bubo frequently leads to a draining sinus tract. Photograph (a): Courtesy of M. Mulvaney, MD, Albany, N.Y.

genital ulcers or bubo aspirates are often inconclusive. When available, culture confirmation is preferable to Gram-stained smears.<sup>72</sup>

#### **Culture and Serology**

Epidemiological studies and laboratory isolation of *H ducreyi* from suspected cases of chancroid have been hampered by (a) the lack of reliable, inexpen-

sive culture media and (b) the absence of a typing system to assist in contact tracing. Additionally, *H ducreyi* is nearly biochemically inert (ie, nonreactive) on a variety of standard in vitro bacteriological tests, a characteristic that has hindered the development of serologic tests. Recent improvements in culture media have replaced the liquid- or clotted-blood-based media of the past. Currently, gonococcal agar base and Mueller-Hinton agar base are



**Fig. 19-17.** (a) This biopsy specimen from a vulvar lesion shows Gram-negative rods, some in chains (Brown and Hopf stain, original magnification 290X). (b) The same biopsy specimen is stained with Warthin-Starry silver stain to demonstrate numerous organisms (Warthin-Starry stain, original magnification 290X). Photographs: Courtesy of R. C. Neafie, Armed Forces Institute of Pathology, Washington, DC.

two selective media that are used to culture *H ducreyi*. Unfortunately, these media, which consist of gonococcal chocolate agar, supplemented with blood or serum and vitamins, amino acids, and antibiotics (vancomycin), are expensive and difficult to produce commercially. Consequently, their availability in developing countries, where most chancroid is reported, is limited.<sup>73</sup>

Material from the base of the ulcer should promptly be inoculated on suitable media and incubated at a reduced temperature (33°C–35°C) in a moist, carbon dioxide-rich (5%–10%) chamber. Small, yellow-gray, semiopaque or translucent colonies develop in 2 to 4 days, but may require up to 7 days after inoculation for growth. The colonies have a characteristic adherence and can be moved as an entire colony across the culture plate with an inoculating loop.<sup>10</sup> Confirmatory identification utilizes the porphyrin test, which demonstrates a requirement for hemin (the X factor) for growth, and the oxidase test demonstrates the absence of a requirement for nicotinamide adenine dinucleotide (NAD, the V factor).<sup>70</sup>

Serologic tests and specific monoclonal antibodies based on mouse and rabbit systems are still experimental and are currently unavailable. Several promising antisera without cross-reactivity with other *Haemophilus* species may be available in the future. Monoclonal antibodies specific for *H ducreyi* have been produced<sup>74</sup> and used to detect the antigen in lesional material from experimental animals and from material in patients with chancroid. Serologic tests such as complement fixation, precipitin, and agglutination tests may be positive in some patients with *H ducreyi* infections. A recently described enzyme-linked immunosorbent assay (ELISA) using whole, lysed *H ducreyi* as the source of antigen is promising.<sup>70,75</sup> The nature and duration of the antibody response to *H ducreyi* is unknown.

## Treatment

As with other STDs caused by bacteria, strains are emerging worldwide that are resistant to multiple antibiotics. The 1993 CDC recommendations for treatment of chancroid in the United States are listed below. Susceptibility of *H ducreyi* to the recommended and alternative antimicrobials varies throughout the world. Clinical efficacy, relapses, and treatment failures should be carefully monitored—with laboratory determination of antibiotic susceptibility patterns, if available.

## Recommended Regimens

The following are the CDC's 1993 recommended regimens for the treatment of chancroid<sup>25</sup>:

- azithromycin 1 g, administered orally in a single dose, or
- ceftriaxone 250 mg, administered intramuscularly in a single dose, or
- erythromycin base 500 mg, administered orally four times daily for 7 days.

All three recommended regimens are effective for the treatment of chancroid in patients without HIV infection. Azithromycin and ceftriaxone offer the advantage of single-dose therapy. Antimicrobial resistance to ceftriaxone and azithromycin has not been reported. Although two isolates resistant to erythromycin were reported from Asia during the 1980s, similar isolates have not been reported.

## Alternative Regimens

The following are the CDC's alternative regimens for the treatment of chancroid<sup>25</sup>:

- amoxicillin 500 mg and clavulanic acid 125 mg, administered orally three times daily for 7 days, or
- ciprofloxacin 500 mg, administered twice daily for 3 days.

Ciprofloxacin is contraindicated for pregnant and lactating women, children, and adolescents younger than 17 years of age.

These alternative regimens have not been evaluated as extensively as the recommended regimens. Neither regimen has been studied in the United States.

## Follow-Up

Patients should be reexamined 3 to 7 days after initiation of therapy. If treatment is successful, ulcers improve symptomatically within 3 days and improve objectively within 7 days after therapy is initiated. If no clinical improvement is evident, the medical officer must consider whether (a) the diagnosis is correct, (b) coinfection with another STD agent exists, (c) the patient is also infected with HIV, (d) the treatment was not taken as instructed, or (e) the strain of *H ducreyi* causing the infection is resistant to the prescribed antimi-

crobial drug. The time required for complete healing is related to the size of the ulcer; large ulcers may require more than 2 weeks. Clinical resolution of fluctuant lymphadenopathy is slower than that of ulcers and may require needle aspiration through adjacent intact skin—even during successful therapy.

### Management of Sexual Partners

Persons who have had sexual contact with a patient who has chancroid within the 10 days before the onset of the patient's symptoms should be examined and treated. The examination and treatment should be done even in the absence of symptoms.

## GRANULOMA INGUINALE

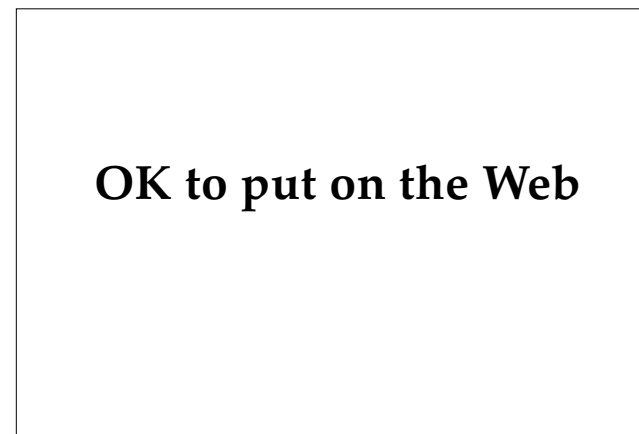
Granuloma inguinale (also called Donovanosis) is a sexually transmitted disease caused by the Gram-negative encapsulated bacillus *Calymmatobacterium granulomatis*. In 1905, C. Donovan described intracellular organisms with peculiar clumping of chromatin at either end that produce a "closed-safety pin" morphology on Giemsa stain.<sup>76</sup> The disease is rare in the United States, although sporadic cases are reported from southern states. In certain parts of the world, especially New Guinea, central Australia, India, the Caribbean countries, and Africa, the disease is endemic and may be among the most prevalent STDs. The disease is reported more often among groups with lower socioeconomic status, and poor hygiene may play a role in transmission and susceptibility to infection.<sup>77</sup>

Significant controversy exists regarding the mode of transmission of the organism. The primary mode appears to be through sexual contact. The disease is considered to be only mildly contagious and repeated exposure is necessary for clinical infection to occur. However, the disease is only rarely reported in prostitutes and is uncommon in sexual partners of clinically infected individuals.<sup>78</sup> The frequent occurrence of perianal and penile lesions in homosexual men who practice anal intercourse has focused attention on colonization of the intestinal tract by organisms resembling *C granulomatis*. Auto-inoculation of fecal material onto traumatized or diseased skin may result in clinical infection. It is possible that transmission occurs by both sexual and non-sexual modes: perineal contamination with fecal organisms may precede transfer by sexual intercourse.<sup>10,79</sup> The disease has been reproduced only by introducing infected material from the granuloma inguinale lesion into an uninfected human. Transfers of organisms grown on tissue or bacterial cultures have not produced clinical disease.<sup>80</sup>

### Clinical Manifestations

The incubation period following exposure is un-

known although it has been estimated to range from weeks to months. The primary lesion is an intensely pruritic papule that occurs in the anogenital area in more than 90% of cases. Less commonly, the initial lesion may be a firm, subcutaneous nodule that later suppurates, rupturing through the skin to produce an ulcer. In women, the primary lesion is frequently overlooked by the patient.<sup>10</sup> The ulcers are clean, sharply defined, granulomatous, usually painless lesions (Figure 19-18). Secondary infection may, however, result in painful lesions or large, mutilating, necrotic ulcerations.<sup>80</sup> Autoinoculation may cause multiple primary lesions. These often coalesce into a large, irregular ulcer that enlarges slowly and bleeds easily on contact; the base is covered by abundant, beefy-red, granulation tissue.<sup>81</sup> Over time, the edge of the ulcer becomes elevated, thickened, and grayish in color. There are no constitutional symptoms in the absence of secondary infection.



**Fig. 19-18.** This ulcer of granuloma inguinale is covered by exuberant, beefy-red, granulation tissue. The disease is asymptomatic and rare, and patients may have multiple lesions as a result of autoinoculation. The diagnosis is difficult to make clinically; a biopsy is usually necessary.



Bacterial spread through subcutaneous tissues in the inguinal region may lead to large subcutaneous granulomas known as pseudobuboes, which can mimic lymphogranuloma venereum or metastatic squamous cell carcinoma. These granulomas can rupture, leading to typical granulomatous ulcers of the overlying skin. True inguinal lymphadenopathy in granuloma inguinale is rare, except when extensive secondary infection<sup>77</sup> or coexistent involvement of the lymph nodes with syphilis, lympho-granuloma venereum, or malignancy are present.<sup>10</sup>

In addition to the classic large, exuberant, beefy-red ulcer with rolled borders (ie, the ulcerovegetative type), other clinical variants occur, albeit less frequently (Figure 19-19):

- In 1975, a case of extensive necrosis of the penis and perineum with production of a large, mutilating lesion and destruction of most of the penile tissue was reported.<sup>80</sup> This patient had no systemic involvement.
- Patients with a rare hypertrophic form

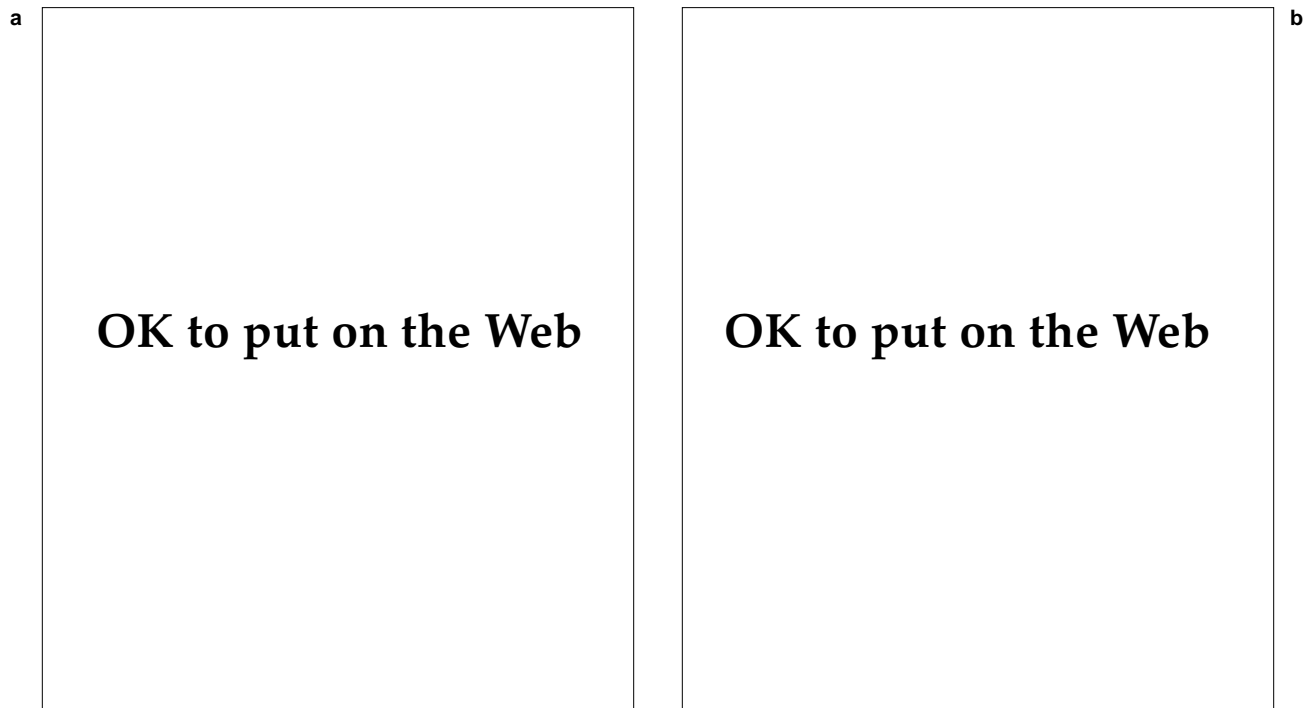
present with two types of ulcers: (1) the large, vegetative masses and (2) the *cicatrical* type, which produces extensive, spreading scar formation as the primary disease process, rather than healing.<sup>82</sup>

Lesions often continue to expand for years and spontaneous healing is slow to occur. Healing generally occurs with extensive fibrosis and significant deformity, and functional disability can occur.

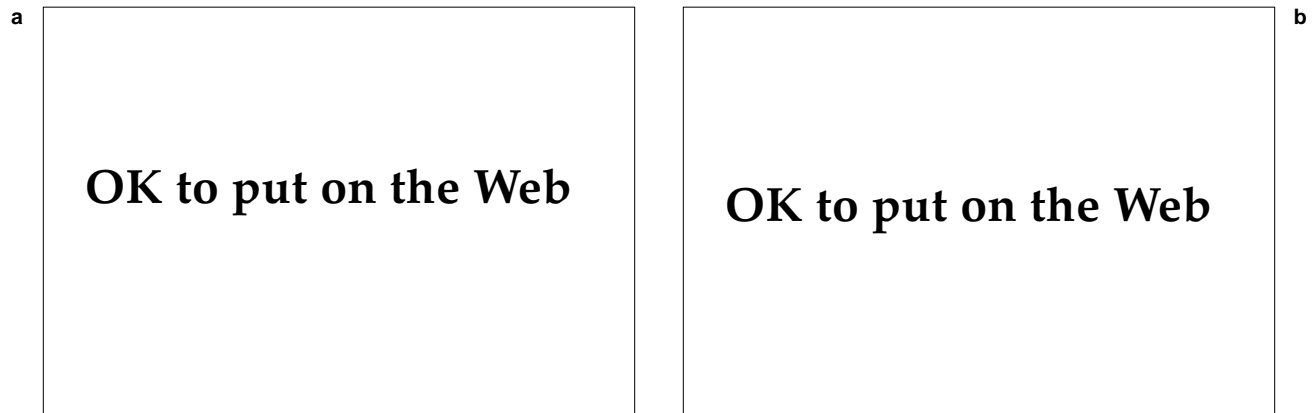
### Complications

Complications of extensive or untreated granuloma inguinale include

- scarring and strictures of the anus, urethra, and vagina, with deformity of the external genitalia;
- elephantiasis of the penis, scrotum, or vulva secondary to destruction of the lymphatics; and



**Fig. 19-19.** Granuloma inguinale often causes large, ulcerative lesions. (a) This patient has a destructive lesion of the penile shaft and a large, exophytic lesion of the lower abdomen. (b) Undiagnosed, untreated granuloma inguinale may lead to massive scrotal and inguinal lymphedema. Photographs: Courtesy of Walter Reed Army Medical Center Dermatology Service slide file, Washington, DC.



**Fig. 19-20.** (a) This Wright-Giemsa stain of a crush preparation of tissue shows intracellular bacilli (Donovan bodies) (arrow). (b) The organisms (arrow) appear black in the Warthin-Starry stain. Photographs: Courtesy of Walter Reed Army Medical Center Dermatology Service slide file, Washington, DC.

- systemic spread of the disease to visceral organs, resulting in death.<sup>83</sup>

Malignancy, either basal cell or squamous cell carcinoma, has been reported to arise in long-standing lesions of granuloma inguinale. Extragenital lesions have been reported in a small number of patients, with occasional involvement of the intestinal tract, bone, orbit, liver, spleen, and oral mucosa.<sup>82</sup>

### Laboratory Diagnosis

The diagnosis of granuloma inguinale is based primarily on stained smears of crushed tissue obtained from the ulcer. The bacterium is an intracellular parasite of macrophages; therefore, swabs or superficial scrapings from the lesion are apt to be nondiagnostic. The lesion is first cleaned with normal saline on a cotton gauze pad and then wiped dry. Under local anesthesia, a punch biopsy, curettage, or thin wedge of the ulcer base or margin is obtained. The tissue is placed between two glass slides and crushed; the slides are separated and then air-dried. Wright-Giemsa stain is used to demonstrate clusters of blue-to-black organisms that resemble safety pins within the vacuoles of enlarged macrophages.<sup>77,84</sup> Additionally, the Warthin-Starry stain has been used to demonstrate the intracytoplasmic organisms (Figure 19-20).<sup>80</sup>

Donovan bodies may be difficult to find in formalin-fixed, hematoxylin-eosin-stained sections. However, thin, plastic-embedded sections permit

easy identification of the rod-shaped encapsulated organisms within macrophages.<sup>80</sup>

Culture of the organism is beyond the capabilities of most laboratories,<sup>81</sup> as the organism fails to grow on conventional solid media. Only 14 isolates have been reported—the latest in 1962. Isolation is hampered by the need to eliminate the contaminants frequently present in genital ulcers.<sup>85</sup>

Complement-fixation serologic tests and skin testing are not routinely available because the disease is rare and a suitable source of antigen is lacking.

### Treatment

Numerous antibiotic regimens have been proposed for the treatment of granuloma inguinale. Tetracycline is the most effective, administered orally as a dose of 500 mg every 6 hours for 21 days. Treatment should be continued until all lesions have completely resolved.<sup>77</sup> Other tetracyclines (eg, doxycycline and minocycline) have also been used successfully.<sup>86</sup>

Alternative regimens include erythromycin 500 mg, administered orally every 6 hours for 12 weeks, or, in cases of treatment failure with tetracycline and erythromycin, ampicillin 500 mg, administered orally every 6 hours for the same duration. Lincomycin, chloramphenicol, and gentamicin are also effective.<sup>77</sup> In 1991, successful treatment was reported in India with norfloxacin.<sup>85</sup>

Inguinal pseudobuboes may require surgical excision if they fail to resolve with antibiotic therapy.<sup>80</sup>

## LYMPHOGRANULOMA VENEREUM

The various serotypes of the bacterium *Chlamydia trachomatis* cause a wide spectrum of serious diseases (Table 19-4).<sup>87</sup> Infections caused by chlamydia, which includes pelvic inflammatory disease and nongonococcal urethritis, are the most common STDs; they account for millions of cases per year and a significant incidence of sterility in women. This chapter focuses on the serotypes of chlamydia that cause lymphogranuloma venereum, a condition characterized by painful inguinal lymphadenitis or proctocolitis which, if untreated, may result in scarring and chronic lymphatic obstruction.

Cases of lymphogranuloma venereum are uncommon in the United States and Europe, with only a few hundred cases reported annually; but the disease is endemic in Africa, India, parts of Southeast Asia, South America, and the Caribbean region.<sup>88</sup> In the United States, a number of outbreaks have been reported among sailors, soldiers, and travelers returning from endemic areas. In a study conducted in 1968 of 20 military patients with lymphogranuloma venereum, 19 were either returning from Vietnam or were sexual partners of a person returning from Southeast Asia.<sup>89</sup> Clusters of cases in the United States occur in Washington, D. C., and the southeastern states, particularly affecting the poor, urban, black population.<sup>90</sup> This parallels epidemiological data gathered from overseas, where lymphogranuloma venereum is found to be more common in urban areas, in particular among the sexually promiscuous and the lower socioeconomic classes.

### Clinical Manifestations

Lymphogranuloma venereum demonstrates three typical stages, although not every patient will

manifest signs and symptoms of each stage<sup>88</sup>:

1. the primary stage, consisting of a small, inconspicuous, transient papule or ulcer;
2. the secondary stage, consisting of acute inguinal lymphadenitis with bubo formation (ie, the inguinal syndrome), associated with fever and other constitutional symptoms; and
3. the uncommon third stage (ie, the anogenitoretal syndrome), consisting of subacute to chronic infection leading, in any combination, to (a) chronic ulceration, (b) fistulae and strictures of the rectum, vagina, or urethra, and (c) lymphatic obstruction.

Following an incubation estimated to be between 3 and 12 days, a primary lesion develops at the site of inoculation. The primary lesion, found in fewer than one half of patients,<sup>91</sup> is most often a herpetiform ulcer, although a small papule, a shallow ulcer or erosion, or symptoms of nonspecific urethritis can also occur. The primary lesion often goes unnoticed by the patient, particularly in women. In men, it is most commonly found in the coronal sulcus and, in a minority of patients, elsewhere on the external genitalia (Figure 19-21).<sup>88</sup>

After a latent period of 1 to 4 weeks following the primary lesion, regional lymph node involvement develops (ie, the inguinal syndrome). The site of the primary lesion determines which group of lymph nodes will be affected, which, in turn, affects the clinical presentation (Table 19-5). In men, painful, regional lymphadenopathy—usually unilateral—develops, with enlargement of nodes above and below the inguinal ligament. This produces the

TABLE 19-4

### SEROTYPES OF *CHLAMYDIA TRACHOMATIS* AND HUMAN DISEASE

---

Table 19-4 is not shown because the copyright permission granted to the Borden Institute, TMM, does not allow the Borden Institute to grant permission to other users and/or does not include usage in electronic media. The current user must apply to the publisher named in the figure legend for permission to use this illustration in any type of publication media.

---

Adapted with permission from Schachter J. Chlamydial infections. Part 1. *N Engl J Med.* 1978;298(8):429.

**TABLE 19-5**  
**SITE OF PRIMARY INFECTION AND**  
**LYMPHATIC INVOLVEMENT IN**  
**LYMPHOGRANULOMA VENEREUM**

Table 19-5 is not shown because the copyright permission granted to the Borden Institute, TMM, does not allow the Borden Institute to grant permission to other users and/or does not include usage in electronic media. The current user must apply to the publisher named in the figure legend for permission to use this illustration in any type of publication media.

Reprinted with permission from Perine PL, Osoba AO. Lymphogranuloma venereum. In: Holmes II, Mardh P-A, Sparling PF, et al, eds. *Sexually Transmitted Diseases*. New York, NY: McGraw-Hill; 1990:197.

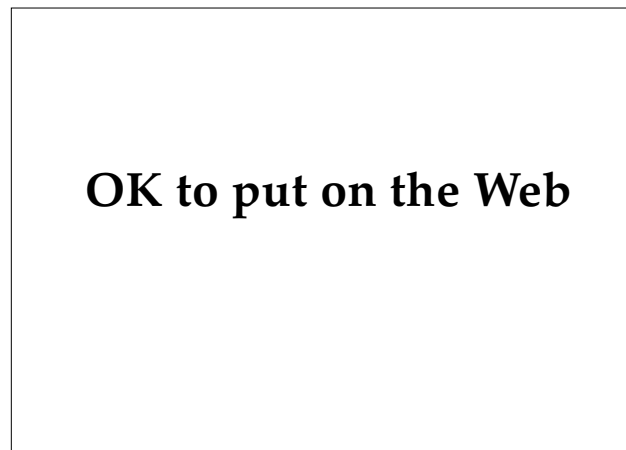“groove” sign, which is virtually pathognomonic of lymphogranuloma venereum. The nodes enlarge and become fluctuant, developing a striking bluish red hue (ie, the characteristic “blue balls”) in the overlying skin (Figure 19-22). They subsequently rupture through the skin to form deep ulcerations with draining sinus tracts.<sup>10</sup> Only 20% to 30% of women will present with acute inguinal lymphadenitis. Patients complain of deep pelvic, abdomi-

nal, or low back pain.<sup>88</sup>

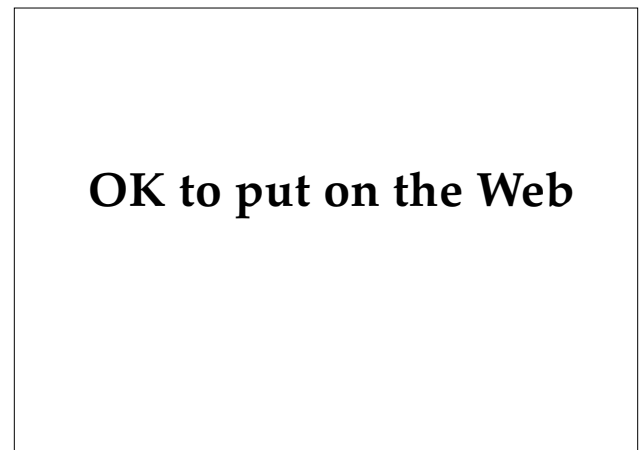
Hematogenous dissemination of the organism results in clinical signs and symptoms of malaise, fever, hepatitis, pneumonitis, arthritis, conjunctivitis, and even encephalitis. Erythema multiforme, erythema nodosum, photosensitivity, and scarlatiniform eruptions may be seen in association with acute infection.<sup>77,86</sup>

Long-standing, untreated disease leads to the development of deep ulcerations, secondary infection with purulent discharge from the anorectal area (proctocolitis) or vagina, and, ultimately, fistulae and scarring. In the anorectal region, strictures and fibrosis of the bowel wall cause fever, constipation, diminished caliber of stools, cramping abdominal pain, and weight loss. Bowel perforation and peritonitis leading to death have been reported.<sup>77</sup>

Following an outbreak of lymphogranuloma venereum in a university, a 1976 report<sup>92</sup> estimated that significant penile deformity in chronic lymphogranuloma venereum occurred in fewer than 5% of infected men. Elephantiasis of the penis and scrotum and chronic penile ulcerations were also reported. However, serious genitourinary deformity occurs in nearly 25% of all untreated women. Anal and rectovaginal fistula formation with fibrosis are reported complications. *Esthiomene* is a deforming vulvar elephantiasis characterized by edema, fibrosis, chronic ulceration, and scarring of the external female genitalia.<sup>92</sup>



**Fig. 19-21.** A rarely seen primary lesion of lymphogranuloma venereum on the penile frenulum. This small, shallow erosion is easily confused with a traumatic injury, genital herpes infection, or syphilis. The penis was rotated upward and to the right to show the lesion.



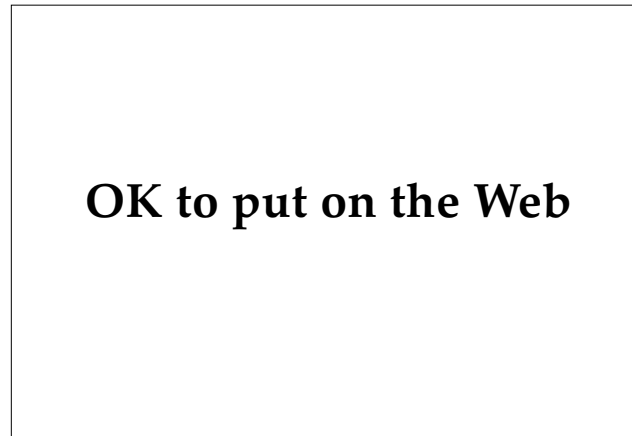**Fig. 19-22.** Massive, bilateral, inguinal lymphadenopathy of lymphogranuloma venereum with large, fluctuant nodes. Spontaneous rupture, which is imminent, may lead to chronic ulcers that heal poorly. Photograph: Courtesy of Walter Reed Army Medical Center Dermatology Service slide file, Washington, DC.

### Laboratory Diagnosis

The diagnosis of lymphogranuloma venereum rests principally on (a) the exclusion of other STDs in which patients present with lymphadenopathy (primarily syphilis, chancroid, and genital herpes infections) and (b) the lymphogranuloma venereum complement-fixation test. Complement-fixation titers of 1:64 or greater are considered positive for the disease. There is cross-reactivity with other chlamydial infections, and high complement-fixation titers have been found in asymptomatic individuals and in those with other chlamydial infections. Titers of less than 1:64 are equivocal and should be interpreted with care.<sup>88</sup>

Several newer tests have been developed, but these are not widely available. The microimmunofluorescent test detects type-specific antibody (L-1, L-2, or L-3) in the serum of infected individuals.<sup>93</sup> IgG antibody titers greater than 1:1,000 or IgM titers greater than 1:32 on the microimmunofluorescent test are seen in most patients with lymphogranuloma venereum.<sup>94</sup> A direct fluorescent antibody technique has been introduced to detect the presence of antigen in biopsy specimens or, in a recent case, of smears prepared from lymph node aspirate.<sup>95</sup>

Culture of the organism on mouse brain, yolk sac, or tissue culture (ie, McCoy cells) is the definitive diagnostic test but is generally unavailable.<sup>77</sup> The Frei test, which involved the intradermal injection of sterilized bubo aspirate, is no longer



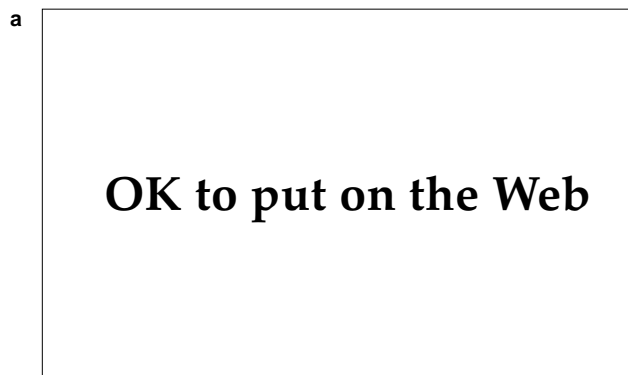**Fig. 19-23.** This histological section through an excised lymph node shows triangular stellate abscesses of lymphogranuloma venereum (hematoxylin-eosin stain, medium-power magnification).

performed and is mentioned only for historical interest.

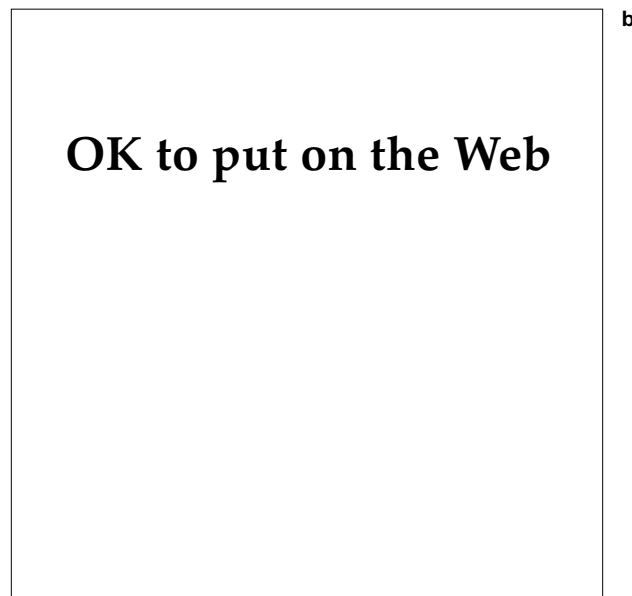Histological sections of involved lymph nodes show characteristic stellate abscesses surrounded by a palisading arrangement of epithelioid cells. No organisms can be seen in histological sections (Figure 19-23).<sup>54</sup>

### Treatment

The CDC's 1993 recommended regimen for treatment of lymphogranuloma venereum is doxy-



**Fig. 19-24. (a)** Surgical incision and drainage, as were inappropriately done in this patient with lymphogranuloma venereum, cause chronic, nonhealing, inguinal ulcers. **(b)** As seen in a different patient, the proper treatment is aspiration from the superior aspect of the node, which reduces pain and the risk of spontaneous rupture, and allows the lymphadenitis to resolve (also see Fig. 19-16).



cycline 100 mg, administered orally twice daily for 21 days.<sup>25</sup> The alternative regimens are the following<sup>25</sup>:

- erythromycin 500 mg, administered orally four times daily for 21 days; or
- sulfisoxazole 500 mg, administered orally four times daily for 21 days; or
- an equivalent course of sulfonamide.

Response to therapy is usually better in acute cases. Many cases require two or more 21-day courses of antibiotic before a clinical response is observed. Aspiration of fluctuant inguinal lymph nodes may speed recovery when rupture of those nodes is imminent. Incision and drainage is contraindicated, as complications such as scarring and delayed healing may occur (Figure 19-24).<sup>96</sup>

### ***Follow-Up***

Patients with lymphogranuloma venereum should be followed clinically until signs and symptoms have resolved.<sup>25</sup>

### ***Management of Sexual Partners***

Persons who have had sexual contact with a patient who has lymphogranuloma venereum within the 30 days before the onset of the patient's symptoms should be examined, tested for urethral or cervical chlamydial infection, and treated.<sup>25</sup>

### ***Pregnant Women***

Pregnant and lactating women should be treated with the erythromycin regimen.<sup>25</sup>

## **GENITAL HERPES INFECTION**

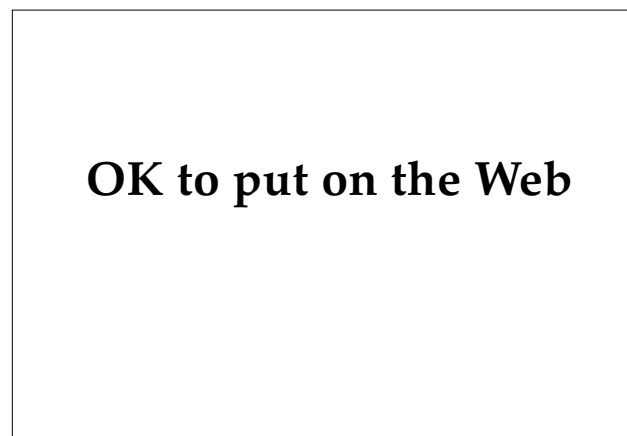
Although public awareness of genital herpes infection (caused by herpes simplex viruses [HSVs]) has been eclipsed by the AIDS epidemic, infections caused by HSVs continue to be an enormous public health problem (Figure 19-25). Although genital herpes infection is not a reportable disease and therefore exact figures are not available, various estimates of its incidence in the United States suggest that (a) 5 to 20 million persons are infected, with 260,000 to 500,000 new cases per year; and (b)

the incidence appears to be increasing.<sup>97</sup> This makes genital herpes infection the most common cause of genital ulceration in the industrialized nations.<sup>98</sup> The increase in this disease may be attributable to an increase in the number of sexual partners; earlier sexual activity among adolescents; and the introduction of oral contraceptives and other forms of contraception, which has led to earlier and more frequent casual sexual encounters.<sup>99</sup> Additionally, genital ulcer diseases, including genital herpes infection, have been linked to transmission of HIV to sexual partners.<sup>100</sup>

### **Clinical Manifestations**

#### ***Primary Genital Herpes Infection***

Following contact with an infected sexual partner, an incubation period of 3 to 7 days, rarely up to 3 weeks, ensues before clinical signs and symptoms appear.<sup>101</sup> Grouped vesicles on an erythematous, edematous base quickly develop and may cover extensive areas of perineal skin. Pain and itching, severe in some individuals, are reported by almost all patients with primary infection. First-episode infections are more severe in women. This may be due to cervical involvement as well as a greater total surface area of infection.<sup>102</sup> The vesicles rupture and coalesce into areas of extensive erosions associated with pain and tenderness. In women, lesions are found on the vulva (the most common location),



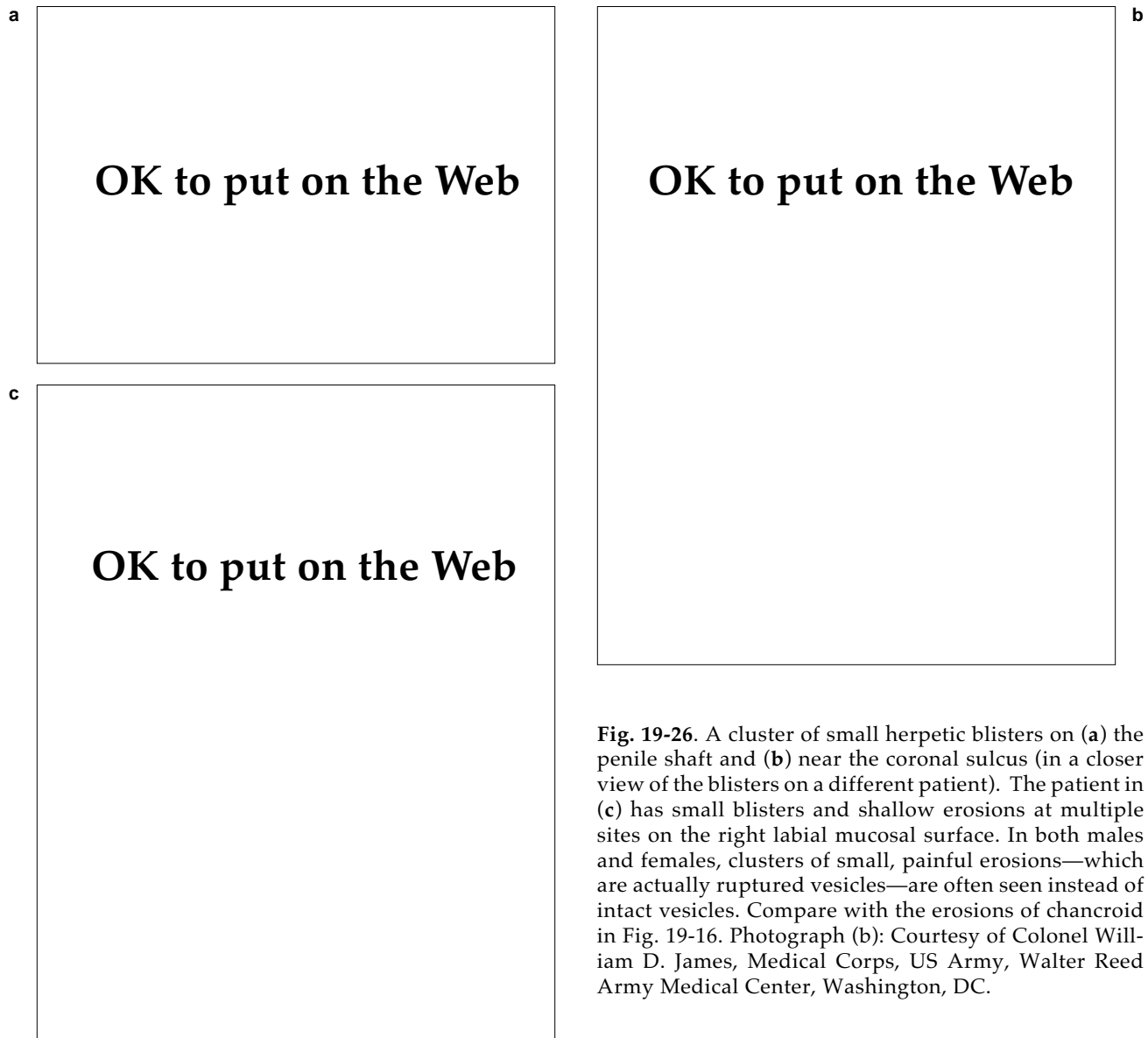
**Fig. 19-25.** Genital herpes infection was the “social disease” of the 1970s and 1980s. Drawing: Courtesy of B. E. Benson, Silver Spring, Md.

labia majora, labia minora, and the perianal skin (Figure 19-26). Women with involvement of the cervix or vagina present with erosions and a profuse, watery vaginal discharge. In men, vesicles are found most frequently on the glans, foreskin, and penile shaft. Autoinoculation may lead to extensive erosions and vesiculation of the penis and the pubic area. In homosexual men, primary herpetic lesions may be seen in the anus or the perianal area.<sup>101</sup> Signs and symptoms of herpes proctitis include rectal pain and discharge, tenesmus, constipation, fever, and malaise. A study published in 1983<sup>103</sup> reported that about one half of patients experience sacral paresthesias, impotence, urinary retention, and

perianal vesicles; these findings are absent in patients with proctitis caused by *Neisseria gonorrhoeae* or chlamydia.

Tender inguinal lymphadenopathy develops during the second or third week of primary infection. Nodes are enlarged, firm, and nonfluctuant. HSV has been isolated from inguinal aspirates of affected nodes.<sup>102</sup>

Complications of primary infections are most common in women and include local extension of the lesions, extragenital involvement secondary to autoinoculation, and various neurological manifestations. Up to one third of patients develop complaints consistent with aseptic meningitis: stiff neck,



**Fig. 19-26.** A cluster of small herpetic blisters on (a) the penile shaft and (b) near the coronal sulcus (in a closer view of the blisters on a different patient). The patient in (c) has small blisters and shallow erosions at multiple sites on the right labial mucosal surface. In both males and females, clusters of small, painful erosions—which are actually ruptured vesicles—are often seen instead of intact vesicles. Compare with the erosions of chancroid in Fig. 19-16. Photograph (b): Courtesy of Colonel William D. James, Medical Corps, US Army, Walter Reed Army Medical Center, Washington, DC.

headache, and photophobia.<sup>102</sup> Encephalitis is a rare complication of genital herpes infection and is more often reported with HSV type 1 (HSV-1), although a fatal case of meningoencephalitis caused by HSV-2 in an individual infected with HIV was reported in 1990. (HSV-1 is more frequently associated with mucocutaneous infections, and HSV-2 with genital lesions; however, either type can be isolated from either location.) Notable findings in this case were (a) the development of an acyclovir-resistant strain of virus during therapy and (b) isolation of the same viral isolate from both a herpetic perirectal abscess and brain tissue.<sup>104</sup>

Other reported complications include temporary sacral anesthesia, urinary incontinence, and impotence. Cutaneous or visceral dissemination or thrombocytopenia may also occur.<sup>105</sup>

In both men and women, lesions persist for 2 to 6 weeks and then resolve, usually without scarring.

### ***Nonprimary Genital Herpes Infection***

In 1984, when evaluating patients with clinical primary genital herpes infection for the presence of antibody to HSV-2, researchers found that more than 50% of patients with *primary* genital herpes had antibodies to HSV-2 by Western blot analysis. This unexpected finding suggests that a significant number of patients have had asymptomatic or subclinical infections at an earlier time; therefore, this category of clinical infection is called *nonprimary*. The existence of this nonprimary genital herpes infection is important to remember when counseling patients or attempting contact tracing to identify the source of the virus.<sup>106</sup>

### ***Recurrent Genital Herpes Infection***

Within a year after the first episode, about two thirds of patients will have recurrent episodes of genital herpes infection. In one study, approximately 50% of these patients had monthly recurrences, 33% had recurrences every 2 to 4 months, and 15% had recurrences fewer than 3 times in the first year.<sup>107</sup> Recurrent lesions are frequently inconspicuous, especially those localized to the cervix. In men, asymptomatic urethral infections are thought to occur at an incidence of approximately 1%.<sup>101</sup>

The clinical manifestations of recurrent disease are usually less severe and of shorter duration than primary infections. The risk of recurrence is influenced by (a) the type of herpes virus and (b) the host immune response to the viral infection. There is a lower rate of recurrence with HSV-1 compared to

HSV-2. Researchers have hypothesized that the frequency of sacral ganglionic latency is lower in HSV-1 infections than in HSV-2, resulting in lower rates. Their evaluation of host cellular-immune factors demonstrated that high titers of neutralizing antibody after primary infection correlates with an increased risk of recurrent disease.<sup>102</sup>

The clinical presentation of recurrent disease differs considerably from that of primary infection. Approximately 50% of patients experience prodromal symptoms—tingling, itching, or pain—for a few hours to 1 to 2 days preceding the attack. The lesions tend to be unilateral and fewer in number, and are grouped vesicles on an erythematous base. Viral shedding averages only 4 days and healing is complete in about 10 days.<sup>99</sup> There is usually no lymphadenopathy or systemic symptoms associated with recurrent disease.

Two theories attempt to explain the reactivation of HSV from sacral ganglia<sup>101</sup>:

1. The ganglionic trigger theory proposes that a triggering stimulus (eg, menstruation, fever, or stress) reactivates the virus, which then travels down the peripheral nerve to epidermal cells, causing a skin lesion.
2. The skin trigger theory proposes that within epithelial cells there is a low level of viral replication that is eliminated by the host immune response. Injury to the skin (eg, trauma, sunburn) results in clinical disease by either suppressing local defenses or stimulating viral replication.

Complications of recurrent genital herpes infection are few. Erythema multiforme may develop in young patients 10 to 14 days following recurrent disease. The erythema multiforme may present as typical target lesions on the extremities or may develop into severe mucocutaneous involvement. Spontaneous improvement is the rule, although patients often have recurrent episodes for 5 to 6 years.<sup>108</sup>

### ***Genital Herpes Infections in Immunocompromised Patients***

Genital herpes infections in immunocompromised patients (eg, patients who are receiving chemotherapy, have received bone marrow transplants, or are infected with HIV) are more severe and more prolonged than in immunocompetent patients (Figure 19-27). Lesions are deep, necrotic, and painful; viral shedding persists for months in some patients with AIDS. In patients infected with HIV, lesions



are most commonly located in the perianal area, followed by the buttocks, scrotum, penis, and the orolabial area. Although there is an increased risk of dissemination in these patients, most untreated infections do not disseminate.<sup>99</sup>

### Laboratory Diagnosis

Numerous laboratory techniques are currently available for the diagnosis of genital herpes infections, although only a few are in routine clinical use. These include viral culture, Tzanck and Papanicolaou smears, direct immunofluorescence staining, and viral serology. Other less frequently employed or research methods include immunoperoxidase staining, ELISA, electron microscopy, and tests to type and subtype virus isolates.

#### Viral Culture

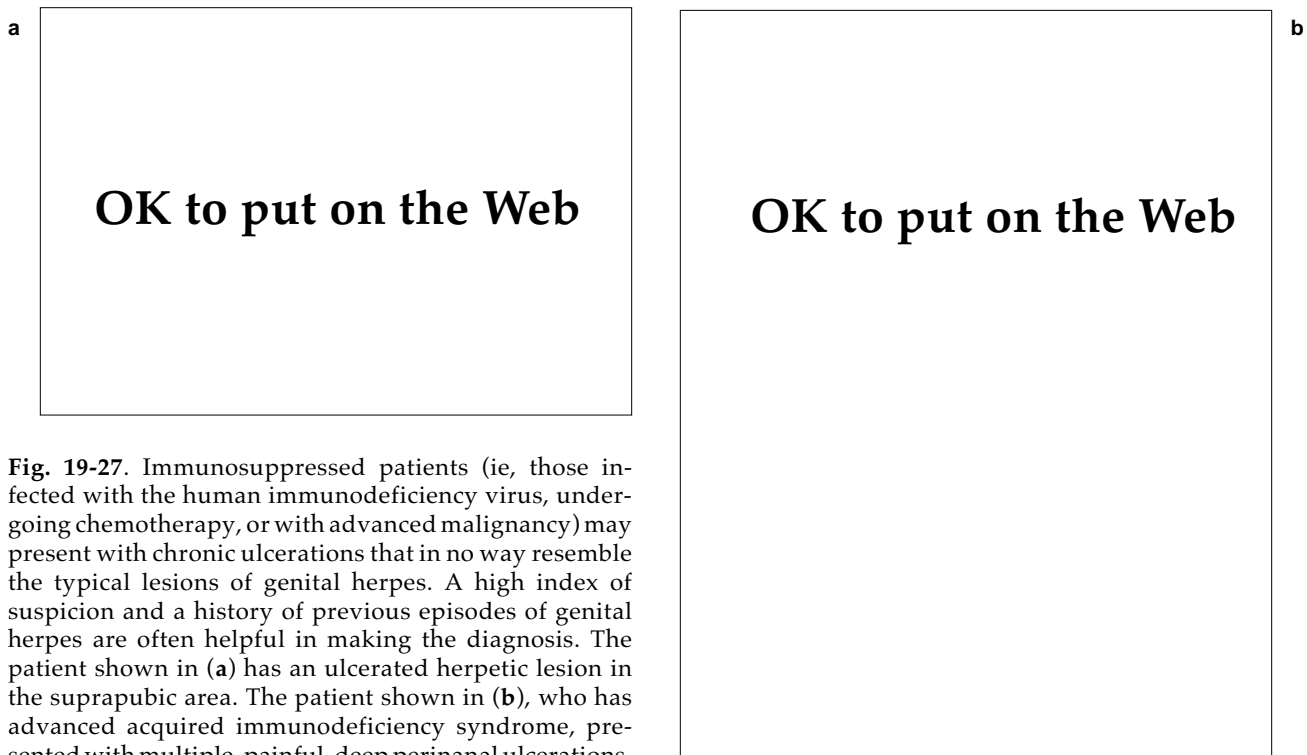
Isolation by tissue culture is the most sensitive method for the detection of HSV. The success of viral isolation depends on the type of lesion cultured (ie, intact vesicle or erosion), the age of the lesion, the size of the inoculum, the immune status of the patient, and the sensitivity of the cell culture (human foreskin fibroblast, monkey kidney, or pri-

mary rabbit kidney).<sup>109</sup> Viral cultures obtained from intact vesicles or pustules in patients with primary genital herpes infections are positive in almost 90% of patients, compared to less than 30% if crusted lesions are cultured.<sup>99</sup> In one large series, HSV was cultured from 94% of vesicles, 87% of pustules, 70% of ulcers, and only 27% of crusted lesions.<sup>98</sup>

The ideal lesion for culture is an intact vesicle or pustule. The lesion should be unroofed and the base swabbed with a synthetic polyester- or cotton-tipped applicator. The material is then placed into a suitable viral transport medium (ie, Hank's balanced salt solution with antibiotics or veal infusion broth). Under refrigeration, the virus can survive in transport material without loss of infectivity for 72 hours at 4°C.<sup>98</sup> The average replication time of HSV is 12 to 18 hours; typical cytopathic effects of the virus in culture are seen in 1 to 3 days, although it may take 6 or 7 days for smaller inocula. Confirmation that HSV is responsible for the cytopathic effect is done using type-specific antisera, direct immunofluorescence, or nucleic acid hybridization.<sup>110</sup>

#### Cytologic Diagnosis

Cytologic diagnosis can be made using the Tzanck (Wright-Giemsa) or Papanicolaou stains of smears



**Fig. 19-27.** Immunosuppressed patients (ie, those infected with the human immunodeficiency virus, undergoing chemotherapy, or with advanced malignancy) may present with chronic ulcerations that in no way resemble the typical lesions of genital herpes. A high index of suspicion and a history of previous episodes of genital herpes are often helpful in making the diagnosis. The patient shown in (a) has an ulcerated herpetic lesion in the suprapubic area. The patient shown in (b), who has advanced acquired immunodeficiency syndrome, presented with multiple, painful, deep perianal ulcerations.

of material taken from the base of lesions. These are rapid, bedside, diagnostic tests that provide information quickly, especially when the test is positive. Cells infected in vivo with HSV show intranuclear inclusions, balloon giant cells, and multinucleated giant cells similar to those seen in tissue culture. Both tests are less sensitive than viral culture and neither differentiates among HSV-1, HSV-2, or herpes zoster infections. With either test, greater sensitivity is seen when intact vesicles or pustules are present than when erosions or ulcers are sampled.<sup>101</sup>

The Tzanck smear is performed by scraping the base and margins of an unroofed vesicle or pustule, or the base of an erosion or ulcer, and spreading the material on a glass slide. After fixation in absolute alcohol, the material is stained with Wright-Giemsa stain and examined for typical balloon and multinucleated giant cells (Figure 19-28). The Papanicolaou smear is especially useful for asymptomatic herpes infections of the cervix. On staining, both multinucleated giant cells and intranuclear viral inclusions are visible, making this test more sensitive than the Tzanck smear.

#### *Antigen Detection Using Direct Immunofluorescence*

One of the tests most commonly used to detect the presence of HSV antigen is the fluorescein-conjugated anti-HSV monoclonal antibody test (also called the direct immunofluorescence antibody test). The sensitivity of the test is approximately 70% to

## OK to put on the Web

**Fig. 19-28.** This Tzanck preparation of a herpetic lesion shows several multinucleated giant cells. Photograph: Courtesy of Colonel Purnima Sau, Medical Corps, US Army, Walter Reed Army Medical Center, Washington, DC.

95% compared to viral culture. The accuracy of the test depends on the presence of sufficient numbers of cells to be studied (Table 19-6).<sup>111</sup>

To prepare a specimen for the direct immunofluorescence antibody test, the base of the lesion is either scraped with a scalpel blade or swabbed with an applicator. The scrapings are placed on a glass slide and transported to the laboratory, where the specimen is fixed and stained. If a swab is used, it is placed in transport medium and sent to the laboratory. There, the cells are

**TABLE 19-6**

### **SENSITIVITY OF DIAGNOSTIC TESTS TO HERPES SIMPLEX VIRUS**

Table 19-6 is not shown because the copyright permission granted to the Borden Institute, TMM, does not allow the Borden Institute to grant permission to other users and/or does not include usage in electronic media. The current user must apply to the publisher named in the figure legend for permission to use this illustration in any type of publication media.

Adapted with permission from Moseley RC, Corey L, Benjamin D, Winter C, Remington ML. Comparison of viral isolation, direct immunofluorescence, and indirect immunoperoxidase techniques for detection of genital herpes simplex virus infection. *J Clin Microbiol.* 1981;13:915.

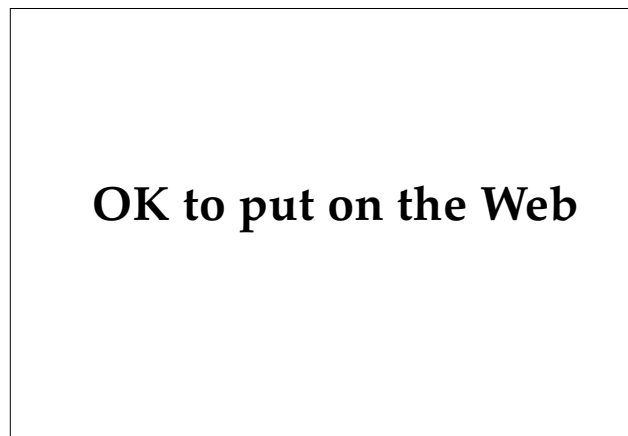concentrated and spotted onto glass slides; the stained slides are then examined under a fluorescence microscope (Figure 19-29). Using monoclonal, fluorescein-tagged antibodies, the determination can be made quickly whether the virus is HSV-1 or HSV-2, which provides important prognostic information.<sup>110</sup>

Two other diagnostic methods are available for antigen detection: the ELISA and the immunoperoxidase tests. These have similar sensitivities as the immunofluorescence stain; they will not be discussed further here.

### Serologic Tests

Serologic testing for the presence of antibodies to herpes viruses has limited clinical value except in primary infections. Once an individual becomes seropositive, antibody titers persist for life, and the titers do not correlate with the timing or severity of recurrent disease. Currently available tests do not differentiate between HSV-1 and HSV-2, and patients should not be told they have had prior HSV-2 infections based on the results of routine antibody screening.<sup>99</sup>

When primary genital herpes infection is suspected, blood samples for antibody testing should be taken on the first visit, and then 10 to 14 days later, for a complement-fixation test. Anti-HSV antibody of the IgM class is produced during a primary infection, but is generally not detected in recurrent cases.<sup>10</sup>



**Fig. 19-29.** Direct immunofluorescence test showing positive fluorescence in a herpes simplex–infected cell. Photograph: Courtesy of Burroughs Wellcome, Research Triangle Park, NC.

### Treatment

Over the last decades, many therapies have been attempted for the management of genital herpes infections. The introduction of acyclovir in oral, topical, and intravenous formulations has revolutionized the management of patients with primary and recurrent disease. However, chronic use of the drug, especially in patients with HIV infections, has led to the emergence of acyclovir-resistant strains.

### Primary Genital Herpes Infections

Primary genital herpes infections are often quite severe, prolonged, and associated with constitutional symptoms in many patients, especially women. Acyclovir, administered orally in a dose of 200 mg five times daily for 7 to 10 days, is considered the treatment of choice for first-episode primary genital herpes infections in immunocompetent individuals. Treatment with oral acyclovir in this population significantly reduces viral shedding, shortens the time to healing, and often reduces the duration of pain and new lesion formation.<sup>112</sup>

In patients with complications (eg, dehydration, severe dysuria, inability to tolerate oral medications) intravenous acyclovir (5 mg/kg infused over 1 h, administered every 8 h) may be initiated. When pain and discomfort have subsided, the patient can be discharged to complete the 10-day course of therapy as an outpatient.<sup>99</sup>

Side effects associated with acyclovir therapy, although uncommon, include the following<sup>113</sup>:

- nausea, vomiting, diarrhea, and headache with oral and intravenous acyclovir;
- agitation, altered mental status, and obtundation with more-serious central nervous system toxicity; and
- reversible renal dysfunction with intravenous administration (which may be prevented by increasing the infusion time to 1 h and adequately hydrating the patient).

Unfortunately, regardless of the route of administration, acyclovir treatment of primary genital herpes infection does not prevent the development of recurrent disease.<sup>112,114</sup>

### Recurrent Disease

Treatment guidelines for recurrent genital herpes infection vary depending on the frequency of recur-

rent episodes, duration and severity of the episodes, and the presence of complications, especially herpes-associated erythema multiforme. Treatment is divided into episodic and long-term suppressive modes.

**Episodic Treatment.** Oral acyclovir, in a dose of 200 mg administered five times daily for 5 days, is the most consistently effective therapy for episodic treatment of recurrent genital herpes infection in immunocompetent individuals. Studies have focused on patient-initiated and physician-initiated therapy, and its impact on duration and severity of recurrences. Patient-initiated therapy, in which the patient begins treatment at the onset of prodromal symptoms, tends to offer greater benefit than physician-initiated regimens. Studies have demonstrated a statistically significant reduction in viral shedding and healing times with episodic treatment but less-than-convincing reduction in local pain and discomfort.<sup>115</sup> In recurrent herpes labialis, higher doses of patient-initiated acyclovir (400 mg administered five times daily for 5 d) have been suggested to improve response and decrease symptoms. Likewise, refractory cases of recurrent genital herpes infection may respond to higher doses.<sup>116</sup>

The CDC suggests that acyclovir 400 mg, administered three times daily for 5 days or 800 mg, administered twice daily for 5 days; might be effective.<sup>25</sup>

**Long-Term Suppressive Therapy.** Rates of recurrent genital herpes infection vary considerably—from 1 or 2 to more than 12 recurrences per year. Most patients who seek therapy for recurrent disease have 5 to 8 recurrences per year.<sup>115</sup> Suppressive therapy is also indicated for the treatment of pa-

tients with recurrent herpes-associated erythema multiforme.<sup>99</sup>

Numerous dosing regimens have been proposed; however, the two most effective are 400 mg, administered twice daily, and 200 mg, administered three to five times daily. Once-daily therapy in any dose is less effective than twice-daily regimens but should be considered in poorly compliant patients. There appears to be little, if any, long-term toxicity and no reason that long periods of use are not safe. However, patients should be encouraged to interrupt therapy after 1 year of continuous therapy to determine if the frequency of recurrences still justifies the continued use of the drug.<sup>25,117</sup>

### *Treatment of Immunocompromised Patients*

Treatment of recurrent genital herpes infections in compromised hosts, particularly patients with HIV infection, is complicated by persistent viral shedding, the necessity in some patients for indefinite suppressive therapy, and the emerging problem of acyclovir-resistant strains of HSV. In *outpatient* immunocompromised patients (eg, those with HIV infection, bone marrow–transplant recipients) with recurrent mucocutaneous disease, higher doses of oral acyclovir (400 mg administered five times daily for 10 d) have been shown to be effective.<sup>118</sup> Enthusiasm for topical acyclovir ointment has diminished. However, the topical preparation applied 6 times daily for 10 days significantly reduces viral shedding, pain, and healing times.<sup>113</sup> The treatment of hospitalized, immunocompromised patients with genital herpes infections is beyond the scope of this discussion.

## GENITAL WARTS

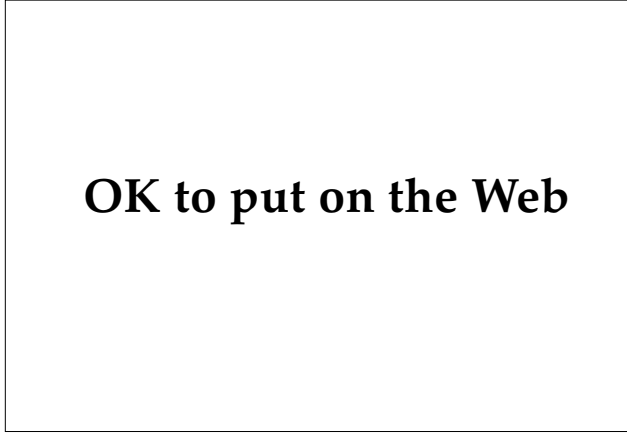Anogenital warts (also called condylomata acuminata and venereal warts) are an ancient disease, with the earliest references to them in literature as *condylomata* (figs). It was well known during the Roman Empire that promiscuous sexual behavior and anal intercourse were implicated in the spread of this disease. An early reference to condyloma acuminata is found in this satirical poem written in the first century AD by Martial in his *Epigrammata Medicae Philosophicae* (XII:3), as translated by J. D. Oriel:

In order to buy some slave boys  
Labienuis sold his gardens,  
But now the poor man has  
Only an orchard of figs.<sup>119(p99)</sup>

Genital warts result from infection by a group of DNA-containing human papillomaviruses (HPVs). Recent investigations of the epidemiology and natural history of human papillomavirus infections have shed light on the transmission, infectivity, and probable oncogenic potential of these agents. Advances in molecular biology have clearly demonstrated the role of certain HPV subtypes in Bowenoid papulosis, cervical dysplasia, and cervical carcinoma. In particular, subtypes 16, 18, 31, and 33 are most often implicated in these conditions; many other HPV subtypes have been found in genital wart tissue and in premalignant and malignant lesions of the genitalia.

The HPV organism consists of circular, double-stranded DNA enclosed in a protein shell (ie, a

capsid) (Figure 19-30). The absence of a lipid envelope renders the virus resistant to drying, freezing, and inactivation by ether. HPVs have never been propagated successfully in tissue culture, which has hindered laboratory studies and vaccine development. By DNA hybridization techniques, at least 55 subtypes of HPV are currently known, with more certain to be discovered (Table 19-7).<sup>120</sup>



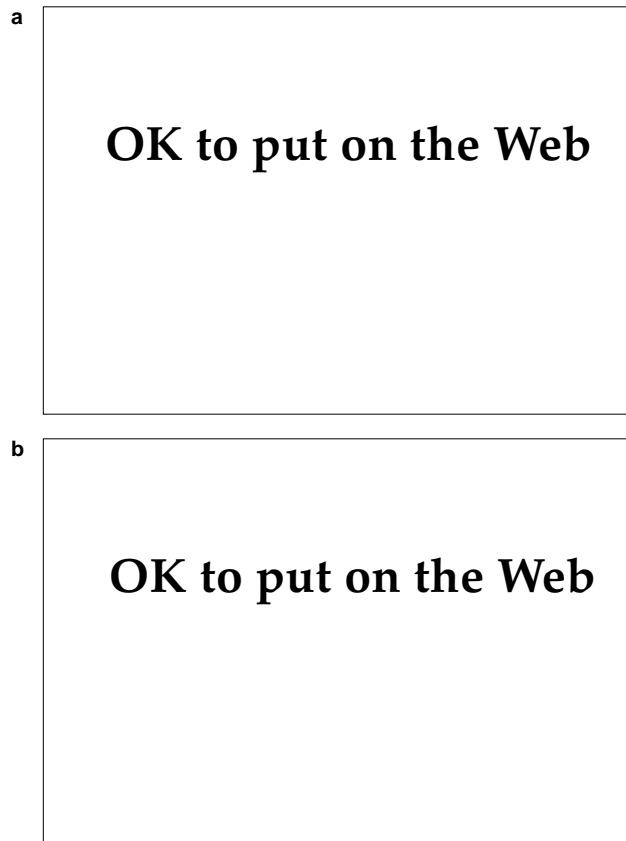
→  
**Fig. 19-30.** This electron micrograph shows clusters of human papillomavirus. Photograph: Courtesy of Walter Reed Army Medical Center Dermatology Service slide file, Washington, DC.

**TABLE 19-7**  
**TYPES AND CLINICAL ASSOCIATION OF HUMAN PAPILOMAVIRUS (HPV)**

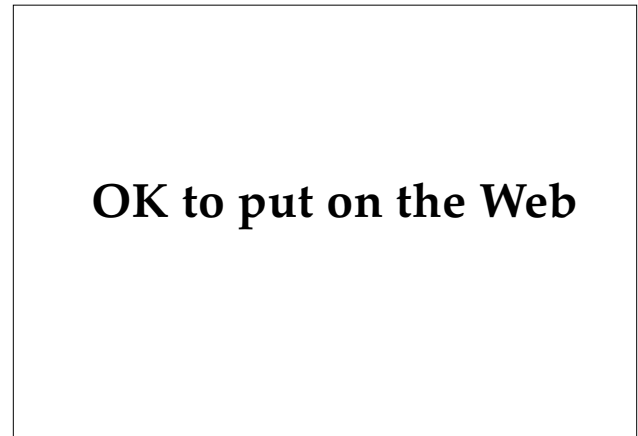Table 19-7 is not shown because the copyright permission granted to the Borden Institute, TMM, does not allow the Borden Institute to grant permission to other users and/or does not include usage in electronic media. The current user must apply to the publisher named in the figure legend for permission to use this illustration in any type of publication media.

## Clinical Manifestations

Clinical signs of genital human papillomavirus infection vary from latent infection, to extensive cauliflower-like vegetations, to frank neoplasia such as cervical carcinoma. The typical lesions are soft, grouped, skin-colored-to-pink papules with a smooth or filiform surface; they occur on moist surfaces of the external genitalia, cervix, or perianal area (Figure 19-31). Although lesions usually are asymptomatic, some patients complain of itching, local irritation, or bleeding, especially in the perianal area.<sup>121</sup> Applying 3% to 5% acetic acid to clinically normal penile or vulvar skin and then examining with magnification may demonstrate areas of flat, whitish epithelium or punctate, fine-caliber, vascular patterns that are subclinical foci of infection with HPV.<sup>122</sup>



**Fig. 19-31.** (a) Filiform condylomata in the coronal sulcus. (b) Grouped and confluent sessile genital warts on the penis. These are different expressions of the same viral infections, (a) being filiform warts, and (b) less-obvious sessile genital warts on the penile shaft.



**Fig. 19-32.** Exophytic mass protruding from the urethral meatus. The lesions may extend proximally to involve the urethral mucosal surface. Intraurethral condylomata may be better seen with urethroscopy.

Most genital warts are seen in young men and women between the ages of 16 and 25. The virus spreads primarily via sexual transmission, with a high rate of infectivity. Nearly two thirds of individuals with infected sexual partners developed genital warts within 2 to 3 months.<sup>123</sup>

In men, condyloma acuminata are most commonly found on the glans, coronal sulcus, and foreskin—moist areas that are prone to trauma and therefore vulnerable to the subsequent entry of the virus during sexual intercourse. The urethral meatus and the urethra itself may be involved with exophytic condylomata, producing dysuria and urethral discharge (Figure 19-32). Papular or flat warts may involve the penile shaft, scrotum, or inguinal folds.<sup>123</sup> Large, exophytic, perianal condyloma may also occur.

Women with genital human papillomavirus infection may present with multiple papular sessile lesions, filiform growths, or vulvar papillomatosis (ie, numerous, small, coalescing papules over the entire vulvar vestibule, giving the area a “cobblestone” appearance) (Figure 19-33). Lesions of the vagina occur in about one third of patients. Subclinical involvement of the cervix is more common than is frank condyloma acuminata. Up to 3% of routine Papanicolaou smears show changes typical human papillomavirus infection: koilocytosis, atypia, and multinucleation. Application of dilute acetic acid to the cervix followed by colposcopy may show flat-topped papules or plaques representing inconspicuous disease. These lesions most commonly contain HPV-6 and HPV-11. Lesions

**OK to put on the Web**

**Fig. 19-33.** Diffuse, confluent lesions of condyloma acuminata give this patient's vulva a distinctive "cobblestone" appearance.

**OK to put on the Web**

**Fig. 19-34.** These are the reddish brown lesions of Bowenoid papulosis, which were confirmed by shave biopsy.

**OK to put on the Web**

**Fig. 19-35.** Perianal condyloma acuminata. These lesions, which may involve the anal mucosa as well as the perianal skin, are difficult to eradicate and frequently recur.

that histologically show atypia are more often associated with HPV-16.<sup>121</sup>

Bowenoid papulosis refers to human papillomavirus infection that is characterized by small, pigmented, smooth-to- verrucous papules that show histological changes suggestive of carcinoma in situ (Figure 19-34). Although previously thought to be benign, recent studies have shown that female partners of men with Bowenoid papulosis have a higher incidence of cervical neoplasia, supporting a causative role of HPV and the subtypes, especially HPV-16, in these conditions.<sup>124</sup>

Anal warts may be found in heterosexual, homosexual, and bisexual men, with HPV-6 and HPV-11 found in the majority of cases (Figure 19-35). In renal transplant recipients and men who are infected with HIV, anal condylomata may become large, exophytic growths. These may be difficult to eradicate with any modality, and invasive squamous cell carcinomas may develop from these lesions.<sup>121</sup>

Giant condyloma of Buschke and Löwenstein is classified by some<sup>54</sup> as a low-grade verrucous carcinoma, although others<sup>125</sup> consider it a benign lesion.

**OK to put on the Web**

**OK to put on the Web**

**Fig. 19-36.** (a) Giant condyloma of the inguinal fold. (b) This closer view of the previous lesion shows the cauliflower-like masses of tumor tissue. Photographs: Courtesy of Lieutenant Colonel L. C. Sperling, Medical Corps, US Army, Walter Reed Army Medical Center, Washington, DC.

It most commonly occurs on the glans penis and foreskin of uncircumcised men. Less often, these lesions occur on the vulva or in the perianal area.<sup>54</sup> Patients with giant condyloma present with large cauliflower-like growths (Figures 19-36 and 19-37), which may penetrate into underlying structures such as the urethra or corpora cavernosa. Local compression and destruction of normal structures result. The lack of nerve, blood vessel, and lym-

phatic invasion probably accounts for the rarity of metastases. DNA sequences of HPV-6 and HPV-11 have been isolated from giant condyloma, supporting the contention that HPV is involved in the genesis, and possible malignant transformation, of these lesions.<sup>123,126,127</sup>

When seen in children, condyloma acuminata is considered a risk factor for sexual abuse, with estimates varying from 30% to 80% of cases (Figure 19-38).<sup>128</sup> Pregnancy has a profound influence on the condylomata, with lesions increasing dramatically in size and number. There is a concomitant increase in the amount of viral DNA material from pregnant women compared to nonpregnant women. There is a risk of laryngeal papillomatosis and anogenital condyloma in infants born to mothers with cervical or vulvar condylomata.<sup>122</sup> Condyloma acuminata in children and during pregnancy will not be discussed further in this chapter.

#### Clinical Diagnosis

Clinical examination remains the principal means of diagnosing genital warts. In a sexually active patient with typical condylomata, biopsy with histological examination offers little except reassurance to the patient that the diagnosis is correct. In the following instances though, additional studies

**OK to put on the Web**

**Fig. 19-37.** Massive Buschke-Loewenstein tumor of the vulva. Photograph: Courtesy of Walter Reed Army Medical Center Dermatology Service slide file, Washington, DC.



## OK to put on the Web

**Fig. 19-38.** Extensive condyloma acuminata in a prepubertal female child. This patient was also evaluated for sexual abuse. Photograph: Courtesy of Major J. Rowe, Medical Corps, US Army, Fort Bragg, N.C.

or histological confirmation should be considered:

- Atypical lesions. The condylomata lata of secondary syphilis may clinically resemble genital warts. Condylomata lata (*lata* means “broad” or “flat”) tend to be broad, flat, and more rounded lesions that are covered with a mucoid exudate. Dark-field microscopy, serologic tests, and the presence of other findings of secondary syphilis are helpful in making the proper diagnosis. In some atypical lesions, biopsy may be necessary for confirmation.<sup>123</sup>
- Lesions that may actually be Bowenoid papulosis. Because of the risk of cervical neoplasia in female sexual partners, histological findings consistent with Bowenoid papulosis mandates careful follow-up in this population.
- Unresponsive lesions. Lesions that are unresponsive to treatment may not be condyloma acuminata. For example, melanocytic nevi, seborrheic keratoses, and epidermal nevi have all been mistaken for condylomata. A scissor biopsy performed under local anesthesia quickly resolves the issue.

- Pediatric presentation. When lesions are present in pediatric patients, and when abuse or other medicolegal issues are at issue, tissue can be submitted for histology and, if available, HPV typing.

Immunoperoxidase staining, using antibody against disrupted bovine papillomavirus as the antigen, has been useful for detecting HPV in tissue sections. Methods of DNA hybridization or ribonucleic acid (RNA) hybridization permit typing of HPV samples; utilizing the polymerase chain reaction to amplify the DNA of the HPV that is present greatly improves the sensitivity of the tests.<sup>120</sup>

The virus cannot be cultivated in vitro, and type-specific viral antigens are currently unavailable for the development of serologic tests.<sup>122</sup>

### Treatment

Locally destructive methods (eg, cryosurgery, electrodesiccation, curettage, carbon dioxide–laser vaporization) and application of chemical agents (eg, podophyllin, 5-fluorouracil) are reasonably effective and convenient methods to treat condyloma acuminata. Unfortunately, all suffer from the same shortcomings: frequent recurrence of the lesions and persistence of the virus in otherwise normal-appearing tissue.

Cryosurgery with liquid nitrogen remains a time-honored and effective treatment for smaller lesions. Liquid nitrogen is applied to the wart until the ice ball extends 1 to 2 mm beyond the visible edge of the lesion. The procedure is somewhat uncomfortable for the patient, and blistering and erosions may result. Local anesthesia during the procedure and oral analgesics following cryosurgery may be necessary if extensive treatment is performed. Retreatment may be necessary every week or two until the lesions have completely resolved.<sup>119</sup> Care should be taken not to treat large areas of the glans penis or foreskin at one visit: the resulting edema may cause the patient to be unable to retract the foreskin, which can lead to acute urinary retention.

Electrosurgery and carbon dioxide–laser vaporization are locally destructive procedures that usually require the administration of local anesthesia prior to performing them. Small localized warts (eg, on the penile shaft) are treatable with electrodesiccation. Undertreatment frequently results in recurrence and overtreatment may lead to scarring. Genital warts in other locations and large exophytic lesions are not generally suitable for treatment with this modality.<sup>119</sup> With the carbon dioxide

laser, low-wattage treatment in the vaporization mode is an excellent method of rapidly treating genital warts with minimal risk of scarring. The laser beam destroys infected tissue by evaporation of water. However, recent concerns regarding the presence of viable HPV and other viruses (ie, HIV) in the electrosurgical and laser smoke plumes have dampened enthusiasm for these two modalities.<sup>129</sup>

Isolated lesions can be removed with a sharp curette or by scissor excision under local anesthesia.<sup>123</sup>

Application of 20% podophyllin in benzoin to condylomata results in arrest of cell mitosis and subsequent cell death. Podophyllin is an unstable, crude, plant extract with significant local reactions including irritation, necrosis, scarring, anal fistulae, and phimosis among the reported complications.<sup>121,123</sup>

Early in treatment, the medication is washed off in 3 to 4 hours. With subsequent applications, the time may be extended up to 12 hours as tolerated by the patient.<sup>121</sup> Care should be taken to avoid adjacent normal skin. Severe inflammation and necrosis can occur when podophyllin is applied to condylomata on the coronal rim or sulcus, or on the periurethral area. Other modalities should be used when treating genital warts in these areas, especially in uncircumcised men.

Systemic reactions caused by overzealous or extensive application are rare but have been reported. Under no circumstances should podophyllin be used in pregnant women because of the potential for maternal and fetal toxicity.<sup>121</sup>

Podophyllotoxin 0.5% in ethanol has been approved for home use by patients. The compound is applied twice daily for 3 days each week for up to 6 weeks. A cure rate of 82% was achieved with this regimen. The advantage is that patients can apply the medication at home, reducing the need for frequent office visits and assuring prompt treatment of recurrent lesions.<sup>130</sup>

The drug 5-fluorouracil has been used as a 5% cream in the treatment of warts in the intrameatal portion of the urethra in men. The cream is applied four times daily using an applicator stick, after the bladder has been emptied. A severe inflammatory reaction may develop and this treatment should be undertaken only by medical officers who are experienced in this method. Follow-up urethroscopy is important.<sup>10</sup>

Interferons, both intralesional and parenteral, and systemic retinoids have been used for human papillomavirus infections that are resistant to other forms of therapy. The doses and indications for these drugs can be found elsewhere.<sup>131,132</sup>

## MOLLUSCUM CONTAGIOSUM

Although molluscum contagiosum is not a reportable disease, there is epidemiological evidence that a substantial increase in the number of cases has occurred since the 1970s. The current estimate is that from 2% to 8% of the population is affected by this condition at any time. However, because it is not currently possible to cultivate the molluscum contagiosum virus (MCV) *in vitro*, estimates are based on examination of populations of affected individuals.<sup>133-135</sup> Because MCV is a poxvirus, some researchers<sup>135</sup> have speculated that the cessation of routine vaccinia virus vaccination in the general population in the 1970s may be responsible for the increasing incidence.

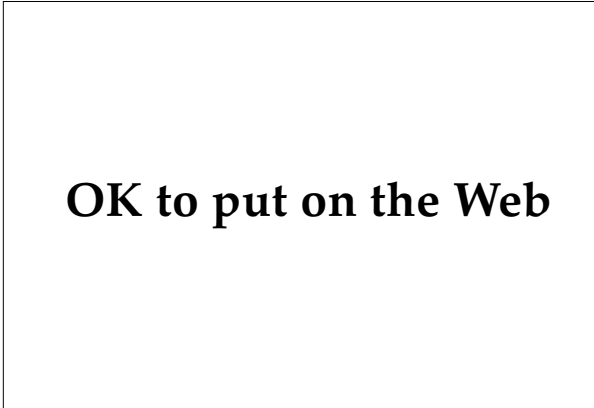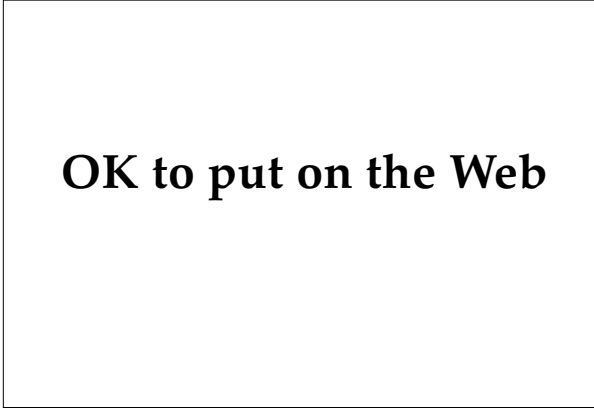MCV is a brick-shaped, DNA-containing poxvirus that morphologically and biochemically resembles other members of the Poxviridae (eg, variola, vaccinia, and cowpox). By analysis of viral DNA sequences, two subtypes have been identified and are designated MCV-1 and MCV-2. However, clinical lesions caused by both subtypes are identical. Studies of virus-host interaction, development of serologic tests, and vaccine production are cur-

rently not possible because researchers have been unable to cultivate the virus *in vitro*.<sup>135</sup> There have been isolated reports of successful propagation of the virus in cell culture.<sup>136,137</sup>

The lesions of molluscum contagiosum occur in two, and perhaps in three, groups. In adults, molluscum contagiosum is usually an STD, with lesions occurring predominately in the genital area (Figure 19-39). In children, lesions are often on exposed surfaces and the face, consistent with transmission by person-to-person contact or possibly by fomites. Recently, a third group of individuals, those with progressive HIV-1 infection, have been described with extensive cutaneous involvement (Figure 19-40).<sup>138</sup> These lesions are particularly refractory to therapy. Additionally, the number of lesions of molluscum contagiosum increase dramatically in these patients with deterioration of their immune status.

### *Clinical Manifestations*

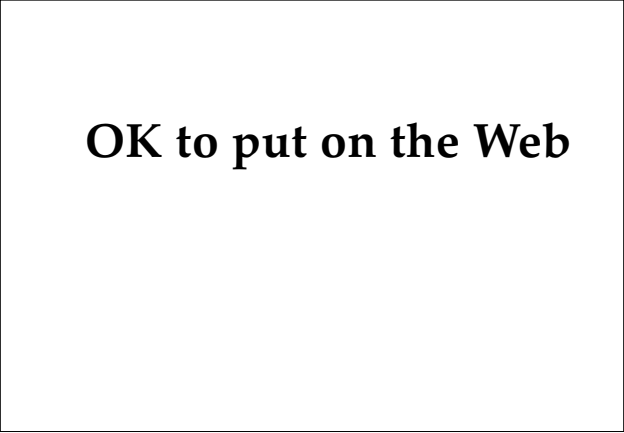Adolescents and adults with molluscum contagi-



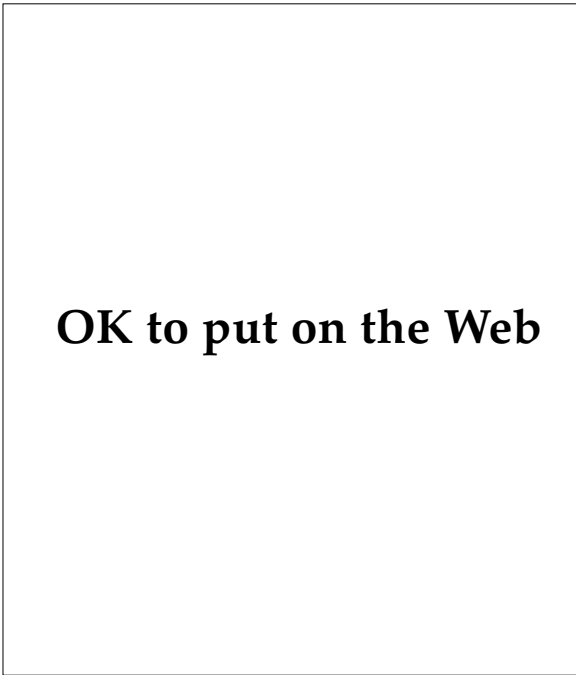
**Fig. 19-39.** (a) The umbilicated skin-colored-to-reddish papules of molluscum contagiosum. (b) Grouped umbilicated papules on the penile shaft. These papules are often confused with the lesions of genital herpes infection unless the contents of the lesions are expressed and examined.

osum present with multiple, firm, 2- to 5-mm, dome-shaped, skin-colored papules that have a central umbilication or “dimple.” Lesions occur most commonly in the inguinal area, buttocks, and inner thighs in both sexes (Figure 19-41).<sup>139</sup> Although most lesions are only a few millimeters in diameter, “giant” molluscum may develop, with lesions approaching 1 cm in diameter (Figure 19-42). In children, lesions are located on exposed surfaces subject to minor trauma—especially the face, trunk, and extremities. Lesions are often grouped, and a linear pattern may develop as a result of scratching. Most cases are asymptomatic; however, a few patients complain of mild pruritus. Lesions may rarely be found on the palms, soles and mucous membranes.<sup>140</sup>

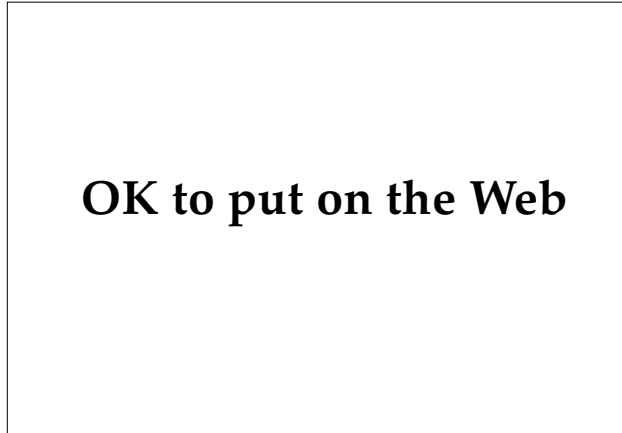
Two groups of patients are at risk to develop extensive molluscum contagiosum: those with atopic dermatitis and those with HIV-1 infection. Patients



**Fig. 19-40.** This patient, who was infected with the human immunodeficiency virus, also had hundreds of papules of molluscum contagiosum on his face. Death occurred within months after the photograph was taken. Photograph: Courtesy of Colonel William D. James, Medical Corps, US Army, Walter Reed Army Medical Center, Washington, DC.



**Fig. 19-41.** Extensive involvement with molluscum contagiosum over the buttocks and thighs in an adult. Patients who present with molluscum in this distribution should be carefully examined for other sexually transmitted diseases.

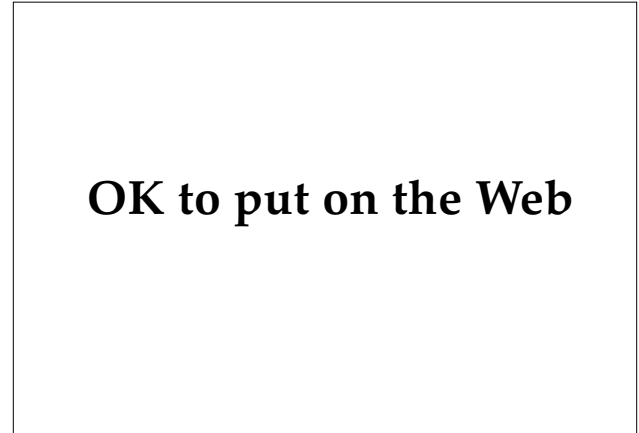


**Fig. 19-42.** Solitary “giant” molluscum on the penile shaft. Biopsy confirmed the diagnosis. Lesions of this size are often mistaken for cysts or tumors.

with atopic dermatitis often develop numerous lesions in areas of active eczematous dermatitis, especially the flexural folds. The reasons given for the widespread lesions include autoinoculation from scratching, use of topical steroids, and impaired cellular immune response.<sup>141,142</sup> Patients with HIV-1 infection can have dozens or even hundreds of lesions, primarily on the face and trunk instead of the inguinal area. As noted previously, a dramatic increase in the number of lesions corresponds to the progressive deterioration of immune function.<sup>143</sup> Patients with sarcoidosis and those receiving chemotherapy or corticosteroids have also been reported to develop extensive molluscum contagiosum.<sup>138</sup>

### Complications

Surprisingly few complications arise from infections with molluscum contagiosum. Two will be considered here—molluscum dermatitis and secondary bacterial infection—as well as the occurrence of molluscum lesions in the genital area of children, which raises the suspicion of child abuse. In about 10% of patients, a sharply demarcated, annular, eczematous dermatitis develops around individual lesions of molluscum contagiosum (Figure 19-43). A few, some, or all of the lesions may be involved, and the dermatitis resolves with disappearance of the molluscum contagiosum papule.<sup>144</sup> Lesions located on the eyelid or conjunctivae are also occasionally involved in molluscum dermatitis, and conjunctivitis or keratitis may develop.<sup>145</sup> Secondary bacterial infection with cellulitis may also occur.



**Fig. 19-43.** This peripheral erythema and crusting is typical of a lesion of molluscum dermatitis.

Regarding genital molluscum contagiosum in infants and children, there is considerable controversy over (a) how often the lesions are transmitted by sexual abuse and (b) when to refer families to social services for investigation. More than 90% of lesions of molluscum contagiosum in children are found on the trunk, axillae, and extremities. Therefore, lesions in the genital area are uncommon and should raise the suspicion of sexual abuse. On the other hand, the CDC opinion<sup>25</sup> is that molluscum contagiosum in infants and children is most frequently caused by nonsexual means of transmission. Several authorities recommend that a child who has genital molluscum alone should be viewed with increased suspicion of sexual abuse.<sup>140,146</sup>

### Diagnosis

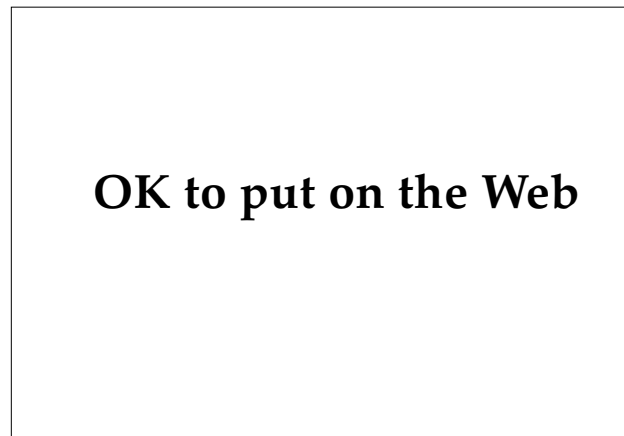Diagnosis is principally on clinical grounds alone, as the appearance of the smooth, dome-shaped, umbilicated papules is characteristic. When doubt exists, a lesion may be curetted or incised and the whitish central core crushed between two glass microscope slides. It can then be stained with methylene blue or Wright-Giemsa stain and examined microscopically. The large, oval, dense, staining bodies known as molluscum bodies are keratinocytes filled with viral particles.<sup>54</sup> With atypical lesions, or in individuals who are infected with HIV, a shave or punch biopsy of a papule may be necessary to confirm the diagnosis. (Recent reports of the lesions of disseminated cryptococcal infection mimicking molluscum contagiosum in patients

infected with HIV lends support to the recommendation for biopsy confirmation in this population.<sup>147</sup>) Sections of hematoxylin-eosin–stained tissue show numerous intracytoplasmic inclusion bodies, which form in the lower epidermis; these large, basophilic molluscum bodies measure up to 35 µm in diameter (Figure 19-44). Disintegration of the stratum corneum in the center of the lesion leads to the development of the central crater.<sup>54</sup>

As noted above, serologic tests or viral cultures are not available.

### Treatment

Numerous modalities have been successful in the treatment of molluscum contagiosum. The disease is self-limited and asymptomatic, and in some instances, such as with very young children, it may be appropriate simply to observe the lesions. However, since autoinoculation and spread to other persons is frequent, it is advisable to initiate treatment. Curettage with a sharp curette, light electrodesiccation, light liquid nitrogen spray, or topical application of 50% trichloroacetic acid are all simple to perform and are nonscarring. Slight



**Fig. 19-44.** This histological section (medium-power view) shows large keratinocytes filled with molluscum virus.

incision of the lesion with expression of the central core is also curative. Other suggested modalities have included topical retinoic acid or griseofulvin.<sup>86</sup> In the case of adolescents and adults with lesions in the genital area, it is important to look for other STDs, as they may also be present.

### SUMMARY

STDs present formidable diagnostic and therapeutic challenges for the field medical officer. The classic STDs discussed in this chapter can, with reasonable care and a well-equipped laboratory and pharmacy, be properly diagnosed and treated. It is imperative, however, that the clinician be familiar with the subtle variations in clinical presentation, subclinical disease, and the ever-changing patterns of antibiotic sensitivity. Likewise, a par-

ticular STD is not acquired in a vacuum. The general medical officer evaluating a soldier with molluscum contagiosum or genital warts must remember that the patient may also be incubating syphilis or may be an asymptomatic carrier of gonorrhea, chlamydia, or HIV infection. A careful and thoughtful approach to the evaluation of the patient with an STD will ensure that both the patient and his or her sexual contacts will be well served.

### REFERENCES

1. Eichmann AR. Sexually transmitted diseases. In: Fitzpatrick TB, Eisen AZ, Wolff K, Freedberg IM, Austen KF, eds. *Dermatology in General Medicine*. 4th ed, Vol 2. New York, NY: McGraw-Hill, Inc; 1993: Chap 217: 2699–2702.
2. Handsfield HH. The clinical approach to genital ulcer disease. *STD 2000*. 1994;1(1):3–5.
3. Deller JJ, Smith DE, English DT, Southwick EG. Venereal diseases. In: Ognibene AJ, Barrett O Jr, eds. *General Medicine and Infectious Diseases*. In: Ognibene AJ, ed. *Internal Medicine in Vietnam*. Vol 2. Washington, DC: Medical Department, US Army, Office of The Surgeon General, and Center of Military History; 1982: 233–255.
4. Padget P. Diagnosis and treatment of the venereal diseases. In: Havens WP Jr, ed. *Infectious Diseases*. In: Coates JB Jr, ed. *Internal Medicine in World War II*. Vol 2. Washington, DC: Medical Department, US Army, Office of The Surgeon General; 1963: 409–435.

5. Sparling PF. Natural history of syphilis. In: Holmes II, Mårdh P-A, Sparling PF, et al, eds. *Sexually Transmitted Diseases*. New York: McGraw-Hill; 1990: 213–219.
6. Luger A. The origin of syphilis. Clinical and epidemiologic considerations on the Columbian theory. *Sex Transm Diseases*. 1993;20:110–117.
7. Hudson EH. Treponematoses and African slavery. *Br J Vener Dis*. 1963;40:43–52.
8. Hollander DH. Treponematosis from pinta to venereal syphilis revisited: Hypothesis for temperature determination of disease patterns. *Sex Transm Dis*. 1981;8:34–37.
9. Joklik WK, Willett HP, Amos DB, Wilfert CM, eds. The spirochetes. In: *Zinsser Microbiology*. 19th ed. Norwalk, Conn: Appleton and Lange; 1988: 384–392, 555–562.
10. Robertson DH, McMillan A, Young H. *Clinical Practice in Sexually Transmitted Diseases*. 2nd ed. Edinburgh, Scotland: Churchill-Livingstone; 1989: 110–111, 435–438, 446–450.
11. Hutchinson CM, Hook EW. Syphilis in adults. *Med Clin N Am*. 1990;74(6):1389–1416.
12. Rolfs RT, Nakashima AK. Epidemiology of primary and secondary syphilis in the United States, 1981 through 1989. *JAMA*. 1990;264(11):1432–1437.
13. Hicks CB, Benson PM, Lupton GP, Tramont EC. Seronegative secondary syphilis in a patient infected with the human immunodeficiency virus (HIV) with Kaposi sarcoma. *Ann Intern Med*. 1987;107:492–495.
14. Centers for Disease Control. *AIDS Recommendations and Guidelines*. Publication 00-5399. Atlanta, Ga: CDC; 1988: 103.
15. Tramont EC. Treatment of syphilis in the AIDS era. *N Engl J Med*. 1987;316:1600–1601.
16. Schulz KF, Murphy FK, Patamasucon P, Meheus AZ. Congenital syphilis. In: Holmes II, Mårdh P-A, Sparling PF, et al, eds. *Sexually Transmitted Diseases*. New York: McGraw-Hill; 1990: 821–842.
17. Wendel GD. Early and congenital syphilis. *Ob Gyn Clin N Am*. 1990;16(3):479–494.
18. Greenblatt RM, Lukehart SA, Plummer FA, Quinn TC. Genital ulcerations as a risk factor for human immunodeficiency virus. *AIDS*. 1988;2:47–50.
19. Stamm WE, Handsfield HH, Rompalo AM, Ashley RL, Roberts PL, Corey L. The association between genital ulcer disease and acquisition of HIV infection in homosexual men. *JAMA*. 1988;260:1429–1433.
20. Zenker P. New case definition for congenital syphilis reporting. *Sex Transm Dis*. 1991;18:44–45.
21. Schroeter AL, Turner RH, Lucas JB, Brown WJ. Therapy for incubating syphilis. *JAMA*. 1971;218:711–713.
22. Shoher PC, Gabriel G, White P, Felton WF, Thin RN. How infectious is syphilis? *Br J Vener Dis*. 1983;59:217–219.
23. Bingham JS. Syphilis. In: Adler MW. *Diseases in the Homosexual Male*. London, England: Springer-Verlag; 1988: 111–128.
24. Magnuson HJ, Thomas EW, Olansky S, Kaplan BI, Mello L, Cutler JC. Inoculation syphilis in human volunteers. *Medicine*. 1956;35:33–82.
25. Centers for Disease Control and Prevention. 1993 Sexually transmitted diseases treatment guidelines. *MMWR*. 1993;42:RR-14.
26. Berry CD, Hooton TM, Collier AC, Lukehart SA. Neurologic relapse after benzathine penicillin therapy for secondary syphilis in a patient with HIV infection. *N Engl J Med*. 1987;316:1587–1589.

27. Lukehart SA, Hook EW, Baker-Zander SA, Collier AC, Critchlow CW, Handsfield HH. Invasion of the central nervous system by *Treponema pallidum*: Implications for diagnosis and treatment. *Ann Intern Med*. 1988;109:855–862.
28. Rhodes AR, Luger AFH. Syphilis and other treponematoses. In: Fitzpatrick TB, Eisen AZ, Wolff K, Freedberg IM, Austen KF, eds. *Dermatology in General Medicine*. 3rd ed. New York, NY: McGraw-Hill; 1987: 2395–2452.
29. Notowicz A, Menke HE. Atypical primary syphilitic lesions on the penis. *Dermatologica*. 1973;147:328–333.
30. Chapel TA. The signs and symptoms of secondary syphilis. *Sex Transm Dis*. 1980;7:161–164.
31. Rudolph AH. Syphilis. In: Demis DJ, ed. *Clinical Dermatology*. 17th rev ed, Vol 3. Philadelphia, Pa: JB Lippincott; 1990: Unit 16-22: 1–36.
32. Clark EG, Danbolt N. The Oslo study of untreated syphilis: An epidemiologic investigation based on a restudy of the Boeck-Bruusgaard material. *J Chronic Dis*. 1955;2:311–344.
33. Johns DR, Tierney M, Felsenstein D. Alteration in the natural history of neurosyphilis by concurrent infection with the human immunodeficiency virus. *N Engl J Med*. 1987;316:1569–1572.
34. Fieldsteel AH, Cox DL, Moeckli RA. Cultivation of virulent *Treponema pallidum* in tissue culture. *Infect Immun*. 1981;32:908–915.
35. Centers for Disease Control. Darkfield microscopy for the detection and identification of *Treponema pallidum*. HEW Publication (CDC) 79-8224. Atlanta, Ga: 1979.
36. Larsen SA, Hunter EF, Creighton ET. Syphilis. In: Holmes II, Mardh P-A, Sparling PF, et al, eds. *Sexually Transmitted Diseases*. New York: McGraw-Hill; 1990: 927–934.
37. Hook EW, Roddy RE, Lukehart SA, Hom J, Holmes KK, Tam MR. Detection of *Treponema pallidum* in lesion exudate with a pathogen-specific monoclonal antibody. *J Clin Microbiol*. 1985;22:241–244.
38. Lukehart SA, Baker-Zander SA. Diagnostic potential of monoclonal antibodies against *Treponema pallidum*. In: Young H, McMillan A, eds. *Immunological Diagnosis of Sexually Transmitted Diseases*. New York, NY: Marcel Dekker; 1988: 213–247.
39. Luger AFH. Serological diagnosis of syphilis: Current methods. In: Young H, McMillan A, eds. *Immunological Diagnosis of Sexually Transmitted Diseases*. New York, NY: Marcel Dekker; 1988: 249–274.
40. Smart C. Medical history. In: *The Medical and Surgical History of the War of the Rebellion*. Part 3, Vol 1. Washington, DC: Government Printing Office; 1888: 891–896.
41. STD Surveillance Department Desk Officer. Centers for Disease Control and Prevention, Atlanta, Ga. Telephone communication, February 1994.
42. Young H, and Reid KG. Immunological diagnosis of gonococcal infection. In: Young H, McMillan A, eds. *Immunological Diagnosis of Sexually Transmitted Diseases*. New York, NY: Marcel Dekker; 1988: 77–116.
43. Holmes KK, Johnson DW, Trostle HJ. An estimate of the risk of men acquiring gonorrhea by sexual contact with infected females. *Am J Epidemiol*. 1970;91:170–174.
44. Feingold DA. Gonorrhea. In: Fitzpatrick TB, Eisen AZ, Wolff K, Freedberg IM, Austen KF, eds. *Dermatology in General Medicine*. 3rd ed. New York, NY: McGraw-Hill; 1987: 2463–2467.
45. Hook EW, Handsfield HH. Gonococcal infections in the adult. In: Holmes II, Mardh P-A, Sparling PF, et al, eds. *Sexually Transmitted Diseases*. New York: McGraw-Hill; 1990: 149–165.

46. Judson FN, Wright RA, Mann EA. Recent micturition does not affect the detection of urethral gonorrhoea. *Br J Vener Dis*. 1977;53:308–310.
47. Apicella MA. Gonorrhoea. In: Sun T, ed. *Sexually Related Infectious Diseases: Clinical and Laboratory Aspects*. Chicago, Ill: Year Book Medical Publishers; 1986: 43–51.
48. Handsfield HH, Lipman TX, Harnisch JP, Tronca E, Holmes KK. Asymptomatic gonorrhoea in men. *N Engl J Med*. 1974;290:117–123.
49. McNeeley SG. Gonococcal infections in women. *Ob Gyn Clin N Am*. 1989;16(3):467–478.
50. Judson FN. Gonorrhoea. *Med Clin N Am*. 1990;74(6):1353–1366.
51. Vazquez F, Palacio V, Vazquez J, Berron S, Gonzalez A, Llanaez JJ. Gonorrhoea in women prostitutes. *Sex Transm Dis*. 1991;18:5–9.
52. Alexander WJ, Griffith H, Housch G, Holmes JR. Infections in sexual contacts and associates of children with gonorrhoea. *Sex Transm Dis*. 1984;11:156–158.
53. Sgroi SM. Pediatric gonorrhoea and child sexual abuse: The venereal disease connection. *Sex Transm Dis*. 1982;9:154–156.
54. Lever WR, Schaumburg-Lever G, eds. Bacterial disease. In: *Histopathology of the Skin*. Philadelphia, Penn: JB Lippincott; 1990: 325, 344–345, 409–410, 417.
55. Jawetz E, Melnick JL, Adelberg EA, Brooks GF, Butel JS, Ornston LN, eds. *Medical Microbiology*. 18th ed. Norwalk, Conn: Appleton and Lange; 1989.
56. Martin JF, Lester A, Price EV, Schmale JD. Comparative study of gonococcal susceptibility to penicillin in the United States, 1955–1969. *J Infect Dis*. 1970;122:459–461.
57. Elwell LP, Roberts M, Mayer LW, Falkow S. Plasmid-mediated beta-lactamase production in *Neisseria gonorrhoeae*. *Antimicrob Agents Chemother*. 1977;11:528–533.
58. Judson FN, Eron LJ, Lutz FB, Rand KH, Tennican PO, Mogabgab WJ. Multicenter study of a single 500-mg dose of cefotaxime for treatment of uncomplicated gonorrhoea. *Sex Transm Dis*. 1991;18:41–43.
59. Knapp JS, Zenilman JM, Biddle JW, et al. Frequency and distribution in the United States of strains of *Neisseria gonorrhoeae* with plasmid-mediated high-level resistance to tetracycline. *J Infect Dis*. 1987;155:819–822.
60. Expert Committee on Pelvic Inflammatory Disease. Pelvic inflammatory disease. *Sex Transm Dis*. 1991;18:46–64.
61. Moran JS, Zeligman JM. Therapy for gonococcal infections: Options in 1989. *Rev Infect Dis*. 1990;12(Suppl 6):S633–S644.
62. Asin J. Chancroid: A report of 1,402 cases. *Am J Syphilis, Gonorrhoea, and Vener Dis*. 1952;36:483–487.
63. Kerber RE, Rowe CE, Gilbert KR. Treatment of chancroid: A comparison of tetracycline and sulfisoxazole. *Arch Dermatol*. 1969;100:604–607.
64. Blackmore CA, Limpakarnjanarat K, Rigau-Perez JG, Albritton WL, Greenwood JR. An outbreak of chancroid in Orange County California: Descriptive epidemiology and disease-control measures. *J Infect Dis*. 1985;151:840–844.
65. Jessamine PG, Ronald AR. Chancroid and the role of genital ulcer disease in the spread of human retroviruses. *Med Clin N Am*. 1990;74(6):1417–1431.



66. Kreiss JK, Coombs R, Plummer F, et al. Isolation of human immunodeficiency virus from genital ulcers in Nairobi prostitutes. *J Infect Dis.* 1989;160(3):380–384.
67. Plummer FA, Wainberg MA, Plourde P, et al. Detection of human immunodeficiency virus Type 1 (HIV-1) in genital ulcer exudate of HIV-1-infected men by culture and gene amplification. *J Infect Dis.* 1990;161:810–811.
68. Bongaarts J, Reining P, Way P, Conant F. The relationship between male circumcision and HIV infection. *AIDS.* 1989;3:373–377.
69. Ronald AR, Plummer FA. Chancroid and *Hemophilus ducreyi*. *Ann Intern Med.* 1985;102:705–707.
70. Ronald AR, Albritton W. Chancroid and *Hemophilus ducreyi*. In: Holmes II, Mårdh P-A, Sparling PF, et al, eds. *Sexually Transmitted Diseases*. New York: McGraw-Hill; 1990: 263–271.
71. Fung JC. Chancroid (*Hemophilus ducreyi*). In: Sun T, ed. *Sexually Related Infectious Diseases: Clinical and Laboratory Aspects*. Chicago, Ill: Year Book Medical Publishers; 1986: 53–57.
72. Rudolph AH. Chancroid. In: Fitzpatrick TB, Eisen AZ, Wolff K, Freedberg IM, Austen KF, eds. *Dermatology in General Medicine*. 3rd ed. New York, NY: McGraw-Hill; 1987: 2452–2457.
73. Easmon CS, Ison CA. Miscellaneous infections. Current status and future prospects of immunological diagnosis. In: Young H, McMillan A, eds. *Immunological Diagnosis of Sexually Transmitted Diseases*. New York, NY: Marcel Dekker; 1988: 499–516.
74. Hansen EJ, Loftus TA. Monoclonal antibodies reactive with all strains of *Hemophilus ducreyi*. *Infect Immun.* 1984;44:196–198.
75. Museyi K, Van Dyck E, Vervoort T, Taylor D, Hoge C, Piot P. Use of an enzyme immunoassay to detect serum IgG antibodies to *Hemophilus ducreyi*. *J Infect Dis.* 1988;157:1039–1043.
76. Donovan C. Medical cases from Madras General Hospital. *Indian Medical Gazette.* 1905;40:411–414.
77. Faro S. Lymphogranuloma venereum, chancroid, and granuloma inguinale. *Ob Gyn Clin N Am.* 1989;16(3):517–530.
78. Goldberg J. Studies on granuloma inguinale. Part 7. Some epidemiologic considerations of the disease. *Br J Vener Dis.* 1964;40:140–145.
79. Goldberg J. Studies on granuloma inguinale. Part 5. Isolation of a bacterium resembling *Donovania granulomatis* from the faeces of a patient with granuloma inguinale. *Br J Vener Dis.* 1962;38:99–102.
80. Fritz GS, Dodson RF, Rudolph A. Mutilating granuloma inguinale. *Arch Dermatol.* 1975;111:1464–1465.
81. Hart G. Donovanosis. In: Holmes II, Mårdh P-A, Sparling PF, et al, eds. *Sexually Transmitted Diseases*. New York: McGraw-Hill; 1990: 273–277.
82. Rothenberg RB. Granuloma inguinale. In: Fitzpatrick TB, Eisen AZ, Wolff K, Freedberg IM, Austen KF, eds. *Dermatology in General Medicine*. 3rd ed. New York, NY: McGraw-Hill; 1987: 2460–2462.
83. Remigio PA. Granuloma inguinale. In: Sun T, ed. *Sexually Related Infectious Diseases: Clinical and Laboratory Aspects*. Chicago, Ill: Year Book Medical Publishers; 1986: 59–64.
84. Sehgal VN, Shyamprasad AL, Beohar PC. The histopathological diagnosis of donovanosis. *Br J Vener Dis.* 1984;60(1):45–47.
85. Richens J. The diagnosis and treatment of donovanosis (granuloma inguinale). *Genitourin Med.* 1991;67:441–452.
86. Arnold HL, Odom RB, James WD, eds. Bacterial infections. In: *Andrews Diseases of the Skin*. 8th ed. Philadelphia, Pa: WB Saunders; 1990: 293–294, 312–314, 409–410.

87. Schachter J. Chlamydial infections. Part 1. *N Engl J Med*. 1978;298:428–434.
88. Perine PL, Osoba AO. Lymphogranuloma venereum. In: Holmes II, Mårdh P-A, Sparling PF, et al, eds. *Sexually Transmitted Diseases*. New York: McGraw-Hill; 1990: 195–204.
89. Abrams AJ. Lymphogranuloma venereum. *JAMA*. 1968;205(4):199–202.
90. Becker L. Lymphogranuloma venereum. *Int J Derm*. 1976;15:26–33.
91. Meheus A, Van Dyck E, Ursi JP, Ballard RC, Piot P. Etiology of genital ulcers in Swaziland. *Sex Transm Dis*. 1983;10:33–35.
92. McLelland BA, Anderson PC. Lymphogranuloma venereum: Outbreak in a university community. *JAMA*. 1976;235:56–57.
93. Wang S, Grayston JT. Immunologic relationship between genital TRIC, lymphogranuloma venereum, and related organisms in a new microtiter indirect immunofluorescence test. *Am J Ophthalmol*. 1970;70:367–374.
94. Fiumara NJ. Lymphogranuloma venereum. In: Demis DJ, ed. *Clinical Dermatology*. Vol 3. Philadelphia, Pa: JB Lippincott; 1990: Unit 16-20: 6–8.
95. Heaton S, Hammerschlag MR, Roblin PM, DiPasquale RC. Lymphogranuloma venereum in a pregnant woman. *Sex Transm Dis*. 1988;15:148–149.
96. Schachter J. Chlamydial infections. Part 2. *N Engl J Med*. 1978;298:490–495.
97. Marlowe SI. Medical management of genital herpes. Editorial. *Arch Dermatol*. 1985;121:467–470.
98. Corey L, Holmes KK. Genital herpes simplex infections: Current concepts in diagnosis, therapy and prevention. *Ann Int Med*. 1983;98:973–983.
99. Mertz GJ. Genital herpes simplex virus infections. *Med Clin N Am*. 1990;74(6):1433–1454.
100. Holmberg SD, Stewart JA, Gerber LAR, et al. Prior herpes simplex type 2 as a risk factor for HIV infection. *JAMA*. 1988;259:1048–1050.
101. Raab B, Lorincz AL. Genital herpes simplex—concepts and treatment. *J Am Acad Dermatol*. 1981;5:249–263.
102. Corey L, Adams HG, Brown ZA, Holmes KK. Genital herpes simplex virus infections: Clinical manifestations, course and complications. *Ann Int Med*. 1983;98:958–972.
103. Quinn TC, Stamm WE, Goodell SE, et al. The polymicrobial origin of intestinal infections in homosexual men. *N Engl J Med*. 1983;309:576–582.
104. Gateley A, Gander RM, Johnson PC, Kit S, Otsuka H, Kohl S. Herpes simplex virus type 2 meningoencephalitis resistant to acyclovir in a patient with AIDS. *J Infect Dis*. 1990;161:711–715.
105. Joseph TJ, Vogt PJ. Disseminated herpes with hepatoadrenal necrosis in an adult. *Am J Med*. 1974;56:735–739.
106. Bernstein DI, Lovett MA, Bryson YJ. Serologic analysis of first-episode nonprimary genital herpes simplex infection: Presence of type 2 antibody in acute serum samples. *Am J Med*. 1984;77:1055–1060.
107. Brown ZA, Kern ER, Spruance SL, Overall JC. Clinical and virologic course of herpes simplex genitalis. *West J Med*. 1979;130:414–421.
108. Leigh IM. Management of non-genital herpes simplex virus infections in immunocompetent patients. *Am J Med*. 1988;85(Suppl 2A):34–38.

109. Smith I W, Peutherer JF. Immunological diagnosis of herpes simplex virus. In: Young H, McMillan A, eds. *Immunological Diagnosis of Sexually Transmitted Diseases*. New York, NY: Marcel Dekker; 1988: 371–401.
110. Fife KH, Corey L. Herpes simplex virus. In: Holmes II, Mårdh P-A, Sparling PF, et al, eds. *Sexually Transmitted Diseases*. New York: McGraw-Hill; 1990: 941–952.
111. Moseley RC, Corey L, Benjamin D, Winter C, Remington ML. Comparison of viral isolation, direct immunofluorescence, and indirect immunoperoxidase techniques for detection of genital herpes simplex virus infection. *J Clin Microbiol*. 1981;13:913–918.
112. Stone KM, Whittington W. Treatment of genital herpes. *Rev Infect Dis*. 1990;12(Suppl 6):S610–S619.
113. Saral R. Management of mucocutaneous herpes simplex virus infections in immunocompromised patients. *Am J Med*. 1988;85(Suppl 2A):57–60.
114. Mertz GL, Critchlow CW, Benedetti J, et al. Double-blind placebo-controlled trial of oral acyclovir in first-episode genital herpes simplex virus infection. *JAMA*. 1984;252(9):1147–1151.
115. Corey L. Genital herpes. In: Holmes II, Mårdh P-A, Sparling PF, et al, eds. *Sexually Transmitted Diseases*. New York: McGraw-Hill; 1990: 391–413.
116. Spruance SL, Stewart JCB, Rowe NH, McKeough MB, Wenerstrom G, Freeman DJ. Treatment of recurrent herpes simplex labialis with oral acyclovir. *J Infect Dis*. 1990;161:185–190.
117. Landy JL, Grossman JH. Herpes simplex virus. *Ob Gyn Clin N Am*. 1989;16(3):495–515.
118. Shepp DH, Newton BA, Dandliker PS, Flournoy N, Meyers JD. Oral acyclovir therapy for mucocutaneous herpes simplex virus infections in immunocompromised marrow transplant recipients. *Ann Int Med*. 1985;102:783–785.
119. Oriel JD. Genital warts. In: Adler MW. *Diseases in the Homosexual Male*. London, England: Springer-Verlag; 1988: 99–109.
120. Cobb MW. Human papillomavirus infection. *J Am Acad Dermatol*. 1990;22(4):547–563.
121. Brown DR, Fife KH. Human papillomavirus infections of the genital tract. *Med Clin N Am*. 1990;74(6):1455–1485.
122. Koutsky LA, Wolner-Hanssen P. Genital papillomavirus infections: Current knowledge and future prospects. *Ob Gyn Clin N Am*. 1989;16(3):541–564.
123. Oriel JD. Genital human papillomavirus infection. In: Holmes II, Mårdh P-A, Sparling PF, et al, eds. *Sexually Transmitted Diseases*. New York: McGraw-Hill; 1990: 433–441.
124. Devillez RL, Stevens CS. Bowenoid papules of the genitalia. *J Am Acad Dermatol*. 1980;3:149–152.
125. Ananthakrishnan N, Ravindran R, Veliath AJ, Parkash S. Loewenstein-Buschke tumour of penis—A carcinomimic. *Br J Urol*. 1981;53:460–465.
126. Gissman L, DeVilliers E-M, Zur Hausen H. Analysis of human genital warts (condylomata acuminata) and other genital tumours for human papillomavirus type 6 DNA. *Int J Cancer*. 1982;29:143–146.
127. South LM, O’Sullivan JP, Gazet JC. Giant condyloma of Buschke and Loewenstein. *Clin Oncol*. 1977;3:107–115.
128. DeJong AR, Emmett GA, Hervada AR. Sexual abuse of children: Sex-, race-, and age-dependent variations. *Am J Dis Child*. 1982;136(2):129–134.
129. Sawchuk WS, Weber PJ, Lowy DR, Dzubow LM. Infectious papillomavirus in the vapor of warts treated with carbon dioxide laser or electrocoagulation: Detection and protection. *J Am Acad Dermatol*. 1989;21(1):41–49.

130. Beutner KR, Conant MA, Friedman-Kien AE, Illeman M, Thisted RA, King DH. Patient-applied podofilox for treatment of genital warts. *Lancet*. 1989;1:831–834.
131. Gross G, Roussaki A, Schopf E, De Villiers EM, Papendick U. Successful treatment of condylomata acuminata and Bowenoid papulosis with subcutaneous injections of low-dose recombinant interferon-alpha. *Arch Dermatol*. 1986;122(7):749–750.
132. Lutzner MA, Blanchet-Bardon C. Oral retinoid treatment of human papillomavirus type 5-induced epidermodysplasia verruciformis. Correspondence. *N Engl J Med*. 1980;302:1091–1092.
133. Becker TM, Blount JH, Douglas J, Judson FN. Trends in molluscum contagiosum in the United States, 1966–1983. *Sex Transm Dis*. 1986;13:88–92.
134. Oriel JD. The increase in molluscum contagiosum. *Br Med J*. 1987;294:74.
135. Billstein SA, Mattaliano VJ. The “nuisance” sexually transmitted diseases: Molluscum contagiosum, scabies, and crab lice. *Med Clin N Am*. 1990;74(6):1487–1515.
136. Francis RD, Bradford HB. Some biological and physical properties of molluscum contagiosum virus propagated in cell culture. *J Virol*. 1976;19:382–388.
137. McFadden G, Pace WE, Purres J, Dales S. Biogenesis of poxviruses: Transitory expression of molluscum contagiosum early functions. *Virol*. 1979;94:297–313.
138. Katzman M, Carey JT, Elmets CA, Jacobs GH, Lederman MM. Molluscum contagiosum and the acquired immunodeficiency syndrome: Clinical and immunological details of two cases. *Br J Dermatol*. 1987;116:131–138.
139. Lynch PJ, Minkin W. Molluscum contagiosum of the adult. *Arch Dermatol*. 1969;98:141–143.
140. Brown ST, Nalley JF, Kraus SJ. Molluscum contagiosum. *Sex Transm Dis*. 1981;8:227–234.
141. Solomon LM, Telner P. Eruptive molluscum contagiosum in atopic dermatitis. *Can Med Assoc J*. 1966;95:978–979.
142. Pauly CR, Artis WM, Jones HE. Atopic dermatitis, impaired cellular immunity and molluscum contagiosum. *Arch Dermatol*. 1978;114:391–393.
143. Redfield RR, James WD, Wright DC, et al. Severe molluscum contagiosum infection in a patient with human T-cell lymphotropic (HTLV-III) disease. *J Am Acad Dermatol*. 1985;13:821–823.
144. Douglas JM. Molluscum contagiosum. In: Holmes II, Mårdh P-A, Sparling PF, et al, eds. *Sexually Transmitted Diseases*. New York: McGraw-Hill; 1990: 443–447.
145. Kipping HF. Molluscum dermatitis. Correspondence. *Arch Dermatol*. 1971;103:106–107.
146. Schachner L, Hankin D. Is genital molluscum contagiosum a cutaneous manifestation of sexual abuse in children? Correspondence. *J Am Acad Dermatol*. 1986;14(5):848–849.
147. Rico MJ, Penneys NS. Cutaneous cryptococcosis resembling molluscum contagiosum in a patient with AIDS. *Arch Dermatol*. 1985;121:901–902.

# Chapter 20

## COMMON SKIN DISEASES

PETER E. O'NEILL, M.D.\*

---

### INTRODUCTION

#### PSORIASIS

- Clinical Features
- Types of Psoriasis
- Diagnosis
- Treatment
- Military Considerations

#### LICHEN PLANUS

- Clinical Features
- Pathogenesis
- Diagnosis
- Treatment
- Military Considerations

#### ATOPIC DERMATITIS

- Clinical Features
- Natural Course
- Complications
- Diagnosis
- Treatment
- Military Considerations

#### URTICARIA

- Clinical Features
- Types of Urticaria
- Diagnosis
- Treatment
- Military Considerations

#### PSEUDOFOLLICULITIS BARBAE

- Clinical Features
- Pathogenesis
- Diagnosis
- Treatment
- Military Considerations

#### CUTANEOUS VIRAL INFECTIONS

- Herpes Simplex Labialis
- Herpes Zoster
- Molluscum Contagiosum
- Warts
- Military Considerations

### SUMMARY

\*3 Claydon Road, Garden City, New York 11530; Assistant Clinical Professor, State University of New York at Stony Brook, Stony Brook, New York; formerly, Major, Medical Corps, U.S. Air Force; Dermatology Service, Wilford Hall U.S. Air Force Medical Center, Lackland Air Force Base, Texas 78236

INTRODUCTION

Although common dermatoses are not generally considered to pose a significant threat to the health of an individual, they can become a major problem for an entire armed force. In harsh environments, such as one would encounter on a field of battle, these minor afflictions can become incapacitating, thus rendering an individual unfit for duty. In a large unit, this collective loss of fighting force could seriously impair the effectiveness of the unit as a whole. During the Vietnam conflict, dermatoses were the third-highest cause of hospital admissions for disease, and outpatient dermatology visits were double the number required for any other condition.<sup>1,2</sup> Clearly, skin diseases can have a staggering impact on military operations.

**TABLE 20-1**  
**MOST COMMON DIAGNOSES IN NEW PATIENTS SEEN AT DERMATOLOGY CLINIC, 17TH FIELD HOSPITAL, SAIGON, VIETNAM, JULY 1967 (% of total shown)**

Diagnosis	No. of Cases	(%)
Pyoderma	47	(10.0)
Miliaria	43	(9.2)
Tinea	43	(9.2)
Verrucae	37	(7.9)
Eczematous dermatitis	26	(5.6)
Candidiasis	22	(4.7)
Infected eczematous dermatitis	20	(4.3)
Acne	18	(3.8)
Tinea versicolor	15	(3.2)
Urticaria	13	(2.8)
Contact dermatitis	11	(2.3)
Plantar warts	11	(2.3)
Alopecia areata	10	(2.1)
Pseudofolliculitis barbae	9	(1.9)
Psoriasis	7	(1.5)
Others	137	(29.2)
Total	469	(100.0)

Adapted from Allen AM. *Skin Diseases in Vietnam, 1965-72*. In: Ognibene AJ, ed. *Internal Medicine in Vietnam*. Vol 1. Washington, DC: Medical Department, US Army, Office of The Surgeon General and Center of Military History; 1977: 38.

**TABLE 20-2**  
**PROPORTIONATE DISTRIBUTION OF SKIN DISEASES SEEN IN U.S. DERMATOLOGY CLINIC, 95TH EVACUATION HOSPITAL, DANANG, VIETNAM, 15 MAY 1970 TO 31 JULY 1971 (14.5 MONTHS) (% of total shown)**

Disease	No. of Cases	(%)
Verrucae, all types	729	(15.83)
Acne, all types	466	(10.12)
Dermatophytosis, all types	371	(8.06)
Pseudofolliculitis barbae	289	(6.28)
Penile ulcer [? chancroid]	221	(4.80)
Miliaria	199	(4.32)
Pyoderma, all types	178	(3.87)
Contact dermatitis	167	(3.63)
Urticaria	126	(2.74)
Tinea versicolor	123	(2.67)
Psoriasis	106	(2.30)
Atopic dermatitis	95	(2.06)
Dyshidrosis	95	(2.06)
Alopecia areata	82	(1.78)
Monilia	71	(1.54)
Lichen planus	70	(1.52)
Herpes progenitalis	68	(1.48)
Seborrheic dermatitis	56	(1.22)
Miscellaneous dermatoses and dermatitides	51	(1.11)
Insect bites	48	(1.04)
Molluscum contagiosum	41	(0.89)
Sebaceous cyst	40	(0.87)
Pityriasis rosea	39	(0.85)
Hand and foot eczema	37	(0.80)
Lichen simplex chronicus	35	(0.76)
Syphilis infection, late and early	33	(0.72)
Erythema multiforme	32	(0.69)
Nevi	32	(0.69)
Balanitis	31	(0.67)
Basal cell epithelioma	25	(0.54)
Keloids	24	(0.52)
Corns and calluses	24	(0.52)
Drug eruptions	21	(0.45)
Vitiligo	20	(0.43)
Photoallergy	15	(0.33)
Nummular eczema	14	(0.30)
Pruritus	14	(0.30)
No diagnosis	56	(1.22)
Others	461	(10.02)
Total	4,605	(100.00)

Adapted from Allen AM. *Skin Diseases in Vietnam, 1965-72*. In: Ognibene AJ, ed. *Internal Medicine in Vietnam*. Vol 1. Washington, DC: Medical Department, US Army, Office of The Surgeon General and Center of Military History; 1977: 39.

TABLE 20-3

## DERMATOLOGY ADMISSIONS TO A BRITISH GENERAL HOSPITAL DURING WORLD WAR I

	1915		1916						Total
	Nov	Dec	Jan	Feb	Mar	Apr	May	Jun	
Impetigo	122	172	151	161	220	170	147	116	1,259
Scabies	95	770	170	8	25	5	9	23	1,105
Boils	24	59	50	51	42	36	65	48	375
Pediculosis	–	17	62	69	36	3	5	6	198
Psoriasis	11	24	17	17	29	21	36	29	184
Eczema	7	22	18	11	37	22	33	31	181
Seborrhoea	8	12	13	11	40	18	18	11	131
Acne	6	22	19	12	8	6	10	7	90
Dermatitis	7	10	10	11	11	8	8	7	72
Syphilis	8	13	4	3	6	4	17	16	71
Folliculitis	1	11	13	9	8	2	5	1	50
Urticaria	2	4	3	3	2	11	8	1	34
Sycosis	4	2	4	1	3	2	5	7	28
Pityriasis rosea	3	2	2	5	3	2	2	3	22
Erythema	3	7	5	–	4	1	–	1	21
Carbuncle	2	4	3	1	4	2	1	2	19
Herpes zoster	2	2	2	–	3	3	1	–	13
Lupus	–	–	2	–	–	3	2	2	9
Erysipelas	–	–	–	–	1	–	1	2	4
Ecthyma	–	–	1	2	–	–	–	–	3
Lichen planus	–	–	1	1	–	–	1	–	3
Erythema nodosum	–	–	–	–	–	–	–	2	2
Ichthyosis	–	–	1	–	–	–	–	1	2
Sudamina	–	–	–	–	–	–	–	2	2

Adapted from Macpherson WG, Herringham WP, Elliott TR, Balfour A, eds. Medical services. Diseases of the war. In: *History of the Great War*. Vol 2. London, England: His Majesty's Stationery Office; 1923: 68.

One might expect the largest category of dermatologic casualties to be composed of exotic tropical diseases; however, the greatest number of casualties has been related to common skin maladies. Experience from previous battles clearly indicates that common dermatoses are a major source of ineffectiveness and temporary disability among battlefield personnel. Pillsbury and Livingood<sup>3</sup> reported that the entire group of rare dermatoses was of no significance in the total disability from skin diseases in World War II. Statistics available from Vietnam and World War I (Tables 20-1 through 20-3) support a similar conclusion.<sup>3,4</sup> It is apparent

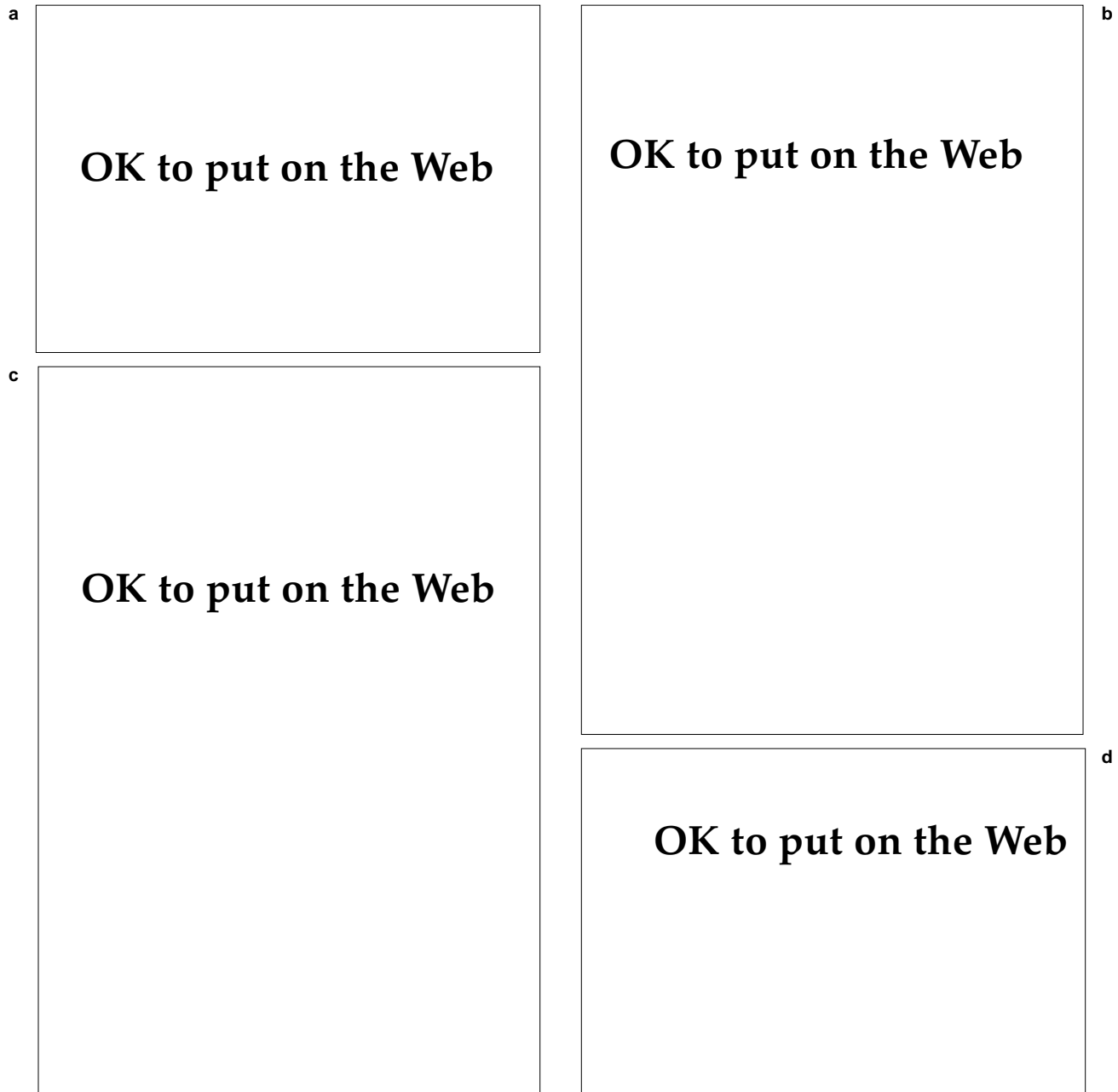from these experiences that many casualties can be averted in the future if more military medical personnel are trained in the recognition and management of some common skin diseases.

Tables 20-1 through 20-3 list a number of skin diseases that were discussed in previous chapters, such as impetigo (Chapter 13, Bacterial Skin Diseases), scabies (Chapter 8, Arthropod and Other Animal Bites), and miliaria (Chapter 3, Skin Diseases Associated with Excessive Heat, Humidity, and Sunlight). This chapter will address common dermatoses that did not fit in the previous chapters of this textbook.

## PSORIASIS

Psoriasis is a common, genetically determined, inflammatory skin disease characterized by distinctive lesional morphology and distribution. It affects men and women equally<sup>5</sup> and typically runs a chronic course that is marked by frequent relapses. It occurs worldwide and affects approximately 1%

of the population in the United States.<sup>6</sup> Psoriasis can have its onset at any age, but is most likely to appear in early adulthood.<sup>7</sup> Although its exact etiology is unknown, it is clear that psoriatic skin is in a hyperproliferative state with a marked increase in the rate of keratinocyte replication.<sup>8-10</sup>



**Fig. 20-1.** Psoriasis. (a) Large, geographic plaques. Note how lesions suggest the coastline of a map. (b) Note symmetry and extensive involvement of lesions. (c) Lichenified geographic plaques in obese individual. (d) Characteristic silvery scale.



## Clinical Features

Psoriasis is a classic example of a papulosquamous disease, characterized by erythematous papules and plaques with a silvery scale. The disorder can vary from a focal disease consisting of localized lesions to a widespread eruption and even a generalized erythroderma with exfoliation.<sup>11,12</sup>

The characteristic early lesion of psoriasis is an erythematous papule with a scale that can be subtle but is usually obvious. Typically, the papules gradually expand and coalesce to form sharply demarcated, symmetrically distributed plaques (Figure 20-1). Frequently, the plaques become surrounded by a thin zone of perilesional blanching, known as a Woronoff ring. This ring is most frequently seen in the early stages of resolution in ultraviolet (UV) light therapy (Figure 20-2). Although some authorities<sup>13</sup> have shown evidence of prostaglandin inhibition to explain this phenomenon, the precise mechanisms involved are likely to be more complex.<sup>14</sup>

Psoriasis can occur at any cutaneous site, although it has a predilection for the scalp, elbows, knees, extensor aspects of the extremities, and the nails. It also frequently involves the penis (Figure 20-3). Oral lesions are unusual in psoriasis; however, some authorities<sup>15-17</sup> believe that the condition known as geographic tongue (Figure 20-4) may actually be a manifestation of psoriasis, because the histological features are identical. Occasionally, only intertriginous areas are involved (inverse psoriasis). When one suspects a diagnosis of psoriasis, it is often helpful to inspect the intergluteal cleft for

**OK to put on the Web**

**Fig. 20-3.** Psoriasis on the penis. Note the paucity of scale.

involvement (Figure 20-5). A typical feature of psoriasis is Köebner's phenomenon, the appearance of lesions in scars or other sites of trauma.<sup>18</sup> The lesions may appear in sites of old, major trauma such as surgical scars or in areas of recent or minimal injury such as an abrasion. The cause of this phenomenon is not known, although recently, speculation has focused on microbial factors.<sup>19</sup>

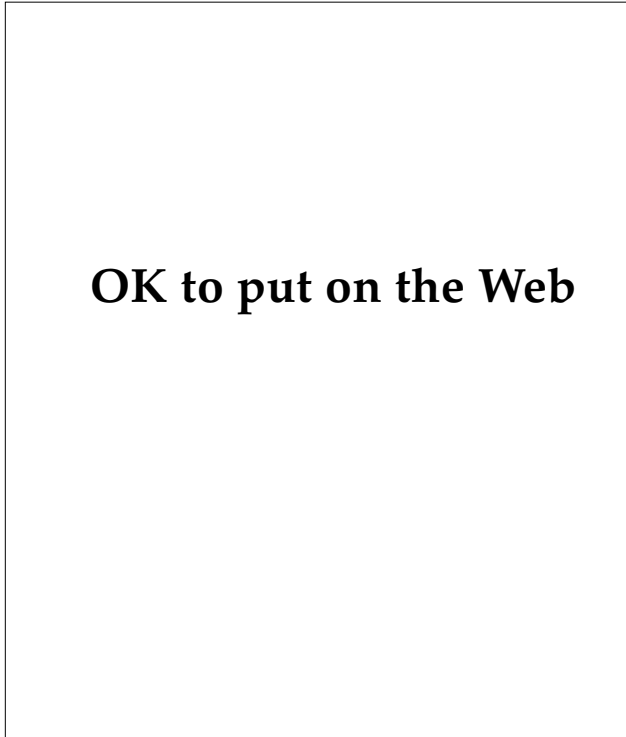
The scale in psoriasis is typically silvery white and stacked in layers. In this way, the scale is said to be micaceous (slatelike). When the scale is removed with curettage or scraping, pinpoint bleeding may be noted. This is known as the Auspitz sign. It is more common, however, to observe a loose scale that easily flakes off in patients with long-standing lesions. Although traditionally con-

**OK to put on the Web**

**Fig. 20-2.** Woronoff's rings. Note the zones of hypopigmentation outlining the resolving psoriatic plaques in this patient undergoing ultraviolet-B phototherapy.


**OK to put on the Web**

**Fig. 20-4.** Annular and arcuate pustular lesions of geographic tongue.

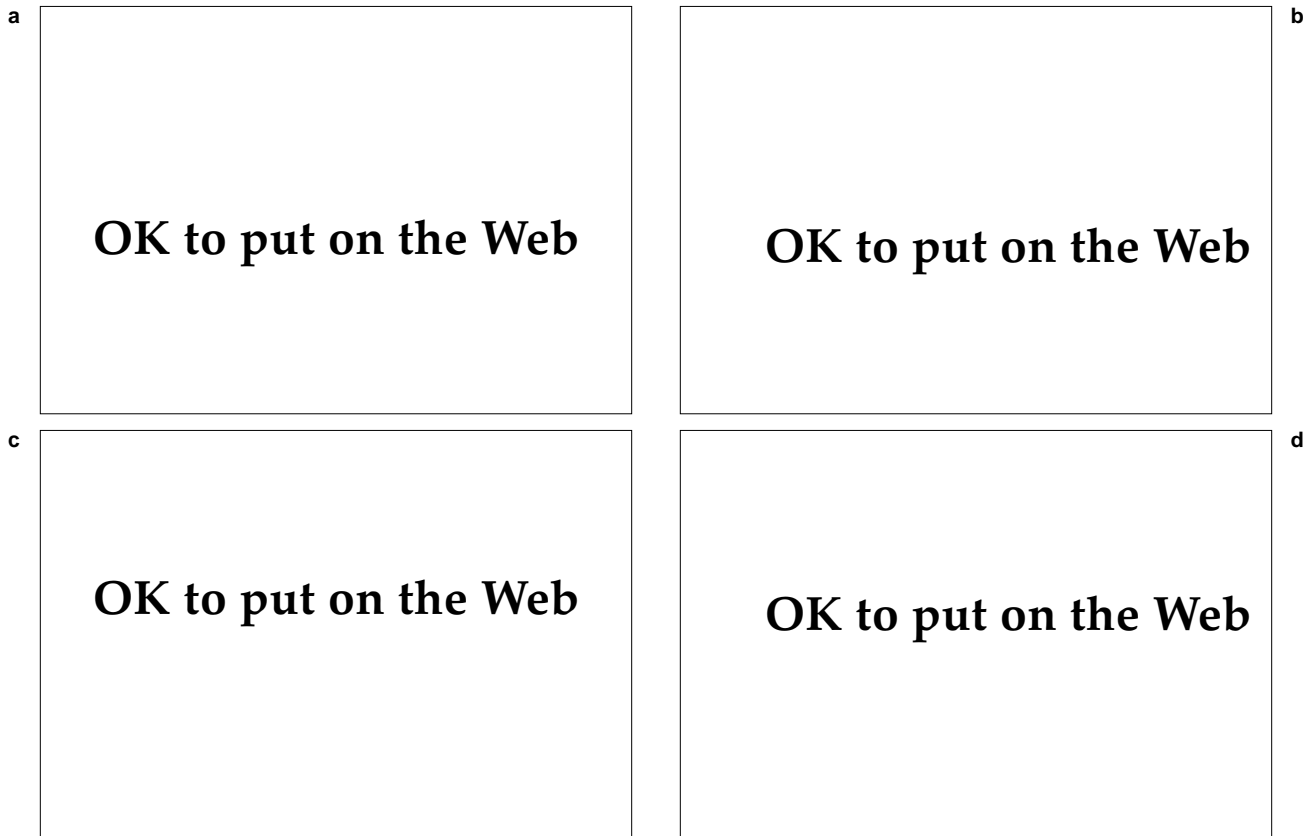


sidered a hallmark of psoriasis, the Auspitz sign's sensitivity and specificity have been questioned by Bernhard, who elicited the sign in several nonpsoriatic, scaling disorders.<sup>20</sup>

When examining a patient with presumed psoriasis, one should always examine the fingernails and toenails, which frequently reveal diagnostic clues (Figure 20-6). Onycholysis—separation of the distal free edge of the nail plate from the nail bed—is a frequent finding. Less common, but more specific, is nail pitting—actual punctate depressions on the surface of the plate. The most specific nail finding, often said to be pathognomonic, is the so-called “oil spot,” which describes a yellowish brown, irregular macule beneath the nail plate and represents involvement of the nail bed with psoria-



**Fig. 20-5.** Annular erythematous plaque with fine surface scale in the intergluteal cleft. This is a common site for psoriasis.



**Fig. 20-6.** Psoriatic nails. (a) Pitting, thickening, and discoloration. (b) Pitting, distal onycholysis, and “oil spot.” (c) Distal onycholysis and “oil spots” in patient with large psoriatic plaques. (d) Onycholysis, discoloration, and crumbling of nail plate. Photograph c: Courtesy of Dr. Charles Trapp, MacDill Air Force Base, Fla.

sis. When the nail matrix is involved, severe onychodystrophy can result, with diffuse crumbling and yellowing of the plate. In pustular psoriasis and acrodermatitis continua of Hallopeau, one commonly observes subungual pustules.

## Types of Psoriasis

### *Psoriasis Vulgaris*

Psoriasis Vulgaris is the most frequent presentation of psoriasis, consisting of chronic, stable, well-defined plaques that may persist for years. While the plaques can occur on any cutaneous surface, they are most likely to appear in the areas of predilection described above.

### *Guttate Psoriasis*

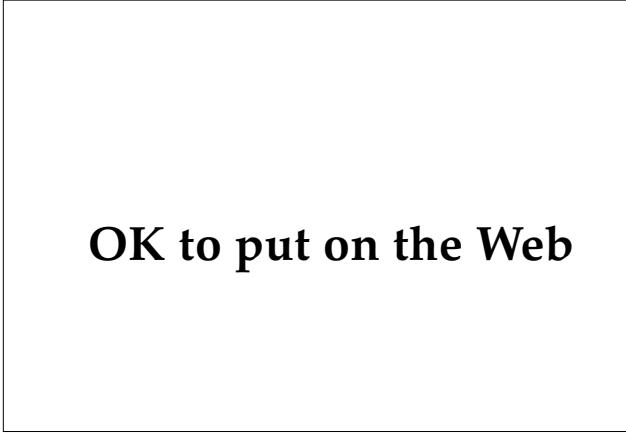
Guttate psoriasis most commonly occurs in young adults and is usually eruptive in onset. It consists of multiple, small, guttate (raindrop-like) lesions over the trunk and proximal extremities (Figure 20-7). Frequently, careful history-taking will reveal an antecedent streptococcal pharyngitis or viral respiratory infection.<sup>21</sup>

### *Localized Pustular Psoriasis*

Localized pustular psoriasis consists of two types: pustular psoriasis of the palms and soles, known as pustulosis palmoplantaris (Figure 20-8), and acrodermatitis continua of Hallopeau. Both forms present with pustules, the former involving the palms and soles, and the latter involving the distal fingers and toes with severe nail dystrophy (Figure 20-9). Both conditions are noted for chronicity and refractoriness to treatment. When severe, either can be disabling. Pustulosis palmoplantaris has been associated with arthritis of the anterior chest wall,<sup>22</sup> cigarette smoking, and thyroid disease.<sup>23</sup>

### *Generalized Pustular Psoriasis*

Generalized pustular (von Zambusch) psoriasis is one of the rarer presentations of psoriasis,<sup>24,25</sup> marked by acute attacks of generalized pustules on erythematous skin and associated with fever, leukocytosis, and systemic toxicity. This disease can be fatal, so hospitalization is mandatory. Several provocative factors are claimed to precipitate attacks, but the most important to consider is the association with steroid withdrawal (ie, systemic and potent topical steroids).<sup>25,26</sup>



**OK to put on the Web**

**Fig. 20-7.** Guttate psoriasis. Note scattered distribution of discrete, small, erythematous papules and plaques with scale.

### *Psoriatic Arthritis*

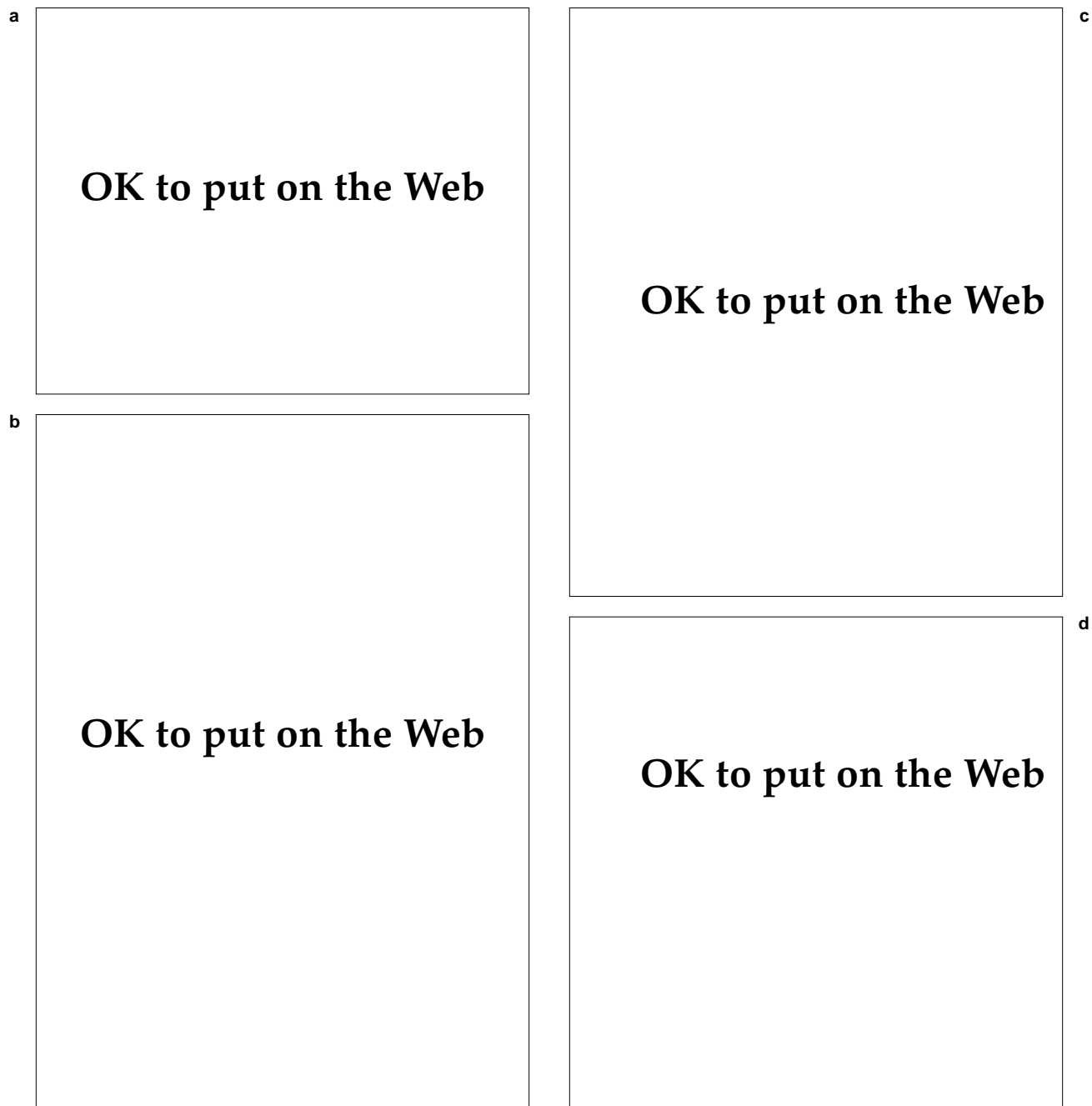
Psoriatic arthritis is an inflammatory, sero-negative arthritis clearly associated with psoriasis (Figure 20-10).<sup>27</sup> It has been neatly classified into five general categories (Table 20-4).<sup>28</sup>

## Diagnosis

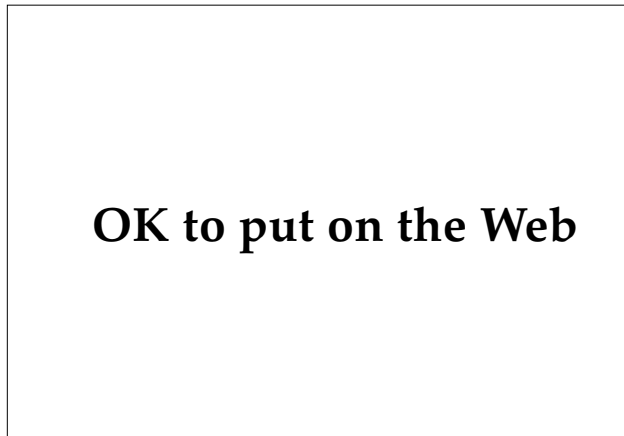
When chronic, scaling plaques are present on extensor surfaces or on the penis or scalp, the diagnosis is usually obvious. Occasionally, however, psoriasis can mimic other papulosquamous disorders: seborrheic dermatitis, lichen planus, pityriasis rosea, pityriasis rubra pilaris, drug eruptions, or even syphilis. Isolated lesions may be confused with lichen simplex chronicus, nummular dermatitis, cutaneous lupus erythematosus, or mycosis fungoides. When one suspects the diagnosis of psoriasis, it is essential to perform a thorough cutaneous exam looking for clues such as nail involvement, evidence of Köebner's phenomenon, or pinking of the intergluteal cleft. Obtaining a family history can also provide useful information. If doubt still exists, biopsy should be obtained because the histopathological features are fairly distinctive.

## Treatment

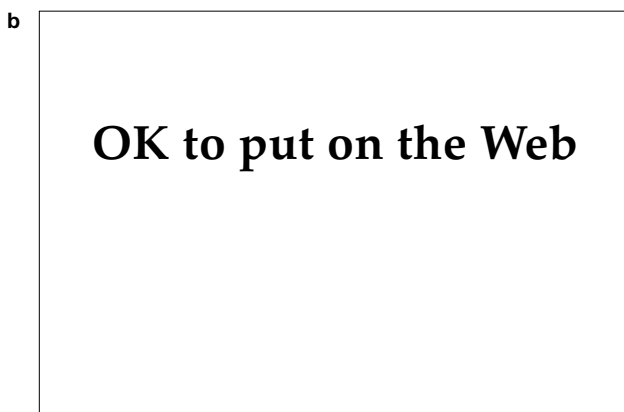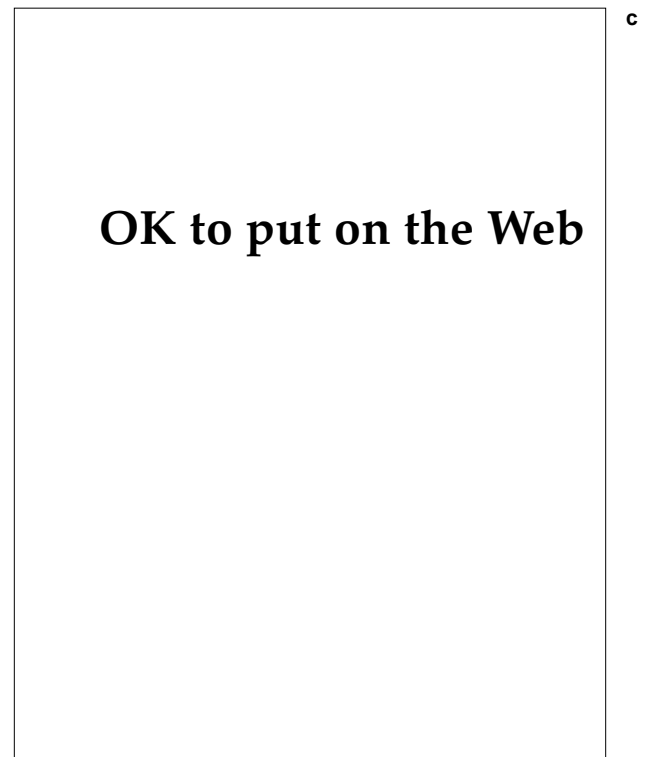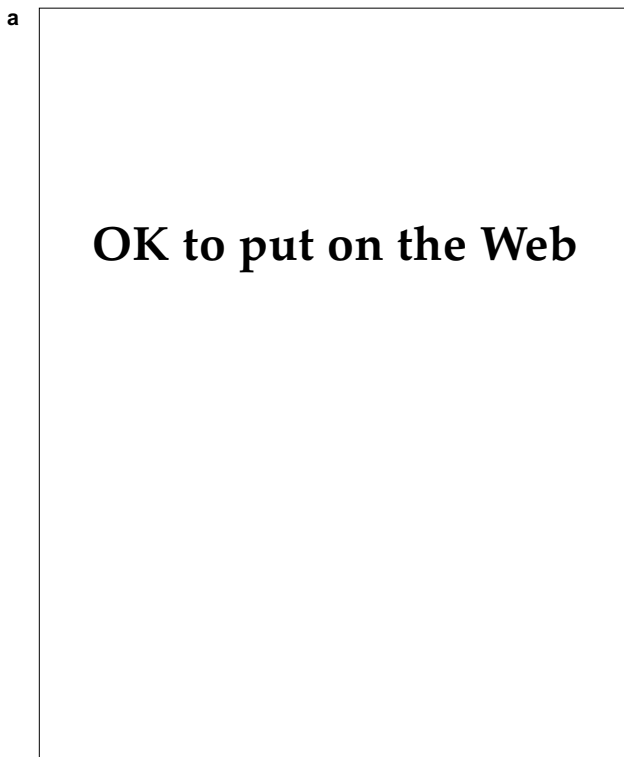
Numerous modalities are available for the treatment of psoriasis. This fact speaks for the complexity of the disease, the mystery of its pathogenesis, and the limitations of all of the available treatments.



**Fig. 20-8.** (a) Psoriasis of the palms. (b) Psoriasis of the soles. (c) Pustulosis plantaris. (d) Close-up view of (c) to reveal characteristic yellow-brown pustules.



**Fig. 20-9.** Scaling and crusted lesions with border of peripheral pustules on the distal digits, characteristic of acrodermatitis continua of Hallopeau.



**Fig. 20-10.** Psoriatic arthritis. (a) Proximal interphalangeal joint of finger. (b) Toe involvement—"sausage digit." (c) Severe involvement of fingers and hand.

**TABLE 20-4**  
**ARTHRITIS IN PSORIASIS**

Type of Arthritis	Characteristics
Asymmetric involvement of a few joints of the fingers	Affects 70% of patients with psoriatic arthritis; "sausage digit"
Symmetric polyarthritis	Affects 15% of patients with psoriatic arthritis; resembles rheumatoid arthritis (seronegative)
Distal interphalangeal joint involvement	Affects 5% of patients with psoriatic arthritis; "classic" psoriatic arthritis
Arthritis mutilans	Affects 5% of patients with psoriatic arthritis; deforming arthritis with bony destruction, telescoping of digits, and ankylosis
Ankylosing spondylitis	Affects 5% of patients with psoriatic arthritis; may also have peripheral joints involved

Data source: Moll JMH, Wright V. Familial occurrence of psoriatic arthritis. *Ann Rheum Dis.* 1973;22:181.

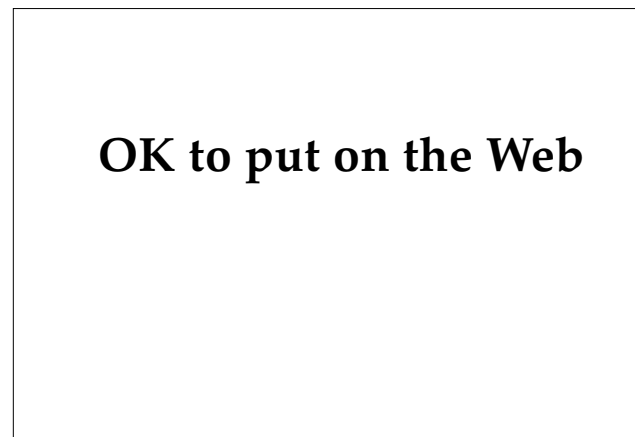There clearly is no treatment of choice in the management of psoriasis. Many new modalities have been described recently, such as vitamin D,<sup>29</sup> fish oil,<sup>30</sup> and cyclosporine.<sup>31</sup> At this point, these therapies should be considered investigational. Medical officers are advised to consider first the more traditional, time-honored modalities available.

No treatment is without side effects. The risks for adverse side effects can often be reduced by combination therapy, such as retinoids combined with psoralen and UV-A (PUVA). The advantage of combination therapy is that the cumulative dose of each agent is diminished. Thus, while the beneficial effects may be additive, the adverse effects are usually decreased. Furthermore, when approaching the treatment of psoriasis, one must realize that the aim of treatment should not be to obtain complete clearing. That is often an unrealistic approach in the management of psoriasis. Complete clearing is often unattainable without experiencing significant toxicity. Realistic expectations by the physician as well as the patient are perhaps the most important aspects of therapy.

**Topical Corticosteroids**

Topical corticosteroids are frequently employed in the management of psoriasis and can be quite beneficial. Due to a potent antiinflammatory effect and inhibition of deoxyribonucleic acid (DNA) synthesis (with a subsequent antiproliferative effect), topical steroids are a logical and effective modality in this disease. Intralesional steroids may be con-

sidered for isolated or resistant plaques. The limiting factor for topical corticosteroids is epidermal and dermal atrophy, which can result in marked thinning of the skin and striae formation (Figure 20-11). More importantly, sustained use of potent topical steroids can lead to suppression of the hypothalamic-pituitary-adrenal axis.<sup>32,33</sup> Pulse dosing may permit extended maintenance with potent topical steroids while limiting adverse effects.<sup>34</sup> Another drawback to consider regarding steroid therapy is the development of tachyphylaxis. For these reasons, one is encouraged to consider alternative topical agents for the treatment of psoriasis.



**Fig. 20-11.** Linear atrophic striae on the back of this patient, who is taking oral steroids.

### ***Anthralin***

Anthralin is a synthetic anthrone derivative that reduces mitotic activity and suppresses free radicals. It is widely used in Europe as an integral component of the Ingram regimen, which consists of a daily coal tar bath followed by suberythemogenic UV-B exposure, then the application of dithranol paste of gradually increasing concentration.<sup>5</sup> Although this method is quite effective and safe, it is cumbersome. For this reason, short-contact anthralin treatment plans have been devised,<sup>35</sup> frequently with the addition of coal tar<sup>36,37</sup> to diminish the irritancy of anthralin, which can limit its use. Due to its lack of systemic toxicity, carefully supervised anthralin therapy combined with thorough patient explanation and education is an ideal modality for the treatment of chronic plaque-type psoriasis.

### ***Coal Tar***

Coal tar has been widely employed in the treatment of psoriasis for more than a century. It is a complex mixture of over 10,000 substances,<sup>38</sup> which may possess antimetabolic activity.<sup>39</sup> Coal tar gained popularity after introduction of a simple method described by Goeckerman in 1925,<sup>40</sup> which consists of continued application of 2% crude coal tar, which is removed with mineral oil once daily for UV-B exposure. The tar is reapplied after bathing.

Coal tar is an extremely safe agent. The most frequent side effect is a tar-induced folliculitis. There have been reports of skin cancers associated with coal tar application<sup>41,42</sup>; however, this is an uncommon event, and such case reports usually involve patients who have been exposed to multiple other skin cancer-inducing agents.

### ***Systemic Methotrexate***

Methotrexate, given in weekly oral doses of 5 to 25 mg, is an extremely valuable agent for treating severe psoriasis and psoriatic arthritis that are not adequately controlled by more conventional therapies. It is a folate antagonist that exerts its antiproliferative effect on psoriatic epidermal cells by directly inhibiting DNA synthesis.<sup>43</sup>

Methotrexate is absolutely contraindicated in pregnant or lactating females. Relative contraindications are many, including liver or renal abnormalities, excessive alcohol consumption, and anemia, leukopenia, and thrombocytopenia. Guidelines

for appropriate use of methotrexate in psoriasis are published periodically by the Psoriasis Task Force of the American Academy of Dermatology.<sup>44</sup> Medical officers should be thoroughly knowledgeable with these guidelines before considering methotrexate for the treatment of psoriasis. The greatest limitation of methotrexate is its hepatotoxicity. For this reason, newer folate antagonists with perhaps fewer effects on the liver are being investigated.<sup>45</sup>

### ***Systemic Retinoids***

The retinoids are synthetic derivatives of vitamin A and vitamin A acid. The effects of vitamin A and vitamin A analogs on the growth and terminal differentiation of epidermal cells and the vitamin's beneficial effect on disorders of keratinization have long been known. Retinoids have been shown to affect growth of epidermal cells by altering keratin synthesis and formation of the cell envelope.<sup>46</sup>

Etretinate (0.5–1.0 mg/kg/d) is the retinoid approved for use in the treatment of psoriasis. It should be considered for initial treatment in the management of pustular psoriasis or erythrodermic psoriasis.<sup>47</sup> It is also beneficial for the patient with extensive plaques and severe involvement recalcitrant to more conventional modalities and has been successful in clearing acrodermatitis continua of Hallopeau.<sup>48</sup>

Etretinate has significant risk for adverse effects including teratogenicity, elevation of serum lipids, liver toxicity, and numerous mucocutaneous side effects. In addition, cases of skeletal hyperostoses have been documented with long-term use.<sup>49</sup> Furthermore, it is known to be stored in adipose tissue for long periods, thus leading to a prolonged half-life (> 100 d).<sup>50</sup> In fact, blood levels are detectable for more than 2 years after discontinuation of therapy. For these reasons, in addition to its potent teratogenicity, etretinate is best avoided in women of child-bearing potential. Alternatives include isotretinoin and, once available, acitretin—the main metabolite of etretinate—which has been shown to be effective in treating psoriasis and has a much shorter half-life (50 h for acitretin vs 120 d for etretinate).<sup>51</sup> Because the side effects of acitretin are similar to those of etretinate, including potent teratogenicity, effective contraception is essential for women and long-term use is discouraged. Because risks are greatly increased with long-term use of retinoids, they are probably best used in combination with other modalities such as phototherapy.

### **Ultraviolet-B Phototherapy**

Natural sunlight has long been known to improve psoriasis. An excellent (and more reliable) substitute is an artificial light source that produces light primarily in the ultraviolet-B (UV-B) range (290–320 nm). This allows for continuous monitoring and metered delivery of UV radiation, thus diminishing the potential for accidental overexposure and burning. Although the mechanism of the therapeutic effect is unknown, UV-B alone or with coal tar is an excellent method for clearing psoriasis and maintaining remission. Its use should be considered early in the course of management.

### **Psoralen and Ultraviolet-A Phototherapy**

Introduced in 1974 by Parrish and Fitzpatrick,<sup>52</sup> PUVA phototherapy has gained worldwide acceptance in the treatment of psoriasis. Patients ingest a specific dose of methoxsalen (consult chart in package insert for precise dosage based on weight), followed in approximately 90 minutes by a carefully metered UV-A (320–400 nm) exposure, which is increased with progressive treatments. Initially, Oxsoralen was the drug employed. This has now been replaced by Oxsoralen-Ultra (methoxsalen, manufactured by ICN Pharmaceuticals, Inc., Costa Mesa, Calif.), a liquid form in a gel capsule that provides more uniform serum drug levels.<sup>53</sup> Patients are treated two to three times per week, and generally respond within 20 to 25 treatments. PUVA can then be continued and gradually tapered to maintain prolonged remission.

PUVA exerts its effect through the production of bifunctional DNA adducts and subsequent inhibition of DNA synthesis and epidermal cell replication.<sup>54</sup> It is an excellent modality for managing severe psoriasis on an outpatient basis. However, it is not without risk. Patients must wear protective eyewear (wraparound UV-A filtering glasses) for 24 hours after ingestion of the drug to prevent cataracts. It has been well documented that PUVA is clearly associated with an increased risk for nonmelanoma skin cancer, particularly squamous cell carcinoma.<sup>55,56</sup> The study by Fitzpatrick and Parrish<sup>55</sup> reveals that the risk of developing squamous cell carcinoma increases with cumulative PUVA exposure. The higher exposure group (> 260 treatments) has a risk that is 12-fold that of the lower exposure group (< 160 treatments) and 100-fold that of the general population.<sup>55</sup> This fact emphasizes the point made previously: the goal of therapy when managing psoriasis should not be

100% clearing. Ninety percent clearing is, generally, much easier to attain and maintain at far less risk, and this is usually quite acceptable to the patient. Clearly, PUVA should not be used unless the patient's psoriasis is severe. While PUVA-induced squamous cell carcinoma has little potential for metastatic spread, all patients receiving PUVA must be carefully monitored to ensure early detection and prevention of disfigurement. All men should shield the genital region during therapy, as this area has proven to be at particular risk for developing PUVA-induced tumors.<sup>57</sup>

PUVA-associated carcinogenesis may possibly be avoided by employing PUVA bath treatments using a trioxsalen solution. This technique has been used extensively in Europe and has been shown to be of equal efficacy<sup>58</sup> to and probably safer than standard PUVA.<sup>58–60</sup> This author has found a similar technique using a solution of Oxsoralen, as described by Coleman et al,<sup>61</sup> to be extremely effective in the management of pustulosis palmoplantaris. All forms of PUVA may be combined with other treatments such as retinoids to obtain superior results while diminishing adverse effects.

### **Military Considerations**

The main point to emphasize to the military physician regarding psoriasis is its tendency towards chronicity and its sometimes unpredictable course. Consider the individual with mild plaque-type psoriasis who is easily controlled with anthralin and intermittent UV-B therapy. That same individual deployed to a northern climate or hostile environment may experience a significant flare-up requiring medical evacuation and preventing mission completion. This author has observed this scenario repeatedly. In World War II, dermatologists found that approximately 20% of psoriatic patients became liabilities and questioned whether troops with significant psoriasis should ever be sent overseas.<sup>62</sup> In U.S. Army medical clinics in Vietnam, psoriasis accounted for up to 6% of outpatient visits.<sup>2</sup> Individuals with psoriasis of even mild severity should be considered for presentation to a medical evaluation board for determination of worldwide qualification.

Another point to consider about psoriasis in the military is a controversial one: the role of antimalarial chemoprophylaxis in inducing exacerbations of psoriasis.<sup>63</sup> This author witnessed one case of a young sailor who experienced a pustular flare-up of his psoriasis while on chloroquin prophylaxis. This required medical evacuation from a



ship and a prolonged hospital course, including an initial stay in the intensive care unit. While this is anecdotal, it illustrates the argument for reconsidering worldwide eligibility for all military mem-

bers with psoriasis. Kuflik reported on 48 U.S. Army patients with psoriasis on prophylactic chloroquin in Vietnam: 42% of the cases worsened, but only 6% had significant flare-ups.<sup>64</sup>

## LICHEN PLANUS

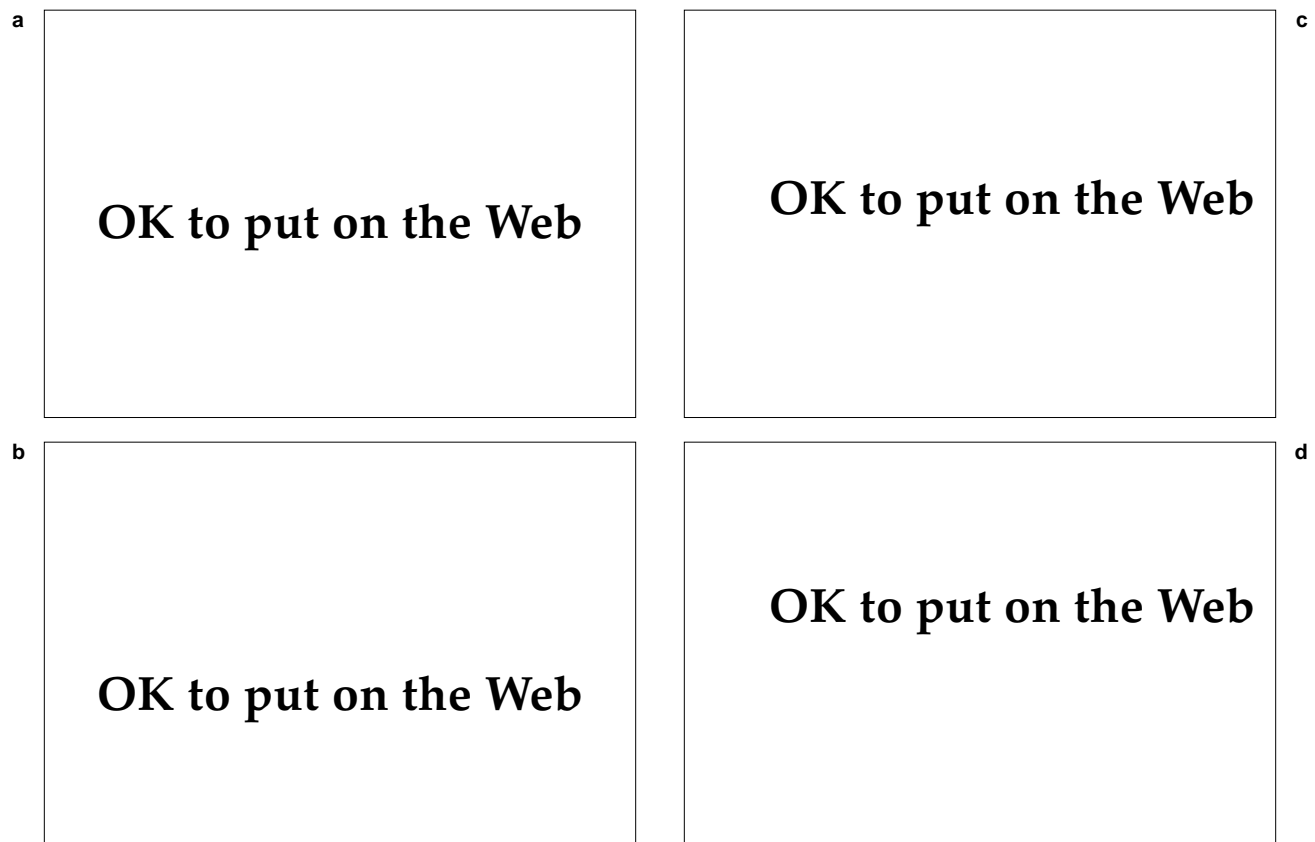
Lichen planus (LP) is an inflammatory skin disease that is often pruritic, with distinctive mucocutaneous findings. In 1969, Erasmus Wilson published a series of 50 cases describing the classic features of LP.<sup>65</sup> The prevalence of LP in the general population is estimated to be 0.13% to 0.34% for cutaneous involvement and 0.19% to 1.5% for oral involvement.<sup>66</sup> In a study of over 670,000 patients in the United States, LP was seen in 0.44%.<sup>67</sup> In a general dentistry clinic, oral LP was seen in 0.6%.<sup>68</sup>

LP predominantly afflicts people in their middle ages, with approximately two thirds of those affected between the ages of 30 and 60.<sup>67</sup> It is world-

wide in its distribution with no racial predisposition. Both sexes are affected approximately equally. Familial cases have been reported.<sup>69,70</sup>

### Clinical Features

The characteristic lesion of LP is a flat-topped, shiny, polygonal papule that is most often described as violaceous in color. Individual papules range in size from pinpoint to greater than 1 cm and may remain discrete or become confluent. Frequently, one can observe fine, reticulate white streaks on the surface. These streaks, known as Wickham's striae, are most easily seen with the use of mineral oil and



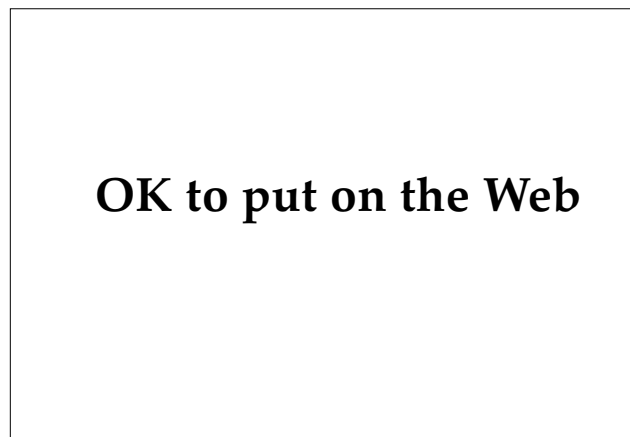**Fig. 20-12.** Lichen planus. (a) Ankle. Note violaceous, flat papules with reticulated white scale. (b) Flexor surface of the wrist, a common location. (c) Dorsum of hand. (d) Close-up of (a) to demonstrate Wickham's striae.

the aid of a hand-held lens. Köebner's phenomenon is sometimes observed.<sup>18,71</sup>

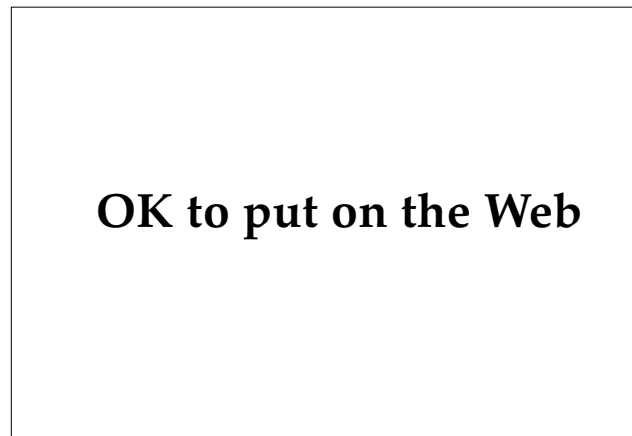LP may remain a localized process or have a generalized distribution. When LP becomes generalized it usually does so within the first month of onset and is typically symmetric in its distribution. The majority of cases begin on the extremities, especially the ankles<sup>72</sup> and the flexor aspects of the wrists (Figure 20-12).<sup>73</sup> The ankles and shins are the most common sites for hypertrophic lesions.<sup>74</sup> Other cutaneous sites commonly involved include the lumbar region and the penis; the latter site may have annular or ulcerative lesions (Figure 20-13). Erosive and ulcerative forms of LP can also be found on other mucous membranes as well as on the palms, soles, and arms (Figure 20-14).<sup>75,76</sup>

The natural course of LP is usually spontaneous resolution—93% within 2 years in Samman's study.<sup>77</sup> Among this same series of patients, the rate of relapse was 20%. Typically, marked postinflammatory hyperpigmentation, hypopigmentation, or both will occur as lesions regress.<sup>78</sup>

Nail involvement is seen in 10% of cases.<sup>77</sup> This is most commonly manifested as surface roughness or flaking with longitudinal ridging. Other changes include brownish discoloration, pitting, and thinning of the nail plate with splitting of the free edge. Chronic nail involvement can result in pterygium formation as a result of the growth of the cuticle and subsequent adherence to the nail bed, resulting in permanent loss of the nail plate. Occasionally, the nails may be the only site of involvement.<sup>79,80</sup> These cases normally require histological confirmation for diagnosis. Twenty-nail dystrophy, a disorder of



**Fig. 20-13.** Annular lichen planus on the penis—a common location. Note violaceous border and central hyperpigmentation.



**Fig. 20-14.** Annular lichen planus on the arm. Note the central hyperpigmentation and characteristic violaceous border with slight scale.

acquired dystrophic nail changes in children, may be a manifestation of LP.<sup>81,82</sup> Several other variants of cutaneous LP exist (Exhibit 20-1).

Involvement of oral mucosa is very common in LP. In Altman and Perry's series of 197 patients, 40% had cutaneous and mucosal involvement, and 25% had oral alone.<sup>83</sup> Oral lesions can be found in up to 71% of LP patients seen in dermatology clinics.<sup>77,83</sup>

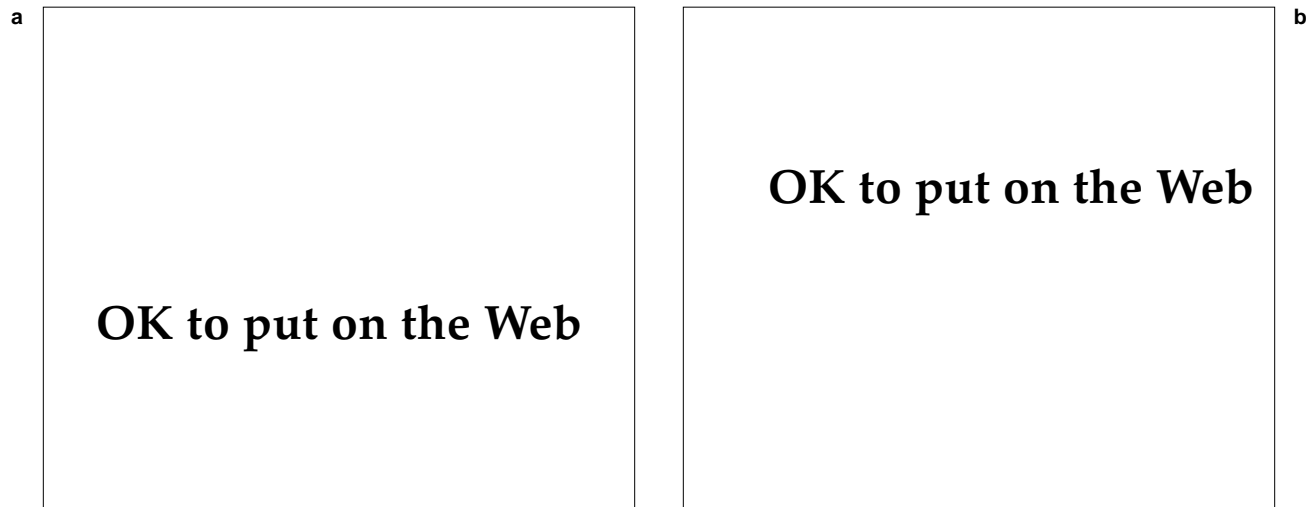
Oral LP typically involves buccal mucosa, although other sites can be involved. These include

#### EXHIBIT 20-1

#### VARIANTS OF CUTANEOUS LICHEN PLANUS

---

- Hypertrophic lichen planus
- Linear lichen planus
- Annular lichen planus
- Atrophic lichen planus
- Lichen planus subtropicus (actinicus)
- Bullous lichen planus
- Lichen planopilaris
- Lichen planus pemphigoides
- Lichen planus–lupus erythematosus overlap
- Ulcerative lichen planus
- Hepatitis-associated lichen planus



**Fig. 20-15.** Oral lichen planus. (a) Characteristic reticulate, white plaque on the buccal mucosa—the most commonly involved site. (b) Involvement of the lower lip.

the tongue, gingiva, and vermillion border of the lip (Figure 20-15).<sup>84</sup> Involvement of the palate and sublingual region is rare. Almost always, oral LP occurs bilaterally. The appearance of LP in the oral mucosa can be quite varied. The most common morphology is that of a plaque consisting of slightly elevated, very fine white lines in a reticulate pattern, similar to Wickham's striae. This has been referred to as "Honiton lace." Other forms include a papular variant or a plaquelike form (resembling leukoplakia), an atrophic form (resembling erythroplakia), bullae (rare), and an erosive form.<sup>84</sup> Erosions are often extensive and can result in desquamative gingivitis.<sup>85</sup>

The natural course of oral LP is one of chronicity, with a mean duration of almost 5 years.<sup>72</sup> Oral LP has been shown to persist for more than 25 years.<sup>85</sup> Persistent, erosive, oral LP may have a potential for the development of squamous cell carcinoma, although this is controversial.<sup>86-89</sup> Some authorities<sup>88</sup> consider oral LP to be a premalignant condition.

### Pathogenesis

The precise etiology of LP remains unknown despite intensive investigation. Multiple hypotheses support numerous etiologies, including infectious agents, tobacco, betel nuts, psychogenic stress, chemicals, and numerous drugs. Some cases of LP have occurred in patients with diabetes, hepatitis,<sup>89,90</sup> hepatic biliary cirrhosis,<sup>91</sup> hypertension, and urolithiasis. While the exact triggering mechanism for LP remains unknown, recent work strongly im-

plicates T-cell-mediated cytotoxicity as the final common pathway leading to the development of the lesion of LP.<sup>92,93</sup> Norris<sup>94</sup> recently demonstrated marked staining for ICAM-1 (intercellular adhesion molecule-1) of basal cells in skin from lesions of lichen planus. One could propose that this would lead to binding between the basal keratinocytes and T lymphocytes within the dense dermal infiltrate, resulting in the cytotoxic destruction of the keratinocytes.

### Diagnosis

Lichen planus has a rather distinctive clinical presentation. Other entities to consider in the differential diagnosis are lichenoid drug eruptions, psoriasis, syphilis, and LP-like keratoses. When the skin lesions suggest a diagnosis of LP, always examine the mouth, which will frequently reveal the characteristic white, reticulate plaques typical of LP. Oral lesions, in the absence of cutaneous findings, may be confused with candida, traumatic erosions, aphthae, leukoplakia, or bullous diseases such as pemphigus vulgaris or erythema multiforme. Biopsy will usually confirm the diagnosis of LP, which has specific histological features. History is the most important feature to distinguish a lichenoid drug eruption from LP.

### Treatment

The mainstay of therapy for LP is corticosteroids. In localized forms, potent topical steroids or

steroids applied under occlusion may be beneficial. Large plaques generally respond to intralesional triamcinolone (3–5 mg/mL). Generalized or eruptive LP usually requires systemic steroid therapy. Alternatives to consider are PUVA<sup>95,96</sup>; retinoids<sup>97,98</sup>; and griseofulvin (125–250 mg twice daily), which has been reported to have a cure rate as high as 90%,<sup>99,100</sup> although other reports show it to be completely ineffective.<sup>101</sup> Oral lesions may respond to topical steroids in Orabase (gelatin, pectin; manufactured by Colgate-Hoyt, Canton, Mass.) or aerosolized betamethasone valerate. Recently, two groups<sup>102,103</sup> have reported significant improvement of oral LP using a topical cyclosporine rinse with no systemic adverse effects and little systemic absorption over a 2-month period. However, the cost of cyclosporine may prove prohibitive.

In addition, antihistamines and antipruritic lotions may be useful and should be employed for relief of pruritus.

### Military Considerations

Although LP is generally considered to be a benign, self-limited disease, the pruritus that usually accompanies it may interfere with performance of duty. It is important, then, to treat

symptomatic patients aggressively to keep them functional.

Of historical significance is the widely reported relationship of atypical LP with the administration of quinacrine for antimalarial prophylaxis in World War II.<sup>104–107</sup> The study by Bazemore et al<sup>104</sup> of 400 patients reveals that long-term therapy with antimalarials is necessary to induce atypical LP, as only 20% of patients developed the disease within 3 months, while 80% developed the disease within 7 months. Many cases were complicated by a secondary pyoderma—usually caused by *Streptococcus pyogenes* and *Staphylococcus aureus*. This most likely was a result of inadequate hygiene in a tropical environment. The eczematous process frequently involved the hands, thus disqualifying many individuals from full military duty. On return to duty, relapse was almost certain, so prompt evacuation became the treatment of choice.<sup>62</sup>

A variant of LP rarely seen in the United States that could potentially be of significance for deployed military personnel is LP subtropicus (actinicus). This is common in the Middle East and consists of annular lesions on sun-exposed surfaces, particularly the face.<sup>108–110</sup> The course is chronic and the condition worsens with sun exposure. Treatment consists of using sun blockers and limiting sun exposure.

## ATOPIC DERMATITIS

Atopic dermatitis is an environmentally induced disorder occurring in genetically predisposed individuals. It is characterized by acute episodes of eczematous cutaneous eruptions with characteristic distribution, usually accompanied by xerosis. The disorder may be considered part of the atopic diathesis that also includes allergic rhinitis, conjunctivitis, and asthma. It is prevalent worldwide and is more common among children, particularly of industrialized countries. Its incidence in England is 1.1% to 3.1%.<sup>111,112</sup> In the United States it is 0.7 to 2.4%.<sup>113</sup>

### Clinical Features

The clinical features of atopic dermatitis can be classified into major features that are seen in most atopic patients and minor, nonspecific features that are frequently seen in atopic patients (Exhibit 20-2).<sup>114</sup> There is no primary lesion of atopic

dermatitis. The lesions are eczematous and marked by erythema, weeping, scaling, crusting, and lichenification (thickening of skin in response to continual rubbing). Often, the lesions may be excoriated or secondarily infected. Atopic dermatitis is recognized by observing these findings in a typical pattern of distribution. In infants and children under 2 years of age, the lesions typically occur on the face (Figure 20-16) and extensor surfaces. Paradoxically, in older children and adults, the characteristic pattern is that of predominantly flexural involvement with sparing of the face (Figure 20-17).

History is extremely helpful in establishing the diagnosis of atopic dermatitis. The age of onset is usually in childhood—60% within the first year of life.<sup>115</sup> Seventy percent of patients will have a history of asthma, hay fever, or both.<sup>114</sup> A family history of atopy is almost always present.

**EXHIBIT 20-2****CLINICAL FEATURES OF ATOPIC DERMATITIS****Major Features**

- Pruritus
- Flexural lichenification in adults
- Facial and extensor involvement in infants and children
- Chronic or chronically relapsing dermatitis
- Personal or family history of atopy (asthma, allergic rhinitis, atopic dermatitis)

**Minor Features**

- Xerosis
- Ichthyosis, palmar hyperlinearity, keratosis pilaris
- Immediate (type 1) skin test reactivity
- Elevated serum immunoglobulin E
- Early age of onset
- Tendency toward cutaneous infections (especially with *Staphylococcus aureus* and herpes simplex virus), impaired cell-mediated immunity
- Tendency toward nonspecific hand or foot dermatitis
- Nipple eczema
- Cheilitis
- Recurrent conjunctivitis
- Dennie-Morgan infraorbital fold
- Keratoconus
- Anterior subcapsular cataracts
- Orbital darkening
- Facial pallor, facial dermatitis
- Pityriasis alba
- Anterior neck folds
- Pruritus when sweating
- Intolerance to wool
- Perifollicular accentuation
- Food intolerance
- Course influenced by environment or emotional factors
- White dermographism, delayed blanch

Data source: Hanifin JM. Clinical and basic aspects of atopic dermatitis. In: *Seminars in Dermatology*. New York, NY: Thoieme-Stratton, Inc; 1983: 25-29.



**OK to put on the Web**

**Fig. 20-16.** Atopic dermatitis in an infant most commonly involves the face, with perioral sparing.

**Natural Course**

The natural course of atopic dermatitis is one of repeated episodes of acute flare-ups, followed by a subacute phase of slow resolution.<sup>116</sup> Acute episodes tend to occur in response to psychic or emotional stress. In a study in which more than 500 patients were interviewed, stress was considered the primary precipitating factor.<sup>117</sup> Between flare-ups, patients will often be bothered by generalized xerosis, which often is quite pruritic and creates an intolerance of the skin for exposure to solvents, soaps and other cleansers, and water (in excessive amounts).



**OK to put on the Web**

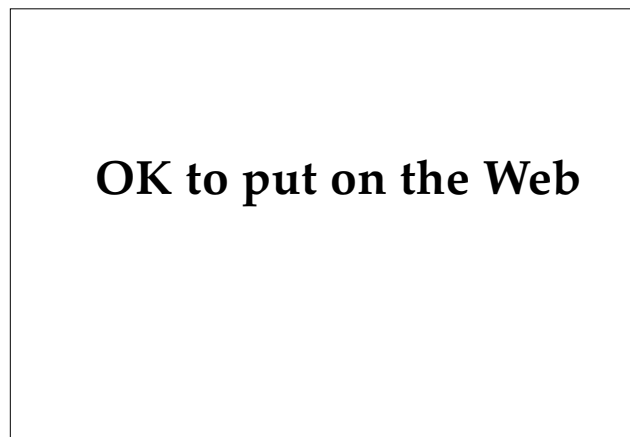**Fig. 20-17.** Atopic dermatitis in a young adult, with typical involvement of antecubital fossae and marked symmetry.

Hand dermatitis is frequently seen in patients with atopic dermatitis, particularly adults. Approximately 70% will experience it.<sup>118</sup> Careful questioning of adult patients with hand dermatitis will often reveal a prior history of atopic dermatitis.

### Complications

Staphylococcal pyoderma is a frequent complication of atopic dermatitis. The skin of nearly all patients with atopic dermatitis is heavily colonized with *S aureus*.<sup>119,120</sup> This is partially explained by the observation that *S aureus* may have specific binding sites for tissue fibronectin and laminin.<sup>121,122</sup> In general, these infections remain superficial, but cases of osteomyelitis have been reported in children with severe atopic dermatitis.<sup>123</sup>

As a result of impaired cellular immune responses,<sup>124</sup> patients with atopic dermatitis sometimes are unable to adequately handle viral or fungal infections of the skin. This increased susceptibility has resulted in widespread cutaneous viral infections such as eczema vaccinatum (vaccinia virus from smallpox vaccine) and Kaposi's varicelliform eruption, which is usually caused by herpes simplex virus (HSV) (Figure 20-18), but has also been seen with coxsackievirus A16. Both produce a similar clinical picture of an acute, widespread, vesiculopustular eruption marked by fever, adenopathy, and prostration. The patients may appear quite ill and some have died.<sup>125,126</sup> Treatment is with intravenous acyclovir (750 mg/m<sup>2</sup>/d) and antibiotics for secondary bacterial infection. Other



**Fig. 20-18.** Kaposi's varicelliform eruption from herpes simplex virus in a young adult female with a history of eczema in childhood.

### EXHIBIT 20-3

#### COMMON PRECIPITATING FACTORS IN ATOPIC DERMATITIS

- Excessive exposure to soap, hot water, or chemicals
- Psychic stress
- Overheating (by physical exertion or hot climate)
- Cutaneous infection or infestation (eg, scabies)
- Extremes of temperature (hot or cold)
- Prickly clothes
- Allergic exposure (when relevant)

viruses that can cause problems for atopic patients include molluscum contagiosum and human papillomavirus (HPV).

### Diagnosis

Atopic dermatitis is most often confused with contact dermatitis (irritant or allergic), but other dermatoses in the differential diagnosis include seborrheic dermatitis, psoriasis, scabies, nummular dermatitis, and lichen simplex chronicus. Atopic dermatitis is a clinical diagnosis based on the findings of at least three major and three minor criteria (see Exhibit 20-2).

### Treatment

When approaching the management of atopic dermatitis, it is useful to keep in mind that this is a disease that is precipitated in genetically predisposed individuals by an environmental stress. The first goal of treatment, therefore, is the elimination of known precipitating factors (Exhibit 20-3).

Topical steroids are a mainstay of therapy in relieving the inflammation of acute episodes and the associated pruritus. Their use should be carefully supervised by the treating physician. Patients must be aware of the risks for dermal atrophy, adrenal suppression, and tachyphylaxis. Because flexural areas are commonly involved, one must be especially alert for possible steroid-induced atrophy. Topical steroids should be applied sparingly and only on inflamed areas. Highly potent topical steroids such as clobetasol propionate applied twice daily may be useful in short courses (less than 2 wk) for treating areas of lichenification, but are best avoided in children. Systemic steroids, while effec-

tive, are not recommended as patients are likely to become dependent on them.

Because xerosis is so often a precipitating factor, hydration of the skin is an essential component of therapy. Emollients such as Eucerin (water, mineral oil; manufactured by Beiersdorf, Norwalk, Conn.), Lac-Hydrin (ammonium lactate, manufactured by Westwood Pharmaceuticals, Buffalo, N.Y.), Moisturel (petrolatum, glycerin; manufactured by Westwood Pharmaceuticals, Buffalo, N.Y.), and 10% urea cream are effective agents that are best applied after bathing. They can be applied to the entire cutaneous surface; topical steroid is applied only to inflamed areas.

Antihistamines such as hydroxyzine (25 mg three times daily), cyproheptadine hydrochloride (4 mg three times daily), and doxepin (75–150 mg/d) can be useful for relieving pruritus. They may be as useful for their associated antiserotonin, anticholinergic, anxiolytic, and sedative effects as for their antihistaminic effect. Topical antipruritic lotions such as Sarna lotion (camphor, menthol, phenol; manufactured by Stiefel, Coral Gables, Fla.) may also be helpful.

Antibiotics are often useful in the management of acute episodes as secondary impetiginization is very common. Erythromycin and dicloxacillin (for both drugs, 250–500 mg twice daily for 10 d) are useful agents and topical mupirocin (applied topically twice daily for 10 d) has been shown to be effective.<sup>19</sup>

Coal tar may be a useful adjunct to therapy. Liquor Carbonis Detergens (coal tar, nonproprietary) can be compounded with a topical steroid such as triamcinolone acetonide. This particular combination can be quite effective.

Phototherapy can be very beneficial in the management of atopic dermatitis. Successful results have been reported with PUVA,<sup>127</sup> UV-B,<sup>128</sup> and a combination of UV-A and UV-B.<sup>129</sup> As these modalities command significant patient cooperation and sophistication, and have long-term risks, they are not recommended for preadolescents. Because PUVA has the greatest long-term risks, it should be reserved for severe, refractory cases.

A time-honored treatment for atopic dermatitis is the Scholtz method developed over 25 years ago.<sup>130</sup> In a modified and simplified form, it consists essentially of

- reducing bathing to a 1-minute shower,
- avoiding soaps (use Cetaphil lotion [manufactured by Owen/Galderma Laboratories, Fort Worth, Tex.] as soap substitute),

- avoiding greasy preparations, and
- applying mild topical steroid solutions (eg, Synalar [fluocinolone acetonide, manufactured by Syntex Laboratories, Palo Alto, Calif.]

In addition, erythromycin (250 mg four times daily) is advocated for any secondary bacterial infections. Vitamin A and desiccated thyroid, although part of Scholtz' original regimen, are not recommended by this author. However, several clinicians have reported excellent results employing the Scholtz method.<sup>131,132</sup>

Usually, however, in managing atopic dermatitis, no one regimen is effective for all patients. Management must be individualized, with particular attention focused on each patient's specific precipitating factors. In most cases, control will be maintained with basic therapy emollients, mild-to-midpotency topical steroids or coal tar products, and antihistamines. Other modalities discussed should be reserved for severe, refractory cases.

### Military Considerations

One need only glance at the common precipitating factors (see Exhibit 20-3) to realize that life in the military can be hostile for the individual with atopic dermatitis. It is difficult, if not impossible, to eliminate all of these factors from the military environment. It is not surprising, then, that Sulzberger estimated that atopic dermatitis accounted for 3% to 5% of all disease-related military discharges during World War II.<sup>133</sup> It was the opinion of most dermatologists who served in World War II that it was not prudent to send overseas any man with a history of atopic dermatitis, as these men frequently required prolonged and repeated hospitalization.<sup>62</sup>

Frequently, an individual will appear to have "outgrown" his or her atopic dermatitis and, indeed, will not have experienced an outbreak for several years. It is important to remember, however, two features of the atopic diathesis: a propensity for hand dermatitis, and an impaired cellular immune response. Both factors are negative considerations for a military career.

Hand dermatitis is most likely to result from exposure to chemical irritants. Often, the exposure is occupationally related. Studies have determined that of patients with an occupational dermatitis, 85% have a personal or family history of atopic disease.<sup>134,135</sup> An individual with a history of atopic dermatitis and a propensity for developing hand dermatitis would be disqualified from many mili-

tary occupations in order to avoid duty-related exposure to irritant chemicals.

Impaired cellular immunity renders the atopic patient susceptible to disseminated vaccinia infection (eczema vaccinatum). For this reason, small-

pox vaccination becomes dangerous, even if the atopic dermatitis is in remission. Although small-pox vaccination is no longer recommended, the military could require it under special circumstances.

## URTICARIA

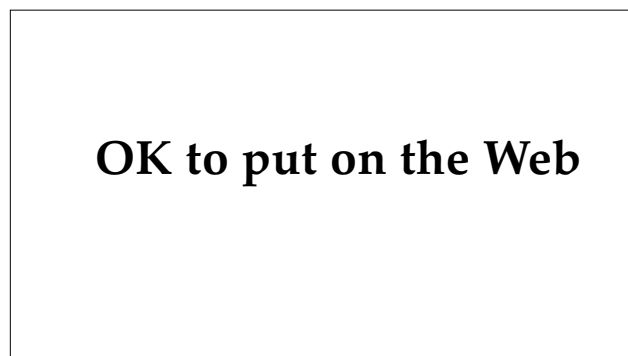Urticaria is a common pruritic eruption, marked by characteristic evanescent lesions known as wheals. It affects approximately 15% to 20% of the population at some point during their lifetime.<sup>136</sup> Wheals are, by definition, superficial in nature. When the edematous process spreads to involve the deep dermis and subcutaneous tissue, then it is termed angioedema (Figure 20-19). The edema can involve other organ systems, particularly the cardiopulmonary system and the gastrointestinal tract. Patients can present with urticaria alone (40%), angioedema alone (10%), or urticaria and angioedema combined (50%).<sup>137</sup>

### Clinical Features

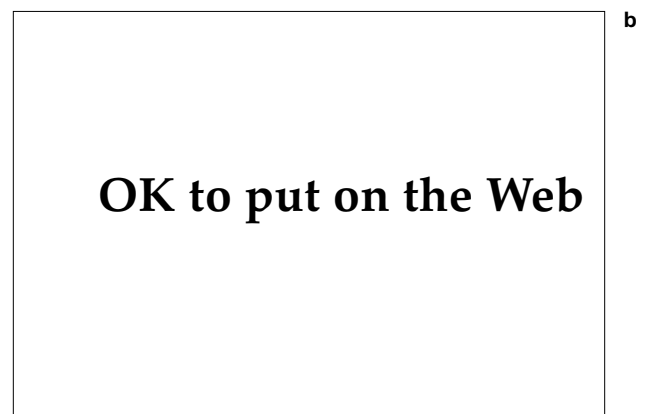
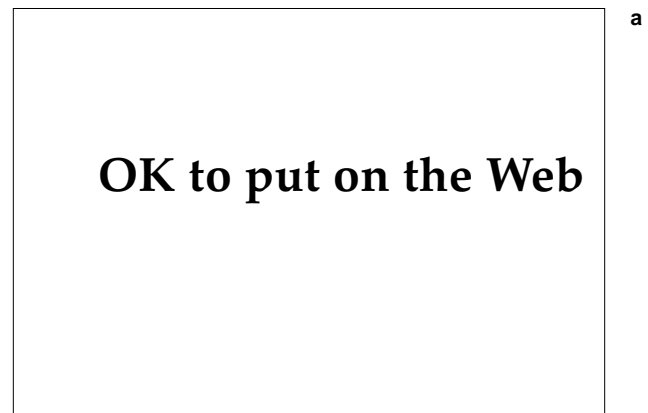The clinical hallmark of urticaria is the wheal or hive. It is an elevated, sharply demarcated, pale red or white, dermal flat-topped plaque with no associated epidermal change. Wheals may be bordered by a thin, pale, or red halo (Figure 20-20). Their size varies from a few millimeters to several centimeters and they may be round or oval or coalesce into large, bizarre polycyclic or serpiginous forms. The most characteristic feature of the wheal is its evanescent nature. Although the process can last weeks or even months, individual lesions usually resolve in a matter of hours and

rarely persist beyond 24 hours. Wheals are typically quite pruritic and can occur anywhere on the integument.

The occurrence of systemic symptoms is not unusual in urticaria or angioedema. For this reason, a thorough history—including an extensive review of systems—and a physical examination are required. Associated symptoms include arthralgias, headache, hypotension, hoarseness, dyspnea, abdominal pain, nausea, and diarrhea. Because angioedema is a deeper process that more commonly involves mucosal surfaces, it is more likely



**Fig. 20-19.** Angioedema. Note marked hand swelling in this man who is taking captopril.



**Fig. 20-20.** Hives. (a) Close-up view of typical pale, edematous wheal with no epidermal change. (b) Note peripheral erythematous halo.



to cause these systemic symptoms, which can be life-threatening.

Urticaria has an unpredictable course. The majority of cases are acute and self-limited with spontaneous resolution after a few hours to several days. Many of these patients do not seek medical attention. Urticaria that persists beyond 8 to 12 weeks is arbitrarily classified as chronic urticaria. Approximately 50% of patients are lesion-free in less than 1 year, while 20% may experience recurrent episodes beyond 20 years.<sup>138</sup>

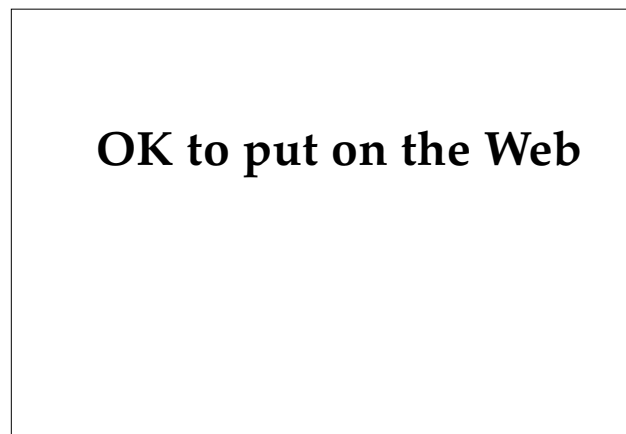### Types of Urticaria

The urticarias can be grouped in a variety of clinical entities. Champion has described some 50 separate classifications.<sup>139,140</sup> Some of the more important types of urticaria are discussed below.

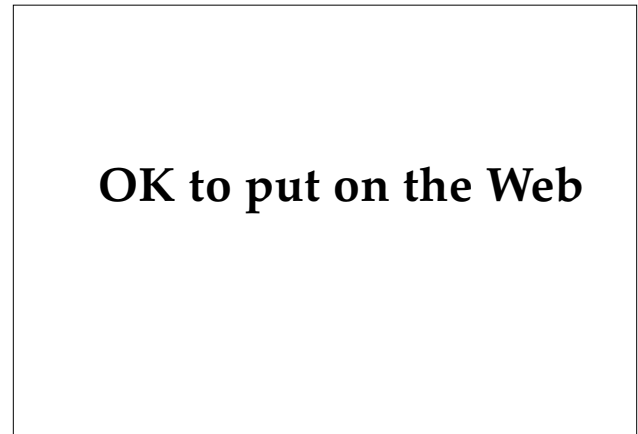
#### *Physical Urticarias*

The physical urticarias account for approximately 16% of all urticarias seen in specialty clinics.<sup>139</sup> Over 20 types have been described. Understanding physical urticaria will permit the identification and possible elimination of the etiologic mechanism, thus preventing recurrent episodes.

Dermatographism is the most common of the physical urticarias (Figure 20-21). It is easily reproducible by the firm, brisk stroking of the skin with a blunt-tipped object. The resultant wheal occurs in minutes in the exact location that the pressure was applied. It can be elicited in approximately 1.5% to



**Fig. 20-21.** Wheal and flare appeared after firm stroking of the back. Such physically induced urticarial response (dermatographism) may be seen in otherwise normal individuals.



**Fig. 20-22.** Pressure urticaria. Wheals occurred when the patient lay on his back for prolonged periods. The circled wheals occurred at the exact location where pressure had been previously applied with a ballpoint pen.

4% of healthy individuals.<sup>141</sup>

Pressure urticaria is a much less common form, characterized by deep, sometimes painful, wheals that occur at sites exposed to deep pressure for prolonged periods (Figure 20-22)—usually the buttocks or feet. The timing of these wheals is unique in that they occur hours after pressure has been applied and often persist for more than 24 hours. In a study of 44 patients with pressure urticaria, Daves et al<sup>142</sup> determined that the mean onset of whealing was 3.5 hours with a peak at 10 hours, and a mean lesion duration of 36 hours. In their experience, systemic corticosteroids were the only effective treatment. Fifty percent of the patients also exhibited delayed dermatographism. Delayed dermatographism has also been described<sup>143</sup> as an independent entity, distinct from pressure urticaria. In general, however, dermatographism is easily distinguished from pressure urticaria by its immediate onset (minutes versus hours).

Cold urticaria represents from 1% to 7% of all forms of the physical urticarias.<sup>144,145</sup> It occurs in an acquired and a familial form with autosomal dominant inheritance. The primary acquired form is the most common (96%),<sup>146</sup> and the familial form is quite rare.<sup>147</sup> Cold urticaria has been associated with cryoglobulins, cryofibrinogens, cold agglutinins, and paroxysmal hemoglobinuria.<sup>146</sup> Such cases are referred to as secondary acquired cold urticaria. In response to cold stimuli, localized symptoms are produced (erythema, pruritus, wheals), as well as systemic manifestations including respiratory distress, hypotension, and even anaphylaxis. The di-

agnosis is easily confirmed by applying an ice cube to the skin. A wheal will occur several minutes later during the rewarming phase. The ice cube test is negative in the familial type.<sup>147</sup> The duration of cold urticaria is from 3 weeks to over 37 years.<sup>146</sup> Patients are advised to avoid cold climates and rapid decreases in temperature, as may occur in ocean swimming.<sup>148</sup>

Solar urticaria is a rare condition characterized by wheal formation within minutes of sun exposure, sometimes with associated systemic symptoms. Lesions can be induced by light of varying wavelengths from the UV-B range (290–320 nm) to the visible light spectrum (> 400 nm).<sup>149</sup> Although the precise mechanisms of lesion induction are not entirely clear, Leiferman et al<sup>150</sup> have provided convincing evidence for the role of eosinophil degranulation in the pathogenesis. In addition, a circulating photoallergen has been described<sup>151</sup> that is generated by absorption of light energy. Removal of this factor by plasmapheresis has been shown<sup>152</sup> to result in prolonged remission. Tolerance may be induced by PUVA<sup>153</sup> or UV-A alone.<sup>154,155</sup>

Aquagenic urticaria is precipitated by contact with water, regardless of temperature. It is a rare condition that resembles cholinergic urticaria (described below). Shelly and Rawasley<sup>156</sup> reported successful control with ChlorTrimeton (chlorpheniramine maleate, manufactured by Schering Corp., Kenilworth, N.J.), 4 mg four times daily. Aquagenic urticaria is a separate clinical entity from aquagenic pruritus.<sup>157</sup>

Vibratory angioedema is also a rare condition in which localized erythema and edema occur in response to vibration. Autosomal dominance has been described,<sup>158</sup> as well as an acquired form that can be occupationally related.<sup>159</sup> A good therapeutic response to terfenadine (60 mg twice daily) has been reported in at least one case.<sup>160</sup>

Localized heat urticaria, another rare physical urticaria, occurs in response to skin exposure to heat above 43°C. Successful induction of tolerance through graduated incremental exposure under medical supervision has been reported.<sup>161</sup>

### **Cholinergic Urticaria**

In cholinergic urticaria, which accounts for 4% of urticarias,<sup>137</sup> wheals are provoked by heat, emotion, or gustatory stimuli. The lesions produced are characteristically tiny (1–3 mm), markedly pruritic, and persist for roughly 45 minutes to 1 hour. The cutaneous response is felt to be produced by the

action of acetylcholine on the mast cell.<sup>136</sup> A new entity of exercise-induced anaphylaxis that is distinguishable from cholinergic urticaria has been described.<sup>162</sup> Cholinergic urticaria is usually easily treated with antihistamines.

### **Contact Urticaria**

Contact urticaria is an uncommon condition that consists of a wheal-and-flare response to a variety of substances applied to the skin, and occurs within 20 to 30 minutes after application. Anaphylaxis can result; it has been described in 12 individuals during surgery, and was caused by their hypersensitivity to natural latex in the surgical glove.<sup>163</sup>

### **Urticarial Vasculitis**

Leukocytoclastic vasculitis presenting as urticaria or angioedema was first recognized at the Mayo Clinic.<sup>164</sup> The cutaneous findings may be identical to common urticaria except that the wheals may be somewhat purpuric, tend to persist for 3 to 5 days, and often heal with residual hyperpigmentation. It is an important entity to recognize because of its frequent association with systemic diseases such as serum sickness, systemic lupus erythematosus, Sjögren's syndrome, and infections such as viral hepatitis type B.<sup>165</sup>

### **Hereditary Angioedema**

Hereditary angioedema is a rare cause of angioedema with its onset in childhood and autosomal dominant inheritance. The episodes of swelling usually recur frequently, are often painful and persistent, and are aggravated by trauma.<sup>140</sup> This form of angioedema occurs without urticaria, so the presence of wheals should exclude the diagnosis. The angioedema is due to a lack of functional C1 esterase inhibitor, an enzyme that controls complement activation. The inhibitor may be diminished in quantity, or may be present but dysfunctional.<sup>166</sup> Daily administration of danazol, an anabolic steroid, may prevent attacks.

### **Urticaria due to Histamine-Releasing Agents**

Many substances (Exhibit 20-4) are capable of causing direct mast cell degranulation with subsequent histamine release. This is not an immunomodulated mechanism. The resultant wheals occur shortly after exposure. Aspirin may exacerbate

**EXHIBIT 20-4****AGENTS CAPABLE OF DIRECT HISTAMINE RELEASE**

Exhibit 20-4 is not shown because the copyright permission granted to the Borden Institute, TMM, does not allow the Borden Institute to grant permission to other users and/or does not include usage in electronic media. The current user must apply to the publisher named in the figure legend for permission to use this illustration in any type of publication media.

Adapted with permission from Burrell BA, Halpean GM, Huntley AC. Chronic urticaria. *West J Med.* 1990;152:269.

urticaria by altering the production of prostaglandins and leukotrienes, but not by direct histamine release.<sup>140</sup> Contact urticaria can occur via exposure to direct histamine-releasing agents. When evaluating angioedema of the oral mucosa, one should consider the possibility of contact urticaria from cinnamic acid or cinnamaldehyde, which are common ingredients in toothpaste.

***Immunoglobulin E-Mediated Urticaria***

Although many patients as well as physicians assume that most cases of urticaria are immunoglobulin (Ig) E-mediated, in fact only 3% to 4% actually are.<sup>140</sup> This type of urticaria requires exposure to an allergen, which can occur via inhalation (pollen, spores, animal dander), ingestion (food, food additives, drugs), or injection (Hymenoptera stings, drugs). Of the drugs, penicillin is the most common cause of IgE-mediated urticaria.

***Idiopathic Urticaria***

Idiopathic urticaria is, by far, the most common category that the physician will see. Many cases

that have an obvious cause will be self-evident, so those patients will often not seek medical attention. The process may be multifactorial, so careful history taking is mandatory to try to uncover possible precipitating factors (Exhibit 20-5).

**Diagnosis**

It is tempting to order multiple screening laboratory tests to rule out the rarer causes of urticaria. Although it may be reasonable to order a few tests, such as a complete blood count or an erythrocyte sedimentation rate, extensive laboratory investigation is often pointless and expensive, and should not be routine. What is important and should be routine is a thorough history and physical examination. The history should be directed at determining whether or not a definable type of urticaria exists that may be related to a physical stimulus, an inhalant, an ingested substance, a systemic disease, an infection, or emotional stress. The information obtained from both the history and the physical will guide any laboratory evaluation. If no specific cause is found, and the symptoms warrant, the patient should be treated empirically.

**Treatment**

The majority of patients with idiopathic urticaria will respond to antihistamine therapy. H<sub>1</sub>-receptor antagonists are the major class of therapeutic agents employed in the management of urticaria. Atarax (hydroxyzine, manufactured by Roerig, New York, N.Y.), 25 mg three times daily, is an excellent first-line therapy and dose may be increased to tolerance, with sedation being its primary dose-limiting effect. It is often useful to add a second H<sub>1</sub> blocker from a different chemical class. Combination with an H<sub>2</sub>-receptor blocker such as cimetidine (300 mg four times daily) may also be helpful.<sup>167</sup> Similarly, good results have been obtained with doxepin (75–150 mg/d), an antidepressant with known anti-H<sub>1</sub> and anti-H<sub>2</sub> activity, in the management of chronic idiopathic urticaria.<sup>168</sup>

Because of the problems with sedation from the traditional antihistamines available, much effort went into the development of newer agents with fewer central nervous system (CNS) side effects. Of these second-generation antihistamines, Hismanal (astemizole, manufactured by Janssen Pharmaceuticals, Piscataway, N.J.), 10 mg daily, is the only one currently approved for the treatment of urticaria, but Seldane (terfenadine, manufactured by Marion

**EXHIBIT 20-5**

**CAUSES OF URTICARIA**

<b>Foods</b>	<b>Drugs</b>	<b>Systemic Diseases</b>
Shellfish	Aspirin	Thyroid disease
Eggs	Penicillins	Systemic lupus erythematosus
Milk	Cephalosporins	Malignancies
Cheese	Aminoglycosides	Serum sickness
Nuts	Sulfonamides	<b>Other</b>
Berries	Barbiturates	Candida sensitivity
Tomatoes	Hydralazine	Worms/infestations
Chocolate	Phenylbutazone	Psychological
<b>Food Additives or Contaminants</b>	Tranquilizers	
Salicylates	Hydantoins	
Tartrazine	Quinine	
Tyramine	Angiotensin-converting enzyme inhibitors	
Benzoates	<b>Infections</b>	
Hydroxybenzoates	Chronic bacterial (sinus, dental, urinary tract, etc.)	
Sulphites	Viral (hepatitis, Epstein-Barr, coxsackie)	
Azo dyes		
Penicillin		
Yeasts		
Citric acid		

Data sources: (1) Burrell BA, Halpean GM, Huntley AC. Chronic urticaria. *West J Med.* 1990;152:268–276. (2) Champion RH. Urticaria: Then and now. *Br J Dermatol.* 1988;119:427–436.

Merrell Dow, Kansas City, Mo.), 60 mg twice daily, can also be beneficial.<sup>169</sup>

**Military Considerations**

Because most cases of urticaria resolve spontaneously in a short period of time, they usually do not become a problem of any special significance in the military. Patients with a physical urticaria could have military occupational exposures that would exacerbate the disease. This obviously poses a potential threat to their health and safety, or to the safety of others, as well as to mission accomplishment. It is hard to imagine a career in the military, particularly in time of war, protected from physical stresses such as heat, cold, pressure, or vibration. Although comprehensive etiologic studies of urticaria and angioedema are not available from

World War II, hospital admission statistics do reveal that there were almost 30,000 admissions for urticaria and more than 7,000 for angioedema between 1942 and 1945.<sup>62</sup> In dermatology clinics in Vietnam, urticaria was seen in 1.75% to 2.74% of patients examined.<sup>2</sup>

Another aspect of urticaria that the military physician must consider is the potential harm from the side effects of therapy. As discussed, antihistamines, the mainstay of therapy for urticaria, can have profound CNS side effects—particularly sedation. Again, this could jeopardize individual safety and mission accomplishment. Thus, the physician must address each patient’s military occupation and consider imposing temporary duty restrictions. The newer antihistamines, by virtue of their diminished permeability of the blood–brain barrier, will lessen the hazards.

## PSEUDOFOLLICULITIS BARBAE

Pseudofolliculitis barbae (PFB) is a condition that occurs in black men in response to shaving. It is common in the military services, where shaving is mandatory, with the prevalence estimated to be 45%<sup>170</sup> to greater than 80%.<sup>171</sup>

### Clinical Features

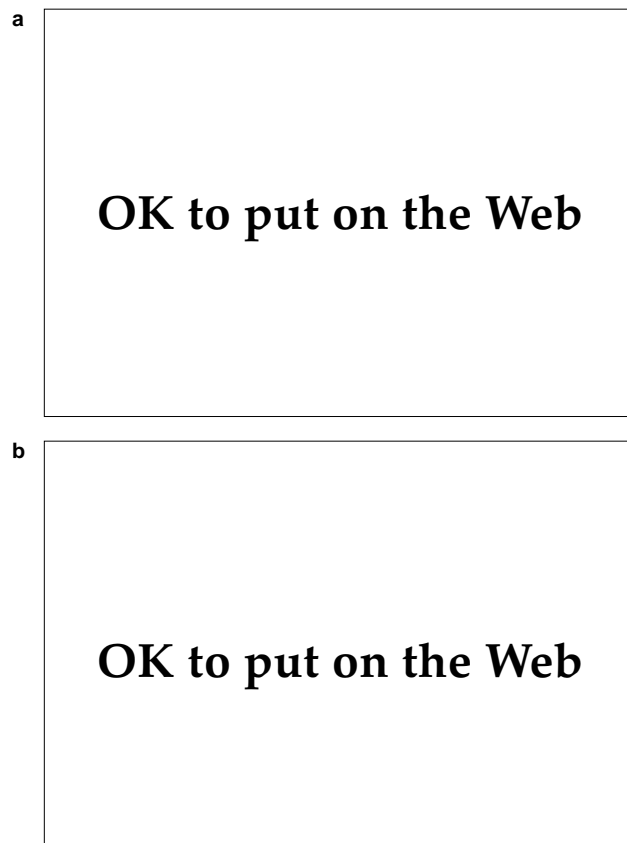
PFB typically manifests as perifollicular, inflammatory papules and papulopustules of the beard area, particularly the anterior portion of the neck and the submandibular region. On close inspection, ingrown hairs are almost always visible (Figure 20-23). In long-standing cases, hyperpigmentation is typical. Severe cases can result in scarring and disfigurement from keloid formation (Figure 20-24).

Acne keloidalis nuchae is a similar condition that

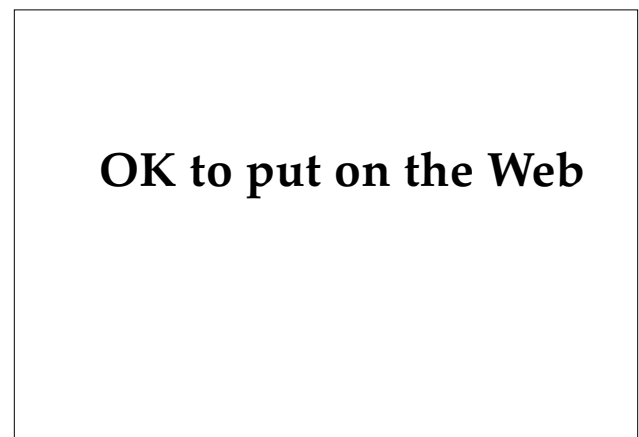occurs on the nape of the neck. It also presents with multiple smooth, flesh-colored papules that are quite firm and may coalesce to form keloids (Figure 20-25). Pustules, cysts, and sinus tracts occasionally form. The condition is aggravated by cutting the hair too close to the skin.

### Pathogenesis

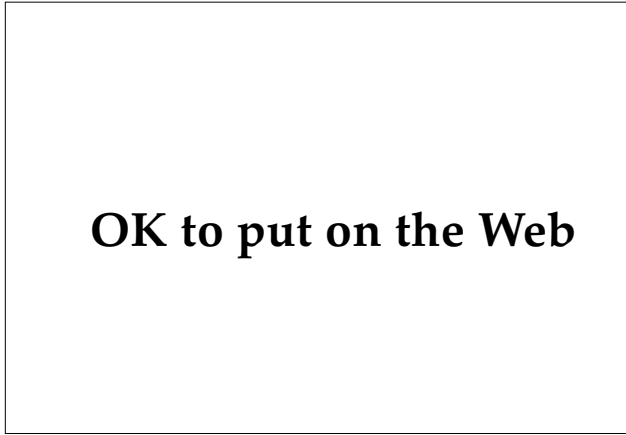The pathophysiological mechanism responsible for PFB has been clearly elucidated. Essentially, it represents a foreign body reaction<sup>172</sup> that is the result of beard hair penetrating the dermis. The tightly curled and undulating surface of hair in black people has several features that facilitate this process. It is elliptical in shape,<sup>173</sup> so it develops a pointed tip when shaved. Furthermore, the hair initially grows parallel to the skin surface,<sup>174</sup> so that when cut obliquely by shaving, the point is even sharper. Finally, because of its tight curl, the hair has a tendency to grow back toward the epidermis, which is easily penetrated by the pointed hair. The actual penetration of the skin can occur via one of two pathways: through the stratum corneum after growing out from the follicle and arching back toward the skin,<sup>174</sup> or by piercing the follicular wall directly.<sup>175</sup> The latter results from applying tension to the skin during shaving, thus allowing the sharpened tip to retract under the skin when tension is released.



**Fig. 20-23.** Pseudofolliculitis barbae. (a) Typical location on anterior neck. (b) Close-up view to show characteristic papules with ingrown hairs.



**Fig. 20-24.** Keloid in an individual with severe pseudofolliculitis barbae.



**Fig. 20-25.** Acne keloidalis nuchae, recurrent after carbon dioxide laser ablation.

### Diagnosis

The clinical presentation of PFB is quite characteristic, so the diagnosis is not a difficult one. It is most often confused with acne vulgaris. The absence of comedones (the primary lesions of acne vulgaris), the restriction of disease activity to the beard area, and the history of onset after close shaving all support the diagnosis. Careful visual inspection with magnification will almost always reveal ingrown hairs in some of the perifollicular papules, confirming the diagnosis of PFB.

### Treatment

Usually, the first phase treatment should be to discontinue shaving and allow beard growth for up to 30 days. By this period of time, most of the

ingrown hairs will have been pulled free by the growth of the hair shaft in a direction away from the skin surface.

The next step is to resume shaving. However, the individual should never attempt a close shave: this will facilitate retraction of the sharpened hairs below the skin surface with subsequent penetration of the follicular wall and renewal of the entire process. The simplest mechanism that avoids this problem is shaving with electric clippers, which produces a stubble shave appearance. Excellent results have been reported with this technique,<sup>176,177</sup> and it is this author's treatment of choice. Patients must also be taught to inspect the beard hair closely and to attempt to free any ingrown hairs with a pick. Use of a coarse facial sponge, such as Buf-Puf (manufactured by 3M Products, St. Paul, Minn.), is also helpful for accomplishing this.<sup>176,178</sup> At the shaving clinic at Lackland Air Force Base, Texas, this method has been successfully initiated at the time of initial patient presentation, without having to wait the customary 30 days. This allows the patient (usually a basic trainee) to maintain a military appearance and control the problem at the same time.

Shaving can also be accomplished with a manual razor, provided that the proper guidelines are followed (Exhibit 20-6). Careful following of these guidelines is time consuming. With practice, it usually requires about 15 minutes. There are no shortcuts. If an individual is usually rushed in the morning, we often recommend shaving in the evening when he can devote the proper amount of attention that is required.

Successful results have also been reported using electric razors<sup>179</sup> and a foil-guarded manual razor specifically designed for patients with PFB (PFB

#### EXHIBIT 20-6

#### SHAVING GUIDELINES FOR PATIENTS WITH PSEUDOFOLLICULITIS BARBAE

1. The beard must be thoroughly hydrated and lubricated; liberal application of shaving cream (foam or gel) will hydrate and soften the beard. Warm, moist heat (hot towel) is also useful.
2. Never pull the skin taut.
3. Never shave over the same area twice; one need shave an area only once, provided the blades are kept sharp by frequent changing (after two shaves).
4. Always shave with the grain of the beard.
5. Carefully inspect the beard area before and after shaving; gently extract the ingrown hairs; avoid plucking.

Shaving System, manufactured by American Safety Razor Co., Staunton, Va.).<sup>180</sup>

Chemical depilatories are also an effective treatment modality.<sup>181,182</sup> Many patients, however, find them irritating. In addition, they are time consuming and they produce a characteristic odor that many patients find bothersome. A minority of patients seem to prefer this mode of treatment.

Keloids may respond to intralesional steroid therapy, which should be instituted early and aggressively to prevent disfigurement. Severe cases have required excision and grafting.<sup>183</sup> The results of surgical therapy are usually disappointing.

Systemic antibiotic therapy is rarely required in the management of PFB, except in those few cases that become secondarily infected. Some authorities claim efficacy for various topical medications such as tretinoin<sup>184</sup> (applied nightly) and clindamycin (applied twice daily).<sup>185</sup> Occasional use of mild topical steroids may also be useful, particularly for relieving any irritation from depilatories.

Patients must be instructed to avoid plucking of hairs as this may cause breakage of the hair shaft within the follicle with subsequent transfollicular dermal penetration and foreign body response.

### Military Considerations

To prevent PFB, one need only grow a beard. Unfortunately, this is contrary to military regulations. This simple fact has created much strife. In the past, the lack of a consistent policy regarding shaving requirements and the management of PFB from an administrative as well as medical viewpoint turned a relatively minor medical problem

into a major social issue. Racial tension over this led to public demonstrations and even frank mutiny by disgruntled black enlisted members in the 1970s.<sup>171</sup> In 1979, one investigator wrote that "pseudofolliculitis barbae has now become the most significant dermatologic disease in the U.S. Army"<sup>171(p62)</sup> and some military dermatologists called for "the pan-service acceptance of the voluntary growth of a beard by any service member".<sup>170(p459)</sup>

Fortunately, the lack of a consistent policy was recognized and rectified so that today, PFB clinics are functioning smoothly throughout the military. Administrative guidelines are clearer, commanders are better informed, and medical providers are better educated on the unique problems regarding PFB.

The importance of keeping PFB under control without growing a beard is not simply to maintain a uniform, clean shaven appearance. It is also important for the safety of the individual in a combat environment, where the threat of chemical weapons is ever present. Although tests on the efficacy of gas masks reveal that beard growth of as much as 1/8 in. (up to 3 d) did not significantly alter the seal to the mask,<sup>186</sup> it seems obvious that excessive beard growth would have an adverse effect on the seal. An individual whose PFB was poorly controlled and who required a 30-day profile to allow for beard growth, would likely require evacuation to the rear. Thus, proper management of a common condition like PFB is essential for avoiding unnecessary loss of manpower. The key to the successful management of PFB will always be education and communication among soldiers, healthcare providers, and supervisors.

## CUTANEOUS VIRAL INFECTIONS

### Herpes Simplex Labialis

Herpes simplex labialis is the condition commonly referred to as "fever blisters." It is caused by herpes simplex virus (HSV), a double-stranded DNA virus, of which two types exist. Most infections involving the oral mucosa are of type 1, while type 2 is responsible for most HSV infections involving the genitalia (genital herpes is discussed in Chapter 19, Sexually Transmitted Diseases). Like all herpes viruses, HSV-1 is able to persist in a latent form in its host, causing recurrent outbreaks.<sup>187</sup> It occurs worldwide, and by the fourth decade of life more than 90% of the population have developed antibodies to HSV.<sup>188</sup> Thus, recurrent HSV labial infec-

tion is an extremely common condition; it affects 20% to 40% of the adult population.<sup>189</sup>

#### Clinical Features

Pharyngitis and gingivostomatitis are the usual manifestations of primary infection with HSV-1, seen most commonly in children and young adults.<sup>190</sup> Vesicles or erosions may be seen on the palate, gingiva, tongue, lip, or perioral region of the face.<sup>191</sup> Primary infection usually is associated with fever and cervical adenopathy as well, and is most severe in adults.

Recurrent infection manifests as vesicles or erosions on the vermilion border of the lip (Figure 20-26) that usually crust over within 48 hours. Of-

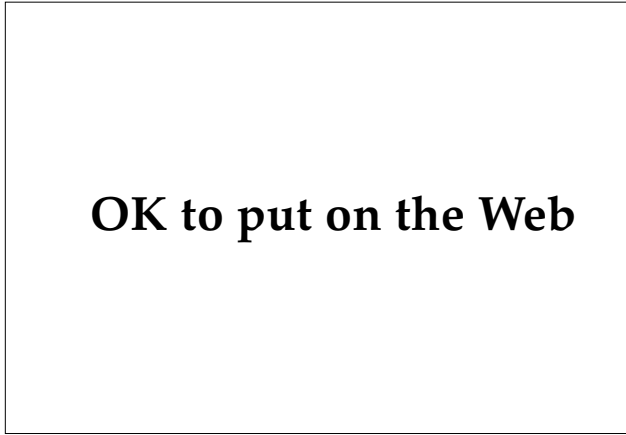

Fig. 20-26. Herpes simplex labialis. Note intact vesicle.

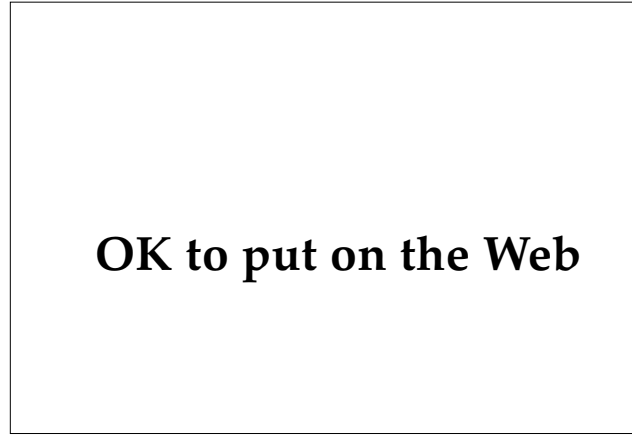

Fig. 20-27. Targetlike lesions in erythema multiforme. Note vesiculation.

ten, the patient experiences burning and itching at the site prior to vesicle formation. The rate of recurrence varies between 16% and 45%.<sup>192</sup> Recurrent outbreaks represent reactivation of the virus from its latent form in the trigeminal ganglion.<sup>192</sup> Although the exact mechanism of reactivation is not known, it is assumed that the virus travels down the axon of the nerve to infect keratinocytes on the adjacent location on the lip. Many precipitating factors have been identified including trauma, UV light exposure, fever, immunosuppression, psychological stress, and exposure to excessive amounts of alcohol, tobacco, or spicy foods.<sup>193,194</sup>

Recurrent HSV-1 outbreaks can precipitate a reaction known as erythema multiforme, an acute, widespread eruption with characteristic targetlike lesions (Figure 20-27). Antiviral therapy with acyclovir has been shown to prevent relapses of recurrent erythema multiforme.<sup>195</sup>

### Diagnosis

Grouped vesicles or crusted erosions on the lip are strongly suggestive of HSV infection. Lesions that are secondarily infected with bacteria may be difficult to distinguish from primary impetigo, which is characterized by honey-colored crusts. A history of recurrence in the exact location of episodes of minor trauma or stress or UV light exposure support the diagnosis of herpes simplex. Primary gingivostomatitis may resemble aphthae, hand-foot-and-mouth disease (coxsackie virus), Behçet's syndrome, or Stevens-Johnson syndrome.

The diagnosis of HSV infection is facilitated by performing a Tzanck smear. Material is obtained by scraping the base of a vesicle or erosion. The specimen is then smeared on a glass slide, stained with Wright's stain, and examined under the microscope. In HSV-infected tissue, multinucleated giant cells and/or keratinocytes with large, pale nuclei with peripheral clumping of chromatin will be seen (Figure 20-28). In addition, culture confirmation of HSV is available through most laboratories. Confirmation of HSV infection through detection of the virus's DNA by polymerase chain reaction, an exquisitely sensitive technique, has been described<sup>196</sup> but is expensive and impractical for ordinary use.

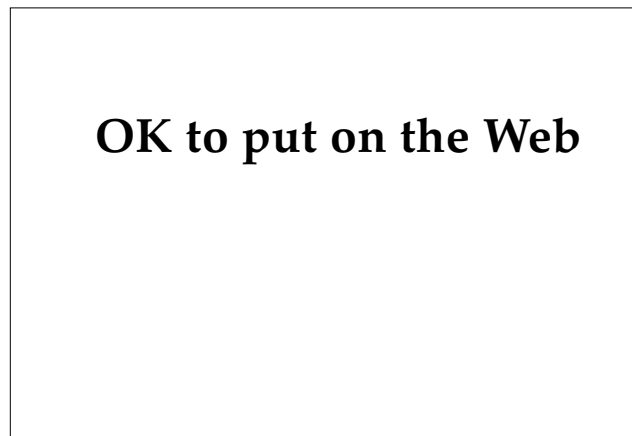


Fig. 20-28. Tzanck smear (original magnification 100X). Note the large multinucleated keratinocyte in the center.



### Treatment

In most instances, systemic treatment of herpes simplex labialis is not required. Cool compresses and topical application of an antibiotic ointment may promote healing and prevent bacterial superinfection. Topical acyclovir is ineffective in immunocompetent individuals.<sup>197</sup> Patients may benefit from oral acyclovir (200 mg five times daily) if initiated immediately after symptom onset.<sup>198</sup>

Recurrences of herpes simplex labialis can be decreased by prophylactic administration of oral acyclovir (200 mg three times daily).<sup>199</sup> In most cases, the expense of this method of treatment precludes its use. It is indicated, however, for patients with recurrent erythema multiforme due to HSV.<sup>195,200</sup> It has also been shown to be of practical value in individuals with a history of UV radiation-induced herpes simplex labialis who are going to be exposed to periods of intense UV exposure such as

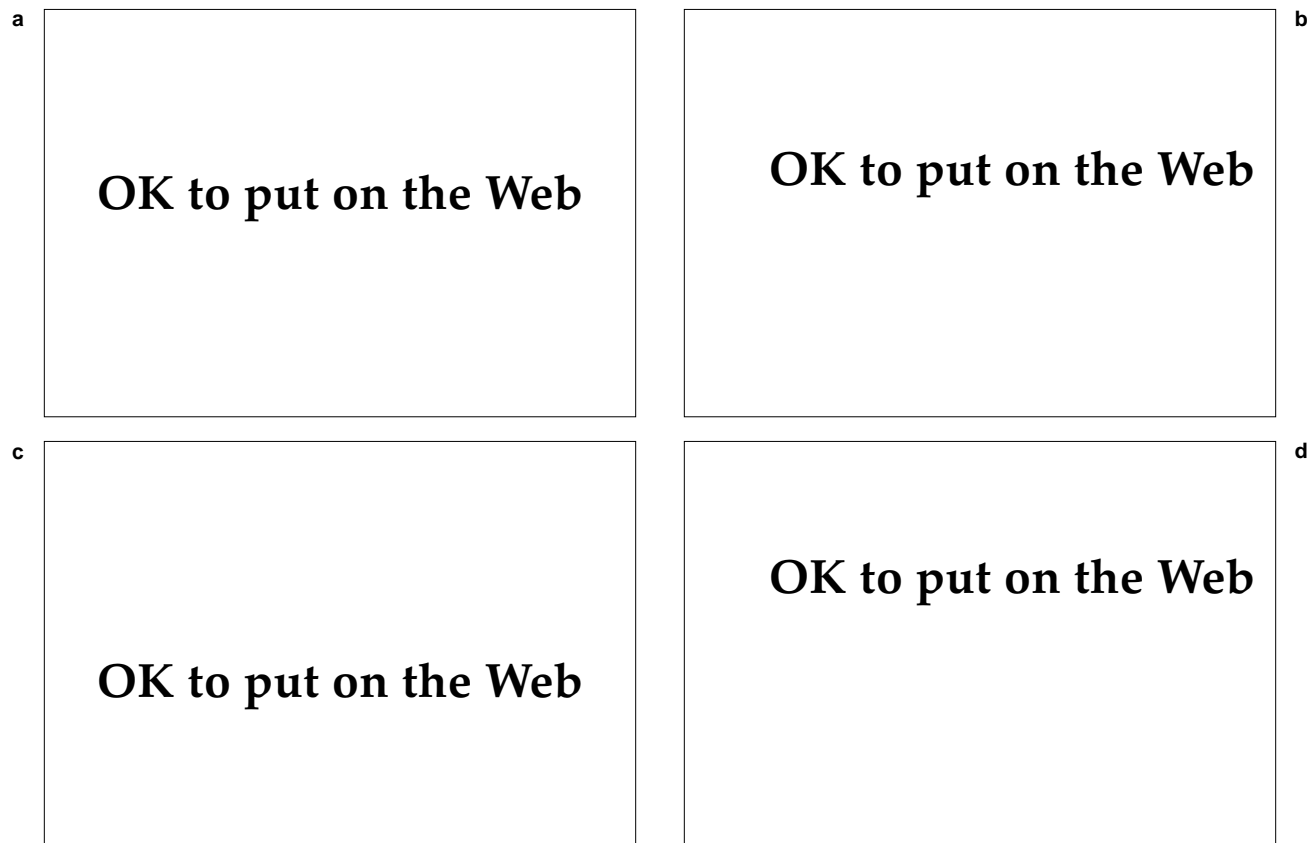
snow skiing (or desert deployment).<sup>199,201</sup> Zinc oxide, a complete sun blocker, should also be considered for these individuals.

### Herpes Zoster

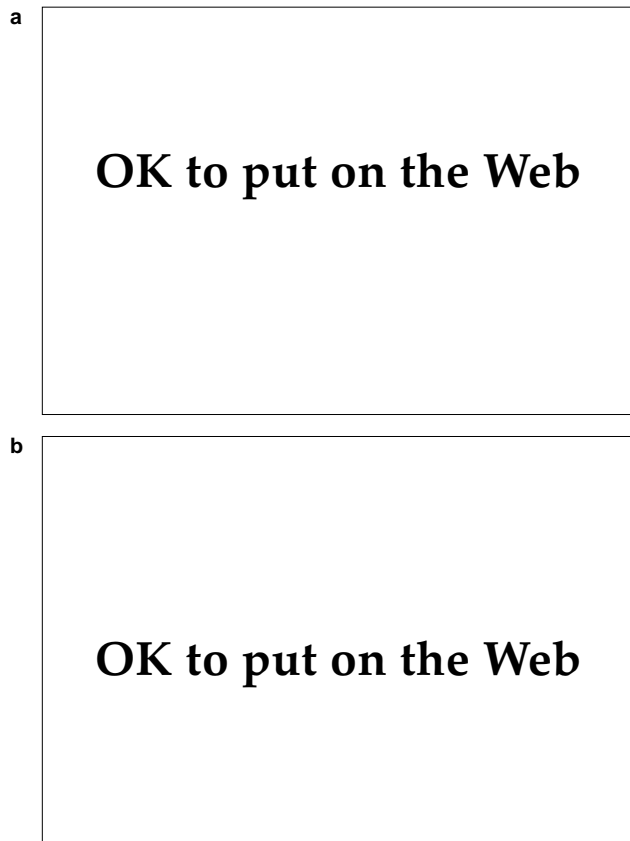
Herpes zoster, also called shingles, is a common neurocutaneous disease caused by the varicella-zoster virus (VZV), a member of the herpesviridae group, which is also the etiologic agent for chickenpox. It occurs in 1.3 to 4.8 persons per 1,000 per year,<sup>202-204</sup> and is characterized by a vesicular eruption in a dermatomal distribution. Often, it is associated with varying degrees of pain, which may persist beyond the point of healing of the rash.

### Clinical Features

Herpes zoster occurs in individuals with a previous history of varicella. Patients typically present



**Fig. 20-29.** Herpes zoster. (a) Thoracic dermatome. Note sharp cutoff at the midline. (b) Close-up view of (a) to reveal characteristic grouped vesicles on an erythematous base. (c) Lumbar distribution. (d) Sacral distribution with sharp cutoff at midline; note vesicles coalescing and becoming purpuric.



**Fig. 20-30.** Herpes zoster. Vesicles have coalesced into larger bullae, which have become (a) purpuric or (b) pustular.

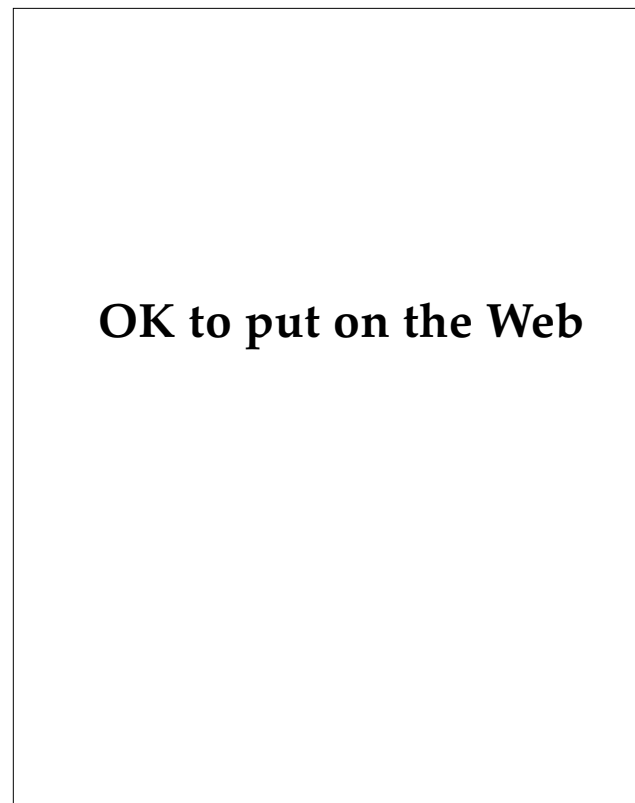
with grouped vesicles on an erythematous base in a dermatomal distribution (Figure 20-29). A generalized eruption may occur in 2% to 5% of patients, particularly in elderly or immunocompromised patients.<sup>205</sup> The eruption is almost always unilateral and rarely extends across the midline. The vesicles may coalesce into larger bullae and may become hemorrhagic or even pustular (Figure 20-30). The patients may or may not experience the prodrome of fever, malaise, and headache. Often, the rash is preceded by radicular pain, a burning sensation, or hyperesthesia in the region of the same dermatome. The most common dermatomes involved are the thoracic, followed by the cranial, cervical, lumbar, and sacral. The most common single nerve involved is the trigeminal nerve—usually a single branch.<sup>206</sup>

New lesions can develop for up to approximately 8 days, but usually do not occur after 4 days from the onset of the rash.<sup>207</sup> Crusting occurs in 10 to 14 days, but lesions may persist for longer periods in

elderly or immunocompromised patients. The areas involved may heal with residual postinflammatory hyperpigmentation and can result in significant scarring (Figure 20-31).

#### *Types of Herpes Zoster*

**Herpes Zoster Ophthalmicus.** Involvement of any branch of the trigeminal nerve is called herpes zoster ophthalmicus (Figure 20-32). Although ocular involvement may occur in association with maxillary or mandibular nerve involvement, this is uncommon. Most frequently, the supraorbital and supratrochlear divisions of the frontal nerve are involved. Hutchinson's sign consists of lesions on the nasal tip, which indicate involvement of the nasociliary branch of the ophthalmic nerve and a high likelihood of ocular complications. When Hutchinson's sign is present, immediate ophthalmological consultation is warranted. Eye complications include lid ulceration and scarring; conjunc-



**Fig. 20-31.** Midline and unilateral forehead and eyelid atrophic scars that resulted after healing of herpes zoster infection.

OK to put on the Web

**Fig. 20-32.** Herpes zoster ophthalmicus with marked periorbital and lid edema. Immediate ophthalmological consultation is required.

tivitis; proptosis; keratitis; corneal ulceration, vascularization, or perforation; uveitis; and vascular ischemic injuries.<sup>206</sup>

**Ramsay Hunt's Syndrome.** Ramsay Hunt's syndrome includes facial nerve palsy as a result of involvement of the geniculate ganglion with VZV (Figure 20-33). Vesicles are usually present on the external ear or tympanic membrane, and auditory symptoms may be present such as tinnitus, vertigo, or diminished auditory acuity. Early intervention with systemic steroids may be beneficial. The facial nerve palsy usually resolves, but can be permanent.

**Postherpetic Neuralgia.** The acute pain of herpes zoster is usually of a transitory nature. In some individuals, however, particularly the elderly, severe pain may persist for months and become disabling. The frequency of postherpetic neuralgia varies between 15% and 70%.<sup>205</sup> It is particularly frequent and severe in patients with herpes zoster ophthalmicus. The neuralgia resolves spontaneously in 50% of patients within 3 months and in 75% within 1 year.<sup>208</sup>

### Diagnosis

The presence of grouped vesicles on an erythematous base in a dermatomal distribution, with associated pain in a similar location, creates little question about the diagnosis of shingles. Disseminated cases may resemble primary varicella infection or disseminated HSV. The Tzanck smear will not differentiate the three. Viral cultures are available, but can take up to 2 weeks to grow. Fluorescein-tagged VZV antibody applied to a Tzanck smear may help to differentiate VSV from HSV but requires a fluorescent microscope.

### Treatment

In most cases involving immunocompetent patients, symptomatic treatment will suffice. Cool compresses with Burow's solution will hasten drying and crusting of the vesicles. For analgesia, narcotics may be required.

Acyclovir has been shown to be effective in shortening the duration of disease and reducing the acute and postzoster pain.<sup>209-211</sup> VZV is up to 8-fold less susceptible to acyclovir than HSV,<sup>212</sup> so higher doses are required. The recommended dose is 800 mg orally five times daily for 10 days.

The role of systemic corticosteroid therapy in the treatment of VZV infection is somewhat controversial.<sup>213</sup> A short course (60 mg/d orally for 5 d tapered over 2 wk) combined with a 10-day course of acyclovir may be useful for the prevention of

OK to put on the Web

**Fig. 20-33.** Ramsay Hunt's syndrome: inability to raise eyebrow with ipsilateral drooping of the corner of the mouth.

postherpetic neuralgia in patients at high risk, such as those greater than 60 years old with VSV involving the trigeminal nerve.

### Molluscum Contagiosum

Molluscum contagiosum is a benign cutaneous infection caused by a poxvirus.<sup>214</sup> It occurs in children and young adults and is worldwide in distribution. It is spread by fomites as well as by direct contact,<sup>215</sup> including venereal transmission.<sup>216</sup> (Molluscum contagiosum is also discussed in Chapter 19, Sexually Transmitted Diseases.)

#### Clinical Features

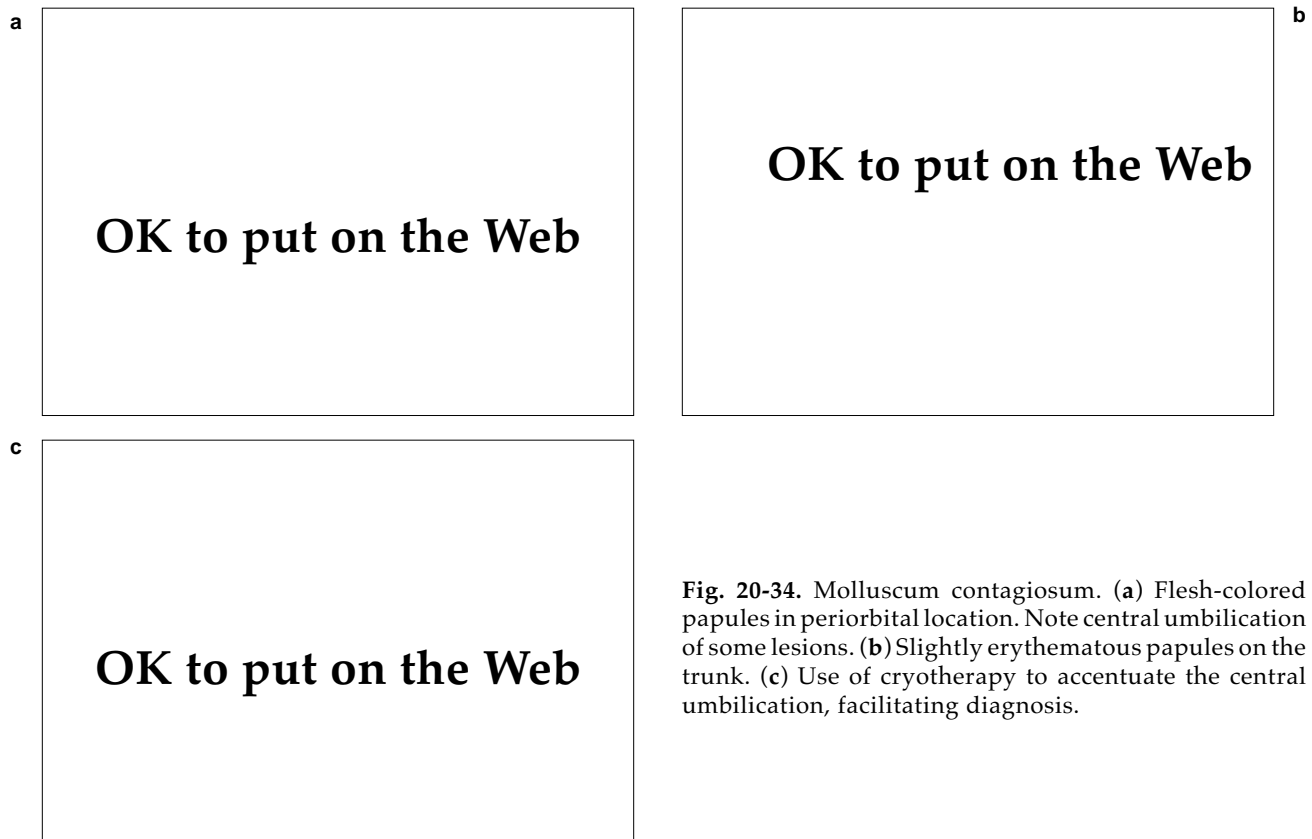The pathognomonic lesion of molluscum contagiosum is a small (2–5 mm), firm, smooth, dome-shaped, translucent papule with a central umbilication. Rapid freezing may accentuate this central depression, thus aiding in the diagnosis (Figure 20-34). With pressure, a white, curdlike substance can be expressed from the center of fully developed lesions. Microscopical examination of a

smear of this substance after staining will reveal the characteristic cytoplasmic inclusions known as Henderson-Patterson bodies.

Patients may have few or numerous lesions. They can occur on any cutaneous site, but have a predilection for the pubic region and adjacent locations in adults; in children, the trunk, face, and proximal extremities are most often involved. In general, the lesions are asymptomatic. Without treatment, the disease will last an average of 6 months to 3 years; individual lesions persist for approximately 2 months.<sup>217</sup>

#### Diagnosis

The appearance of typical, small, umbilicated papules on the exposed areas of children or the area of the genitalia of adults usually leaves little doubt as to the diagnosis of molluscum contagiosum. In acquired immunodeficiency syndrome (AIDS) patients, lesions may appear with atypical features.<sup>218</sup> Recently, there have been reports of cutaneous cryptococcosis in AIDS patients resembling molluscum contagiosum,<sup>219,220</sup> and a case of molluscum contagiosum mimicking a basal cell car-



**Fig. 20-34.** Molluscum contagiosum. (a) Flesh-colored papules in periorbital location. Note central umbilication of some lesions. (b) Slightly erythematous papules on the trunk. (c) Use of cryotherapy to accentuate the central umbilication, facilitating diagnosis.

cinoma in a patient with AIDS.<sup>221</sup> If any doubt exists, demonstration of the pathognomonic Henderson-Patterson intracytoplasmic inclusions by cytological or histological examination will confirm the diagnosis.

### Treatment

When approaching the management of molluscum contagiosum, it is important to consider that it is a benign disease in which the lesions eventually resolve spontaneously. Therefore, one should avoid aggressive treatment that may be painful or result in scarring. Some argue that the disease should not be treated at all, particularly in children.<sup>222</sup> Treatment may be justified, however, as an attempt to shorten the course of the disease, thus preventing viral transmission and autoinoculation.

Treatment involves destruction of the lesions by mechanical means such as curettage, cryotherapy, or electrosurgery or by chemical irritants such as retinoic acid, cantharidin, phenol, podophyllin, or trichloroacetic acid. The most effective of these modalities is probably removal by curettage. The treatment may be facilitated in children by use of newly developed topical anesthetic agents such as eutectic mixture of local anesthetic (EMLA).<sup>223</sup>

### Warts

Warts are benign cutaneous tumors that will affect up to 10% of the population.<sup>224</sup> They are caused by the human papillomavirus (HPV), a virus that has gained a considerable degree of attention due to its ubiquitous nature, tenacity, and oncogenic potential. (Genital warts caused by HPV are discussed in Chapter 19, Sexually Transmitted Diseases.)

The papillomavirus (PV) of the papova group of viruses consists of multiple species that are host-specific such as bovine PV, sheep PV, cottontail rabbit PV (Shope fibroma virus), and HPV.<sup>225</sup> Natural infection by PV is limited to the skin and mucous membranes of the host species. HPV is an ether-resistant virus with icosahedral symmetry and a double-stranded circular DNA.<sup>226</sup> It is the presumed etiologic agent of human warts, based on the facts that DNA and viral particles of HPV have been found in human warts, and filtered extracts of warts will produce papillomas if injected into the skin of human.<sup>227</sup>

At least 55 types of HPV have been recognized based on DNA homology, and each type appears to have some degree of anatomic specificity. For in-

stance, HPV type 4 is associated with common warts, while types 6 and 11 are associated with condyloma acuminata of the genital region.<sup>228</sup> Some types apparently have significant oncogenic potential, particularly types 16, 18, and 31, which are commonly identified in cervical carcinoma.<sup>228</sup>

### Clinical Manifestations

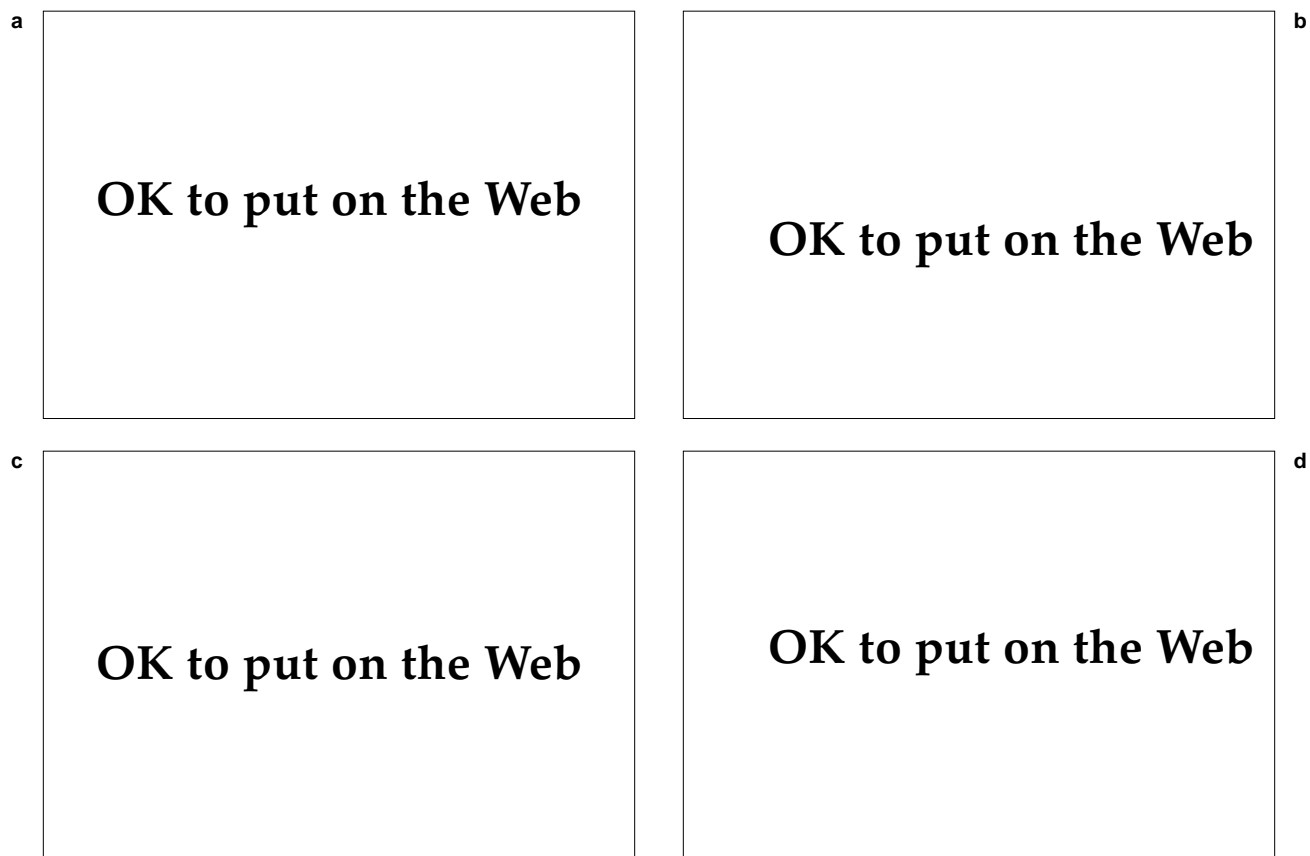
Like all papillomaviruses, HPV can infect the skin and mucous membranes including the genitalia, conjunctiva, oral cavity, and larynx. This discussion is limited to HPV infection of the skin.

**Common Warts.** The common wart (*verruca vulgaris*) is an exophytic, rough-textured, hyperkeratotic papule that is usually painless. Although typically smaller than 1 cm, warts can form larger plaques. Warts can occur almost anywhere on the skin, but are most common on the dorsum of the hands and fingers, particularly in young children (Figure 20-35). Patients may present with single lesions, but multiple lesions are more common since autoinoculation is a frequent process. Common warts will frequently resolve spontaneously after several months, but they may persist or recur after many years. Warts that resolve spontaneously do not scar. When they occur in the periungual region, they may cause nail plate deformities (Figure 20-36).

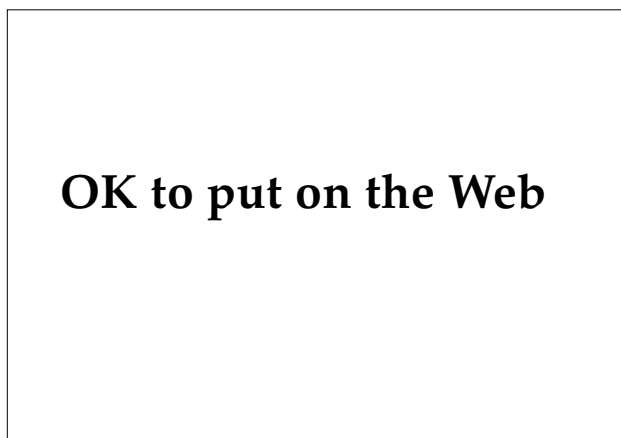
**Flat Warts.** Flat warts (*verruca plana*) are small (1–3 mm), slightly elevated, flesh colored, flat papules that are almost always multiple. They occur mainly on the face, neck, hands, or knees of young adults and adolescents (Figure 20-37), and are resistant to treatment.

**Filiform Warts.** Filiform warts (*verruca filiformis*) occur most commonly on the face. Multiple lesions may be seen, but they are usually single. These are elongated, thin, pointed projections that, although cornified, remain relatively soft.

**Plantar Warts.** Plantar warts (*verruca plantaris*) are of two types: mosaic and myrmecia (Figure 20-38). The most commonly seen are the mosaic types, which appear as multiple flat, slightly elevated, hyperkeratotic papules that are usually coalescent. They are most frequently seen in adolescents overlying the metatarsal heads, and are frequently tender and can cause pain on walking. Close inspection of these warts will reveal the typical coarse surface that is sharply demarcated from the surrounding skin. The normal skin markings are interrupted on the surface of the warts. Paring of the keratotic surface will reveal dark, punctate areas that represent thrombosed capillaries. Continued paring will produce pinpoint bleeding.



**Fig. 20-35.** Common verrucae. (a) Typical grouped warts in a periungual location. (b) Isolated wart on dorsum of hand. (c) Larger wart on thumb; note thrombosed capillaries visible on the surface. (d) Large wart on arm.



**Fig. 20-36.** Periungual wart causing lifting of distal free edge of the nail plate.

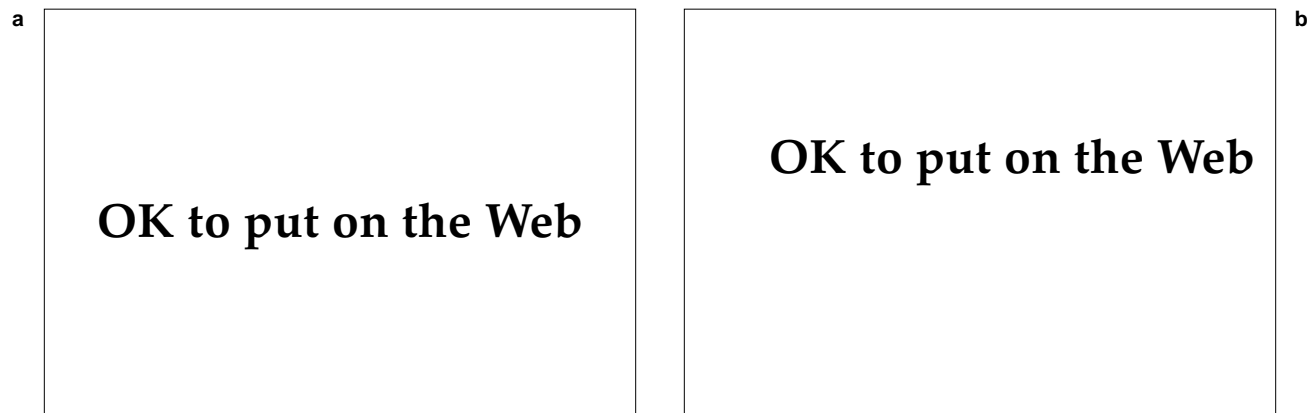


Fig. 20-37. Flat warts. (a) Facial involvement. (b) Lesions on the knee.

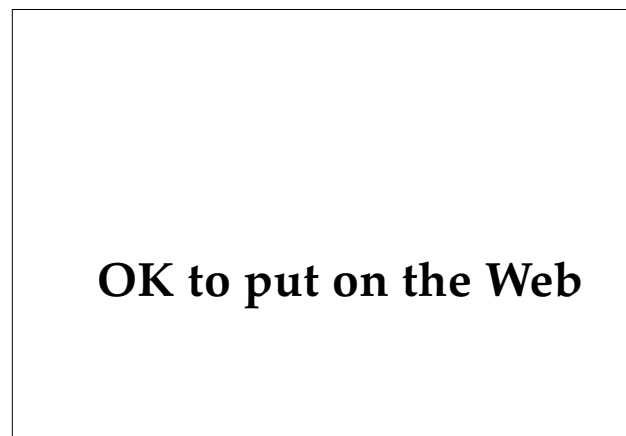

Fig. 20-38. Plantar warts. Mosaic types predominate surrounding a myrmecia type. Location over metatarsal heads is common.

The second type of plantar wart is the myrmecia (“ant hill”) type. These are deeper, dome-shaped papules that frequently become inflamed.

**Other Cutaneous Manifestations.** Epidermodysplasia verruciformis is a rare, inherited disease characterized by widespread verruciform plaques that occur in childhood and persist into adulthood. These plaques represent extensive infection with HPV in individuals with impaired immunity. Squamous cell carcinoma will develop in a large number of these patients, particularly on sun-exposed areas.<sup>229</sup>

The DNA of HPV has been demonstrated in some keratoacanthomas<sup>230</sup> and lesions of Bowen’s disease (squamous cell carcinoma in situ).<sup>231</sup>

### Diagnosis

The morphology of warts usually is distinctive enough to allow diagnosis by visual inspection. At

times they may resemble seborrheic keratoses, actinic keratoses, molluscum contagiosum, cutaneous horns, or acrokeratosis verruciformis of Hopf. Plantar warts may mimic corns (clavi) or calluses. Squeezing a plantar wart usually elicits pain, unlike a callus. In contradistinction to warts, the normal skin markings are accentuated in clavi and calluses. Paring of the warts with a scalpel blade will reveal the characteristic dark, punctate, thrombosed capillaries.

### Treatment

Like molluscum contagiosum, cutaneous warts are generally a benign infectious process that will frequently resolve spontaneously. Spontaneous remission is seen in 40% of patients within 6 months, and 66% in 2 years.<sup>232</sup> Therefore, the physician should avoid overly aggressive treatment that may result in scarring, and be particularly careful to

avoid scarring on the plantar surface as this could cause pain on walking. The modalities available for treating warts are numerous, which speaks for the tenacity of HPV. Recalcitrance is common with warts, and the physician should explain to patients at the initial visit that multiple treatments are sometimes required and recurrences are frequent.

Effective topical keratolytic agents are available. These include salicylic acid, which is available in 40% concentration in a self-adhesive tape (Mediplast, manufactured by Beiersdorf, Norwalk, Conn.) and combined with lactic acid in flexible collodion (Duofilm, manufactured by Stiefel, Coral Gables, Fla.). Both work well under occlusion, if applied daily for several weeks. These may be helpful for treating plantar warts, particularly in children, but can require a fair amount of patience and compliance.

One of the easiest and most effective treatments for warts is curettage with or without electrodesiccation or cryotherapy to the base. Mahrle and Alexander<sup>233</sup> report good results in the treatment of periungual and plantar warts with light focal electrocoagulation, followed by curettage.

Cryotherapy with liquid nitrogen can also be an effective means of eradication. Again, multiple treatments may be required. Bunney et al<sup>234</sup> reported a cure rate of 80% when treating warts on the hands with cryotherapy every 3 weeks for up to 12 weeks.

For warts recalcitrant to the methods already described, particularly periungual or plantar, one might consider intralesional bleomycin<sup>235</sup> or vaporization with the carbon dioxide laser.<sup>236</sup> Facial verruca plana can be most refractory to treatment. Daily application with Retin-A (tretinoin, manufactured by Ortho, Raritan, N.J.) may be helpful, as can

twice-daily application of Efudex (5-fluorouracil, manufactured by Roche Laboratories, Nutley, N.J.).<sup>237</sup>

### Military Considerations

An important consideration for the military physician regarding cutaneous viral infections concerns the role played by stress in triggering outbreaks. The battlefield certainly provides a degree of stress, both emotional and physical, that most people will never experience elsewhere. For this reason, the incidence of infections such as herpes simplex labialis or herpes zoster is likely to be increased. It is extremely important, then, for the military physician to have some useful knowledge regarding their treatment and possible prevention. Some degree of protection may be granted to the individual with a history of UV radiation-induced herpes labialis with the prophylactic use of acyclovir and sun blockers such as zinc oxide. There are no measures available to prevent an episode of shingles. However, the physician can intervene to prevent secondary bacterial infection, which is certainly more likely to occur during wartime, when standards of hygiene are unavoidably lowered. This can be achieved through temporary isolation or hospitalization and the use of topical or systemic antibiotics.

In the treatment of warts, early medical intervention is encouraged to avoid the possible impairment of performance that may occur as the result of widespread involvement of the fingers or the presence of painful plantar lesions. However, overly aggressive treatment should be avoided, because scars or large, iatrogenic bullae could negatively affect performance, permanently or temporarily.

### SUMMARY

It is imperative for the medical officer to have some basic understanding of the common dermatoses. Historically, these skin diseases have had a substantial impact on the number of casualties suffered during armed conflicts. While usually not considered significant threats to an individual's health, these maladies will frequently be exacerbated under battlefield conditions, resulting in significant morbidity with a subsequent negative impact on performance of combat duty.

The common dermatoses are usually not difficult to manage. Prompt recognition and intervention by the medical officer may prevent a simple problem

from rapidly escalating into an incapacitating condition.

Medical officers with a firm grasp on the recognition and management of common skin diseases will be able to intervene easily to maintain the health of individual troops as well as the collective fighting effectiveness of their units. During armed conflict, given the harsh environmental conditions that exist, intervention may be required frequently. Understanding the information contained in this chapter will enable the medical officer to manage these common dermatoses appropriately and skillfully.



## REFERENCES

1. Sulzberger MB, Akerg WA. Impact of skin diseases on military operations. *Arch Dermatol*. 1969;100:702.
2. Allen AM. *Skin diseases in Vietnam, 1965–72*. In: Ognibene AJ, ed. *Internal Medicine in Vietnam*. Vol 1. Washington, DC: Medical Department, US Army, Office of The Surgeon General and Center of Military History; 1977: 29–40.
3. Pillsbury DM, Livingood CS. Experiences in military dermatology. *Arch Dermatol Syphilol*. 1947;55:441–462.
4. Macpherson WG, Horrocks WH, Beveridge WWO, eds. *History of the Great War, Medical Services, Hygiene of the War*. London: His Majesty's Stationery Office; 1923: 68.
5. Baker H. Psoriasis. In: Rook A, Esling FJG, Wilkinson DS, Burton JL, eds. *Textbook of Dermatology*. 4th ed. Oxford, England: Blackwell Scientific Publications; 1988: 1469–1532.
6. Christophers E, Krueger GG. Psoriasis. In: Fitzpatrick TB, Eiseu AZ, Wolff K, Freedberg IM, Austen KF, eds. *Dermatology in General Medicine*. 3rd ed. New York, NY: McGraw-Hill Book Co; 1987: 461–491.
7. Farber EM, Nall ML. The natural history of psoriasis in 5,600 patients. *Dermatologica*. 1974;148:1–18.
8. Van Scott EJ, Ekel TW. Kinetics of hyperplasia in psoriasis. *Arch Dermatol*. 1961;88:373–381.
9. Guilhou JJ, Maynodier J, Clot J. New concepts in the pathogenesis of psoriasis. *Br J Dermatol*. 1978;18:585–592.
10. Krueger GG. Psoriasis: Current concepts of its etiology and pathogenesis. In: Sobson RL, Thiecs BH, eds. *Yearbook of Dermatology*. Chicago, Ill: Yearbook Medical Publishers; 1981: 13–70.
11. Nicholas GD, Helwig EB. Exfoliative dermatitis: A clinicopathologic study of 135 cases. *Arch Dermatol*. 1973;108:788–797.
12. Abrahams T, McCarthy JT, Sanders SR. One hundred and one cases of exfoliative dermatitis. *Arch Dermatol*. 1963;87:96–101.
13. Penneys NS, Ziboh V, Lord J. Pathogenesis of Woronoff ring in psoriasis. *Arch Dermatol*. 1976;112:955–957.
14. Gupta AK, Ellis CN, Goldfarb MT, Vorhees JJ. Woronoff ring during anthralin therapy for psoriasis. *Arch Dermatol*. 1986;122:248.
15. Weathers DR, Baker G, Archard HO, Burkes EJ Jr. Psoriasiform lesions of the oral mucosa. *Oral Surg*. 1974;37:872–888.
16. Cataldo E, McCarthy P, Yaffee H. Psoriasis with oral manifestations. *Cutis*. 1977;20:705–708.
17. Buchners A, Begleiter A. Oral lesions in psoriatic patients. *Oral Surg*. 1976;41:327–332.
18. Depaoli M. Experimental study of the phenomenon of the isomorphous reaction in psoriasis and lichen planus. *Minerva Dermatol*. 1953;28:197.
19. Rosenberg EW, Noah PW. The Köebner phenomenon and the microbial basis of psoriasis. *J Am Acad Dermatol*. 1988;18:151–158.
20. Bernhard JD. Auspitz sign is not sensitive or specific for psoriasis. *J Am Acad Dermatol*. 1990;22:1079–1081.
21. Whyte HJ, Baughman RD. Acute guttate psoriasis and streptococcal infection. *Arch Dermatol*. 1964;89:350.

22. Jurik AG, Tenowitz T. Frequency of skeletal disease, arthro-osteitis, in patients with pustulosis palmoplantaris. *J Am Acad Dermatol*. 1988;18:666–671.
23. Rosen K, Lindstedt G, Mobacken H, Nystrom E. Thyroid function in patients with pustulosis palmoplantaris. *J Am Acad Dermatol*. 1988;19:1009–1016.
24. Lindgren S, Groth O. Generalized pustular psoriasis: A report of 13 patients. *Acta Derm Venereol*. 1976;56:139–147.
25. Baker H, Ryan TJ. Generalized pustular psoriasis: A clinical and epidemiological study of 104 cases. *Br J Dermatol*. 1986;80:771–793.
26. Hellgren L. Induction of generalized pustular psoriasis by topical use of betamethasone-dipropionate ointment in psoriasis. *Ann Clin Res*. 1976;8f:317–318.
27. Wright V. Psoriasis and arthritis. *Ann Rheum Dis*. 1956;15:348–356.
28. Moll JMH, Wright V. Familial occurrence of psoriatic arthritis. *Ann Rheum Dis*. 1973;22:181.
29. Kragballe R, Beck HI, Sogaard H. Improvement of psoriasis by a topical vitamin D<sub>3</sub> analogue (MC903) in a double-blind study. *Br J Dermatol*. 1988;119:223–230.
30. Kettler AH, Baughn RE, Orengo IF, Black H, Wolf JE. The effect of dietary fish oil supplementation on psoriasis. *J Am Acad Dermatol*. 1988;18:1267–1273.
31. Ellis C, Gorsolowski D, Hamilton T. Cyclosporine improves psoriasis in a double-blind study. *JAMA*. 1986;256:3110–3116.
32. Keczek K, Teasdale P, Wiseman RA, Mugglestone CJ. Plasma cortisol levels after topical application of diflucortolone valerate (0.3%) or clobetasol propionate (0.05%) in psoriatic patients. *Br J Dermatol*. 1970;99:417–420.
33. Katz HI, Hien NT, Praver SE, Mastbaum LI, Mooney JJ, Samson CR. Superpotent topical steroid treatment of psoriasis vulgaris—clinical efficacy and adrenal function. *J Am Acad Dermatol*. 1987;16:804–811.
34. Katz HI, Hien NT, Praver SE, Scott JC, Grivna EM. Betamethasone dipropionate in optimized vehicle: Intermittent pulse dosing for extended maintenance treatment of psoriasis. *Arch Dermatol*. 1987;123:1308–1311.
35. Lowe NI, Ashton RE, Koudsi H, Verschoore M, Schufer H. Anthralin for psoriasis: Short contact anthralin therapy compared with topical steroid and conventional anthralin. *J Am Acad Dermatol*. 1989;10:69–72.
36. Schulze HJ, Schauder S, Mahrle G, Steigleder GK. Combined tar-anthralin versus anthralin treatment lowers irritancy with unchanged antipsoriatic efficacy. Modifications of short contact therapy and Ingram therapy. *J Am Acad Dermatol*. 1987;17:19–24.
37. Young E, Weelden HV. Treatment of psoriasis with a combination of dithranol and coal tar. *Br J Dermatol*. 1987;116:281–282.
38. Comaish JS. The effect of tar and ultra-violet on the skin. *J Invest Dermatol*. 1987;88(Suppl):61–64.
39. Fischer LB, Maibach HI. Topical antipsoriatic agents and epidermal mitosis in man. *Arch Dermatol*. 1973;108:374–377.
40. Goeckerman WH. The treatment of psoriasis. *Northwest Med*. 1925;24:229–231.
41. Stern RS, Ziegler S, Parrish JA. Skin carcinoma in patients with psoriasis treated with coal tar and artificial ultraviolet radiation. *Lancet*. 1980;1:732–735.
42. Moy LS, Chalet M, Lowe NJ. Scrotal squamous cell carcinoma in a psoriatic patient treated with coal tar. *J Am Acad Dermatol*. 1986;14:518–519.

43. Joivet J, Cowan KH, Curt GA, Clendennin NJ, Chabner BA. The pharmacology and clinical use of methotrexate. *N Engl J Med*. 1983;309:1094–1104.
44. Roenigh HH Jr, Auerbach R, Mailbach HI, Weinstein GD. Methotrexate in psoriasis: Revised guidelines. *J Am Acad Dermatol*. 1988;19:145–156.
45. Guzzo C, Benik K, Lazarus GI, Johnson J, Weinstein G. Treatment of psoriasis with piritrexim, a lipid-soluble folate antagonist. *Arch Dermatol*. 1981;127:511–514.
46. Eichner R. Epidermal effects of retinoids: In-vitro studies. *J Am Acad Dermatol*. 1986;15:789–797.
47. Ellis CN, Vorhees JJ. Etretnate therapy. *J Am Acad Dermatol*. 1987;16:267–291.
48. Slawsky LD, Libow L. Successful treatment of acrodermatitis continua of Hallopeau with etretinate. *J Am Acad Dermatol*. 1990;6:1176–1178.
49. DiGiovanna JJ, Helfgott RK, Gerber LH, Peck GL. Extraplural tendon and ligament calcification associated with long-term therapy with etretinate. *N Engl J Med*. 1986;315:1177–1182.
50. DiGiovanna JJ, Zech LA, Ruddel ME, Gant G, McClean SW. Etretnate: Persistent serum levels of a potent teratogen. *J Invest Dermatol*. 1984;82:434.
51. Goldfarb MT, Ellis CN, Gupta AK, et al. Acetretn improves psoriasis in a dose-dependent fashion. *J Am Acad Dermatol*. 1988;18:655–662.
52. Parrish JA, Fitzpatrick TB, Tanenbaun L, Pathak M. Photochemotherapy of psoriasis with oral methoxsalen and long-wave UVL. *N Engl J Med*. 1974;291:1207–1211.
53. Lowe NJ, Urbach F, Bailin P, Weingarten DP. Comparative efficiency of two dosage forms of oral methoxsalen in psoralen plus UVA therapy of psoriasis. *J Am Acad Dermatol*. 1987;16:994–998.
54. Wolff K, Honigsman H. Safety and therapeutic effectiveness of selected psoralens. *NCI Monogr*. 1982;66:159–164.
55. Fitzpatrick TB, Parrish JA. Non-melanoma skin cancer occurring in patients treated with PUVA five to ten years after first treatment. *J Invest Dermatol*. 1988;91:120–124.
56. Bruyzeel I, Bergman W, Hartevelt HM, et al. “High single dose” European PUVA regimen also causes an excess of non-melanoma skin cancer. *Br J Dermatol*. 1991;124:49–55.
57. Stern RS. The photochemotherapy follow-up study group. Genital tumors among men with psoriasis exposed to psoralens and ultraviolet A radiation. *N Engl J Med*. 1990;322:1083–1097.
58. Hannuksela M, and Karvonen J. Trioxsalen bath plus UVA: Effective and safe in the treatment of psoriasis. *Br J Dermatol*. 1978;99:703–707.
59. Berne B, Fisher T, Michaelson G. Long-term safety of trioxsalen bath PUVA treatment: An 8-year follow-up of 149 psoriasis patients. *Photodermatol*. 1984;1:18–22.
60. Hannuksela M, Karvonen J. Carcinogenicity of trioxsalen bath PUVA. *J Am Acad Dermatol*. 1989;21:813–814.
61. Coleman WR, Lowe NJ, David M, Halder RM. Palmoplantar psoriasis: Experience with 8-methoxypsoralen soaks plus ultraviolet A with the use of a high output metal halide device. *J Am Acad Dermatol*. 1989;20:1078–1082.
62. Pillsbury DM, Livingood CS. Dermatology. In: Havens WP, ed. *Infectious Diseases and General Medicine*. In: Havens WP, Anderson RS, eds. *Internal Medicine in World War II*. Vol 3. Washington, DC: Medical Department, US Army, Office of The Surgeon General; 1968: 543–674.

63. Kuflik EG. Effect of antimalarial drugs on psoriasis. *Cutis*. 1980;26:153–155.
64. Olsen TG. Chloroquin and psoriasis. *Ann Intern Med*. 1981;94:546–547.
65. Wilson E. On lichen planus. *J Cutan Med*. 1969;3:112–132.
66. Fine JD, Arndt KA. Lichen planus. In: Demis DJ, ed. *Clinical Dermatology*. Philadelphia, Pa: JB Lippincott Co; 1980: Units 1-9, 1-22.
67. Arndt KA. Lichen planus. In: Fitzpatrick TB, Eisen AZ, Wolff K, Freedberg IM, Austen KF, eds. *Dermatology in General Medicine*. 3rd ed. New York, NY: McGraw-Hill Book Co; 1987: 967–973.
68. Shklar G. Lichen planus as an oral ulcerative disease. *Oral Surg*. 1972;33:376–388.
69. Copeman DW, Tan RS, Timlin D, Samman PD. Familial lichen planus: Another disease or a distinct people? *Br J Dermatol*. 1978;98:573–577.
70. Sodalfy M, Vollium DI. Familial lichen planus: A case report. *Br J Dermatol*. 1978;98:579–581.
71. Stankler L, Ewen SWB. The effects of experimental skin damage in patients with lichen planus. *Br J Dermatol*. 1974;90:25.
72. Tomkins JK. Lichen planus: A statistical study of 41 cases. *Arch Dermatol*. 1955;71:519–525.
73. White CJ. Lichen planus: Critical analysis of 64 cases. *J Cutan Dis*. 1919;37:671–684.
74. Black MM. Lichen planus and lichenoid eruptions. In: Rook A, Eblong FJG, Wilkinson DS, Champion RH, Burton JL, eds. *Textbook of Dermatology*. 4th ed. Oxford, England: Blackwell Scientific Publications; 1986: 1665–1685.
75. Cram DL, Kierland RR, Winkelman RK. Ulcerative lichen planus of the feet. *Arch Dermatol*. 1966;93:692–701.
76. Crotty CP, Su WPD, Winkelman RK. Ulcerative lichen planus. *Arch Dermatol*. 1980;116:1252–1256.
77. Samman PD. Lichen planus: Analyses of 200 cases. *Trans St Johns Hospital Dermatol Soc*. 1961;46:36–38.
78. Kanwar AJ, Singh OP. Leukoderma as a sequela of lichen planus. *Arch Dermatol*. 1978;114:130.
79. Marks R, Samman PD. Isolated nail dystrophy due to lichen planus. *Trans St John's Hospital Dermatol Soc*. 1972;58:93–97.
80. Burgoon CF. Lichen planus limited to the nails. *Arch Dermatol*. 1969;100:371.
81. Scher RK, Fischbein R, Ackerman AB. Twenty-nail dystrophy: A variant of lichen planus. *Arch Dermatol*. 1978;114:612–613.
82. Wilkinson JD, Dawber RPR, Bowers RP. Twenty-nail dystrophy of childhood: Case report and histopathological findings. *Br J Dermatol*. 1979;100:217–221.
83. Altman J, Perry HO. Variations and course of lichen planus. *Arch Dermatol*. 1961;84:179–191.
84. Scully C, El-Kom M. Lichen planus review and update on pathogenesis. *J Oral Path*. 1985;14:431–458.
85. Andreason JO. Oral lichen planus: A clinical evaluation of 115 cases. *Oral Surg*. 1968;25:31–42.
86. Silverman S, Griffith M. Studies on oral lichen planus. *Oral Surg*. 1974;32:705–710.

87. Thorn JJ, Holmstrup P, Rindum J, Pindberg JJ. Course of various clinical forms of oral lichen planus. A prospective follow-up study of 611 patients. *Oral Pathol.* 1988;17:213–218.
88. Holmstrup P, Thorn JJ, Rindum J, Lindberg JJ. Malignant development of lichen planus-affected oral mucosa. *J Oral Pathol.* 1988;17:219–225.
89. Korkij W, Chuvang T, Saltani K. Liver abnormalities in patients with lichen planus. *J Am Acad Dermatol.* 1984;11:609–615.
90. Mokni M, Rybojad M, Puppin D, et al. Lichen planus and hepatitis C virus. *J Am Acad Dermatol.* 1991;24:792.
91. Powell FC, Rogers RS, Dickson ER. Primary biliary cirrhosis and lichen planus. *J Am Acad.* 1983;9:540–545.
92. Alario A, Ortonne J, Schmitt D, Thivolet J. Lichen planus: Study with anti-human T lymphocyte antigen serum on frozen tissue section. *Br J Dermatol.* 1978;98:601–604.
93. Bjerke JR, Krogh HK. Identification of mononuclear cells in situ in skin lesions of lichen planus. *Br J Dermatol.* 1978;98:605–610.
94. Norris DA. Cytokine modulation of adhesion molecule in the regulation of immunologic cytotoxicity of epidermal targets. *J Invest Dermatol.* 1990;95(Suppl):111–120.
95. Gonzales E, Montaz KT, Freedman S. Bilateral comparison of generalized lichen planus treated with psoralens and ultraviolet A. *J Am Acad Dermatol.* 1984;10:958–961.
96. Ortonne JP, Thivolet J, Sannwald C. Oral photochemotherapy in the treatment of lichen planus. *Br J Dermatol.* 1978;99:77–88.
97. Handler HL. Isotretinoin for oral lichen planus. *J Am Acad Dermatol.* 1984;10:674.
98. Vighoglia PA, Villaneuva CR, Martasano AD. Efficacy of acetrein in severe cutaneous lichen planus. *J Am Acad Dermatol.* 1990;5:852–853.
99. Seghal VN, Bickchandani R, Karanut RV. Histopathological evaluation of griseofulvin therapy in lichen planus: A double-blind controlled study. *Dermatologica.* 1980;161:22–27.
100. Levy A, Stempler D, Yuzuk S, Schewak-Miller M, Roneu M, Tel-Hashower I. Treatment of lichen planus with griseofulvin. *Int J Dermatol.* 1986;25:405.
101. Massa NC, Rogers RS. Griseofulvin therapy of lichen planus. *Acta Derm Venereol.* 1981;61:542–550.
102. Frances C, Boisnic S, Etienne S, Szpirglas H. Effect of the local application of cyclosporine A on chronic erosive lichen planus of the oral cavity. *Dermatologica.* 1988;177:194–195.
103. Eisen D, Ellis CN, Duell EA, Griffiths CEM, Vorhees JJ. Effect of topical cyclosporine rinse on oral lichen planus. *N Engl J Med.* 1990;323:290–294.
104. Bazemore JM, Johnson HH, Swanson ER, Hayman JM. Relation of quinacrine hydrochloride to lichenoid dermatitis (atypical lichen planus). *Arch Derm Syphilol.* 1946;54:308–324.
105. Livingood CS. Follow-up report of occurrence of an unusual skin disease. Report to Surgeon General. Washington, DC: Government Printing Office, 1945.
106. Nishber TW. A new cutaneous syndrome occurring in New Guinea and adjacent islands. Preliminary report. *Arch Derm Syphilol.* 1945;52: 221–225.

107. Schmitt CL, Alpins O, Chambers G. Clinical investigation of a new cutaneous entity. *Arch Derm Syphilol*. 1945;52:226–229.
108. Bagby JW. A tropical lichen planus-like disease. *Arch Derm Syphilol*. 1945;512:217–220.
109. Dilaimy M. Lichen planus subtropicus. *Arch Dermatol*. 1976;112:1251–1253.
110. Dostrovsky A, Sagher R. Lichen planus in subtropical countries. *Arch Derm Syphilol*. 1949;59:308–328.
111. Breserton EM, Carpenter RG, Rook AJ. The prevalence and prognosis of eczema and asthma in Cambridgeshire school children. *Medical Officer*. 1959:317.
112. Walker RB, Warren RP. The incidence of eczema in early childhood. *Br J Dermatol*. 1956;68:182.
113. Johnson ML. Prevalence of dermatologic disease among persons 174 years of age: United States. In: *Advance Data From Vital and Health Statistics, No. 4*. Washington, DC: National Center for Health Statistics: 1977.
114. Hanifin JM. Clinical and basic aspects of atopic dermatitis. In: *Seminars in Dermatology*. New York, NY: Thieme-Stratton, Inc; 1983 (2): 5–29.
115. Rajka G. *Atopic dermatitis*. London, England: WB Saunders; 1975: 36.
116. Roth HL, Kierland R. The natural course of atopic dermatitis. *Arch Dermatol*. 1964;89:209–214.
117. Hanifen JM, Cooper KD, Roth HL. Atopy and atopic dermatitis. *J Am Acad Dermatol*. 1986;15:703–706.
118. Agrup G. Hand eczema and the hand dermatoses in south Sweden. *Acta Derm Venereol*. 1969;49:81–91.
119. Leves R, Hadley K, Downey D, Mackie R. Staphylococcal colonization in atopic dermatitis and the effect of topical mupirocin therapy. *Br J Dermatol*. 1988;119:189–190.
120. Masenga MD, Garbe C, Wagner J, Orianos CE. *Staphylococcus aureus* in atopic dermatitis and non-atopic dermatitis. *Int J Dermatol*. 1990;29:579–582.
121. Bibel DJ, Aly R, Shinefield HR, Maibach HI. The *Staphylococcus aureus* receptor for fibronectin. *J Invest Dermatol*. 1983;80:494–496.
122. Lopez JO, Reis MD, Bretani RR. Presence of laminin receptors in *Staphylococcus aureus*. *Science*. 1985; 229:275–277.
123. Boiko S, Kaufman R, Lucky AW. Osteomyelitis of the distal phalanges in three children with severe atopic dermatitis. *Arch Dermatol*. 1988;124:418–423.
124. Leung DYM, Wood N, Dubey D. Cellular basis of defective cell-mediated lympholysis in atopic dermatitis. *J Immunol*. 1983;130:1678–1682.
125. Wheeler CE Jr, Abele DC. Eczema herpeticum, primary and recurrent. *Arch Dermatol*. 1966;93:162–171.
126. Fivenson DP, Breneman D, Wonder AH. Kaposi's varicelliform eruption. *Arch Dermatol*. 1990;126:1037–1039.
127. Atherton DJ, Carabott F, Glover MT. The role of psoralen photochemotherapy (PUVA) in the treatment of severe atopic eczema in adolescents. *Br J Dermatol*. 1988;118:791–795.
128. Sekler S, Larko O. UVB phototherapy of atopic dermatitis. *Br J Dermatol*. 1988;119:692–705.
129. Jkler J, Larko O. Combined UVA-UVB versus UVB phototherapy for atopic dermatitis: A paired-comparison study. *J Am Acad Dermatol*. 1990;22:49–53.

130. Scholtz JR. Management of atopic dermatitis. *Calif Med*. 1965;102:210.
131. Jacobs AH. Atopic dermatitis. In: Sellis S, Kagan J, eds. *Current Pediatric Therapy*. 11th ed. Philadelphia, Pa: WB Saunders Co; 1984: 438–439.
132. Ayres S Jr. Atopic dermatitis: Papaverine therapy versus the Scholtz regimen. *J Amer Acad Dermatol*. 1986;15: 1052–1053.
133. Sulzberger MB. Atopic dermatitis: Its clinical and histologic picture. In: Baer RC, ed. *Atopic Dermatitis*. New York, NY: University Press; 1955: 11–42.
134. Glickman FS, Silvers SH. Hand eczema and atopy in housewives. *Arch Dermatol*. 1967;95:487–489.
135. Shmunis E, Kell JE. Occupational dermatoses in South Carolina: A descriptive analysis of cost variables. *J Am Acad Dermatol*. 1983;9:861–866.
136. Burrell BA, Halpean GM, Huntley AC. Chronic urticaria. *West J Med*. 1990;152:268–276.
137. Champion RH, Roberts SB, Carpenter RG. Urticaria and angioedema: A review of 554 patients. *Br J Dermatol*. 1969;81:588–597.
138. Sater NA. Urticaria: Current therapy. *J Allergy Clin Immunol*. 1990;86:1009–1014.
139. Champion RH. Urticaria: Then and now. *Br J Dermatol*. 1988;119:427–436.
140. Champion RH. A practical approach to the urticarial syndromes—a dermatologist's view. *Clin Exp Allergy*. 1990;20:221–224.
141. Sater NA, Wasserman SI. Physical urticaria and angioedema: An experimental model of mast-cell activation in humans. *J Allergy Clin Immunol*. 1980;66:358–365.
142. Daves JS, Black AK, Ward AM, Breaves MW. Delayed pressure urticaria. *J Am Acad Dermatol*. 1988;18:1289–1298.
143. Shuster S. Delayed shear-induced dermatographism and delayed pressure-induced dermatographism are distinct entities. *J Am Acad Dermatol*. 1989;21:588–589.
144. Gorevik PO, Kaplan AP. The physical urticarias. *Int J Dermatol*. 1980;19:417–435.
145. Illig L. Physical urticaria: Its diagnosis and treatment. *Curr Probl Dermatol*. 1973;5:79–116.
146. Neittoanmuki H. Cold urticaria: Clinical findings in 220 patients. *J Am Acad Dermatol*. 1985;13:636–644.
147. Douglas HMG, Blemink E. Familial cold urticaria. *Arch Dermatol*. 1974;110:382–386.
148. Bermen BA, Ross RN, Sly RM. Acquired cold urticaria. *Cutis*. 1983;32:20–32.
149. Rauits M, Armstrong RB, Harber LC. Solar urticaria: Clinical features and wave length dependence. *Arch Dermatol*. 1982;118:228–231.
150. Leiferman KM, Norris PG, Murphy GM, Hauk JL, Winkelman RK. Evidence for eosinophil degranulation with deposition of granular major basic protein in solar urticaria. *J Am Acad Dermatol*. 1989;21:75–80.
151. Leenutaphong V, Holzle E, Hewig G. Pathogenesis and classification of solar urticaria: A new concept. *J Am Acad Dermatol*. 1989;21:232–240.
152. Duschet P, Leyen P, Schwartz T. Solar urticaria treatment by plasmapheresis. *J Am Acad Dermatol*. 1988;15:712–713.

153. Parrish JA, Jarnicke KF, Morrison WL. Solar urticaria: Treatment with PUVA and mediator inhibitors. *Br J Dermatol.* 1982;106:575–580.
154. Bernhard JD, Japnicke K, Montaz TK, Parrish JA. Ultraviolet A phototherapy in the prophylaxis of solar urticaria. *J Am Acad Dermatol.* 1984;10:29–33.
155. Keahey TM, Lauker RM, Kaidbey FH. Studies on the mechanism of clinical tolerance in solar urticaria. *Br J Dermatol.* 1984;110:327–330.
156. Shelly WB, Rawasley HM. Aquagenic urticaria: Contact sensitivity reaction to water. *JAMA.* 1964;189:895–898.
157. Greaves MW, Black AK, Eady RA, Cautts A. Aquagenic pruritus. *Br Med J.* 1981;282:2003–2010.
158. Epstein PA, Kidd KK. Dermodistortive urticaria: An autosomal dominant dermatologic disorder. *Am J Med Genet.* 1981;96:307–315.
159. Weues MH, Metzger WJ, Simon RA. Occupationally acquired vibratory angioedema with secondary carpal tunnel syndrome. *Ann Int Med.* 1983;98:44–46.
160. Lawlor F, Black AK, Breathnack AS, Greaves MW. Vibratory angioedema: Lesion induction, clinical features, laboratory and ultrastructural findings and response to therapy. *Br J Dermatol.* 1989;120:93–94.
161. Tatnall FM, Gaylarde PM, Saskaney I. Localized heat urticaria and its management. *Clin Exp Dermatol.* 1984;9:367–374.
162. Sheffner AL, Soter NA, McFadden ER. Exercise-induced anaphylaxis: A distinct form of physical allergy. *J Allergy Clin Immunol.* 1983;71:311–316.
163. Pecquet C, Leynadier F, Dry J. Contact urticaria and anaphylaxis to natural latex. *J Am Acad Dermatol.* 1990;22:631–633.
164. McDuffie FC, Sams WM, Maldonado JE. Hypocomplementemia with cutaneous vasculitis and arthritis. *Mayo Clin Proc.* 1973;48:340–348.
165. Black AK, Greaves MW, Champion RH, Pye RJ. The urticarias: 1990. *Br J Dermatol.* 1991;124:100–108.
166. Dahl MV. *Clinical Immunodermatology.* Chicago, Ill: Yearbook Medical Publishers; 1988: 133–134.
167. Monroe EW, Cohen SH, Kalbfleisch J, Schulz CI. Combined H<sub>1</sub> and H<sub>2</sub> antihistamine therapy in chronic urticaria. *Arch Dermatol.* 1981;117:404–407.
168. Green SL, Reed LE, Schroeter AL. Double-blind crossover study comparing doxepin with diphenhydramine for the treatment of chronic urticaria. *J Amer Acad Dermatol.* 1985;12:669–675.
169. Monrop EW. Chronic urticaria: Review of nonsedating H<sub>1</sub> antihistamines in treatment. *Arch Dermatol.* 1988;19: 842–849.
170. Alexander AM, Delph WI. Pseudofolliculitis barbae in the military: A medical, administrative, and social problem. *J Natl Med Assoc.* 1974;66:459–464.
171. Brauner GJ, Flaudesmeyer KL. Pseudofolliculitis barbae: Medical consequences of interracial friction in the US Army. *Cutis.* 1977;23:61–66.
172. Strauss JS, Kligman AM. Pseudofolliculitis of the beard. *Arch Dermatol.* 1956;74:533–542.
173. Steggerda M. Cross section of human hair from four racial groups. *J Hersed.* 1940;31:475.



174. Strauss J, Kligman A. Pseudofolliculitis of the beard. *Arch Dermatol*. 1956;74:533–542.
175. Craig G. Shaving. *Arch Dermatol*. 1955;71:11.
176. Coute MS, Lawrence JE. Pseudofolliculitis barbae: No “pseudo problem.” *JAMA*. 1979;241:53–54.
177. Brown LA. Pathogenesis and treatment of pseudofolliculitis barbae. *Cutis*. 1983;32:373–375.
178. Kenney JA. Management of dermatoses peculiar to Negroes. *Arch Dermatol*. 1965;91:126–129.
179. Garcia RL, Henderson R. The adjustable rotary electric razor in the control of pseudofolliculitis barbae. *J Assoc Milit Dermatol*. 1978;4:28.
180. Alexander AM. Evaluation of foil-guarded shaver in the management of pseudofolliculitis barbae. *Cutis*. 1981;27:534–542.
181. de la Guardia M. Facial depilatories on black skin. *Cosmet Toilet*. 1976;91:37–38.
182. Halder RM. Pseudofolliculitis barbae and related disorders. *Dermatol Clin*. 1988;6:402–412.
183. Edlich RF, Haines PC, Nichter LS, Silloway KA, Morgan RF. Pseudofolliculitis barbae with keloids. *Arch Dermatol*. 1986;4:283–286.
184. Kligman AM, Mills OH. Pseudofolliculitis of the beard and topically applied tretinoin. *Arch Dermatol*. 1973;107:551–552.
185. Halder RM. Pseudofolliculitis barbae and related disorders. *Practitioner*. 1989;233:307–309.
186. US Department of the Army. *Pseudofolliculitis of the Beard*. Washington, DC: DA; 1983. Technical Bulletin MED 287.
187. Nahmias AJ. Herpesviruses from fish to man—a search for pathobiologic unity. *Pathobiol Annu*. 1972;2:153–182.
188. Nahmias AJ, Roizmea B. Infection with herpes simplex virus 1 and 2. *N Engl J Med*. 1973;289:667–674, 719–725, 781–789.
189. Davis LE, Redman JC, Skipper BJ, McClaren LC. Natural history of frequent recurrences of herpes simplex labialis. *Oral Surg*. 1988;66:558–561.
190. Corey L, Spear PG. Infections with herpes simplex viruses. *N Engl J Med*. 1986;314:686–691, 749–757.
191. Hale BD, Rendtoff RC, Walker LC, Roberts AN. Epidemic herpetic stomatitis in an orphanage nursery. *JAMA*. 1963;183:1068–1072.
192. Spruance SL. Pathogenesis of herpes simplex labialis: Excretion of virus in the oral cavity. *J Clin Microbiol*. 1984;19:675–679.
193. Scully C. Orofacial herpes simplex virus infections: Current concepts in the epidemiology, pathogenesis and treatment, and disorders in which the virus may be implicated. *Oral Surg*. 1989;68 701–710.
194. Fiumara NJ. Herpes simplex. *Clinics in Dermatology*. 1989;7:23–36.
195. Molin L. Oral acyclovir prevents herpes simplex virus associated erythema multiforme. *Br J Dermatol*. 1987;116:109–111.
196. Penneys NS, Goldstein B, Nahass GT, Leonardi C, Zhu W. Herpes simplex virus DNA in occult lesions: Demonstration by the polymerase chain reaction. *J Am Acad Dermatol*. 1991;24:689–692.

197. Raborn GW, McGow WT, Grace M, Percy J, Samuels S. Herpes labialis treatment with acyclovir 5% modified aqueous cream: A double-blind randomized trial. *Oral Surg.* 1989;67:676–679.
198. Spruance SL, Stewart JCB, Rowe NH, McKeogh MB, Wenerstrom G, Freeman DL. Treatment of recurrent herpes simplex labialis with oral acyclovir. *J Infect Dis.* 1990;161:185–190.
199. Spruance SL. Cutaneous herpes simplex virus lesions induced by ultraviolet radiation. *Am J Med.* 1988;85(suppl 2A):43–45.
200. Green JA, Spruance SL, Wenerstrom G, Plepkorn WM. Post-herpetic erythema multiforme prevented with prophylactic oral acyclovir. *Ann Intern Med.* 1985;102:632–633.
201. Spruance SL, Hamill ML, Hoge WS, Davis G, Mills J. Acyclovir prevents reactivation of herpes labialis in skiers. *JAMA.* 1988;260:1597–1599.
202. Wilson JB. Thirty-one years of herpes zoster in a rural practice. *Br Med J.* 1986;293:1349–1351.
203. Ragozzino WM, Melton LJ, Kurland LT. Risk of cancer after herpes zoster: A population-based study. *N Engl J Med.* 1982;307:393–397.
204. Guess HA, Broughton DD, Melton LJ. Epidemiology of herpes zoster in children and adolescents: A population-based study. *Pediatrics.* 1985;76:512–517.
205. Hope-Simpson RE. The nature of herpes zoster: A long-term study and a new hypothesis. *Proc R Soc Lond.* 1965;58:9–20.
206. Liesgang TJ. The varicella-zoster virus: Systemic and ocular features. *J Am Acad Dermatol.* 1984;11:165–191.
207. Burgoon CF Jr, Burgoon JS, Baldrige GD. The natural history of herpes zoster. *JAMA.* 1957;164:265–269.
208. Blumberg EA, Molavi A. Herpes zoster. *Clin Dermatol.* 1989;7:37–48.
209. Huff JC, Bean B, Balfour HH. Therapy of herpes zoster with oral acyclovir. *Am J Med.* 1988;85(suppl 24):84–88.
210. McKendrick MW, Negill JL, White JE, Wood MJ. Oral acyclovir in acute herpes zoster. *Br Med J.* 1986;293:1529–1532.
211. McKendrick MW. Oral acyclovir in herpes zoster. *Scand J Infect Dis.* 1985;47:76–79.
212. Biron KK, Elion GB. In vitro susceptibility of varicella-zoster virus to acyclovir. *Antimicrob Agents Chemother.* 1980;18:443–447.
213. Post BT, Philbrick JT. Do corticosteroids prevent postherpetic neuralgia? A review of the evidence. *J Am Acad Dermatol.* 1988;10:605–610.
214. Postelthwaite K. Molluscum contagiosum: A review. *Arch Environ Health.* 1970;21:432–452.
215. Brown ST, Nalley JF, Draus SL. Molluscum contagiosum. *Sex Transm Dis.* 1981;8:227–234.
216. Brown ST, Weinberger J. Molluscum contagiosum: Sexually transmitted disease in 17 cases. *J Am Vener Dis Assoc.* 1974;1:35–36.
217. Hawley TG. Molluscum contagiosum. *N Z Med J.* 1972;75:313.
218. Fischer B, Warner L. Cutaneous manifestations of the acquired immunodeficiency syndrome. *Int J Dermatol.* 1987;26:615–630.

219. Simienez AF, Casado M, Borbujo J, Soto MJ, Vegues JM, Sanjurjo MJ. Cutaneous cryptococcosis mimicking molluscum contagiosum in a hemophiliac with AIDS. *Clin Exp Dermatol*. 1987;12:446–450.
220. Piron L, Vaillant L, Duong T, et al. *Acta Derm Venerol*. 1989;69:365–367.
221. Fireuson DP, Weltman RE, Cibson SH. Giant molluscum contagiosum presenting as basal cell carcinoma in an acquired immunodeficiency syndrome patient. *J Am Acad Dermatol*. 1988;19:912–914.
222. Weston WL, Lane AT. Should molluscum be treated? *Pediatrics*. 1980;65:865.
223. de Waad van der Spek FB, Aranje AP, Lillieborg S, Hop WC, Stolz E. Treatment of molluscum contagiosum using a lidocaine/prilocaine cream (EMLA) for analgesia. *J Am Acad Dermatol*. 1990;32:665–688.
224. Celmetti C, Cerri D, Schluma AA, Menni S. Treatment of extensive warts with etretinate: A clinical trial in 20 children. *Ped Dermatol*. 1987;4:254–258.
225. Lancaster WR, Olson C. Animal papillomaviruses. *Microbiol Rev*. 1982;46:191–207.
226. Beutner KR. Human papillomavirus infection. *J Am Acad Dermatol*. 1989;20:114–123.
227. Ciutto G. Innesto positivo con filtrato di versusue volgare. *Giorn Ital Mal Venereol*. 1907;48:12–17.
228. Fuchs PG, Girardi F, Pfistee H. Human papillomavirus DNA in normal, metaplastic, preneoplastic, and neoplastic epithelia, of the cervix uteri. *Int J Cancer*. 1988;41:41–45.
229. Lutzer YA, Blanchet-Bardon C, Ortho G. Clinical observations, virologic studies and treatment trials in patients with epidermodysplasia verruciformis, a disease induced by specific human papilloma viruses. *J Invest Dermatol*. 1986;83:185–255.
230. Gasseumaler A, Pfister H, Horustein OP. Human papillomovirus 25-related DNA in solitary keratoacanthoma. *Arch Dermatol Res*. 1986;279:73–76.
231. Kawashima M, Jablonska S, Favre M. Characterization of a new type of human papillomavirus found in a lesion of Bowen's disease of the skin. *J Virol*. 1986;57:688–692.
232. Massing AM, Epstein WL. Natural history of warts. *Arch Dermatol*. 1963;87:306–310.
233. Mahrle G, Alexander W. Surgical treatment of recalcitrant warts. *J Dermatol Surg Oncol*. 1983;9:445–450.
234. Bunney MH, Nolan MW, Williams DA. An assessment of methods of treating viral warts by comparative treatment trials based on a standard design. *Br J Dermatol*. 1976;94:667–678.
235. Shumer S, O'Keefe E. Bleomycin in the treatment of recalcitrant warts. *J Am Acad Dermatol*. 1983;9:91–96.
236. McBurney E, Rosen D. Carbon dioxide laser treatment of verrucae vulgares. *J Dermatol Surg Oncol*. 1984;10:45–48.
237. Lockshin N. Flat facial warts treated with fluorouracil. *Arch Dermatol*. 1979;115:929–930.

## T

2,4,5-T: 2,4,5-trichlorophenoxyacetic acid  
TCDD: 2,3,7,8-tetrachlorodibenzo-*p*-dioxin  
TOE: Table of Organization and Equipment  
TRNG: tetracycline-resistant strains of *Neisseria gonorrhoeae*  
TRUST: toluidine red unheated serum test  
TTP: tuberculoid tuberculoid polar leprosy  
TTs: tuberculoid tuberculoid subpolar leprosy

## U

USR: unheated serum reagin  
UV: ultraviolet  
UV-A: ultraviolet A  
UV-B: ultraviolet B

## V

VDRL: Venereal Disease Research Laboratory test  
VZV: varicella-zoster virus

## W

WHO: World Health Organization  
WRAIR: Walter Reed Army Institute of Research

## INDEX

### A

- Abdomen
  - and contact dermatitis, 136
- Achiya, Michihiko, 70, 71
- Acids
  - See Alkalis and acids
- Acquired immunodeficiency syndrome (AIDS)
  - and atypical mycobacterial infections, 404, 417
  - and cryptococcosis, 481
  - and genital herpes infection, 531
  - and leprosy, 352
  - and molluscum contagiosum, 580-581
  - and secondary syphilis, 503
  - and tuberculosis, 376, 377, 379
  - See also Immunocompromised patients
- Acrocyanosis, 33
  - clinical manifestations, 33
  - etiology, 33
  - treatment, 33
- Acrodermatitis chronica atrophicans, 311
- Actinomycosis, 483-485
- Africa
  - and dracunculiasis, 279
  - and filariasis, 274
  - and histoplasmosis, 457
  - and loiasis, 276
  - and lymphogranuloma venereum, 522
  - and mycetoma, 476
  - and onchocerciasis, 277, 278
  - and schistosomiasis, 281
  - and streptocerciasis, 279
- African trypanosomiasis, 266-268
  - clinical manifestations, 267
  - diagnosis, 267
  - treatment, 267-268
- Afzelius, A., 309
- Age differences
  - and plague, 298
  - and Rocky Mountain spotted fever, 220
- AIDS
  - See Acquired immunodeficiency syndrome (AIDS)
- Albrecht, 305
- Alexander the Great, 321
- Alexander, W., 584
- Algorithms
  - for diagnosing blisters, 14
  - for diagnosing changing growths, 15
  - for diagnosing deep fungal diseases, 455
  - for diagnosing genital ulcer disease, 496
  - for diagnosing and isolating atypical mycobacteria, 402
  - for diagnosing macular erythema, 17
  - for diagnosing new growths, 15
  - for diagnosing pruritic, inflamed papules, 18
  - for diagnosing pustular lesions, 13
  - for diagnosing scaling papules, plaques, and patches, 16
  - for diagnosing and treating Rocky Mountain spotted fever, 225
  - for diagnosing vesicles and bullae, 14
  - for treating dermatophyte infections, 436
  - for treating reactional states in leprosy, 349
- Alimentary toxic aleukia, 87
- Alkalis and acids
  - and irritant contact dermatitis, 132
- Allen, Alfred M., 5, 112, 396, 425
- Allergic contact dermatitis, 113-131
  - and cashew, 118-119
  - and clothing, 129-130
  - and fragrances, 131
  - and ginkgo, 119-120
  - and *Gluta*, 120
  - and India marking nut tree, 117
  - and Japanese lacquer tree, 117-118
  - and mango, 118
  - and metals, 125-128
  - and miscellaneous sensitizers, 131
  - and plants, 113-114
    - geographical distribution, 120-123
  - and poison ivy and poison oak, 114-117
  - and poison sumac, 117
  - and preservatives, 130-131
  - and rubber compounds, 129
  - and shoes, 128-129
  - and sunscreens, 125
  - and topical drugs, 123-125
  - See also Atopic dermatitis; Contact dermatitis; Irritant contact dermatitis
- Almeida, Louis, 323
- Altman, J., 562
- Amebiasis, 268-269
  - clinical manifestations, 269-269
  - diagnosis, 269
  - treatment, 269
- Amenhotep II, 321
- American Dermatologic Association, 464
- American Revolution
  - and cold injuries, 22
  - and shoes, 56
- Americas
  - and allergenic, indigenous plants, 120-122
  - and filariasis, 274
  - and onchocerciasis, 277
  - and schistosomiasis, 281
  - and tularemia, 300
- Amherst, 71
- Anacardiaceae, 113-114, 117
- Anesthesia
  - for surgery on cutaneous trauma, 150
- Angioedema, hereditary, 570
- Animal bites
  - arachnids, 170-178
  - arthropods, 159
  - and bacterial contamination, 149
  - cats and dogs, 180
  - centipedes and millipedes, 160
  - insects, 160-170
  - reptiles, 179-180
- Animal hookworm, 272
- Annelids, 269
  - See also Helminthic infections
- Annular lesion, 12
- Ansamycins
  - and leprosy, 346

*See also* Drugs

Anthralin  
in treatment of psoriasis, 559

Anthrax in biological warfare, 82-84  
clinical findings, 83  
cutaneous findings, 83  
diagnosis, 83-84  
military significance, 84  
prophylaxis, 84  
treatment, 84

Antibiotics  
and contact dermatitis, 138

Antigen detection  
of genital herpes, 529-530

Arabian peninsula  
and schistosomiasis, 281  
*See also* Middle East

Arachnids, 170-178  
mites and ticks, 185-190  
nonscabietic mites, 173-174  
scabietic mites, 172-173  
scorpions, 174-175  
spiders, 175-178  
ticks, 170-171

Arenaviridae-caused hemorrhagic fevers, 205-207

Aretaeus, 322, 357

Argentine hemorrhagic fever, 206-207  
laboratory findings and treatment, 207  
signs and symptoms, 206-207

Aristotle, 22, 322, 357

Aronson, 394

Arsenic  
and contact dermatitis, 128

Arsenical vesicants in chemical warfare, 101

Arthritis, psoriatic, 555, 558

Arthritis-dermatitis syndrome, 307

Arthropods, 184  
and bites, 159  
as vectors of disease, 184  
*See also* Arachnids; Centipedes and millipedes; Insects;  
Vectors of disease

Atopic dermatitis, 564-568  
clinical features, 564, 565  
complications, 566  
course, 565-566  
diagnosis, 566  
military considerations, 567-568  
precipitants, 566  
treatment, 566-567

Ashworth, 480

Asia  
and allergenic, indigenous plants, 122-123  
and filariasis, 274  
and lymphogranuloma venereum, 522  
and tularemia, 300

Asklepiades, 322

Asteatotic eczema, 27  
clinical manifestations, 27  
etiology, 27  
treatment, 27

Atrophy, 10

Aufrecht, 358

Aurelianus, Caelius, 322

Australia  
and allergenic, indigenous plants, 123  
and atypical mycobacterial infections, 412  
and histoplasmosis, 457

and murine typhus, 234  
and tick paralysis, 189

Avicenna, 324

Azithromycin  
for chancroid, 518

## **B**

Bacille bilié de Calmette-Guérin (BCG), 351, 363

*Bacillus anthracis*, 82

Bacterial index  
and leprosy, 332

Bacterial skin infections  
and heat and humidity, 46

Baillie, 357

Baldwin, E.R., 356

"Balkan grippe," 238

Balsam of Peru  
and allergic contact dermatitis, 131

*Bamboo Book*, 322

Bancroft, J., 189, 198

Bancroftian filariasis, 274-275  
clinical manifestations, 274-275  
diagnosis, 275  
treatment, 275

Barrett, O., Jr., 356

Baumgarten, 358, 359

Bayle, Gaspard Laurent, 357

Bazemore, J.M., 564

Beaman, J.H., 114

Bedbugs, 193-194

Bees, wasps, and hornets, 168

Beetles, 167

Belly  
*See* Abdomen

Benzocaine  
and allergic contact dermatitis, 123-124

Bernhard, J.D., 554

Bible  
and leprosy, 321  
and swarm of flies, 184-185

Bikini BRAVO shot, 76

Biological and Toxin Weapons Convention, 73

Biological warfare, 82-90  
anthrax, 82-84  
botulism, 87  
hemorrhagic fevers, 84-87  
history, 71-73  
mycotoxins, 87-90  
plague, 84  
tularemia, 84

Biting flies, 194  
*See also* Mosquitoes and flies

Black Death, 295  
*See also* Plague

Black piedra, 448

Black widow spider, 177-178

Blackhead, 11

Blastomycosis, 464-467  
clinical manifestations, 465-466  
diagnosis, 466  
distribution, 464-465  
epidemiology, 464  
history, 464  
military implications, 467  
primary cutaneous inoculation, 466  
primary pulmonary, 465

- systemic, 465-466
  - treatment, 466-467
  - Bloch, Iwan, 321
  - Blood agents, 105
  - Body lice, 164
  - Bojalil, 394
  - Bolivian hemorrhagic fever, 207
  - Borovsky, 257
  - Borrelia burgdorferi*, 187, 309
  - Bosch, Hieronymus, 71, 72
  - Botulism in biological warfare, 87
    - cutaneous and other clinical findings, 87
    - diagnosis, 87
    - military significance, 87
    - prophylaxis, 87
    - treatment, 87
  - Boutonneuse fever, 215, 225-228
    - clinical findings, 226-227
    - diagnosis, 228
    - differential diagnosis, 227
    - epidemiology, vectors, and hosts, 226
    - laboratory findings, 227
    - microbiology, 225-226
    - prevention, 228
    - treatment, 228
  - Bowenoid papulosis, 534
  - Boxer Rebellion
    - and leprosy, 325
  - Bradt, J.G., 515
  - Brazil
    - and lobomycosis, 479
    - and sporotrichosis, 470
  - Bretonneau, 301-302
  - Brill-Zinsser disease, 215, 233
    - See also* Recrudescence typhus (Brill-Zinsser disease)
  - B'rit milah, 365
  - Brown recluse spider, 176-177
  - Brugia malayi*, 275
    - See also* Malayan filariasis
  - Brugia timori*, 275
    - See also* Timorian filariasis
  - Brugsch, 321
  - Bubo, 295
  - Bubonic plague, 297-298
  - Buhl, 358
  - Bulla, 8
  - Bunney, M.H., 584
  - Bunyaviridae-caused hemorrhagic fevers, 202-205
  - Burgdorfer, W., 309
  - Burkina Faso
    - and yellow fever, 201
  - Burrow, 11
  - Byogenkorosenkin-ho*, 323
- C**
- Calomys callosus*, 207
  - Candidosis, 437-443
    - clinical features, 438-441
    - diagnosis, 441-442
    - intertrigo, 438-439
    - onychomycosis, 439-441
    - paronychia, 439-441
    - treatment, 442-443
  - Caribbean region
    - and allergenic, indigenous plants, 120-122
    - and filariasis, 274
    - and lymphogranuloma venereum, 522
    - and schistosomiasis, 281
  - Carter, Vandyke, 476
  - Case histories
    - of tuberculous gumma, 374
  - Cashew
    - and contact dermatitis, 118-119
  - Cat and dog bites, 180
  - Caterpillars and moths, 160-161
  - Catherine the Great, 295
  - Ceftriaxone
    - for chancroid, 518
  - Cell wall
    - and leprosy, 328, 329
  - Cellulitis, 293
  - Celsus, 357
  - Celsus, Aulus Cornelius, 322
  - Centers for Disease Control and Prevention
    - diagnostic criteria for Rocky Mountain spotted fever, 221
    - Plague Branch, 298
  - Centipedes and millipedes, 160
  - Cercariae, 281
  - Chagas' disease, 193
  - Chagoma, 264-265
  - Champion, R.H., 569
  - Chancroid, 515-519
    - clinical manifestations, 516
    - laboratory diagnosis, 516-518
    - treatment, 518-519
  - Chang Chung-ching, 323
  - Chemical warfare, 90-105
    - and arsenical vesicants, 101
    - and cyanides, 105
    - doctrine and weaponry, 90
    - history, 73-76
    - and nerve agents, 105
    - and oximes, halogenated, 104-105
    - and sulfur mustard and nitrogen mustard, 90-101, 101-104
  - Chemoprophylaxis
    - of meningococcal infections, 308
  - Chernobyl (U.S.S.R.), 82
  - Chien Chen, 323
  - Chilblain, 31
  - Children
    - and condyloma acuminata, 535
    - and gonorrhea, 511
    - and leprosy, 346
    - and tetracycline, 301
    - and tick paralysis, 189
    - and treating Lyme disease, 313
  - China, ancient
    - and leprosy, 322-323
    - and plague, 295
    - and schistosomiasis, 281
    - and syphilis, 498
  - Chiracanthium, 178
  - Chloracne
    - and irritant contact dermatitis, 132-133
  - Chlorovinyldichloroarsine, 101
  - Cholinergic urticaria
    - and heat and humidity, 45
  - Christ, Jesus, 321, 322
  - Chromates
    - and contact dermatitis, 127
  - Chromoblastomycosis, 473-475
    - clinical manifestations, 473
    - diagnosis, 473-475

- epidemiology and distribution, 473
- history, 473
- treatment, 475
- Chrysops* deerflies
  - vectors for loiasis, 276
- Civil War
  - and chancroid, 515
  - and shoes, 56
- Cleland, 198
- Clinics of Dermatology*, 120
- Clofazimine
  - and leprosy, 345
  - See also Drugs
- Clostridium botulinum*, 87
- Clothing
  - and contact dermatitis, 129-130
  - and heat loss, 26
  - and mite control, 237
  - and preventing Rocky Mountain spotted fever, 224
  - See also Shoes
- Clovis, 357
- Coal tar
  - in treatment of psoriasis, 559
- Coccidioidomycosis, 459-464
  - clinical manifestations, 461
  - diagnosis, 461-463
  - distribution, 460-461
  - epidemiology, 460
  - history, 459-460
  - prevention, 463-464
  - treatment, 463
- Cold-induced injury, 21-37
  - direct, 27-30
  - history, 22-24
  - indirect, 31-36
  - influential factors, 25-26
  - mechanisms, 24-25
  - pathogenesis, 27
  - prevention, 24
- Cold panniculitis, 34
  - clinical manifestations, 34
  - etiology, 34
  - treatment, 34
- Coleman, W.R., 560
- Colophony
  - and allergic contact dermatitis, 131
- Columbus, Christopher, 192, 498
- Combat type
  - and heat loss, 26
- Comedo, 11
- Commentary of Taiho-rei, 323
- Conder, 321
- Conduction, 24
- Confucius, 322
- Contact dermatitis, 112
  - allergic, 113-131
  - by anatomical site, 135-137
  - irritant, 131-133
  - and mechanical injury, 133
  - patch and use testing, 137-138
  - and pharmacological reactions, 133-134
  - treatment, 138-139
  - urticaria, 134
  - See also Allergic contact dermatitis; Atopic dermatitis; Irritant contact dermatitis
- Contact urticaria, 134
- See also Urticaria, contact
- Convection, 24
- Cook, Albert, 392
- Corticosteroids, topical
  - in treatment of psoriasis, 558
- Corynebacterium diphtheriae*, 301
- Creosote
  - and contact dermatitis, 132
- Crimean-Congo hemorrhagic fever, 203
  - laboratory findings and treatment, 203
  - signs and symptoms, 203
- Crimean War
  - and frostbite, 224
- Crust, 10
- Cryptococcosis, 481-482
  - clinical manifestations, 481-482
  - diagnosis, 482
  - epidemiology and distribution, 481
  - treatment, 482
- Culicoides grahami*
  - and streptocerciasis, 279
- Culture
  - for diagnosing gonorrhea, 512-513
- Culture, viral
  - to diagnose genital herpes, 528
- Culture and serology
  - for chancroid, 517-518
- Cunningham, D.D., 256-257
- Cuprozinc-superoxide dismutase (CSD), 81
- Cutaneous manifestations
  - of amebiasis, 269
  - of human hookworm disease, 270-271
  - of strongyloidiasis, 273
- Cutaneous nerve biopsy
  - and leprosy, 333
- Cutaneous trauma, 143-156
  - anatomy, 146-148
  - evaluation and first aid, 148-149
  - friction blisters, 144-146
  - microbiology, 149
  - pathogenesis, 144-145
  - prevention and treatment, 145-146
  - risk factors, 145
  - surgical intervention, 149-154
- Cutaneous viral infections
  - See Viral infections, cutaneous
- Cutis marmorata, 31
- Cyanides in chemical warfare, 105
- Cytologic diagnosis
  - of genital herpes, 528-529

## D

- da Costa Cruz, 393, 415
- da Rocha-Lima, Henrique, 456
- Dally, Clarence, 70
- Damsch, 358
- Dante, 324
- Dapsone
  - and leprosy, 343
  - See also Drugs
- Darier, Jean, 380
- Darius I, 321
- Darling, Samuel Taylor, 456
- Daves, J.S., 569
- Debridement, 151



- Dengue hemorrhagic fever, 198-200  
 laboratory findings and treatment, 200  
 signs and symptoms, 200
- Deoxyfructo-5-hydroxytryptamine (DF5-HT)  
 and leprosy, 346  
*See also* Drugs
- Dermatitis  
*See* Allergic contact dermatitis; Atopic dermatitis; Contact dermatitis; Irritant contact dermatitis
- Dermatology  
*See* Military dermatology
- Dermatophytes, 424
- Dermatophytosis, 425-437  
 clinical features, 425-426  
 diagnosis, 433-434  
 tinea barbae, 428  
 tinea capitis, 426-428  
 tinea corporis, 428-430  
 Majocchi granuloma, 429  
 tinea faciei, 429  
 tinea imbricata, 429-430  
 tinea cruris, 430  
 tinea manuum, 431  
 tinea pedis, 430-431  
 tinea unguium, 432-433  
 treatment, 434-437
- Deutschmann, 358
- Dhobie itch, 117
- Dhobie mark dermatitis, 117
- Diadochen, 321
- Diagnosis, principles, 6-19  
 anatomy, 6  
 differential diagnostic considerations, 8, 13-18  
 patient history, 7  
 physical examination, 7, 8-12
- Diethyltoluamide dermatitis, 132
- Diphtheria, 301-305  
 clinical manifestations, 303-304  
 diagnosis, 304  
 epidemiology, 302-303  
 etiology, 302  
 immunization, 305  
 treatment, 304-305
- Direct cold injury, 27-30  
 asteatotic eczema, 27  
 frostbite, 28-30
- Dog bites, 180
- Donovan, C., 257, 519
- Donovanosis, 519  
*See also* Granuloma inguinale
- Dopter, 305
- Doughty, John W., 73, 74, 75
- Downgrading reaction, in leprosy, 347, 351
- Dracunculiasis, 279-280  
 clinical manifestations, 279  
 diagnosis, 279-280  
 treatment, 280
- Dracunculus medinensis*  
 and dracunculiasis, 279
- Drugs  
 antimycotic, 435  
 against leprosy, 343-346
- Drugs, topical  
 and contact dermatitis, 123-125
- Duncan, T., 4
- Dyshidrosis, 45
- Dyshidrotic eczema  
 and heat and humidity, 45-46
- ## E
- Ebola hemorrhagic fever, 208-209  
 laboratory findings and treatment, 208-209  
 signs and symptoms, 208
- Ebstein, 358
- Ecthyma, 293
- Ecumenical Council to the Lateran, 73
- Edison, Thomas, 70
- Edward the Confessor, 357
- Egypt, ancient  
 and leprosy, 321
- Ehrlich, 358, 359
- Ehrlichiae, 240  
*See also* Ehrlichiosis; Sennetsu fever
- Ehrlichiosis, 215, 241-244  
 clinical findings, 243  
 diagnosis, 243-244  
 differential diagnosis, 243  
 epidemiology, 242  
 laboratory findings, 243  
 microbiology, 241  
 treatment, 244  
 vectors and reservoirs, 241-242
- Emergency War Surgery* NATO Handbook, 6
- Emperor Gwyo, 323
- Empress Komyo, 323
- Endemic (murine) typhus, 215, 233-235  
 clinical manifestations, 234  
 control, 235  
 diagnosis, 234  
 differential diagnosis, 234  
 epidemiology, vectors, and hosts, 233-234  
 laboratory findings, 234  
 microbiology, 233  
 treatment, 234
- Endocervicitis, 509
- Entomophthoromycosis, 482-483
- Epidemic typhus, 215, 229-233  
 and Brill-Zinsser disease, 233  
 clinical findings, 231-232  
 control, 232-233  
 diagnosis, 232  
 differential diagnosis, 232  
 epidemiology, hosts, and vectors, 230-231  
 laboratory findings, 232  
 microbiology, 230  
 military significance, 229-230  
 treatment, 232
- Epidermization  
 in wound healing, 152-153
- Epidermodysplasia verruciformis, 583
- Epigrammata Medicae Philosophicae*, 531
- Erosion, 10
- Erythema chronicum migrans, localized, 310
- Erythema induratum, 380-382  
 clinical features, 381  
 course, 382  
 differential diagnosis, 382  
 epidemiology, 380-381  
 etiology and pathogenesis, 381  
 histopathology, 381  
 laboratory features, 381

treatment, 382  
Erythema nodosum leprosum, 347  
  histological findings, 350  
  treatment, 350-351  
Erythralgia  
  and heat and humidity, 47  
Erythrocyanosis, 34  
  clinical manifestations, 34  
  etiology, 34  
  treatment, 34  
Erythromycin  
  for chancroid, 518  
Erythropoietic protoporphyria, 52  
Espundia, 261  
Esthiomene, 523  
Ethionamide  
  and leprosy, 345  
  *See also* Drugs  
Ethiopia  
  and murine typhus, 234  
Euphorbin, 133  
Europe  
  and histoplasmosis, 457  
  and leprosy in the Middle Ages, 323-324  
  and leprosy in the Renaissance, 324  
  and Lyme disease, 311  
  and plague, 295  
  and syphilis, 498  
  and tularemia, 300  
Evaporation, 25  
Exposure duration  
  and heat loss, 26  
Eye findings  
  and Rocky Mountain spotted fever, 219  
  *See also* Herpes zoster ophthalmicus  
Eyedrops  
  *See* Topical drugs  
Eyelids  
  and contact dermatitis, 135

## F

Face  
  and contact dermatitis, 135-136  
  and cutaneous trauma, 146-147  
Faget, Guy, 325  
Feasby, W.R., 4  
Feet  
  and contact dermatitis, 137  
Fibroplasia  
  in wound healing, 152  
Filariae  
  of medical significance, 274  
Filariasis, 274-279  
  Bancroftian, 274-275  
  loiasis, 276-277  
  Malayan, 275  
  onchocerciasis, 277-279  
  streptocerciasis, 279  
  Timorian, 275  
Filiform warts, 581  
Filoviridae-caused hemorrhagic fevers, 208-209  
Finlay, Charles, 200-201  
Fire ants, 169  
Fissure, 10  
Fitzpatrick, T.B., 560  
Flat warts, 581, 583  
Flaviviridae-caused hemorrhagic fevers, 198-202

Fleas, 169-170, 190-193  
  and bites, 192  
  and papular urticaria, 192  
  and plague, 192  
  and tungiasis, 192-193  
  as vectors of diseases, 191  
Flexner, 305  
Foot injuries, 55-68  
  immersion foot, 63  
  management, 63  
  trench foot, 57-62  
  tropical immersion foot, 64-66  
  warm water immersion foot, 66  
Fort Chaffee, Arkansas, 241  
Fracastorius, 324  
Fragrances  
  and contact dermatitis, 131  
*Franciscella tularensis*, 84, 299  
Franco-Prussian War  
  and frostbite, 22  
Frederick the Great, 295  
Frei test, 524  
Friction blisters, 144-146  
  and heat and humidity, 47  
  pathogenesis, 144-145  
  prevention and treatment, 145-146  
  risk factors, 145  
Friede, H., 190  
Friedländer, 358  
Friedman, 415  
Frostbite, 28-30  
  clinical manifestations, 28-29  
  etiology, 28  
  prognostic signs, 29  
  treatment, 30  
Frostnip, 28  
Fuller, J.F.C., 76  
Fungal skin diseases, deep, 453-492  
  actinomycosis, 483-485  
  blastomycosis, 464-467  
  chromoblastomycosis, 473-475  
  coccidioidomycosis, 459-464  
  cryptococcosis, 481-482  
  entomophthoramycosis, 482-483  
  histoplasmosis and histoplasmosis duboisii, 456-459  
  introduction, 454-456  
  lobomycosis, 478-479  
  mycetoma, 475-478  
  nocardiosis, 485  
  paracoccidioidomycosis, 467-469  
  rhinosporidiosis, 480-481  
  sporotrichosis, 470-473  
Fungal skin diseases, superficial, 423-451  
  candidosis, 437-443  
    clinical features, 438-441  
    diagnosis, 441-442  
    treatment, 442-443  
  causative fungi, 424  
  dermatophytosis, 425-437  
    clinical features, 425-426, 426-433  
    diagnosis, 433-434  
  Majocchi granuloma, 429  
  tinea barbae, 428  
  tinea capitis, 426-428  
  tinea corporis, 428-430  
  tinea cruris, 430  
  tinea faciei, 429  
  tinea imbricata, 429-430

tinea manuum, 431  
 tinea pedis, 430-431  
 tinea unguium, 432-433  
 treatment, 434-437  
 epidemiology and military history, 424-425  
 miscellaneous infections, 447-449  
   black piedra, 448  
   tinea nigra, 447-448  
   white piedra, 448-449  
 pityrosporum infections, 443-447  
   clinical features, 443-445  
   diagnosis, 445-447  
   treatment, 447  
 Fungal skin infections  
   and heat and humidity, 46  
 Fungi, 424  
 Funk, E.H., 356  
 Furunculosis, 293

## G

Galen, 22, 322, 324, 357  
 Gambia  
   and yellow fever, 201  
 Gastrointestinal manifestations  
   of human hookworm disease, 271-272  
   of strongyloidiasis, 273  
   *See also* Intestinal manifestations  
 Genetics  
   and leprosy, 328-329  
 Geneva Gas Protocol, 73  
 Genital herpes, 525-531  
   clinical manifestations, 525-528  
   in immunocompromised patients, 527-528  
   nonprimary infection, 527  
   primary infection, 525-527  
   recurrent infection, 527  
   laboratory diagnosis, 528-530  
     antigen detection, 529-530  
     cytologic diagnosis, 528-529  
     serologic testing, 530  
     viral culture, 528  
   treatment, 530-531  
 Genital warts, 531-537  
   clinical manifestations, 533-535  
   diagnosis, 535-536  
   treatment, 536-537  
 Germany  
   and chemical warfare, 75  
   research to inactive mustard compounds, 103-104  
 Ghon, 305  
 Gila monsters, 179-180  
 Gilchrist, Thomas Caspar, 464  
 Ginkgo  
   and contact dermatitis, 119-120  
*Gluta*  
   and contact dermatitis, 120  
 Goeckerman, W.H., 559  
 Gold  
   and contact dermatitis, 128  
 Goldberg, 360  
 Gonococcal infection, disseminated  
   diagnosis, 510-511  
   treatment, 514-515  
 Gonococcal infection, uncomplicated  
   treatment, 513-514  
 Gonorrhea, 508-515  
   clinical manifestations, 508-511

asymptomatic infection in men, 509  
 complicated infections, 510  
 disseminated gonococcal infection, 510-511  
 endocervicitis in women, 509  
 infections in infants and children, 511  
 pharyngeal infection, 510  
 rectal infection, 510  
 urethritis in men, 508-509  
 laboratory diagnosis, 511-513  
 treatment, 513-515  
 Gorgas, William, 456  
 Granulation  
   in wound healing, 152  
 Granuloma inguinale, 519-521  
   clinical manifestations, 519-520  
   complications, 520-521  
   laboratory diagnosis, 521  
   treatment, 521  
 Great Dying, 295  
 Great Fire of 1666, 295  
 Great Pestilence, 295  
 "Great Pox," 498  
 Greece, ancient  
   and leprosy, 321-322  
 Groin  
   and contact dermatitis, 136  
 Ground itch, 270  
 Guatemala  
   and onchocerciasis, 278  
 Guiton, C.R., 356  
 Gummata, 503  
 Guttate psoriasis, 555

## H

Haber, L.F., 73  
 Haffkine, 296  
 Hammurabi, 320  
*Handbook of Diseases of the Skin*, 356  
 Hands  
   and contact dermatitis, 137  
 "Hanging groin," 278, 279  
 Hansen, G. Armave, 324, 392  
 Hansen's disease  
   *See* Leprosy  
 Hantaan virus, 204  
 Harwood, R.F., 184  
 Hawaii  
   and allergenic, indigenous plants, 120  
 Hazleton Research Products, 208  
 Head  
   and cutaneous trauma, 146-147  
 Head lice, 162-164  
 Heat cramps, 41  
 Heat exhaustion, 41  
 Heat injury, 40-41  
   cramps, 41  
   exhaustion, 41  
   heatstroke, 41  
 Heat loss mechanisms, 24-25  
   conduction, 24  
   convection, 24  
   evaporation, 25  
   radiation, 24-25  
   respiration, 25  
 Heatstroke, 41  
 Hebra, 32  
 Hellerström, 393

Helminthic infections, 269-282  
  animal hookworm, 272  
  dracunculiasis, 279-280  
  filariasis, 274-279  
  human hookworm disease, 270-272  
  schistosomiasis, 280-283  
  strongyloidiasis, 272-273  
  trichinosis, 280  
Helminths, 269  
  and cutaneous disease, 270  
Hematologic manifestations  
  of strongyloidiasis, 273  
Hemorrhagic fevers, viral, 197-212  
  Argentine, 206-207  
  associated viruses, 199  
  Bolivian, 207  
  Crimean-Congo, 203  
  dengue, 198-200  
  Ebola, 208-209  
  introduction, 198  
  Kyasanur Forest disease, 202  
  Lassa fever, 205-206  
  Marburg, 209  
  Omsk, 202  
  prevention, 210  
  with renal syndrome, 203-205  
  Rift Valley fever, 202-203  
  supportive treatment, 210  
  yellow fever, 200-202  
Hemorrhagic fevers in biological warfare, 84-87  
  cutaneous and other clinical findings, 84-85  
  diagnosis, 85  
  military significance, 86-87  
  prophylaxis, 86  
  treatment, 85-86  
Henry IV, 357  
Henry of Navarre, 357  
Herodotus, 321  
Herpes simplex labialis, 575-577  
  clinical features, 575-576  
  diagnosis, 576  
  treatment, 577  
Herpes zoster, 577-580  
  clinical features, 577-578  
  diagnosis, 579  
  treatment, 579-580  
  types, 578-579  
Herpes zoster ophthalmicus, 578-579  
Herxheimer, 132  
Hippocrates, 22, 321, 322, 357  
Histamine  
  agents, and urticaria, 570-571  
Histoplasmosis and histoplasmosis duboisii, 456-459  
  clinical manifestations, 457-458  
  diagnosis, 458-459  
  epidemiology and distribution, 457  
  history, 456-457  
  military implications, 459  
  treatment, 459  
Histoplasmosis duboisii  
  *See* Histoplasmosis and histoplasmosis duboisii  
*History of the First Gas Regiment*, 75  
Hitler, Adolf, 75  
Hollstrom, E., 309  
Hookworm  
  animal, 272  
  human, 270-272  
Hornets

*See* Bees, wasps, and hornets  
Hugar, D.W., 62  
Human hookworm disease, 270-272  
  clinical manifestations, 270-272  
  diagnosis and treatment, 272  
Human papillomavirus (HPV)  
  types, 532  
Hunter, John, 498  
Hutchinson, Jonathan, 34, 360  
Hydrocarbons  
  and irritant contact dermatitis, 132  
Hypohidrosis syndrome  
  and heat and humidity, 44  
Hyskos, 321

## I

Iatrogenic immunization tuberculosis, 375  
Immersion foot, 63  
Immersion foot syndromes, 57  
  comparison, 60-61  
Immunity, cell-mediated  
  and leprosy, 330  
Immunity, humoral  
  and leprosy, 329-330  
Immunization  
  against diphtheria, 305  
  against meningococcal infections, 308  
  *See also* Vaccines  
Immunocompromised patients  
  and genital herpes, 527-528, 531  
  *See also* Acquired immunodeficiency syndrome (AIDS)  
Immunoglobulin E  
  and mediation of urticaria, 571  
Impetigo, 293  
India  
  and allergenic, indigenous plant, 117  
  ancient, and leprosy, 322  
  and dracunculiasis, 279  
  and histoplasmosis, 457  
  and Kyasanur Forest disease, 202  
  and lymphogranuloma venereum, 522  
  and murine typhus, 234  
  and mycetoma, 476  
  and plague, 295-296  
  and rhinosporidiosis, 480  
India marking nut tree  
  and contact dermatitis, 117  
Indirect cold injury, 31-36  
  acrocyanosis, 33  
  cold panniculitis, 34  
  erythrocyanosis, 34  
  livedo reticularis, 31-33  
  pernio, 31  
  Raynaud's disease and phenomenon, 34-36  
  trench foot, 34  
Indonesia  
  and histoplasmosis, 457  
  and schistosomiasis, 281  
Infants  
  and gonorrhoea, 511  
Inflammation  
  in wound healing, 152  
Insect repellents  
  *See* Diethyltoluamide dermatitis  
Insects, 160-170  
  bedbugs, 193-194  
  beetles, 167

biting flies, 194  
 caterpillars and moths, 160-161  
 fleas, 169-170, 190-193  
 lice, 162-164, 193  
 mosquitoes and flies, 164-167  
 stinging insects, 168-169  
 true bugs, 161-162  
*See also* Arachnids; Arthropods; Centipedes and millipedes  
 Intertrigo, 438-439  
 Intestinal manifestations  
   of amebiasis, 268-269  
   *See also* Gastrointestinal manifestations  
 Iran  
   and sulfur mustard victims, 95-97  
 Irritant contact dermatitis, 131-133  
   and alkalis and acids, 132  
   chloracne, 132-133  
   diethyltoluamide dermatitis, 132  
   and hydrocarbons, 132  
   from plants, 133  
 Irving, Laurence, 57  
 Isocrates, 357  
 Isolation  
   of rickettsiae, 221-222  
 Italy  
   and chemical warfare, 75

## J

James, M.T., 184  
 Japan  
   and allergenic, indigenous plant, 117-118  
   ancient, and leprosy, 323  
   and chemical warfare, 75  
   and Sennetsu fever, 244  
   and sporotrichosis, 470  
 Japanese lacquer tree  
   and contact dermatitis, 117-118  
 John of Gaddesden, 324

## K

*Kanjin*, 323  
 Katayama fever  
   *See* Schistosomiasis  
 Kerandel's sign, 267  
 Kerion, 427  
 Kiefer, 305  
 Kirchheimer, Waldemar, 325  
 Kissing bugs, 162, 263  
 Kitasato, 296  
 Klebs, E., 302, 358  
 Klingmüller, V., 320  
 Koch, Robert, 356, 358-361, 381, 392  
 Köebner's phenomenon, 553  
 Korean conflict  
   and chancroid, 515  
   and cold injuries, 23-24  
   and heat injuries, 40  
   and jump boots, 56  
   and meningococcal disease, 306  
   and sexually transmitted diseases, 497  
   and tuberculosis, 361  
 Kortum, 357  
 Koster, 358  
 Ktesias, 321  
 Kuflik, E.G., 561  
 Kwo-Hon, 323  
 Kyasanur Forest disease, 202

## L

Laennec, René, 357  
 Lai-ping, 323  
 Lamb, B.H., 300  
 Lamberg, S.I., 132  
 Langhans, 358  
 Lanolin  
   and allergic contact dermatitis, 131  
 Larrey, Baron, 22  
 Lassa fever, 205-206  
   laboratory findings and treatment, 206  
   signs and symptoms, 206  
*Last Judgment*, 71, 72  
 Leakey virus, 204  
 Leather  
   *See* Shoes  
 Leiferman, K.M., 570  
 Leishman, W.B., 257  
 Leishmaniasis, 256-263  
   cutaneous manifestations, 258-260  
   diagnosis, 262  
   mucocutaneous manifestations, 260-261  
   treatment, 262-263  
   visceral manifestations, 261-262  
 Lennhoff, C., 309  
 Lepromin test  
   and leprosy, 330-331  
 Leprosy, 319-354  
   and acquired immunodeficiency syndrome, 352  
   clinical and histological diagnostic criteria, 333-342  
   complications, 346-351  
   epidemiology, 326-328  
   history, 320-326  
   immunology, 329-331  
   introduction, 320  
   laboratory diagnosis, 331-333  
   microbiology, 328-329  
   pathogenesis, 335  
   treatment, 343-346  
   vaccination, 351  
 Lewisite (L), 101  
   compared with mustard, 102  
 Lice, 162-164, 193  
   body, 164  
   head, 162-164  
   pubic, 164  
 Lichen planus, 561-564  
   clinical features, 561-563  
   diagnosis, 563  
   military considerations, 564  
   pathogenesis, 563  
   treatment, 563-564  
   variants, 562  
 Lichen scrofulosorum, 383-384  
   clinical features, 384  
   course, 384  
   differential diagnosis, 384  
   laboratory and histopathological features, 384  
   prognosis, 384  
   treatment, 384  
 Lichenification, 10  
 Linear lesions, 12  
 Linell, 394  
 Liston, 296  
 Livedo reticularis, 31-33  
   clinical manifestations, 33  
   etiology, 32-33

- treatment, 33
- Livingood, C.S., 4, 56, 551
- Loa loa*, 276
  - See also Loiasis
- Lobo, Jorge, 478
- Lobomycosis, 478-479
  - clinical manifestations, 479
  - diagnosis, 479
  - epidemiology and distribution, 478-479
  - treatment, 479
- Loeffler, 302
- Loiasis, 276-277
  - clinical manifestations, 276
  - diagnosis, 276
  - treatment, 276-277
- Long, E., 356
- LOST, 90
- Lovell, Joseph, 56
- Lucio's phenomenon, 347, 351
- Lucretius, 322
- Lupus vulgaris, 371-374
  - clinical features, 372-373
  - course and prognosis, 374
  - differential diagnosis, 374
  - epidemiology, 371
  - histological features, 373
  - laboratory features, 373
  - pathogenesis, 371-372
- Lutz, Adolpho, 467
- Lyme disease, 309-313
  - clinical manifestations, 309-312
  - diagnosis, 312
  - epidemiology, 309
  - and mites and ticks, 187-188
  - treatment, 312-313
- Lymphogranuloma venereum, 522-525
  - clinical manifestations, 522-523
  - laboratory diagnosis, 524
  - treatment, 524-525

## M

- M258 kit, 89, 102
- M-1944 Shoepac, 56
- MacKenna, R.M.B., 5
- Macule, 8
- Magée, James C., 3
- Maggots, 165-167
- Admiral Mahan, 73
- Mahrle, G., 584
- Majocchi granuloma, 429
- Malassezia furfur, 443
- Malaya
  - and murine typhus, 234
- Malayan filariasis, 275
- Malaysia
  - and filariasis, 275
  - and Sennetsu fever, 244
- Management
  - of vesicant injury, 101
- Manetho, 321
- Mango
  - and contact dermatitis, 118
- Manson, Patrick, 324
- Mansonella streptocerca*, 279
  - See also Streptocerciasis
- Mantoux, Charles, 360
- Marburg hemorrhagic fever, 209

- Maturation
  - in wound healing, 153
- McCoy, G.W., 299
- McCrae, T., 356
- Mein Kampf*, 75
- Mellanby, K., 159
- Men
  - and gonorrhea, 508-509
  - and nickel dermatitis, 127
  - See also Sex differences; Women
- Meningitis, 307
- Meningococcal infections, 305-308
  - chemoprophylaxis in carriers, 308
  - clinical manifestations, 307-308
  - diagnosis, 308
  - epidemiology, 306
  - etiology, 306
  - treatment, 308
  - vaccines, 308
- Meningococcal pneumonia, 307-308
- Meningococcemia, fulminant, 307
- Mercurialis, 184
- Mercury
  - and contact dermatitis, 127-128
- Metals
  - and contact dermatitis, 125-128
- Methotrexate, systemic
  - in treatment of psoriasis, 559
- Mexico
  - and murine typhus, 234
  - and mycetoma, 476
  - and onchocerciasis, 278
  - and sporotrichosis, 470
- Microbiology and Virology Institute, 84
- Microscopy, dark-field
  - for syphilis, 504
- Microscopy, direct fluorescence
  - for syphilis, 504
- Middle East
  - and schistosomiasis, 281
- Miliaria, 41-44
  - crystallina, 42
  - and heat and humidity, 41-44
  - pathogenesis and treatment, 42-44
  - profunda, 42
  - pustulosa, 42
  - rubra, 42
- Miliary tuberculosis of the skin, 369
  - clinical features, 369
  - course and prognosis, 369
  - differential diagnosis, 369
  - laboratory and histological features, 369
- Military dermatology
  - recommendations, 5-6
  - unlearned lessons, 4-5
  - in Vietnam conflict, 3-4
  - in World War I, 2
  - in World War II, 3
- Millipedes
  - See Centipedes and millipedes
- Minocycline
  - and leprosy, 346
  - See also Drugs
- Miracidium, 281
- Mites and ticks, 170-171, 185-190
  - characteristics, 185-187
  - as disease vectors, 186
  - and handling, 187

- and Lyme disease, 187-188
- nonscabetic mites, 173-174
- and relapsing fever, 188
- and Rickettsial diseases, 188-189
- scabetic mites, 172-173
- and tick paralysis, 189-190
- and tick-bite alopecia, 190
- and tick-bite reactions, 190
- Molluscum contagiosum, 537-540, 580-581
  - clinical features, 537-539, 580
  - complications, 539
  - diagnosis, 539-540, 580-581
  - treatment, 540, 581
- Modern Medicine: Its Theory and Practice*, 356
- Modern times
  - and advances against leprosy, 324-325
- Móller-Christensen, 324
- "Moon-boot syndrome," 66
- Morgagni, 357
- Morphologic index
  - and leprosy, 333
- Morton, Samuel, 357
- Moses, 321
- Mosquitoes and flies, 164-167
  - as vectors of diseases, 165
  - See also Biting flies
- Moths
  - See Caterpillars and moths
- Mulrennan, J.A., 132
- Multibacillary leprosy
  - treatment, 343
- Multidrug-resistant tuberculosis, 376
- Murine typhus, 233-235
  - See also Rickettsial diseases
- Musculoskeletal manifestations
  - of Lyme disease, 311
- Mustard
  - compared with Lewisite, 102
- Mustard toxicity
  - skin manifestations, 98
- Mycetoma, 475-478
  - clinical manifestations, 476-477
  - diagnosis, 477-478
  - epidemiology and distribution, 476
  - history, 475
  - treatment, 478
- Mycobacterial diseases, atypical, 391-422
  - and acquired immunodeficiency syndrome, 404, 417
  - atypical infections, 404-417
  - classification systems, 398-400
  - colony growth
    - and temperature, 403
  - diagnosis and isolation, algorithm, 402
  - epidemiology, 397-398
    - distribution, 398
    - incidence, 397
    - organism sources, 397-398
  - histopathology, 400
  - history, 392-396
    - general, 392-395
    - military, 395-396
  - mycobacteriology, 401-404
- Mycobacterium*, 401
- Mycobacterium avium-intracellulare* disease, 411-412
  - clinical presentation, citations, 408
  - course, treatment, prognosis, prevention, 412
  - diagnostic features, 411-412
    - histopathology, 412
    - laboratory features, 412
  - epidemiology, 411
- Mycobacterium chelonae* disease
  - clinical presentation, citations, 408
- Mycobacterium fortuitum-chelonae* complex disease, 415-416
  - course, treatment, prognosis, prevention, 416
  - diagnostic features, 415-416
    - histopathology, 416
    - laboratory features, 416
  - epidemiology, 415
- Mycobacterium gordonae* disease, 410-411
  - clinical presentation, citations, 408
  - course, treatment, prognosis, prevention, 411
  - diagnostic features, 410-411
    - histopathology, 410-411
    - laboratory features, 411
  - epidemiology, 410
- Mycobacterium haemophilum* disease, 413-414
  - course, treatment, prognosis, prevention, 414
  - diagnostic features, 414
    - histopathology, 414
    - laboratory features, 414
  - epidemiology, 413-414
- Mycobacterium kansasii* disease, 407
  - clinical presentation, citations, 408
  - course, treatment, prognosis, prevention, 407
  - diagnostic features, 407
    - histopathology, 407
    - laboratory features, 407
  - epidemiology, 407
- Mycobacterium leprae*
  - and drug resistance, 345-346
  - persistence, 346
  - See also Leprosy
- Mycobacterium malmðense* disease, 414-415
  - course, treatment, prognosis, prevention, 414-415
  - diagnostic features, 414
    - histopathology, 414
    - laboratory features, 414
  - epidemiology, 414
- Mycobacterium marinum* disease, 404-407
  - clinical presentation, citations, 408
  - course, treatment, prognosis, prevention, 406-407
  - diagnostic features, 405-406
    - differential diagnosis, 405-406
    - histopathology, 406
    - laboratory features, 406
  - epidemiology, 404-405
- Mycobacterium scrofulaceum* disease, 409
  - clinical presentation, citations, 408
  - course, treatment, prognosis, prevention, 409
  - diagnostic features, 409
    - histopathology, 409
    - laboratory features, 409
  - epidemiology, 409
- Mycobacterium smegmatis* disease, 416-417
  - course, treatment, prognosis, prevention, 416-417
  - diagnostic features, 416
    - histopathology, 416
    - laboratory features, 416
  - epidemiology, 416
- Mycobacterium szulgai* disease, 408-409
  - course, treatment, prognosis, prevention, 408-409
  - diagnostic features, 408
    - histopathology, 408
    - laboratory features, 408
  - epidemiology, 408
- Mycobacterium ulcerans* disease, 412-413

course, treatment, prognosis, prevention, 413  
diagnostic features, 412-413  
  histopathology, 413  
  laboratory features, 413  
epidemiology, 412  
*Mycobacterium xenopi* disease, 409-410  
  course, treatment, prognosis, prevention, 410  
  diagnostic features, 410  
  histopathology, 410  
  laboratory features, 410  
  epidemiology, 409-410  
Mycoses, opportunistic, 481-485  
Mycoses, subcutaneous, 470-481  
Mycoses, systemic, 456-469  
Mycotoxins in biological warfare, 87-90  
  clinical findings, 88  
  cutaneous findings, 88  
  diagnosis, 88-89  
  military significance, 89-90  
  prophylaxis, 89  
  treatment, 89  
Myocardial manifestations  
  of Lyme disease, 311  
Myocarditis  
  and diphtheria, 303

**N**

Napoleon, 230, 295  
Napoleonic Wars  
  and cold injuries, 22  
Native Americans  
  and biological warfare, 71  
  and mosquitoes, 184  
  and polymorphous light eruption, 50  
  and syphilis, 498  
Neck  
  and contact dermatitis, 136  
Neisser, Albert L.S., 356, 358  
Nematodes, 269  
  *See also* Helminthic infections  
Neomycin  
  and allergic contact dermatitis, 123  
Nernst, Walther, 73  
Nerve agents in chemical warfare, 105  
Nerve biopsy, cutaneous  
  and leprosy, 333  
Neuralgia, postherpetic, 579  
Neurological manifestations  
  of Lyme disease, 311  
  and Rocky Mountain spotted fever, 219  
New Guinea  
  and atypical mycobacterial infections, 412  
New York City  
  and Rickettsialpox, 228  
Nickel  
  and contact dermatitis, 126-127, 136  
Nigeria  
  and yellow fever, 201  
Nitrogen mustard  
  *See* Sulfur mustard and nitrogen mustard in chemical warfare  
Nocardiosis, 485  
  clinical presentation, citations, 408  
Nodule, 9  
Nonscabietic mites, 173-174  
Nonsteroidal antiinflammatory drugs (NSAIDs), 103

Nontreponemal tests  
  and false-positive reactions, 507  
  for syphilis, 505  
  *See also* Treponemal tests  
Norden, 394  
Norris, D.A., 563  
North Africa  
  and mustard poisoning, 101  
Nuclear warfare, 76-82  
  history, 70-71  
  radiation and thermal effects, 76-79  
  cutaneous, treatment, 79-81  
  sequelae, late, 81-82

**O**

Ofloxacin  
  and leprosy, 346  
  *See also* Drugs  
Oklahoma  
  and sporotrichosis, 470  
Oleoresin, 114  
Omsk hemorrhagic fever, 202  
*Onchocerca volvulus*, 277  
  *See also* Onchocerciasis  
Onchocerciasis, 277-279  
  clinical manifestations, 277-278  
  diagnosis, 278-279  
  treatment, 279  
Onychomycosis, 432, 439-441  
Oozing, 10  
Operations Desert Shield/Desert Storm  
  and heat injuries, 40  
Organization  
  and military dermatology, 4, 5-6  
Oriol, J.D., 531  
Orr, K., 24  
Osler, W., 356  
Oximes, halogenated  
  in chemical warfare, 104-105

**P**

Pacific  
  and filariasis, 274  
"Paddy foot," 64  
Pakistan  
  and dracunculiasis, 279  
  and murine typhus, 234  
Papular urticaria  
  and fleas, 192  
Papule, 9  
Papulonecrotic tuberculid, 382-383  
  clinical findings, 383  
  course, 383  
  differential diagnosis, 383  
  epidemiology, 382-383  
  laboratory and histopathological findings, 383  
  pathogenesis, 382  
  treatment, 383  
Paracoccidioidomycosis, 467-469  
  clinical manifestations, 468-469  
  diagnosis, 469  
  epidemiology and distribution, 467  
  history, 467  
  treatment, 469  
Parasitic infections, tropical, 255-290  
  African trypanosomiasis, 266-268



- amebiasis, 268-269
- animal hookworm, 272
- dracunculiasis, 279-280
- filariasis, 274-279
- human hookworm disease, 270-272
- introduction, 256
- leishmaniasis, 256-263
- schistosomiasis, 280-283
- South American trypanosomiasis, 263-265
- strongyloidiasis, 272-273
- trichinosis, 280
- Paronychia, 439-441
- Parrish, J.A., 560
- Pasteur, Louis, 184, 358
- Paucibacillary leprosy
  - treatment, 343
- Pefloxacin
  - and leprosy, 346
  - See also* Drugs
- Pellagra, 52
- Peloponnesian War
  - and chemical warfare, 73
- Perfumes
  - and contact dermatitis, 131
- Pernio, 31
  - clinical manifestations, 31
  - etiology, 31
  - treatment, 31
- Perry, H.O., 562
- Persia, ancient
  - and leprosy, 321
- Peru
  - balsam of, and dermatitis, 131
- Peterson, G., 62
- Pharaoh Sapti 5th, 321
- Pharynx
  - and gonorrhoea, 510
- Philippine Insurrection
  - and leprosy, 325
- Philippines
  - and filariasis, 275
  - and schistosomiasis, 281
- Philon, 322
- Philumenus, 322
- Phosgene oxime (CX), 104-105
- Phototoxicity and photoallergy, 48, 49-50
- Piatt, A.D., 361
- Piedra, black, 448
- Piedra, white, 448-449
- Pillsbury, D.M., 4, 56, 551
- Pin-yüan-hou-lun, 323
- Pityriasis versicolor, 443-444
- Pityrosporum folliculitis, 444-445
- Pityrosporum infections, 443-447
  - clinical features, 443-445
  - diagnosis, 445-447
  - treatment, 447
- Plague, 295-299
  - in biological warfare, 84
  - clinical features, 297-298
  - diagnosis, 298
  - epidemiology, 296-297
  - etiology, 296
  - and fleas, 192
  - laboratory findings, 298
  - transmission, 296-297
  - treatment, 298-299
- Plantar warts, 581-583
- Plants
  - and contact dermatitis, 113-114
  - geographical distribution, 120-123
  - and irritant contact dermatitis, 133
  - See also* individual plants
- Plaque, 9
- Platinum
  - and contact dermatitis, 128
- Platyhelminths, 269
  - See also* Helminthic infections
- Pliny, 324, 357
- Pliny the Elder, 322
- Plutarch, 322
- Pneumonia, meningococcal, 307-308
- Pneumonic plague, 298
- Poison ivy and poison oak
  - and contact dermatitis, 114-117
  - field identification, 117
  - signs and symptoms, 114-117
- Poison sumac
  - and contact dermatitis, 117
- Polymorphous light eruption, 50-51
- Pompey, 322
- Pompholyx, 45
- Pope Damasius II, 324
- Pope Innocent III, 73
- Porphyria cutanea tarda, 52
- Posadas, Alejandro, 459
- Pregnancy
  - and condyloma acuminata, 535
  - and gonorrhoea, 515
  - and lymphogranuloma venereum, 525
  - and plague treatment, 299
  - and tetracycline, 301
  - and treating genital warts, 537
  - and treating Lyme disease, 313
- Preservatives
  - and contact dermatitis, 130-131
- Prevention, Treatment and Control of Heat Injury*, 40
- Prickly heat, 42
- Primary inoculation tuberculosis, 365-368
  - clinical features, 367
  - course and prognosis, 367
  - differential diagnosis, 367-368
  - epidemiology, 365
  - laboratory and histological features, 367
- Primary lesions, 8
- Promin, 326
- Properdin deficiency, 306
- Prospect Hill virus, 204
- Prothionamide
  - and leprosy, 345
  - See also* Drugs
- Protozoal infections, 256-269
  - African trypanosomiasis, 266-268
  - amebiasis, 268-269
  - leishmaniasis, 256-263
  - South American trypanosomiasis, 263-265
- Pseudofolliculitis barbae, 573-575
  - clinical features, 573
  - diagnosis, 574
  - military considerations, 575
  - pathogenesis, 573
  - and shaving guidelines, 574
  - treatment, 574-575
- Psoralen and ultraviolet-A phototherapy (PUVA)

- in treatment of psoriasis, 560
- Psoriasis, 552-561
  - clinical features, 553-555
  - diagnosis, 555
  - guttate, 555
  - military considerations, 560-561
  - psoriatic arthritis, 555, 558
  - pustular, generalized, 555
  - pustular, localized, 555
  - treatment, 555-560
  - vulgaris, 555
- Psoriasis vulgaris, 555
- Psoriatic arthritis, 555
- Pubic lice, 164
- Pulex irritans*, 190
- Pulmonary findings
  - of human hookworm disease, 271-272
  - and Rocky Mountain spotted fever, 219
  - of strongyloidiasis, 273
- Pustular psoriasis, generalized, 555
- Pustular psoriasis, localized, 555
- Pustule, 8
- PUVA (psoralen and ultraviolet-A phototherapy)
  - in treatment of psoriasis, 560
- Puumala virus, 204
- Pyodermas, 292-295
  - clinical features, 293-295
  - etiology, 292-293
  - prognosis, 295
  - treatment, 295

## Q

- Q fever, 215, 238-240
  - clinical findings, 239-240
  - diagnosis, 240
  - epidemiology, 239
  - microbiology, 238-239
  - prevention, 240
  - rare presentations, 239
  - treatment, 240

## R

- Racial differences
  - and coccidioidomycosis, 461
  - and pseudofolliculitis, barbae, 573
  - and pyodermas, 292
  - and Rocky Mountain spotted fever, 220
  - and sunburn, 47
- Radiation, 24-25
- Ramon, 302
- Ramsay Hunt's syndrome, 579
- Rawasley, H.M., 570
- Raynaud, 34-35
- Raynaud's disease and phenomenon, 34-36
  - causes, 34
  - clinical manifestations, 35
  - etiology, 35
  - treatment, 35-36
- Recrudescence typhus (Brill-Zinsser disease), 215, 233
- Rectum
  - and gonorrhea, 510
- Reed, Walter, 184, 200, 201, 210
- Rees, 324
- Refugees
  - and tuberculosis control, 379-380
- Reid, 357

- Relapsing fever
  - and mites and ticks, 188
- Renal syndrome, and hemorrhagic fever, 203-205
  - laboratory findings and treatment, 205
  - signs and symptoms, 204-205
- Renault, 32
- Reptiles, 179-180
  - gila monsters, 179-180
  - snakes, 179
- Research
  - and military dermatology, 6
- Respiration, 25
- Reston, Virginia
  - and Ebola virus, 208
- Retinoids, systemic
  - in treatment of psoriasis, 559
- Reversal reaction, in leprosy, 346-349
  - histological findings, 348
  - treatment, 348, 349
- Rhameses II, 321
- Rhinosporidiosis, 480-481
  - clinical manifestations, 480-481
  - diagnosis, 481
  - epidemiology and distribution, 480
  - history, 480
  - treatment, 481
- Richter, 321
- Ricketts, Howard T., 229
- Rickettsiae
  - identifying, 222
  - isolating, 221-222
  - of spotted fever group diseases, 226
- Rickettsial diseases, 213-254
  - boutonneuse fever, 225-228
  - ehrlichiosis, 241-244
  - endemic (murine) typhus, 233-235
  - epidemic typhus, 229-233
  - introduction, 214
  - and mites and ticks, 188-189
  - Q fever, 238-240
  - recrudescence typhus (Brill-Zinsser disease), 233
  - rickettsialpox, 228-229
  - Rocky Mountain spotted fever, 214-225
  - scrub typhus, 235-237
  - Sennetsu fever, 244
  - trench fever, 237-238
- Rickettsialpox, 215, 228-229
  - clinical findings, 228-229
  - differential diagnosis, 229
  - epidemiology, vectors, and hosts, 228
  - laboratory findings, 229
  - microbiology, 228
  - treatment, 229
- Ridley Logarithmic Scale, 332
- Rifampin
  - and leprosy, 343
  - See also* Drugs
- Rift Valley fever, 202-203
  - laboratory findings and treatment, 203
  - signs and symptoms, 202-203
- Rig veda sanhita, 322
- Rocky Mountain spotted fever, 214-225
  - clinical manifestations, 217-219
  - diagnosis, 220-222
  - differential diagnosis, 222-223
  - epidemiology and vectors, 216-217
  - laboratory findings, 219-220

- microbiology, 215-216
  - pathological findings, 222
  - prevention, 224-225
  - prognosis, 220
  - treatment, 223-224
  - vectors, 217
  - Roentgen, W.C., 70
  - Roman Empire
    - and leprosy, 322
  - Rosin
    - and allergic contact dermatitis, 131
  - Ross, M.S., 190
  - Roux, 302
  - Rubber compounds
    - and contact dermatitis, 129
  - Runyon, E.H., 392, 394, 396, 398-399
  - Rush, Benjamin, 22, 357
- S**
- Samman, P.D., 562
  - Sarin, 105
  - Satyriasis, 322
  - Scabietic mites, 172-173
  - Scale, 9
  - Scar, 11
  - Schenck, Benjamin Robinson, 470
  - Schick, 302
  - Schistosoma haematobium*, 280
  - Schistosoma japonicum*, 280
  - Schistosoma mansoni*, 280
  - Schistosoma mekongi*, 280
  - Schistosoma intercalatum*, 280
  - Schistosomiasis, 280-283
    - clinical manifestations, 281-282
    - diagnosis, 282
    - treatment, 282-283
  - Schistosomulum, 281
  - Scholtz, J.R., 567
  - Schüller, 358
  - Scopulariopsis (blochi)
    - clinical presentation, citations, 408
  - Scorpions, 174-175
  - Scrofuloderma, 369-371
    - clinical features, 369-370
    - course and prognosis, 371
    - differential diagnosis, 371
    - epidemiology, 369
    - laboratory and histopathological features, 370-371
  - Scrub typhus, 215, 235-237
    - clinical findings, 236
    - control, 237
    - diagnosis, 237
    - differential diagnosis, 236
    - epidemiology and vectors, 236
    - laboratory findings, 236
    - microbiology, 235-236
    - military significance, 235
    - treatment, 237
  - Scutt, R.W.B., 128
  - Scutula, 428
  - Secondary lesions, 8
  - Secundus, Cajus Plinius, 322
  - Seeber, Guillermo, 480
  - Sennetsu fever, 215, 244
  - Septicemic plague, 298
  - Septuigent, 321
  - Serologic testing, 504-506
    - of genital herpes, 530
    - and leprosy, 333
    - nontreponemal tests, 505
    - sensitivity of, in untreated syphilis, 506
    - treponemal tests, 505-506
  - Sex differences
    - and chancroid, 515
    - and erythralgia, 47
    - and papulonecrotic tuberculid, 382-383
    - and Raynaud's disease, 35
    - and Rocky Mountain spotted fever, 220
    - See also* Men; Women
  - Sex partners
    - and chancroid, 519
    - and gonorrhea, 514
    - and lymphogranuloma venereum, 525
  - Sexually transmitted diseases (STDs)
    - chancroid, 515-519
      - clinical manifestations, 516
      - laboratory diagnosis, 516-518
      - treatment, 518-519
    - genital herpes, 525-531
      - clinical manifestations, 525-528
      - laboratory diagnosis, 528-530
      - treatment, 530-531
    - genital warts, 531-537
      - clinical manifestations, 533-535
      - diagnosis, 535-536
      - treatment, 536-537
    - gonorrhea, 508-515
      - clinical manifestations, 508-511
      - laboratory diagnosis, 511-513
      - treatment, 513-515
    - granuloma inguinale, 519-521
      - clinical manifestations, 519-520
      - complications, 520-521
      - laboratory diagnosis, 521
      - treatment, 521
    - introduction, 494-497
    - lymphogranuloma venereum, 522-525
      - clinical manifestations, 522-523
      - laboratory diagnosis, 524
      - treatment, 524-525
    - and military impact, 497-498
    - molluscum contagiosum, 537-540
      - clinical manifestations, 537-539
      - complications, 539
      - diagnosis, 539-540
      - treatment, 540
    - syphilis, 498-508
      - clinical manifestations, 500-503
      - incidence, 499-500
      - laboratory diagnosis, 504-506
      - treatment, 506-508
  - Shaving guidelines
    - for pseudofolliculitis barbae, 574
  - Shelly, W.B., 570
  - Shepard, Charles, 325
  - Shingles
    - See* Herpes zoster
  - Shoes
    - and American Revolution, 56
    - and Civil War, 56
    - and contact dermatitis, 128-129
    - and risk of friction blister, 145
    - See also* Clothing

- Prince Shotokautai, 323  
Siegler, 361  
*Simulium* blackflies  
  and onchocerciasis, 277  
Skin anatomy, 6-7, 144  
Skin diseases, bacterial, 291-317  
  diphtheria, 301-305  
  introduction, 292  
  Lyme disease, 309-313  
  meningococcal infections, 305-308  
  plague, 295-299  
  pyoderma, 292-295  
  tularemia, 299-301  
Skin diseases, common, 549-595  
  dermatitis, atopic, 564-568  
  introduction, 550-551  
  lichen planus, 561-564  
  pseudofolliculitis barbae, 573-575  
  psoriasis, 552-561  
  urticaria, 568-572  
  viral infections, cutaneous, 575-584  
Skin diseases associated with heat and humidity  
  bacterial skin infections, 46  
  cholinergic urticaria, 45  
  dyshidrotic eczema, 45-46  
  erythralgia, 47  
  friction blisters, 47  
  fungal skin infections, 46  
  hypohidrosis syndrome, 44  
  miliaria, 41-44  
  tropical acne, 44-45  
Skin diseases associated with sunlight  
  erythropoietic protoporphyria, 52  
  phototoxicity and photoallergy, 48, 49-50  
  polymorphous light eruption, 50-51  
  porphyria cutanea tarda, 52  
  solar urticaria, 51-52  
  sunburn, 47-49  
*Skin Diseases in Vietnam, 1965-72*, 292, 396  
Slit-skin examination technique  
  and leprosy, 331  
Smadel, Joseph E., 235  
Smith, J.L., 63  
Snakes, 179  
Socks, 145  
Solar urticaria, 51-52  
Soman, 105  
South Africa  
  and histoplasmosis, 457  
South America  
  and histoplasmosis, 457  
  and lymphogranuloma venereum, 522  
  and murine typhus, 234  
South American trypanosomiasis, 263-265  
  clinical manifestations, 264-265  
  diagnosis and treatment, 265  
Soviet Union  
  and biological warfare, 71, 73  
  and chemical warfare doctrine, 90  
  and Lyme disease, 311  
Spalteholz, 32  
Spanish-American War  
  and leprosy, 325  
Spiders, 175-178  
  black widow, 177-178  
  brown recluse, 176-177  
  Chiracanthium, 178  
  tarantulas, 178  
Sporotrichosis, 470-473  
  clinical manifestations, 470-472  
  clinical presentation, citations, 408  
  diagnosis, 472  
  epidemiology and distribution, 470  
  history, 470  
  treatment, 472-473  
Sri Lanka  
  and rhinosporidiosis, 480  
Stark, 357  
STDs  
  *See Sexually transmitted diseases (STDs)*  
Steere, A.C., 309  
Steroids  
  and contact dermatitis, 138-139  
Stinging insects, 168-169  
  bees, wasps, and hornets, 168  
  fire ants, 169  
Storrs, Eleanor, 325  
Stout, M., 4  
Streptocerciasis, 279  
Streptomycin  
  and leprosy, 346  
  *See also Drugs*  
Strongyloidiasis, 272-273  
  clinical manifestations, 273  
  diagnosis and treatment, 273  
Su-wen, 322  
Sulfur mustard and nitrogen mustard in chemical warfare,  
  90-91, 90-101, 101-104  
  complications, 104  
  decontamination, 101-102  
  pathophysiology of poisoning, 93-95  
  properties, 92-93  
  signs and symptoms, 95-101  
  structure, 90-92  
  treatment, traditional, 102-103, 104  
  treatment, unconventional, 103-104  
Sulzberger, M.B., 567  
Sunburn, 47-49  
Sunscreens  
  and contact dermatitis, 125  
Surgery, for cutaneous trauma, 149-154  
  anesthesia, 150  
  complications, 153-154  
  technique, 150-151  
  wound dressings, 153  
  wound healing, 152-153  
Sverdlovsk (former U.S.S.R.)  
  and anthrax, 71, 84  
Sylvius, 357  
Synanthropy, 184  
Syphilis, 498-508  
  incidence, 499-500  
  clinical manifestations, 500-503  
  clinical presentation, citations, 408  
  laboratory diagnosis, 504-506  
  treatment, 506-508  
  latent syphilis of unknown duration, late latent  
  syphilis, and tertiary syphilis, 508  
  primary, secondary, and early latent syphilis, 506-508  
Systemic lupus erythematosus, 52

## T

- Dr. Tabuchi, 70  
Tabun, 105

- Tarantulas, 178
- Tartars  
and biological warfare, 71
- Tasker, A.N., 2
- Telangiectasia, 11
- Thailand  
and murine typhus, 233, 234
- Thalidomide  
and leprosy, 345  
*See also* Drugs; Management
- Thatcher, James, 22
- Theodoric of Cervia, 324
- Thothmes IV, 321
- Threadworm, 272
- Tiberius, 322
- Tick paralysis  
and mites and ticks, 189-190
- Tick-bite alopecia  
and mites and ticks, 190
- Tick-bite reactions  
and mites and ticks, 190
- Ticks  
*See* Mites and ticks
- Timorian filariasis, 275
- Timpe, A., 392, 394, 398
- Tinea barbae, 428
- Tinea capitis, 426-428
- Tinea corporis, 428-430
- Tinea cruris, 117, 430
- Tinea faciei, 429
- Tinea imbricata, 429-430
- Tinea manuum, 431
- Tinea nigra, 447-448
- Tinea pedis, 430-431
- Tinea unguium, 432-433
- Tompkins, E.A., 506
- Topical drugs  
and contact dermatitis, 123-125
- Training  
and military dermatology, 4-5, 6
- Travis, Richard T., 75-76
- Trematodes, 269  
*See also* Helminthic infections
- Trench fever, 215, 237-238  
clinical findings, 238  
diagnosis and treatment, 238  
epidemiology, vectors, and host, 237-238  
microbiology, 237  
prevention and control, 238
- Trench foot, 22, 34, 57-62
- Treponemal tests  
and false-positive reactions, 507  
for syphilis, 505-506  
*See also* Nontreponemal tests
- Trichinella spiralis*  
and trichinosis, 280
- Trichinosis, 280  
clinical manifestations, 280  
diagnosis, 280  
treatment, 280
- Trichothecene toxicosis, stages, 88
- Tropical acne  
and heat and humidity, 44-45
- Tropical diseases  
*See* Parasitic infections, tropical
- Tropical immersion foot, 64-66
- True bugs, 161-162
- Trunk  
and contact dermatitis, 136
- Trypanosomiasis  
African, 266-268  
South American, 263-265
- Tsui Yen, 323
- Tuberculids, 380-384  
erythema induratum, 380-382  
lichen scrofulosorum, 383-384  
papulonecrotic, 382-383
- Tuberculosis  
and acquired immunodeficiency syndrome (AIDS), 376, 377, 379  
clinical presentation, citations, 408  
*See also* Tuberculosis, cutaneous
- Tuberculosis, cutaneous, 355-389  
bacteriology, 363  
classification, 364-375  
control, among refugees, 379-380  
diagnosis, 375-376  
epidemiology, 361-363  
histopathology, 363-364  
history, 356-361  
introduction, 356  
pathogenesis, 366  
prevention, 378-379  
treatment, 376-378  
and tuberculids, 380-384  
*See also* Tuberculosis
- Tuberculosis cutis orificialis, 371  
clinical and diagnostic features, 371  
epidemiology, 371
- Tuberculosis fungosa serpiginosa, 375
- Tuberculosis verrucosa cutis, 368-369  
clinical features, 368  
course and prognosis, 368  
differential diagnosis, 368-369  
epidemiology, 368  
laboratory and histological features, 368
- Tuberculous gumma, 374-375
- Tuberculous mastitis, 375
- Tularemia, 299-301  
in biological warfare, 84  
clinical manifestations, 300-301  
clinical presentation, citations, 408  
diagnosis, 301  
epidemiology, 300  
etiology, 300  
treatment, 301
- Tumor, 9
- Tunga penetrans*, 192
- Tungiasis  
and fleas, 192-193
- Typhus  
*See* Endemic typhus; Epidemic typhus; Recrudescence typhus; Scrub typhus

## U

- U.S. military  
and leprosy, 325-326
- USS *John Harvey*, 75
- Uganda  
and atypical mycobacterial infections, 412
- Ulcer, 10
- Ultraviolet-B phototherapy  
in treatment of psoriasis, 560

United States  
  and murine typhus, 234  
Unna, Paul Gerson, 32, 321, 324, 360  
Urethritis  
  and gonorrhea, 508-509  
Urticaria, 568-572  
  causes, 572  
  cholinergic, 570  
  clinical features, 568-569  
  contact, 134, 570  
  diagnosis, 571  
  hereditary angioedema, 570  
  from histamine-releasing agents, 570-571  
  idiopathic, 571  
  immunoglobulin E-mediated, 571  
  military considerations, 572  
  physical, 569-570  
  treatment, 571-572  
  vasculitis, 570

**V**

Vaccine  
  against leprosy, 351  
  against meningococcal infections, 308  
  against plague, 296  
  *See also* Immunization  
Valentine, 324  
Valsalva, 357  
Vasculitis, urticarial, 570  
Vectors of disease, 183-194  
  bedbugs, 193-194  
  biting flies, 194  
  fleas, 190-193  
  lice, 193  
  mites and ticks, 185-190  
Vesicant Workshop, 75  
Vesicants, arsenical  
  in chemical warfare, 101  
Vesicle, 8  
  grouped, 12  
Vietnam conflict  
  and atypical mycobacterial infections, 396  
  and candidosis, 438  
  and chancroid, 515  
  and dermatologic disease, 158  
  and dyshidrotic eczema, 45-46  
  and heat injuries, 40  
  and immersion foot, 57, 63  
  and leprosy, 326  
  and meningococcal disease, 306  
  and military dermatology, 3-4  
  and murine typhus, 233  
  and pyodermas, 292  
  and schistosomiasis, 281  
  and sexually transmitted diseases, 497-498  
  and skin diseases, 3, 396  
  and tuberculosis, 361  
Vieusseaux, 305  
Villemin, Jean Antoine, 358  
Viral culture  
  of genital herpes, 528  
Viral hemorrhagic fevers  
  *See* Hemorrhagic fevers, viral  
Viral infections, cutaneous, 575-584  
  herpes simplex labialis, 575-577  
  herpes zoster, 577-580  
  military considerations, 584

  molluscum contagiosum, 580-581  
  warts, 581-584  
Virchow, 357  
Viruses  
  associated with hemorrhagic fevers, 199  
von Aue, Hartmann, 324  
Von Behring, 302  
von Hebra, Ferdinand, 383  
von Pirquet, Clemens, 360  
von Prowazek, Stanislaus, 229

**W**

Wade, 324  
Warm water immersion foot, 66  
Warts, 581-584  
  clinical features, 581-583  
  diagnosis, 583  
  military considerations, 584  
  treatment, 583-584  
Warts, common, 581  
Wasps  
  *See* Bees, wasps, and hornets  
Waterhouse-Friderichsen syndrome, 307  
Weather  
  and heat loss, 26  
Weichselbaum, 305  
Weigert, 358  
West Africa  
  and yellow fever, 201  
Wheal, 9  
Wherry, W.B., 299-300  
White piedra, 448-449  
Whitehead, 11  
Willis, I., 65  
Wilson, Erasmus, 561  
Women  
  and coccidioidomycosis, 461  
  and disseminated gonococcal infection, 510  
  and gonorrhea, 509  
  and nickel dermatitis, 126-127  
  and solar urticaria  
  *See also* Men; Sex differences  
Woodward, T.E., 309  
Woolhandler, H.W., 112  
World Health Organization (WHO)  
  estimates on leprosy prevalence, 326  
  guidelines for treating leprosy, 344  
World War I  
  and biological warfare, 71  
  and cold injuries, 22  
  and dermatologic disease, 158  
  and footwear, 56  
  and leprosy, 325  
  and meningococcal disease, 306  
  and military dermatology, 2  
  and mustard exposure, 95  
  and pyodermas, 292  
  and sexually transmitted diseases, 497  
  and trench foot, 23  
  and tuberculosis, 360  
  and typhus, 230  
World War II  
  and biological warfare, 71  
  and combat boots, 56  
  and dermatologic disease, 158  
  and diphtheria, 302  
  and heat injuries, 40

- and hypohidrosis syndrome, 44
  - and immersion foot, 63
  - and leprosy, 325-326
  - and meningococcal disease, 306
  - and miliaria, 41-42
  - and military dermatology, 3
  - and murine typhus, 233
  - and mycotoxins, 87
  - and pyodermas, 292
  - and relapsing fever, 188
  - and rickettsial diseases, 230
  - and schistosomiasis, 281
  - and sexually transmitted diseases, 497
  - and topical drug overtreatment, 123
  - and tuberculosis, 360-361
  - and trench foot, 23
  - Wound contraction
    - in healing, 152
  - Wound dressings, for cutaneous trauma, 153
  - Wound healing, 152-153
    - epidermization, 152-153
    - fibroplasia and wound contraction, 152
    - granulation, 152
    - inflammation, 152
    - maturation, 153
  - Wright, 257
  - Wuchereria bancrofti*, 274
    - See also Bancroftian filariasis
- X**
- Xerxes I, 321
- Y**
- Yaws
    - clinical presentation, citations, 408
  - Yellow fever, 200-202
    - laboratory findings and treatment, 201-202
    - signs and symptoms, 201
  - Yemen
    - and onchocerciasis, 277, 278
  - Yersin, 296, 302
  - Yersinia pestis*, 84, 192, 296
  - Yperite, 90
- Z**
- Zaire
    - and atypical mycobacterial infections, 412
  - Ziehl, 358
  - Ziemssen, v.H., 356

